

Date:

SIMPLE COLUMNAR EPITHELIUM WITH BRUSH/STRIATED BORDER**SPECIFIC LEARNING OBJECTIVES**

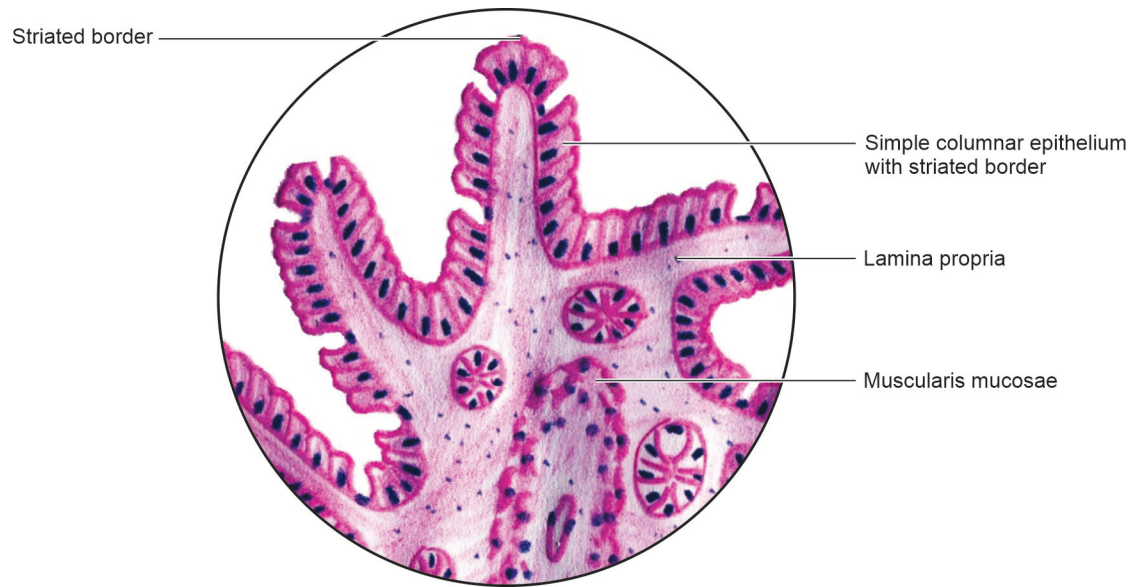
At the end of the session the student should be able to:

1. Describe the appearance of brush/striated border under light microscope.
2. Identify simple columnar epithelium with brush/striated border under light microscope.
3. Give examples of tissues with columnar epithelium with brush/striated border.
4. Describe the function of simple columnar epithelium with brush border.
5. Differentiate between brush border and striated border.
6. Explain what microvilli are.
7. Draw a diagram showing microanatomy of simple columnar epithelium with brush/striated border.

Distribution and function

Three points of identification

Date:



Simple columnar epithelium with striated border

