Cardiovascular Emergencies in India (An Overview)

Cardiovascular emergencies are life-threatening disorders that must be recognized immediately to avoid delay in treatment and to minimize morbidity and mortality. The terms like 'The Golden Hour' and the 'Platinum Ten Minutes' that typify the importance of emergency medical services (EMS) all over the world. It is a well-accepted fact that a patient who receives basic care from trained professionals and is transported to the nearest healthcare facility within 15–20 minutes of an emergency has the greatest chance of survival. EMS is an essential part of the overall healthcare system, as it saves lives by providing care immediately. It's this recognition that has led to research and development in EMS. Over the years several advancements have been made and research is underway to create services that provide medical assistance to patients at the earliest. However, the state of EMS varies drastically from developed to developing countries like India. In spite of the development in the healthcare sector over the past decade, India is yet to create a single, comprehensive EMS that can be accessed throughout the country.

Patients may present with severe hypertension, chest pain, dysrhythmia or cardiopulmonary arrest. It is estimated that by 2020, cardiovascular disease (CVD) will be the largest cause of disability and death in India. The country already has more than 118 million people with hypertension, which is expected to increase to 213 million by 2025. Within CVD, coronary heart disease (CHD) and congestive heart failure are major contributors to the disease burden. CHD has led to an estimated 23% of deaths across all age ranges and 32% of adult deaths from 2010 to 2013. In 2010, it was the leading cause of disability-adjusted life years worldwide (up from fourth in 1990 and increased by 29%).

In cardiac emergencies, ambulance based emergency medical services are the important link in the chain of survival. In view of the time sensitive interventions required in cardiac emergencies and anticipated growing burden of CVDs, such EMS services should be available throughout the country including rural areas on high priority.

Close monitoring of the response time of EMS is critical. Plans should be in place to further reduce the current response times. Training of emergency response officers and involvement of emergency response center physicians in cardiac emergencies may have higher survival rates and desired prognosis.

Bystander cardiopulmonary resuscitation (CPR), public access automatic external defibrillation (AED) and telephone CPR are strongly recommended in case of sudden cardiac arrest situations. Emergency medical techniques (EMT)



Fig. 1: Indoor and outdoor scenes of an emergency wing of one of the Indian hospitals including air and road ambulance services

education and re-education should remain to be a continuous endeavor. Protocol adherence by prehospital care providers and equity, reciprocity and competition (ERC) physicians in providing online medical direction, can reduce deaths and enable appropriate management of cardiac emergencies. Pre-arrival information including ECG transmission should be considered even in India at the earliest. Communities, EMS and hospital based care should have care continuum. Cardiac emergency education, training and research at basic and advanced levels of care should remain high in non-communicable diseases agenda at the national level.

Emergency medical services are an essential part of the overall healthcare system, as it saves lives by providing care immediately. These services are not limited to actual in-hospital treatment, from hospital arrival to stabilization, but include prehospital care and transportation. The World Health Organization regards EMS systems as an integral part of any effective and functional healthcare system. It is the first point of contact for the majority of people to health-care services during emergencies and life-threatening injuries and can connect people to necessary secondary and tertiary healthcare services. India faces a growing number of emergencies amenable to EMS care and requires a stronger EMS system. GVK Emergency Management and Research Institute (GVK EMRI) has been providing comprehensive emergency services, in partnership with various state governments, by running a single toll-free number 108 in 17 states and union territories across India. The aim of this study is to describe the epidemiology of suspected cardiac emergencies presenting to GVK EMRI across 11 states in India in 2015.

The importance of a reliable EMS cannot be over emphasised, especially in India where the government has the responsibility of caring for a majority of the population. It can be argued that a nation of a over billion people has been deprived of a decent EMS for too long now and it is high time the government takes definitive action. The success of a few services is evident enough of the need for EMS and what it will take to ensure that it works as expected. In a healthcare system that is sprouting and experiencing the benefits of involving private players, a public-private partnership framework could be the right way forward for policy-makers. At a time when the emphasis on preventing damage is greater than ever, the provision of prehospital care will be the key to ensure that lives are not lost due to avoidable circumstances.[*]

TYPES OF CARDIAC EMERGENCIES IN INDIA

Listed below are conditions that constitute a possible medical emergency and may require immediate first aid, emergency room care, surgery, or care by a physician or nurse. Not all medical emergencies are life-threatening; some conditions require medical attention in order to prevent significant and long-lasting effects on physical or mental health. However, comprehensive reviews of different cardiovascular emergencies has been done separately in this book (*see* chapters of this book).

Angina Pectoris

Although, James B. Herrick identified clinical features of angina as early as 1912, but William Heberden is still considered as the first person who drew attention of the world towards this condition for the first time in the history of medical science delivering his classical lecture on angina pectoris before the August audience of Royal College of Physician in 1968 in London Angina pectoris is the result of myocardial ischemia caused by an imbalance between myocardial blood supply and oxygen demand. Angina is a common presenting symptom (typically, chest pain) among patients with coronary artery disease. A comprehensive approach to diagnosis and to medical management of angina pectoris is an integral part of the daily responsibilities of physicians.

Acute Coronary Syndrome

Acute coronary syndrome (ACS) refers to a spectrum of clinical presentations ranging from those for ST-segment elevation myocardial infarction (STEMI) to presentations found in non-ST-segment elevation myocardial infarction (NSTEMI) or in unstable angina. In terms of pathology, ACS is almost always associated with rupture of an atherosclerotic plaque and partial or complete thrombosis of the infarct-related artery.

Percutaneous Coronary Interventions (Balloon Angioplasty and Stentoplasty)

Grüntzig's first successful coronary angioplasty treatment on a human was performed in 1977, in Zurich, Switzerland. He expanded a short, about 3 mm, non-branching section of the left anterior descending (LAD) artery (the front branch of the left coronary artery), which supplies the front wall and tip of the heart which had a high grade stenosis, about 80%, of the lumen. Dr Grüntzig presented the results of his first four angioplasty cases at the 1977 American Heart Association (AHA) meeting, which led to widespread acknowledgement of his pioneering work.

Acute Pulmonary Edema

Pulmonary edema is the term used when edema happens in the lungs. The immediate area outside of the small blood vessels in the lungs is occupied by very tiny air sacs called the alveoli. This is where oxygen from the air is picked up by the blood passing by, and carbon dioxide in the blood is passed into the alveoli to be exhaled out. Alveoli normally have a thin wall that allows for this air exchange, and fluids are usually kept out of the alveoli unless these walls lose their integrity. Pulmonary edema occurs when the alveoli fill up with excess fluid seeped out of the blood vessels in the lung instead of air. This can cause problems with the exchange of gas (oxygen and carbon dioxide), resulting in breathing difficulty and poor oxygenation of blood.

*Prasanthi P. "Emergency Services in India-Counting on betterment," Asian Hospital and Healthcare Management. Available from: *http://www.asianhhm.com/healthcare-management/emergency-services-india* [Last accessed on 2016 Jul 16].

Sometimes, this can be referred to as 'water in the lungs' when describing the condition to patients. Pulmonary edema can be caused by many different factors. It can be related to heart failure, called cardiogenic pulmonary edema, or related to other causes, referred to as non-cardiogenic pulmonary edema.

Heart Failure

Heart failure is the pathophysiologic state in which the heart, via an abnormality of cardiac function (detectable or not), fails to pump blood at a rate commensurate with the requirements of the metabolizing tissues or is able to do so only with an elevated diastolic filling pressure. Heart failure is a common condition, affecting up to 3 per cent of the population aged 45 and older, and is associated with high mortality and poor quality of life. Major diagnostic and therapeutic advances have been made over the past three decades, but international and national audits suggest that many patients are incompletely investigated and treated. Heart failure may be caused by myocardial failure but may also occur in the presence of near-normal cardiac function under conditions of high demand. Heart failure always causes circulatory failure, but the converse is not necessarily the case, because various noncardiac conditions (e.g. hypovolemic shock, septic shock) can produce circulatory failure in the presence of normal, modestly impaired, or even supranormal cardiac function.

Syncopal Attacks

Syncope is defined as a partial or complete loss of consciousness with interruption of awareness of oneself and ones surroundings. When the loss of consciousness is temporary and there is spontaneous recovery, it is referred to as syncope or, in nonmedical quarters, fainting. Syncope accounts for one in every 30 visits to an emergency room. It is pronounced sin-ko-pea.

Syncope is due to a temporary reduction in blood flow and, therefore, a shortage of oxygen to the brain. Determining that certain individuals are at 'low mortality risk' and often benign from a mortality perspective, tends to recur, is associated with risk of physical injury, diminishes quality-of-life and might lead to restriction from employment or avocation.

Cardiac Temponade

Cardiac tamponade is a medical emergency. Early diagnosis and treatment are crucial to reduce morbidity and mortality. Untreated, it is rapidly and universally fatal. Cardiac tamponade is a clinical syndrome caused by the accumulation of fluid in the pericardial space, resulting in reduced ventricular filling and subsequent hemodynamic compromise. Cardiac tamponade is a medical emergency. The overall risk of death depends on the speed of diagnosis, the treatment provided and the underlying cause of the tamponade.

Cardiac Arrhythmia

Arrhythmias may cause you to feel premature or extra heartbeats, or you may feel that your heart is racing or beating too slowly. Other signs and symptoms may be related to your heart not pumping effectively due to the fast or slow heartbeat. These include shortness of breath, weakness, dizziness, lightheadedness, fainting or near fainting and chest pain or discomfort.

Seek urgent medical care, if you suddenly or frequently experience any of these signs and symptoms at a time when you wouldn't expect to feel them. Ventricular fibrillation is one type of arrhythmia that can be deadly. It occurs when the heart beats with rapid, erratic electrical impulses. This causes pumping chambers in your heart (the ventricles) to quiver uselessly instead of pumping blood. Without an effective heartbeat, blood pressure plummets, cutting off blood supply to your vital organs.

Cardiopulmonary Arrest

Cardiopulmonary arrest is a sudden and unexpected loss of perfusing pulsatile blood flow attributable to cessation of cardiac mechanical activity. It occurs as a result of a multitude of cardiovascular, metabolic, infectious, neurologic, inflammatory and traumatic diseases. These diseases can be generally classified into '5 Hs' and '4 Ts' [Hypovolemia, Hypoxemia, Hydrogen ion (acidosis), Hypokalemia or Hyperkalemia, Hypothermia, Tension pneumothorax, Tamponade, Toxins and Thrombosis–both pulmonary and cardiac]. The endpoint of these disorders is commonly pulseless ventricular tachycardia (VT) or ventricular fibrillation (VF), pulseless electrical activity or asystole.

Hypertensive Emergency

A hypertensive emergency is an acute, severe elevation in blood pressure accompanied by end-organ compromise. It is usually associated with a systolic blood pressure (SBP) equal to or higher than 180 mmHg and/or a diastolic blood pressure (DBP) equal to or higher than 120 mmHg. End-organ compromise includes acute renal failure due to nephrosclerosis, ocular involvement with retinal exudates, hemorrhages, or papilledema, hypertensive encephalopathy, acute stroke or intracranial hemorrhage, acute myocardial infarction, aortic dissection and eclampsia. Hypertensive encephalopathy signals the presence of cerebral edema and loss of vascular integrity. If left untreated, hypertensive encephalopathy may progress to seizure and coma. Aortic dissection is associated with severe elevations in systemic blood pressure and wall stress, requiring immediate lowering of the blood pressure and emergent surgery for type-A dissection to reduce morbidity and mortality. Eclampsia, the second most common cause of maternal death, occurs from the second trimester to the peripartum period. It is characterized by the presence of seizures, coma, or both, in the setting of pre-eclampsia. Delivery remains its only cure.

Aortic Dissection

Aortic dissection is a tear of the aortic intima that allows the shear forces of blood flow to dissect the intima from the media and, in some cases, penetrate the diseased media

with resultant rupture and hemorrhage. 65% of dissections originate in the ascending aorta, 20% in the descending aorta, 10% in the aortic arch, and the remainder in the abdominal aorta. While some older classification systems of aortic dissection (such as Stanford and DeBakey) still exist and are used, they seem anachronistic in the current era of advanced imaging. The most commonly used old classification system is the Stanford system; a dissection that involves the ascending aorta is classified as type-A, and one that does not, only affecting the aorta distal to the left subclavian artery, is classified as type-B. Dissections are further classified by chronicity as acute (<2 weeks) or chronic (>2 weeks); mortality peaks at 80% after 2 weeks, and then levels off.

Cardiogenic Shock

Cardiogenic shock is a major, and frequently fatal complication of a variety of acute and chronic disorders, that impair the ability of the heart to maintain adequate tissue perfusion. Cardiac failure with cardiogenic shock continues to be a frustrating clinical problem; the management of this condition requires a rapid and well-organized approach. Cardiogenic shock is a physiologic state in which inadequate tissue perfusion results from cardiac dysfunction, most commonly following acute myocardial infarction (MI). Although ST-elevation MI (STEM, previously termed Q-wave MI) is encountered in most patients, cardiogenic shock may also develop in patients with non-ST-elevation acute coronary syndrome (NSTEMI, NSTACS or unstable angina).

Cardiac Valvular Emergencies

Chronic rheumatic valvular dysfunctions can lead to very high morbidity and mortality among patients unless they are helped with either reconstructive surgery or replacement of an artificial valve. Two types of artificial valves which are available today have their own limitations and till date there is no ideal valve which could closely resemble with natural valve in terms of cost and post-operative long term out come. Recently attempts have been made in constructing artificial heart valves with the help of stem cell modification and genetic engineering techniques though long term follow up is still awaited.

In developing countries, rheumatic process is so extensive that often more than one valves (multi-valvular) are affected which further complicates the final management of the patients besides the cost implications among poor patients.

Deep Vein Thrombosis and Pulmonary Embolism

Pulmonary embolism (PE) is a blockage of the main artery of the lung or one of its branches by a substance that has travelled from elsewhere in the body through the bloodstream (embolism). PE most commonly results from deep vein thrombosis (a blood clot in the deep veins of the legs or pelvis) that breaks off and migrates to the lung, a process termed venous thromboembolism (VTE). A small proportion of cases are caused by the embolization of air, fat, or talc in drugs of intravenous drug abusers or amniotic fluid.

Peripheral Vascular Disease and Endovascular Therapy

Peripheral vascular diseases (PVDs) are circulation disorders that affect blood vessels outside of the heart and brain. PVD typically strikes the veins and arteries that supply the arms, legs and organs located below your stomach. These are the blood vessels that are distant from the heart. They are known as peripheral vessels. In PVD, blood vessels are narrowed. Narrowing is usually caused by arteriosclerosis. Arteriosclerosis is a condition, where plaque builds up inside a vessel. It is also called 'hardening of the arteries.' Plaque decreases the amount of blood and oxygen supplied to the arms and legs. As plaque growth progresses, clots may develop. This further restricts the affected vessel. Eventually, arteries can become obstructed. PVD that develops only in the arteries is called peripheral arterial disease (PAD). This is the most common form of PVD. Approximately, 12–20% of people over age 65 have PAD. PVD that develops in the deep veins in the body is usually caused from claudication and is called deep vein thrombosis (DVT) Aggressive treatment of existing conditions that may aggravate PVD, such as diabetes, hypertension, and hyperlipidemia (elevated blood cholesterol). Medications for improving blood flow, such as antiplatelet agents (blood thinners) and medications that relax the blood vessel walls Some cases who do not responde to medical therapy, are subjected to catheter/laser based endovascular therapy.

Extracorporeal Membrane Oxygenation Support in Critically Ill Patients

The term extracorporeal membrane oxygenation (ECMO) was initially used to describe long-term extracorporeal support that focused on the function of oxygenation. Subsequently, in some patients, the emphasis shifted to carbon dioxide removal, and the term extracorporeal carbon dioxide removal was coined. Extracorporeal support was later used for postoperative support in patients following cardiac surgery. Other variations of its capabilities have been tested and used over the last few years, making it an important tool in the armamentarium of life and organ support measures for clinicians. With all of these uses for extracorporeal circuitry, a new term, extracorporeal life support (ECLS), has come into vogue to describe this technology. In emergency medicine, ECMO is an extracorporeal technique of providing both cardiac and respiratory support oxygen to patients whose heart and lungs are so severely diseased or damaged that they can no longer serve their function. Initial cannulation of a patient receiving ECMO is performed by a surgeon and maintenance of the patient is the responsibility of the ECMO specialist and gives 24/7 monitoring care for the duration of the ECMO treatment.

First Heart Transplant in India

AIIMS is the first Indian center to perform a successful cardiac transplant. The surgery was performed by Dr Panangipalli Venugopal, the ex-director of AIIMS in 1994. The Organ Transplant Bill 1994, was passed in the Indian Parliament in May 1994, which legalized the organ transplants in India. The Bill was on the Table of the President of India for final approval when Dr Venugopal led a team of doctors to perform the first successful heart transplant in India on 3 August 1994. This was the first of the 26 heart transplant procedures performed by Dr Venugopal. Another heart surgeon from India, i.e. Dr K M Cherian performed the first coronary artery bypass surgery in India in 1975. He also performed the country's first heart transplant, first infant cardiac surgery and the first heart and lung transplant (1999). Pioneering pediatric cardiac surgery in India, Cherian has pioneered the first coronary artery bypass surgery in India, as well as the first heart transplant after the legislation of Brain Death in India; the first bilateral lung transplant; the first pediatric heart transplant; the first auto-transplant; and the first heart and lung transplant (1999).

Emergencies Among Patients on Anticoagulant Therapies

Thromboembolism is a common complication of heart disease. The decision to prescribe an anticoagulant to prevent thromboemboli should be based on a particular patient's risk without treatment and the likely benefit and side effects of the proposed treatment. In this article, we will discuss the use of warfarin and heparin in patients with heart disease.

- Whether anticoagulant treatment should be started depends on the balance between the risk of thromboemboli without treatment and the likely benefits of treatment in each patient.
- Factors increasing the risk of bleeding include serious concomitant disease, previous gastrointestinal bleeding, uncontrolled hypertension and immobility.
- Factors that cumulatively increase the risk of thromboembolism in non-rheumatic atrial fibrillation include age over 60, recent congestive heart failure, hypertension (treated or untreated), previous thromboembolism, and the presence of a large atrium or of global left ventricular dysfunction.
- Cardioversion of non-rheumatic atrial fibrillation (including fibrillation of new onset) is associated with an increased thromboembolic risk, which is reduced by anticoagulant treatment.
- Heparin and aspirin are both beneficial in unstable angina.
- Anticoagulants should be considered after myocardial infarction in patients with an increased risk of thromboemboli—patients in atrial fibrillation and those with persistent heart failure.

K C Verma

1 History Taking, Symptoms, Signs and Investigations in a Heart Patient (An Overview)

In order to arrive at an accurate diagnosis of heart disease among patients, it is important for the physician/cardiologist to follow the set clinical procedures of extracting accurate clinical history, thorough clinical examination supported with basic biochemical investigation. This provisional diagnosis is further confirmed with the help of specialised invasive techniques, such as cardiac catheterisation and angiocardiography and noninvasive tests like echocardiography, CMRI and MD/CT. The following are the different clinical and investigative steps which could help physician/cardiologist to arrive at a correct diagnosis.

HISTORY TAKING

BEDSIDE HISTORY

A painstaking and problem-oriented history taking is often helpful in the diagnosis. Family history and attention to pertinent symptomatology in the various age-groups, such as cyanosis, poor feeding, tachypnoea and orthopnea, cyanotic spells, squatting, growth retardation, easy fatigability, recurrent pneumonia and congestive failure, may offer clues for the presence of heart disease. It is necessary to establish whether the disease is congenital or acquired. This can be achieved by a good history and a well conducted physical examination (Fig. 1.1).

The presence of a murmur especially below the age of 1 year, cyanosis and parasternal murmurs are suggestive of congenital heart disease. Even apical murmurs do not exclude the presence of congenital heart disease and have to be carefully evaluated.

History of Rheumatic Fever

1. Chorea twitches or clumsiness for a few months in childhood. Epistaxis. Frequent sore throats. Tonsillectomy and adenoidectomy.



Fig. 1.1: Doctor examining an adolescent admitted with recurrent palpitation

2. Growing pains (i.e. nocturnal pains or aches in the legs). (Arthritis or other joint involvement in daytime suggests rheumatic fever.)
3. Was the diagnosis of rheumatic fever based merely on signs of fever and murmur or were actually red swollen, painful joints and rash?
4. What was the therapy given? (Aspirin, steroids, prophylactic penicillin and prolonged bed rest.)
5. Is there a family history of rheumatic fever? (This is almost as suggestive of a rheumatic origin of a patient's murmur as a history of rheumatic fever in the patient.)

History of Rheumatic Heart Disease

1. Murmurs heard on previous examination (school, operation, hospitalization, insurance or military service).
2. Carditis with Caray-Coombs murmur and rheumatic nodules (Fig. 1.2).
3. Results of cardiac catheterization. When and where was it done?

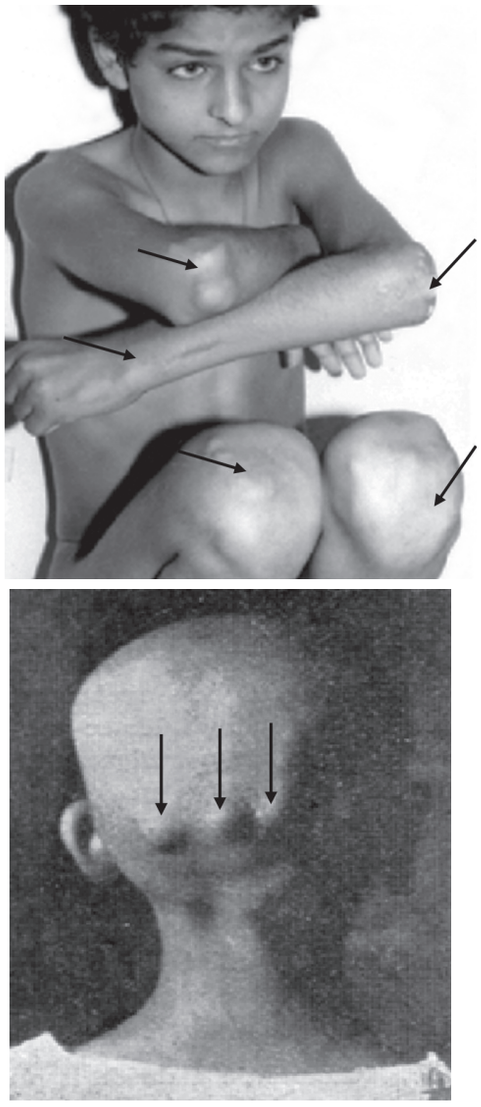

Fig. 1.2: Multiple rheumatic nodules over both elbows, wrist, knee joints and occiput regions in active rheumatic fever

Complications of Rheumatic Heart Disease

1. In the presence of mitral disease
   a. Hemoptysis: Is it mixed or pure? Quantity, color and frequency. (If this occurs with dyspnea or pleuritic pain, consider pulmonary infarction. If it arises from the submucosal bronchial veins, the blood is dark, and the cause is usually raised left atrial pressure due to mitral stenosis).
   b. Hoarseness of voice: Without obvious upper respiratory infection? The cardio-vocal syndrome, due to the pressure of a large left atrium on an enlarged pulmonary artery, which in turn may press on the peribronchial lymph nodes to compress the recurrent laryngeal nerve. Dysphagia may be due to both pressure by a large left atrium and stretch of the autonomic fibers to the esophagus.
   c. Winter bronchitis or wheezing.
   d. Ruptured chordae tendinae suggested by sudden worsening of dyspnea orthopnea, or paroxysmal nocturnal dyspnea (PND).
   e. Embolic phenomena: Hematuria, pleurisy and unilateral weakness. Sudden loss of vision or loss in one visual field of one eye.
2. In the presence of aortic stenosis, angina, exertional syncope, or dyspnea (a classic triad).
3. In the presence of aortic regurgitation nocturnal angina [but is a sign of vasospastic angina if no aortic regurgiatation (AR)].
4. Awareness of large pulsations in arms, neck or cheek.
5. Epilepsy (increased incidence with mitral stenosis).
6. Possible infective endocarditis (Fig. 1.3).
   a. Fever and night sweats (enough to require change of pajamas).
   b. Tooth extraction or cleaning or other possible causes of bacteremia.
   c. Prolonged treatment with penicillin or other antibiotic.
   d. Embolic phenomena, hematuria, back pain, splinter hemorrhages, petechiae, tender finger pads, or cerebro-vascular accident (unilateral weakness, paralysis or speech difficulty).
   e. Seagull murmur usually is indicative of aortic valvulitis.

Could it be a Congenital Heart Disease?

To be asked, if patient is an infant.

1. Growth and development: High birth weight suggests transposition of the great vessels.
2. Mother's pregnancy:
   a. Stilbestrol in pregnancy has been linked to transposition of great vessels.
   b. Viral illness

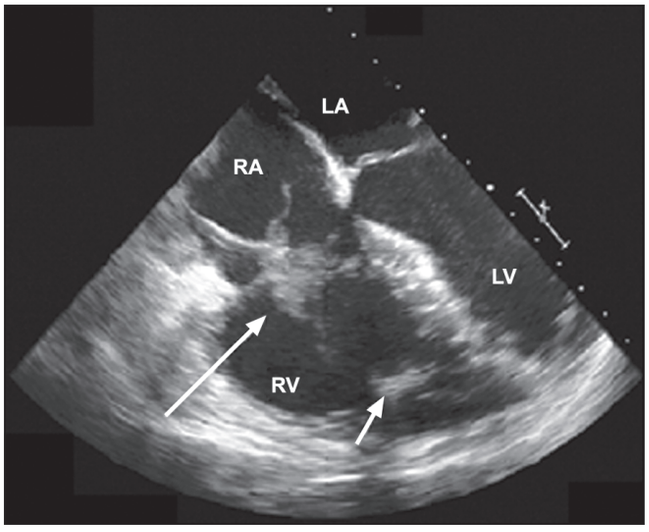

Fig. 1.3: Transesophageal echocardiography—4-chamber view shows multiple vegetations on the tricuspid valve (long arrow) and pacing leads (short arrow)

c. Diabetes in pregnancy suggests transposition of great vessels combined with high birth weight.

3. Frequent pneumonias.
4. Excessive sweating. Asthmatic attacks in newborn.
5. Has mother been aware of infant's heart beating against chest wall or the vibrations or a thrill?

To be Asked if Patient is a Child or Adult

1. *Mother's pregnancy:* Rubella in first trimester.
2. *Family history:* Congenital heart disease or murmur in family.
3. *Cyanosis:* When did it begin? [Cyanosis either from birth or within a few days of birth, suggests transposition of the great vessels (TGV)]. Delayed for years and associated with palpitations suggests Ebstein's anomaly, especially if present with little dyspnoea on exertion (DOE). If delayed until adolescence of middle age, suggests atrial septal defect with Eisenmenger's reaction or syndrome. Does it occur with crying, feeding or warm bath or only with syncope? (Suggests tetralogy of Fallot.) Differential cyanosis and clubbing suggests patent ductus arteriosus with Eisenmenger's syndrome, especially if there is unexpectedly little DOE. Frequent phlebotomies.
4. *Syncope or faintness:* Do these signs occur on exposure to cold or only during effort or excitement? (Sugggests primary pulmonary hypertension.) With straining, after a long sleep and with cyanosis? (Suggests tetralogy of Fallot or complete atrioventricular block.) Only with effort (suggests severe aortic stenosis, pulmonary stenosis, or primary pulmonary hypertension).
5. Angina (suggests severe aortic or pulmonary stenosis)
6. Exact day the murmur was first heard. (Stenotic murmurs are heard in newborn nursery; left-to-right shunt murmurs are often delayed a few weeks.) Was it discovered by a physician who had seen the patient before or by a physician seeing the patient for the first time?
7. *Squatting or knee-chest position frequent* (suggests decreased pulmonary flow due to tetralogy or Fallot or more rarely, due to tricuspid atresia).
8. Headaches, epistaxis, leg fatigue or aches after exercise, cold legs, or claudication (suggests aortic coarctation. Epistaxis alone suggests rheumatic fever).
9. When and where was cardiac catheterization done?
10. *Dysphagia* (consider coarctation, with the right subclavian artery passing behind the esophagus).
11. *Awareness of pulsations in the neck* (consider coarctation, aortic regurgitation, thyrotoxicosis or the venous pulsations or gaint A waves in primary pulmonary hypertension or severe pulmonary stenosis).
12. *Strokes* (consider emboli from endoardial fibroelastosis if patient is an infant or emboli from idiopathic cardiomyopathy if patient is a child. May be due to paradoxical emboli or cerebral abscess if patient is cyanotic. Somnolence with cyanosis suggests cerebral abscess).
13. *Hoarseness of voice* (suggests primary pulmonary hypertension or large patent ductus arteriosus).
14. *Surgery:* When, where and by whom? What were the symptomatic results?
15. *Mental retardation* (consider Down's syndrome or supravalvular aortic stenosis).
16. *Swelling, pain, warmth and tenderness of lower extremities* (hypertrophic osteo-orthropathy suggests patent ductus arteriosus with Eisenmenger's syndrome).
17. Recurrent bleeding from the nose, lips or mouth with hemoptysis or melena, multiple cerebral symptoms such as dizziness and visual disturbances and a family history of epistaxis (this complex of symptoms comprises hereditary hemorrhagic telangiectasis or Rendu-Osler-Weber disease and suggests a pulmonary arteriovenous fistula, especially if the patient is cyanotic)
18. *Weakness and incoordination* (suggests the cardiomyopathy of Friedreich's ataxia or muscular dystrophy).

SPLINTER HEMORRHAGES

Splinter hemorrhages (or haemorrhages) are tiny lines that run vertically under nails (Fig. 1.4). Splinter hemorrhage is a nonspecific finding and can be associated with subacute bacterial endocarditis, scleroderma, trichinosis, systemic lupus erythematosus (SLE), rheumatoid arthritis, psoriatic nails, antiphospholipid syndrome, and trauma. At first they are usually plum-colored, but then darken to brown or black in a couple of days. In certain conditions (in particular, infective endocarditis), clots can migrate from the affected heart valve and find their way into various parts of the body. If this happens in the finger, it can cause damage to the capillaries resulting in a splinter hemorrhage.

There are a number of other causes for splinter hemorrhages.

They could be due to hitting the nail ('trauma'), a sign of inflammation in blood vessels all around the body ('systemic vasculitis'), or they could be where a bit of



Fig. 1.4: Thumb showing splinter hemorrhage under nail in patient with infective endocarditis

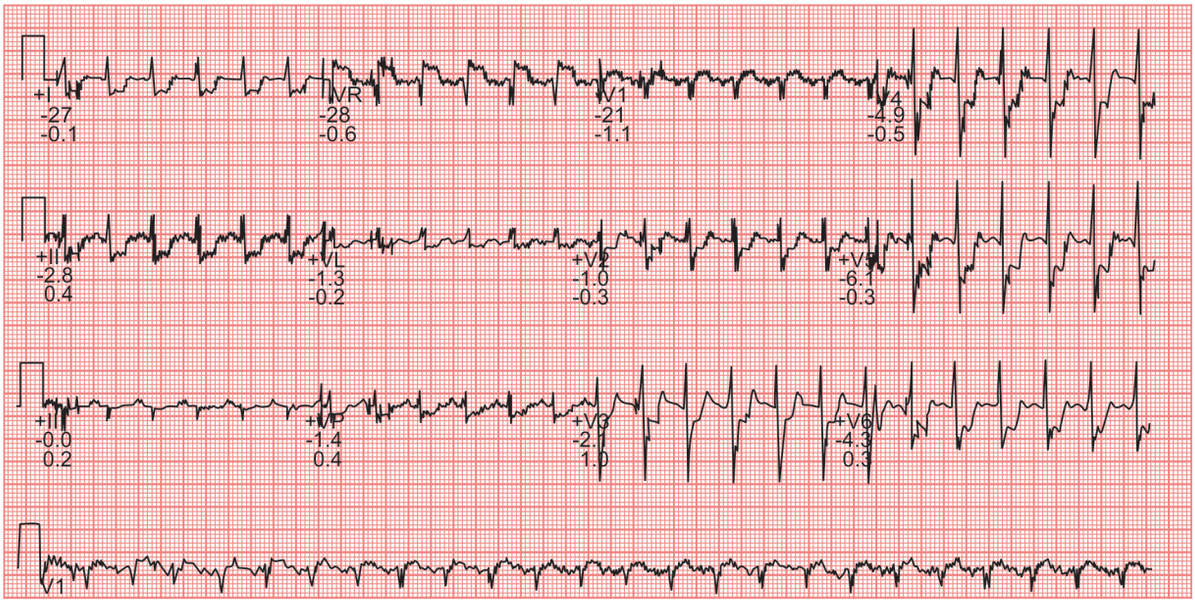

Fig. 1.5: ST-depression in leads 1, 11, aVF and V3–V6 strongly positive TMT in a patient with cardiac syndrome X

cholesterol has got lodged in the finger's capillaries. Even if a patient does have infective endocarditis, probably 5 in every 6 patients won't have splinter hemorrhages.

CARDIAC SYNDROME X (ANGINA WITH NORMAL CORONARY ARTERIES)

Cardiac syndrome X (CSX) (not to be confused with metabolic syndrome X, or metabolic syndrome) is the name given to a clinical condition which produces angina-like chest pain, often with signs of cardiac ischemia (i.e. poor blood flow in the heart muscle) in the absence of coronary artery disease (Figs 1.5 and 1.6). The chief characteristics of CSX are as follows:

- Angina-line chest pain during exertion
- Characteristic ECG changes during exercise testing
- Normal coronary arteries on cardiac catheterization
- No inducible coronary artery spasm during catheterization

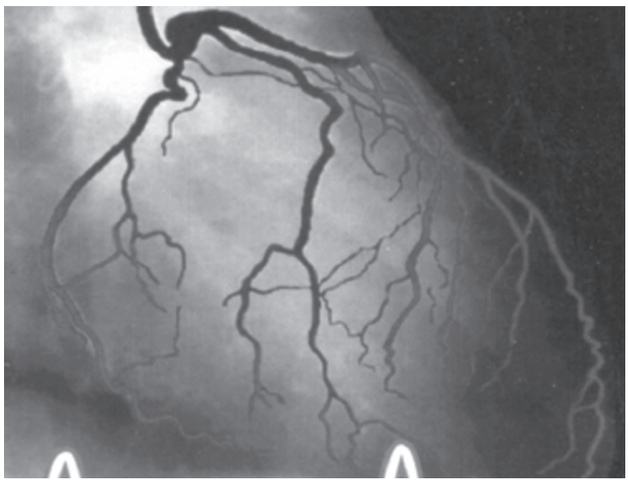

Fig. 1.6: Angiogram showing normal coronary vessels in a patient with chest pain in syndrome X with positive TMT results

INTERMITTENT CLAUDICATION

Intermittent claudication (*Latin:* claudicatio intermittens) is a clinical diagnosis given for muscle pain (ache, cramp, numbness or sense of fatigue), classically in the calf muscle, which occurs during exercise and is relieved by a short period of rest (Fig. 1.7). Claudication derives from the *Latin* verb claudicare, 'to limp'.

Signs

One of the hallmarks of arterial claudication is that, it occurs intermittently. It disappears after a brief rest and the patient can start walking again until the pain recurs. The following are the general signs of atherosclerosis of the lower extremity arteries:

- Cyanosis
- Atrophic changes like loss of hair, shiny skin
- Decreased temperature
- Decreased pulse
- Redness when limb is returned to a 'dependent' position

All the 'Ps' are

1. Increase in Pallor
2. Decrease in Pulses
3. Perishing cold
4. Pain
5. Paraesthesia
6. Paralysis

Causes

Most commonly, intermittent (or vascular or venous) claudication is due to peripheral arterial disease which

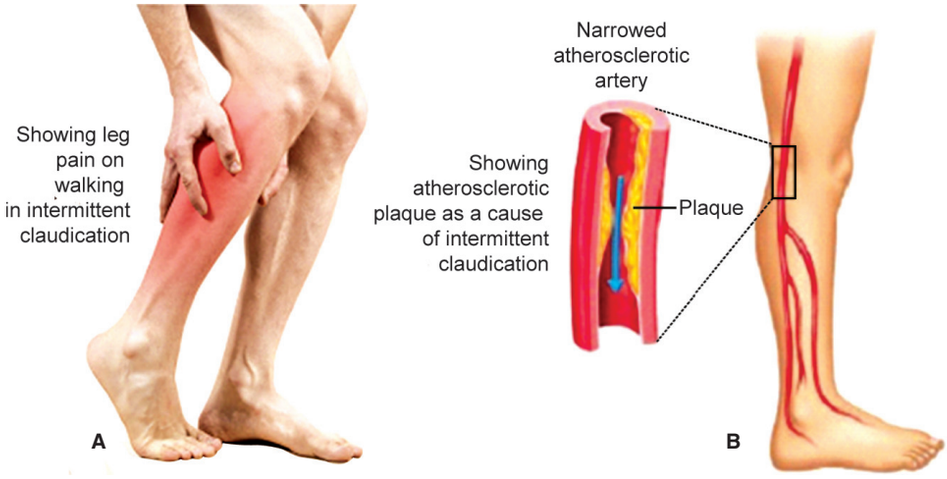

Fig. 1.7: (A) Patient is feeling severe leg pain during walking. (B) Atherosclerotic obstruction as a cause of intermittent claudication

implies significant atherosclerotic blockages resulting in arterial insufficiency. It is distinct from neurogenic claudication, which is associated with lumbar spinal stenosis.

Epidemiology

Atherosclerosis affects up to 10% of the western population older than 65 years and for intermittent claudication this number is around 5%. Intermittent claudication most commonly manifests in men older than 50 years.

Peripheral, Venous Congestion or Pseudo-right Heart Failure Possibilities

1. *Peripheral edema:* Maximum and minimum weight. Reasons for any weight gain or loss.
2. *Ascites* (if this occurs before or simultaneously with orthopnea or dyspnea, consider tamponade)
3. *Upper abdominal pain, especially on exercise* (this suggests increased stretch of liver capsule due to hepatomegaly.)
4. *Bending or stooping discomfort* (suggests hepatomegaly)
5. Positive hepato-jugular reflux.

Low Output State Possibilities

1. *Weakness and fatigue:* Do these occur only in the morning (depression)? Is afternoon nap necessary? If these signs occur only in the afternoon, they suggest low blood sugar or hypothyroidism. Is the patient on drugs that would cause weakness (i.e. digitalis, diuretics, β-blockers, or tranquilizers)? Is there only psychoneurotic basis (relationship to family, spouse, work supervisor)? Is the patient taking a contraceptive pill, diphenylhydantion and spironolactone?
2. *Coldness of extremities:* For how long?
3. *Excessive perspiration* (a common sign of failure in infants. If recent in an adult and not due to hyperthyroidism or neurosis; it suggests severe failure. With warm hands, it suggests thyrotoxicosis; with cold hands it suggests psychoneurosis or heart failure.)
4. Insomnia due to hyperpnea on going to sleep or dozing. It should be asked to his wife or closely associated family member.
5. Nocturia with polyuria.

Possibilities of Fixed Output State

1. Syncope, faintness or dizzines.
2. Chest pain tightness, pressure or discomfort. Could it be a high out put failure?
   a. Anemia
      i. Has the patient ever been told that he has anemia? Pins and needles? Bleeding from menorrhagia, hemorrhoids, or ulcers. Is anemia being treated?
      ii. Bone marrow or metabolic disorders; upper GIT surgery in the past (leading to B12 deficiency), sickle cell disease in self or family, contact with lead or radiation.
   b. Thyrotoxicosis
   c. Beriberi

EXPLORING HYPERTENSIVE HEART DISEASE

1. When was the patient first told? Under what circumstances was it discovered?
2. Has treatment been taken regularly? What drugs in what dosage have been taken?
3. Has there been a previous kidney infection or nephritis, or back injury in sport or accident?
4. Frequency of urination or nocturia, polyuria, kidney X-rays, renal calculi, gout, severe diabetes.
5. Family history of hypertension. At what age the patient was told?
6. Coarctation of aorta; cold legs or intermittent claudication, nosebleeds, shoulder girdle pains. Have angiograms been done?

7. Pheochromocytoma; flushing with pounding headaches, dizziness, sweating, palpitations, nausea, chest pain and paresthesia. Weight loss. Elevated blood sugar.
8. Cushing syndrome hirsutism, corticosteroid intake, easy bruising slow wound healing, acne, muscle weakness, kidney stones, emotional unstability or depression.
9. Past blood pressure reading. Visual problems, convulsions, strokes, head aches, dyspnea on exertion, orthopnea, post-nasal drip (PND) or epistaxis.
10. Known X-ray or EKG abnormalities.
11. Amount of success of medical or surgical therapy
12. Metabolic syndrome and obesity
13. Side effects of treatment; muscle aches and pains, weakness, sleepiness, postural hypotension, nausea, nasal stuffiness, impotence or palpitation.

ENQUIRING FOR COR PULMONALE

1. Chronic obstructive pulmonary disease; pulmonary function tests. Easier to breathe leaning forward? Smoking history. Chronic cough and sputum.
2. Asthma, wheezing or dyspnea relieved by bronchodilators.
3. Ever worked in a soft or hard coal mine.
4. Pulmonary emboli. History of phlebitis. Marked diuresis with diuretics. On contraceptive pills. Ever sudden dyspnea at rest with palpitations pleurisy, faintness, cold sweat, or hemoptysis. Recurrent stabbing groin pains. Recent trauma or surgery. Pregnancy or long automobile trip.
5. History of lung infiltrate or tuberculosis.
6. Bilateral rales over the bases of the chest.

CARDIAC CHAMBER ENLARGEMENT POSSIBILITIES

1. Trepopnea (certain positions in bed cause discomfort).
2. Palpitations or awareness of heart beat.
3. Has patient been told of an enlarged heart? When was he first told? If yes, was it after an ECG or X-ray or echocardiogram. Where and when done?
4. Has an X-ray examination been done? When and where was first and last one done?

HOW TO KNOW ABOUT PAST CARDIAC SURGERY?

1. Date and place of surgery. Type of operation or prosthesis. Name of surgeon.
2. Heart failure or other cardiac symptoms present before surgery. Which symptoms were present, and for how long?
3. Was patient catheterized before or after surgery? Was he told about the results of the studies?
4. Complications after surgery; embolic phenomenon, infections or other.
5. What treatment was given after surgery (anti-coagulants, digitalis, diuretics)? For how long? (Fig. 1.8)



Fig. 1.8: Ecchymosis over the legs in an adolescent patient with consumption of anticoagulants after corrective surgery

PERICARDITIS, EFFUSION CONSTRICTION OR TAMPONADE POSSIBILITIES

History of chest trauma, recent heart surgery. (The postcardiotomy syndrome, fever, pleurisy, pericarditis and polyserositis may occur as long as 2 months after heart surgery). Myocardial infarction (Dressler's syndrome, which is the same as postcardiotomy syndrome but follows myocardial infarction, now extremely rare), radiation to chest in past few months, uremia, metastatic cancer, lymphoma, leukemia, myxedema, scleroderma, lupus, rheumatoid arthritis, and contact with tuberculosis, or recent viral infection Is patient taking drugs that would produce lupus erythematosus syndrome procainamide, hydralazine, penicillin and isoniazid? Is he on drug, like minoxidil? (Fig. 1.9)

Symptoms of Pericarditis

1. Chest pain on exertion, swallowing or deep breathing.
2. Joint symptoms (with facial rash suggests possible lupus erythematosus; with rash on limbs or body, rheumatic fever).
3. Past history of pericarditis (in about one-fourth of cases idiopathic pericarditis is recurrent).
4. Epigastric pain for 1–3 days before the chest pain (this is the initial manifestation in one-third of patients with acute idiopathic pericarditis. Pain may occur alone in the abdomen).

Symptoms of Tamponade

1. Dyspnea on exertion (DOE).
2. Edema or ascites preceding dyspnea. Abdominal swelling before or simultaneous with edema (highly suggestive of tamponade).

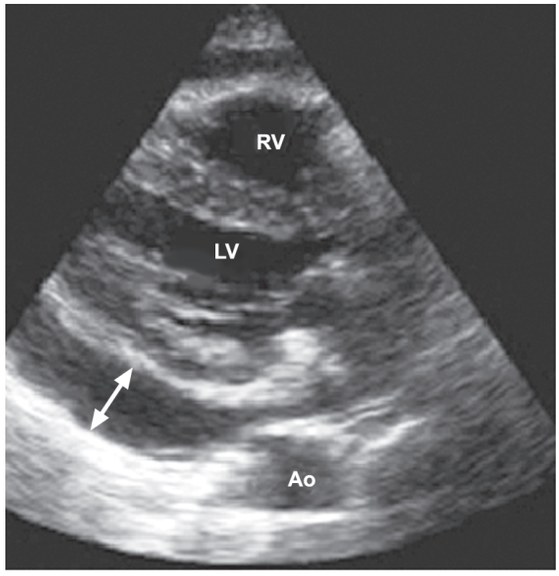

Fig. 1.9: LPS LAX echo scan showing large pericardial effusion (arrow)



Fig 1.10: Bilateral clubbing of fingers in infective endocarditis in patient with chronic rheumatic valvular dysfunction

3. Does DOE stop immediately when the patient stops moving (rare sign)?

Myocarditis, Endocarditis and Other Heart Disease Possibilities

1. *Acute myocarditis:* Recent influenza-like illness with myalgia.
2. *Infective endocarditis:* Has patient ever been told about it or cardiac murmur? Drug addiction, fevers, surgical or dental cause of bacteremia, prolonged penicillin treatment hematuria, back pain, petechiae, strokes? (Fig. 1.10).
3. *'Collagen' disease:* Raynaud's phenomenon, dysphagia, arthritis, or arthralgias tight skin epistaxis, rash in sunlight?
4. *Ankylosing spondylitis:* Pain in the hip or sciatic region, or low back pain. Does the pain awaken patient in the early morning hours? Morning back stiffness. Pain increased on coughing.
5. *Carcinoid heart disease:* Diarrhoea, bronchospasm, flushing of the upper chest and head that lasts from minutes to days.
6. *Parasitic disease (trichinosis or Chagas' disease):* Consumption of special meat preparation. Foreign travel.
7. *Hypophosphatemia:* High intake of phosphorus-binding antacids, aluminum hydroxide gel. Acute alcohol excess.
8. *Atrial myxoma:* Embolic phenomena, recurrent fevers, arthralgias, or skin lesions of a vasculitis type. Paresthesias in hands. Pulsations in neck (giant A waves, as in tricuspid stenosis) (Fig. 1.11).
9. Syncope or faintness on changing body position.
10. *Hemochromatosis:* History of diabetes especially, if patient is insulin resistant. Skin color changes. Liver failure and enlargement symptoms; upper abdominal

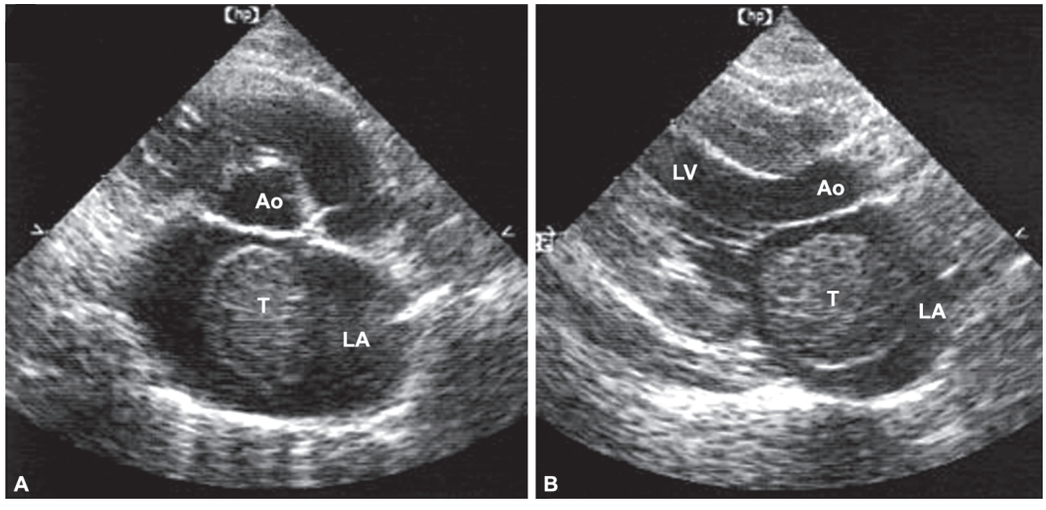

Fig. 1.11: Echocardiogram short axis (A) and parasternal long-axis, (B) show tumor mass in LA

pain, sexual impotence or gynecomastia? Frequent transfusions.
11. *Sarcoidosis:* Syncope (due to complete atrioventricular block). Known bundle branch block. Abnormal chest radiograph. Cough. Kidney stones or eye symptoms (uveitis).
12. Hypertrophic subaortic stenosis family history of sudden death. Angina or syncope after but not during exercise intermittent murmur. Do symptoms become worse on digitalis? (Fig. 1.12)
13. Amyloid heart disease; postural hypertension with peripheral neuropathy. Skin lesions, especially if there is bleeding on scratching.
14. Aortic regurgitation or aneurysm. History of venereal disease or positive serology.
15. Hoarseness due to recurrent laryngeal nerve compression by aneurysm.
16. Traumatic tricuspid regurgitation may not cause cardiac sympoms for up to 3 years after the accident.

NEW YORK HEART ASSOCIATION FUNCTIONAL AND THERAPEUTIC CLASSIFICATION

Functional Classification

This functional classification refers to fatigue, dyspnea or angina. The original classification is too long to grasp and a simplified one follows.

Class 1: The patient is asymptomatic, or symptoms occur on extraordinary exertion (there is no class, or classification for a patient with a normal heart).
Class 2: Symptoms occur on ordinary exertion.
Class 3: Symptoms occur on less than ordinary exertion.
Class 4: Symptoms occur even at rest.

Note: The functional classification is easily remembered, if one simply remembers the words ordinary exertion, because class 1 simply adds extra in front of ordinary class 2 adds no words in front of ordinary, and class 3 adds less than in front of ordinary.

Therapeutic Classification

It also refers only to patients with abnormal heart.
Class A: No restriction
Class B: Severe effort restricted
Class C: Ordinary effort moderately restricted
Class D: Ordinary effort markedly restricted
Class E: Confined to chair.

Enquiring about the symptoms of the heart disease. The nature of the underlying physiological disturbances can often be assessed from the symptoms. For example:
1. Raised pulmonary venous pressure
   a. Dyspnea
   b. Orthopnea
   c. Paroxysmal nocturnal dyspnea
   d. Cough
   e. Haemoptysis
2. Inadequate coronary blood flow; angina pectoris
3. Congestive cardiac failure; ankle swelling, hepatic pain.
4. Right to left intracardiac shunt;
   a. Cyanosis
   b. Dyspnea
   c. Squatting
   d. Syncopal attacks.

SYMPTOMS RESULTING FROM A RAISED PULMONARY VENOUS PRESSURE

DYSPNEA

Definition

Dyspnea is an uncomfortable and inappropriate awareness of respiration. Dyspnea can result from several physiological disturbances, the most frequent cause in cardiac disease being a high pulmonary venous pressure.

Mechanism

Any rise in pressure in the left atrium and pulmonary veins is transmitted to the pulmonary capillaries, increasing the

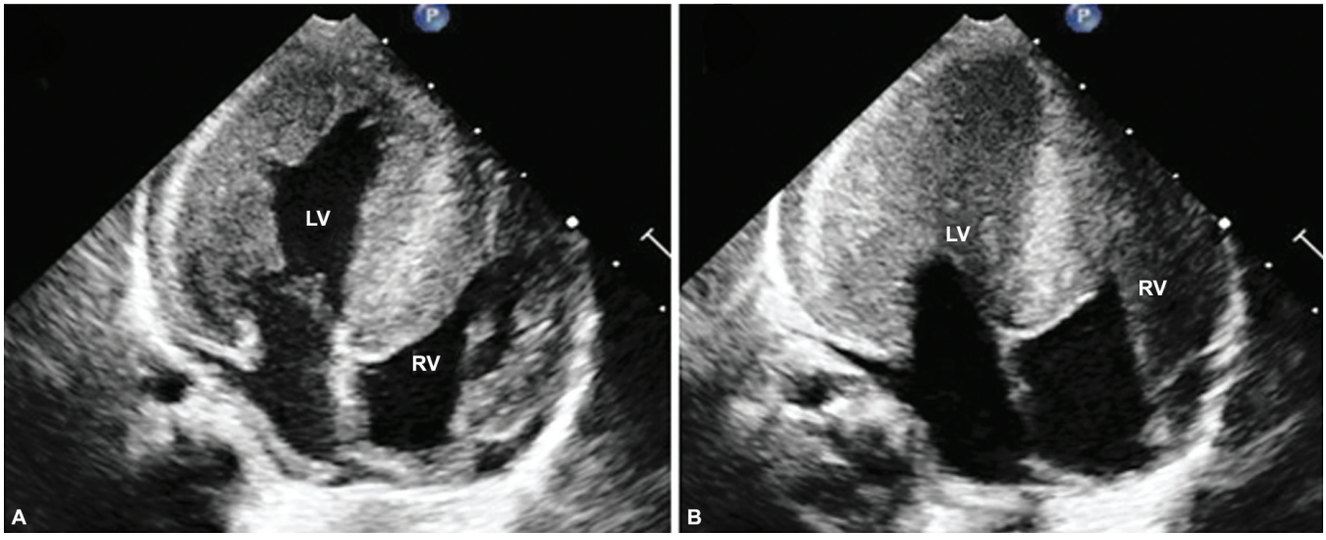

Fig. 1.12: Transthoracic echocardiogram. Apical 4-chamber view shows LV hypertrophy in HOCM. LV=left ventricle, RV=right ventricle

transudation of fluid from the capillaries into the interstitial tissues of the lung. The lungs then offer more resistance to inflation and deflation and the greater muscular effort required gives the patient the sensation of dyspnea. Frank pulmonary oedema represents the extreme situation when severe elevation of the pulmonary venous pressure forces large amounts of fluid into the alveoli.

Types

Orthopnea and paroxysmal nocturnal dyspnea describe specific forms of dyspnea arising from a high pulmonary venous pressure. The presence of either or both is evidence that the patient's dyspnoea is caused by a high pulmonary venous pressure.

ORTHOPNOEA

Definition

It may be defined as respiratory difficulty while lying flat and relieved while sitting up.

Mechanism

In normal subjects the volume of blood in the lungs is increased by lying flat, right atrial filling pressure is increased and the increased filling of the right atrium and ventricle is passed on into the lungs. The pulmonary blood volume is already large in patients with a high pulmonary venous pressure and the further volume change on lying flat adds to the stiffness of the lungs.

PAROXYSMAL NOCTURNAL DYSPNEA

It is that kind of acute dyspnea in which the patient feels uncomfortable during awakening from sleep.

Description

Acute dyspnea, awakening the patient from sleep, forcing him to sit upright or stand out of bed for relief. A dry cough and wheeze are commonly present during the attack, which passes off gradually after 10–20 minutes.

Mechanism

During the night the circulation of blood volume increases in heart failure as interstitial fluid returns to the blood, and the pulmonary venous pressure may build up to high levels. The reduced awareness during sleep allows high levels to be reached before dyspnea awakens the patient.

ACUTE PULMONARY EDEMA

Figure 1.13 shows chest X-ray depicting bilateral acute pulmonary edema.

Description

Dyspnea is acute and is accompanied by cough and a copious white or pink frothy sputum. There is cyanosis, perspiration, tachycardia, raised systemic blood pressure and wide spread crepitations over the lungs.

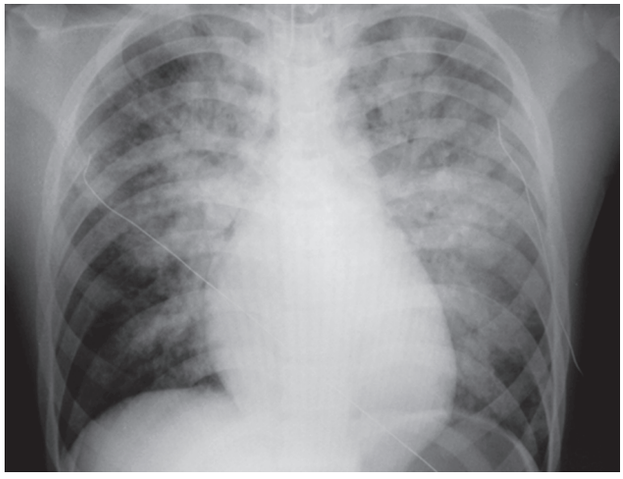

Fig. 1.13: Chest X-ray showing bilateral acute pulmonary edema

Mechanism

When levels of pressure of 40 mmHg, are exceeded in the pulmonary veins, the osmotic pressure of the plasma is overcome and fluid transits from the lungs capillaries into the alveoli in large quantities. Rupture of pulmonary capillaries from the high pressures produces pink expectorated sputum.

GRADATION OF DYSPNEA

Useful information about the severity of heart disease is obtained by grading the severity of dyspnea. The following workable categories have been found useful in clinical practice.

- *Grade 1 (Mild dyspnea):* When undertaking unusual exertion (running, walking and scrubbing).
- *Grade 2 (Moderate):* Walking on the level causes dyspnea
- *Grade 3 (Severe):* Unable to continue walking even slowly on the level.
- *Grade 4 (Gross):* The slight effort induces severe breathlessness. The patient is practically confined to bed by dyspnea. A history of nocturnal dyspnea or acute pulmonary oedema places the patient in the severe grade and irrespective of the effort tolerance.

COUGH

Two types of cough may be caused by a high pulmonary venous pressure. Dry cough during exertion. Cough, producing expectoration along with wheezing.

Mechanism

The bronchial venous return is mainly drained into the pulmonary veins, so that when the pulmonary venous pressure rises during exertion there is engorgement of the bronchial mucosa. This activates the cough reflex resulting in a troublesome dry cough. Chronic elevation of the bronchial venous pressure results in an edematous mucosa offering less resistance to infection and prone to repeated attacks of bronchitis.

HAEMOPTYSIS (COUGHING OUT OF BLOOD)

As a result of the high venous pressure a bronchial vein may rupture and cause a small or large haemoptysis.

1. Diseases associated with a raised pulmonary venous pressure.
2. Left ventricular failure. The high filling pressure required for the failing left ventricle results in an increased pressure in the left atrium and the pulmonary veins which in turn leads to left ventricular failure.
3. Obstruction to blood flow from the lungs. The pressure in the pulmonary veins proximal to any obstruction is high, e.g. mitral stenosis, left atrial myxoma.

SYMPTOMS OF AN INADEQUATE CORONARY BLOOD FLOW

Angina Pectoris (Figs 1.14 and 1.15)

Four major characteristics are:

1. *Quality:* A crushing pain or a tight constricting sensation.
2. *Site:* Pain is maximum behind the sternum or across the front of the chest.
3. *Radiation:* Radiates into the shoulders, the neck, jaw and the fingers and through to the back of the chest.
4. *Relation to exertion:* Pain is experienced during exertion. When exertion is discontinued, the pain wears off in 2–3 minutes, pain may also be provoked by anger or excitement.

SYMPTOMS OF RIGHT TO LEFT INTRACARDIAC SHUNTS

Central Cyanosis

Blue discoloration of skin, nail beds and mucous membrane which is more marked on exertion or during crying. Central cyanosis in congenital heart disease implies that blood low in oxygen content reaches the systemic arteries without first passing through the lungs.

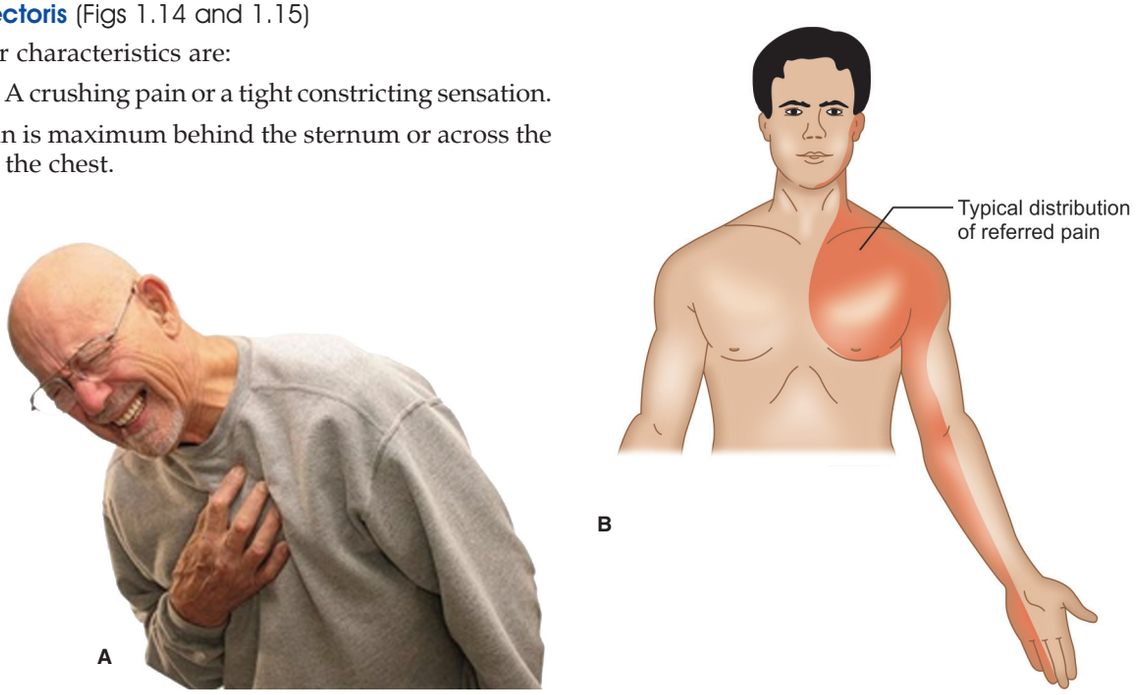

Fig. 1.14: (A) An elderly person experiencing an excruciating retrosternal chest pain with bending farward posture in angina pectoris. (B) Classical radiating pain of angina pectoris over the shoulder, neck and medial side of left arm and hand

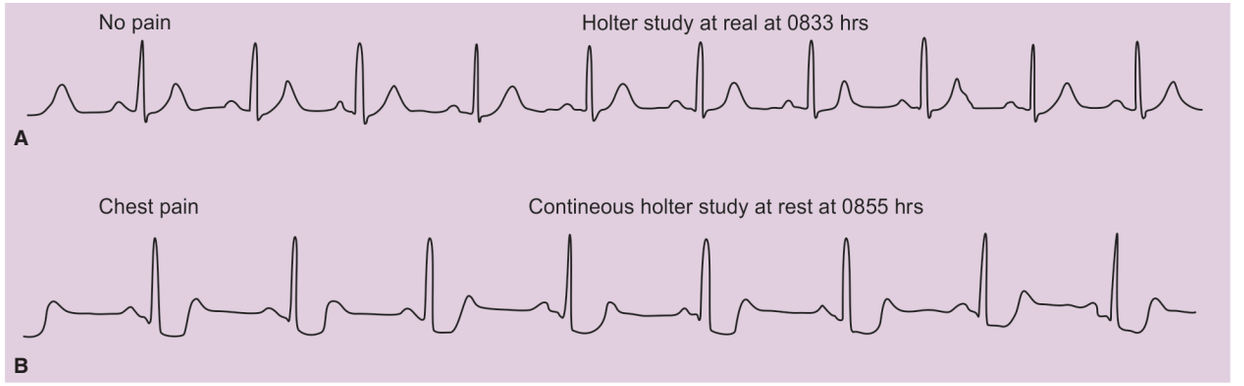

Fig. 1.15: (A) Normal sinus rhythm at 0833 hrs and (B) chest pain with significant ST-segment depression at 0855 hrs on Holter monitor recording of a patient with angina pectoris

Dyspnea

Breathlessness on exertion is present with all right to left intracardiac shunts. The reduced oxygen content of the arterial blood causes breathlessness by stimulating the chemoreceptors of the carotid body and the respiratory centre.

Squatting—characteristic posture of children who crawl on their heels when breathless, particularly after exertion. Squatting is most commonly seen in Fallot's tetralogy, but is not specific to this condition, being occasionally seen in other forms of cyanotic congenital heart disease. By squatting the arterial oxygen saturation is improved during the compression of the great vessels of the lower extremities particularly over the femoral vessels thereby decreasing the input of the right ventricle and raising the systemic blood pressure, hence both leading to better oxygenation in a squatting posture. However, precise mechanism is not known.

SYMPTOMS OF CONGESTIVE HEART FAILURE

Congestive heart failure (CHF) symptoms are illustrated in Figs 1.16–1.18.

Ankle Swelling

An excess of tissue fluid follows abnormal retention of sodium and water by the kidneys in heart failure, and this tissue fluid tends to localise under the influence of gravity into the most dependent parts of the body (Fig. 1.16).

Thus, the ambulant patient develops swelling of the feet and legs which is most marked in the evenings, whereas the patient confined to bed has a pad of edema overlying the sacrum. Edema over the ankles due to congestive cardiac failure (CCF) should be differentiated from other causes, such as:

1. Renal disease
2. Deficient lymphatic drainage of legs
3. Deep vein thrombosis of the legs or severe varicose veins
4. Cirrhosis of the liver
5. Ankle swelling in normal individual after standing for much of the day.



Fig 1.16: Edema of ankles and lower legs in patient with congestive cardiac failure

Abdominal Pain due to Hepatic Distension

The high systemic venous pressure due to right heart failure causes hepatic enlargement and distension of the hepatic capsule. This is responsible for a dull ache in the epigastrium and the right hypochondrium. It is often aggravated by exertion which, further increases the systemic venous pressure.

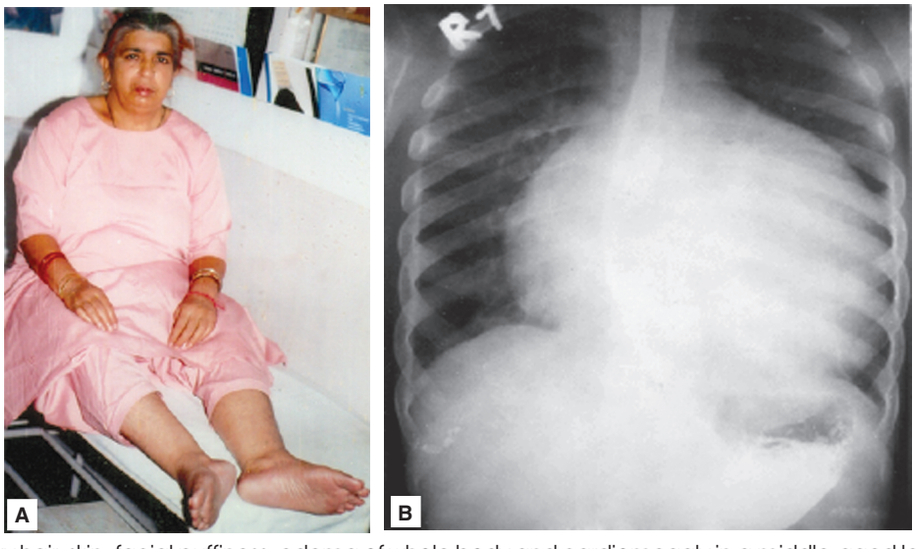

Fig. 1.17: (A) Rough, dry hair, skin, facial puffiness, edema of whole body and cardiomegaly in a middle-aged lady with hypothyroidism and heart failure. (B) Chest X-ray of patient with gross diffuse cardiomegaly who presented with grade-4 type of dyspnea



Fig. 1.18: A middle-aged patient showing protruded umbilicus due to ascites in congestive heart failure

Ascites

It is also one of the features of right heart failure (Fig. 1.18).

Symptoms of Low Cardiac Output

Fatigue: A low cardiac output has the effect of producing a constant feeling of fatigue, presumably related to the poor blood supply to muscles and other organs. However, the symptom of tiredness is so usual in all types of illness, including psychological illness, that it cannot be regarded as reliable evidence of a low cardiac output.

Dyspnea

The tissue anoxia of low cardiac output may lead to mild dyspnea.

Symptoms of Cardiac Arrhythmia (Figs 1.19–1.21)

Palpitations is a frequently used term for any increased beats of the heart. Occasional extra beats are described as the heart 'seeming to miss a beat', or as the heart 'turning over in the chest'. The sudden onset of faster heart rate may represent the onset of an attack of paroxysmal tachycardia or of atrial fibrillation.

CARDIAC SYNCOPE

Definition

Syncope resulting from the sudden cessation of cerebral blood flow when there is an arrest of the cardiac pumping action (Figs 1.22–1.24 and Table 1.1).

Description

There is an abrupt loss of consciousness with extreme pallor. The pupils dilate and epileptiform convulsions may occur. When efficient cardiac pumping action returns, there is abrupt restoration of consciousness, accompanied by a red flush of the skin as blood flows into vessels widely dilated by the accumulation of metabolites during the brief period of circulatory arrest.

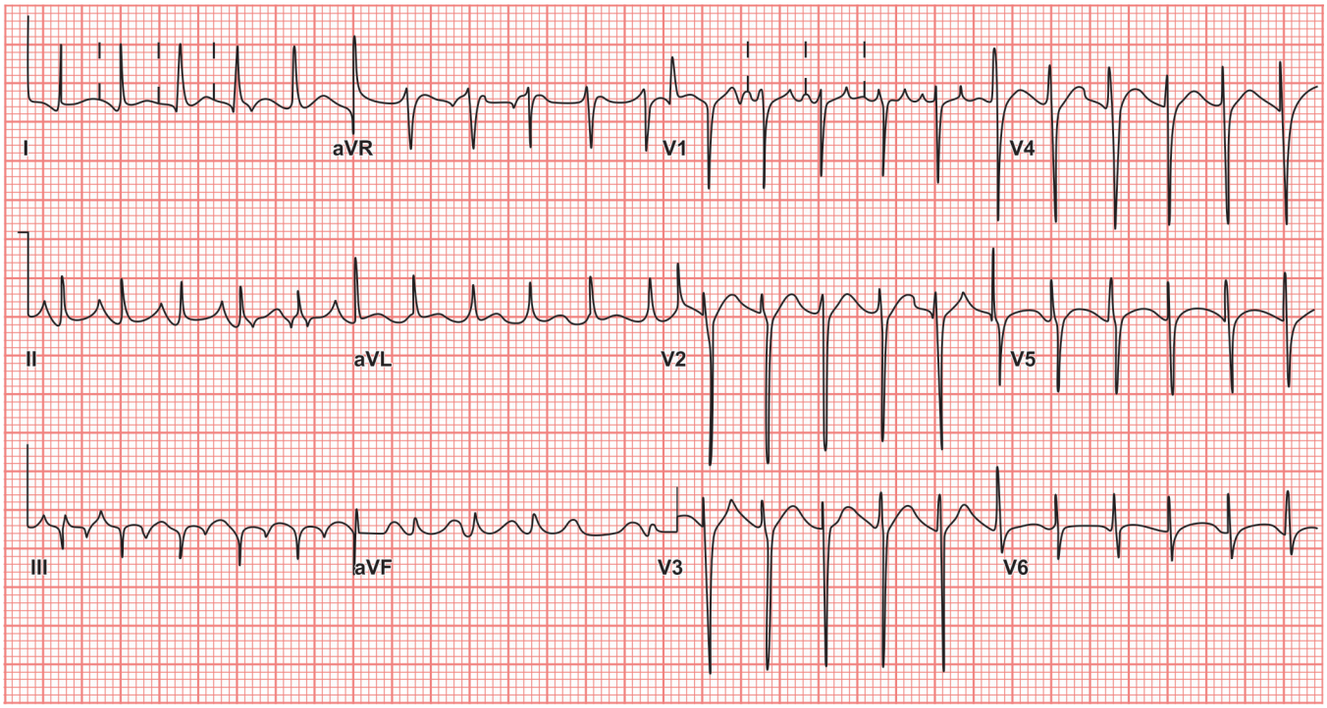

Fig. 1.19: ECG showing features of focal atrial tachycardia with 1:1 conduction. Note the narrow and regular tachycardia. The P-waves are marked with arrows (long-RP interval), and the P-wave morphology differs from that of sinus rhythm

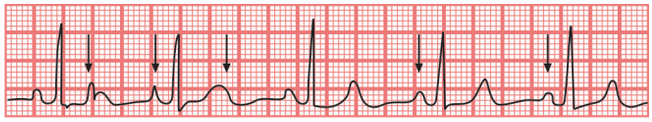

Fig. 1.20: ECG graph showing complete heart block respectively presenting syncopal attack

Sudden attacks of loss of consciousness are common in children suffering from Fallot's tetralogy, during the atack the child has a pallid cyanosis and profound desaturation of the arterial blood at a normal blood pressure. These attacks occur with emotion, stress, being particularly common in hospital and may be due to spasm of the infundibulum of the right ventricle. The blood flow is then greatly reduced through the lungs most of the blood passing across the ventricular septal defect into the aorta. Cerebral anoxia produces syncope and if the attack is prolonged death may also occur.

Causes

1. Complete heart block (Stokes Adams attack): Short episodes of cardiac arrest or of ventricular fibrillation are particularly frequent at the onset of complete heart block before the ventricular pacemaker has become well established.
2. Severe aortic stenosis: The syncope of severe aortic stenosis during exertion is a result of brief attacks of ventricular arrhythmias in some patients.
3. Paroxysmal tachycardia: Occasionally, the cardiac output is so reduced at the onset of fast arrhythmia that syncope results.
4. Left atrial thrombus, and left atrial myxoma: Impaction of these structures in the mitral valve orifice is a rare cause of syncope.

Table 1.1: Cardiovascular causes of syncope

Neurally-mediated (vasovagal)
- Situational
  - Micturition
  - Defecation
  - Postprandial
  - Swallowing
  - Coughing
  - Sneezing
- Glossopharyngeal neuralgia
- Orthostatic syncope
- Carotid sinus syncope
  - Cardioinhibitory
  - Vasodepressor
  - Mixed

Mechanical
- Aortic stenosis
- Hypertrophic cardiomyopathy
- Left atrial myxoma
- Mitral stenosis
- Pulmonic stenosis
- Pulmonary hypertension or embolism
- Right atrial myxoma
- Myocardial infarction
- Cardiac tamponade

Electrical
- Second- and third-degree atrioventricular block
- Sick sinus syndrome
- Supraventricular tachycardia
- Ventricular tachycardia
- Torsade de pointes
- Pacemaker malfunction

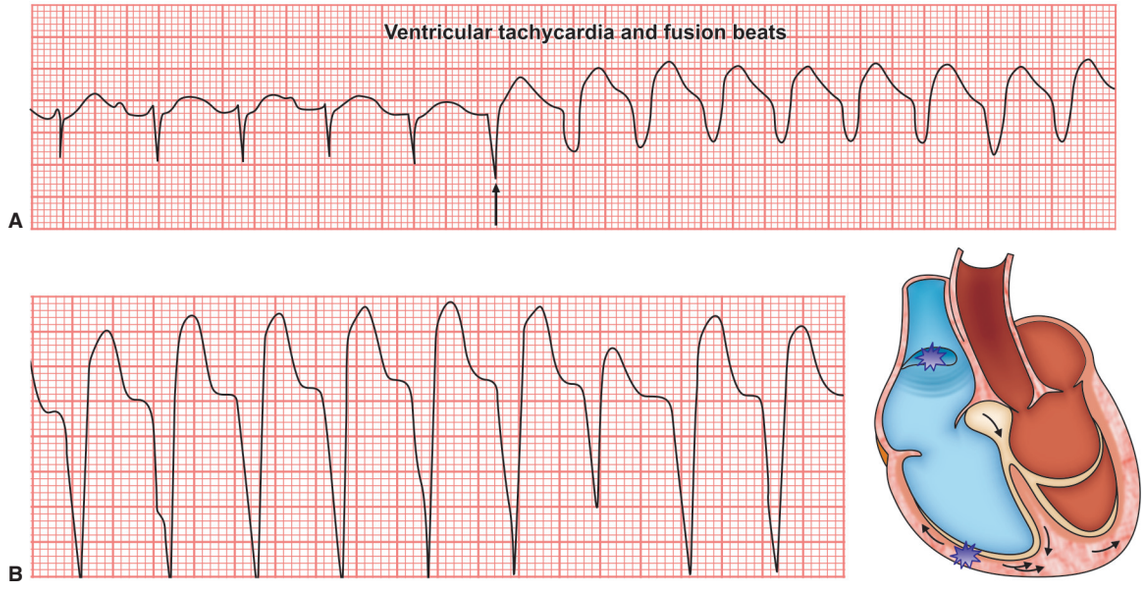

Fig. 1.21: ECG showing (A) ventricular tachycardia and fusion beat as indicated and (B) diagram showing the genesis of fusion beats



Fig. 1.22: Illustration showing syncopal attack, becoming temporarily unconcious, toneless and tendency to fall on the ground

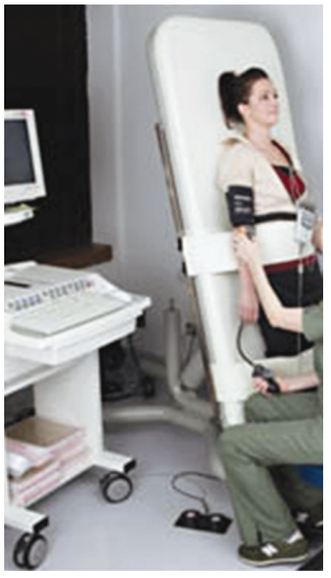

Fig. 1.23: Performance of HUTT test a young lady with syncopal attack

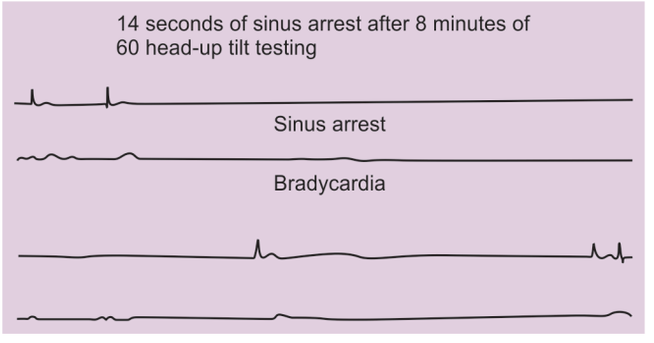

Fig. 1.24: EC graph depicting 14 second sinus arrest and critical bradycardia in positive head up tilt test for investigation of cardiogenic syncope

Balance Problems

Other names: Dizziness, unsteadiness, lightheadedness.

Description: Inability to walk or stand without holding on to something to maintain balance. Some causes related to cardiovascular disease can be seen after stroke, or due to general weakness caused by low cardiac output or low blood pressure. Some causes related to other disorders can be seen with several neurological problems or with inner ear problems, as well as to numerous general medical problems.

Significance: Many significant medical problems can cause problems with balance. This symptom always needs to be carefully evaluated by a physician.

GENERAL PHYSICAL EXAMINATION

Physical Examination

Chronic severe heart failure may cause emaciation, and cyanotic congenital heart disease may be responsible for stunted growth and poor development (Figs 1.25–1.35).

Obesity aggravates the effect of cardiac disease.

Anatomical Abnormalities

Anatomical abnormalities, i.e. anatomical defects. Absence or hypoplasia of one or both upper limbs are associated with intracardiac defects such as atrial septal defect (ASD) or ventricular septal defect (VSD) (Holt-Oram syndrome).

Genetic Abnormalities

Many genetically determined disorders are easily recognised from their effects on the general body configuration. The cardiac malformations commonly associated with specific genetic defects are given below.

Chromosome Disorders

Mongolism is also known as Down syndrome is caused by a random error in cell division that results in the presence of an extra copy of chromosome 21. The type of error is



Fig. 1.25: An obese patient with metabolic syndrome



Fig. 1.26: Genetically transmitted hypothyroidism in husband, wife and son (middle)



Fig. 1.27: A child with syndactylism in Apert syndrome

called nondisjunction (pronounced non-dis-JUHNGK-shuhn). Usually, when one cell divides in two, pairs of chromosomes are split so that one of the pair goes to one cell, and the other from the pair goes to the other cell. In nondisjunction, something goes wrong and both chromosomes from one pair go into one cell and no chromosomes for that pair go into the other cell.

Heart defects. Endocardial cushion defects. Turner's syndrome (XO) coarctation of the aorta pulmonary stenosis.

DiGeorge Syndrome

DiGeorge syndrome, additionally known as 22q11.2 deletion syndrome, could be a disorder caused by a defect in chromosome 22. It ends up in the poor development of several body systems. Medical problems usually associated with DiGeorge syndrome embrace heart defects, poor immune system performance, a cleft palate, complications associated with low levels of calcium in the blood, and delayed development with behavioral and emotional problems. The quantity and severity of symptoms related to DiGeorge syndrome vary greatly.

Heart defects. DiGeorge syndrome typically causes heart defects that end in an meagre supply of oxygen-rich blood. These defects might include a hole between the lower chambers of the heart (ventricular septal defect); only one large vessel, instead of two vessels, leading out of the heart (truncus arteriosus); or a mixture of four abnormal structural heart defects (tetralogy of Fallot). DiGeorge syndrome will cause smaller than traditional parathyroid glands that secrete insufficient parathyroid hormone (PTH), leading to a condition called hypoparathyroidism. This condition ends up in low levels of calcium and high levels of phosphorus in your blood. In children with DiGeorge syndrome, the thymus gland could also be small

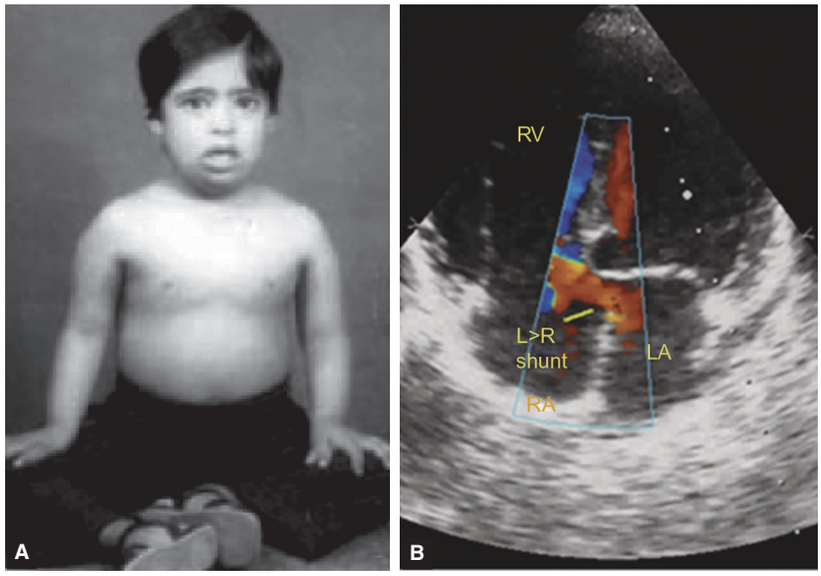

Fig. 1.28: (A) Stunted growth, polydactylism and chest deformity in a child with endocardial cushion defect, (B) Color flow apical 4C views in dual scan showing large septum primum defect with almost single dilated atrium, dilated LV with gross mitral regurgitation in patient with endocardial cushion defect

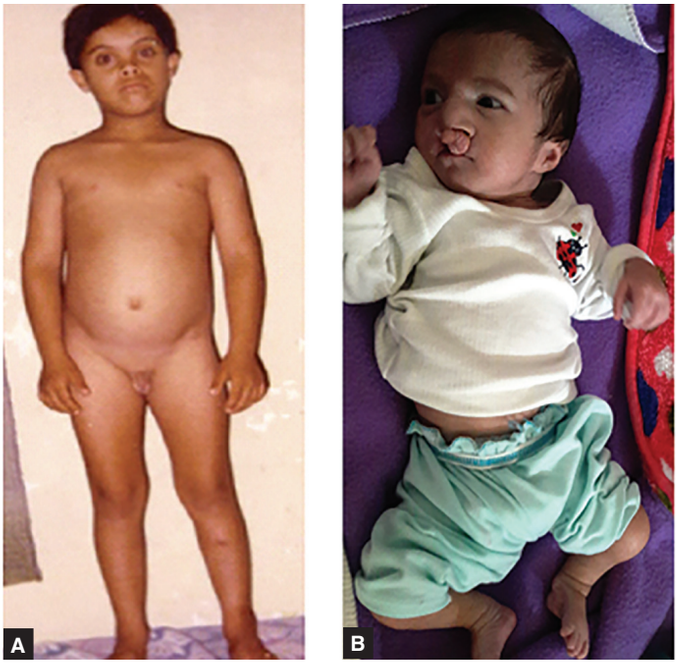

Fig. 1.29: (A) Physical features of mongolism associated with VSD, (B) DiGeorge syndrome with cleft lip, hypoparathyroidism, hemitruncus, VSD, pulmonary stenosis and hypoplasia of left sided upper and lower limbs with poor physical growth

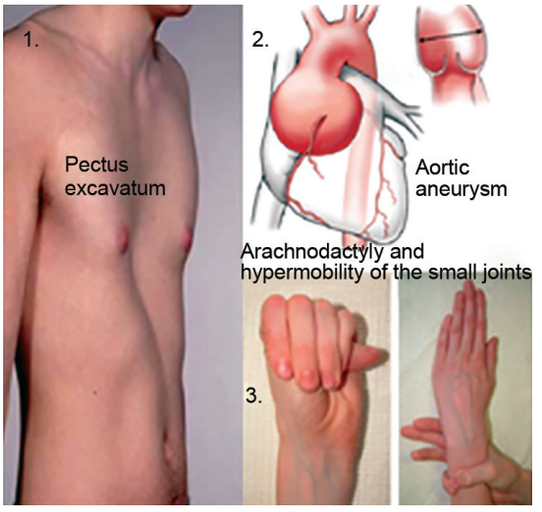

Fig. 1.30A: Different clinical features of Mafan syndrome

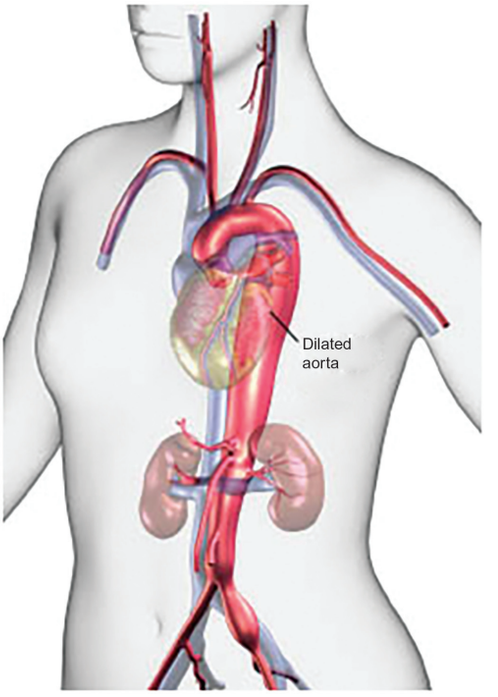

Fig. 1.30B: Dilation of aorta in Mafan syndrome

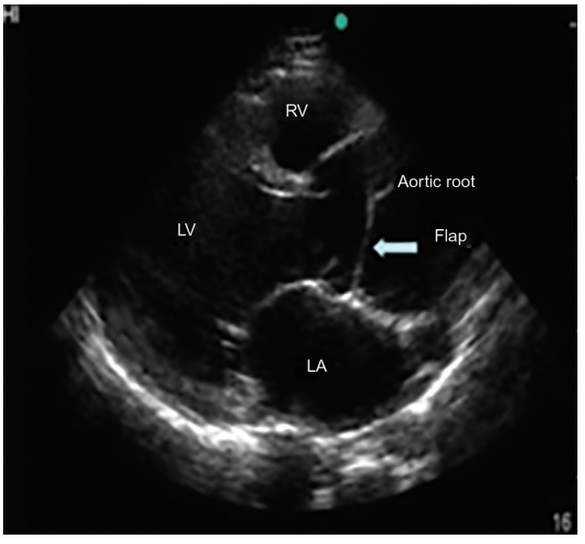

Fig. 1.30C: Echo scan showing dilated aortic root in Mafan syndrome

or missing, leading to poor immune functions and frequent, severe infections.

Single Gene Disorders

Marfan syndrome: Aortic ectasia, dissecting aneurysm of the aorta. Hereditary haemorrhagic telangiectasia, pulmonary arteriovenous fistulae, neurofibromatosis phaeochromocytoma, polydactyly common atrium, atrial septal defect etc.

Rubella infection Lesions such as mental deficiency, nerve deafnes and cataract in a child suggest that the mother was infected during early pregnancy by rubella. In such cases there is a strong likelihood of congenital heart disease (Fig. 1.31).

The common cardiac lesions produced by the virus are:

- Patent ductus arteriosus
- Pulmonary Valve Stenosis
- Pulmonary artery branch stenosis

Thoracic Deformity

Massive enlargement of the heart in infancy can produce a permanent deformity of the overlying chest wall with a forward bulge of the precordium to the left of the sternum.

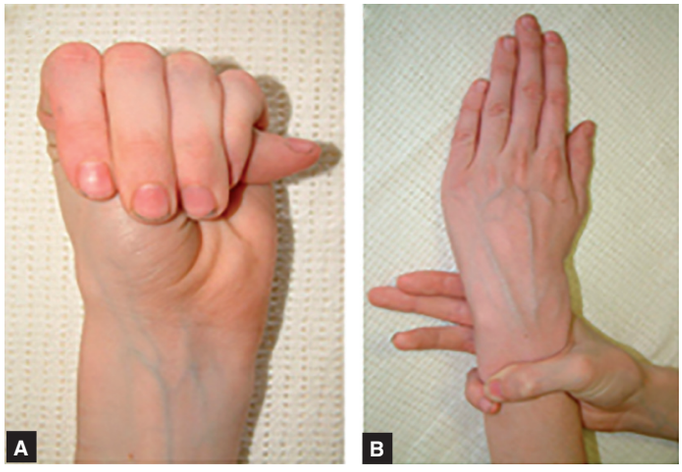

Fig. 1.30D: Arachnodactyly. (A) Steinberg thumb sign. Entire thumb nail protrudes beyond ulnar border of hand, (B) Walker-Murdoch wrist sign. Thumb and fifth finger can overlap around wrist. Both signs must be present to diagnose arachnodactyly according to the Ghent Marfan diagnostic criteria

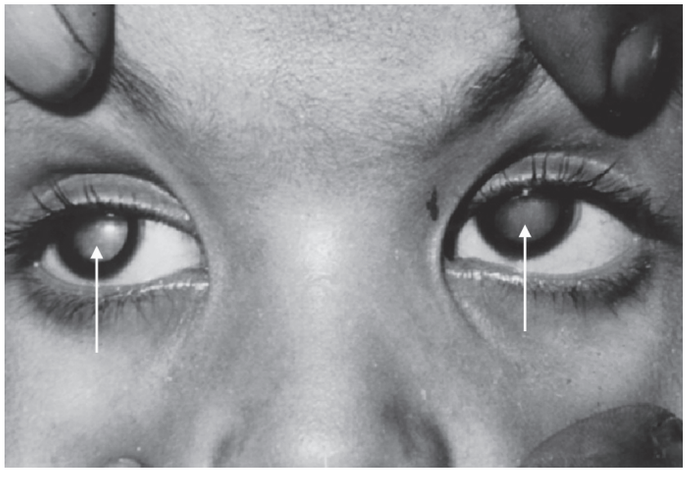

Fig. 1.31: Bilateral congenital cataracts in congenital Rubella syndrome with PDA (arrows)



Fig. 1.32: Pigeon chest deformity

Pulmonary hypertension complicating a left to right intracardiac to right intracardiac shunt may result in an abnormally rounded configuration of the front of the chest in children. Pectus excavatum type of chest deformity may also be associated with high incidence of mitral valve prolapse (MVP) and ASD (Fig. 1.32).

Earlobe crease: Taken in conjunction, most of the studies conducted clearly show an association between earlobe creases and heart disease. In fact, most studies including the larger ones-suggest that this association is true and conclude the association cannot be explained by other risk factors. Unfortunately, although research supports an association as of yet we don't have a convincing explanation as to why earlobe crease would be associated with heart disease.

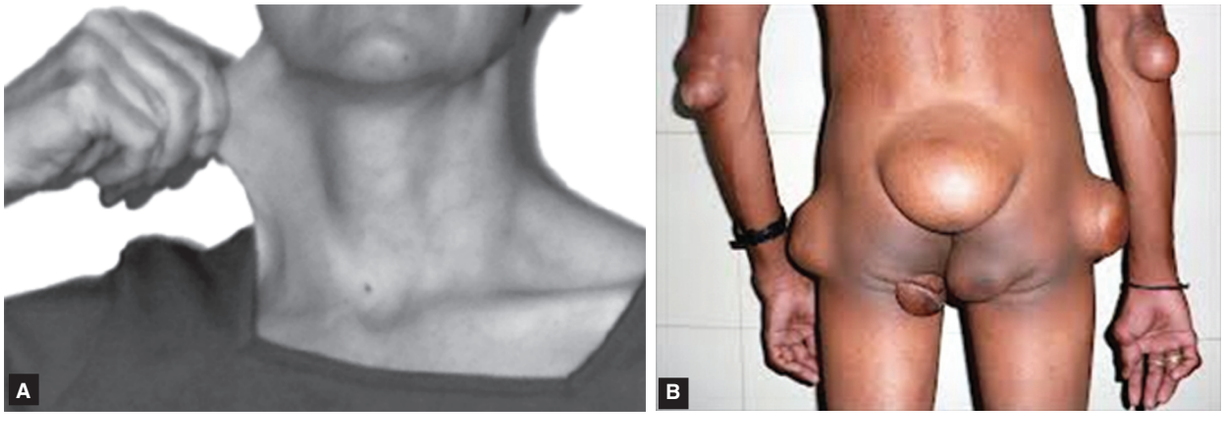

Fig. 1.33: (A) Feature of cutus hyperelastica. The vascular type 111 is considered one of the more serious forms of Ehlers-Danlos syndrome because blood vessels and organs are fragile and prone to tearing (rupture). (B) Multiple swellings over extensor aspects of limbs and buttocks in hereditary tuberous xanthomas

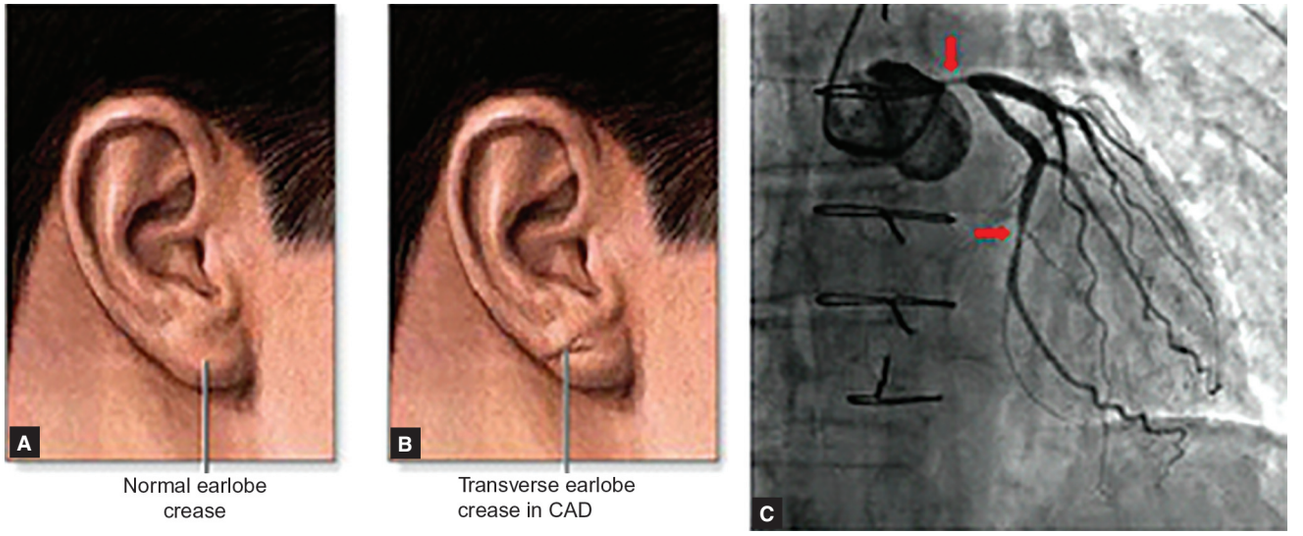

Fig. 1.34: (A) Normal earlobe crease, (B) transverse earlobe crease as a physical sign in coronary artery disease and (C) coronary angiography of a critical sub-occlusion of the common trunk of the left coronary artery and the circumflex artery (see arrows)

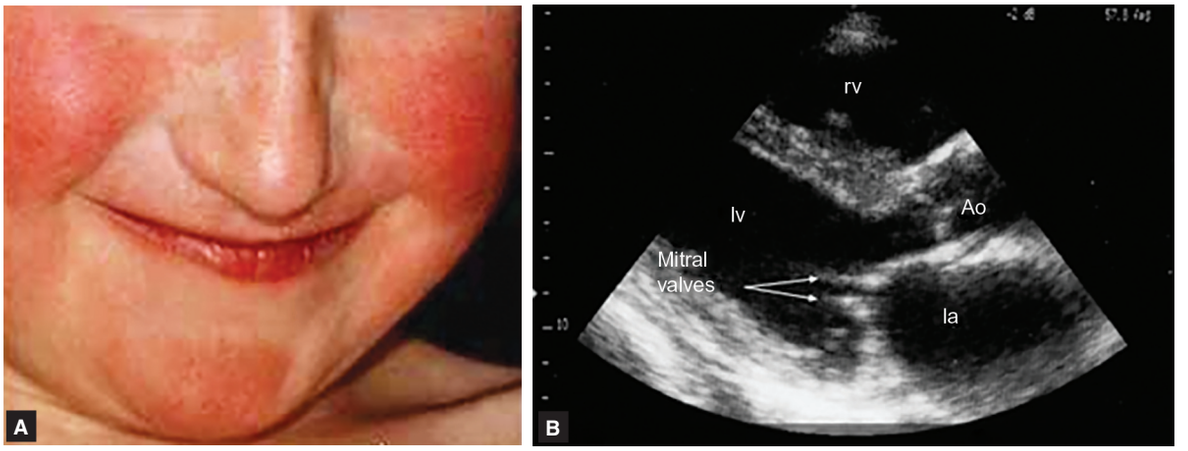

Fig. 1.35: (A) Photograph of a young lady suffering from chronic rheumatic mitral stenosis with facial redness as malar flush. (B) Echo scan in LAX view showing thickened and restricted opening of both AML and PML in mitral stenosis

Malar Flush

Patients with a chronic low cardiac output have a dusky flush of the cheeks. This color is the result of dilated capillaries in the dermis, in which the circulation of blood is slow, and is most commonly seen in mitral stenosis complicated by pulmonary hypertension.

CYANOSIS

A blue discoloration of the skin and mucous membranes caused by 5.0 g or more of reduced haemoglobin per 100 ml of blood in the skin capillaries (Fig. 1.36).

Peripheral Cyanosis

There is a slow circulation of blood to the cyanosed part and, because the blood is in prolonged contact with the tissues, the extraction of oxygen is more complete than nomal. The blood in the capillaries thus has an increased proportion of reduced haemoglobin. Vasoconstriction due to cold or as compensation for a low cardiac output is the usual cause of peripheral cyanosis, which is best seen in the lobes of the ears, the nose and the fingers.

1. *Central Cyanosis*

Definition

Central cyanosis is defined as cyanosis caused by a reduced oxygen saturation of the systemic arterial blood.

Clinical Features

The following features accompany central cyanosis and distinguish it from peripheral cyanosis.



Fig. 1.36: Two children having central cyanosis with congenital heart diseases

Finger clubbing: Warm mucous membranes, blue tongue, lips and conjunctiva. Polycythaemia is present with abnormally raised haemoglobin and haematocrit. Arteries blood, obtained by needle puncture from a peripheral artery, is desaturated, this is the absolute differentiating test in doubtful cases.

Causes

Cardiac disease: Venous blood entering the left heart without passing through the lungs, i.e. right to left shunting of blood through abnormal communication in the heart.

Pulmonary Disease

Inadequate oxygenation of the blood as the blood passes through the lungs. The breathing of oxygen for a few minutes increases the oxygen tension in the alveoli of the lungs thus compensating for poor lung functions. Cyanosis due to lung disease is markedely improved with O_2 therapy while cyanosis caused by a right to left intracardiac shunt is little affected.

2. Differential Cyanosis

This condition is depicted in Fig. 1.37.

Definition

Cyanosis is more intense in the feet than in the hands when both are warm.

Cause

Differential cyanosis implies that the oxygen content of the arterial blood in the legs is lower than in the arms. Blood low in oxygen will pass from the pulmonary artery through a persistent ductus arteriosus only when there is severe pulmonary hypertension. The presence of differerential cyanosis is therefore, diagnostic of persistent ductus arteriosus with pulmonary hypertension.



Fig. 1.37: Differential cyanosis in a patient with patent ductus arteriosus, severe pH, and right to left shunt (Eisenmenger syndrome). Note the severe clubbing and cyanosis of the toes as compared to the lesser degree of clubbing and cyanosis of the fingers

CLUBBING OF THE FINGERS

Clubbing of the fingers is shown in Figs 1.38–1.41.

Stages

1. Obliteration of the normal angle between the finger nail and skin on the dorsum of the finger by an increase in the soft tissues underneath the nail bed.
2. The nail becomes curved longitudinally.
3. Swelling of soft tissues of the terminal phalanges gives a drum stick appearance to the digits.

Causes

The exact stimulus producing finger clubbing is not known. Heart disease finger clubbing is due to cyanotic heart disease, bacterial endocarditis or left atrial myxoma. However, rarely it may be of a heredito-familial .

ABDOMINAL PAIN

Description: Pain or discomfort in or around the abdominal area (Fig. 1.42).

Causes related to cardiovascular disease: Vascular disease can cause abdominal pain in several ways. Blockage or partial blockage (due to atherosclerosis) of arteries supplying the vital organs can cause those organs to become ischemic, and therefore painful. This type of pain is usually greater after a meal. An aneurysm of the abdominal aorta can cause pain, especially if the aneurysm begins to tear or rupture. This pain is often very severe, and sudden in onset. It is a medical emergency.

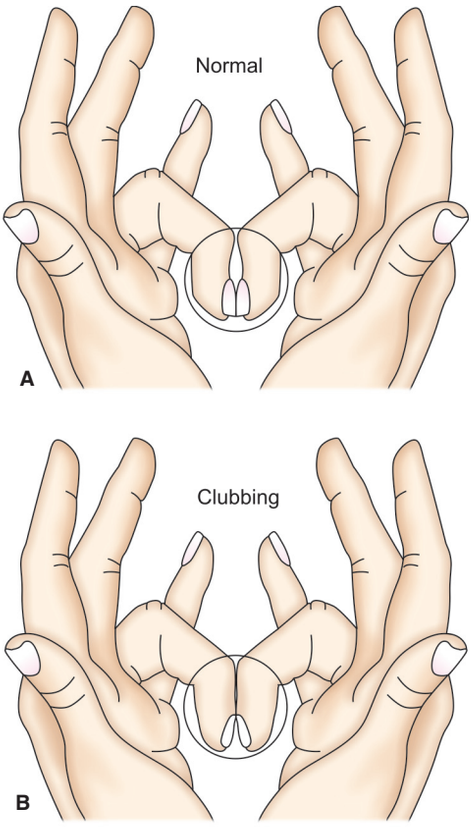

Fig. 1.38: (A) Normal curvatures of the ring fingers of both hands in flexion. (B) Clubbing of fingers

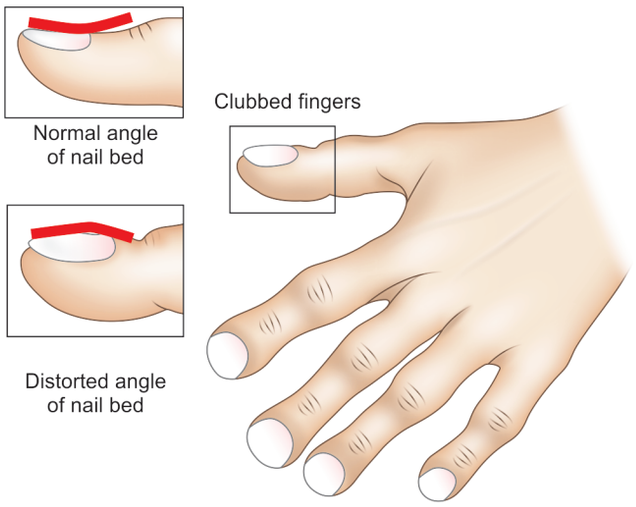

Fig. 1.39: Features of clubbing of fingers

Causes related to other disorders: Numerous disorders of abdominal organs—stomach, intestines, bowel, liver, spleen, gallbladder, reproductive organs, can cause pain.

Significance: Vascular disease involving the abdominal blood vessels is always significant, and potentially dangerous medical problem. A ruptured or torn abdominal aortic aneurysm is often fatal. Many non-cardiovascular diseases causing pain in abdominal organs are also medically significant. Any unexplained abdominal pain that is severe, frequent, prolonged or persistent needs to be evaluated by a physician.

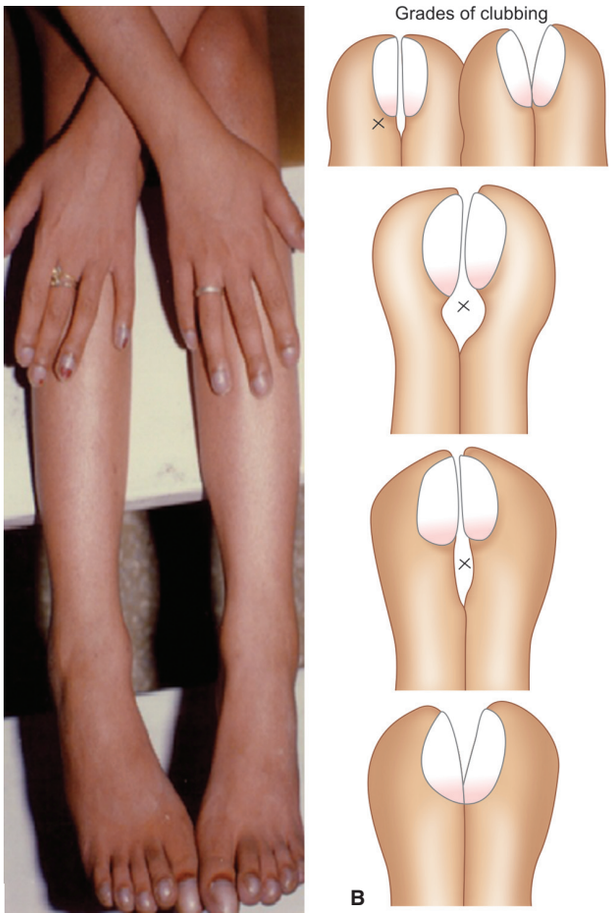

Fig. 1.40: Bilateral digital clubbing and central cyanosis in patient with Fallot's tetralogy (A) and graphic representation of various grades of digital clubbing (B)



Fig. 1.41: Hereditary transmitted bilateral congenital clubbing among all the members of a family

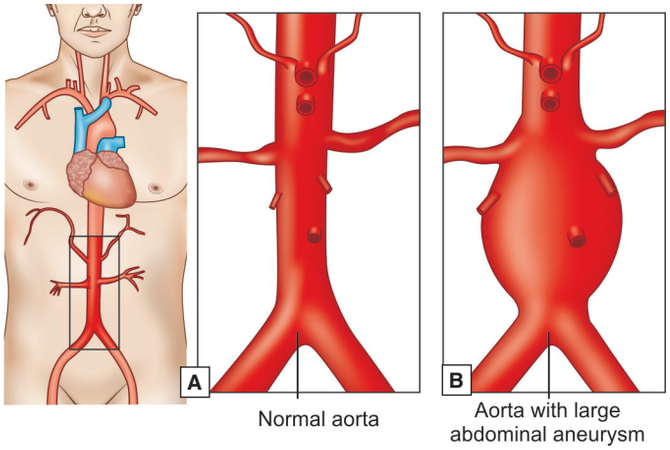

Fig. 1.42: (A) Normal thoracic and abdominal aorta. (B) Aneurysmal dilatation of thoracic and abdominal aorta as a cause of abdominal pain and abnormal pulsations

ABNORMAL PULSE

Description: The patient notices an area in or on the body where an unusual or a vigorous pulsation can be seen or felt. Some causes related to cardiovascular disease are:

- Abnormal pulsations can be related to vascular disease, such as an aneurysm (an abnormal dilation or 'ballooning' of an artery). Abnormal pulsations in the abdomen, in particular, are often indicative of an aortic aneurysm. A 'bounding' pulse can also be felt in patients who have aortic insufficiency (a 'leaky' aortic valve.)
- Some causes related to other disorders: Any condition that leads to particularly vigorous pumping of the heart can create an unusual awareness of the pulse. Such conditions include anemia, thyroid disease, hypertension, anxiety, or other medical problems.

Significance: A persistent abnormal pulsation can indicate significant medical disease, and should be reported to a doctor.

THE ARTERIAL PULSE

The brachial arterial pulse: It is larger and more convenient for detailed study than the radial. For maximum information, the palpating finger should compress the vessel with just sufficient force to collapse the lumen in diastole. The rise in pressure with each heart beat forcibly expands the wall against the finger (Figs 1.43–1.45).

The carotid pulse: It is also examined and other arterial pulses are compared with each other.

The brachial pulse is analysed under four headings:

1. Rate
2. Rhythm
3. Amplitude
4. Waveform

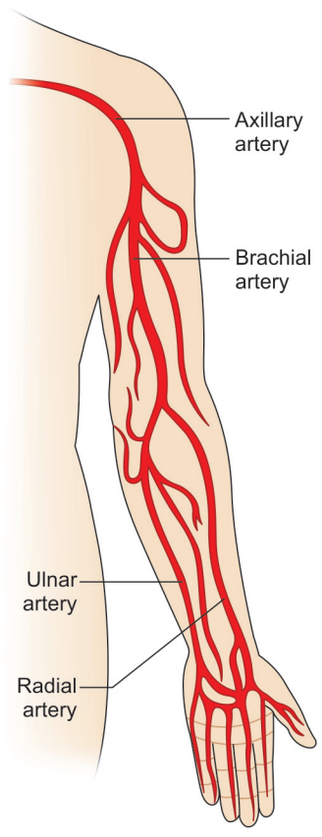

Fig. 1.43: Anatomy of axillary/brachial and radial arteries which are used in clinical assessment of peripheral arterial diseases



Fig. 1.44: The radial pulse is palpable over the lateral wrist

Rate

1. An abnormally fast pulse may represent:
   a. Sinus tachycardia (sinoatrial node remains in control), e.g. excitement, fever, exertion, thyrotoxicosis and haemorrhage.
   b. Arrhythmia (an ectopic focus in the heart has taken over the pacemaking function from the sinoatrial node),

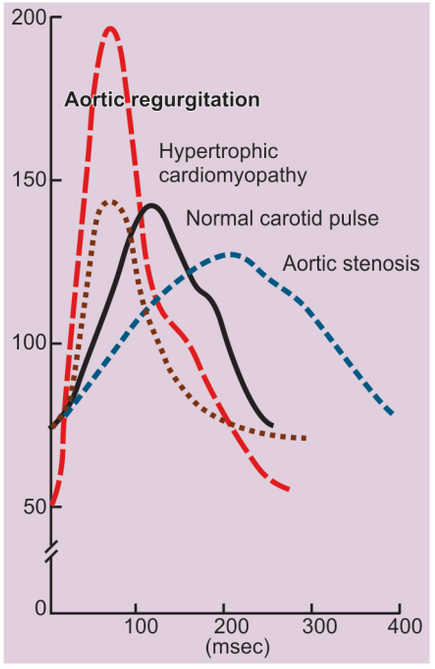

Fig. 1.45: The normal carotid arterial pulse recording compared with recordings in hypertrophic cardiomyopathy, aortic regurgitation and aortic stenosis. Note the very rapid upstroke of the pulse in hypertrophic cardiomyopathy and aortic regurgitation compared with the slow upstroke in aortic stenosis. The pulse pressure in aortic regurgitation is widened because of the exaggerated systolic peak and the diastolic collapse

e.g. paroxysmal atrial tachycardia and atrial flutter, atrial fibrillation, ventricular tachycardia.

2. An abnormally slow pulse may represent:
   a. Sinus bradycardia (sinoatrial node remains in control), e.g. trained athletes, increased intracranial pressure, jaundice.
   b. Arrhythmia (a pulse rate below 40 beats per minute usually means complete heart block).

Rhythm

The normal pulse is regular apart from a slight speeding up on inspiration and slowing on expiration most obvious in younger individuals (sinus arrhythmia). Complete irregularity indicates atrial fibrillation, but both sinus rhythm with multiple extrasystoles and atrial flutter with changing block can simulate atrial fibrillation.

During exercise, a patient with atrial fibrillation, the irregularity of the pulse is accentuated, atrial extrasystoles, disappear, so that the pulse become regular. In atrial flutter, regular degree of atrioventricular (AV) block becomes established, and the pulse becomes regular.

Amplitude

The amplitude of the pulse is judged by the movement of the palpating finger produced by the arrival of the pulse wave. A large amplitude pulse means that the pressure wave is large, i.e. there is a large difference between systolic and diastolic blood pressures.

LARGE AMPLITUDE PULSE

Causes

1. Leakage of blood from the aorta in aortic valve regurgitation
2. Persistent ductus arteriosus and arteriovenous fistula
3. Increased flow of blood from aorta through dilated arterioles
4. Thyrotoxicosis and other high output states
5. Increased left ventricular volume
6. Complete heart block
7. Raigidity of aorta, i.e. atherosclerosis
8. Increased left ventricular stroke volume-heart block

Mechanism

The rapid escape of blood from the aorta in the first two groups results in a low pressure in the arterial system by the end of diastole and the large left ventricular stroke volume ejected into the aorta causes a high systolic pressure. The very large stroke volume of complete heart block gives an abnormally large pressure peak in the aorta. A normal stroke volume produces an abnormal great pressure rise when the aorta has lost its elasticity.

SMALL AMPLITUDE PULSE

Cause

Low left ventricular stroke volume (shock, tachycardia and mitral stenosis). Obstruction to left ventricular ejection (aortic stenosis).

Mechanism

In the low cardiac output states, the volume of blood ejected into the aorta with each beat is small and the pressure rise also tends to be small.

Obstruction to left ventricular ejection reduces the speed of blood flow into the aorta during systole, thereby producing a smaller and slower than normal pressurise in aortic stenosis.

PULSE VARYING IN AMPLITUDE

A. Pulsus Alternans

Description

The amplitude of the pulse wave, in a patient in sinus rhythm is large and small alternately.

Mechanism

Usually, in a patient with heart failure, an episode of alternans is initiated by an extra systole. In the succeeding pause, there is excessive filling of the left ventricle and the next ventricular contraction is powerful and prolonged because of the large volume to be expelled. The period available for diastolic filling of the ventricle prior to the next beat is therefore short and the contraction less forceful.

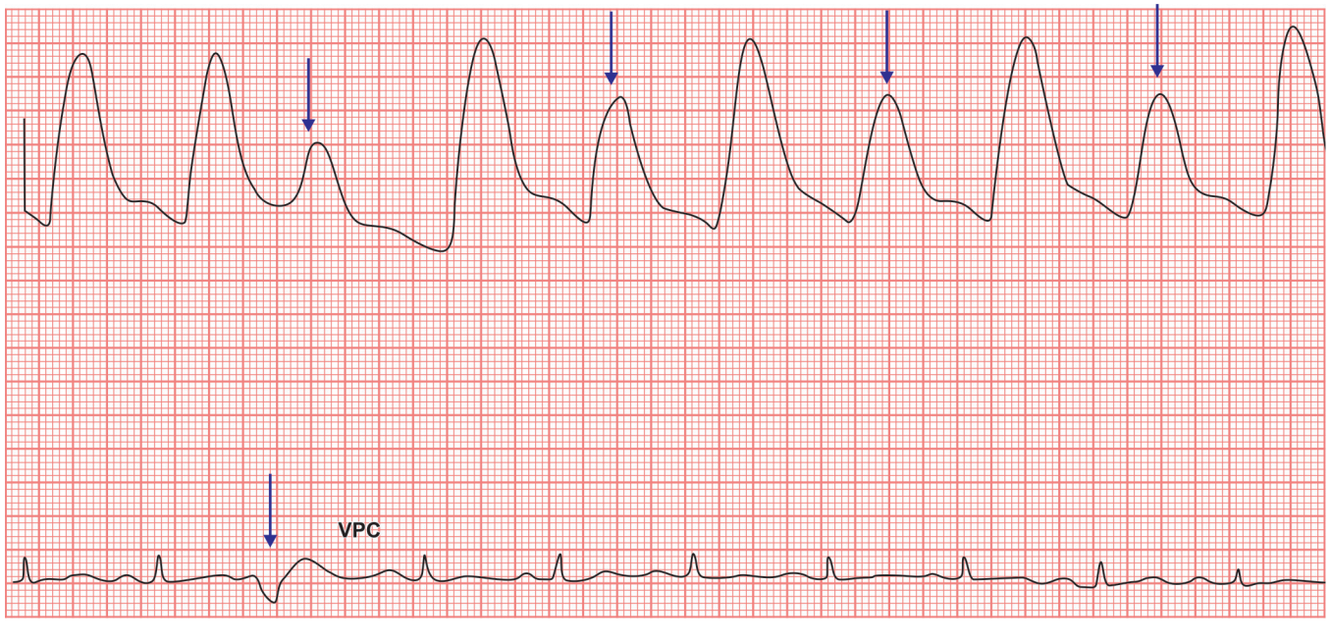

Fig. 1.46: Hemodynamic study shows an alternating pulse-arterial pressure recording in severe left ventricular failure. After the second beat a ventricular premature beat triggers an episode of alternating pulse

Significance

Pulsus alternans is a good evidence of left ventricular failure (Fig. 1.46).

B. Pulsus Paradoxus

Description

A marked accentuation of the normal decrease in the amplitude of the arterial pulse during quiet inspiration.

Causes

1. Increased inspiratory effort (laryngeal stridor, severe asthma)
2. Restriction of diastolic filling of the heart (cardiac tamponade, constrictive pericarditis)
3. Occasionally present in right ventricular failure.

Mechanism

1. *Pulsus paradoxus in asthma:* The powerful inspiratory effort to overcome airway obstruction considerably increases the capacity of the lung vessels and thereby reduces the flow of blood out of the lungs to the left heart. The systemic arterial pulse pressure is then diminished during inspiration.
2. *Pulsus paradoxus in tamponade:* When the diastolic volume of the heart is limited by a pericardial effusion or a rigid pericardium, the normal increased filling of the right atrium and right ventricle during inspiration leaves less available volume for the left atrium and the left ventricle. Left ventricular stroke volume is reduced during inspiration and pulsus paradoxus is produced.
3. *Pulsus paradoxus in right ventricular failure:* If the failing right ventricle does not increase its output during inspiration, the normal increase in the capacity of the lung vessels will restrict the flow out of the lungs into the left heart and the left ventricular stroke output will decrease resulting into formation of pulsus paradoxus.

Pulse Varying in Waveforms

The shape of the pressure wave is of diagnostic value as many abnormalities of the circulation produce characteristic changes in the form of the pulse wave which are readily detected by palpation. The normal brachial pulse has a smooth fairly sharp upstroke, a momentarily sustained peak and a quick downstroke. The dicrotic notch, representing aortic valve closure, cannot be detected clinically, but the other features are readily analysed.

ANACROTIC PULSE (PLATEAU PULSE, SLOW RISING PULSE)

Description

The upstroke is slow with often a distinct notch on it. The time taken to reach the peak is prolonged and the entire pulse wave is of small amplitude.

Causes

Aortic valve stenosis. The rate of ejection of blood into the aorta is decreased so that the ejection is prolonged and the amplitude of the pulse is diminished.

WATER HAMMER PULSE (COLLAPSING PULSE)

Description

The upstroke is more abrupt and steep than normal. The peak is reached early, is not sustained and the downstroke is also rapid. The amplitude is usually abnormally large. The examiner's finger appreciates the sharper than normal upstroke rather than the downstroke and experiences a sharp tap with each pulse beat (Fig. 1.47).



Fig. 1.47: The collapsing pulse. The collapsing pulse is best elicited by grabbing the patient's left wrist with your left hand (bottom, left). After you have detected the pulsation of his radial pulse in your palm, gradually relax the grip of your hand until the radial pulse just disappear. Then with the help of your right hand, lift the patient's arm in the air (bottom, right) while maintaining the same grip pressure. If the pulse returns, it has become more forceful and thus deemed collapsing

Causes

The sharp upstroke represents the rapid ejection of blood into an empty arterial system and the rapid downstroke indicates abnormally fast escape of blood from the arteries during diastole. A water hammer or bounding pulse is found in:

1. Aortic valve regurgitation
2. Persistent ductus arteriosus
3. Systemic arteriovenous fistula
4. Pregnancy
5. Fever
6. Thyrotoxicosis (Fig. 1.48)
7. Anemia
8. Anoxic lung disease

PULSUS BISFERIENS

Description

The upstroke is sharp to a high peak, the pressure then falls and rises again to a second peak of about the same height as the first peak before falling off. The amplitude of the pulse wave is large and the palpating finger experiences two distinct impulses with each pulse beat.

Cause

This waveform indicates combined stenosis and incompetence of the aortic valve, both lesions being severe. The exact mechanism producing pulsus bisferiens is unknown.



Fig. 1.48: Enlargement of thyroid gland, mild exophthalmos,thin physique in 40-year-old female suffering from hyperthyroidism who clinically presented with atrial fibrillation and cardiomegaly and water-hammer type of pulse

DICROTIC PULSE

Description

A secondary pressure wave follows the dicrotic notch (later than the second peak of the bisferiens pulse) so that two impulses are felt with each pulse beat and may give the impression that the heart rate is twice as fast as it really is.

Cause

The normal very small secondary pressure wave produced by aortic valve closure is accentuated during its transmission



Fig. 1.49: Palpation of carotid arteries in a young child

to the peripheral arteries when the tone of the arterial system is low, classically in typhoid fever.

CAROTID PULSE

Carotid arterial pulsation is normally visible in the neck (Fig. 1.49).

1. Invisible carotid pulsation—small pulse pressure, e.g. aortic stenosis.
2. Prominent carotid pulsation—large pulse pressure, e.g. aortic regurgitation, persistent ductus arteriosus, heart block, excitement, or loss of elascity of the aorta, e.g. atheroma of the aorta and coarctation of the aorta.
3. Unequal carotid pulses:
   a. Atheroma of innominate or common carotid arteries,
   b. Aortic arch syndrome
   c. Dissecting aneurysm

COMPARISON OF THE PULSES

The radial pulses are compared one with the other and with the femoral pulses. The pulsations of both carotid arteries are also compared (Figs 1.50–1.52).



Fig. 1.50: The popliteal pulse is palpable in the popliteal fossa whilst holding the bent knee with both hands

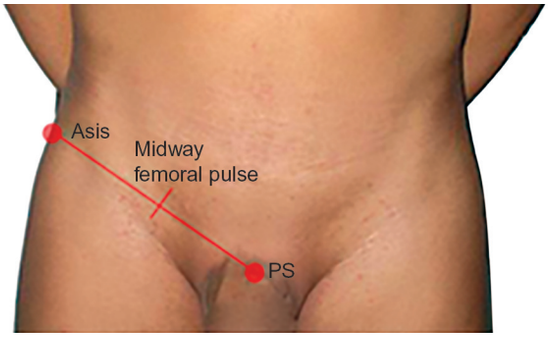

Fig. 1.51: The femoral pulse is palpable at the mid-inguinal point, halfway between the pubic symphysis (PS) and the anterior superior iliac spine (ASIS)



Fig. 1.52: The dorsalis pedis pulse is palpable over the foot, lateral to the path taken by the extensor hallicus longus (the muscle which supplies the big toe)

1. Unequal or delayed radial pulsation on one side indicates obstruction
   a. At origin of a subclavian artery, e.g. atheromatous plaque; involvement of the origin by an aortic aneurysm and origin of a subclavian artery below a coarctation of the aorta.
   b. Distal to origin of subclavian artery, e.g. subclavian or brachial embolus.
2. Femoral pulses small or delayed compared with radial pulses
   a. Coarctation of the aorta (obstruction to blood flow in the thoracic aorta)
   b. Saddle embolus

BLOOD PRESSURE

Blood pressure is the pressure exerted by circulating blood upon the walls of blood vessels. When used without further specification, 'blood pressure' usually

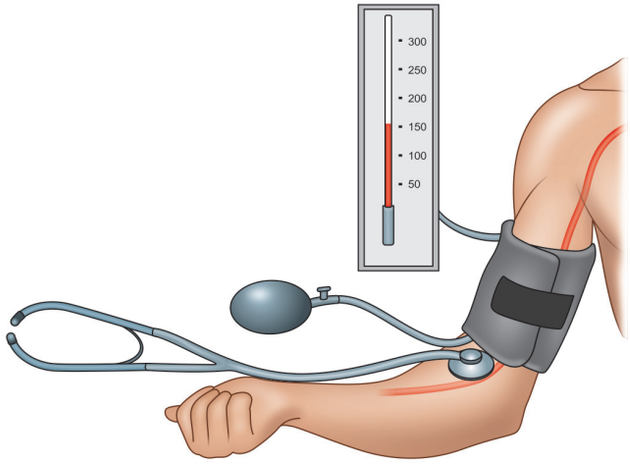

Fig. 1.53: Application of sphygmomanometer a common instrument for measuring systolic and diastolic blood pressure in human body

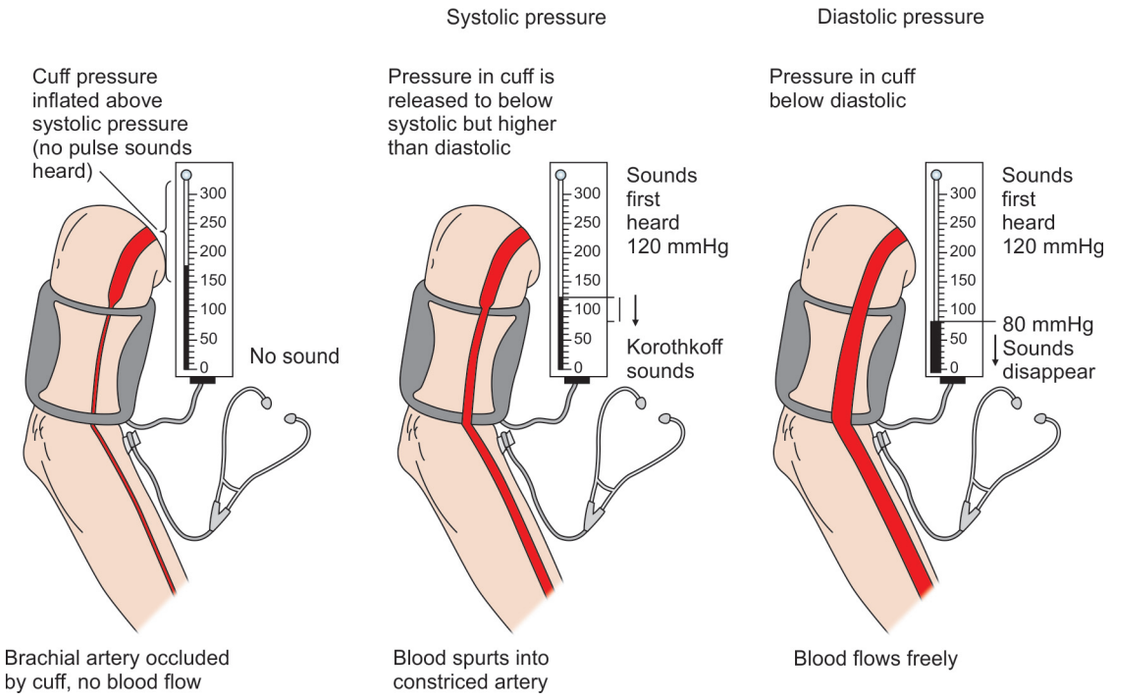

Fig. 1.54: Technique of measuring systolic and diastolic blood pressure



Fig. 1.55: Technique of measuring systolic and diastolic blood pressures with an automatic electronic instrument

refers to the arterial pressure in the systemic circulation. It is usually measured at a person's upper arm. Blood pressure is usually expressed in terms of the systolic (maximum) pressure overdiastolic (minimum) pressure and is measured in millimeters of mercury (mmHg). It is one of the vital signs along with respiratory rate, heart rate, oxygen saturation, and body temperature. Normal resting blood pressure in an adult is approximately under 140/90 mmHg (Figs 1.53–1.58).

The blood pressure depends primarily on the

1. Cardiac output
2. Peripheral resistance
3. Elasticity of the aorta, the blood volume
4. Blood viscosity



Fig. 1.56: Placing the BP monitoring equipment for 24 hours. The diagnostic test begins with fitting a patient with a portable monitor and BP cuff

Types of Blood Pressure

a. The systolic blood pressure is the peak pressure achieved during the ejection of blood from the ventricle into the aorta.

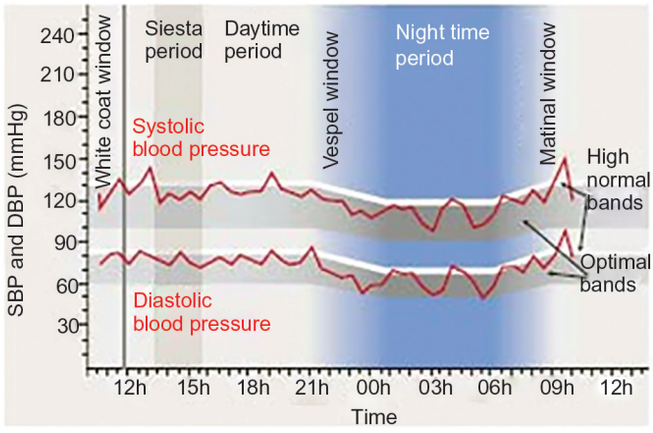

Fig. 1.57: ABPM suggests low daytime systolic and diastolic blood pressure (100 mmHg/59 mmHg) and moderate night time systolic and diastolic hypertension (146 mmHg/89 mmHg) with a white-coat effect (181 mmHg/102 mmHg). Reverse dipping pattern

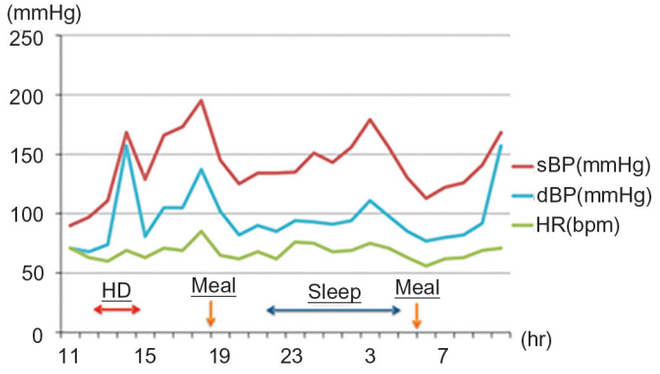

Fig. 1.58: The data of 24-hour ambulatory blood pressure monitoring (24-hour ABPM). This is the data of 24-hour ABPM on dialysis day. There was an extreme change in blood pressure during the day and the patient experienced hypotensive episodes several times. Most episodes were after inserting meal from PEG and after lying in bed, when vagus nerve was stimulated. These episodes also indicate that the patient was unable to have vasovagal reflex when there was vagus nerve stimulation

b. The diastolic blood pressure varies with the peripheral resistance. If there is a rapid escape of blood from the aorta, there will be a low pressure at the end of diastole. In the absence of anatomical leaks (persistent ductus arteriosus, arteriovenous fistula) the peripheral resistance is governed by the arterioles, vasodilatation lowering the diastolic pressure.

Measurement

An inflatable cuff firmly bound to the upper arm and connected to a mercury column is used for measurement of the arterial pressure in the arm. For accurate results, the width of the sphygmomanometer cuff must be appropriate to the circumference of the arm. A cuff 5 inches in width is correct for a normal sized adult and smaller cuffs are necessary for the children since a large cuff gives a falsely low reading. The systolic pressure is the highest pressure at which successive sounds are heard when auscultating over the brachial artery, and the diastolic pressure is taken at the point when sounds abruptly become dull and muffled.

Doppler technique may be employed when pulses are weak. Such as in pulseless disease. In the adult, top normal pressure should probably be taken to be about 120/80 mmHg. Whereas in infants and children one may apply the rule that by age one year the systolic pressure is about 90 mmHg. and increases by 5 mmHg. about every 3 years, so that by the age of 13 or 14, it has reached to adult level.

Ambulatory Blood Pressure Monitoring

It provides accurate and reliable blood pressure day and night. Ambulatory blood pressure monitoring (ABPM) is considered the gold standard for measuring blood pressure by clinicians worldwide. It provides valuable diagnostic information that in-clinic and home blood pressure monitoring systems are incapable of measuring including:

1. Blood pressure variability and a more accurate estimation of true blood pressure
2. Overnight changes in blood pressure (dipper status)
3. Morning surges in blood pressure
4. In general, ABPM is recognized in the medical community as a valuable tool for supporting the management of appropriate pharmacologic treatment as well as the assessment of 1 and 2.
5. 'White coat' hypertension, when elevated blood pressure measurements are recorded in the physican's office environment while blood pressure readings outside the physician's office are within a normal range.
6. Resistant hypertension, when multiple anti-hypertensive medications fail to adequately control high blood pressure.
7. Masked hypertension, when in-office measurements fall within an acceptable range, but the mean blood pressure is actually above the acceptable range.
8. Hypotensive symptoms with hypertensive medications.

The diagnostic test begins with fitting a patient with a portable monitor and BP cuff. The patient leaves and returns the next day. Over this period of time, the monitor takes measurements periodically as programmed by the clinician, generally each 15–30 minutes during awake hours and 30–45 minutes during sleeping hours. When the patient returns, these measurements are transferred to a computer, where they can be easily viewed and documented in a report using the enclosed AccuWin Pro™ software. The results of ambulatory blood pressure testing provide the most comprehensive representation of a patient's complete blood pressure profile.

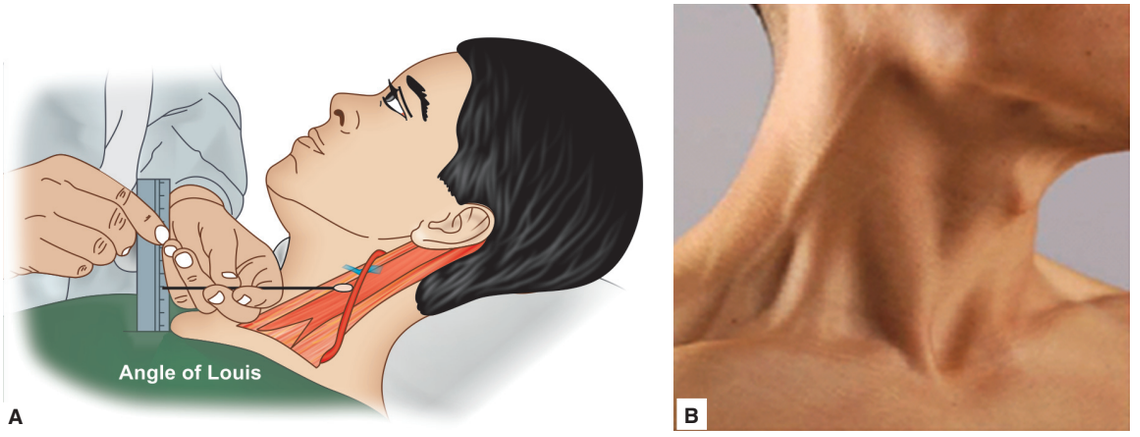

Fig. 1.59: (A) Demonstrating the RA pressure in relation to anatomical position of both RA, RV and internal jugular vein to the body positioned at 45°, (B) showing raised internal jugular venous pressure in a person with CHF

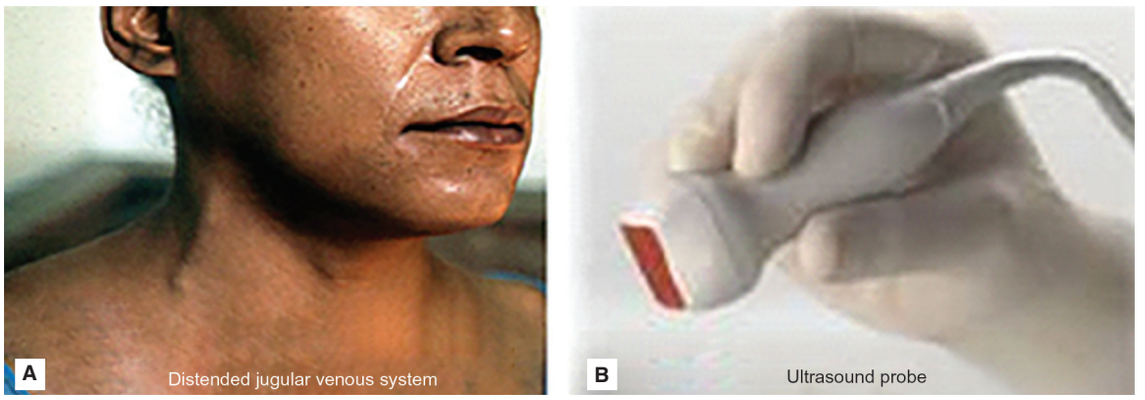

Fig. 1.60: (A) Looking at the neck veins for hours together has been a favorite pastime of our cardiology ancestors. Thanks to those sharp intellect, that has led us to this height of cardiovascular revolution. Measuring JV pressure by itself was considered a big science. Putting a patient at 45°, marking the sternal angle, identify the oscillating venous column, measuring the vertical distance, etc. Now in 2010, with bedside hand-held echo (B) one can rapidly rule out an elevated central venous pressure by imaging the jugular vein directly

JUGULAR VENOUS PRESSURE

Jugular venous pressure is depicted in Figs 1.59–1.63.

Measurement

The patient is placed at an angle of 45° with the head supported on a pillow and the pulsations of the internal jugular vein in the neck are usually visible. The internal jugular vein is collapsed except for its lower part, where the pressure from the right atrium keeps it distended. The right atrial pressure fluctuates throughout the cardiac cycle and the changing level of distension of the internal jugular vein imparts a gentle undulation to the skin of the neck which is readily distinguishable from the single sharp movement produced by carotid arterial pulsation. The vertical distance in centimetres between the top of this undulation and the sternal angle is called the jugular venous pressure and is a measurement of the pressure in the right atrium. The external jugular vein is often partially kinked and obstructed near the root of the neck and is a less reliable measure of the right atrial pressure. The jugular venous pulse is analysed for height above the sternal angel and for waveform. The normal mean pressure is 0–2 cm above sternal sangle and the waveform reveals 'a' and 'v' waves of approximately equal height. Many other workers refer the figure of 4.6 cm at 45° inclination.

Causes of a Raised Mean Jugular Venous Pressure

1. *High right ventricular filling pressure:*
   a. Right ventricular failure: Failing right ventricle requires a diastolic pressure as high as 4.0 mmHg to maintain a cardiac output of 4.0 litres per minute. The whole circulation adjusts to maintain a high right atrial filling pressure under these circumstances.
   b. High output states: A slight increase in right atrial filling pressure is required even in normal hearts for the right ventricle to maintain a high cardiac output.

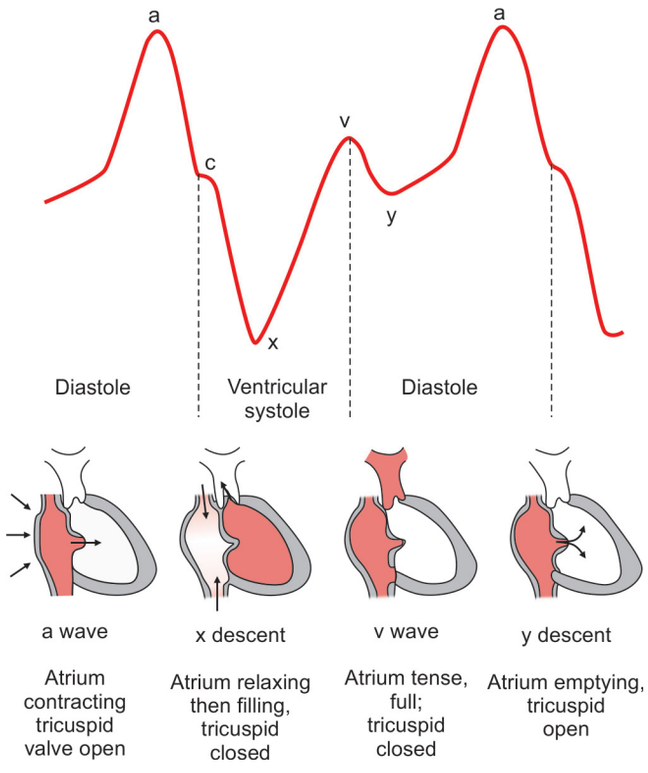

Fig. 1.61: Illustration showing graphic presentation of genesis of various waveforms in relation to cardiac contraction undulation and the sternal angle is called the jugular venous pressure and is a measurement of the pressure in the right atrium. The external jugular vein is often partially kinked and obstructed near the root of the neck and is a less reliable measure of the right atrial pressure. The jugular venous pulse is analysed for height above the sternal angel and for wave form. The normal mean pressure is 0–2 cm above sternal angle and the waveform reveals 'a' and 'v' waves of approximately equal height. Many other workers refer the figure of 4.6 cm at 45° inclination

c. Increased blood volume (over transfusion, acute nephritis). Until the blood vessels dilate to accommodate the increased volume, there is an increased venous return and a raised right atrial pressure.
d. Restriction of relaxation of the heart in diastole: Normal filling of the heart is impeded during diastole in tamponade and in constrictive pericarditis.

2. *Obstruction to blood flow from right atrium to right ventricle (tricuspid stenosis, right atrial myxoma):* A high right atrial pressure serves to maintain the blood flow across the obstructed region.
3. *Superior vena cava obstruction (involvement by or retrosternal thyroid gland enlargement):* The distended veins do not pulsate which distinguishes this cause of an elevated venous pressure.
4. *Loss of negative intrathoracic pressure (emphysema, pleural effusion and pneumothorax):* Any rise in pressure within the thorax is transmitted to the right atrium.

ABNORMALITIES OF WAVEFORM IN THE JUGULAR

Venous Pulse

Normal

Two peaks (a and v) and two troughs (x and y) are seen during each cardiac cycle. The waves are timed by relating them to the carotid pulse. The a wave precedes the carotid arterial pulse and is the pressure wave of right atrial systole. A fall in pressure follows, the x descent, during which the right atrium relaxes. The v wave is the positive pressure wave immediately after the carotid pulse and represents the rise in pressure in the right atrium, as it fills with the tricuspid valve closed during ventricular systole. At the termination of ventricular systole with the opening of the tricuspid valve, blood leaves the right atrium and its pressure falls, producing the y descent. The a and v waves are of approximately equal height and do not rise more than 2 cm above the sternal angle.

Abnormalities of the a Wave

1. *Large a wave (powerful right atrial contraction):* This implies an increase resistance to blood flow from right atrium to right ventricle. The resistance may be at valve level

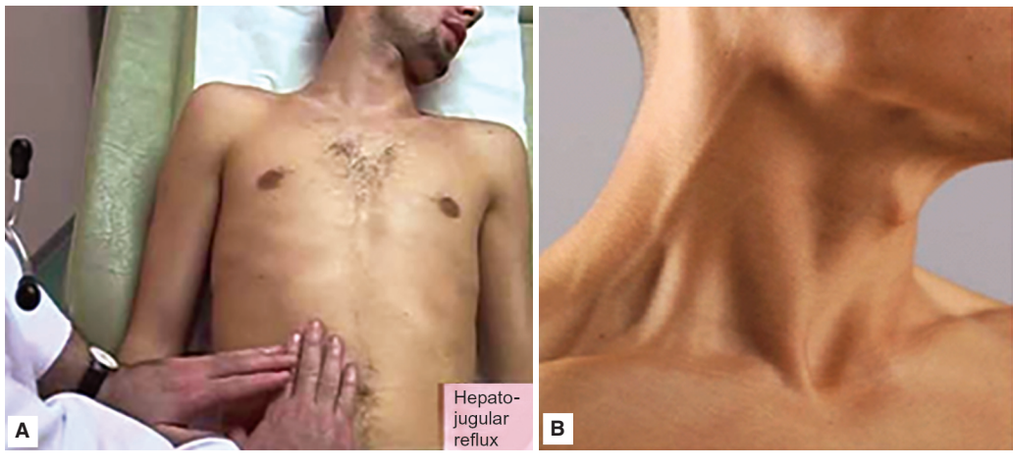

Fig. 1.62: (A) Doctor is pressing over the liver area and looking for distension of neck veins to demonstrate hepatojugular reflux in an adolescent with congestive heart failure and (B) engorged jugular vein in intractable heart failure

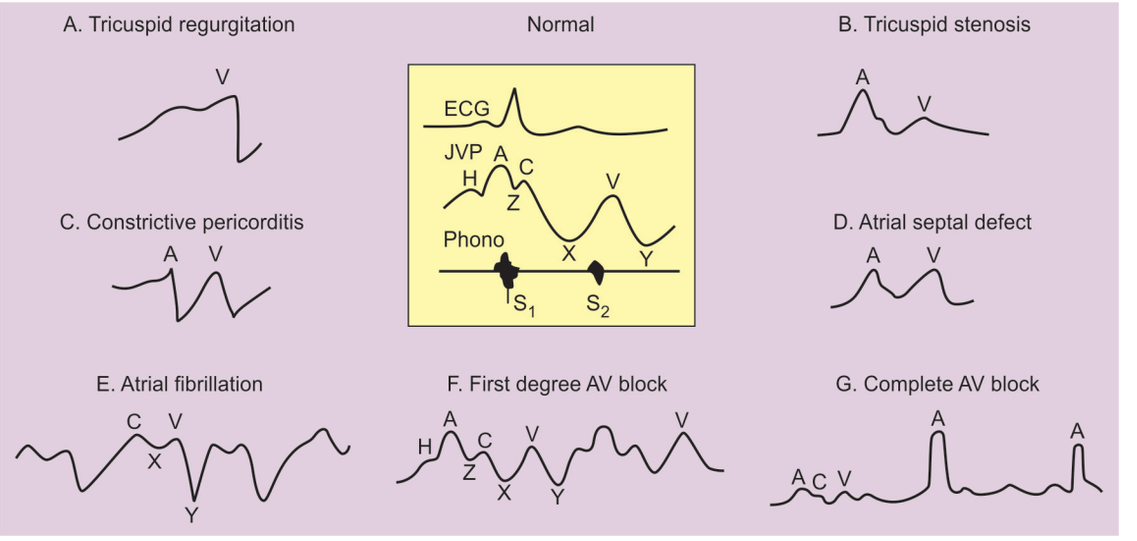

Fig. 1.63: Schematic representation of the normal jugular venous pulse (JVP), four types of abnormal JVPs, and the JVPs in three arrhythmias

(tricuspid stenosis, tricuspid atresia), or the right ventricle may offer more resistance to filing when its walls are hypertrophied (pulmonary stenosis, pulmonary hypertension).

2. Absent a wave non-coordinated contraction of the right atrium), i.e. atrial fibrillation.

Abnormalities of the v Wave

Large v waves indicate considerable reflux of blood into the right atrium during ventricular systole, i.e. tricuspid valvular regurgitation (TR).

Abnormalities of the x Descent

It is absent in atrial fibrillation. Accentuated in tamponade and in some cases of constrictive pericarditis. During ventricular systole, blood is ejected from the heart into the pulmonary artery and into the aorta. The decrease in volume of the ventricles with the rigid pericardial sac creates more volume available for filling of the right atrium from the great veins.

Abnormalities of the y Descent

1. *Sharp y descent:* The higher the venous pressure the more abrupt is the fall in pressure when the tricuspid valve opens, provided there is no obstruction to flow from the right atrium into the right ventricle.
2. *Slow y descent:* This provides evidence of obstruction to flow from right atriam into right ventricle and is found in tricuspid stenosis or when there is tumor mass within the right atrium.

Cannon Waves

Large venous pressure waves synchronous with the carotid pulse, produced by atrial contraction against a closed tricuspid valve. A cannon wave, therefore, implies atrial contraction coinciding with ventricular systole (Fig. 1.64).

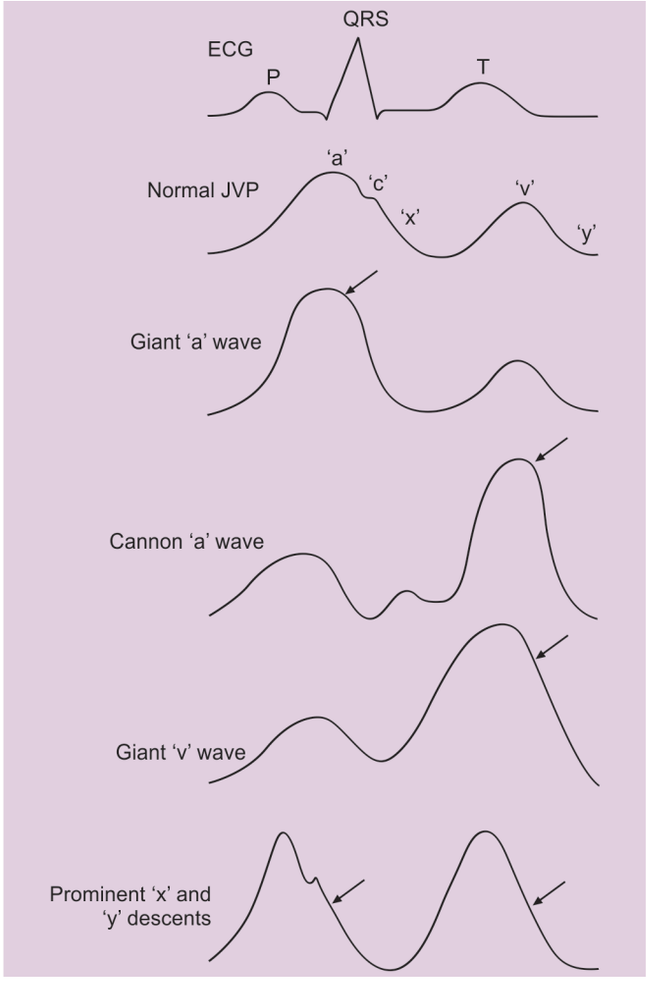

Fig. 1.64: The jugular venous pulse (JVP). Electrical events always precede mechanical events. Thus, the P-wave of the ECG (representing atrial depolarization) and the QRS complex (representing ventricular depolarization) precede the 'a' wave and the 'v' wave of the JVP, respectively

Causes of Cannon Waves

Regular fast cannon waves are found in paroxysmal nodal tachycardia. Occasional irregular cannon waves are also encountred in complete heart block. Cannon waves are only seen when atrial and ventricular systole happen to coincide.

Respiratory Variation and Kussmaul's Sign

The mean jugular venous pressure normally falls with inspiration, passively following the intrathoracic pressure. In some patients with decreased RV compliance, the relative height of the 'a' wave will increase with inspiration even though the mean venous pressure falls. This is considered to be related to an enhancement in the force of atrial contraction wth atrial distention caused by the ventilatory increase in the venous return. Subjects with a marked decrease in RV compliance, such as those with constrictive pericarditis. In the later, there is a rise in the mean height of the jugular venous pulse during inspiration. This is known as Kussmaul's sign and is observed approximately 40% of the patients with constrictive pericarditis. Kussmaul's sign is generally not seen in patients with pericardial tamponade or massive pericardial effusion (Fig. 1.65).

NORMAL PRECORDIAL ACTIVITY

Examination of the heart begins with observation and palpation of the chest for abnormal impulses and thrills The palpable apical impulse in a normal subject is produced by an anterior movement of the left ventricle during early systole. As isovolumic intraventricular pressure rises, the left ventricle rotates in a counterclockwise direction on its long axis as the cardiac apex lifts and makes contact with the left anterior chest wall following aortic valve opening and the first half of ejection, the LV chamber moves away from the chest wall and continues to diminish in size until systole is completed. Thus, the impulse felt or recorded on the precordium is made up of an early outward thrust followed by retraction during the last part of systole; normal palpable cardiac activity occurs only during the first half of systole. The retraction wave can be seen but is not felt. Diastolic events, such as the LV rapid filling phase or left atrial contraction, are normally not palpable. In angiographic studies, the interventricular septum (composed mostly of LV muscle) and the anteroseptal aspect of the left ventricle makes contact with the inner thoracic cage to form the palpable apical impulse. The true anatomical LV apex is actually slightly lower and more lateral than the palpable apical impulse.

How to Examine the Precordium

For optimal precordial examination, it is important for the examiner and the patient to be relaxed. The room should be confortably warm. Clothing and undergarments must be removed to allow wider inspection and palpation of the chest. Because the examiner must be prepared, e.g. to count intercostal spaces, measure the distance of the precordial impulse from the sternum or axillary line, and chest exposure should be maximal. The patient should be lying comfortably, in the supine position or with the thorax elevated not more than 30°. Perloff suggests that the 30° position is preferable because precordial examination in this position may bring out abnormalities more often than

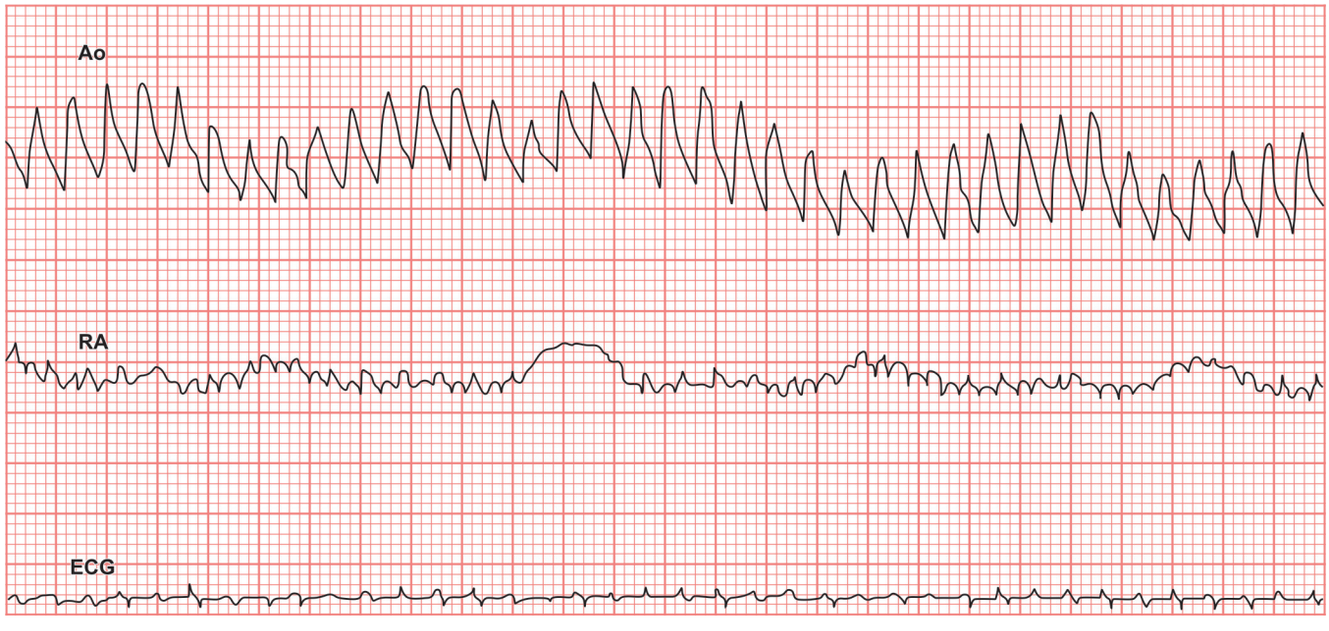

Fig. 1.65: Paradoxical pulse and Kussmaul's sign. Pericardial effusion (evidenced by the small voltage deflexions on the ECGI has caused tamponade. Respiratory fluctuations in the aortic (Ao) and right atrial (RA) pressure signals are seen. During inspiration aortic pressure falls markedly (paradoxical pulse) and right atrial pressure rises (Kussmaul's sign)

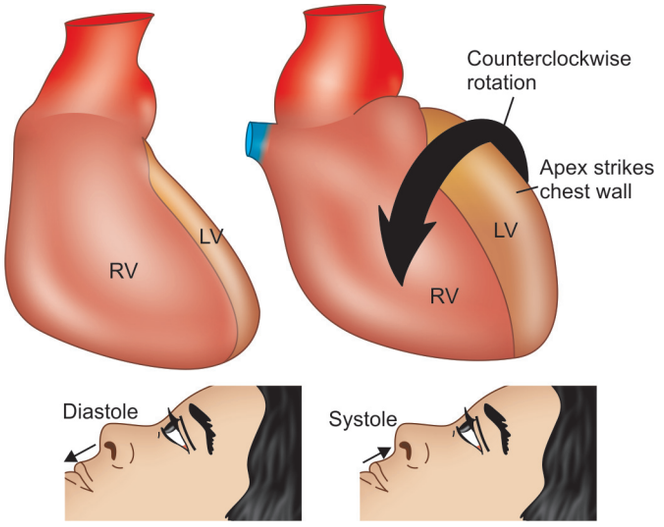

Fig. 1.66: Diagrammatic demonstration of apical movements in syslole and diastole during cardiac cycle

when the patient is lying supine. In a given patient, cardiovascular diseases should routinely be examined in the left lateral decubitus position; the subject should be instructed to turn on his or her left side at a 45° to 60° angle with the examining table, elevating the left arm over the head, so that the examiner may have unobstructed access to the left precordium (Fig. 1.66).

1. INSPECTION

Careful inspection of the chest is useful in the precordial examination, particularly after preliminary palpation has identified the site of the apical beat or any other impulses that may be present. Retraction movements, which may be more obvious than outward motion are quite prominent in severe degrees of LV enlargement. Tangential lighting with the examining lamp or a pen torch may accentuate visible movements on the chest wall (Figs 1.67, 1.68 and Table 1.2).

2. PALPATION

The physician should be standing comfortably at the patient's right side. Both the palm of the hand and the ventral aspect of the proximal metacarpals and fingers should be used for palpation (Figs 1.69–1.71). One must learn which aspect the hand has the best sense of touch, it is advisable to use the pads of the fingers for precise localization and assessment of LV and RV activity. The palm and proximal metacarpals are usually best used to localize palpable cardiac motion as well as to detect precordial thrills. Varying pressure with the hand should be applied once a precordial impulse has been identified.

High frequency sounds, such as an increased S1, and opening snap, or a transmitted thrill, are best localized with the hand firmly applied to the chest. However, the subtle, low frequency motion of a palpable S3 or S4 or double systolic apical impulse will be felt only with light pressure of the fingers and may be totally obscured if the examination is not performed correctly. In most normal subjects, parasternal activity is not usually detectable. However, in young or thin people, a gentle shock or tap at the lower left sternal border may be felt, and, occasionally, a pulmonary artery mpulse in the second to third left intercostal space adjacent to the sternum may be detected. Forceful, unstained, or high amplitude parasternal motion is always an abnormal finding.

Point of Maximum Impulse (PMI)

Many textbooks use the term for PMI, the same as the apical beat. Although not ideal, this expression is so frequently



Fig. 1.67: (A) Pectus excavatum deformity of chest in VSD. (B) Photograph of 20 years old male had bicuspid aortic stenosis with AR with LVH. He was successfully operated with AVR and regular follow up for more than 6 years maintained good health



Fig 1.68: Dual chamber pacemaker with epicardial electrodes implanted through a median sternotomy in a newborn with complete heart block

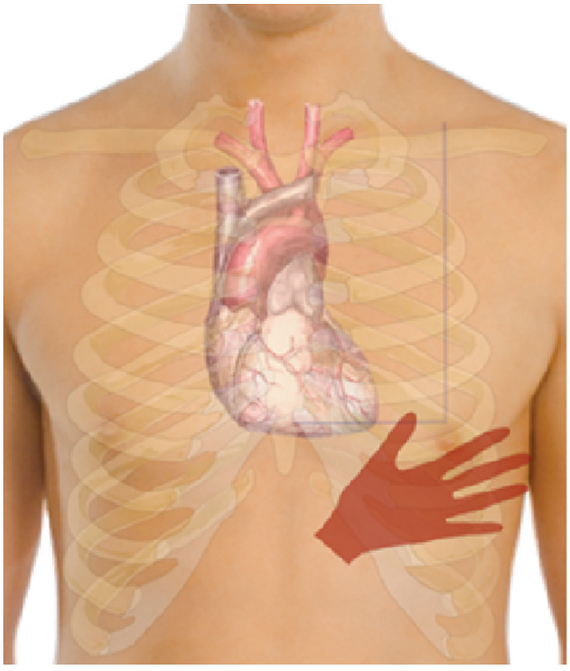

Fig. 1.69: The apex beat is the lowest, most lateral point where the heartbeat can be felt

used that it has become acceptable to many. Nevertheless, it should be recognized that the terms PMI and apical impulse are not necessarily synonymous. In some patients, the most prominent, 'maximal', impulse may actually reflect ectopic LV motion, RV activity, or a vascular impulse.

Other Palpable Events

In a subject with suspected cardiac disease. the examiner should explore the entire precordium with firm pressure of the hand and proximal fingers, separating the aortic, pulmonic, lower sternal and apical regions. In this way, the unexpected vascular impulse, such as a dilated or aneurysmal ascending aorta or pulmonary artery, may be detected. Particular attention should be given to the upper sternal area, to the manubrium, and to the adjacent first to second intercostal spaces below the medial aspect of the clavicles. Aortic pulsations and systolic thrills are often found there. If a patient has coronary artery disease, particularly with a prior myocardial infraction, careful

Table 1.2: Clinical classification and causes of precordial impulses

Site of impulse	Sustained	Hyperdynamic	Late systole
1. Parasternal area	***Pressure overload:***	Hyperkinetic circulatory	Severe mitral
	Pulmonary hypertension	states in young subjects	regurgitation
	Cor pulmonale		
	Mitral stenosis	***Volume overload:***	
	Pulmonary emboli	Atrial septal defect	
	Cardiomyopathy	Tricuspid regurgitation	
2. LV (apical beat)	***Pressure overload:***	Hyperkinetic	LV dyssynergy HOCM
	Hypertension aortic stenosis	circulatory states	
	Chronic or severe	Thin chest wall	Mitral valve prolapse (uncommon)
		Pectus excavatum	
	Volume overload:		
	LV dilatation,	***Volume overload:***	
	especially with decreased	Aortic regurgitation	
	ejection fraction	Mitral regurgitation	
	LV dysfunction	Ventricular septal defect	
	LV aneurysm		

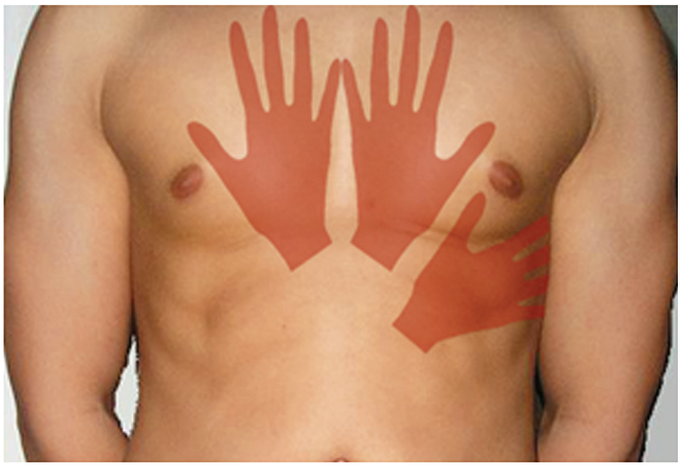

Fig. 1.70: Heaves and thrills can be detected by placing the hand flat against either side of the sternum and over the apex of the heart

examination for ectopic impulse should be carried out. These typically occur medial and superior to the ectopic impulse. The use of the entire palm and proximal metacarpals will help to detect the diffuse lift of a very large left or right ventricle. At times the entire anterior precordium will move in systole. This technique is also suited for detection of thrills and palpable heart sounds.

Assessment of the Apical Cardiac Impulse

The assessment of the apical cardiac impulse should include analysis of the following headings:

- Location
- Size
- Force
- Duration
- Contour

In addition, there should be visual inspection of the chest for the presence of prominent retraction waves as well as for systolic and diastolic events.Timing of precordial events is best carried out by simultaneously palpating the carotid arterial pulse with the left hand. Some find that concomitant auscultation of S1 and S2 is useful for timing purposes. Application of the stethoscope chest piece directly on the apical impulse can help identify systole.

It is desirable to use held end expiration for the RV examination. Firm pressure, using the heel of the hand with the wrist turned upward, is advisable. The lower sternum and adjacent third through fifth rib and left interspaces should be examined in this manner. The examining hand and fingers should be carefully observed, as low amplitude RV activity is often found in epigastric region, with the extended fingers oriented superiorly; the patient should be instructed to hold his breath in end-inspiration and careful palpation for the descending right ventricle is



Fig. 1.71: Palpating the heart. (A) Use the hand to palpate the cardiac impulse. (B) Localise the apex beat with a middle finger. (C) If necessary, roll the patient into the left lateral position. (D) Palpate from apex to sternum for parasternal pulsations

performed. This technique is particularly useful in patients with an increased anteroposterior diameter, obesity or chronic obstructive lung disease.

Characteristics of the Normal Apical Impulse

1. A gentle, nonsustained tap.
2. An early systolic anterior motion that ends before the last third of systole.
3. Location within l0 cm of the midsternal line in the fourth or fifth left intercostal space.
4. A palpable area less than 2–2.5 cm^2 and detectable in only 1 intercostal space.
5. RV motion that is not normally palpable.
6. Diastolic events that are normally palpable.
7. Complete absence in some older individuals.

Location

To identify the site of the apical impulse on the thorax with respect to both the longitudinal and horizontal axes of the patient. To note in which intercostal space the, PMI or apical beat is located; occasionally a large heart will result in detectable precordial activity in 2 or even 3 intercostal spaces. Localize the apical impulse with reference to the mid-clavicular line, distance from the midsternum or relationship to the left anterior axillary line.

Size

If the apical impulse is larger than normal, it is useful to note the area of contact with the chest. Any area greater than 2–2.5 cm^2 in the supine position, or greater than 3 cm^2 in the left decubitus position, represents cardiac enlargement.

Force or Amplitude

Is the apical beat a soft, unimpressive impulse? Or Does it lift the examining fingers off the chest well? Is the anterior or outward excursion greater than normal or consistent with a hyperdynamic or hyperkinetic PMI? An increase in force is consistent with LV hypertrophy with preserved systolic functions. Assessment of the force of contraction is the most subjective and least quantifiable aspect of precordial examination.

Duration

The duration of the systolic outward motion is probably the most important feature of the precordial examination, although cardiomegaly or hypertrophy can exist in the presence of a brief 'normal' outward movement, or even when the PMI is absent, truly sustained LV impulse in the supine or 30° elevation position is distinctly abnormal. Such findings suggest a pressure overstressed ventricle (e.g. aortic stenosis, hypertension or an LV chamber with a depressed ejection fraction and a substantialy dilated cavity. A Study by 'Conn' demonstrated that a sustained apex impulse in the supine position was highly correlated with an increase in angiographically determined LV mass, and this observation was actually more sensitive than the electrocardiogram (ECG) in the diagnosis of LV hypertrophy. The critical point to assess is whether or not the impulse 'stays up' into the second half of systole. Timing that uses simultaenous auscultation of S1 and S2 is essential in making this observation. With practice, one can be quite accurate in assessing the actual duration of the apical impulse. Simple observation of movement of the chest piece of the stethoscope resting on the PMI may be helpful.

Left Lateral Decubitus Position

It is unclear whether LV impulse that becomes sustained when the patient is turned into left lateral position which is of normal duration in the supine position, has the same specificity for LV enlargement as a sustained impulse (LV heave) that is present when the patient is lying flat. Since the left decubitus position causes the heart to approximate the chest wall more closely, many experts feels that the observation of a prolonged impulse in this position has little diagnostic value. Some believe that a definite sustained impulse in the left lateral position is highly indicative of true LV dilatation. False positives may occur, however, echocardiography is recommended in equivocal cases.

Contour

The normal apical impulse is a brief, nonsustained anterior motion in early systole. A sustained LV movement is the commonest abnormality of contour, but occasionally other different types are also recorded.

A Double Systolic Impulse or Bifid Impulse

It may be seen in hypertrophic obstructive cardiomyopathy (IHSS) and occasionally in some patients with severe LV dyssnergy or LV aneurysm in coronary artery disease. Presystolic distention is commonly found in the left lateral position in subjects who have decreased LV compliance, complicated from coronary artery disease, hypertensive heart disease, or aortic valve disease. Palpable diastolic events, such as an S3 or a pericardial knock, also fall into the general category of contour variations.

Palpable a Wave (Presystolic Distention)

Palpable a waves are usually detected in the left posture. The apical beat is carefully localised, and varying pressure is applied with the pads of the fingers at the site of the LV impulse. A double early systolic impulse is noted, feeling like a 'shelf or ridge' on the upstroke of the beat. Usually, this low amplitude finding will best be felt when finger pressure is light; firm pressure with the fingers may make the finding more difficult or impossible to feel. On occasion, this presystolic distention can be quite prominent. The palpable a wave reflects a high LV end-diastolic pressure and decrease LV compliance. It is important observation because it documents a definite abnormality that usually implies LV hypertrophy and increased chamber stiffness. The audibility of the S4 does not correlate with palpability; presystolic distention may be detectable when the S4 is quite soft. Occasionally, one may not be able to hear an S4 at all, even though it is palpable; this is because the

frequency of the diastolic filling event is extremely low (usually, less than 60 cycles per second).

Palpable S3

The S3 is less often palpable than an S4. It is most often observed in severe mitral regurgitation or in a markedly dilated cardiomyopathic ventricle. As with S4, palpation is greater enhanced in the left decubitus position. The S4, appears as a brief outward motion in early systole, gently tapping the examining finger pads, but not displacing the fingers, since it is usually not forceful.

Palpable S4

A palpable S4 is related to decreased LV compliance usually as a result of hypertrophy without dilatation or ischemia with increased, diastolic stiffness. A palpable S4 is always associated with LV end-diastolic pressure that is elevated, sometimes strikingly so, although early and mid-diastolic pressure is often normal in hypertensive heart disease, coronary artery disease, and occasionally, in congestive cardiomyopathy. The implications of a palpable S4 are quite different from those of a palpable S3 in the former case, LV systolic function is usually well preserved and the ejection fraction is normal. A palpable S3 (in the absence of significant mitral regurgitation) is associated with high LV filling pressurs, as in dilated ventricle, and decreased systolic function.

Palpable Right Ventricle (S3 and S4)

The pathophysiology of palpable S3 and S4 generated in the right ventricle is similar to that in the left heart. Compliance changes (RV hypertrophy secondary to pulmonay hypertension) may result in a palpable RV S4. Increased blood flow across the tricuspid valve may produce a prominent S3. Tricuspid regurgitation is a good example. A large left-to-right shunt and atrial septal defect may also occasionally produce a palpable RV S3. In severe RV dysfunction, an S3 may be heard and felt. Classically, RV events are marked by inspiratory augmentation and expiratory attenuation or disappearance.

Other Causes of Palpable Cardiovascular Activity

In addition to the tactile precordial phenomena related to LV and RV systolic and diastolic events palpable precordial activity is occasionally detectable as a result of vascular pulsations or ectopic LV wall motion abnormalities.

Palpable Cardiovascular Events at the Level

Aorta

When either the ascending aorta or the aortic arch is enlarged or dilated, palpable systolic pulsations may be detected. Thus, with aortic aneurysms, diffuse aortic dilatation, or aortic dissection, a systolic impulse may be felt in the right first or second intercostal space, in the right or left sternoclavicular junction, or in the suprasternal areas. Dilatation or enlargement of the brachiocephalic vessels may also cause prominent vascular pulsations at the supersternal notch or above the clavicles.

Pulmonary Artery

Dilatation or enlargement of the pulmonary artery is usually associated with pulmonary hypertension, which itself may resuit from hyperkinetic; high flow states or from increased pulmonary vascular resistance. Idiopathic dilatation of the pulmonary artery results in an enlarged proximal pulmonary artery segment. All these conditions may produce a palpable systolic impulse in the second to third left intercostal space just to the left of the sternal edge. This is easily detectable in thin subjects.

Left Ventricular Ectopic Impulse

Focal wall-motion abnormalities or big LV aneurysms may produce systolic impulses that are detectable at sites away from the LV apical beat, usually medial and superior to the apical area. With anteroseptal LV scarring or dyskinesis, the ectopic impulse may be found at the lower parasternal edge and thus may simulate RV activity.

Palpable Heart Sounds and Murmurs

Loud sounds, such as an increased S1, A2 or P2 are often readily palpable. An opening snap is commonly palpable in mitral stenosis, as a loud S1, on occasion the diagnosis of this valve lesion can be made prior to using the stethoscope. Ejection clicks may be easily felt; the aortic ejection sound is detected at the LV apex, while a pulmonic ejection sound is palpable at the upper left sternal border.

Thrills

Any loud murmur may be transmitted to the chest wall, where it can produce a vibratory sensation to the examining hand. These palpable murmurs or thrills correlate with a murmur intensity of grade IV/VI or greater. Such murmurs may be felt at the apex (mitral regurgitation, hypertrophic obstructive cardiomyopathy), left sternal border (ventricular septal defect) or cardiac base (pulmonic stenosis, aortic stenosis). Obviously, in thin subjects the likelihood of a thrill is greater than in muscular or bulky patients. A diastolic thrill may occasionally be felt usually a the apex with the subject in the lateral decubitus position in mitral stenosis, or at the lower left sternal border in acute aortic regurgitation secondary to a perforated or ruptured aortic cusp.

PERCUSSION

Under ordinary circumstances, percussion is neither necessary nor useful. When a PMI cannot be identified, however, the technique may help establish the presence or absence of cardiomegaly and will identify the approximate left border of the heart. In patients with a large pericardial effusion, the apex beat may actually be detected inside the lateral border of the cardiac silhouette, as determined by percussion (Figs 1.72 and 1.73).



Fig. 1.72: Senior resident in cardiology is demonstrating to the medical students the clinical technique of percussion on the chest of one of the patients admitted to the medical college hospital

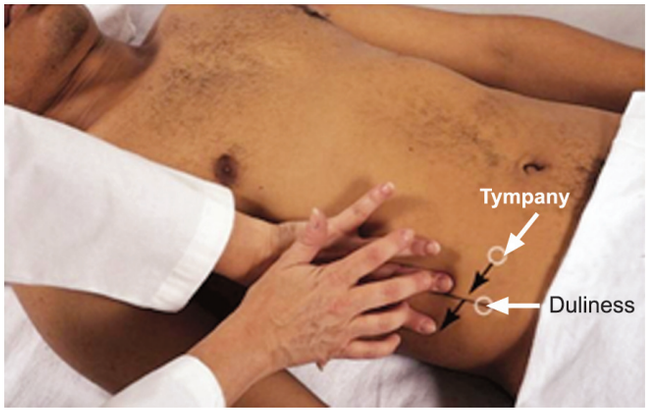

Fig. 1.73: Method of percussion over lower lung and liver areas for fluid and enlargement in patient with heart failure



Fig. 1.74: (A) Conventional stethoscope used by the doctors for auscultation. (B) 3M Littmann Scope-to-Scope Tele-Auscultation System for remote diagnosis

AUSCULTATION

Auscultation is depicted with Figs 1.74–1.85.

Stethoscope

The chest piece should have a diaphragm and a bell. High frequency sounds and murmurs are heard better with the diaphragm, e.g. opening snap and aortic diastolic murmur. The bell transmits low frequency sounds better, e.g. gallop sounds, and mitral diastolic murmur. The bell should be applied very lightly to the chest when listening for these low frequency sounds.

New Visual, Amplified Stethoscope for Hearing Impaired Clinicians

Properly diagnosing the patients using a stethoscope requires good hearing to discern the murmurs from normal heart sounds. Yet many doctors and nurses suffer from poor



Fig. 1.75: New visual, amplified stethoscope for hearing impaired clinicians



Fig. 1.76: (A) Mobile phone stethoscopes, and (B) its applicability over the chest of the patient



Fig. 1.77: Heart murmur detection software designed to support physicians in analyzing cardiac sounds for the identification and classification of suspected murmurs

hearing, making it difficult to auscultate their patients, seriously hampering their ability to perform a basic screening. The Cardionics ViScope aims to solve that problem by providing both amplification of the audio signal and a visual display of the phonocardiogram or phonopneumogram.

The device is compatible with in-the-ear or open fit behind-the-ear hearing aids, offering the ability to boost the signal 30 times over a conventional stethoscope. Visualization assists the listener in identifying the position of clicks, rubs, knocks, snaps or murmurs in the cardiac cycle. Murmurs such as aortic stenosis, aortic regurgitation or mitral regurgitation are clearly seen. Pediatric sounds including atrial septal defect, ventricular septal defect and primary pulmonary hypertension are easily identified.

How it works: Simply place the stethoscope on the chest and as the sounds are detected, the phonocardiogram of heart sounds will be displayed on the screen. Sounds can be downloaded to the ViScope-100 software for storage and recall. With a resolution of 1024×768 pixels, the software allows the trace to be enlarged for a better view. Calipers allow measurement of events such as the opening snap of mitral stenosis.

Mobile Phone Stethoscopes

A team of researchers from the University of Oxford have developed a new kind of stethoscope that uses the micro-

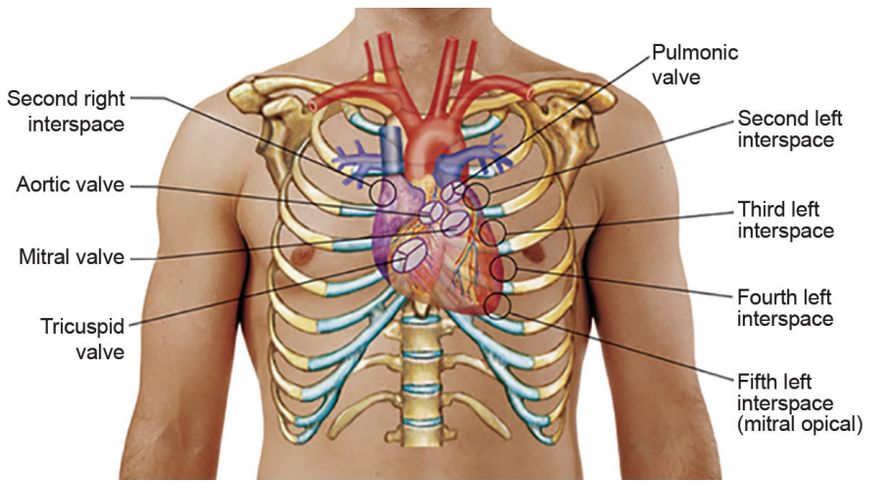

Fig. 1.78: Diagrammatic representation of conventional area of auscultation



Fig. 1.79: Method of auscultation lying left lateral position for augmentation of apical events



Fig. 1.82: Method of auscultation for aortic defects



Fig. 1.80: Method of auscultation lying supine in the bed at 45° position for apical events



Fig. 1.83: Method of auscultation while sitting and leaning farward posture for augmentation of aortic and pulmonary events



Fig. 1.81: Method of auscultation for mitral and tricuspid valvular defects



Fig. 1.84: Method of auscultation for pulmonary valve

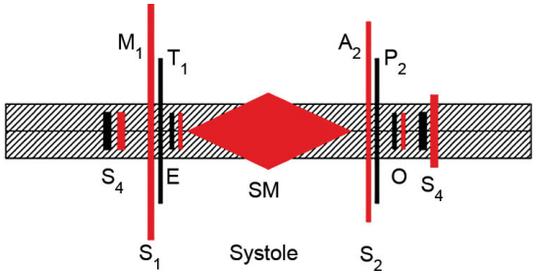

Fig 1.85: Heart sound events represented graphically. The red bars represent left-side events, and the black bars represent right-side events. The gray area is normally inaudible. The first heart sound (S1) contains two components—the mitral valve closure sound (M1) and the tricuspid valve closure sound (T1). The second heart sound (S2) contains two components—the aortic valve closure sound (A2) followed by the pulmonary valve closure sound (P2). The presystolic (atrial) gallop sound (S4) is normally inaudible. The prodiastolic (ventricular) gallop (S3) may be audible and is normal in children. Innocent systolic murmur (SM) is a common normal finding, especially in children. Ejection sounds (E) are normally inaudible. Opening snaps (O), if audible, indicate some level of pathology. Adapted from Leatham

phone input of a cell phone. The rudimentary stethoscope is basically a cell phone with an external microphone attached to the base of an egg-cup to focus and collect the sounds. The phonocardiograms recorded can be analyzed by a computer to filter out distortion and noise and process the signal to identify heart rate and abnormal heart sounds. So far, the stethoscope has been tested with an iPhone 3G and a Nokia 3100 Classic. Surprisingly, the Nokia 3100 Classic outperformed a 3M Littmann Electronic Stethoscope in detecting heart rate. According to Oxford, an Android version of the phonocardiogram processing software is also in the work.

A New Littmann Scope-to-Scope Tele Auscultation System

It allows physicians to remotely listen to patients using a stethoscope as though they are on-site. Using bluetooth connectivity, the system transfers the real time audio gathered on one Littmann Model 3200 stethoscope to another, anywhere in the world. It is truly amazing how the stethoscope, from being a medical diagnostic device, has moved to also become a communication and telemedicine device.

- Allows clinicians to provide world-class patient care by hearing internal sounds of the body clearly across data networks in real-time, from anywhere in the world.
- Uses the bluetooth enabled Littmann Model 3200 electronic stethoscope.
- Offers a user-friendly design and phenomenal sound quality.
- Requires one-time software set-up that takes only a few minutes to complete.
- At the patient site, the scope-to-scope software digitally captures heart sound with a state-of-the-art sound sensor, wirelessly transfers the sound to software using the bluetooth → enabled Littmann → Model 3200 electronic stethoscope, and sends the sound across the internet securely.
- At the consultant site, the sound is delivered to the eartips of the consultant, who hears the patient's internal sounds as if the patient were in the room.

Site of Auscultation

The site of maximum intensity of a sound of murmur is important in deciding its origin, but it cannot be taken as reliable clinical observation, e.g. the murmur of aortic stenosis is frequently loudest at the apex. The diagnosis of the basic defect accounting for a murmur is considerably more accurate when the murmur is also analysed for:

- Timing
- Quality
- Direction of selective propagation
- Influence of respiration.

Mitral Events

Loudest in the region of the apex beat heard with the patient turned on the left side and with the breath held in expiration (heart nearest chest wall with increased flow through valve on expiration).

Tricuspid Events

Localised to the fourth left intercostal space at the sternal edge. Accentuated by inspiration (increased flow across valve during inspiration) (Fig. 1.81).

Aortic Events

Systolic murmur loud in the aortic area, at the cardiac apex and over the carotid arteries in the neck (Figs 1.82 and 1.83).

Regurgitant murmur loudest in third and fourth left intercostals spaces at the sternal edge with the patient leaning forward in expiration (direction of the turbulent jet).

Pulmonary Events

Loudest in the pulmonary area and usually localised to it. Accentuated during inspiration. Low pressures in the right heart produce soft noises which are not conducted widely, but become louder with the increased blood flow into the lungs with inspiration (Fig. 1.84).

THE HEART SOUNDS

The sudden tensing of a heart valve produces vibrations to both the valve and chordae tendineae and papillary muscles attached to the valve. Many of the vibrations, so produced are within the acoustic range of the ear, and the normal and abnormal heart sounds are the audible vibrations produced in this way from the four valves of the heart (Figs 1.85–1.89 and Tables 1.3 and 1.4).

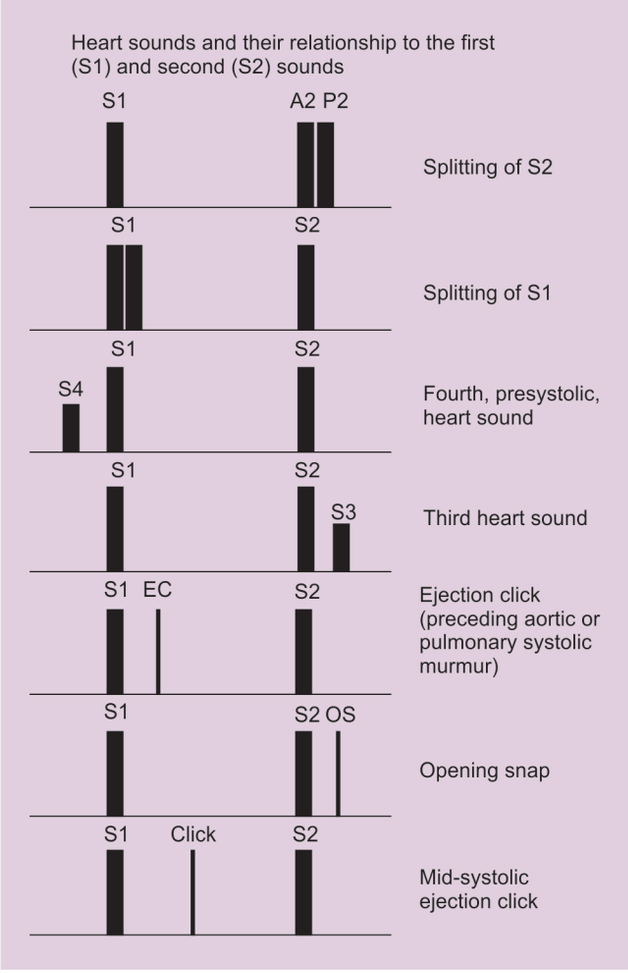

Fig 1.86: Diagrammatic representation of various types of ejection clicks, sounds and their splitting, along with opening snap at different timings of human cardiac cycle

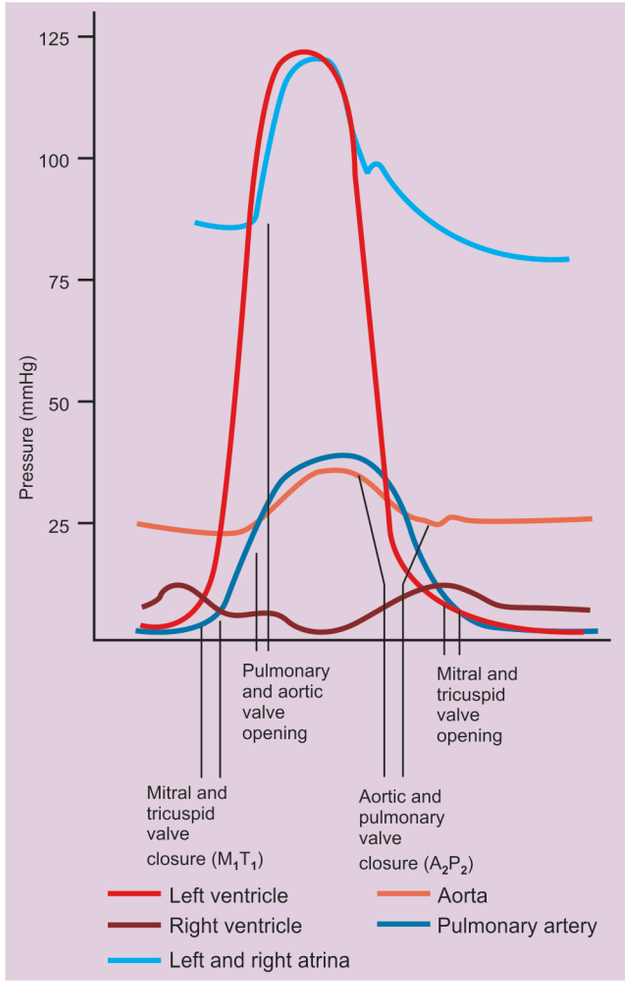

Fig. 1.87: Intracardiac tracings of LV, RV, RA, LA, aorta and pulmonary artery demonstrating opening and closure of mitral and tricuspid valve (M1-T1) and opening and closure of aortic and pulmonary valves (A2- P2) in cardiac cycle of normal person

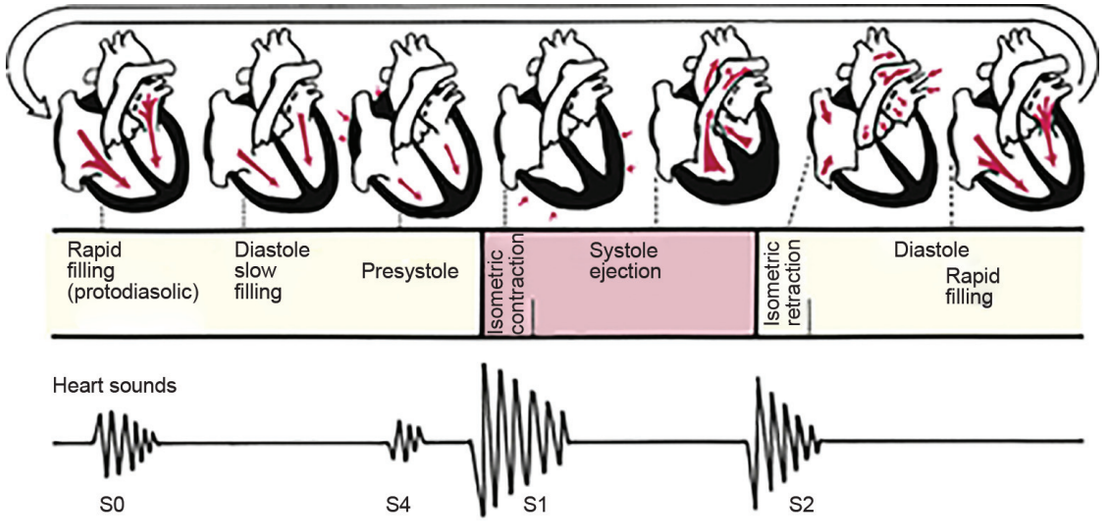

Fig. 1.88: Cardiac sounds and associated cardiac physiological changes are part of the cardiac cycle (From Jarvis C: Physical examination and health assessment, 5th edition, Philadelphia, Saunders, 2008)

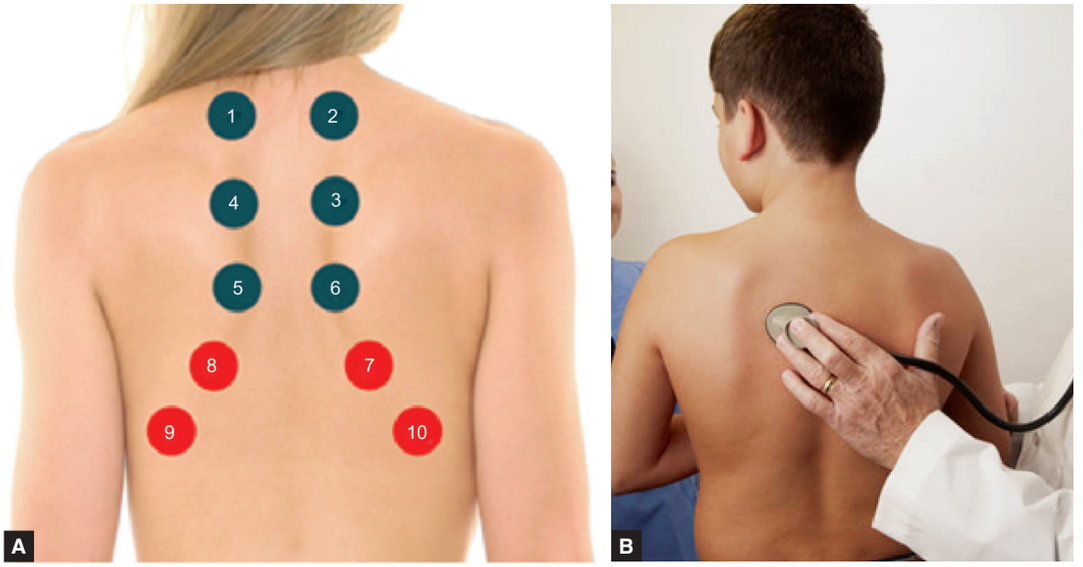

Fig. 1.89: Auscultation of the lung bases—zones 7–10 shown (A) should be performed in a thorough cardiovascular examination (B)

First Heart Sound (S1)

Normal

The sudden tensing of the mitral and tricuspid valves at the onset of ventricular systole produces the first heart sound. With the onset of ventricular systole, the left ventricular pressure rapidly exceeds the left atrial pressure. The mitral valve cusps are therefore thrust into the left atrium until suddenly held in apposition by the papillary muscles and chordae tendineae. The tricuspid valve is also closed by the rising pressure in the right ventricle within 20 msec of mitral valve closure and the sounds produced

Table 1.3: Heart sounds and their causes

Heart sounds	Causes
S_1: This results from contraction of the ventricles and closure of AV valves and opening of the semilunar valves	
	1. The heart beats force fully in exerciseor excitement, fever or anemia 2. Mitral stenosis when it is 'booming'
Decreased in intensity	1. Pericardial effusion 2. Constrictive pericarditis 3. When P-R interval is prolonged in acute rheumatic fever 4. Myocarditis.
Varying in intensity	Congenital heart block
Splitting of first heart sound	1. Normal in healthy children 2. Bundle branch block
S_2: This results from the closure of the semilunar valves	
Wide splitting of second heart sound	1. In children mild degree of splitting of S2 is normal 2. Right bundle branch block (splitting increased with inspiration) 3. Any condition where there is increased flow of blood to the right ventricle (ASD, VSD, anomalous venous drainage) in ASD both the factors are operative so that there is a wide splitting of S2
Single P_2	1. Tetralogy of Fallot 2. Severe type of pulmonary stenosis/pulmonary atresia
S_3: This results from the vibrations of the heart during rapid filling of the ventricles	
	It is heard at the apex and latter in the cardiac cycle in about 20% of the normal children and about 30% among children with rheumatic carditis
S_4: This results from the high atrial pressurewave which is reflected back from the ventricles	
	1. Left ventricle stress 2. Systemic hypertension, ischemic heart disease and aortic stenosis

Table 1.4: Reversed splitting of S2

Delayed A2

- Delayed electric activation of the left ventricle
- Complete left bundle branch block
- RV paced beats
- RV ectopic beats

Prolonged LV mechanical systole

- Compete left bundle branch block
- LV outflow tract obstruction
- Hypertensive cardiovascular disease
- Arteriosclerotic heart disease
- Chronic ischemic heart disease
- Angina pectoris

Decreased impedance of the systemic vascular bed (increasead hangout)

- Poststenotic dilation of the aorta as a result of aortic stenosis or regurgitatation
- Patent ductus arteriosus

Early P2

- Early electric—activation of the right ventricle
- Wolf-Parkinson-White's syndrome type B

by these two valves are heard as a single sound, i.e. the first heart sound (S1).

Loud S1

Mechanism

At the commencement of ventricular systole the valves are already almost in apposition as blood flowing into the ventricles has practically ceased. If the cusps still wide apart at the onset of ventricular systole with slack chordae, an abnormally loud first sound is produced when they are abruptly tensed.

Causes

Mitral stenosis, tricuspid stenosis; high cardiac output states (the flow of blood through the valve in late diastole remains high, keeping the cusps wide open); short PR interval (atrial contraction maintains a high flow of blood through the valve in late diastole, keeping the mitral and tricuspid valves wide apart).

Soft S1

Mechanism

If the valve cusps are rigid and incapable of much movement, or if the cusps are already close together before the onset of ventricular systole, the first heart sound is soft.

Causes

- Calcification or fibrosis of the mitral valve cusps in some of the patients with mitral stenosis limit valve movement. The valve cusps are nearly closed before the onset of ventricular systole when the PR interval is long, i.e. in first degree heart block.
- The varying PR interval of complete heart block has the effect of modifying the intensity of the first heart sound from loud, when the interval is short, to soft when the PR interval is long.

Splitting of S1

Normally the tricuspid valve closes within 0.02 sec of the mitral valve and only one sound is heard. Asynchronous contraction of the ventricles in bundle branch block particularly right bundle branch block, may produce appreciable splitting of the first heart sound.

Ejection Clicks

An ejection click is a short, high frequency clicking occurring shortly after the first heart sound and it arises from abnormal semilunar valves or from dilated great vessels.

Mechanism

- When the ventricular pressures exceed the aortic and pulmonary artery pressures in early systole, the normal aortic and pulmonary valve cusps open widely against the vessel wall so that there is no obstruction to flow. Fusion of the cusps of these valves prevents their full opening and the abrupt arrest of the valve dome in a semi-open position produces a high pitched sound soon after the first heart sound.
- Ejection clicks can also arise from the ejection of blood into a dilated aortic root or into a dilated pulmonary artery.

Types of Ejection Clicks

Aortic ejection click, arising from an abnormal aortic valve or from a dilated aorta. This click is loudest at the apex and at the lower left sternal edge.

Pulmonary ejection click, arising from an abnormal pulmonary valve or from a dilated pulmonary artery. A pulmonary ejection click is loudest at the pulmonary area and often heard only during expiration.

Causes

- Aortic click
- Aortic valve stenosis
- Bicuspid aortic valve (a bicuspid valve cannot open completely)
- Dilated ascending aorta, e.g. systemic hypertension
- Pulmonary click
- Pulmonary valve stenosis
- Pulmonary hypertension (dilated main pulmonary artery)

Second Heart Sound (S2)

Normal

The vibrations produced by closure of the aortic and pulmonary valves give rise to the second heart sound. The

aortic valve closes at the end of left ventricular systole when the left ventricular pressure falls below the aortic pressure and the pulmonary valve closes at the end of right ventricular systole.

In expiration, both valves close almost simultaneously and the sound is single. During inspiration the systemic venous return to the right ventricle is increased, and right ventricular systole is prolonged. Accordingly pulmonary valve closure is delayed and the second heart sound becomes split during inspiration into an aortic component (A2) and a pulmonary component (P2) which A2 by 0.04 seconds or more.

Normal splitting of the second heart sound on inspiration is usual at all ages, but is most frequent in the younger subjects. It is best heard in the pulmonary area.

Loud S2, when the sound splits on inspiration. It is possible to determine which of the valve closures sounds is loud. A2 is loud in systemic hypertension (more forceful closures of the aortic valve). P2 is loud in pulmonary hypertension. P2 is soft and not heard at the cardiac apex unless there is pulmonary hypertension.

Splitting of S2

A constant gap between A2 and P2 throughout all phases of respiration is the characteristic feature of an ASD.

When the defect is large the right and left atria act as one common chamber and the increased return of blood to the right atrium during inspiration increased blood flow equally to both right and left ventricles. It therefore, results into the prolongation of both right and left ventricular systole and the gap between A2 and P2 does not alter.

Reversed Splitting S2

Description

In reversed splitting, second heart sound is single on inspiration and clearly split into two components during expiration.

Mechanism

Reversed splitting implies that the aortic valve closes after the pulmonary valve. This occurs when left ventricular systole is prolonged or when the left ventricle contracts after the right ventricle.

Causes

Myocardial ischaemia or infarction, aortic stenosis, coarctation of the aorta (increased resistance to ejection) and large persistent ductus arteriosus (increase in left ventricular volume load). Left bundle branch block (delay in a activation of the left ventricle).

Wide Splitting of S2

This is heard when pulmonary valve closure is delayed either because of prolonged right ventricular systole (pulmonary stenosis) or delay in onset of right ventricular systole (right bundle branch block).

Opening Snap

Opening snap (OS) is a short, high-pitched, clicking sound closely following the second heart sound (0.06–0.12 seconds), heard loudest medial to the apex or at the lower left sternal border.

Mechanism

The sound is heard in mitral stenosis provided the fused valve cusps retain pliability. When the left ventricular pressure falls below the left atrial pressure, the mobile valve is pushed downward into the left ventricular cavity until it suddenly tightens in its most fully open position with a high pitched snapping sound.

Causes

Mitral stenosis: The opening snap is absent if the valve pliability is reduced by calcification or fibrosis.

Tricuspid stenosis: A tricuspid opening snap is only occasionally present and is difficult clinically to differentiate it from a mitral snap. A low frequency, soft thud, late after the second sound and heard at the apex (left ventricular third sound) or at the tricuspid area (right ventricular third sound).

Third Heart Sound (LVS3)

Mechanism

During the rapid inflow phase of early diastole, the left ventricle elongates. The apex moving downward and the mitral valve ring upward. This phase of rapid ventricular filling ends when the mitral valve cusps are suddenly drawn taut, stretched between the apex and the mitral valve ring, by the papillary muscles and chordae tendinae. The vibrations produced may be audible as third heart sound which occurs about 0.16 seconds after A2 at the end of the rapid ventricular filling phase. Similarly, rapid filling of the right ventricle may produce a third heart sound from tautening of the tricuspid valve.

Causes

Physiological third heart sound heard at the apex in most children and in few young adults.The early filling phase of the ventricle is more rapid due to altered myocardial tone and the raised filling pressure.

Abnormally, large flow in the filling phase (mitral incompetence, aortic incompetence, ventricular septal defect, persistent ductus arteriosus) result into left ventricular third heart sound.

Causes of Right Ventricular Third Sound (RVS3)

1. Right ventricular failure
2. Constrictive pericarditis

This sound has a different mechanism and is of higher pitch and earlier than the usual third sound (0.1 second after A2). Sudden restriction of filling of the ventricle by the rigid pericardium plays some part in this.

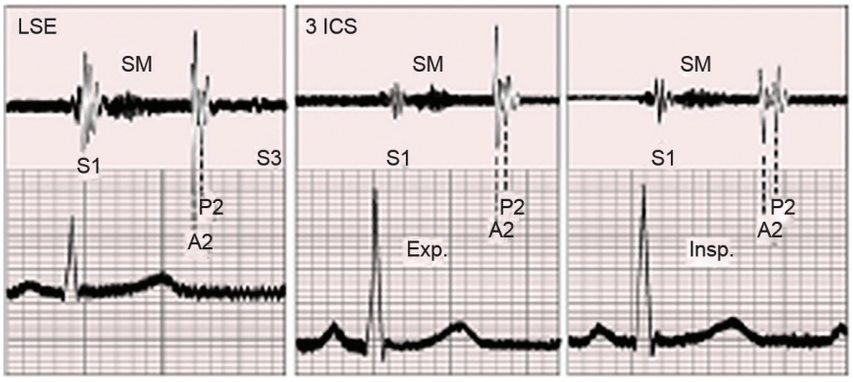

Fig. 1.90: A vibratory midsystolic murmur (SM) from a healthy 7-year-old boy. The murmur is maximal along the lower left sternal edge (LSE) and is accompanied by a physiologic third heart sound (S3) and normal respiratory splitting of the second heart sound. (A2/P2=aortic and pulmonary components; 3 ICS=third intercostal space)

Fourth Heart Sound (Atrial Sound) (S4)

A low frequency, soft sound preceding the first heart sound.

Mechanism

This sound is heard when the left or right atrium contracts more forcefully than normal. A high atrial pressure wave reflected back from the ventricle tenses the mitral or tricuspid valve to produce the fourth heart sound. The sound is presystolic in timing, coincides with atrial systole and is heard when a ventricle is under stress.

Causes of a Left Ventricular Fourth Sound

Left ventricular stress, systemic hypertension, ischaemic heart disease and aortic stenosis.

Causes of a Right Ventricular Fourth Sound

1. Right ventricular stress
2. Pulmonary hypertension
3. Embolism
4. Pulmonary stenosis

GALLOP RHYTHM

The presence of a third or fourth heart sound (or both) in addition to the usual first and second sounds is referred to as a gallop rhythm. By convention the term is used to imply a pathological condition. However, physiological third sound of the young is not called a gallop.

Summation Gallop

At faster heart rate, an inaudible fourth sound may be superimposed on a normally inaudible third sound, the combined effect being the production of a gallop rhythm. The summation gallop disappears with slowing of the heart and does not necessarily mean ventricular stress

CARDIAC MURMURS

Cardiac murmurs are depicted in Figs 1.90–1.98 and briefly described in Tables 1.5 and 1.6.

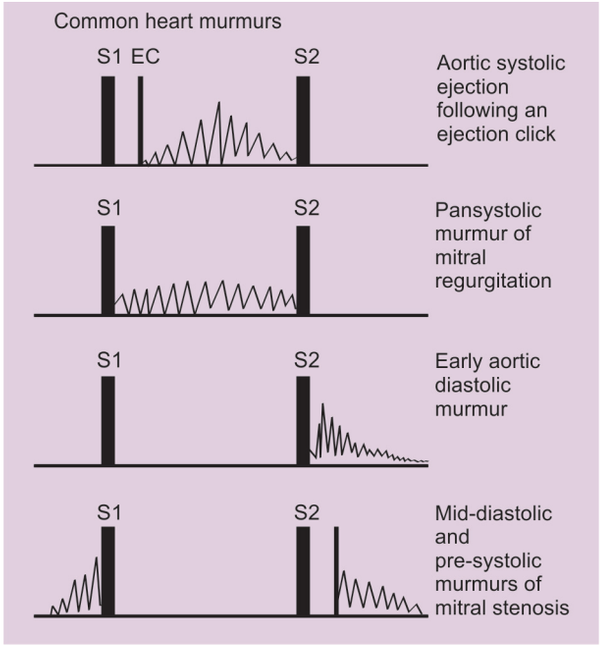

Fig. 1.91: Graphic representation of common heart murmurs in clinical practice

How to diagnose innocent versus/pathological murmurs?

How should a clinician distinguish between innocent murmurs and pathological murmurs, and what factors should be evaluated? If the primary care physician is unsure whether the murmur is innocent, then referral to a pediatric cardiologist is the next step. Murmurs are common findings in infants and children. Most murmurs in infants and children originate through normal flow patterns with no structural or anatomic abnormalities of the heart or vessels and are referred to as 'innocent', 'physiological', or 'normal' murmurs. 'Innocent' is the preferred term because it strongly conveys that nothing is abnormal, as opposed to the older term 'functional', which is not always understood clearly by parents and patients as being 'normal'. Although

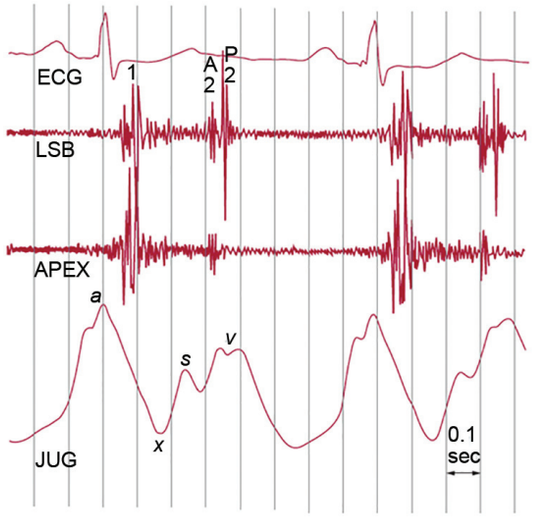

Fig. 1.92: Jugular venous pulse tracing from a patient with mitral stenosis and tricuspid regurgitation secondary to pulmonary hypertension. Note the shallow x descent, the midsystolic s wave, and the respiratory increase in the v wave (reproduced, with permission, from Tavel ME. Clinical Phonocardiography and External Pulse Recording. Year book Medical Publishers, 1978)

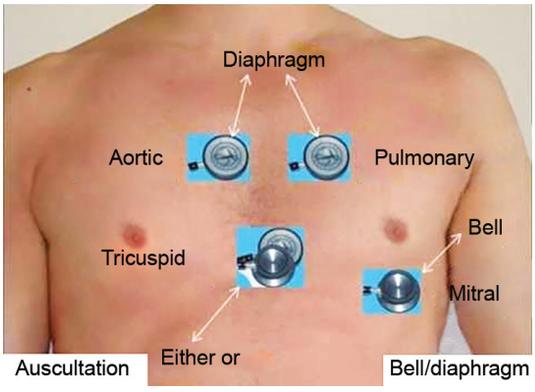

Fig. 1.93: Selective approach of application of bell/diaphragm of the Littmann stethoscope in listening of heart sounds and murmurs over the chest

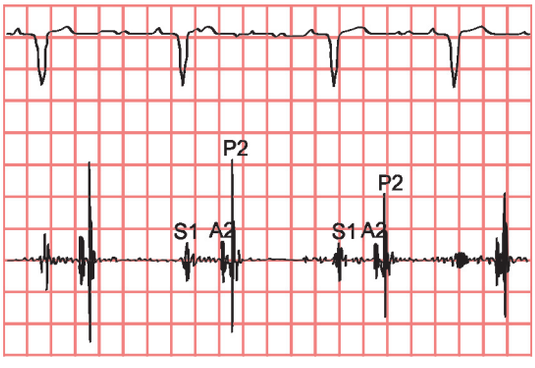

Fig. 1.94: Split second heart sound in a patient with severe pulmonary hypertension associated with a reversed patent ductus arteriosus. S1, first heart sound; A2, aortic component of second heart sound; P2, pulmonic component of second heart sound

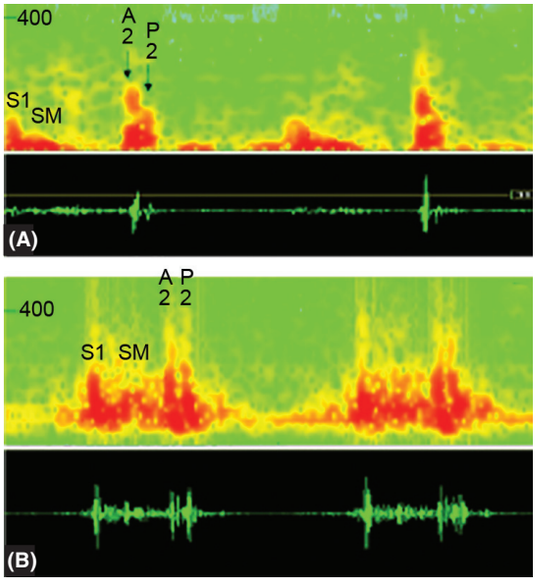

Fig. 1.95A: Examples of second heart sound characteristics, normal and abnormal. (A) Normal second sound, demonstrating both aortic (A2) and pulmonic (P2) components. Peak frequencies of the aortic component exceed those of the pulmonic. (B) Spectral display from a patient with an atrial septal defect. In this example, the second sound is widely split, with the peak frequency of the pulmonic component equaling or exceeding that of the aortic component. A systolic ejection murmur (SM) is also displayed in this instance, which contains relatively low peak frequencies in the range of 250 Hz. S1 indicates first heart sound

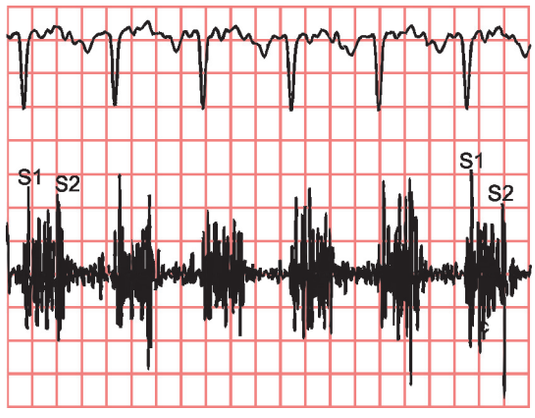

Fig. 1.95B: Phonocardiographic tracing of the plateau-shaped systolic murmur of mitral regurgitation. S1=first heart sound; S2=second heart sound; M=systolic murmur

murmurs may be heard in virtually anyone, they are most commonly heard in children. Virtually all children will have a murmur sometime while they are growing up. Conversely, murmurs may be created by abnormal flow patterns in the heart and vessels resulting from congenital heart abnormalities, valve disease, or other acquired conditions. In evaluating the infant or child with a murmur, the clinician must make a complete assessment of the cardiovascular system—not just listen to the murmurs because there are some serious cardiovascular abnor-

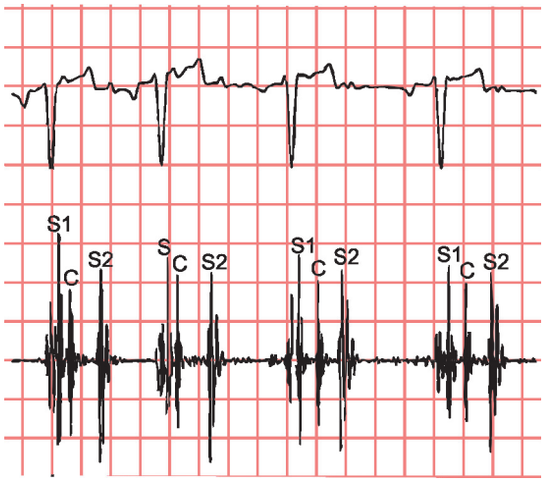

Fig. 1.96: Phonocardiogram showing high-frequency systolic clicks occurring at various points within systole. Midsystolic clicks are caused by valvular prolapse in patients with degenerative valve disease. S1, first heart sound; S2, second heart sound; C, systolic click

malities, that may have no murmurs. Looking for clues of heart disease, the clinician must obtain a focused history from the patient's parents. For infants, this history will include birth history, feeding patterns, breathing difficulties, color changes, growth pattern and activity levels. Changes in feeding patterns, particularly a progressively longer time to complete the feeding, may be an early sign of congestive heart failure. For children,

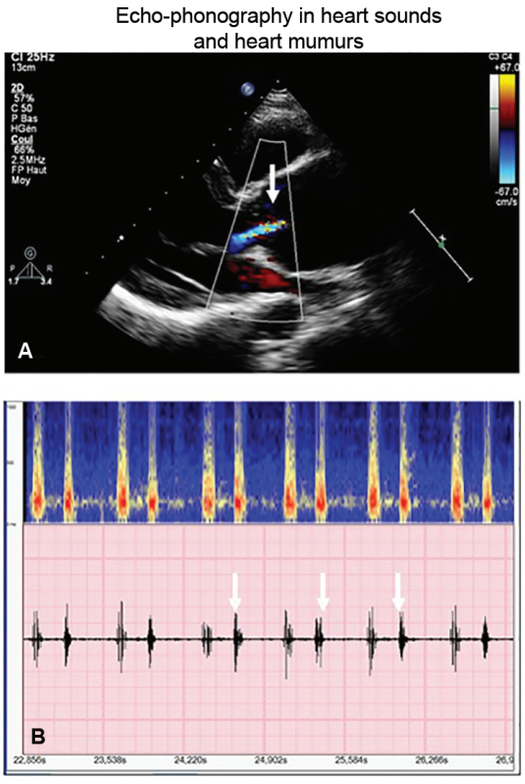

Fig. 1.98: Aortic insufficiency (indicated by white arrows) not heard with the acoustic stethoscope, but visualized using our intelligent stethoscope prototype and confirmed by echocardiography

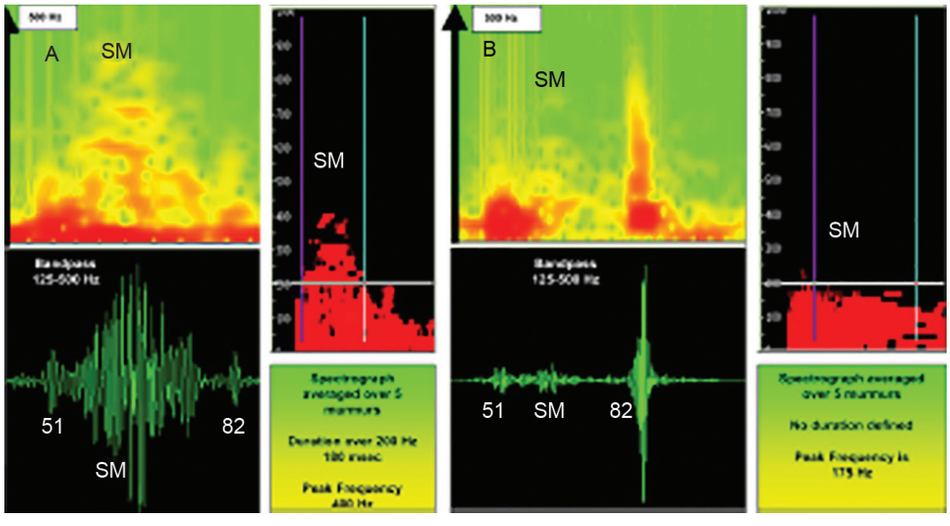

Fig. 1.97: (A) An example of a spectral display (upper left panel) recorded simultaneously with a waveform display (below) in a patient with severe aortic stenosis. The waveform image was obtained with a band-pass filter (125–500 Hz). A systolic murmur is noted that has a crescendo-decrescendo contour in the waveform display, whereas it also shows a crescendo-decrescendo frequency pattern in the spectral image. This latter image presents a colored plot, in which the relative signal intensities correlate with the colors, i.e. greater intensity is shown in orange and lesser intensity in yellow. Absence of sound is shown in green. The panel at the right shows a spectral average of murmurs derived from multiple cycles in this case. It is color coded to demonstrate only more intense frequencies uniformly in red, i.e. after a given 'cutoff' attenuation (–25 dB in this example), the red changes abruptly to black. Displayed in this way, this latter image shows a relatively high-peak frequency of 400 Hz (vertical scale at the left). This display also allows for measurement of the time duration for the murmur to exceed any arbitrary frequency level, in this case 200 Hz. (B) An example demonstrating a similar display for an individual with an innocent murmur, which appears primarily in early systole and does not reach a peak frequency of 200 Hz. SM indicates systolic murmur

Table 1.5: Heart murmurs in congenital heart diseases

Description of murmurs	Disease
Continuous murmur with thrill	1. PDA 2. Tetralogy of Fallot 3. Venous hum 4. Pulmonary arteriovenous fistula
Pansystolic murmur	***Ventricular septal defect*** Plateua throughout systole, loud, harsh in the third and fourth left intercostal space close the left lower sternal border. P2 heard in pulmonary area with normal split—if not obscured by the murmur. Systolic thrill in most cases (80%).
Mid or late systolic murmur with thrill	***Pulmonary stenosis*** Murmur in second left intercostal space. Thrill may be present. P2 single or may be split in moderate stenosis. In severe cases, P2 may not be heard.
Ejection systolic murmur (moderate or harsh)	***Fallot's tetralogy*** Systolic murmur in the third or fourth left intercostal space in 25% of cases the murmur is in the second left intercostal space due to valvular stenosis shorter than the murmur of the pulmonary stenosis. Murmur fainter or abscent when the pulmonary valve is much narrowed. The murmur is lower down in the cases of infundibular stenosis. The murmur is abscent in pulmonary atresia, P2 is single and loud in 20% of cases. Thrill is not common in infancy.
Systolic murmur of loud intensity, wide splitting of P2	***Atrial septal defect*** Moderate or Faint systolic murmur in second left intercostal space with widely P2. Apical diastolic murmur is an indication of rapid inflow at the begining of diastole, occurs in larger defects of ASD and VSD. Associated systolic thrill indicates pulmonary stenosis.
Loud, harsh systolic murmur with a thrill in the first and second right interspace	***Congenital aortic stenosis*** Loud, harsh, systolic murmur in aortic area ending before second sound; systolic thrill present over the aortic area and transmitted to the neck over the carotids.

Table 1.6: Heart murmurs (acquired heart disease)

Description of murmur	Disease
Mitral systotic	1. In mitral insufficiency (apex, blowing-conduction to axilla or inferior angle of scapula) 2. In any myocarditis 3. In endocardial fibrucelastosis
Mitral presystolic	Mitral stenosis, presystolic and crescendo leading to an accentuated first sound
Mitral mid-diastolic	In rheumatic heart disease of some standing but not yet full blown picture of mitral stenosis; first sound accentuated.
Mitral early diastolic	Short, faint, with a third sound occurs in 30% of acute rheumatic fever and disappears during convalescence.
Aortic diastolic	Occurs in 10% of children with acute rheumatic fever, collapsing pulse, etc. only later on. Decrescendo, often faint and best heard down the left sternal border with breath held at the end of expiration.
Pulmonary diastolic	Same features as aortic diastolic, best heard in congenital hearts and severe anemia. Also right ventricle hypertrophy and prominent pulmonary artery with pulsating hilar shadows.

parents should be asked about activity capacity. Can the child keep up with peers while playing vigorously? Have there been complaints of shortness of breath, palpitations, or chest pain? Chest pain is a common complaint, but a cardiac cause is found in less than 1% of children complaining of chest pain.

Blood flow through the cardiac chambers is normally systematically streamlined. Murmurs are produced when there is turbulence of the blood flow. The origin of murmurs is determined by the application of the following parameters.

1. Timing in the cardiac cycle

2. Site of maximal intensity and conduction
3. Loudness and quality
4. Influence of respiration
5. Timing in cardiac cycle

Auscultation begins with listening for the normal sounds of the valves closing and for S1 and S2. It is important not to focus on murmurs initially. Atrial septal defect accounts for about one-third of the congenital defects first detected in adulthood. This is because the characteristic murmur, a pulmonary flow murmur, also is one of the most common childhood innocent murmurs. The key to diagnosis is appreciating the wide fixedly split-second heart sound resulting from right volume overload. This will not be easily appreciated if the clinician focuses on murmurs before defining the heart sounds. Gallop sounds also may be present, signaling difficulty in keeping up with the demands placed on the heart. Conversely, isolated S3 gallop sounds may be heard in healthy adolescents.

Site of Maximal Intensity and Conduction of the Murmur

This is helpful in identifying the origin of murmurs but is unreliable if used in isolation from the other features, e.g. aortic systolic murmurs are often loudest at the apex and aortic diastolic murmurs are loudest at the fourth left interspace close to the sternum.

Loudness and Quality

The loudness of a murmur correlates poorly with the severity of the lesion producing it. A very loud murmur may be produced by turbulent blood flow through a small ventricular septal defect whereas the murmur is softer with larger defects. Similarly the loudness of a mitral pansystolic murmur is a poor guide to the severity of the regurgitation.

The Quality or Pitch of a Murmur Aids in its Identification

High pitched murmurs indicate a stream of blood under high pressure (aortic incompetence, mitral incompetence). Low-pitched murmurs are indicative of a turbulent blood flow under low pressure (mitral stenosis, diastolic flow murmurs).

Influence of Respiration

With inspiration, the negative pressure in the thorax, sucks more blood into the right atrium from the superior and inferior venae cavae. The blood flowing across the tricuspid and pulmonary valves is, therefore, increased during inspiration and increases the intensity of pulmonary and tricuspid murmurs, making this a useful clinical sign. Inspiration also brings the lung over the heart, which tends to make all sounds less well heard on the chest wall and this at times leads to confusion.

In general, right sided events are louder or unchanged on inspiration and left-sided events are louder on expiration.

Classic Types of Innocent or Flow Murmurs

Presence or absence: Innocent murmurs are murmurs produced by normal flow. Changing the flow should therefore change the intensity of the murmur. Characteristically, maneuvers that decrease the flow of blood returning to the heart through the venous system will decrease the intensity of flow murmurs, suggesting that the murmur is flow related or innocent. Changing the child's position from supine to sitting, then to standing, and finally to squatting during the examination will change the flow and is useful in helping to define innocent murmurs. The child may be asked to push out the abdomen or bear down to perform a Valsalva maneuver, which reduces venous blood flow to the heart and the intensity of innocent murmurs. An examiner can coax even a young toddler into doing this by placing a hand on the child's abdomen and asking the child to push it out.

Still's Murmurs

These murmurs are low-pitched sounds heard at the lower left sternal area. They are musical or have a relatively pure tone in quality or may be squeaky. These most commonly occur between age of 3 and adolescence.

Because of low-pitched, they are heard best with the bell of the stethoscope. They are related to flow, and they can change with position alteration and then can decrease or disappear with the Valsalva maneuver. No clicks are present. Pulmonary flow murmurs. These are high-pitched, harsher murmurs heard at the upper left sternal border. Because they are high pitched, they are heard best with the diaphragm of the stethoscope. They are flow-dependent and also will change with position alteration and decrease or disappear with the Valsalva maneuver. These murmurs originate from the right ventricular outflow tract and radiate along the pulmonary arteries and, thus may be well heard in the back and axilla bilaterally. They are differentiated from pulmonic stenosis by their quality and from valvar pulmonic stenosis by the absence of an ejection click. Pulmonary flow murmurs can occur at any age, but they are common particularly in adolescents or in children with pectus excavatum. They are prominent in high-flow situations, such as when a child has a fever or is anemic, because flow increases in these situations. In infants, these sounds may be most prominent in the back or axilla because turbulence occurs when the blood flows from the larger main pulmonary artery to the smaller, less well-developed distal pulmonary arteries. In fetal life, the main pulmonary artery transports about 90% of the blood to the ductus arteriosus and only about 10% to the distal pulmonary arteries. The main pulmonary artery is thus large, whereas the distal pulmonary arteries are relatively smaller and come off at more acute angles than they do later as the child's chest grows. An analogy from nature would be the noise, that is created as a large stream narrows into smaller streams. This innocent murmur has been termed 'benign peripheral pulmonary stenosis of the newborn' to differentiate it from true anatomic obstructions to distal pulmonary arteries that occur in pathological conditions such as congenital rubella syndrome.

Systolic murmurs occur during ventricular systole. Diastolic murmurs occur in ventricular diastole. Continuous

murmurs are heard throughout the cardiac cycle. Systolic Murmurs (Pansystolic, Ejection and Late systotic).

Grading and Types of Murmurs

Murmurs are graded on a four point or, more commonly, a six-point scale. A common six-point scale is:

- Grade 1—audible with difficulty
- Grade 2—faint but recognizable
- Grade 3—moderate intensity
- Grade 4—loud
- Grade 5—louder, but still needing a stethoscope
- Grade 6—audible without a stethoscope

Pansystolic Murmur

The pansystolic murmur beings with the first heart sound and remains of uniform intensity throughout systole up to the second heart sound A pansystolic murmur is caused by a 'leaking ventricle' (mitral incompetence tricuspid incompetence, ventricular septal defect). Blood escapes from the ventricle as soon as it begins to contract (first sound) and continues to escape until the pressures equalise between the ventricle and atrium (just after second sound). Left ventricular pressure exceeds left atrial pressure throughout systole from the first heart sound untill after A2 and blood escapes through the mitral valve into the left atrium giving rise to a murmur throughout systole).

A pansystolic murmur is heard in the following conditions:

Mitral incompetence: The murmur is maximal at the apex, loudest on expiration and conducted into the axila.

Tricuspid incompetence: The murmur is maximal at the lower left sternal edge and becomes louder during inspiration.

Ventricular septal defect: The murmur is classically loud and rasping in quality, maximal at the lower left sternal edge and loudest on expiration.

Ejection Murmur

There is a short gap between the first heart sound and the beginning of the murmur.

The murmur begins slowly, reaches highest intensity in midsystole and ends before the second heart sound. An ejection systolic murmur arises at the aortic or pulmonary valves when the blood flow through them is turbulent. This may be caused by narrowing of the valve orifice (aortic stenosis and pulmonary stenosis) or by a greatly increased flow through an orifice of normal size (high cardiac output states and left to right shunts). The murmur begins when the aortic or pulmonary valve opens, reaches its maximum with top most flow in midsystole and becomes soft again towards the end of systole. An ejection murmur must cease when flow across the valve ceases, that is, before the end of second sound which indicates closure of that valve.

Late Systolic Murmur

This murmur likely to start well after the first heart sound and thereafter increases in intensity up to the second sound. It is characteristic of mild mitral regurgitation, when the greatest regurgitant flow occurs in late systole as seen in mitral valve prolapse.

Diastolic Murmurs

Early diastolic (regurgitant): The murmur begins immediately after the second sound and is loudest at its onset, but may extend throughout diastole. High frequency and blowing in quality, the murmur is maximal usually in the third and fourth intercostal spaces close to the sternum, and may also be heard in the aortic area and at apex.

A leaking aortic or pulmonary valve allows blood to flow back into the ventricle as soon as the valve closes (second sound), and is loudest at the beginning when the aortic or pulmonary artery pressure is highest, becoming softer as the pressure falls in diastole.

An early diastolic murmur is heard in either aortic valve regurgitation or pulmonary valve regurgitation, usually as a result of pulmonary hypertension.

The murmurs of aortic and pulmonary regurgitation are so similar that differentiation is made on other evidence, such as a water hammer pulse favouring aortic in-competence, and evidence of pulmonary hypertension suggesting pulmonary incompetence.

Mid-diastolic Murmur

The diastolic murmur begins some time after the second heart sound (Fig. 1.98). Delayed diastolic murmur is a more accurate description than mid-diastolic since the murmur may be short or may extend throughout the remainder of diastole. It is characteristically low-pitched rumbling in character.

The murmur from a stenosed mitral or tricuspid valve begins with the resumption of flow through valve at the end of isometric relaxation of the ventricle. The opening snap indicates the end of isometric relaxation and is followed by the murmur, loudest at its onset when the atrial pressure is greatest, becoming softer as the pressure gradient between atrium and ventricle falls during diastole. The length of the murmur is determined by the time taken for the left atrial pressure to equalize with left ventricular pressure. When stenosis is severe the left atrial pressure does not fall to the left ventricular diastolic level in the time available and the diastolic murmur persists up to the first heart sound.

Causes of a Mid-diastolic and Flow Murmurs

Mitral stenosis: Murmur is maximal at the apex.

Tricuspid stenosis: Murmur maximal at the lower left sternal edge and becoming louder during inspiration. Increased blood flow across normal mitral and tricuspid valve (flow murmurs). Flow murmurs are low pitched, usually short and occur at the time when blood flow through the valve is rapid, that is, around mid-diastole. Mitral flow murmurs

are present when there is an increased flow across that valve due to a left to right intracardiac shunt (ventricular septal defect and persistent ductus arteriosus) or due to a generalised high cardiac output states (thyrotoxicosis, anemia and systemic arteriovenous fistula). Tricuspid flow murmurs are usually the result of an increased flow over the tricuspid valve resulting from an atrial septal defect.

Presystolic Murmur

This murmur begins in late diastole and is at its loudest just before the first heart sound.

The presystolic murmur is the result of atrial systole due to flow of blood through a narrowed mitral or tricuspid valve. Atrial systole causes an increase in blood flow across the valve just before the first heart sound, provided the PR interval is normal. There is no presystolic murmur if atrial contraction is absent as in atrial fibrillation.

Causes

Mitral stenosis: Murmur maximal at the apex.

Tricuspid stenosis: Murmur maximal at the lower left sternal edge and louder during inspiration.

Austin Flint Murmur

A presystolic murmur or a low rumbling diastolic murmur maximal at the apex and indistinguishable from the murmur of mitral stenosis.

This murmur is heard when there is free regurgitation at the aortic valve. The regurgitant stream impinges on the anterior cusp of the mitral valve and tends to hold it closed. Under these circumstances the diastolic murmur of mitral stenosis can be produced by a normal mitral valve.

Continuous Murmurs

A continuous murmur extends uninterrupted from systole into diastole and is often heard throughout all phases of the cardiac cycle. When a communication exists between two parts of the circulation, one of which is at a higher pressure than the other throughout the cardiac cycle, blood flows uninterruptedly which results into a continuous murmur.

Causes

1. *Escape of blood from aorta:* Persistent ductus arteriosus. Blood flow through the ductus is maximal towards the end of systole when aortic pressure is highest. The murmur is heard below the left clavicle and is loudest in late systole.
2. *Pulmonary atresia:* Blood flows from high pressure aortic bronchial arteries into the lungs. Again loudest in systole, often heard below the right left clavicles or in the interscapular region at the back.
3. *Ruptured aortic sinus of valsalva:* Coronary artenovenous fistula and any other large systemic arteriovenous fistula.
4. Blood flowing from a high to a low pressure region in the lungs.
   a. Pulmonary artery branch stenosis
   b. Pulmonary arteriovenous fistula.

SYSTEMIC FLOW MURMURS (SUPRACLAVICULAR SYSTEMIC BRUITS)

The systemic flow murmurs are harsh high-pitched murmurs caused by normal blood flow into the aorta and into the head and neck vessels and are heard best high up in the chest and above the clavicles (Figs 1.99–1.101). They are also heard best with the diaphragm of the stethoscope. No ejection click is associated with these murmurs. They are transmitted to the arch vessels and are heard when listening over the carotid arteries of the neck. It has been said that because of these sounds 'all children have carotid bruits'; however, the sounds differ in quality from true carotid bruits and are not associated with aortic outflow pathology.

VENOUS HUM

It is common in children; mimics a continuous murmur and is caused by blood flowing through the great veins in the neck and the innominate veins (Fig. 1.102).

It can be distinguished from the murmur of a persistent ductus arteriosus by the following features; variations in posture and placing the head in different positions markedly affect the venous hum. Light pressure on the neck reduces venous return from the jugular veins and may abolish the venous hum. These are low-pitched continuous murmurs made by blood returning from the great veins to the heart. They are heard best with the bell of the stethoscope. By changing the position of the patient's head or by pressing in the area of the major neck veins, the flow may be changed and these murmurs will change or



Fig. 1.99: Auscultation over the carotid artery

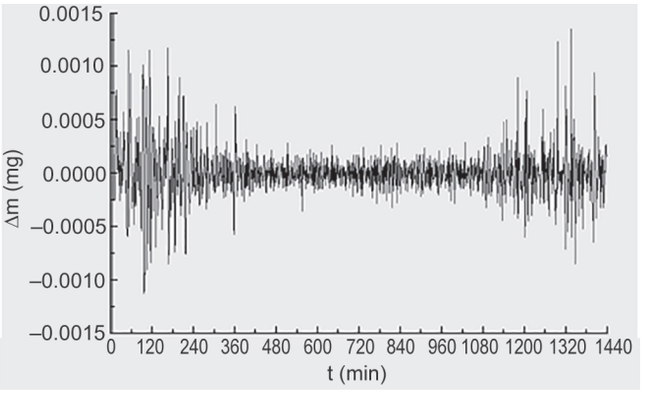

Fig. 1.100: A carotid bruit is an abnormal sound from the heart. The sound is in synchronization with the heartbeat. It is generally caused by turbulent blood flow, such as caused by irregularities in the wall of the blood vessel or by an abnormal connection (fistula) between an artery and vein. A bruit that is normally heard over the carotid artery is a sign that there are fats in the wall of the vessel. The bruit can be heard by using a stethoscope to listen to blood flow in the carotid artery. The carotid artery is the main artery in the neck region and is responsible for bringing blood to the head. A bruit indicates a fatty buildup (atherosclerosis) in the artery. Carotid bruit is a sign of the person's higher stroke risk

disappear. Having the child look down or to the side while listening will often make these murmurs or sounds disappear. They are differentiated from the murmurs of patent ductus arteriosus in that they are louder in diastole, when maximal flow occurs in the venous system, and are often heard bilaterally. Venous hums are sensitive to posture and head and neck position, whereas the murmur of patent ductus is not. Although an ECG is usually part of the evaluation and may be helpful, further testing is not needed in the overwhelming majority of infants and children to distinguish between normal or pathological hearts. It has been shown that a competent pediatric cardiologist can determine with a high degree of certainty, whether there is heart disease. Because of the characteristics of the sounds and the maneuvers that can be used to facilitate identifying them as flow-related phenomenon, these murmurs can be correctly identified without further testing. After concluding that the murmur or murmurs (a child may have more than one kind) are innocent, the practitioner should explain the findings to the parents and child. The practitioner should emphasize during the discussion that murmurs simply mean sounds or noises and that in and of themselves they are not synonymous with abnormalities of the heart. The clinician should stress

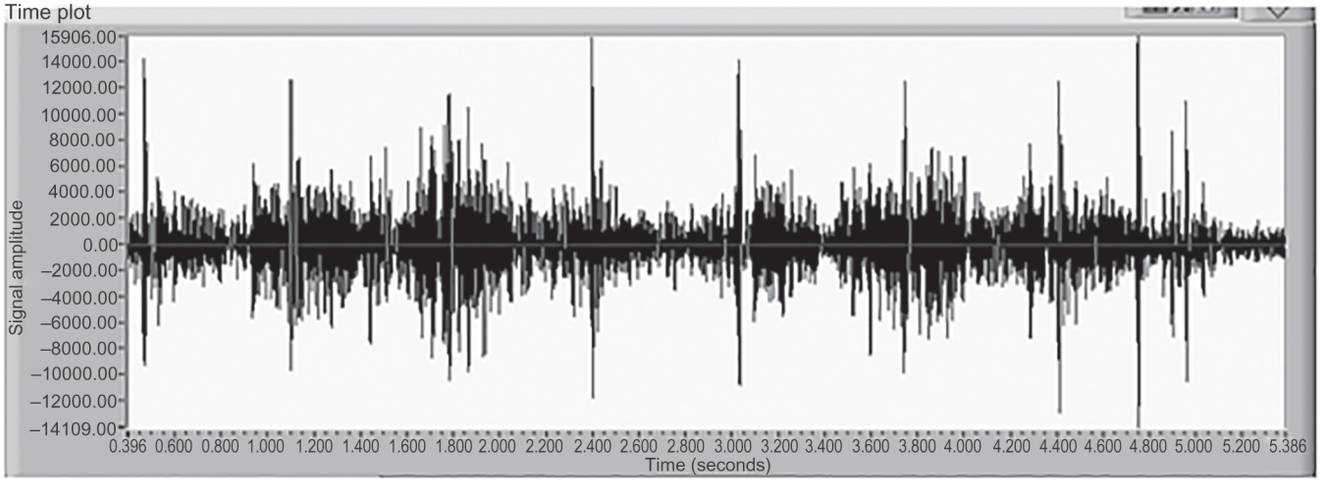

Fig. 1.101: Phonogram showing systo-diastolic murmur heard over the clavicle

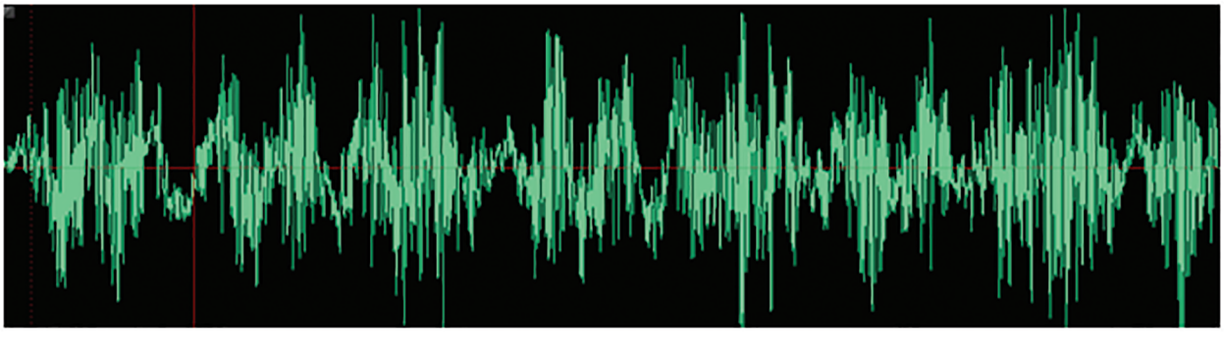

Fig. 1.102: Friction rub—murmur heard in a continuous fashion, regardless of cardiac cycle and may change in character in different patient positions (supine, on side, sitting, etc.)

that although a large percentage of infants and children have murmurs, less than 1% are born with the congenital heart defects that are the most common cause of heart disease in children. Parents should not be promised that their children will outgrow these murmurs because this is not necessarily true; adults can have innocent murmurs as well. Assurances should be given that because the heart is normal, whether or not the murmur disappears or changes is of no consequence. In addition, because flow changes the murmur, with growth and the changing configuration of chest and heart dynamics, murmurs may change, disappear, and reappear at various times-further evidence that the murmurs are indeed flow related and innocent.

PERICARDIAL FRICTION RUB

The pericardial friction rub is a superficial sound produced by the rubbing together of inflammed surfaces of the pericardium (Fig. 1.102). It may be heard anywhere over the precordium and usually has two components during each cardiac cycle. It is often soft, localised to one small area, and the rub can be abolished by a pericardial effusion separating the inflammed surfaces. The superficial quality and timing of the sound, which is confined neither to systole nor diastole, distinguishes it from a murmur. It is commonly found in pericarditis of different aetiology.

INVESTIGATIONS REQUIRED IN ESTABLISHING DIAGNOSIS

These investigations are depicted in Figs 1.103–1.114.

Routine Laboratory Tests

Estemation of Hb%, packed cell volume (PCV), HIV screening and blood group typying are most most essential part of a preoperative work up in both acquired and congenital heart ailments.

Chest X-ray

The interpretation of chest films requires lot of experience and proper technique. It is difficult to obtain a satisfactory film in the newborn and young in fants (Fig. 1.103).

Likewise, a film taken in expiration may produce a false picture of cardiac enlargement, or suggestive of congenital heart disease, because of the large thymic and cardiac silhouette. Dark films may create difficulties in detection of pulmonary vascularity. It is also worthwhile remembering that the cardiothoracic ratio is 55% in infants. After this age period a cardiothoracic ratio of 50% or less can be taken as normal. For a proper evaluation at least four views—posterior, anterior, lateral and oblique views may be necessary. In addition, these views of the chest may have to be supplemented with a barium swallow.

Electrocardiogram

The electrocardiogram is an important diagnostic aid in the evaluation of the cardiovascular system and is a must for the diagnosis of arrhythmias (Fig. 1.104).

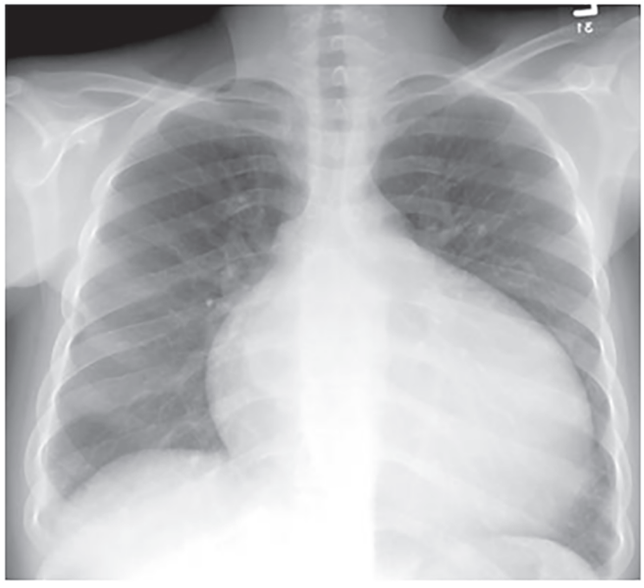

Fig. 1.103: X-ray chest (PA view). Showing cardiomegaly with enlargement of left ventricle with dilated main pulmonary artery along with congested lung fields in left to right shunt

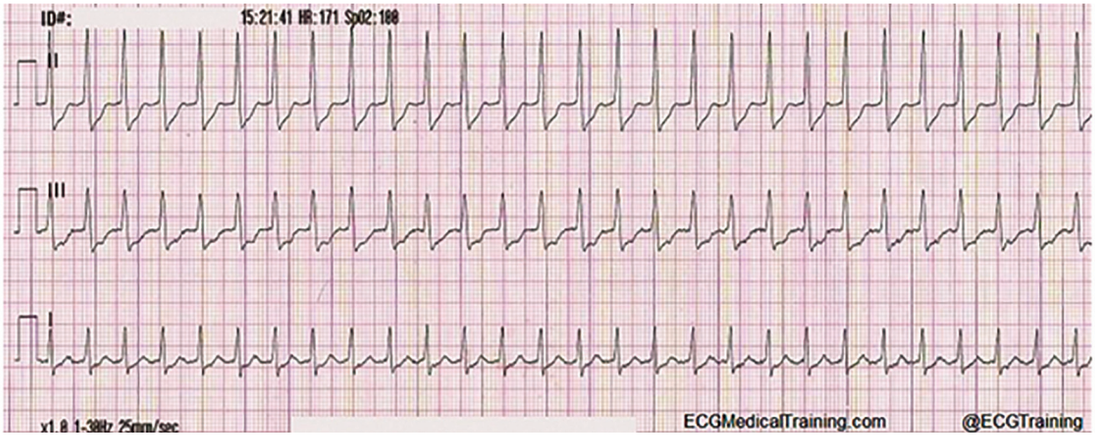

Fig. 1.104: ECG trace showing re-entrant SVT due to AVNRT

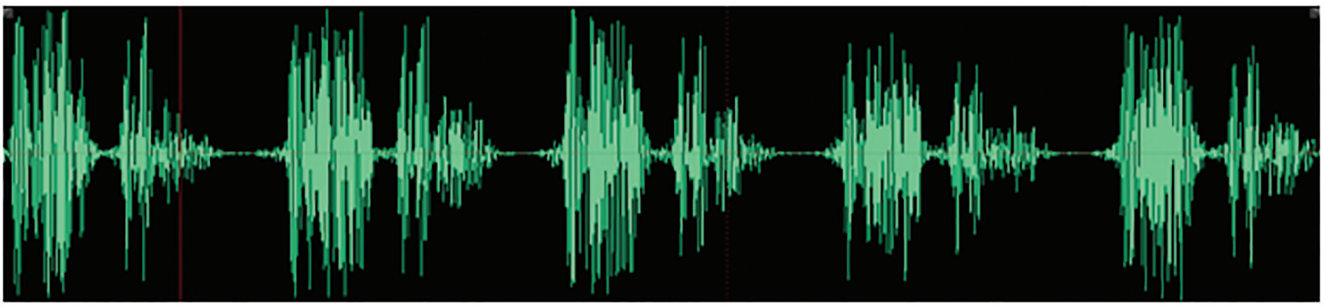

Fig. 1.105: Mid-systolic murmur—murmur heard in systole, in a crescendo-decrescendo fashion. The murmur is mid-systolic and NOT associated with a click. Ejection systolic murmurs indicate shunting of blood between two structures in which the pressure in one structure is higher than the other in mid-systole, e.g. Increase volume of blood flowing through normal valves ASD, this murmur is associated with a mid-diastolic murmur and fixed splitting of second heart sound. Anemia or small VSD, which is not open throughout systole due to constricting effecting of contracting myocardial fibers

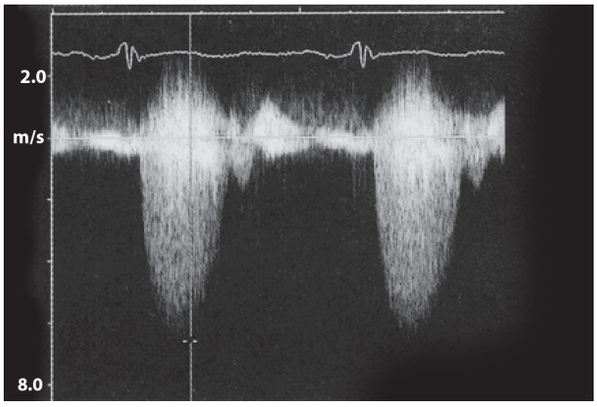

Fig. 1.106: Continuous-wave Doppler recording across a severely stenosed aortic valve showing an instantaneous pressure gradient by the application of Bernoulli equation

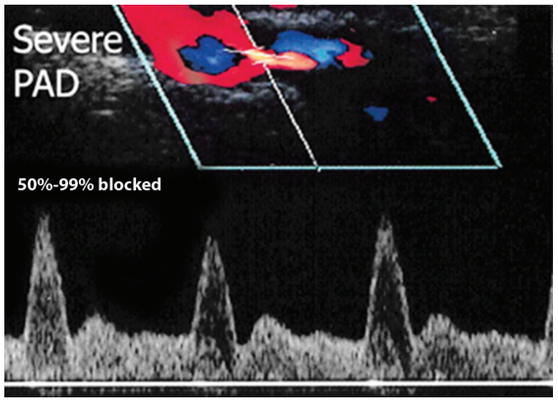

Fig. 1.107: A duplex ultrasound image of an artery that has been almost completely blocked by peripheral arterial disease (PAD). The blue areas indicate slow blood flow, and not much blood flow is visible beyond the blockage because PAD has nearly closed off the artery

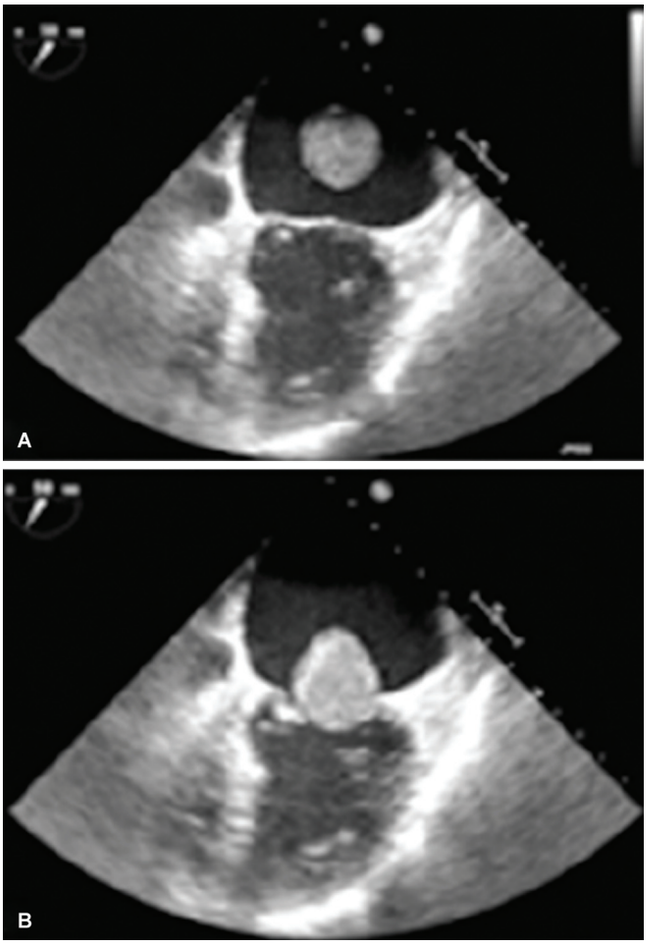

Fig. 1.108: Intraoperative transesophageal echocardiogram showing the free-floating myxoma in the left atrium (A) and the myxoma obstructing the mitral valve orifice at end-diastole (B)

Phonocardiogram is also a useful aid, as there is a close correlation between visual and acoustic events. The severity of lesion can also be assessed by this method besides obtaining graphic record of heart sounds and murmurs (Fig. 1.105).

Echocardiogmphy is being widely used at present and makes use of ultrasonic sounds for the detection of anatomic and physiologic abnormalities. Measurements the dimensions of the ventricles, the outflow tracts,

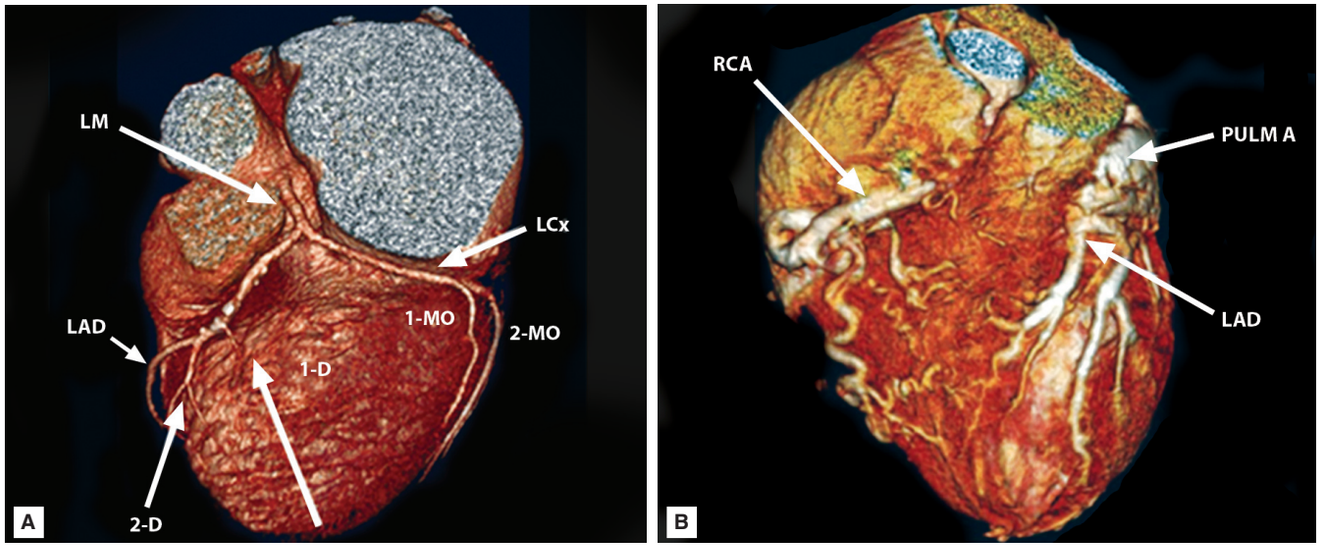

Fig. 1.109: (A) Volume-rendered CT image (right anterior oblique view with cranial angulation) shows the arteries: right coronary artery (RCA), marginal acute branch (MAb), left anterior descending (LAD) and second diagonal (2-D). (B) CT angiography volume rendered image. Right coronary artery is dilated and tortious with a large number of collaterals feeding the left coronary system. Left coronary artery is emerging from pulmonary artery trunk. The left anterior descending artery and their diagonal branches are also dilated and tortious

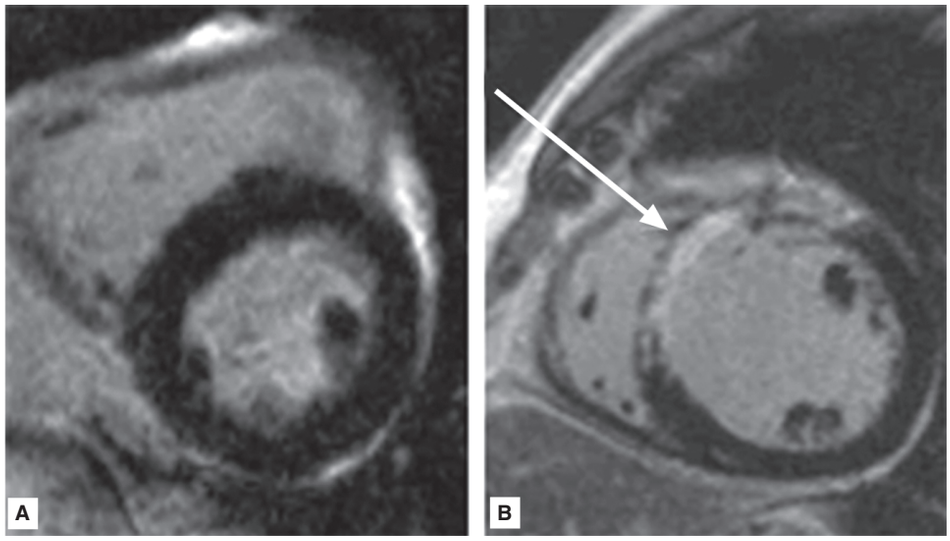

Fig. 1.110: Cardiac MRI—(A) normal heart muscle, (B) scarring after a heart attack

detection of pericardial effusion, congenital and acquired heart dysfunctions are now possible with this technique without risk or injury to the body tissues (Figs 1.106–1.108).

Computed Tomography and MRI

It is one of the most useful noninvasive techniques employed in the assessment of cardiac fuctions and its great vessels. In children, it is being used in the diagnosis of congenital and acquired cardiac dysfunctions with least discomfort. It also gives most useful information before and after cardiac surgery and medical therapy (Figs 1.109–1.111).

Radioisotopic studies using technitium 99 m is useful for delineating left to right shunts as well as the vessels and location of cardiac chambers (Fig. 1.112).

Cath Laboratory Procedures

Cardiac catheterisation aims at defining the anatomical and physiological variation of congenital heart disease and is undertaken only in specialised cardiac centres. It is indicated in infants and children with progressive lesions, complex malformations, severe degrees of cyanosis, severe degrees of refractory heart failure and in those in whom early surgery is contemplated (Fig. 1.113).

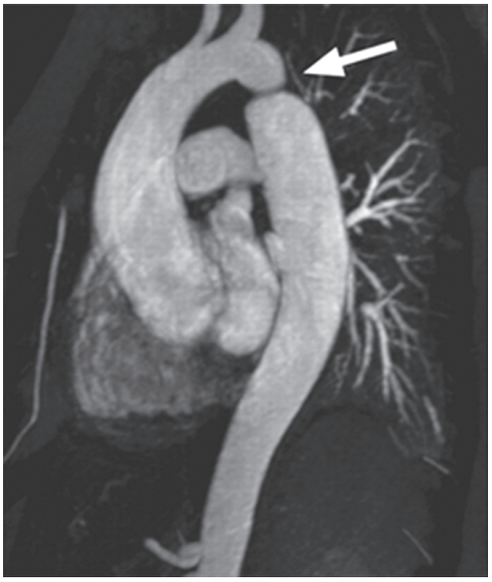

Fig. 1.111: MR angiography of the thoracic aorta with gadolinium-enhanced 3D gradient-echo imaging. in a 47-year-old man with recurrent aortic coarctation (arrow)

In competent hands, the technique is low risk procedure and provides data regarding O_2 content in the various chambers, systemic and pulmonary vascular resistance. Special techniques, such as the hydrogen electrode catheter (for very small L-R shunts) and the indicator dilution curves, detection of shunts as well as cardiac outputs, are employed when special indication exists. Cardiac catheterisation is also used for injection of contrast material for angiography and percutaneous introduction of intracardiac devices in the management of congenital and acquired heart defects.

Angiocardiography

Injection of contrast media into the required chambers or great vessels permits identification of specific anomalies (selective angiocardiography) producing pictures without shadows from other areas of the caxdiovascular system. A number of serial X-ray films (6–14/sec and even faster) are taken. Cineangiocardiography is being employed on a large scale in well-equipped centres (Fig. 1.114).

Cardiac Biomarkers

The use of cardiac biomarkers for the diagnosis and risk stratification of patients in the emergency department (ED) is evolving rapidly. Previously, the role of cardiac enzymes was restricted to the diagnosis of acute myocardial infarction (AMI). The identification of new biomarkers and more sensitive assays has extended the use of biomarkers beyond the diagnosis of cardiac necrosis. As novel biomarkers are identified, emergency physicians should be aware of both the potential clinical usefulness and the limitations of promising biomarkers. Testing should always

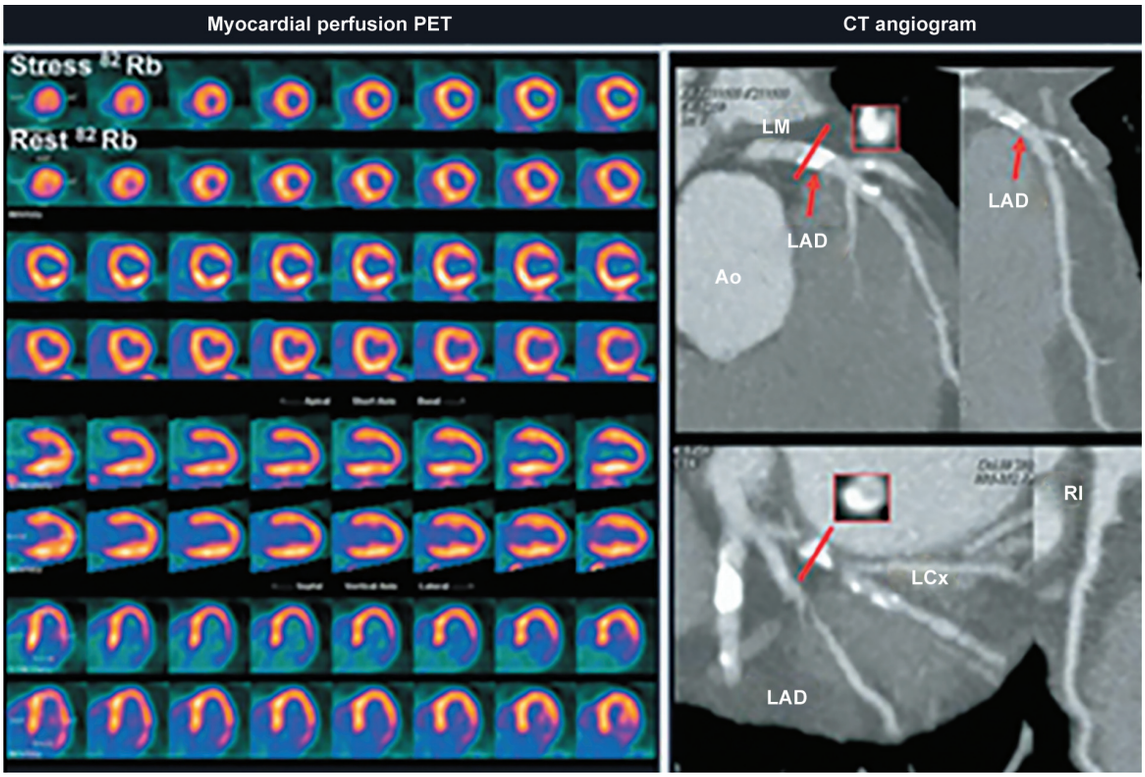

Fig. 1.112: Well-correlated myocardial perfusion with PET and CT coronary angiography of an obstructed and calcified left anterior descending artery



Fig. 1.113: Pullback catheter pressure trace across an aortic valve showing a peak-to-peak pressure gradient in excess of 110 mmHg indicating severe stenosis (LV=left ventricular pressure; Ao=aorta)

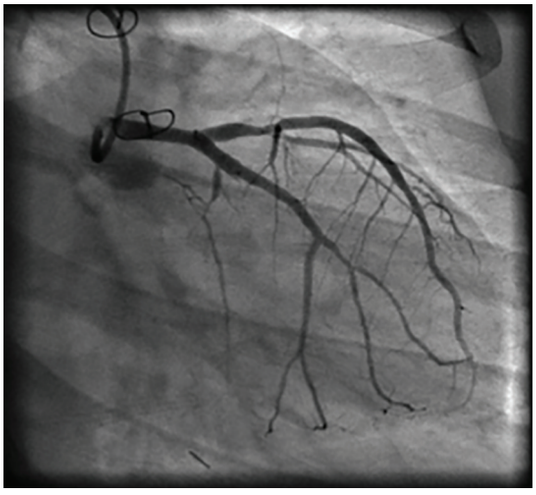

Fig. 1.114: Cine-angiography of coronary system showing osteal circumflex artery obstruction

be guided by a patient's history and physical examination to avoid misusing biomarkers as 'screening' tools in critically ill patients. This update focuses on the present and future value of cardiac biomarkers in the care of patients who have suspected cardiac and cardiac-related diseases in the emergency department.

Galectin-3, a biomarker: Galectin-3 is a protein that binds and activates myofibroblasts in damaged heart tissue, which leads to collagen synthesis and subsequently problematic fibrosis. Though, the current use case for galectin-3 is simply to get a better sense for the probability of adverse disease outcomes in patients with heart failure, ideally, treatments would be found that work best in patients with high galectin-3 levels. Believers include Abbott, Alere and bioMérieux, who have all entered agreements with BG Medicine to commercialize the assay for use in their own systems. From the press release, galectin-3 is a protein that has been shown to play an important role in the development and progression of heart failure in approximately 30% of the patients diagnosed with heart failure. (i) This galectin-3, mediated form of heart failure is associated with progressive fibrosis, or stiffening, in the heart muscle, which impairs the heart's ability to pump. (ii) The role of galectin-3 in heart failure was first established in 2004. (iii) The clearance of the company's galectin-3, blood test now for the first time allows physicians to use this product in the evaluation of patients diagnosed with heart failure. The availability of a galectin-3 test to identify high risk patients with cardiovascular disease and myocardial fibrosis represents another step toward the goal of enabling more efficient targeting of therapeutic approaches to reduce fibrosis in patients with chronic heart failure.

BIBLIOGRAPHY

1. A viles RJ, Askari AT, Lindahl B, et al. Troponin T levels in patients with acute coronary syndromes, with or without renal dysfunction. N Engl J Med 2002;346:2047–52.
2. Alpert LS, Thygesen K, Antman E, et al. Myocardial infarction redefined: a consensus document of The 10 Int. European Society of Cardiology/American College of Cardiology Committee for the redefinition of myocardial infarction. Am Coil Cardio 2000;36:959–69.
3. Ammann P, Sabine M, Kraus M, et al. Characteristics and prognosis of myocardial infarction in patients with normal coronary arteries. Chest 2000;117:333.
4. Antman EM, Tanasijevic MJ, Thompson B, et al. Cardiac-specific troponin I levels to predict the risk of mortality in patients with acute coronary syndromes. N Engl J Med 1996; 335: 1342–9.
5. Apple FS, Murakami MM, Pearce LA, et al. Predictive value of cardiac troponin I and T for subsequent death in end-stage renal disease. Circulation 2002;106:2941–5.

6. Aviles R1, Wright RS, Aviles M, et al. Long-term prognosis of patients with clinical unstable angina pectoris without elevation of creatine kinase but with elevation of cardiac troponin I levels. Am J Cardiol 2002;90:875–8.
7. Azzazy HM, Christenson RH. Cardiac markers of acute coronary syndromes: is there a case for point-of-care testing? Clin Biochem 2002;35:13–27.
8. Balk EM, Ioannidis P, Salem D, et al. Accuracy of biomarkers to diagnose acute cardiac ischemia in the emergency department: a meta-analysis. Ann Emerg Med 2001;37:478–94.
9. Blake GJ, Ridker PM. Inflammatory bio-markers and cardiovascular risk prediction. J Intern Med 2002;252:283–94.
10. Braunwald E, Antman EM, Beasley W, et al. ACC/AHA guidelines for the management of patients with unstable angina and non-ST-segment elevation myocardial infarction: executive summary and recommendations: a report of the American College of Cardiology/American Heart Association task force on practice guidelines (committee on the management of patients with unstable angina). Circulation 2000;102:1193–209.
11. Cantwell RV, Aviles RL, Bjornsson L, et al. Cardiac amyloidsis presenting with elevations of cardiac troponin I and angina pectoris. Clin Cardiol 2002;25:33–7.
12. Cheitlin MD, Alpert JS, Armstrong WF, et al. ACC/AHA Guidelines for the clinical application of echocardiography. A report of the American College of Cardiology/American Heart Association Task Force on Practice Guidelines (Committee on Clinical Application of Echocardiography). Developed in collaboration with the American Society of Echocardiography. Circulation 1997;95:1686.
13. Chou TM, Amidon TM. Evaluating coronary artery disease noninvasively: which test for whom? West J Med 1994; 161:173.
14. Diamond GA, Forrester JS. Analysis of probability as an aid in the clinical diagnosis of coronary artery disease. N Engl J Med 1979;300:1350.
15. Donnino MW, Karriem-Norwood V, Rivers EP, et al. Prevalence of elevated troponin I in end-stage renal disease patients receiving hemodialysis. Acad Emerg Med 2004; II:979–81.
16. Garber AM, Solomon NA. Cost effectiveness of alternative test strategies for the diagnosis of coronary artery disease. Ann Intern Med 1999;130:719.
17. Geleijnse ML, Elhendy A, Fioretti PM, et al. Dobutamine stress myocardial perfusion imaging. J Am Coll Cardiol 2000;36:2017.
18. Gianrossi R, Detrano R, Mulvihil D, et al. Exercise-induced ST-depression in the diagnosis of coronary artery disease: a meta-analysis. Circulation 1989;80:87.
19. Gibbons RJ, Balady GJ, Beasley JW, et al. ACC/AHA guidelines for exercise testing: a report of the American College of Cardiology/American Heart Association Task Force on Practice Guidelines (Committee on Exercise Testing). J Am Coll Cardiol 1997;30:260.
20. Gibbons RJ, Chatterjee K, Daley J, et al. ACC/AHA/ACP-ASIM guidelines for the management of patients with chronic stable angina: a report of the American College of Cardiology/American Heart Association Task Force on Practice Guidelines (Committee on the Management of Patients with Chronic Stable Angina). J Am Coll Cardiol 1999;33:2092.
21. Goyal RK. Changing focus on unexplained esophageal chest pain. Ann Intern Med 1996;124:1008.
22. Hertzer NR, Beven EG, Young JR, et al. Coronary artery disease in peripheral vascular patients: a classification of 1,000 coronary angiograms and results of surgical management. Ann Surg 1984;199:223.
23. Hwang SJ, Ballantyne CM, Sharrett AR, et al. Circulating adhesion molecules VCAM-I, CAM-I, and E-selectin in carotid atherosclerosis and incident coronary heart disease cases: the Atherosclerosis Risk In Communities (ARIC) study. Circulation 1997;96:4219–25.
24. Kontos MC, Fritz LM, Anderson FP, et al. Impact of the troponin standard on the prevalence of acute myocardial infarction. Am Heart 2003;146:446–52.
25. Koukkunen H, Penttila K, Kemppainen A, et al. Differences in the diagnosis of myocardial infarction by troponin T compared with clinical and epidemiologic criteria. Am 1 Cardiol 2001;88:727–31.
26. Kwok Y, Kim C, Grady D, et al. Meta-analysis of exercise testing to detect coronary artery disease in women. Am J Cardiol 1999;83:660.
27. Laffe AS, Katus H. Acute coronary syndrome biomarkers: the need for more adequate reporting. Circulation 2004; 110:104–6.
28. Laffe AS, Ravkilde, Roberts R, et al. It's time for a change to a troponin standard. Circulation 2000;102:1216–20.
29. Lee TH, Goldman L. Evaluation of the patient with acute chest pain. N Engl J Med 2000;341:1187.
30. Lee-Lewandrowski E, Corboy D, Lewandrowski K, et al. Implementation of a point-of-care satellite laboratory in the emergency department of an academic medical center: impact on test turnaround time and patient emergency department length of stay. Arch Pathol Lab Med 2003; 127:456–60.
31. Libby P. Inflammation in atherosclerosis. Nature 2002;420: 868–74.
32. Newby LK. Markers of cardiac ischemia, injury, and inflammation. Prog Cardiovasc Dis 2004;46:404–16.
33. Nissen SE, Grines CL, Gurley JC, et al. Application of a new phased-array ultrasound catheter in the assessHamm CW, Giannitsis E, Katus HA. Cardiac troponin elevations in patients without acute coronary syndrome. Circulation 2002; 106:2871–2.
34. Panteghini M. Acute coronary syndrome: biochemical strategies in the troponin era. Chest 2002; 122: 1428–35.
35. Panteghini M. Role and importance of biochemical markers in clinical cardiology. Eur Heart J. 2004;25:1187–96.
36. Polanczyk CA, Lee TH, Cook EF, et al. Cardiac troponin I as a predictor of major cardiac events in emergency department patients with acute chest pain. J Am Coli Cardiol 1998; 32:8–14.
37. Pryor DB, Harrell FE, Lee KL, et al. Estimating the likelihood of significant coronary artery disease. Am J Med 1983;75:771.
38. Quiles J, Roy D, Gaze D, et al. Relation of ischemia-modified albumin (IMA) levels following elective angioplasty for stable angina pectoris duration of balloon-induced myocardial ischemia. Am J Cardiol 2003;92:322–4.

39. Ridker PM, Brown NJ, Vaughan DE, et al. Established and emerging plasma biomarkers in the prediction of first atherothrombotic events. Circulation 2004; 109:IV6–19.
40. Ridker PM, Hennekens CH, Buring JE, et al. C-reactive protein and other markers of inflammation in the prediction of cardiovascular disease in women. N Engl J Med 2000;342: 836–43.
41. Ridker PM, Hennekens CH, Roitman-Johnson B, et al. Plasma concentration of soluble intercellular adhesion molecule I and risks of future myocardial infarction in apparently healthy men. Lancet 1998;351:88–92.
42. Roongsritong C, Warraich I, Bradley C. Common causes of troponin elevations in the absence of acute myocardial infarction: incidence and clinical significance. Chest 2004; 125: 1877–84.
43. Ross R. Atherosclerosis-an inflammatory disease. N Engl J Med 1999;340:115–26.
44. Roy D, Quiles J, Aldama G, et al. Ischemia modified albumin for the assessment of patients presenting to the emergency department with acute chest pain but normal or non-diagnostic 12-lead electrocardiograms and negative cardiac troponin T. Int J Cardiol 2004;97:297–301.
45. Sinha MK, Gaze DC, Tippins JR, et al. Ischemia modified albumin is a sensitive marker of myocardial ischemia after percutaneous coronary intervention. Circulation 2003;107: 2403–5.
46. Smith SC Jr, Anderson JL, Cannon RO III, et al. CDC/AHA workshop on markers of inflammation and cardiovascular disease: application to clinical and public health practice: report from the clinical practice discussion group. Circulation 2004;110:e550–3.
47. Wu AH, Apple FS, Gibler WB, et al. National Academy of Clinical Biochemistry Standards of Laboratory Practice: recommendations for the use of cardiac markers in coronary artery diseases. Clin Chem 1999;45:1104–21.
48. Wu AH, Smith A, Christenson RH, et al. Evaluation of a point-of-care assay for cardiac markers for patients suspected of acute myocardial infarction. Clin Chem Acta 2004;346: 211–9.

2 Recognition and Management of Angina Pectoris

Although James B. Herrick identified clinical features of angina as early as 1912, but William Heberden is still considered as the first person who drew attention of the world towards this condition for the first time in the history of medical science delivering his classical lecture on angina pectoris before the August audience of Royal College of Physician in 1968 in London. Since then, its spectrum of manifestation and modalities of treatment have been the attraction of the various medical scientists from time to time. Angina pectoris may be called symptom complex in which sensation of 'strangling' or 'squeezing' in restrostemal area of the chest remains the dominant symptom. It is a symptom and not a disease. Although the most common cause of the angina is coronary artery disease due to atheroma, it is important not to overlook other conditions that give rise to angina. These include valvular heart disease, congenital coronary artery anomalies syphilitic aortitis, cardiomyopathy and coronary artery vasculitis. Several 'anginal equivalents', such as dyspnea on exertion and exhaustion, that are not associated with chest discomfort, but are caused by myocardial ischemia also occur. Angina pectoris is the result of myocardial ischemia caused by an imbalance between myocardial blood supply and oxygen demand. Angina is a common presenting symptom (typically, chest pain) among patients with coronary artery disease. A comprehensive approach to diagnosis and to medical management of angina pectoris is an integral part of the daily responsibilities of physicians (Figs 2.1, 2.2 and Tables 2.1–2.5).

MAIN CATEGORIES OF ANGINA PECTORIS

The major types of angina are stable, unstable, variant (Prinzmetal's), and microvascular. Their knowledge is important due to the fact that they have different symptoms and require different treatments (Figs 2.3 and 2.8).



Fig. 2.1: A middle-aged man experiencing excruciating chest pain in angina pectoris

1. Stable Angina

It is the commonest type of angina, and occurs when the heart is working harder than usual. It has a regular pattern. ('Pattern' refers to how often the angina occurs, how severe it is, and what factors trigger it.)

If somebody is suffering with stable angina, one can learn its pattern and predict when the pain will happen. The pain usually goes away a few minutes after you rest or take your angina medicine.

It cannot be considered as a heart attack, but it can warn the person for heart attack, which is more likely to happen in the future.

2. Unstable Angina

Unstable angina is defined as new-onset angina (i.e. within 2 months of initial presentation) of at least class III severity, significant recent increase in frequency and severity of

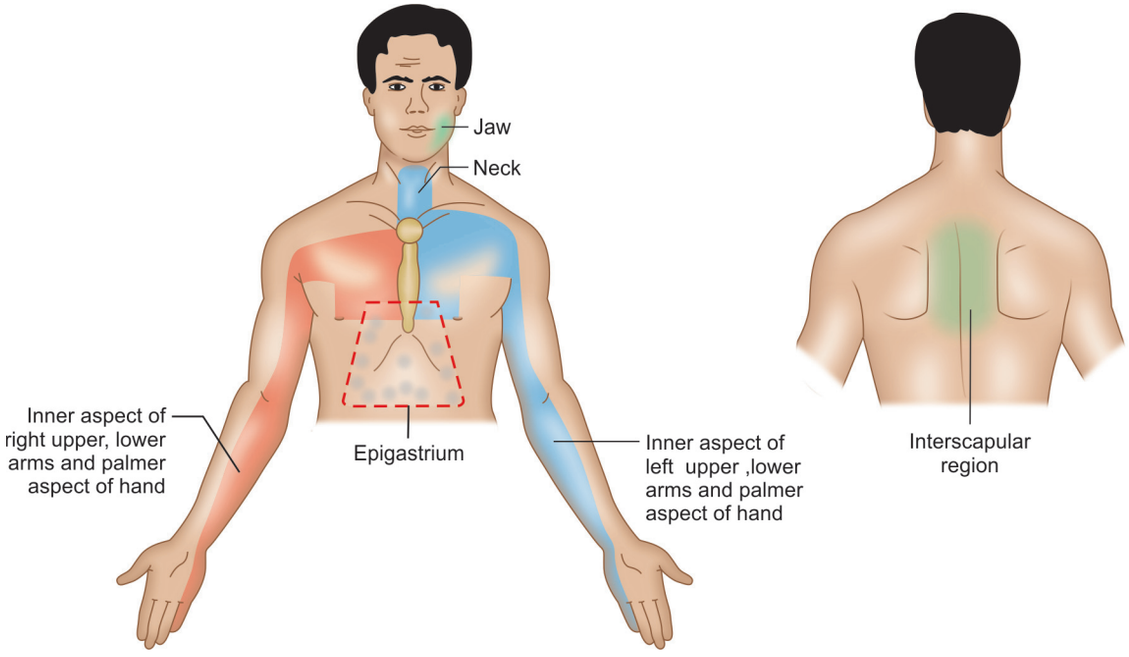

Fig. 2.2: Diagrammatic representation of regional distribution of anginal pain

Table 2.1: Classification of unstable angina

Severity	
Class I	New-onset, severe or accelerated angina Patients with angina of less than 2 months' duration, severe or occurring 3 or more times per day, or angina that is distinctly more frequent and precipitated by distinctly less exertion. No rest pain in the last 2 months.
Class II	Angina at rest, subacute Patients with 1 or more episodes of antina at rest during preceding month but not within 48 hours.
Class III	Angina at rest, acute. Patients with 1 or more episodes of angina at rest within the preceding 48 hours.
Clinical circumstances	
Class A	Secondary unstable angina A clearly identified condition extrinsic to the coronary vascular bed that has intensified myocardial ischemia, such as anemia, infection, fever, hypotension, tacharrhythmia, thyrotoxicosis, and hypoxemia due to respiratory failure.
Class B	Primary unstable angina
Class C	Postinfarction unstable angina (within 2 weeks of documented myocardial infarction).
Intensity of treatment	
1.	Absence of treatment or minimal treatment
2.	Occurring in the presence of standard therapy for chronic stable angina (conventional doses of oral β-adrenergic blockers, nitrates and calcium antagonists).
3.	Occurring despite maximally tolerated doses of all three categories of oral therapy, including intravenous nitroglycerin.

angina, or angina at rest. Unstable angina does not follow a fixed pattern. It may occur more often and be more severe than stable angina. Unstable angina can also occur with or without physical exertion, and rest or medicine may not relieve the pain. It is usually fatal and needs an urgent management. Unstable angina is a sign that a heart attack may happen soon.

3. Variant (Prinzmetal's) Angina

This type of angina is very uncommon. A spasm in a coronary artery leads to this type of angina. Variant angina usually occurs while one is resting and the pain can be severe. It usually happens between midnight and early morning. Coronary vasodilators can relieve the pain of this type of angina. Electrocardiogram reveals ST-segment

Table 2.2: Differential diagnosis of chest pain

Life-threatening causes
Acute coronary syndrome and aortic dissection
Pulmonary embolus
Tension pneumothorax
Other cardiovascular and nonischemic causes
Pericarditis
Atypical angina
Hypertrophic cardiomyopathy
Vasospastic angina
Other noncardiac causes
Boerhaave's syndrome (esophageal rupture with mediastinitis)
Gastroesophageal reflux and spasm
Chest-wall pain
Pleurisy
Peptic ulcer disease
Panic attack
Biliary or pancreatic pain
Cervical disc or neuropathic pain
Somatization and psychogenic pain disorder

Table 2.3: The New York Heart Association classification

Class I	No limitation of physical activity (ordinary physical activity does not cause symptoms)
Class II	Slight limitation of physical activity (ordinary physical activity causes symptoms)
Class III	Moderate limitation of activity (patient is comfortable at rest, but less than ordinary activities cause symptoms.)
Class IV	Unable to perform any physical activity without discomfort, therefore severe limitation (patient may be symptomatic even at rest)

Table 2.4: Canadian cardiovascular society angina grading scale

The Canadian Cardiovascular Society Angina Grading Scale is commonly used for the classification of severity of angina.

Class I	Angina only during strenuous or prolonged physical activity
Class II	Slight limitation, with angina only during vigorous physical activity
Class III	Symptoms with everyday living activities, i.e. moderate limitation
Class IV	Inability to perform any activity without angina or angina at rest, i.e. severe limitation

Table 2.5: Comparative features between Prinzmetal's classic effort angina and variant angina

Effort angina	Variant angina
1. Its occurance at time of day	
Ischaemic episodes cluster in early hours the day (6 am to noon)	Attacks usually cluster in very early of the day (mid-night to 6 am)
2. Pain	
Brought on by exertion or emotion	Occur at rest
Less severe	Frequently more severe
Shorter duration	Longer duration
Relieved after the exertion or emotional stress is taken away	
Non-cyclic	May occur in cycles
3. ECG	
ST-segments usually depressed without reciprocal changes	ST-segments is typically elevated with reciprocal depression
4. Holter monitoring	
Approximately 70% ST-segment depression without symptoms	ST-segment equally elevated and depressed (90%) without symptoms
5. Cardiac arrhythmia	
Hardly associated with cardiac arrhythmia	In about 50% of the cases cardiac arrhythmia occures either during or immediately after the attack
6. Treadmill testing	
There is ST-segment depression and/or precordial pain	Usually there is no ST-segment shift and/or chest pain

elevation caused by focal coronary artery spasm. Although, most patients had coronary lesions, some have angiographically normal coronary arteries. Different types of mechanisms have been been cited for Prinzmetal angina, such as focal deficiency of nitric oxide production, hyperinsulinemia, low intracellular magnesium levels, smoking cigarettes and using cocaine. Approximately, 30% of patients with chest pain referred for cardiac catheterization have normal or minimal atherosclerosis of coronary arteries. A subset of these patients demonstrates reduced coronary flow reserve (CFR), which is considered due to functional and structural changes of small coronary arteries and arterioles (i.e. resistance vessels). Normally, resistance vessels are responsible for as much as 95% of coronary

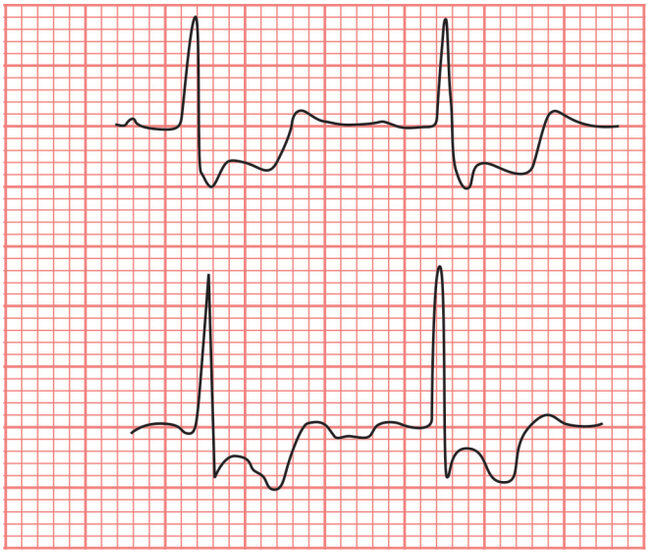

Fig. 2.3: Substantial ST-segment depression in patient with angina pectoris

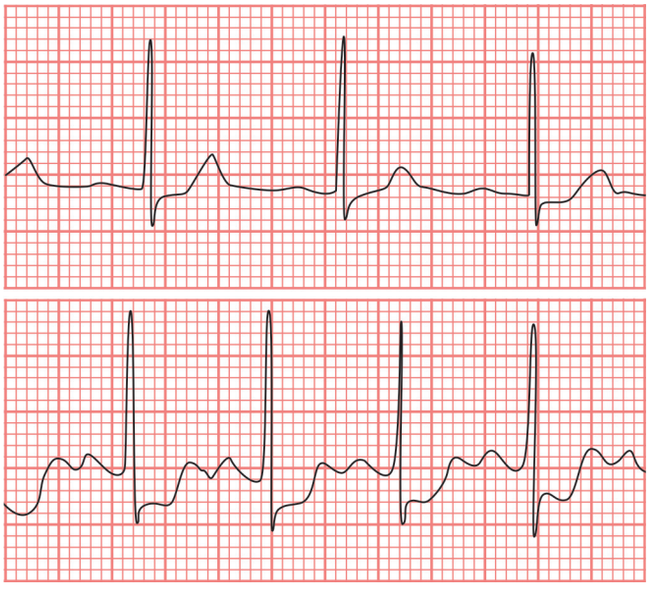

Fig. 2.4: Electrocardiogram showing stress induced ST-depression in patient with stable angina

artery resistance, with the remaining 5% being from epicardial coronary arteries (i.e. conductive vessels). The former is not visualized during regular coronary catheterization.

Angina which results from dysfunction of small coronary arteries and arterioles is called microvascular angina. Several diseases, such as diabetes mellitus, hypertension and systemic collagen vascular diseases (e.g. systemic lupus erythematosus, polyarteritis nodosa), are thought to produce microvascular abnormalities with subsequent reduction in CFR.

4. Microvascular Angina

Microvascular angina (MVA) can be considered as a result of microvascular disease (MVD) of the coronary artery. It

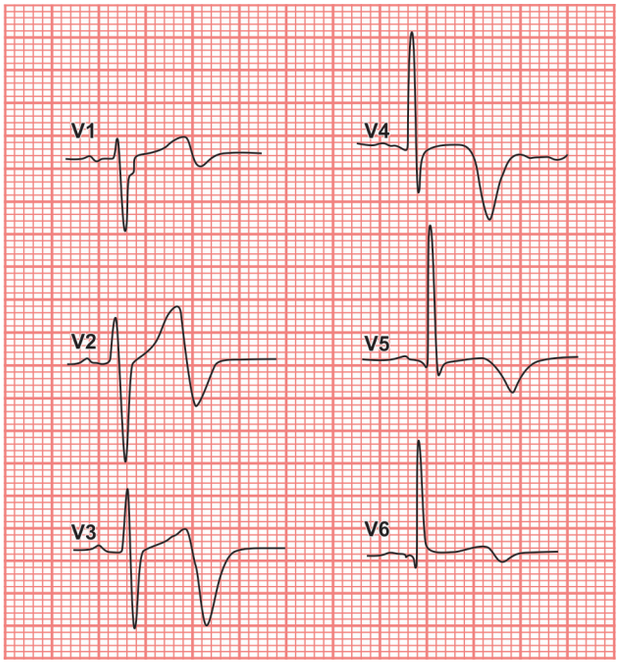

Fig. 2.5: Biphasic T-waves in patient with unstable angina

is a type of heart disease that affects the heart's smallest coronary arteries. Reduction in blood supply of the smaller coronary arteries may cause microvascular angina. Later can occur due to factors, such as plaque in the arteries, artery spasms, or damaged or diseased artery walls.

5. Angina Decubitus

Angina decubitus is a variant of angina pectoris that happens at night while the patient is in a recumbent posture. It is thought to be induced by an increase in myocardial oxygen demand due to expansion of the blood volume with increased venous return at recumbency. This type of angina is found equally among both the sexes. It can be a sign of coronary heart disease (CHD), irrespective of initial tests do not point to the disease. However, not all chest pain or discomfort is a sign of coronary artery disease.

Other conditions can also cause chest pain, such as

- Pulmonary embolism (a blockage in a lung artery)
- A lung infection
- Aortic dissection (tearing of a major artery)
- Aortic stenosis (narrowing of the heart's aortic valve)
- Hypertrophic cardiomyopathy (KAR-de-o-mi-OP-ah-thee; heart muscle disease)
- Pericarditis (inflammation in the tissues that surround the heart)
- A panic attack

MYOCARDIAL ISCHEMIA IN ANGINA PECTORIS

It can result due to the following reasons:

1. A reduction of coronary blood flow caused by fixed and/or dynamic epicardial coronary artery (i.e. conductive vessel) stenosis

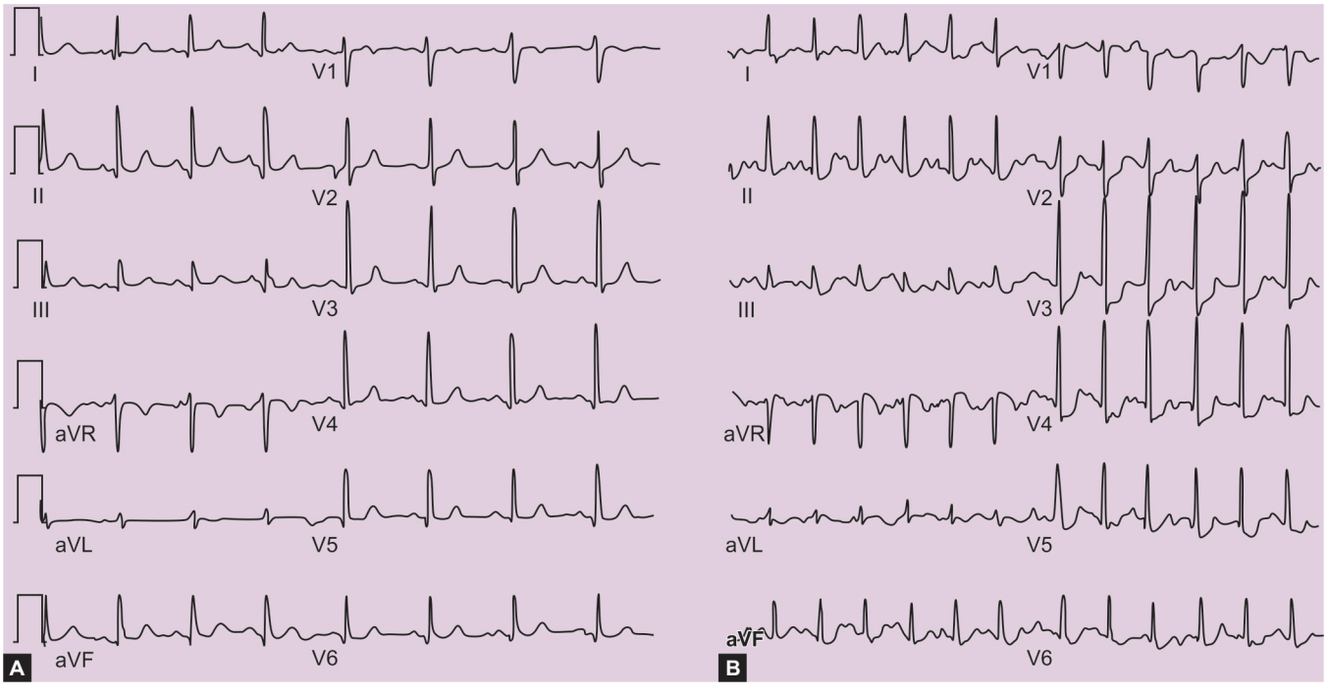

Fig. 2.6: ECG showing endothelial vascular angina with normal coronary arteries

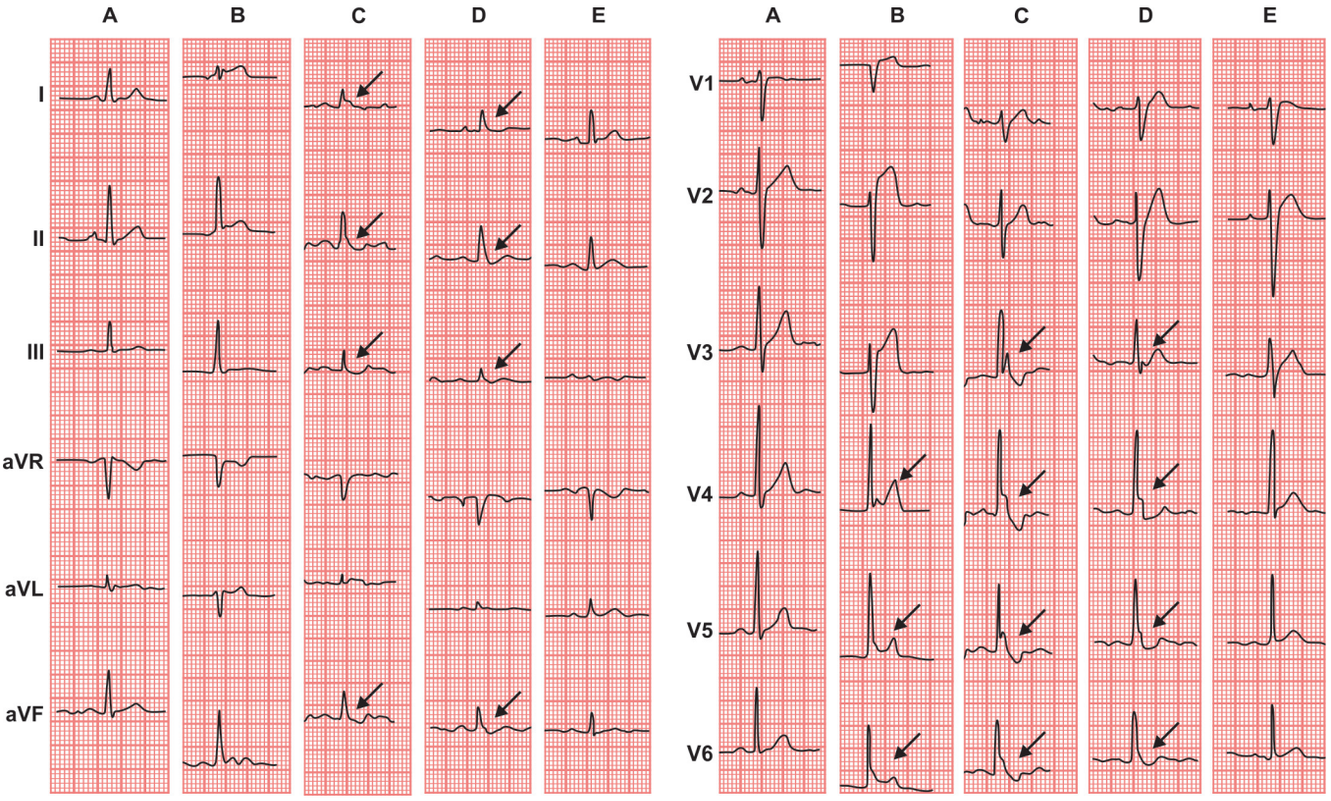

Fig. 2.7: The time course of twelve-lead ECG in a 52-year-old man with vasospastic angina. ECGs were obtained prior to the ischemic attack (A), at the onset of chest pressure (B), immediately before ventricular fibrillation (C), after defibrillation and administration of intravenous lidocaine and magnesium (D), and 2 days after the episode (E). Osborn waves (arrowheads) were best seen in the inferior and lateral leads around the occurrence of ventricular fibrillation. In contrast to hypothermic patients, the tracing shows sinus tachycardia and short QT

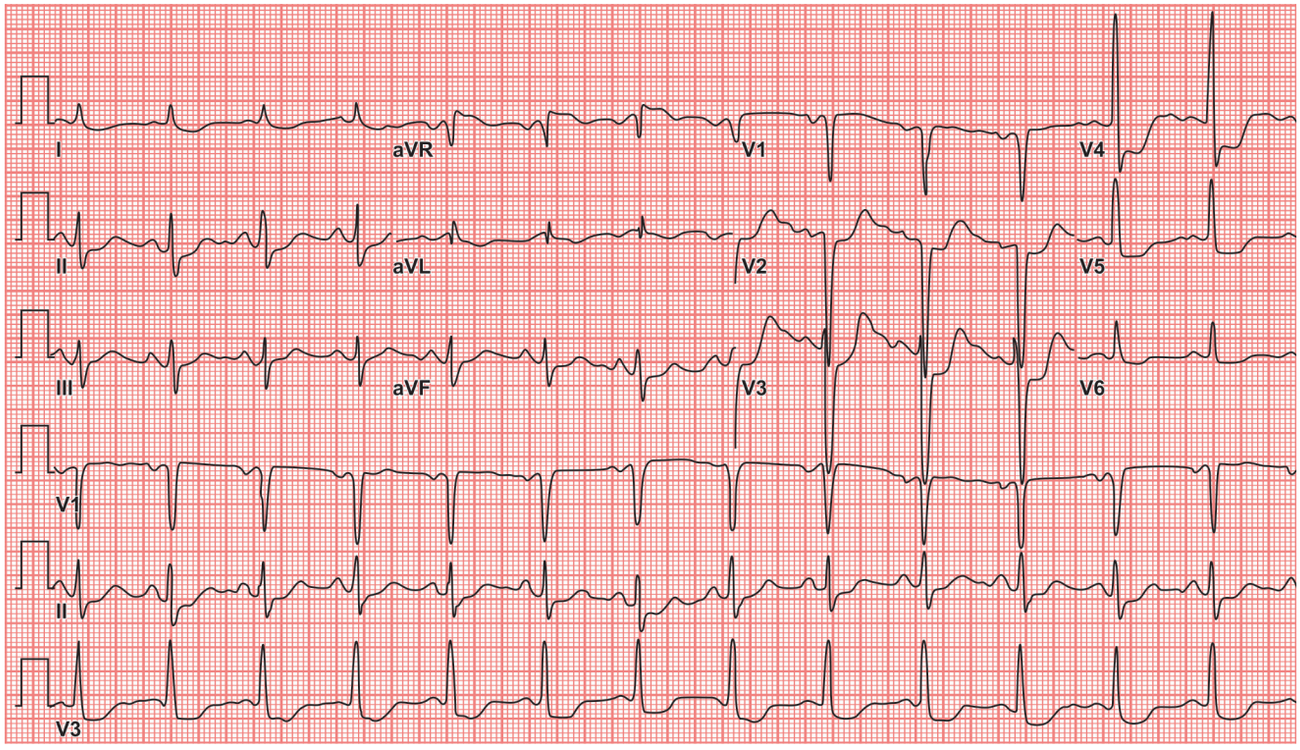

Fig. 2.8: A 12-lead electrocardiogram example of ischemic anterolateral ST-segment depression in a patient with known case of chronic stable angina

2. Abnormal constriction or deficient relaxation of coronary microcirculation (i.e. resistance vessels), or
3. Reduced oxygen-carrying capacity of the blood

Atherosclerosis is the most common cause of epicardial coronary artery stenosis and, hence, angina pectoris. Patients with a fixed coronary atherosclerotic lesion of at least 50% show myocardial ischemia during increased myocardial metabolic demand as the result of a significant reduction in CFR. These patients are notable to increase their coronary blood flow during stress to match the increased myocardial metabolic demand, thus they experience angina. Fixed atherosclerotic lesions of at least 90% almost completely abolish the flow reserve; patients with these lesions may experience angina at rest.

Coronary spasm can also reduce CFR significantly by causing dynamic stenosis of coronary arteries.

PATHOGENESIS IN ANGINA PECTORIS

Reduction in blood supply to heart muscle can occur when coronary blood flow becomes insufficient to meet myocardial oxygen demand. It can lead to myocardial cells to switch from aerobic to anaerobic metabolism, with a progressive impairment of metabolic, mechanical and electrical functions. It is the most common clinical presentation of myocardial ischemia. It is caused by chemical and mechanical stimulation of sensory afferent nerve endings in the coronary vessels and myocardium. These nerve fibers extend from the first to fourth thoracic spinal nerves, ascending via the spinal cord to the thalamus, and from there to the cerebral cortex. Currently it has been

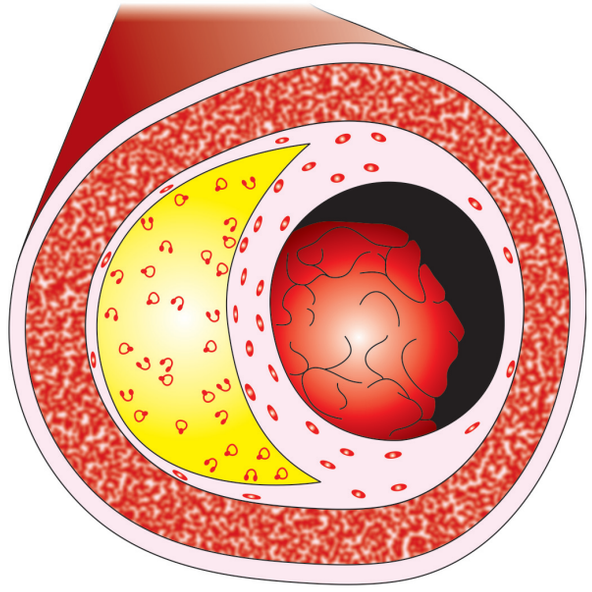

Fig. 2.9: Cross-section of an artery with an atherosclerotic lesion with a narrowed lumen in the genesis of angina pectoris

demonstrated that adenosine may be the main chemical mediator of anginal pain. At the time of ischemia, ATP is degraded to adenosine, which after diffusion to the extracellular space, causes arteriolar dilation and anginal pain. Adenosine induces angina mainly due to stimulating the A1 receptors in cardiac afferent nerve endings. The major determinants of myocardial metabolic activity are myocardial oxygen demand. Increases in the heart rate and

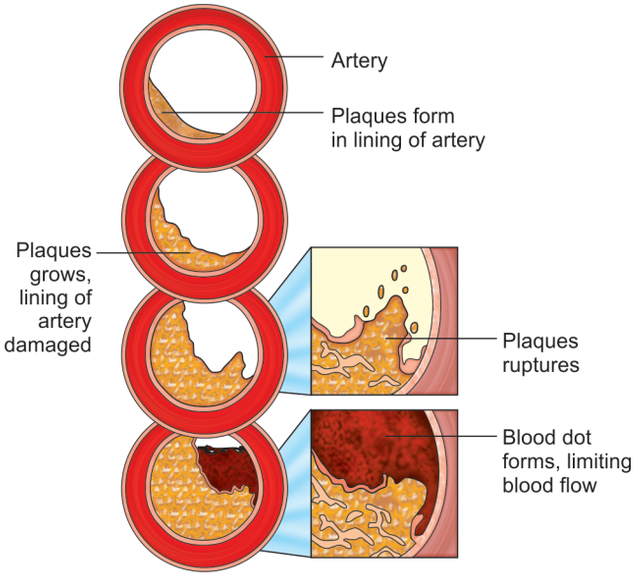

Fig. 2.10: Gradual onset of atherosclerosis in an artery with plaque buildup. It finally leads to blockage of artery with rupture of plaque and terminal unstable angina or myocardial infarction

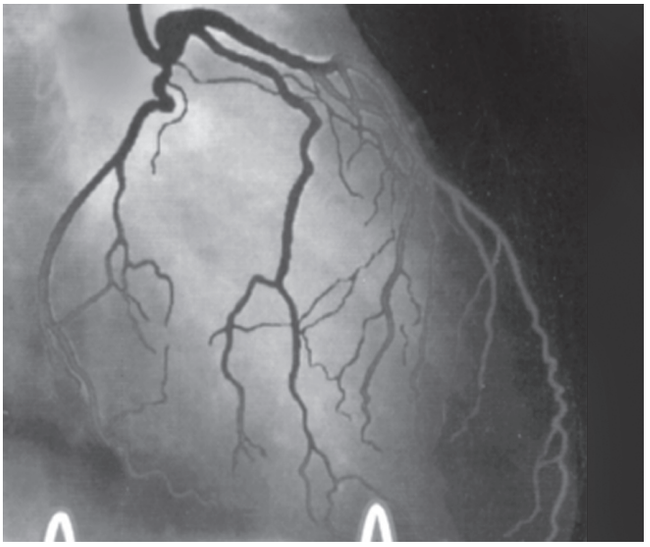

Fig. 2.11: Angiogram showing normal coronary vessels in patient with atypical noncardiac chest pain

myocardial contractile state which result in increased myocardial oxygen demand. Increases in both afterload (i.e. aortic pressure) and preload (i.e. ventricular end-diastolic volume) result in a proportional elevation of myocardial wall tension which in turn leads to increased myocardial oxygen demand. Oxygen supply to any organ system is determined by blood flow and oxygen extraction. Since the resting coronary venous oxygen saturation is already set at its lower level approximately (30%), the myocardium has a limited capacity to increase its oxygen extraction during certain situations of increased demand. Hence, an increase in myocardial oxygen demand (e.g. during exercise) must be met by a proportional increase in coronary blood flow. The capacity of the coronary arteries to enhance blood flow in reaction to increased cardiac metabolic demand is often called coronary flow reserve (CFR). Among normal persons, the maximal coronary blood flow after full dilation of the coronary arteries is approximately 4–6 times of the resting coronary blood flow. CFR is usually dependant upon at least 3 factors: Large and small coronary artery resistance, extravascular (i.e. myocardial and interstitial) resistance, and blood composition (Figs 2.9 and 2.10).

Syndrome X

The signs and symptoms comprising of syndrome X include angina pectoris, ischemia like ST-segment changes and/or myocardial perfusion defects during stress testing, and angiographically normal coronary arteries (Figs 2.11 and 2.12). In majority, patients with this syndrome are postmenopausal women, and they usually carry an excellent prognosis. Syndrome X is thought to be caused by microvascular angina. The following are the different mechanisms which can result this type of syndrome:

1. Impaired endothelial dysfunction
2. Increased release of local vasoconstrictors
3. Fibrosis and medial hypertrophy of the microcirculation
4. Abnormal cardiac adrenergic nerve function, and/of
5. Estrogen deficiency

Many of the extravascular forces produced by contraction of adjacent myocardium and intraventricular pressures can affect coronary microcirculation resistance and thus lead to fall in CFR. Extravascular compressive forces are highest in the subendocardium and decrease toward the subepicardium. Left ventricular (LV) hypertrophy together with a higher myocardial oxygen demand (e.g. during tachycardia) can result in greater susceptibility to reduced blood supply in the region of subendocardial layers. Reduction in blood supply to the myocardium can also be due to other factors affecting blood composition, such as reduced oxygen carrying capacity of blood, as is observed with severe anemia (hemoglobin, <8 g/dl), or elevated levels of carboxyhemoglobin. The latter may be the result of inhalation of carbon monoxide in a closed area or of long-term smoking. Holter Electrocardiographic Monitoring Study has revealed that silent ischemia is a common phenomenon among patients with established coronary artery disease. In one particular study some workers had demonstrated as many as 75% of episodes of ischemia (defined as transient ST-depression of ≥1 mm persisting for at least 1 min) happening in patients with stable angina were clinically silent. Silent ischemia occurs most frequently in early morning hours and may result in transient myocardial contractile dysfunction (i.e. stunning). The exact pathophysiology for silent ischemia is not very well known. However, autonomic dysfunction (especially in diabetic patients, a higher pain threshold in some individuals, and the production of excessive quantities of endorphins are the popular hypotheses in silent myocardial ischemia.

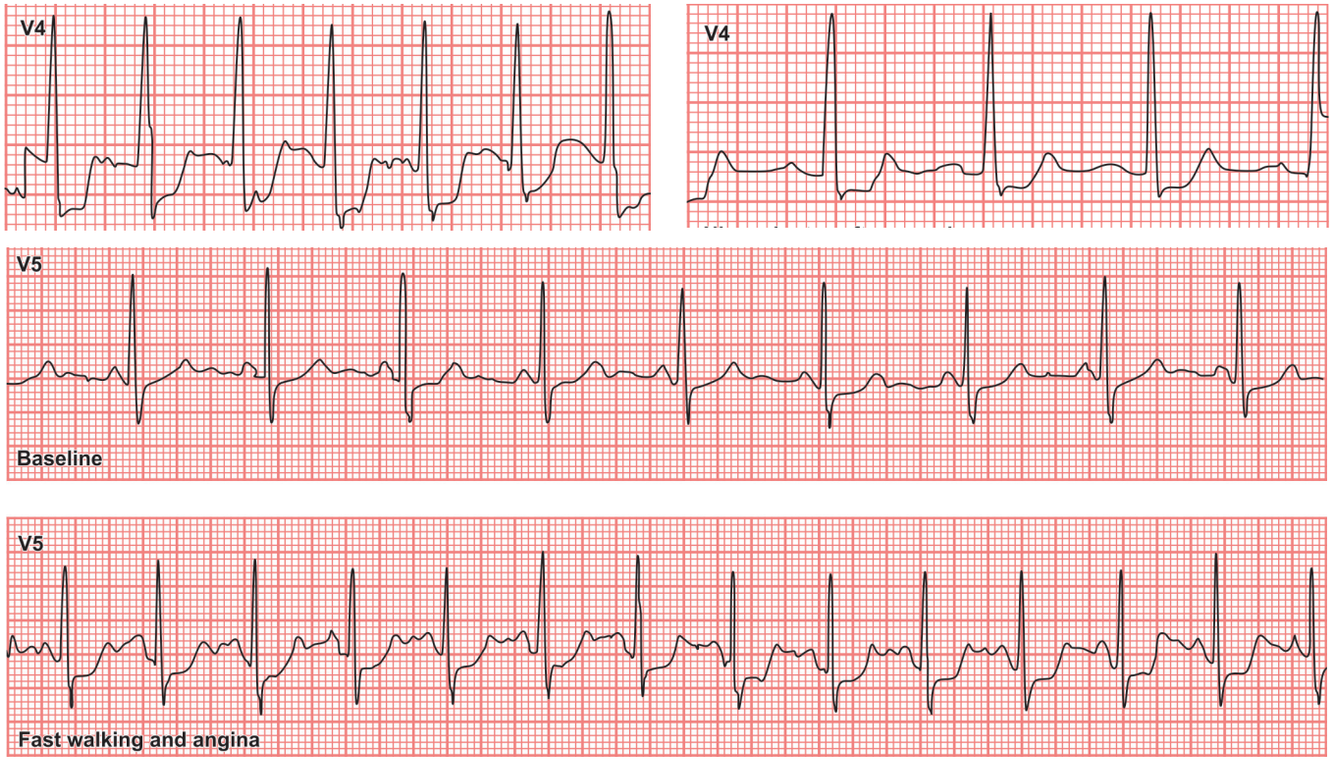

Fig. 2.12: (Top) Syndrome X'-exercise testing in a patient with angina and angiographically normal coronary arteries showed CAD-like ST-segment depression. Similarly, transient ischemia like ST-segment changes were recorded during 24-hours ECG monitoring in another patient with exertional chest pain and normal coronary angiograms (bottom)

INCIDENCE OF ANGINA PECTORIS

Approximately, 6.3 million Americans are estimated to experience angina. An estimated 350,000 new cases of angina occur every year. Each year, 1.1 million new and recurrent cases of an acute coronary event occur, of which more than 40% are fatal. Roughly, more than 12 million had a history of myocardial infarction (MI) and/or angina pectoris in the year 2000.

Mortality/Morbidity: Coronary artery disease is the single most common cause of death in most of developed and developing countries, accounting for almost one death per minute. More than half of those who die suddenly from coronary artery disease have no previous symptoms.

Race: The rate of angina pectoris in women older than 2 years ranges from 3.9% in non-Hispanic white women to 6.2% in non-Hispanic black women and 5.5% in Mexican American women. The rates of angina pectoris for men in the same ethnic groups are 2.6%, 3.1% and 4.1%, respectively. Among American Indians aged 65–74 years, the rates (per 1000 persons) of new and recurrent heart attacks are 25.1% for men and 9.1% for women.

Gender: Angina pectoris is more often the presenting symptom of coronary artery disease in women than in men, with a female-to-male ratio of 1.7:1. It has a prevalence of 3.9 million in women and 2.3 million in men. The frequency of atypical presentations is also more common among women compared with men. Women have a slightly higher rate of mortality from coronary artery disease compared with men, in part because of an older age at presentation and a frequent lack of classic anginal symptoms. The estimated age-adjusted prevalence of angina is greater in women than in men.

Age: The prevalence of angina pectoris increases with age. Age is a strong independent risk factor in ischemic heart disease.

HISTORY IN ANGINA PECTORIS

Most patients with angina pectoris report of retrosternal chest discomfort rather than frank pain. The former is usually described as a pressure, heaviness, squeezing, burning, or choking sensation. Anginal pain may be localized primarily in the epigastrium, back, neck, jaw, or shoulders. Typical locations for radiation of pain are arms, shoulders and neck.

Typically, angina is precipitated by exertion, eating, exposure to cold, or emotional stress. It lasts for approximately 1–5 minutes and is relieved by rest or nitroglycerin. Chest pain lasting only a few seconds is not usually angina pectoris. The intensity of angina does not change with respiration, cough, or change in position. Pain above the mandible and below the epigastrium is rarely anginal in nature. Ask patients about the frequency of angina, severity of pain, and number of nitroglycerin pills used during angina episodes.

PHYSICAL EXAMINATION IN ANGINA PECTORIS

For most patients with stable angina, physical examination findings are normal. Diagnosing secondary causes of angina, such as aortic stenosis, is important.

A positive Levine sign (characterized by the patient's fist clenched over the sternum when describing the discomfort) is suggestive of angina pectoris. Look for physical signs of abnormal lipid metabolism (e.g. xanthelasma, xanthoma) or of diffuse atherosclerosis (e.g. absence or diminished peripheral pulses, increased light reflexes or arteriovenous nicking upon ophthalmic examination and carotid bruit).

Clinical examination of patients during the angina attack may be more contributory. Examination findings, which are most important include third and/or fourth heart sounds due to LV systolic and/or diastolic dysfunction and mitral regurgitation secondary to papillary muscle dysfunction. Pain which is produced with pressure on the chest wall is usually of chest wall diseases. Factors leading to angina pectoris decrease in myocardial blood supply due to increased coronary resistance in large and small coronary arteries.

Significant coronary atherosclerotic lesion in the large epicardial coronary arteries (i.e. conductive vessels) with at least a 50% reduction in arterial diameter. Coronary spasm (i.e. Prinzmetal angina), abnormal constriction or deficient endothelial-dependent relaxation of resistant vessels associated with diffuse vascular disease (i.e. microvascular angina) syndrome X. Systemic inflammatory or collagen vascular disease, such as scleroderma, systemic lupus Erythematous, Kawasaki disease, polyarteritis nodosa, and Takayasu arteritis. Increased extravascular forces, such as severe LV hypertrophy caused by hypertension, aortic stenosis, or hypertrophic cardiomyopathy, or increased LV diastolic pressures. Reduction in the oxygen-carrying capacity of blood, such as elevated carboxyhemoglobin or severe anemia (hemoglobin, < 8 g/dl)

The following are congenital anomalies of the origin and/or course of the major epicardial coronary arteries:

1. Structural abnormalities of the coronary arteries
2. Congenital coronary artery aneurysm or fistula
3. Coronary artery ectasia
4. Coronary artery fibrosis after chest radiation
5. Coronary intimal fibrosis following cardiac transplantation

RISK FACTORS

Major risk factors which can lead to atherosclerosis are:

1. Family history of premature coronary artery disease,
2. Cigarette smoking
3. Diabetes mellitus
4. Hypercholesterolemia or
5. Systemic hypertension
6. Other risk factors include LV hypertrophy, obesity, and elevated serum levels of homocysteine, lipoprotein (a), plasminogen activator inhibitor, fibrinogen, serum triglycerides, or low high-density lipoprotein (HDL).

Metabolic syndrome: The main features of this syndrome are the presence of hyperinsulinemia (fasting glucose level ≥110 mg/dl), abdominal obesity (waist circumference >40 inches for men or >35 inches for women) decreased HDL cholesterol levels (<40 mg/dl for men or <50 mg/dl for women), hypertriglyceridemia (>150 mg/dl), and hypertension (≥130/85 mmHg). Patients with the metabolic syndrome have a 3-fold increased risk for coronary atherosclerosis and stroke compared with those without these features.

Precipitating factors: The factors which can precipitate angina pectoris are severe anemia, fever, tachyarrhythmias, catecholamines, emotional stress, and hyperthyroidism, due to increase in myocardial oxygen demand.

Preventive factors: Factors associated with reduced risk of atherosclerosis are a high serum HDL cholesterol level, physical activity, estrogen, and moderate alcohol intake (1–2 drinks/day).

Other problems to be considered

1. Esophageal spasm
2. Esophageal rupture
3. Costochondritis
4. Herpes zoster
5. Pneumonia with pleural involvement

LABORATORY INVESTIGATIONS

Chest radiography: Findings are usually normal in patients. However, they may show cardiomegaly in patients with previous MI, ischemic cardiomyopathy, pericardial effusion or acute pulmonary edema. Calcification of coronary arteries frequently correlates with major coronary artery disease with angina pectoris.

Imaging Studies

Exercise stress testing: When performed alone, exercise stress testing generally has somewhat lower sensitivity and

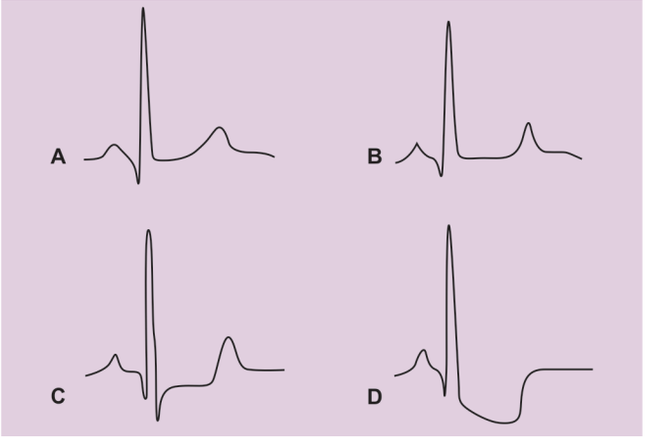

Fig. 2.13: (A) ST changes with ischemia depicting normal waveforms, (B) Flattening of ST-segment, (C) Making T-wave more prominent, horizontal ST-segment depression, (D) Down slopping ST-segment depression



Fig. 2.14: (A) ECG showing normal STT changes at rest and (B) marked ST-depression in a in stable angina patient with exercise

specificity, but it is cheaper and therefore is a reasonable option in patient with a low probability of disease. It can be performed alone and in conjunction with echocardiography or myocardial perfusion scintigraphy tests. Stress echocardiography has an overall sensitivity of 78% and specificity of 86%; myocardial perfusion scintigraphy has an overall sensitivity of 83% and specificity of 77%. Test results must be interpreted with the background of patient's history and physical examination. In population with low prevalence, the predictive abilities of these tests are low; however, in patients with a high likelihood of coronary artery disease, the predictive value is much higher (Figs 2.13 and 2.14).

Stress echocardiography: It can be used to evaluate segmental wall motion during exercise. It detects changes in regional wall motion that occur during myocardial ischemia. Normal myocardium becomes hyperdynamic during exercise; ischemic segments become hypokinetic or akinetic (Fig. 2.15).

It has the advantage of simultaneous evaluation of LV function, cardiac dimensions,valvular disease, in patients with baseline ECG abnormalities and those with systolic murmurs suggestive of aortic stenosis or hypertrophic cardiomyopathy. It is also helpful for localizing ischemia and evaluating its severity. During exercise stress echocardiography signs of severe coronary artery disease include LV dilation, a decrease in global systolic function, and new or worsening mitral regurgitation. However, with dobutamine stress echocardiography, even in patients with severe coronary artery disease, the LV cavity may not dilate and global systolic function may improve. A major problem with stress echocardiography is the technical difficulty with obtaining adequate images in some patients.

Nuclear evaluation in anginal patient: These are the most frequently used myocardial perfusion scintigraphy tests. These tests are especially useful in patients with baseline

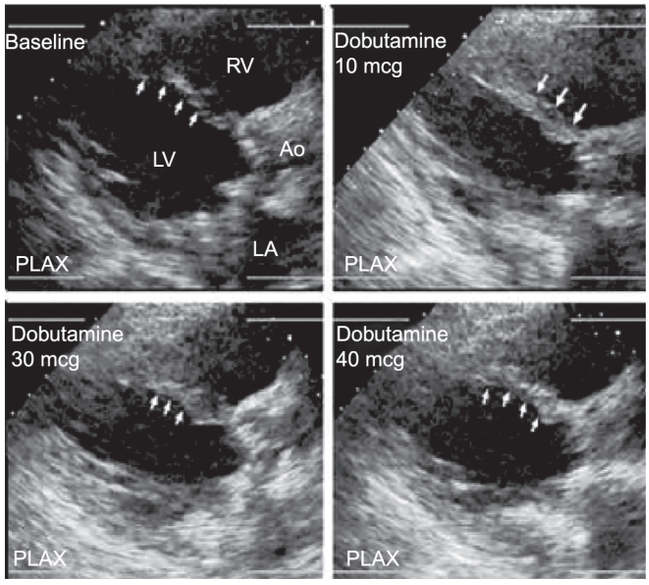

Fig. 2.15: Dobutamine stress echocardiogram—biphasic response. A biphasic response on dobutamine stress echocardiography in an anginal patient who is considered as a candidate for coronary artery revascularization procedures

ECG abnormalities, to localize the region of ischemia, and as prognostic indicators (Figs 2.16 and 2.20).

The presence of increased lung uptake upon thallium imaging is associated with a poor prognosis. Increased lung uptake, together with post-stress dilation of the LV and multiple perfusion defects, is suggestive of either left main coronary artery disease or severe three-vessel disease. The number of affected myocardial segments is predictive of long-term survival. Smaller perfusion defects are usually associated with peripheral coronary artery lesions, which are associated with a better prognosis. The absence of perfusion defects even in the presence of symptoms indicates an excellent prognosis. The frequency of infarction or death is 1 case per 10,000 stress tests. Absolute contra-

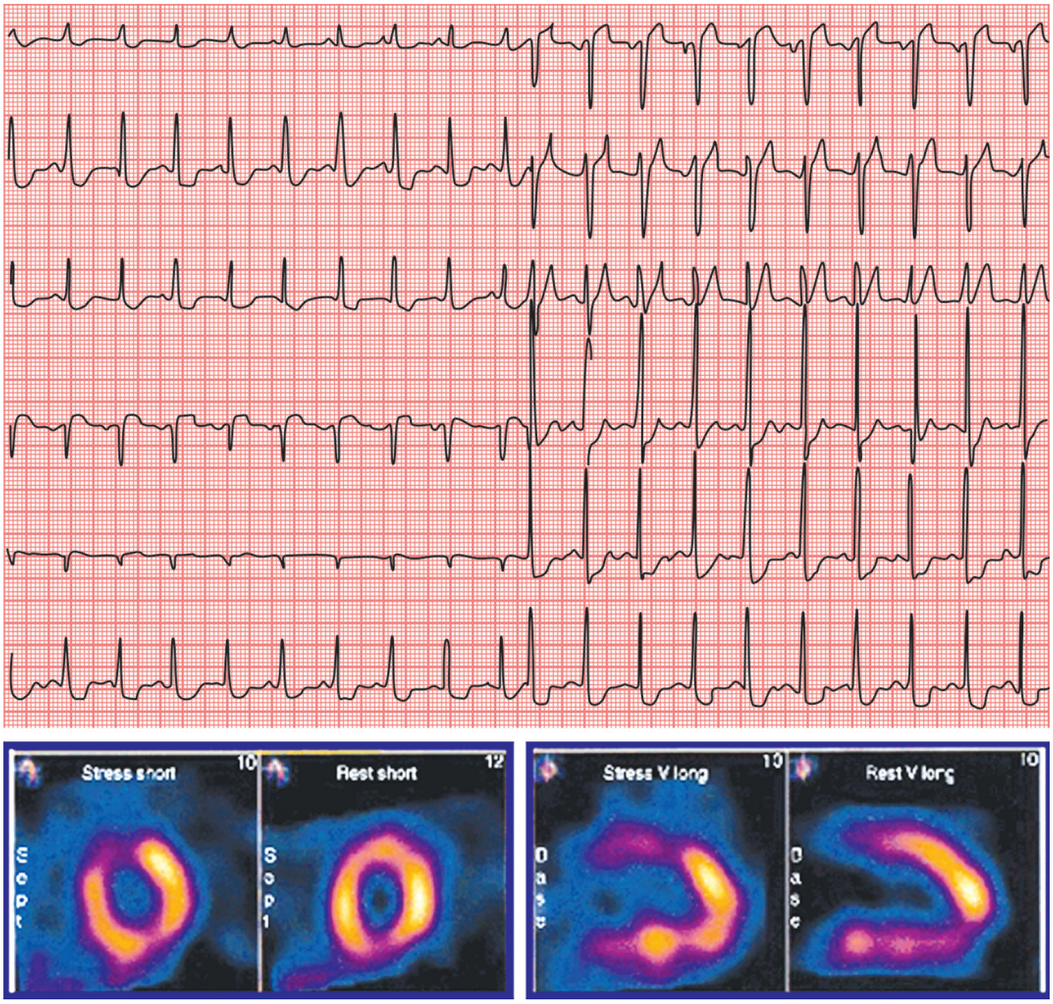

Fig. 2.16: Effort ECG and (upper panel) corresponding myocardial SPECT (lower panel) of the DM2 patient. At maximal exercise, ECG shows diffuse ST-segment depression. At the same time, SPECT reveals septal myocardial perfusion defect which is reversible at rest

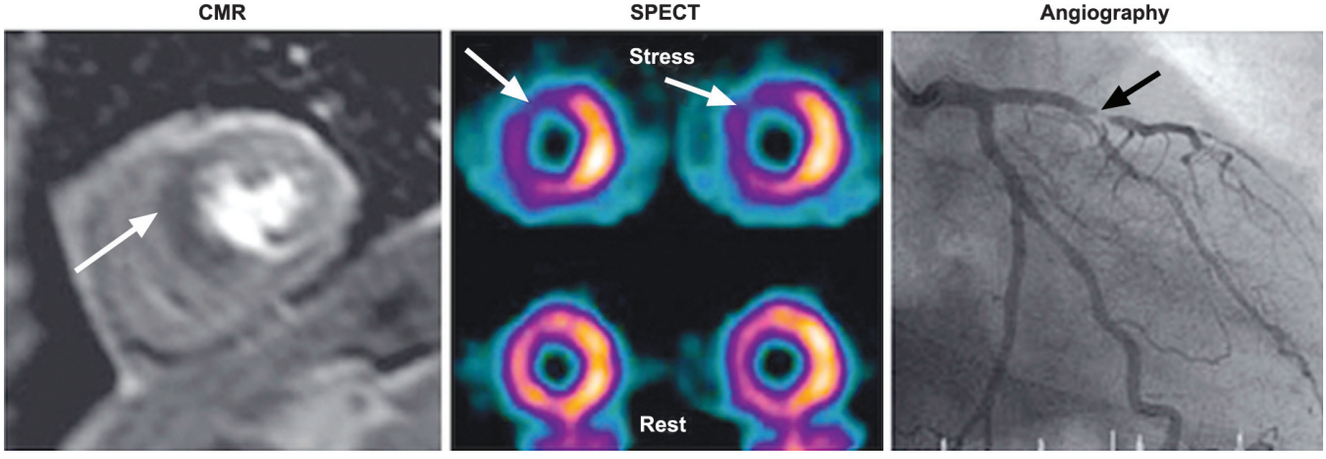

Fig. 2.17: Hypoperfusion of the anterior wall and septum seen on MRI (left) and SPECT (centre). Angiography demonstrates this to be due to LAD and diagonal disease

indications include symptomatic cardiac arrhythmias, severe aortic stenosis, acute MI within the previous 2 days, acute myocarditis, or pericarditis. Discontinue the exercise stress test in the presence of chest pain, a drop in systolic blood pressure of more than 10 mmHg, severe shortness of breath, fatigue, dizziness or near syncope, ST-depression

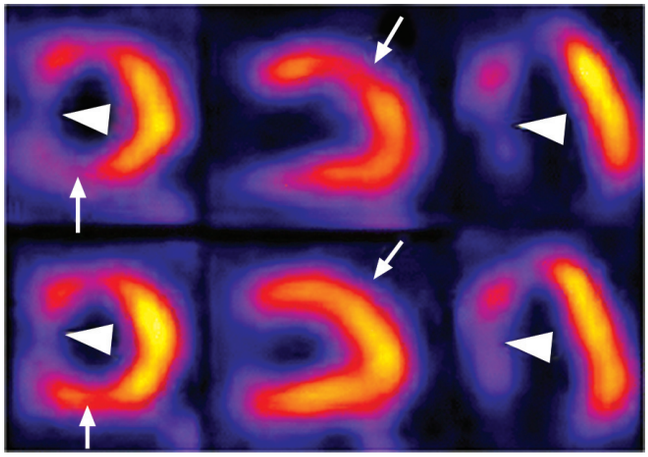

Fig. 2.18: Example of a patient with a reversible defect as well as an irreversible defect on perfusion SPECT. Example of a patient with reversible perfusion defect in the inferior (white arrows short-axis images) and anterior wall (white arrows vertical long-axis images), and an irreversible perfusion defect in the septum (arrow heads short-axis and horizontal long-axis images). The upper panel shows from left to right the short axis, the vertical long axis and the horizontal long axis reconstructions after stress and the lower panel shows the same reconstructions during rest

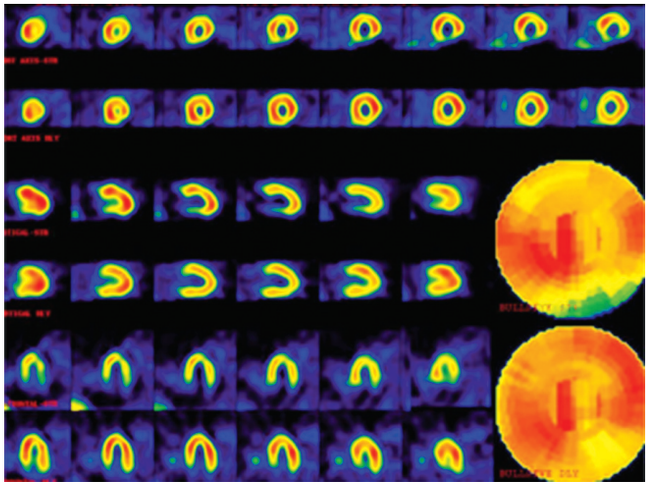

Fig. 2.19: A patient with multiple perfusion defects with different degrees of severity. The upper images are stress phase and lower images are rest or delayed images. There is moderate ischemia in the mid-anterolateral and mid-inferolateral walls. Also there is severe ischemia in the basal inferior wall. Mild ischemia in the apex, apical septal and basal anterolateral are also noted

of more than 2 mm, ST-elevation of at least 1 mm without diagnostic Q-waves, or development of ventricular tachyarrhythmia.

Other Tests

Electrocardiography: It is a useful tool for evaluating persons with angina pectoris; however, findings are variable among patients (Figs 2.21 and 2.22). Approximately 50% of patients with angina pectoris have normal findings after a resting ECG. However, abnormalities, such as

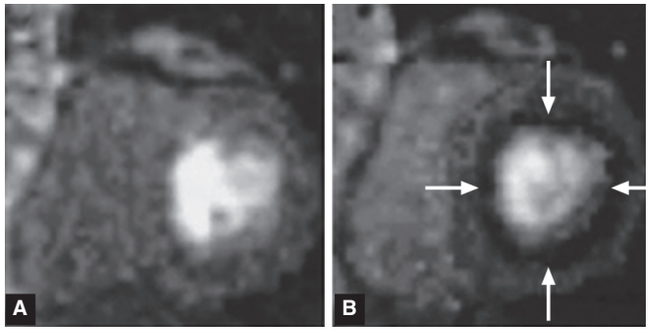

Fig. 2.20: Images of myocardium at peak myocardial enhancement during the first pass of gadolinium in a patient with syndrome X at rest (A) and during stress (B), showing a ring of delayed subendocardial enhancement (arrows in B)

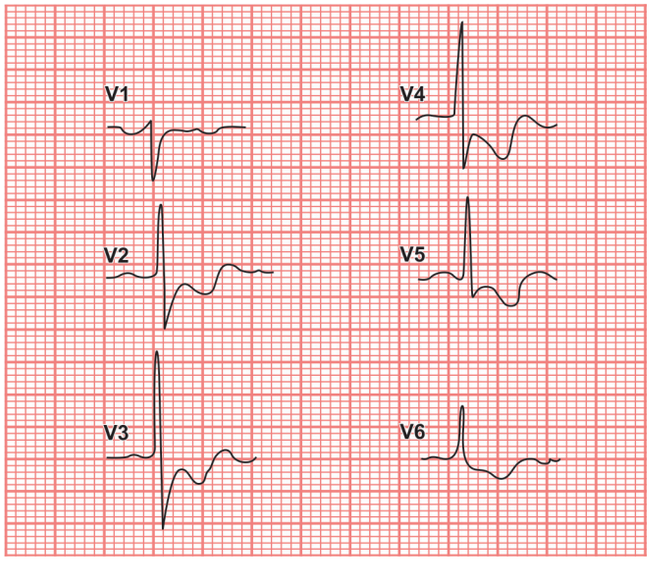

Fig. 2.21: Widespread ST-segment depression in patient with unstable angina



Fig. 2.22: Reversible ST-segment alterations in patient with chest pain; the ST-segment elevation returns to normal as the pain subsides

evidence for prior MI, intraventricular conduction delay, various degrees of atrioventricular block, arrhythmias, or

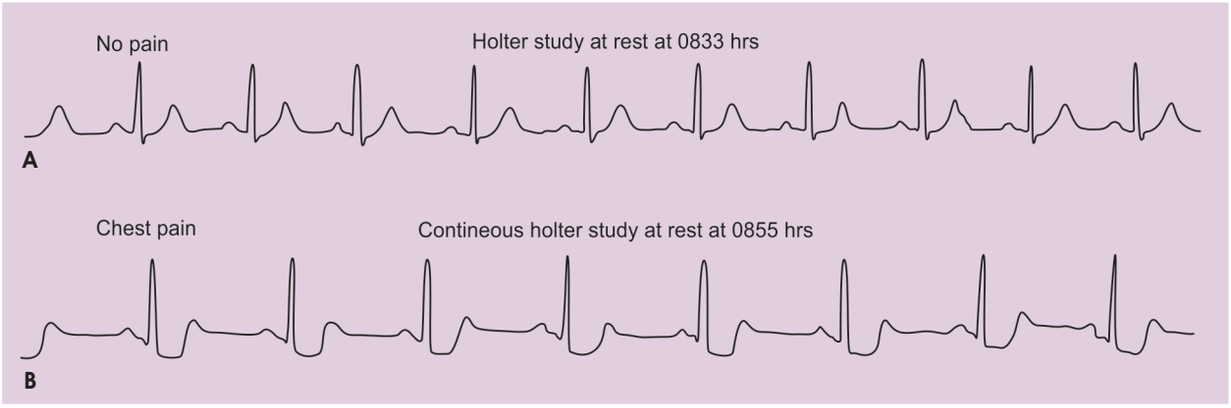

Fig. 2.23: (A) normal sinus rhythm at 0833 hrs and (B) chest pain with significant ST-segment depression at 0855 hours on Holter monitor recording of a patient with angina pectoris

ST-T-wave changes may be seen. During an attack of angina pectoris, 50% of patients with normal findings after resting ECG show abnormalities. A 1 mm or greater depression of the ST-segment below the baseline, measured 80 milliseconds from the J point, is the most characteristic change. Reversible ST-segment elevation occurs with Prinzmetal angina. Some patients with coronary artery disease may show pseudo-normalization of the resting ECG ST-T-wave abnormalities during episodes of chest pain.

Exercise with ECG monitoring alone is the initial procedure of choice in patients without baseline ST-segment abnormalities or in whom anatomic localization of ischemia is not a consideration. Horizontal or downsloping ST-segment depression of at least 1 mm, measured 80 milliseconds from the J point, is considered the characteristic ischemic response. ST-segment depression of more than 2 mm at a low workload or that persists for more than 5 minutes after termination of exercise and a failure of blood pressure to rise or an actual drop in blood pressure are signs of severe ischemic heart disease and a poor prognosis. Withhold beta-blockers for approximately 48 hours before the stress test, whenever possible. Patients on digoxin and those with LV hypertrophy with repolarization abnormalities more often show positive results. Exercise stress tests have lower sensitivity and specificity in women and in patients with left bundle-branch block.

Ambulatory ECG monitoring: It can be used for diagnostic purposes in patients with chest pain suggestive of Prinzmetal angina but is primarily used to evaluate the frequency of silent ischemia (Fig. 2.23). Silent ischemia has been shown to be an independent predictor of mortality in patients with angina pectoris.

Several studies have shown that calcium in the coronary arteries as detected by electron-beam computed tomography is an important indicator of coronary artery stenosis. In these studies, the sensitivity of a positive electron-beam computed tomography scan ranged from 85% to 100% and the specificity varied from 41% to 76%, while the positiv predictive value varied from 55% to 84% and the negative predictive value varied from 84% to 100%. However, several studies, have shown inconsistent reproducibility in repeated measures of coronary calcium with electron-beam computed tomography. Thus, its proper role at this time remains controversial.

Procedures

Selective coronary angiography: It is the definitive diagnostic test for evaluating the anatomic extent and severity of coronary artery disease. Consider coronary angiography in symptomatic patients with inconclusive noninvasive study results, in survivors of sudden cardiac death, in those who are considered to have a poor prognosis based on the results of noninvasive studies, in those with occupational requirements for a definite diagnosis (e.g. pilots), or in patients with coronary artey disease who are severely symptomatic despite maximal medical therapy.

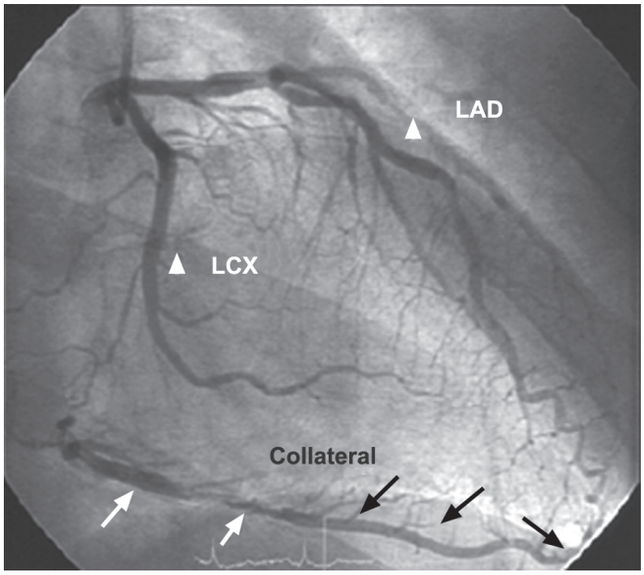

Fig. 2.24: Representative coronary angiography for collaterals. The patient is a 42-year-old man. His right coronary artery is totally occluded, but Rentrop grade III collateral (arrowheads) can be seen from the left coronary artery. His left ventricular ejection fraction is 60%. LAD, left anterior descending coronary artery; LCX, left circumflex coronary artery

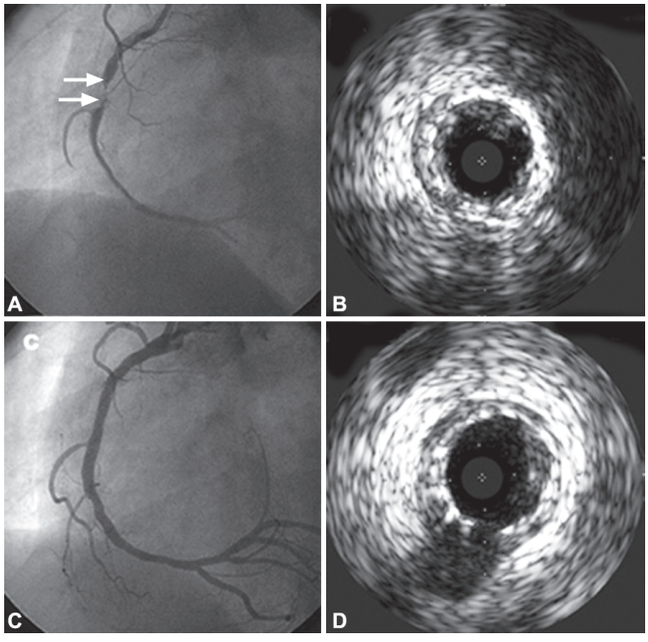

Fig. 2.25: (A) Right coronary angiogram showing very late stent thrombosis in RCA stent, (B) IVUS showing neointima breakdown and ruptured plaque within the RCA stent, (C) Coronary angiography after plain old balloon angioplasty (POBA). Final coronary angiogram showed good distal flow, (D) IVUS showed markedly decreased residual stenosis

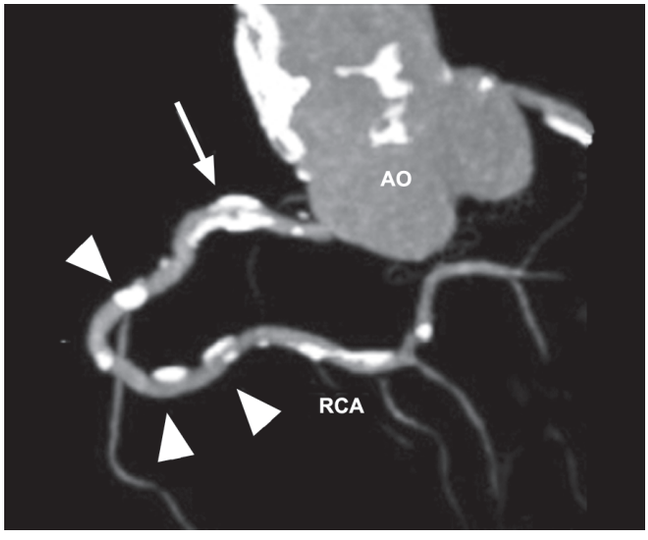

Fig. 2.26: A 58-year-old man with stable angina. Diffuse calcification (arrow and arrowheads) was detected in right coronary artery (RCA) on MDCT angiography maximum-intensity-projection (MIP) image. AO=aorta

In patients in whom Prinzmetal angina is suggested, provocative testing with ergonovine maleate during coronary angiography may be useful (Figs 2.24–2.32).

Optical coherence tomography in angina: It is an excellent investigation in the evaluation of ruptured plaque of stent complication in unstable angina and other complications in coronary artery disease (Figs 2.33 and 2.35).

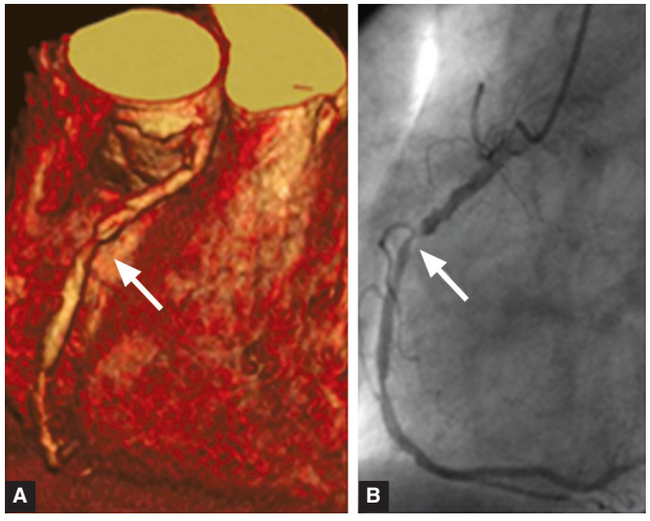

Fig. 2.27: Multislice computed tomography study. 3-D volumetric image (A) and angiographic image (B) showing occlusive stenosis in the right coronary artery (arrow)

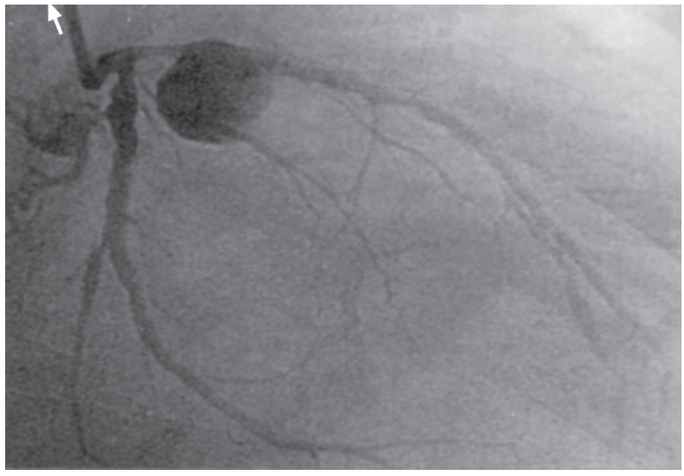

Fig. 2.28: Giant aneurysm proximal to stent and progression of lesion in LAD and LCx arteries in patient with persistent angia pectoris even after stentoplasty for the treatment of effort angia

MANAGEMENT OF ANGINA PECTORIS

Enhanced external counterpulsation (EECP): It is a non-invasive technique that reduces angina and extends time to exercise-induced myocardial ischemia in patients with symptomatic coronary disease (Figs 2.36 and 2.39). EECP uses the sequential inflation of 3 sets of pneumatic cuffs wrapped around the lower extremities. The cuffs are inflated sequentially (from calf to thigh to buttock) at the onset of diastole, producing aortic counterpulsation, diastolic augmentation, and increased venous return. At the onset of systole, the external pressure in the cuffs is released rapidly, producing a decrease in systolic pressure. It has been hypothesized that the sustained benefits of EECP result from effective diastolic augmentation that may promote collateral development or improve endothelial

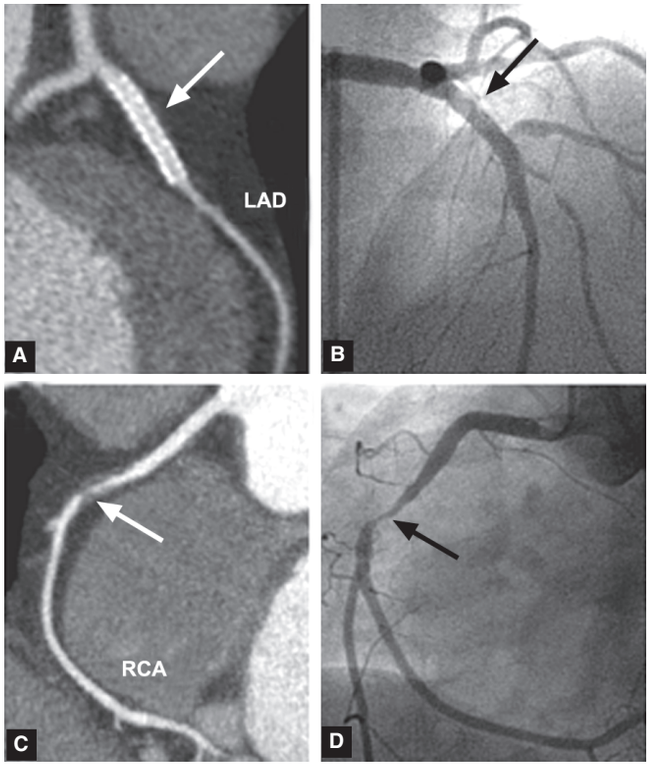

Fig. 2.29: MDCT and invasive angiographic findings in a 51-year-old woman with atypical chest pain and nondiagnostic stress test 7 months after anterior myocardial infarction and PCI to the left anterior descending (LAD) coronary artery. MDCT (A) and invasive angiography (B) showed patent LAD stent (arrow) but new soft noncalcified plaque (arrow), (C) in right coronary artery (RCA) causing severe RCA stenosis (C, D)

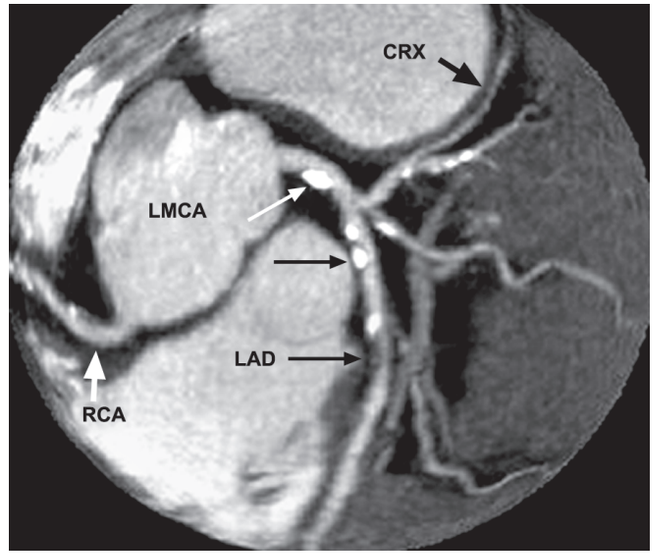

Fig. 2.30: A 72-year-old man with unstable angina pectoris shows several nonsignificant calcified plaques in left main and proximal left anterior descending (LAD) coronary arteries (dotted arrows) and significant heterogenous plaque in mid-left anterior descending coronary artery (solid arrows) that is causing 60% diameter stenosis detected on MDCT angiography maximum-intensity-projection (MIP) image

function. Most studies have shown that patients with higher levels of diastolic augmentation measured by finger plethysmography have improved early and late clinical outcomes.

In practice, EECP is limited to treating outpatients with chronic stable angina pectoris. Early external counter pulsation models involving a lower-extremity hydraulic water-compression system were shown to provide clinical benefit in a small sample of patients with either acute myocardial infarction or cardiogenic shock. Whether the acute hemodynamic effects of the sequential, pneumatic EECP device could benefit inpatients with these acute cardiac disorders is not known.

Measurements of the acute hemodynamic effects during EECP have been limited to noninvasive finger plethysmography, thoracic electrical bioimpedance methodology, echocardiography, right heart catheterization, and radial artery catheterization. Because the EECP cuffs cover the femoral site, invasive left heart catheterization or intracoronary hemodynamic studies during EECP have not been performed previously. The purpose of this study was to assess intracoronary, central aortic and cardiac hemodynamics during EECP and to determine whether these acute hemodynamic effects of EECP will have a favorable profile for patients with disorders such as acute coronary syndrome or cardiogenic shock. For this study, left heart catheterization and measurements of intracoronary pressure and Doppler flow velocity were performed from the right radial arterial site at baseline and during EECP.

Clinical indications of enhanced external electro-counterpulsation therapy:

1. Those who have been advised bypass surgery and choose not to have it.
2. Those who cannot afford the cost of bypass surgery.
3. Those who have other diseases which make them unfit for surgery, e.g. coexisting diabetes mellitus, bronchial asthma, kidney failure, rhyroid disorders, old age, i.e. more than 80 years.
4. Those who have already had bypass surgery done a few years earlier and don't want to suffer the experience again.
5. Those patients who cannot afford the exorbitant cost of angioplasty with two cipher stents.
6. Those patients who have chest pain or breathlessness of cardiac origin and do not wish to undergo any further investigation can go for EECP directly.
7. Patients whose stents have got blocked again.

Intra-aortic balloon counterpulsation: It can be used in patients who continue to have unstable angina pectoris despite maximal medical treatment (Fig. 2.40). This procedure should be followed promptly by coronary angiography with possible coronary revascularization.

In patients whose angina is refractory to medical therapy who are not suitable candidates for either percutaneous or surgical revascularization.

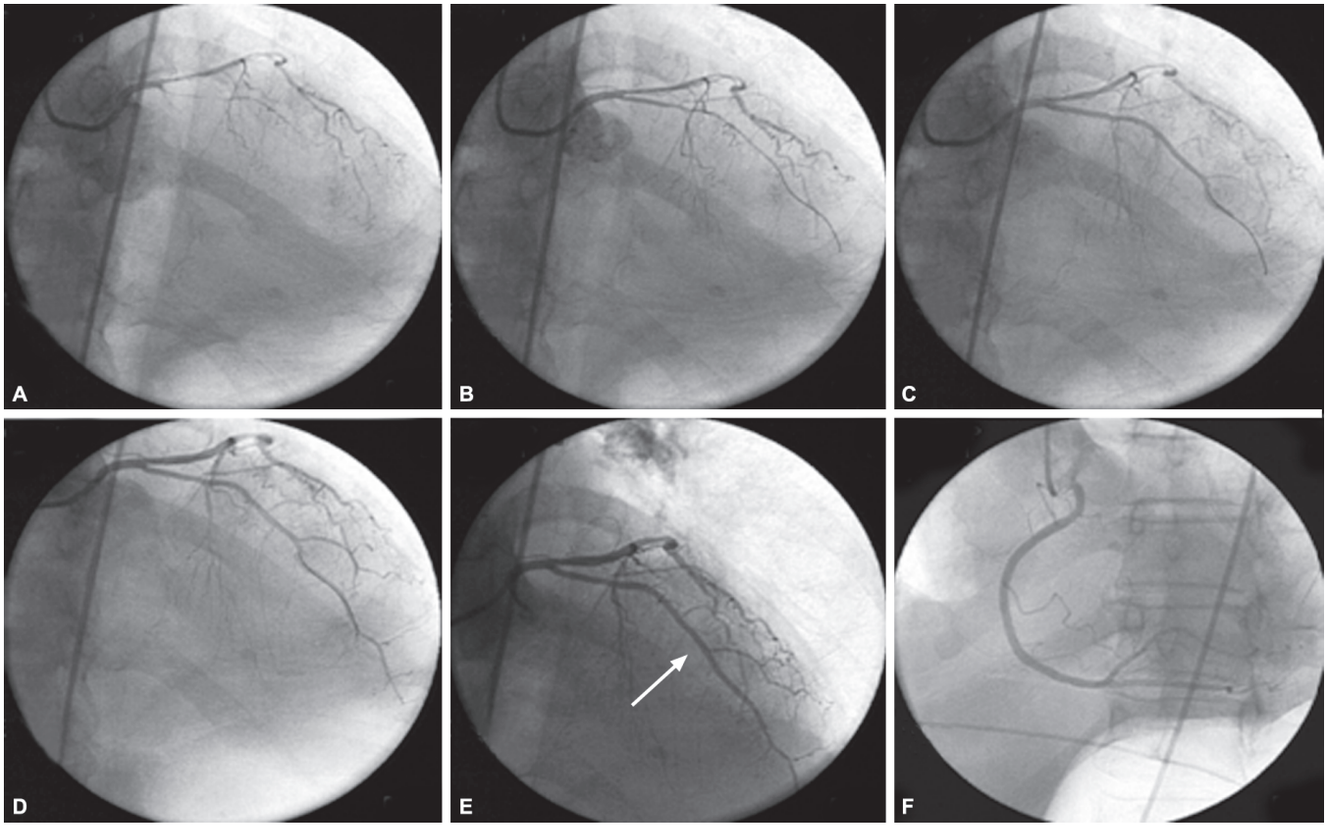

Fig. 2.31: Coronary vasospasm is a well-known cause of exercise-induced angina pectoris, Prinzmetal's unstable angina, and myocardial infarction. In general, the prognosis of patients with isolated coronary vasospasm is good, although in the setting of myocardial infarction, mechanical complications, such as free wall or interventricular septal rupture, malignant arrhythmias, and sudden death can occur

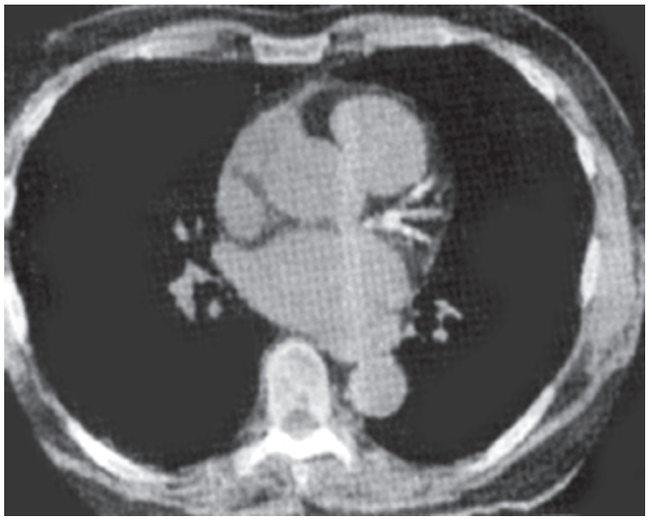

Fig. 2.32: MRI scan for coronary arteries showing significantly thickened and calcified major coronary vessels in patient with effort angina

Surgical Care

Revascularization therapy (i.e. coronary revascularization): It can be considered in patients with left main artery stenosis greater than 50%, 2- or 3-vessel disease and LV dysfunction (ejection fraction, <45%), poor prognostic signs during noninvasive studies, or severe symptoms despite maximum medical therapy (Fig. 2.41). The two main coronary revascularization procedures are percutaneous transluminal coronary angioplasty, with or without coronary stenting, and coronary artery bypass grafting.

Patients with 1- or 2-vessel disease and normal LV function, who have anatomically suitable lesions are candidates for percutaneous transluminal coronary angioplasty and coronary stenting. Restenosis is the major complication, with symptomatic restenosis occurring in 20–25% of patients. Restenosis mostly occurs during the first 6 months after the procedure and can be managed by repeat angioplasty. Several recent trials have demonstrated that the use of drug-eluting stents (e.g. sirolimus-eluting stents and paclitaxel-coated stents) can remarkably reduce the rate of in-stent restenosis. Recently, with the introduction of these drug-coated stents, patients with multivessel coronary artery disease are more frequently treated with percutaneous revascularization as opposed to the surgical revascularization.

Patients with single-vessel disease and normal ventricular function treated with percutaneous transluminal coronary angioplasty show improved exercise tolerance and fewer episodes of angina compared with those who receive medical treatment. However, no difference in the

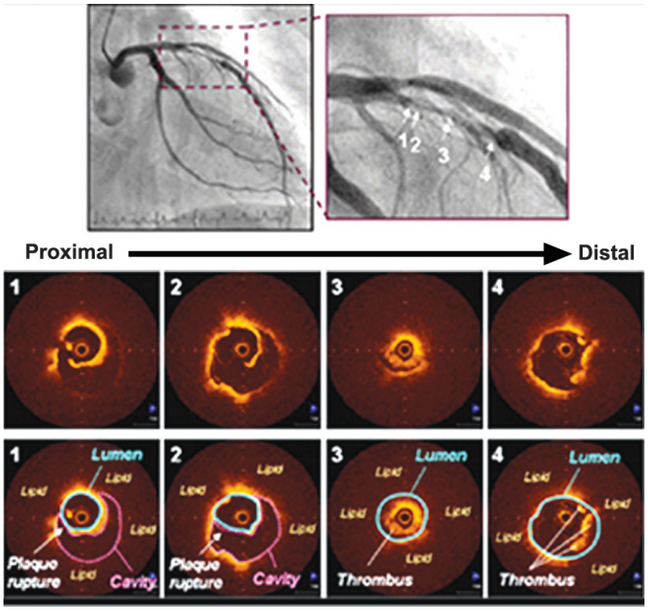

Fig. 2.33: Representative OCT images of plaque rupture in unstable angina pectoris. Angiography showed a complex lesion in the left anterior descending coronary artery. OCT revealed a plaque rupture with a residual fibrous-cap and plaque cavity (#1 and #2), and intracoronary thrombi (#3 and #4). Schemas demonstrate plaque rupture, lumen, ruptured cavity, lipid, and thrombi. Plaque rupture was observed at the minimal lumen area site [minimal lumen area = 1.83 mm^2 (#1); maximal ruptured cavity area = 3.26 mm^2 (#2)]. The plaque was considered to contain abundant lipid (number of lipid quadrants = 4). Thrombi occupied coronary lumen distal to the plaque rupture

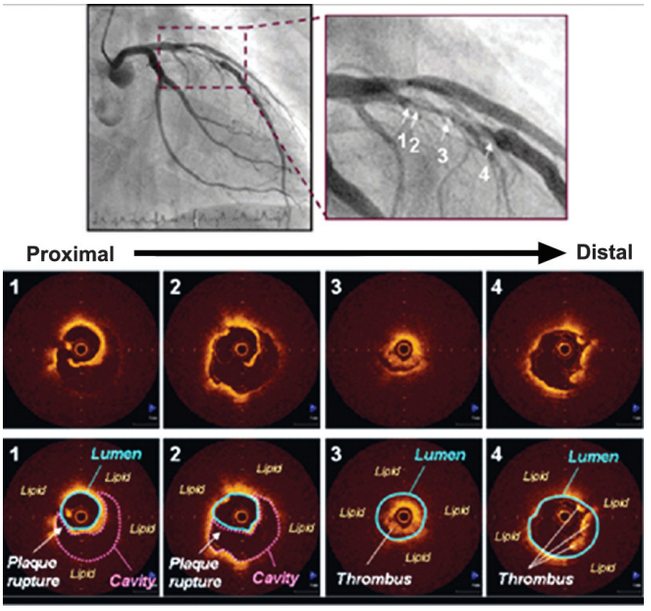

Fig. 2.34: Representative OCT images of plaque rupture in stable angina pectoris. Angiography showed an eccentric stenosis in the left anterior descending coronary artery. OCT revealed a plaque rupture with a residual fibrous-cap and plaque cavity (#1, #2 and #3). Schemas demonstrate plaque rupture, lumen, ruptured cavity, 3-layered coronary artery wall, lipid, and calcification. Plaque rupture was located proximally to the minimal lumen area site [maximal ruptured cavity area = 0.45 mm^2; (#2) minimal lumen area = 2.59 mm^2 (#4)]. The plaque contained lipdic tissue (number of lipid quadrants = 2) and calcium. Intracoronary thrombi were not detected in the lesion with plaque rupture

frequency of MI or death has been shown between these two groups.

Patients with significant left main coronary artery disease, 2- or 3-vessel disease and LV dysfunction, diabetes mellitus, or lesions anatomically unsuitable for percutaneous transluminal coronary angioplasty have better results with coronary artery bypass grafting. The overall operative mortality rate for coronary artery bypass grafting is approximately 1.3%. The rate of graft patency 10 years after surgery is less than 50% for vein grafting, although more than 90% of grafts using internal mammary arteries are patent at 10 years. In recent years, interest has increased regarding surgery without cardiopulmonary bypass (i.e. off-pump) in an attempt to avoid the morbidity associated with cardiopulmonary bypass. A recent randomized study demonstrated that off-pump coronary surgery was as safe as on-pump surgery and caused less myocardial damage. However, the graft-patency rate was lower at 3 months in the off-pump group than in the on-pump group.

Recently, laser transmyocardial revascularization has been used as an experimental therapy for the treatment of severe, chronic, stable angina refractory to medical or other therapies. This technique has been performed with either an epicardial surgical technique or by a percutaneous approach. In both approaches, a series of transmural endomyocardial channels are created to improve myocardial perfusion. The surgical transmyocardial revascularization technique has been associated with symptomatic relief for end-stage chronic angina in the short term. However, no published data address the long-term efficacy of surgical transmyocardial revascularization. Nonetheless, this technique appears to provide at least symptomatic relief for end-stage chronic angina in the short term (Fig. 2.42).

General measures: Smoking cessation results in a significant reduction of acute adverse effects on the heart and may reverse, or at least slow, atherosclerosis. Strongly encourage patients to quit smoking, and take an active role in helping them to achieve this goal. Treat risk factors, including hypertension, diabetes mellitus, obesity, and hyperlipidemia. Several clinical trials have shown that in patients with established coronary artery disease, reduction of low-density lipoprotein (LDL) level with a beta-hydroxy-beta-methylglutaryl coenzyme A reductase inhibitor (i.e. statin) is associated with significant reductions in both mortality rate and major cardiac events. These benefits are present even in patients with mild-to-moderate elevations of LDL cholesterol level.

Diet: A diet low in saturated fat and dietary cholesterol is the mainstay of the step I and step II diet from the American Heart Association.

Activity: The level of activity that aggravates anginal symptoms is different for each patient. However, most

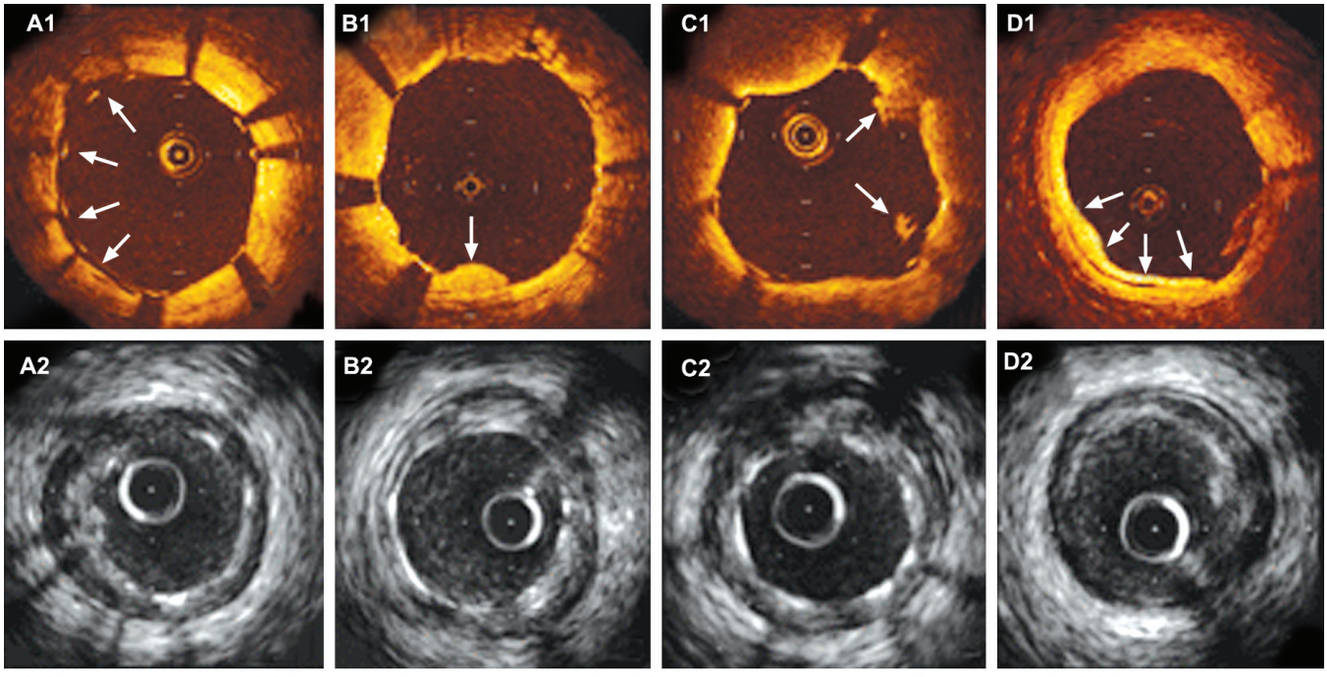

Fig. 2.35: Representative OCT images of stented lesions after PCI and corresponding IVUS images. (A1) OCT-visualized inadequate stent strut apposition (arrows). (A-2) It was not shown clearly on IVUS. (B1) Tissue protrusion between stent struts was observed in OCT image (arrow). (B2) It was not evident in the IVUS image. (C1) Intracoronary thrombi were identified as intraluminal mass images with signal-free shadow by OCT (arrows). (C2) They were not detected by IVUS. (D1) Coronary dissection at the site of stent edge was demonstrated by OCT (arrows). (D2) IVUS documented dissection (5 o'clock) and clot (2 o'clock). IVUS=intravascular ultrasound; OCT=optical coherence tomography; PCI=percutaneous coronary intervention

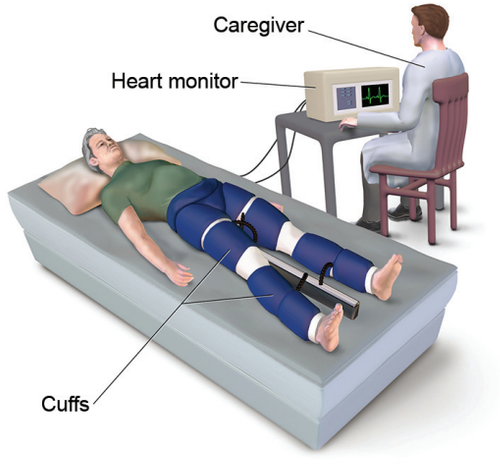

Fig. 2.36: Patient with chronic angina pectoris has been connected with EECP equipment ready to perform the application. Patient receives treatment of 1 hour daily for 35 days course

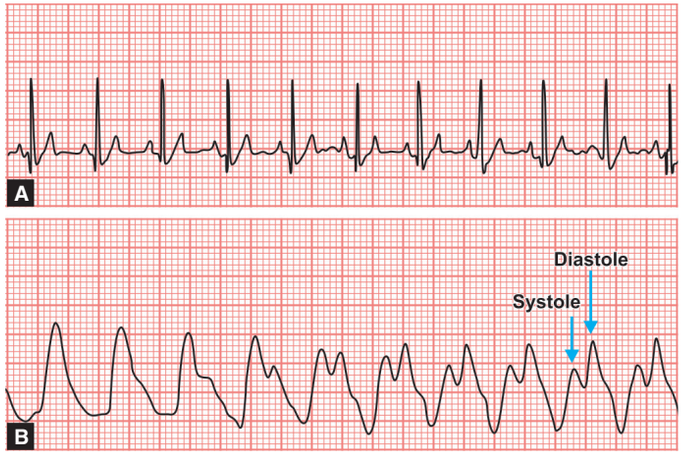

Fig. 2.37: Electrocardiogram (A) and finger plethysmographic recording (B) after initiation of enhanced external counterpulsation (EECP). Enhanced external counterpulsation leads to an increase in diastolic pressure (diastolic augmentation) and a decrease in systolic pressure (systolic unloading). The magnitude of EECP-induced hemodynamic changes is commonly assessed by measuring the diastolic-to-systolic effectiveness ratio, which is calculated by dividing the peak diastolic amplitude by the peak systolic amplitude of the finger plethysmographic signal

patients with stable angina can avoid symptoms during daily activities simply by reducing the speed of activity.The goals of pharmacotherapy are to reduce morbidity and to prevent complications.

Medical Care

The main goals of treatment in angina pectoris are to relieve the symptoms, slow the progression of disease, and reduce the possibility of future events, especially MI and premature death.

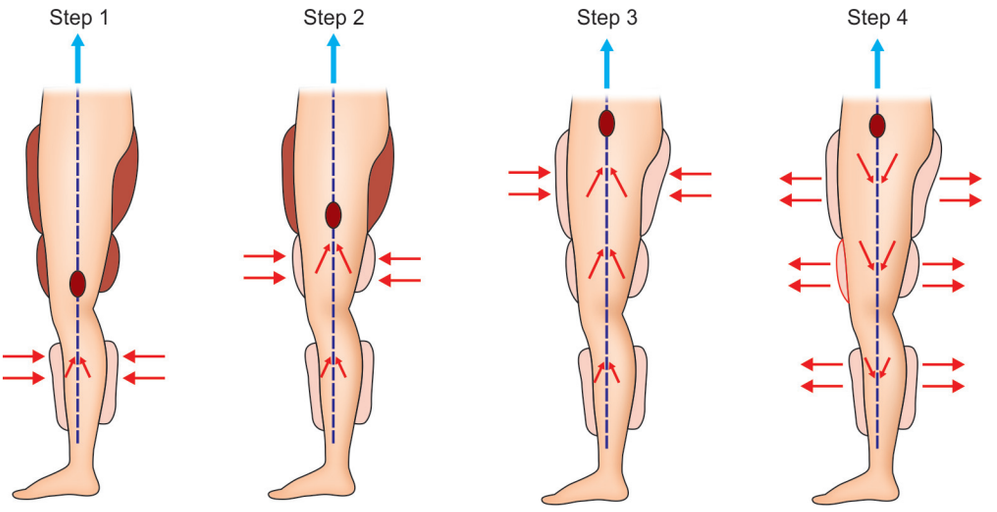

Fig. 2.38: Technique of EECP—three pairs of pneumatic cuffs are applied to the calves, lower thighs and upper thighs. The cuffs are inflated sequentially during diastole, distal to proximal. The compression of the lower-extremity vascular bed increases diastolic pressure and flow, and increases venous return. The pressure is then released at the onset of systole. Inflation and deflation are timed according to the R-wave on the patient's cardiac monitor. The pressures applied and the inflation–deflation timing can be altered by using the pressure waveforms and electrocardiogram on the enhanced external counterpulsation (EECP) therapy monitor

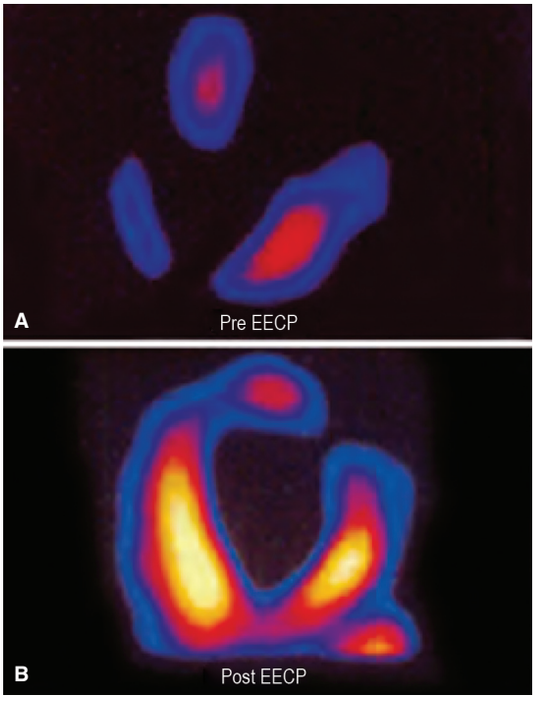

Fig. 2.39: (A) Nuclear scan prior to the application of EECP and (B) improvement in angina patient after the application of EECP

Recent trials with cholesterol-lowering agents have confirmed the benefits of the therapeutic LDL lowering in older persons.

Angiographic studies demonstrate that a reduction of the LDL level in patients with coronary artery disease could cause slowing of progression, stabilization, or even regression of coronary artery lesions.

A recent study demonstrates a significant reduction of symptomatic myocardial ischemia in patients with unstable angina or non-Q-wave infarction with the administration of a statin during the early acute phase.

In a more recent study of 10,001 patients with stable coronary artery disease, an aggressive cholesterol-lowering approach with atorvastatin 80 mg daily (mean cholesterol level of 77 mg/dl) compared to a less-aggressive approach with atorvastatin 10 mg daily (mean cholesterol level of 101 mg/dl) resulted in a 2.2% absolute reduction and a 22% relative reduction in the occurrence of a first major cardiovascular event (define as death from coronary heart disease; nonfatal, non-procedure-related myocardial infarction; resuscitation from cardiac arrest; or fatal or nonfatal stroke). This occurred with a greater incidence of elevated aminotransferase levels with the aggressive cholesterol-lowering approach (1.2% vs 0.2%, $p<0.001$).

On the basis of several recent studies that have demonstrated the benefits of more aggressive LDL-lowering therapies in high-risk patients with coronary artery disease, the Committee of the National Cholesterol Education Program recently made the following modifications to the Adult Treatment Panel III (ATP III) guidelines. In high-risk patients, a serum LDL cholesterol level of less than 100 mg/dl is the goal.

In very high-risk patients, an LDL cholesterol level goal of less than 70 mg/dl is a therapeutic option. Patients in the category of very high risk are those with established coronary artery disease with one of the following:

- Multiple major risk factors (especially diabetes)
- Severe and poorly controlled risk factors (especially continued cigarette smoking)
- Multiple risk factors of the metabolic syndrome (especially high triglyceride levels ≥200 mg/dl plus non-

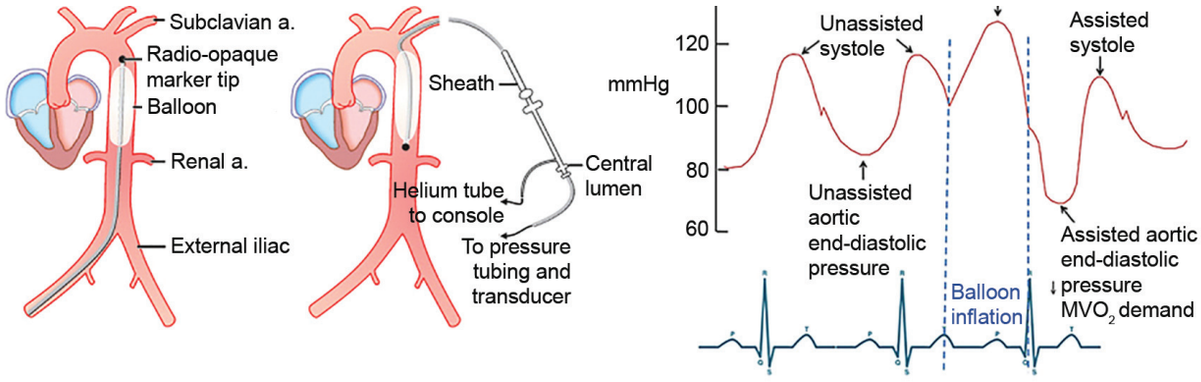

Fig. 2.40: Illustrations showing application of intra-aortic balloon counterpulsation in the tratment of unstable angina

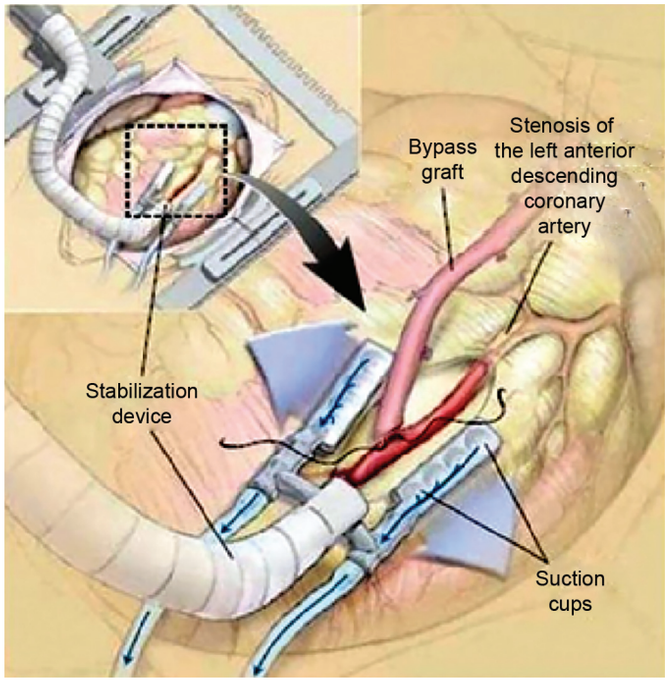

Fig. 2.41: Bypass graft to critically stenosed LAD in a patient with exercise stress positive test

HDL cholesterol level ≥130 mg/dl with low HDL cholesterol level <40 mg/dl)

- Patients with acute coronary syndromes.

For moderately high-risk persons (2+ risk factors), the recommended LDL cholesterol level is <130 mg/dl, but an LDL cholesterol level of 100 mg/dl is a therapeutic option. Some triglyceride-rich lipoproteins, including partially degraded very LDL levels, are believed to be independent risk factors for coronary artery disease. In daily practice, non-HDL cholesterol level (i.e. LDL + very LDL cholesterol [total cholesterol-HDL cholesterol]) is the most readily available measure of the total pool of these atherogenic lipoproteins. Thus, the ATP III has identified non-HDL cholesterol level as a secondary target of therapy in persons with high triglyceride levels (>200 mg/dl). The goal for non-HDL cholesterol level (for persons with serum triglyceride levels >200 mg/dl) is 30 mg/dl higher than the identified.

LDL cholesterol level goal. Patients with established coronary disease and low HDL/cholesterol levels are at high risk for recurrent events and should be targeted for aggressive nonpharmacological (i.e. dietary modification, weight loss, physical exercise) and pharmacological treatment.

A recent study demonstrated that in patients with established coronary artery disease who have low HDL and low-risk LDL levels, drug therapy with medications that raise HDL cholesterol levels and lower triglyceride levels but have no effect on LDL cholesterol levels (e.g. gemfibrozil) could significantly reduce the risk of major cardiac events.

Currently, the accepted approach to the management of patients with coronary artery disease and low HDL levels is as follows.

In all persons with low HDL cholesterol levels, the primary target of therapy is to achieve the ATP III guideline LDL cholesterol level goals with diet, exercise, and drug therapy as needed. After reaching the targeted LDL level goal, emphasis shifts to other issues. That is, in patients with low HDL cholesterol levels, who have associated high triglyceride levels (>200 mg/dl), the secondary priority is to achieve the non-HDL cholesterol level goal of 30 mg/dl higher than the identified LDL cholesterol level goal. In patients with isolated low HDL cholesterol levels (triglycerides <200 mg/dl), drugs to raise the HDL cholesterol level (e.g. gemfibrozil and nicotinic acid) can be considered. Exercise training results in improvement of symptoms, increase in the threshold of ischemia, and improvement of patients' sense of well-being. However, before enrolling a patient in an exercise-training program, perform an exercise tolerance test to establish the safety of such a program. Consider enteric-coated aspirin at a dose of 80–325 mg/day for all patients with stable angina, who have no contraindications to its use. In patients in whom aspirin cannot be used because of allergy or gastrointestinal complications, consider clopidogrel. Although, early observational studies suggested a cardiovascular protective effect with the use of hormone replacement therapy, recent large randomized trials failed to demonstrate any benefit with hormone replacement therapy in the primary or secondary prevention of cardiovascular disease.

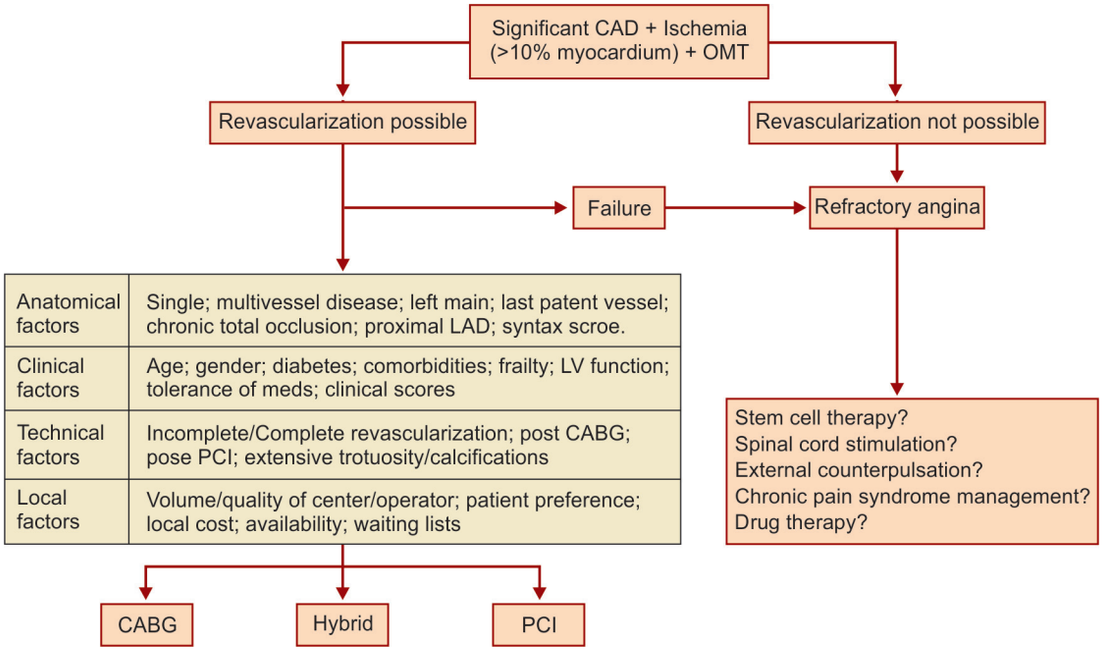

Fig. 2.42: Indications of revascularization therapy

In fact, these studies even demonstrated an increased risk of coronary artery disease and stroke in patients on hormone replacement therapy.

The women's health initiative study demonstrated that the use of hormone replacement therapy for 1 year in 10,000 healthy postmenopausal women is associated with 7 more instances of coronary artery disease, 8 more strokes, 8 more pulmonary emboli, 8 more invasive breast cancers, 5 fewer hip fractures, and 6 fewer colorectal cancers.

Based on these data, the risks and benefits of hormone replacement therapy must be assessed on an individual basis for each patient.

Sublingual nitroglycerin: It has been the mainstay of treatment for angina pectoris. Sublingual nitroglycerin can be used for acute relief of angina and prophylactically before activities that may precipitate angina. No evidence indicates that long-acting nitrates improve survival in patients with coronary artery disease.

Beta-blockers: These are also used for symptomatic relief of angina and prevention of ischemic events. They work by reducing myocardial oxygen demand and by decreasing the heart rate and myocardial contractility. Beta-blockers have been shown to reduce the rates of mortality and morbidity following acute MI.

Long-acting calcium channel blockers can be used to control anginal symptoms in patients with a contraindication to beta-blockers and in those in whom symptomatic relief of angina cannot be achieved with the use of beta-blockers, nitrates, or both. Avoid short-acting dihydropyridine calcium channel blockers because they have been shown to increase the risk of adverse cardiac events.

Anginal symptoms in patients with Prinzmetal angina can be treated with calcium channel blockers with or without nitrates. In one study, supplemental vitamin E added to a calcium channel blocker significantly reduced anginal symptoms among such patients.

In patients with syndrome X and hypertension, angiotensin converting enzyme (ACE) inhibitors may normalize thallium perfusion defects and increase exercise capacity.

Antianginal Pharmacology

Antiplatelet agents: Prevent thrombus formation by inhibiting platelet aggregation. Aspirin is proven beneficial in primary and secondary prevention of coronary artery disease. In patients with aspirin intolerance, use clopidogrel. Clopidogrel is also used in combination with aspirin after coronary stent placement. Recently, clopidogrel use in addition to aspirin has been shown to be significantly superior to aspirin alone in patients with acute coronary syndrome without ST-segment elevation MI.

Aspirin (bayer, empirin and anacin): Prevents platelet aggregation by irreversible cyclooxygenase inhibition with subsequent suppression of thromboxane A2. Antiplatelet effects can last as along as 7 days.

Adult dose: 81–325 mg PO qd

Clopidogrel (plavix): Selectively inhibits ADP binding to platelet receptor and subsequent ADP-mediated activation of GPIIb/IIIa complex, thereby inhibiting platelet aggregation. Consider in patients with contraindication to aspirin.

Adult dose: 75 mg PO qd

Beta-adrenergic blocking agents: These work by competing with endogenous catecholamines for beta-adrenergic receptors. Reduce myocardial oxygen consumption via several effects, including decrease in resting and exercise heart rates and reductions in myocardial contractility and afterload. Classified as non-selective, beta-1 selective and having intrinsic sympathomimetic effects.

Metoprolol (lopressor, toprol XL): Selective beta-1 adrenergic receptor blocker that decreases automaticity of contractions. It is lipophilic and penetrates CNS.

Adult dose: 50–200 mg PO bid

Atenolol (tenormin): It selectively blocks beta-1 receptors with little or no effect on beta-2 receptors. It is hydrophilic and does not penetrate CNS.

Adult dose: 50–200 mg PO qd

Propranolol (inderal): Non-selective beta-blocker that is lipophilic (penetrates CNS). Although, generally short-acting agent, long-acting preparations also available.

Adult dose: Immediate release: 40–160 mg PO bid
Sustained release: 60–320 mg PO qd

Calcium channel blockers: They reduce transmembrane flux of calcium via calcium channels. Cause smooth muscle relaxation, resulting in peripheral arterial vasodilation and afterload reduction. Indicated when symptoms persist despite treatment with beta-blockers or when beta-blockers are contraindicated. Also indicated in patients with Prinzmetal angina with or without nitrates.

Amlodipine (Norvasc): During depolarization, inhibits calcium ions from entering slow channels and voltage-sensitive areas of vascular smooth muscle and myocardium.

Adult dose: 5–10 mg PO qd

Diltiazem (cardizem CD, dilacor): During depolarization, inhibits calcium ions from entering slow channels and voltage-sensitive areas of vascular smooth muscle and myocardium.

Adult dose: Immediate release (IR): 120–360 mg PO divided tid/qid
Sustained release (SR): 120–480 mg PO qd

Verapamil (calan, covera): During depolarization, inhibits calcium ion from entering slow channels or voltage-sensitive areas of vascular smooth muscle and myocardium.

Adult dose: Immediate release: 80–120 mg PO tid/qid
Sustained release: 120–240 mg PO qd/bid

Short-acting nitroglycerins: Suitable for immediate relief of exertional or rest angina. Can also be used for prophylaxis several minutes before planned exercise to avoid angina. Reduce myocardial oxygen demand by reduction of LV and arterial pressure, primarily by reducing preload.

Nitroglycerin (nitrostat, nitro-bid, nitrol): It causes relaxation of vascular smooth muscle by stimulating intracellular cyclic GMP production. Result is decrease in BP.

Adult dose: 0.3–0.6 mg SL prn 0.4 mg metered-dose spray PO prn 0.1–0.8 mg/h patch TD qd 1

Long-acting nitroglycerins: These reduce LV preload and afterload by venous and arterial dilation, which subsequently reduces myocardial oxygen consumption and relieves angina. Also cause dilation of epicardial coronary arteries, which is beneficial in patients with coronary spasm. In addition, nitroglycerin has antithrombotic and anti-platelet effects in patients with angina pectoris. No evidence suggests that nitrates improve survival or slow progression of coronary artery disease.

Isosorbide [isordil, isosorbide mononitrate (ISMO)]: It relaxes vascular smooth muscle by stimulating intracellular cyclic guanosine monophosphate (GMP). Decreases LV pressure (i.e. preload) and arterial resistance (i.e. afterload). Reduces cardiac oxygen demand by decreasing LV pressure and dilating arteries.

Adult dose: *Isosorbide dinitrate:* 2.5–10 mg SL prn IR 10–30 mg PO bid/tid SR 80–120 mg PO qd.
Isosorbide mononitrate: 10–20 mg PO bid SR 30–120 mg PO qd

Angiotensin-converting enzyme inhibitors: Recently, shown to reduce rates of death, MI, stroke and need for revascularization procedures in patients with coronary artery disease or diabetes mellitus and at least one other cardiovascular risk factor, irrespective of the presence of hypertension or heart failure.

Ramipril (altace): Prevents conversion of angiotensin I to angiotensin II, a potent vasoconstrictor, resulting in lower aldosterone secretion.

Adult dose: 2.5–5 mg PO qd not to exceed 20 mg/d

Anti-ischemic agents, miscellaneous: Ranolazine elicits action unlike beta-blockers, calcium antagonists, or nitrates. It does not affect hemodynamics or contractile and conduction parameters.

Ranolazine (Ranexa): Cardioselective anti-ischemic agent (piperazine derivative) that partially inhibits fatty acid oxidation. Also inhibits late sodium current into myocardial cells and prolongs QTc interval. Indicated for chronic angina unresponsive to other antianginal treatments. Used in combination with amlodipine, beta-blockers, or nitrates. Unlike beta-blockers, calcium channel blockers and nitrates, does not reduce blood pressure or heart rate. Effect on angina rate or exercise tolerance appears to be smaller in women than in men. Absorption is highly variable but unaffected by food.

Adult dose: 500 mg PO bid initially; if necessary, may increase to 1000 mg PO bid

Contraindications: Documented hypersensitivity; pre-existing QT prolongation; hepatic impairment [Child-Pugh class A (mild), B (moderate), or C (severe)]; QT-prolonging drugs (see interactions); potent or moderate CYP4503A inhibitors (e.g. ketoconazole and diltiazem).

Interactions: CYP4503A and P-gp substrate; potent CYP3A inhibitors (e.g. ketoconazole at 200 mg bid) increase levels approximately 3.2-fold, moderate CYP3A inhibitors (e.g. diltiazem at 180–360 mg/day) increase levels approximately 1.8- to 2.3-fold, and verapamil (a CYP3A and P-gp inhibitor) increases levels approximately 2-fold; caution with other P-gp inhibitors (e.g. ritonavir, cyclosporine); toxicity may occur when coadministered with other drugs that increase QTc interval (e.g. class I and III antiarrhythmic agents, certain macrolide and quinolone antibiotics, phenothiazines, TCAs). Inhibits CYP4503A, CYP 4502D6, and P-gp; may increase plasma levels of digoxin, simvastatin, dextromethorphan, TCAs, and antipsychotics.

Precautions: Causes dose-related QTc-interval prolongation (obtain baseline and follow-up ECGs to monitor for torsades de pointes and potential for sudden death; mild and moderate hepatic impairment increases QTc interval compared with normal hepatic function at the same plasma level; increases blood pressure by approximately 15 mmHg in persons with severe renal impairment; common adverse effects include dizziness, headache, constipation, and nausae.

Prevention: Coronary atherosclerosis is the main preventable cause of mortality in the United States. A rigorous effort to address correctable risk factors is the mainstay of preventive cardiovascular medicine. Smoking cessation is the single most effective preventive intervention to reduce coronary atherosclerosis prevalence. It has been associated with a coronary artery disease reduction of 7–47% in primary prevention settings.

- Aggressive treatment of diabetes mellitus, hypertension, LV hypertrophy, hyperlipidemia, and obesity has an important role in the prevention of coronary artery disease.
- The most important recent development in coronary atherosclerosis risk modification is the introduction of inhibitors of beta-hydroxy-beta-methylglutaryl coenzyme A reductase. Reductions of total and LDL cholesterol levels by 25% and 35%, respectively, can achieve a similar reduction in rates of total and coronary mortality, MI, and need for coronary revascularization.

Optimal medical therapy for stable coronary artery disease versus PCI or CABG (STICH Trial 2011):

Medical, percutaneous interventional and surgical treatments for the management of coronary heart disease have progressed markedly during the past decade. There is evidence to suggest that for patients with stable coronary heart disease optimal medical therapy is equal in effectiveness for lowering the risk of major cardiovascular events, such as cardiovascular death, myocardial infarction, and stroke, as are revascularization procedures, such as coronary artery bypass grafting or percutaneous coronary intervention. The landmark surgical treatment for ischemic heart failure (STICH) trial found no significant difference between medical therapy alone and medical therapy plus coronary artery bypass grafting with respect to the primary end point of death from any cause (all-cause mortality). However, secondary outcomes showed fewer deaths from cardiovascular causes in the surgical group versus the medical group. Medical therapy has improved over time, as have surgical techniques including myocardial preservation, and both approaches have their place, especially since chest pain relief and quality of life may benefit more in some cases by revascularization. Certainly, coronary artery bypass grafting has general acceptance for three-vessel coronary heart disease, and percutaneous coronary artery intervention is the standard of care for the involved artery in acute ST-segment elevation myocardial infarction when the intervention can be accomplished rapidly. Medical management includes lifestyle changes that benefit coronary heart disease, drug therapy to improve prognosis, and drug therapy to improve symptoms. The key to clinical management is the selection of the procedure and/or medical management strategy that is in the best interest of the individual cardiovascular patient. In addition, discussing with patients their options and considering what best fits their wishes is especially critical when there is no clear-cut best strategy. Continued collaboration between cardiologists concentrating on medical approaches with interventionists and cardiac surgeons (heart team approach) is essential for optimal management for each individual patient.

The abstract of complete results of FAME II Study revealed that in patients with stable coronary artery disease and at least one stenosis with a fraction flow reserve (FFR) <0.80, optimal medical therapy (OMT) alone was associated with a more than fourfold larger hazard of major adverse cardiac events than FFR-guided percutaneous coronary intervention (PCI) with drug-eluting stents plus OMT. This difference was driven by a difference in unplanned hospitalization with urgent revascularisation. In contrast, in patients with hemodynamically non-significant stenoses (FFR >0.80), OMT alone was associated with a favorable clinical outcome (Table 2.6).

Complications: Complications of angina pectoris include unstable angina, MI, and death.

Prognosis: Important prognostic indicators in patients with angina pectoris include LV function, severity and location of atherosclerotic lesions, and response of symptoms to medical treatment.

Left ventricular function is the strongest predictor of long-term survival. Elevated LV end-diastolic pressure and volume along with reduced LV ejection fraction (<40%) are poor prognostic signs.

Critical lesions of left main and proximal left anterior descending coronary arteries are associated with a greater risk. Mortality rates are also directly associated with the number of epicardial arteries involved.

Unstable angina, recent MI, or both is a sign of atherosclerotic plaque instability, which is a strong predictor of increased risk of short-term coronary events.

A number of signs during noninvasive testing is predictive of a higher risk of coronary events, including ST-segment depression of more than 2 mm at a low workload, ST-segment depression that persists for more

Table 2.6: Indications for diagnostic testing in patients with suspected CAD and stable symptoms

	Asymptomatic[a]		*Smptomatic*					
			Probability of significant disease[b]					
			Low (<15%)		Intermediate (15–85%)		High (>85%)	
	Class[c]	Level[d]	Class[c]	Level[d]	Class[c]	Level[d]	Class[c]	Level[d]
Anatomical detection of CAD								
Invasive angiography	**III**	**A**	**III**	**A**	**IIb**	**A**	**I**	**A**
CT angiography[e]	**III**	**B**	**III**	**C**	**IIa**	**A**	**III**	**B**
Functional test								
Stress echo	**III**	**A**	**III**	**A**	**I**	**A**	**III**	**A**
Nuclear imaging	**III**	**A**	**III**	**A**	**I**	**A**	**III**	**A**
Stress MRI	**III**	**B**	**III**	**C**	**I**	**A**	**III**	**B**
PET perfusion	**III**	**B**	**III**	**C**	**I**	**A**	**III**	**B**
Combined or hybrid imaging test								
	III	**C**	**III**	**C**	**IIa**	**B**	**III**	**B**

a = In asymptomatic patients, the decision will be guided by the extent of ischemia on stress testing; b = with documented ischemia or FFR <0.80 for angiographic diameter stenoses 50–90%; c = as assessed by noninvasive test (SPECT, MRI and stress echocardiography); d =class of recommendation; e =level of evidence. (Adapted from 2013 ESC guidelines on the management of stable coronary artery disease)

than 5 minutes after termination of exercise, and failure of blood pressure to rise or an actual drop in blood pressure.

- Patients who continue to smoke after MI have a 22–47% increased risk of reinfarction and death.
- In general, Prinzmetal angina and syndrome X are associated with excellent long-term prognoses.

Patient education: Educating patients about the benefits of smoking cessation, a low-cholesterol diet, physical activity, and periodic screening for diabetes mellitus and hypertension is the prime component of a long-term management plan.

Medical/Legal Pitfalls

- In patients with stable angina pectoris, even the most carefully performed history and physical examination have limitations. Classification of these patients solely on the basis of history and physical examination findings may lead to serious mistakes. Some type of stress testing is usually indicated to confirm the diagnosis and quantitate the severity of ischemia.
- In women, elderly persons, and diabetic patients, coronary artery disease may manifest with atypical presentations other than angina pectoris, such as silent ischemia or infarction. Physicians should use a careful approach when evaluating these patients.

KEY POINTS

- Angina pectoris occurs when cardiac workload exceeds the ability of coronary arteries to supply an adequate amount of oxygenated blood.
- Symptoms of stable angina pectoris range from a vague, barely troublesome ache to a severe, intense precordial crushing sensation; they are typically precipitated by exertion, last no more than a few minutes, and subside with rest.
- Do stress testing with ECG for patients with normal resting ECG or with myocardial imaging (e.g. echocardiography, radionuclide imaging, and MRI) for patients with abnormal resting ECG.
- Do coronary angiography when revascularization (percutaneous intervention or coronary artery bypass grafting) is being considered.
- Give nitroglycerin for immediate relief of angina.
- Maintain patients on an antiplatelet drug, a β-blocker, and a statin, and add a Ca channel blocker for further symptom prevention if needed.
- Consider revascularization if significant angina persists despite drug therapy or if lesions noted during angiography indicate high risk of mortality.

BIBLIOGRAPHY

1. Allen KB, Dowling RD, Fudge TL, et al. Comparison of transmyocardial revascularization with medical therapy in patients with refractory angina. N Engl J Med 1999;341(14): 1029–36.
2. Ambrosio G, Betocchi S, Pace L, et al. Prolonged impairment of regional contractile function after resolution of exercise-induced angina. Evidence of myocardial stunning in patients with coronary artery disease. Circulation 1996; 94(10):2455–64.
3. Anderson HV. Angiotensin-converting enzyme inhibitors: ischemia is not the correct measure of benefit. J Am Coll Cardiol 2003;42(12):2060–2.
4. Arora RR, Chou TM, Jain D, et al. The multicenter study of enhanced external counterpulsation (MUST-EECP): effect of EECP on exercise-induced myocardial ischemia and anginal episodes. J Am Coll Cardiol 1999;33(7):1833–40.
5. Borden WB, Redberg RF, Mushlin AI, et al. Patterns and Intensity of Medical Therapy in Patients Undergoing Percutaneous Coronary Intervention. JAMA 2011;305:1882–9.
6. Brown G, Albers JJ, Fisher LD, et al. Regression of coronary artery disease as a result of intensive lipid-lowering therapy in men with high levels of apolipoprotein B. N Engl J Med 1990;323(19):1289–98.
7. Califf RM, Armstrong PW, Carver JR, et al. 27th Bethesda Conference: matching the intensity of risk factor management with the hazard for coronary disease events. Task Force 5. Stratification of patients into high, medium and low risk subgroups for purposes of risk factor management. J Am Coll Cardiol 1996;27(5):1007–19.
8. Cannon CP, Braunwald E, McCabe CH, et al. Intensive versus moderate lipid lowering with statins after acute coronary syndromes. N Engl J Med 2004;350(15):1495–504.
9. Chauhan A, Mullins PA, Taylor G, et al. Both endothelium-dependent and endothelium-independent function is impaired in patients with angina pectoris and normal coronary angiograms. Eur Heart J 1997;18(1):60–8.
10. Connolly DC, Elveback LR, Oxman HA. Coronary heart disease in residents of Rochester, Minnesota. IV. Prognostic value of the resting electrocardiogram at the time of initial diagnosis of angina pectoris. Mayo Clin Proc 1984;59(4): 247–50.
11. Crea F, Pupita G, Galassi AR, et al. Role of adenosine in pathogenesis of anginal pain. Circulation 1990;81(1):164–72.
12. de Bruyne B, Pijls NH, Kalesan B, et al. Fractional flow reserve-guided PCI versus medical therapy in stable coronary disease. N Eng J Med 2012;367:991–1001.
13. Deedwania PC, Carbajal EV. Silent ischemia during daily life is an independent predictor of mortality in stable angina. Circulation 1990;81(3):748–56.
14. Frileux S, Munoz Sastre MT, Mullet E, et al. The impact of the preventive medical message on intention to change behavior. Patient Educ Couns 2004;52(1):79–88.
15. Gibbons RJ, Abrams J, Chatterjee K, et al. ACC/AHA 2002 guideline update for the management of patients with chronic stable angina—summary article: a report of the American College of Cardiology/American Heart Association Task Force on practice guidelines (Committee on the Management of Patients. J Am Coll Cardiol 2003;41(1): 159–68.
16. Gibbons RJ, Balady GJ, Bricker JT, et al. ACC/AHA 2002 guideline update for exercise testing: summary article: a report of the American College of Cardiology/American Heart Association Task Force on Practice.
17. Guidelines (Committee to Update the 1997 Exercise Testing Guidelines). Circulation 2002.;106(14):1883–92.
18. Grundy SM, Cleeman JI, Merz CN, et al. Implications of recent clinical trials for the National Cholesterol Education Program Adult Treatment Panel III Guidelines. J Am Coll Cardiol 2004;44(3):720–32.
19. Hamm CW, Bassand JP, Agewall S, et al. ESC Guidelines for the management of acute coronary syndromes in patients presenting without persistent ST-segment elevation: The Task Force for the management of acute coronary syndromes (ACS) in patients presenting without persistent ST-segment elevation of the European Society of Cardiology (ESC). Eur Heart J 2011;32:2999–3054.
20. Juul-Moller S, Edvardsson N, Jahnmatz B, et al. Double-blind trial of aspirin in primary prevention of myocardial infarction in patients with stable chronic angina pectoris. The Swedish Angina Pectoris Aspirin Trial (SAPAT) Group. Lancet 1992; 340(8833):1421–5.
21. Kannel WB, Feinleib M. Natural history of angina pectoris in the Framingham study. Prognosis and survival. Am J Cardiol 1972;29(2):154–63.
22. Kaski JC, Elliott PM, Salomone O, et al. Concentration of circulating plasma endothelin in patients with angina and normal coronary angiograms. Br Heart J 1995;74(6):620–4.
23. Kaski JC, Rosano G, Gavrielides S, et al. Effects of angiotensin-converting enzyme inhibition on exercise-induced angina and ST-segment depression in patients with microvascular angina. J Am Coll Cardiol 1994;23(3):652–7.
24. Khan NE, De Souza A, Mister R, et al. A randomized comparison of off-pump and on-pump multivessel coronary-artery bypass surgery. N Engl J Med 2004;350(1):21–8.
25. Kugiyama K, Yasue H, Okumura K, et al. Nitric oxide activity is deficient in spasm arteries of patients with coronary spastic angina. Circulation 1996;94(3):266–71.
26. Kuo L, Davis MJ, Chilian WM. Longitudinal gradients for endothelium-dependent and -independent vascular responses in the coronary microcirculation. Circulation 1995; 92(3):518–25.
27. Lacoste LL, Theroux P, Lidon RM, et al. Antithrombotic properties of transdermal nitroglycerin in stable angina pectoris. Am J Cardiol 1994.;73(15):1058–62.
28. Lanza GA, Giordano A, Pristipino C, et al. Abnormal cardiac adrenergic nerve function in patients with syndrome X detected by ^{123}I metaiodobenzylguanidine myocardial scintigraphy. Circulation 1997;96(3):821–6.
29. LaRosa JC, Grundy SM, Waters DD, et al. Intensive lipid lowering with atorvastatin in patients with stable coronary disease. N Engl J Med 2005;352(14):1425–35.
30. Margolis JR, Chen JT, Kong Y, et al. The diagnostic and prognostic significance of coronary artery calcification. A report of 800 cases. Radiology 1980;137(3):609–16.
31. Mark DB, Califf RM, Morris KG, et al. Clinical characteristics and long-term survival of patients with variant angina. Circulation 1984;69(5):880–8.

32. Maseri A, Crea F, Kaski JC, et al. Mechanisms and significance of cardiac ischemic pain. Prog Cardiovasc Dis 1992; 35(1):1–18.
33. Miwa K, Miyagi Y, Igawa A, et al. Vitamin E deficiency in variant angina. Circulation 1996;94(1):14–8.
34. Morice MC, Serruys PW, Sousa JE, et al. A randomized comparison of a sirolimus-eluting stent with a standard stent for coronary revascularization. N Engl J Med 2002;346(23): 1773–80.
35. National Cholesterol Education Program. Executive Summary of The Third Report of The National Cholesterol Education Program (NCEP) Expert Panel on Detection, Evaluation, And Treatment of High Blood Cholesterol In Adults (Adult Treatment Panel III). JAMA 2001;285(19):2486–97.
36. Ndrepepa G, Braun S, Mehilli J, et al. Prognostic value of sensitive troponin T in patients with stable and unstable angina and undetectable conventional troponin. Am Heart J 2011;161:68–75.
37. Norwegian Multicenter Study Group. Timolol-induced reduction in mortality and reinfarction in patients surviving acute myocardial infarction. N Engl J Med 1981;304(14): 801–7.
38. O'Keefe JH, Barnhart CS, Bateman TM. Comparison stress echocardiography and stress myocardial perfusion scintigraphy for diagnosing coronary artery disease and assessing its severity. Am J Cardiol 1995;75(11):25D–34D.
39. Oesterle SN, Sanborn TA, Ali N, et al. Percutaneous transmyocardial laser revascularisation for severe angina: the PACIFIC randomised trial. Potential Class Improvement From Intramyocardial Channels. Lancet 2000;356(9243): 1705–10.
40. Piatti P, Fragasso G, Monti LD, et al. Endothelial and metabolic characteristics of patients with angina and angiographically normal coronary arteries: comparison with subjects with insulin resistance syndrome and normal controls. J Am Coll Cardiol 1999;34(5):1452–60.
41. Ridker PM, Manson JE, Gaziano JM, et al. Low-dose aspirin therapy for chronic stable angina. A randomized, placebo-controlled clinical trial. Ann Intern Med 1991;114(10):835–9.
42. Rocco MB, Nabel EG, Campbell S, et al. Prognostic importance of myocardial ischemia detected by ambulatory monitoring in patients with stable coronary artery disease. Circulation 1988;78(4):877–84.
43. Rosano GM, Collins P, Kaski JC, et al. Syndrome X in women is associated with oestrogen deficiency. Eur Heart J 1995; 16(5):610–4.
44. Rossouw JE, Anderson GL, Prentice RL, et al. Risks and benefits of estrogen plus progestin in healthy postmenopausal women: principal results From the Women's Health Initiative randomized controlled trial. JAMA 2002;288(3):321–33.
45. Rubins HB, Robins SJ, Collins D, et al. Gemfibrozil for the secondary prevention of coronary heart disease in men with low levels of high-density lipoprotein cholesterol. Veterans Affairs High-Density Lipoprotein Cholesterol Intervention Trial Study Group. N Engl J Med 1999;341(6):410–8.
46. Scandinavian Simvastatin Survival Study Group. Randomised trial of cholesterol lowering in 4444 patients with coronary heart disease: the Scandinavian Simvastatin Survival Study (4S). Lancet 1994;344(8934):1383–9.
47. Schwartz GG, Olsson AG, Ezekowitz MD, et al. Effects of atorvastatin on early recurrent ischemic events in acute coronary syndromes: the MIRACL study: a randomized controlled trial. JAMA 2001;285(13):1711–8.
48. Sever PS, Dahlof B, Poulter NR, et al. Prevention of coronary and stroke events with atorvastatin in hypertensive patients who have average or lower-than-average cholesterol concentrations, in the Anglo-Scandinavian Cardiac Outcomes Trial—Lipid Lowering Arm (ASCOT-LLA): a multicentre randomi. Lancet 2003;361(9364):1149–58.
49. Shepherd J, Blauw GJ, Murphy MB, et al. Pravastatin in elderly individuals at risk of vascular disease (PROSPER): a randomised controlled trial. Lancet 2002; 360(9346):1623–30.

3 Recognition and Management of Acute Coronary Syndrome

Acute coronary syndrome (ACS) refers to a spectrum of clinical presentations ranging from those for ST-segment elevation myocardial infarction (STEMI) to presentations found in non-ST-segment elevation myocardial infarction (NSTEMI) or in unstable angina. In terms of pathology, ACS is almost always associated with rupture of an atherosclerotic plaque and partial or complete thrombosis of the infarct-related artery. Components of acute coronary syndrome are:

1. **ST-segment elevation myocardial infarction (STEMI)**
2. **Non-ST-segment elevation myocardial infarction (NSTEMI)**
3. **Unstable angina**

In some instances, however, stable coronary artery disease (CAD) may result in ACS in the absence of plaque rupture and thrombosis, when physiologic stress (e.g. trauma, blood loss, anemia, infection, tachyarrhythmia) increases demands on the heart. The diagnosis of acute myocardial infarction in this setting requires a finding of the typical rise and fall of biochemical markers of myocardial necrosis in addition to at least one of the following (Figs 3.1–3.3):

- Ischemic symptoms
- Development of pathologic Q-waves

Ischemic ST-segment changes on electrocardiogram (ECG) or in the setting of a coronary intervention. The terms *transmural* and *nontransmural* (subendocardial) myocardial infarction are no longer used because ECG findings in patients with this condition are not closely correlated with pathologic changes in the myocardium. Therefore, a transmural infarct may occur in the absence of Q-waves on ECGs, and many Q-wave myocardial infarctions may be subendocardial, as noted on pathologic examination. Because elevation of the ST-segment during ACS is correlated with coronary occlusion and because it affects



Fig. 3.1: Doctor examining a middle-aged patient admitted in ICCU with acute coronary syndrome in a stage of shock

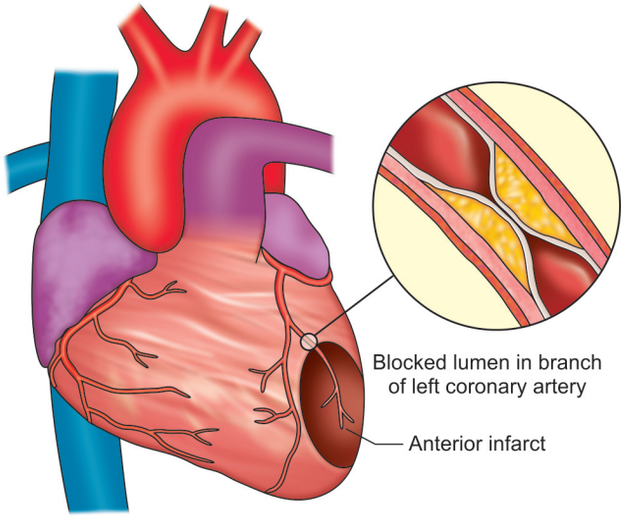

Fig. 3.2: Left ventricular infarct due to obstructed lumen of the left coronary artery

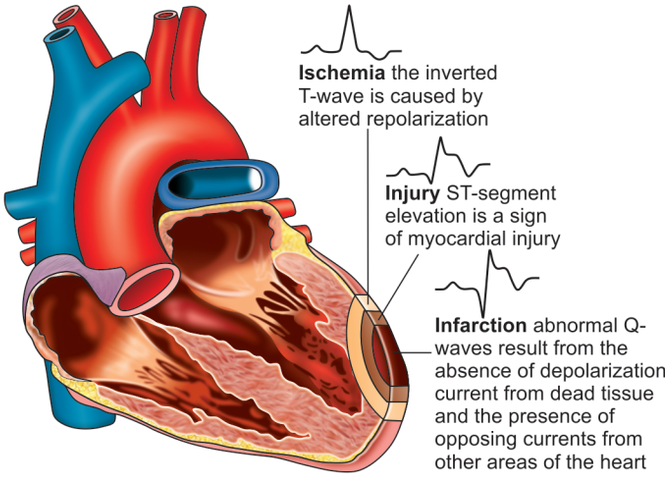

Fig. 3.3: Left ventricular infarct due to obstructed lumen of the left coronary artery (left) and ECG morphology showing various stages of ST- and T-waves changes in its resolution (right)

the choice of therapy (urgent reperfusion therapy), ACS-related myocardial infarction should be designated STEMI or NSTEMI.

Attention to the underlying mechanisms of ischemia is important when managing ACS. A simple predictor of demand is rate-pressure product, which can be lowered by beta blockers (e.g. metoprolol or atenolol) and pain/stress relievers (e.g. morphine), while supply may be improved by oxygen, adequate hematocrit, blood thinners (e.g. heparin, IIb/IIIa agents, such as abciximab, eptifibatide, tirofiban, or thrombolytics), and/or vasodilators (e.g. nitrates, amlodipine).

In 2010, the American Heart Association (AHA) published new guideline recommendations for the diagnosis and treatment of ACS.

Etiological Factors

Acute coronary syndrome is caused primarily by atherosclerosis. Most cases of ACS occur from disruption of a previously nonsevere lesion (an atherosclerotic lesion that was previously hemodynamically insignificant yet vulnerable to rupture). The vulnerable plaque is typified by a large lipid pool, numerous inflammatory cells, and a thin, fibrous cap.

Elevated demand can produce ACS in the presence of a high-grade fixed coronary obstruction, due to increased myocardial oxygen and nutrition requirements, such as those resulting from exertion, emotional stress, or physiologic stress (e.g. from dehydration, blood loss, hypotension, infection, thyrotoxicosis, or surgery).

Acute coronary syndrome without elevation in demand requires a new impairment in supply, typically due to thrombosis and/or plaque hemorrhage.

The major trigger for coronary thrombosis is considered to be plaque rupture caused by the dissolution of the fibrous cap, the dissolution itself being the result of the release of metalloproteinases (collagenases) from activated inflammatory cells. This event is followed by platelet activation and aggregation, activation of the coagulation pathway, and vasoconstriction. This process culminates in coronary intraluminal thrombosis and variable degrees of vascular occlusion. Distal embolization may occur. The severity and duration of coronary arterial obstruction, the volume of myocardium affected, the level of demand on the heart, and the ability of the rest of the heart to compensate are major determinants of a patient's clinical presentation and outcome. (Anemia and hypoxemia can precipitate myocardial ischemia in the absence of severe reduction in coronary artery blood flow.)

A syndrome consisting of chest pain, ischemic ST-segment and T-wave changes, elevated levels of biomarkers of myocyte injury, and transient left ventricular apical ballooning (Takotsubo syndrome) has been shown to occur in the absence of clinical CAD, after emotional or physical stress. The etiology of this syndrome is not well understood, but is thought to relate to a surge of catechol stress hormones and/or high sensitivity to those hormones.

PATHOGENESIS AND PATHOPHYSIOLOGY

The factors responsible for the sudden thrombotic occlusion of a coronary artery have only recently been elucidated. Atherosclerotic plaques rich in foam cells (lipid-laden macrophages) are susceptible to sudden plaque rupture and hemorrhage into the vessel wall, which may result in the sudden partial or total occlusion of the coronary artery. Although severe stenosis of a coronary artery (i.e. stenosis 70% of the diameter of the artery) is generally required to produce anginal symptoms, such stenoses tend to have dense fibrotic caps and are less prone to rupture than mild to moderate stenoses, which are generally more lipid laden. Studies of patients in whom angiography was performed before and after a myocardial infarction revealed that in most cases, acute coronary artery occlusion occurred at sites in the coronary artery circulation with stenoses of less than 70%, as demonstrated on the preinfarction angiogram. Although patients who have unstable anginal syndromes with increasingly frequent and severe angina are clearly at increased risk for myocardial infarction (MI), the ability of physicians to predict which patients with stable anginal syndromes are likely to experience infarction and which coronary artery stenoses are likely to result in acute thrombotic occlusion is poor.

Atherosclerosis is the disease primarily responsible for most ACS cases. Approximately 90% of MIs result from an acute thrombus that obstructs an atherosclerotic coronary artery. Plaque rupture is considered to be the major trigger of coronary thrombosis. Following plaque rupture, platelet activation and aggregation, coagulation pathway activation, and endothelial vasoconstriction occur and lead to coronary thrombosis and occlusion. Consider nonatherosclerotic causes of acute MIs in younger patients or if no evidence of atherosclerosis is noted. Such causes include coronary emboli from sources, such as an infected cardiac valve, coronary occlusion secondary to vasculitis, primary coronary vasospasm (variant angina), cocaine use, or other

factors leading to mismatch of oxygen supply and demand, as may occur with a significant gastrointestinal (GI) bleed (Figs 3.4–3.9 and Table 3.1).

DIAGNOSTIC APPROACH IN ACS

As many as half of all cases of ACS are clinically silent in that they do not cause the classic symptoms of this syndrome. Consequently, ACS goes unrecognized by the patient. Maintain a high index of suspicion for ACS, especially when evaluating women, patients with diabetes, older patients, patients with dementia, and those with a history of heart failure.

Although, ST-segment and T-wave changes are associated with CAD, alternative causes of these findings are left ventricular aneurysm, pericarditis, Prinzmetal angina, early repolarization, Wolff-Parkinson-White syndrome, and drug therapy (e.g. with tricyclic antidepressants, phenothiazines).

Increasing public awareness of the typical and atypical presentations of ACS is of the utmost importance for optimal and timely treatment. Many patients do not recognize that their symptoms are cardiac in origin and

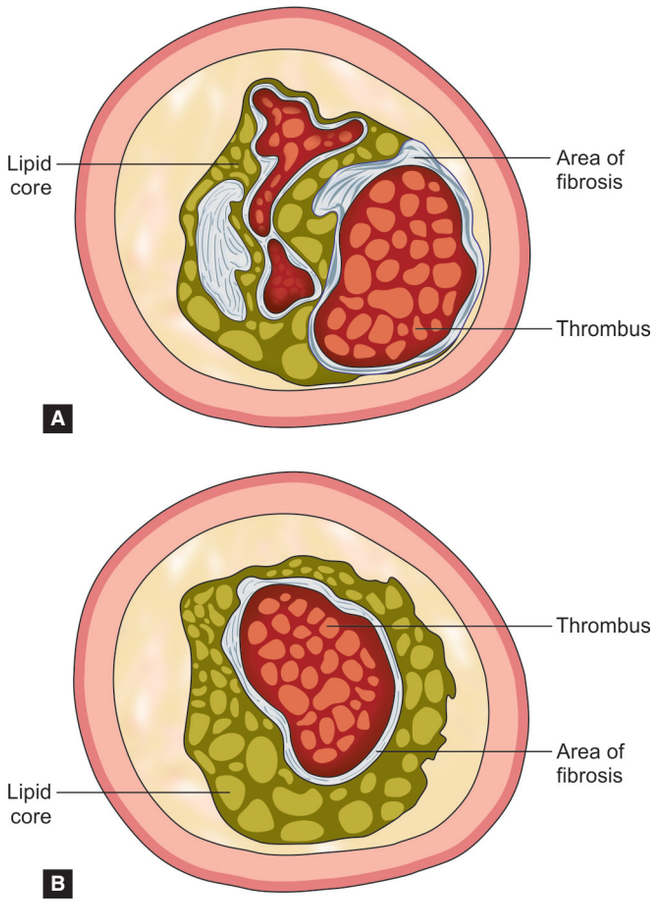

Fig. 3.4: Diagrams showing the two mechanisms of coronary total occlusion formation—(A) late evolution of an acute occlusion of an eccentric stenosis, (B) progressive occlusion of a long standing concentric stenosis

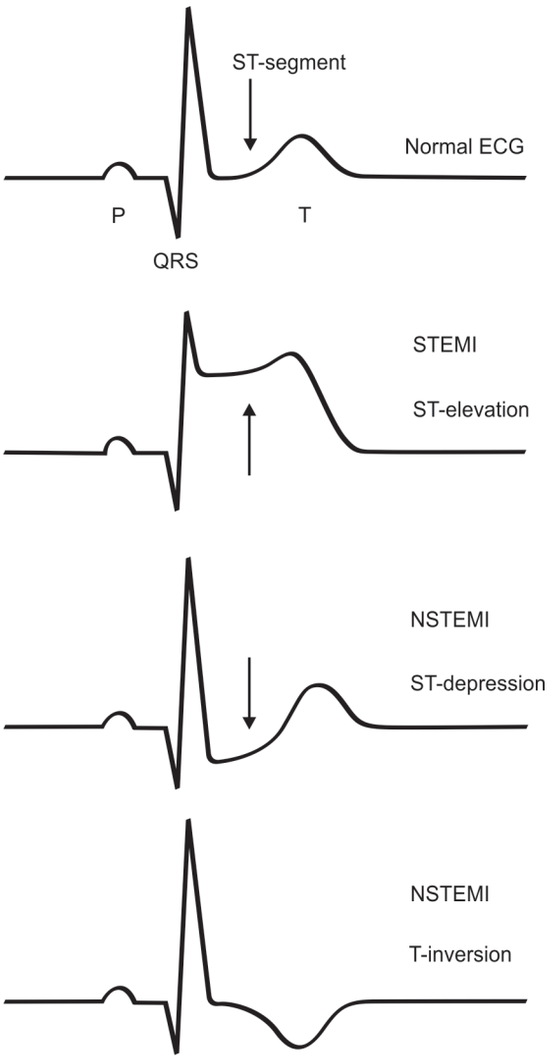

Unstable Angina or Pre-infarction Syndrome

- **Diagnosis:** Transient ECG changes—these are 'ST' elevation/depression and 'T' inversion.
- Changes revert back to normal in 24 hours
- Since no necarosis

Suspect MI when:

- ECG changes no revert back in 24 hours
- Cardiac enzymes levels are increased

Fig. 3.5: ECG diagram showing diagnosis of acute coronary syndrome. When ECG shows transient ST-elevation/depression and T-wave inversion without elevation of cardiac markers, it is classified as unstale angina pectoris and when markers are elevated, it could be either Q-/non-Q-wave STEMI or non-Q-wave NSTEMI

therefore may delay seeking medical help. Guidelines from the European Society of Cardiology (ESC)/American College of Cardiology (ACC)/American Heart Association (AHA) recommend that patients with established CAD call emergency medical services if they have chest pain that does not resolve after they take a sublingual nitroglycerin tablet.

In patients presenting to the emergency department (ED) with chest pain, a structured diagnostic approach that

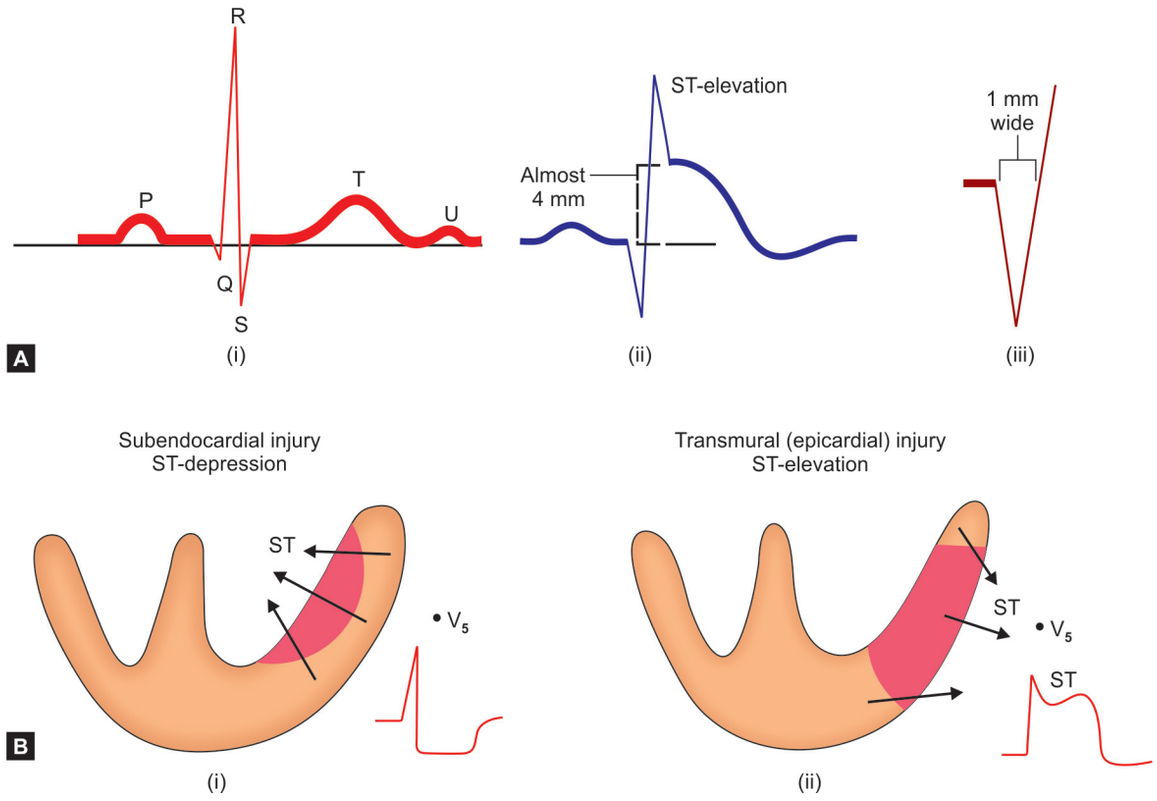

Fig. 3.6: (A) (i) ECG tracing showing normal P, Q, R, S, and T-waves. (ii) ST-elevation with acute ischemia. (iii) Q-wave with acute myocardial infarction. (B) Current-of-injury patterns with acute ischemia. With predominant subendocardial ischemia (i), the resultant ST-segment is directed toward the inner layer of the affected ventricle and the ventricular cavity. Overlying leads therefore record ST-segment depression. With ischemia involving the outer ventricular layer (ii) (transmural or epicardial injury), the ST vector is directed outward. Overlying leads record ST-segment elevation. *Credit: (Bottom) adapted from Braunwald E, Zipes DP, Libby P [2002]. (Heart disease: A textbook of cardiovascular medicine) [6th ed. p. 108]. Philadelphia: WB Saunders*

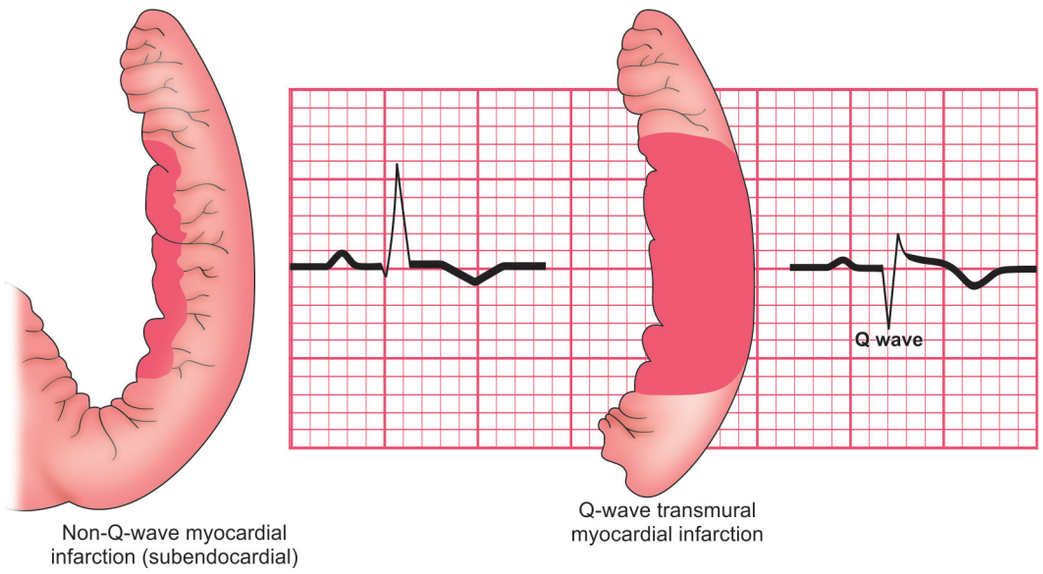

Fig. 3.7: ECG tracing showing subendocardial (non-Q-wave) versus a transmural (Q-wave) myocardial infarction

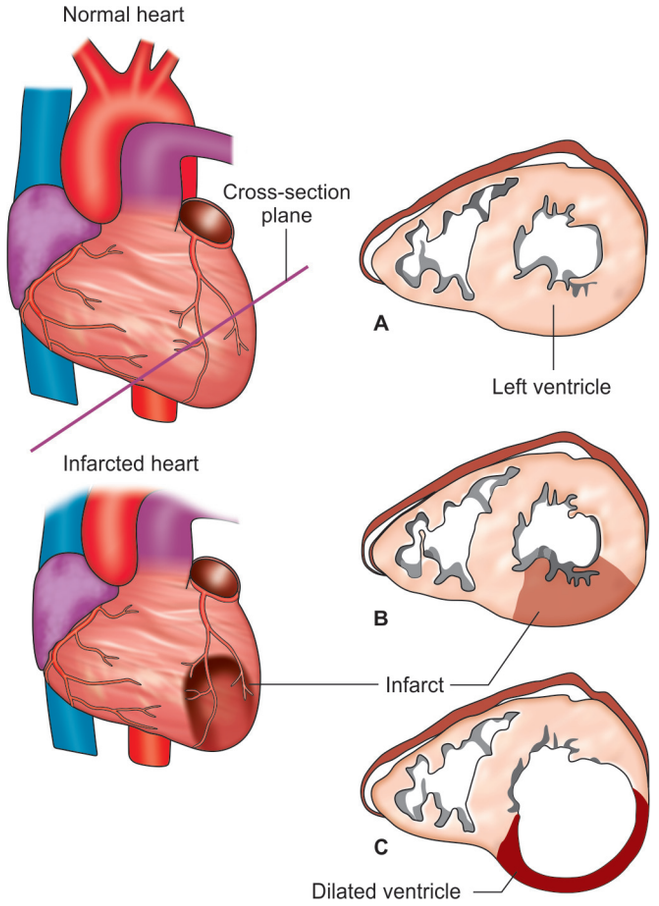

Fig 3.8: Normal vs infarcted heart. (A) The left ventricle has a thick muscular wall, shown in cross-section. (B) After a myocardial infarction (heart attack), heart muscle cells in the left ventricle are deprived of oxygen and die. (C) Eventually causing the ventricular wall to become thinner

includes time-focused ED decision points, brief observation, and selective application of early outpatient provocative testing appeared both safe and diagnostically efficient in a study by Scheuermeyer et al. However, some patients with ACS may be discharged for outpatient stress testing on the index ED visit.

Table 3.1: Different risk factors for atherosclerosis

Non-modifiable risk factors for atherosclerosis
Age
Sex
Family history of premature coronary heart disease
Modifiable risk factors for atherosclerosis
Smoking or other tobacco use
Diabetes mellitus
Hypertension
Dyslipidemia
Obesity
New and other risk factors for atherosclerosis
Elevated homocysteine levels
Male pattern baldness
Sedentary lifestyle and/or lack of exercise
Psychosocial stress
Presence of peripheral vascular disease
Poor oral hygiene
Non-atherosclerotic causes
Vasculitis
Coronary emboli
Congenital coronary anomalies
Coronary trauma
Coronary spasm
Drug use (cocaine)

Clinical History

The severity and duration of coronary artery obstruction, the volume of myocardium affected, the level of demand, and the ability of the rest of the heart to compensate are major determinants of a patient's clinical presentation and outcome. A patient may present to the ED because of a change in pattern or severity of symptoms.

Typically, angina is a symptom of myocardial ischemia that appears in circumstances of increased oxygen demand. It is usually described as a sensation of chest pressure or heaviness that is reproduced by activities or conditions that increase myocardial oxygen demand. A new case of angina is more difficult to diagnose because symptoms are often

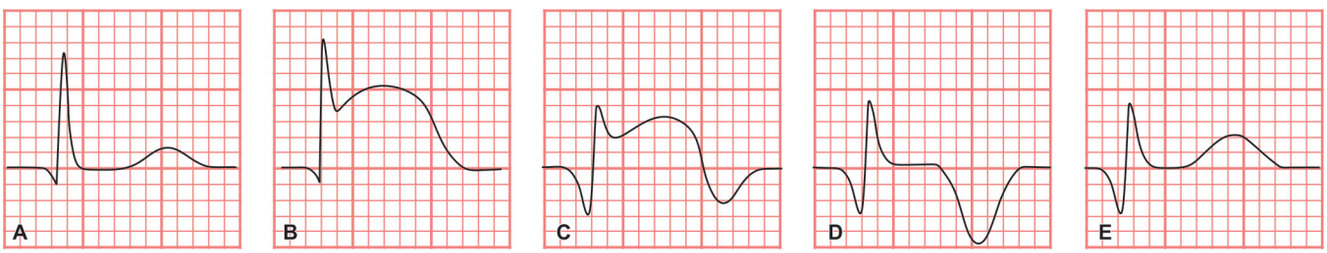

Fig. 3.9: ECG showing the evolution of an infarct on the ECG. ST-elevation, Q-wave formation, T-wave inversion, normalisation with a persistent Q-wave

vague and similar to those caused by other conditions (e.g. indigestion and anxiety).

However, not all patients experience chest pain. They may present with only neck, jaw, ear, arm, or epigastric discomfort. Some patients, including some who are elderly or who have diabetes, present with no pain, complaining only of episodic shortness of breath, severe weakness, light-headedness, diaphoresis, or nausea and vomiting. Elderly persons may also present only with altered mental status. Those with preexisting altered mental status or dementia may have no recollection of recent symptoms and may have no complaints.

In addition, evidence exists that women more often have coronary events without typical symptoms, which may explain the frequent failure of clinicians to initially diagnose ACS in women.

A summary of patient's complaints is as follows:

- Palpitations
- Pain, which is usually described as pressure, squeezing, or a burning sensation across the precordium and may radiate to the neck, shoulder, jaw, back, upper abdomen, or either arm
- Exertional dyspnea that resolves with pain or rest
- Diaphoresis from sympathetic discharge
- Nausea from vagal stimulation
- Decreased exercise tolerance

Stable angina involves episodic pain lasting 5–15 minutes, is provoked by exertion, and is relieved by rest or nitroglycerin. In unstable angina, patients have increased risk for adverse cardiac events, such as myocardial infarction or death. New-onset exertional angina can occur at rest and is of increasing frequency or duration or is refractory to nitroglycerin. Variant angina (Prinzmetal angina) occurs primarily at rest, is triggered by smoking, and is thought to be due to coronary vasospasm.

Physical Examination

Physical examination (Fig. 3.10) results are frequently normal. If chest pain is ongoing, the patient will usually lie quietly in bed and may appear anxious, diaphoretic, and pale. Physical findings can vary from normal to any of the following:

- Hypotension: Indicates ventricular dysfunction due to myocardial ischemia, infarction, or acute valvular dysfunction
- Hypertension: May precipitate angina or reflect elevated catecholamine levels due to anxiety or to exogenous sympathomimetic stimulation
- Diaphoresis
- Pulmonary edema and other signs of left heart failure
- Extracardiac vascular disease
- Jugular venous distention
- Cool, clammy skin and diaphoresis in patients with cardiogenic shock

In addition, a third heart sound (S3) may be present, and frequently, a fourth heart sound (S4) exists. The latter is especially prevalent in patients with inferior-wall ischemia and may be heard in patients with ischemia or systolic murmur secondary to mitral regurgitation.



Fig. 3.10: A patient with acute coronary syndrome is being examined by the attending doctor after resuscitation in a recovery unit of the hospital

A systolic murmur related to dynamic obstruction of the left ventricular (LV) outflow tract may also occur. It is caused by hyperdynamic motion of the basal left ventricular myocardium and may be heard in patients with an apical infarct.

A new murmur may reflect papillary muscle dysfunction. Rales on pulmonary examination may suggest LV dysfunction or mitral regurgitation.

Patients who present to the ED with chest pain who have a low short-term risk of a major adverse cardiac event must be identified to facilitate early discharge in order to avoid lengthy and costly hospital stays. The ASPECT study tested a 2-hour, accelerated diagnostic protocol (ADP) that included the use of a structured pretest probability scoring method, electrocardiography, and a point-of-care biomarker panel that included troponin, creatine kinase MB, and myoglobin levels. The study suggests that ADP can identify patients at low risk for a short-term major adverse cardiac event who may be suitable for early discharge; such an approach could be used to decrease the overall observation periods and admissions for chest pain and has the potential to affect health-service delivery worldwide.

Differential Diagnosis in ACS

- Anxiety
- Aortic stenosis
- Asthma
- Cardiomyopathy, dilated
- Esophagitis
- Gastroenteritis
- Hypertensive emergencies in emergency medicine
- Myocardial infarction
- Myocarditis
- Pericarditis and cardiac tamponade

Laboratory Blood Tests

Measurement of CK-MB Levels

CK-MB, the isoenzyme specific to the heart muscle, was the principal biomarker of cardiac injury until troponin supplemented it.

In the setting of myocardial infarction, plasma CK-MB concentrations typically rise about 4–6 hours after the onset of chest pain. They peak within 12–24 hours and return to baseline levels within 24–48 hours. Serial measurements obtained every 6–8 hours (at least 3 times) are warranted until peak values are determined.

The area under the concentration-time curve for CK-MB created with serial measurements of blood enzyme levels provides a reliable estimate of the size of the infarct.

Clinical settings other than ACS, such as trauma, heavy exertion, and skeletal muscle disease (e.g. rhabdomyolysis), may elevate CK-MB values.

Determination of subforms of CK-MB (CK-MB2 that is more specific to heart muscle) may improve the sensitivity of this test (Fig. 3.11).

Measurement of Troponin Levels

The troponins are regulatory proteins found in skeletal and cardiac muscle. The three subunits that have been identified include troponin I (TnI), troponin T (TnT), and troponin C (TnC). The genes that code for the skeletal and cardiac isoforms of TnC are identical; thus, no structural difference exists between them. However, the skeletal and cardiac subforms for TnI and TnT are distinct, and immunoassays have been designed to differentiate between them. This explains the cardiospecificity of the cardiac troponins. Skeletal TnI and TnT are structurally different. No cross-reactivity occurs between skeletal and cardiac TnI and TnT with the current assays.

The cardiac troponins are sensitive, cardiospecific, and provide prognostic information for patients with ACS.

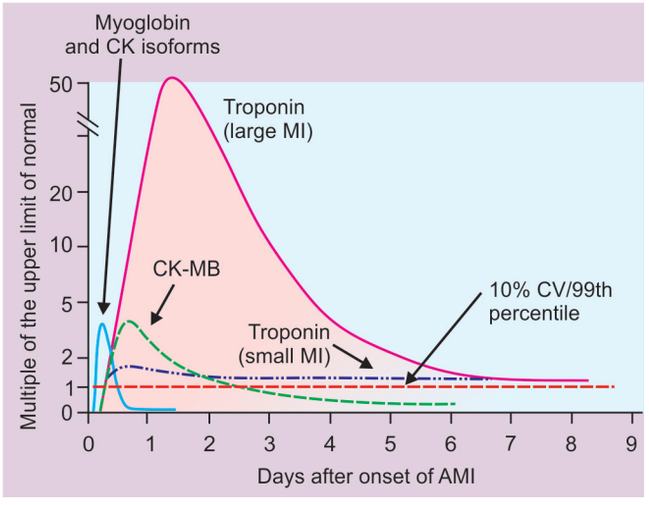

Fig. 3.11: Elevation of different biomarkers at different ACS

They have become the cardiac markers of choice for patients with ACS.

Early studies on the release kinetics of the cardiac troponins indicated that they were not early markers of myocardial necrosis. The early generation troponin assays yielded positive results within 4–8 hours after symptom onset, similar in timing to the release of CK-MB; however, they remained elevated for as long as 7–10 days post-myocardial infarction.

Initial studies on the cardiac troponins revealed a subset of patients with rest unstable angina in whom CK-MB levels were normal, but who had elevated troponin levels. These patients had higher adverse cardiac event rates (acute myocardial infarction, death) within the 30 days after the index admission and a natural history that closely resembled patients with NSTEMI.

As previously mentioned, an elevated troponin level also enables risk stratification of patients with ACS and identifies patients at high risk for adverse cardiac events (i.e. myocardial infarction, death) up to 6 months after the index event.

In a study by Antman et al. the initial TnI level on admission in patients with ACS correlated with mortality at 6 weeks. CK-MB levels, although sensitive and specific for the diagnosis of acute myocardial infarction (AMI), were not predictive of adverse cardiac events and had no prognostic value. The relationship between TnI levels and risk of cardiac events and mortality is demonstrated in the graphs shown in Fig. 3.11.

Use of cardiac markers in the ED. Troponin I levels and cardiac mortality in ACS. Cardiac event rates in the platelet receptor inhibition for ischemic syndrome (PRISM) study based on TnI results.

Data from a meta-analysis indicated that an elevated troponin level in patients without ST-segment elevation is associated with a nearly fourfold increase in cardiac mortality rate. For the composite end point of acute myocardial infarction or death, an elevated troponin level was associated with an odds ratio of 3.3.

The TIMI IIIB, GUSTO IIa, GUSTO IV ACS, and Fragmin during instability in coronary artery disease (FRISC) trial all demonstrated a direct correlation between the level of TnI or TnT and the adverse cardiac event rate and mortality rate in ACS. These studies confirmed the use of the cardiac troponins, i.e. TnI and TnT in risk stratification and therapeutic decision making.

Studies by Ohman et al. and Stubbs et al. revealed that an elevated troponin level at baseline was an independent predictor of mortality even in patients with chest pain and acute myocardial infarction with ST-segment elevation who were eligible for reperfusion therapy.

With the introduction of increasingly sensitive and precise troponin assays, up to 80% of patients with acute myocardial infarction will be found to have an elevated troponin within 2–3 hours of ED arrival. With this improved clinical performance in cardiac troponin assays, the so-called rapidly rising cardiac biomarkers, such as myoglobin

or CK-MB isoforms, have a little clinical utility. In a prospective multicenter study, patients with ACS who presented with acute chest pain to the ED were followed for 12 months. The study found that patients with normal high-sensitivity cardiac troponin T (hs-cTnT) levels at presentation have low mortality rates but an increased rate of acute myocardial infarction during the subsequent 360 days. As a result, some authorities have called for a troponin standard alone and recommend eliminating CK-MB.

Many patients with acute myocardial infarction present with equivocal ECG patterns, making prehospital ECG diagnosis difficult. A study by Sorensen et al. suggests prehospital TnT testing may improve diagnosis in patients with chest pain transported by ambulance. When quantitative TnT was measured at hospital arrival in 958 patients after 8 and 24 hours, a diagnosis of acute myocardial infarction was established in 208 of 258 patients with increased TnT levels, showing prehospital TnT testing is feasible with a high success rate. Prehospital implementation of quantitative tests, with lower detection limits, may identify most patients with acute myocardial infarction irrespective of ECG changes.

The 2007 American College of Cardiology (ACC) guidelines for NSTEMI recommend that serial troponins be obtained for a definitive rule out at baseline and 6–9 hours later. To establish the diagnosis of acute myocardial infarction, only one elevated level above the established cutoff is required. The demonstration of a rising or falling level is needed to distinguish persistently elevated troponin levels (e.g. in some patients with renal failure) from those patients with acute myocardial infarction.

If myocardial injury is suspected despite negative cardiac-specific troponin findings, additional, sensitive laboratory assays are indicated.

Measurement of Myoglobin Levels

Myoglobin is not cardiac specific, but it may be detected as early as 2 hours after myocardial necrosis starts. However, myoglobin results should be supplemented with other, more specific cardiac biomarkers, such as CK-MB or troponin.

Myoglobin values have a high negative predictive value when blood is sampled in the first 4–8 hours after onset.

Complete Blood Count Determination

The complete blood count (CBC) helps in ruling out anemia as a secondary cause of ACS. Leukocytosis has prognostic value in the setting of acute myocardial infarction.

Basic Metabolic Panel

Obtain a basic metabolic profile, including a check of blood glucose level, renal function, and electrolytes levels, for patients with new-onset angina. Close monitoring of potassium and magnesium levels is important in patients with ACS because low levels may predispose them to ventricular arrhythmias. Routine measurement of serum potassium levels and prompt correction are recommended.

Creatinine levels must be considered before using an angiotensin-converting enzyme (ACE) inhibitor and particularly if cardiac catheterization is considered. Use of N -acetylcysteine and adequate hydration can help prevent contrast material-induced nephropathy.

Other useful metabolic profiles include amylase and lipase.

A study by Charpentier et al. suggests that a serum glucose level of more than 140 mg/dl is associated with non-ST-elevation ACS in patients admitted to an ED for chest pain. However, when this level of blood glucose is added to the conventional diagnostic tools, the result is only a small increase in the ability to classify ACS.

New Biomarkers

Levels of brain natriuretic peptide (BNP) and N-terminal pro-BNP (NT-pro-BNP) are elevated in acute MI and provide predictive information for risk stratification across the spectrum of ACS. However, a single, low BNP level obtained within 4 hours of a patient presenting to the ED does not identify the patient as low-risk for 30-day acute myocardial infarction or death.

In the future, a combination of levels of troponin (a biomarker for myocardial necrosis), NT-pro-BNP (an indicator of elevated LV end-diastolic pressure and wall stress), and C-reactive protein (CRP, an estimate of the extent of systemic inflammation) may prove useful for predicting the outcome of patients with ACS.

Routine measurement of BNP and CRP levels in patients with ACS is not warranted.

Interleukin-6 is the major determinant of acute-phase reactant proteins in the liver, and serum amyloid A is another acute-phase reactant. Elevations of either of these can be predictive in determining increased risk of adverse outcomes in patients with unstable angina.

Cavusoqlu et al. suggests that elevated baseline levels of plasma interleukin-10 are associated with long-term adverse outcomes in patients with ACS.

Several other biomarkers with variable sensitivity and specificity have been investigated, including **sCD40** ligand, myeloperoxidase, pregnancy-associated plasma protein-A, choline, placental growth factor, cystatin C, fatty acid binding protein, ischemia modified albumin, chemokines ligand-5 and -18 (mediators of monocyte recruitment induced by ischemia), angiogenin, SCUBE1 (a novel platelet protein), and others. In a study that included 107 patients presenting to an emergency department with chest pain, ischemia modified albumin was not found to have superior sensitivity and specificity over traditional biomarkers, with a sensitivity of 0.86 and specificity of 0.49.

Noninvasive and Invasive Laboratory Procedures

Chest Radiography

Chest radiography (Figs 3.13 and 3.14) helps in assessing cardiomegaly and pulmonary edema, or it may reveal complications of ischemia, such as pulmonary edema. It may also provide clues to alternative causes of symptoms,

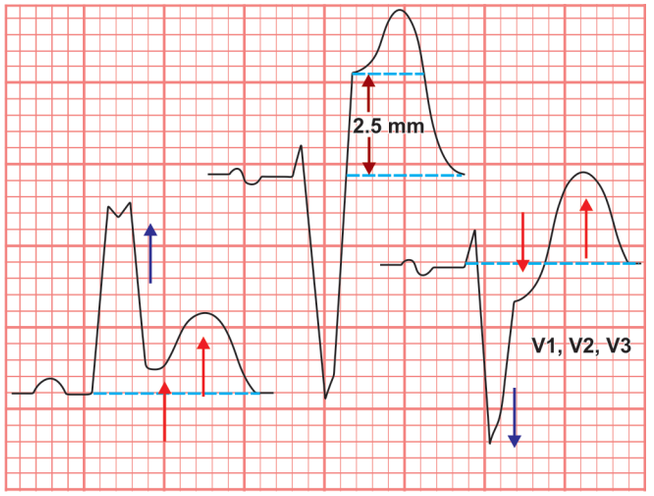

Fig. 3.12: Diagrammatic ECG criteria. The three criteria used to diagnose infarction in patients with LBBB are—concordant ST-elevation >1 mm in leads with a positive QRS complex (score 5) concordant ST depression >1 mm in V1–V3 (score 3), and excessively discordant ST-elevation >5 mm in leads with a negative QRS complex (score 2). This criterion is sensitive, but not specific for ischemia in LBBB. It is however associated with a worse prognosis, when present in LBBB during ischemia. A total score of >3 has a specificity of 90% for diagnosing MI

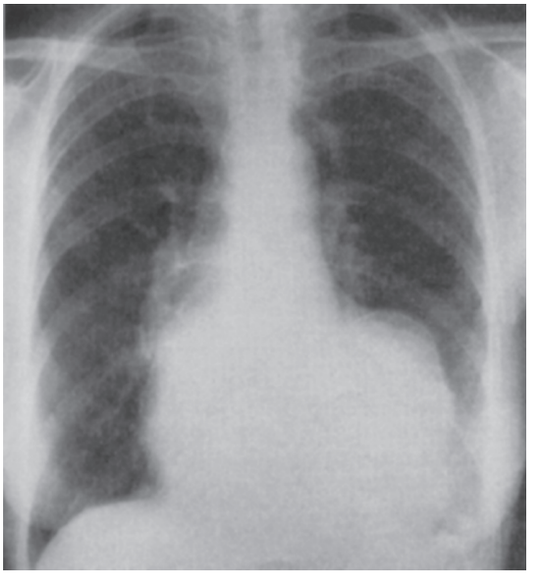

Fig. 3.13: Chest X-ray (PA) view showing bulge in the region of anterolateral border of LV in patient with aneurysm of LV wall following chronic MI

such as thoracic aneurysm or pneumonia (which can be a precipitating cause of ACS).

Electrocardiography

ECGs should be reviewed promptly (Figs 3.15–3.31 and Table 3.2). Involve a cardiologist when in doubt.

Recording an ECG during an episode of the presenting symptoms is valuable. Transient ST-segment changes

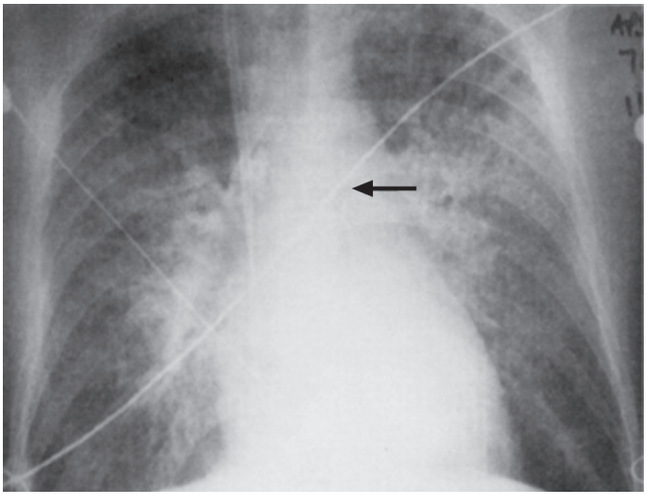

Fig. 3.14: Cardiogenic alveolar edema. Symmetrical airspace opacity with perihilar predominance is one characteristic pattern produced by cardiogenic edema

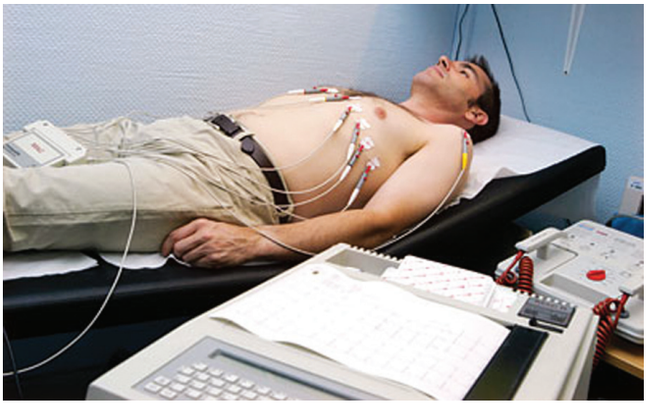

Fig. 3.15: An electrocardiogram (ECG) test records the electrical activity of the heart in a young patient with ACS

(>0.05 mV) that develop during a symptomatic period and that resolve when the symptoms are strongly predictive of underlying CAD and have prognostic value. Comparison with previous ECGs is often helpful.

Alternative causes of ST-segment and T-wave changes are left ventricular aneurysm, pericarditis, Prinzmetal angina, early repolarization, Wolff-Parkinson-White syndrome, and drug therapy (e.g. with tricyclic antidepressants, phenothiazines).

In the emergency setting, ECG is the most important ED diagnostic test for angina. It may show change during symptoms and in response to treatment, confirm a cardiac basis for symptoms. It may also demonstrate preexisting structural or ischemic heart disease (left ventricular hypertrophy, Q-waves). A normal ECG or one that remains unchanged from the baseline does not exclude the possibility that chest pain is ischemic in origin. Changes that may be seen during anginal episodes are given in Fig. 3.31.

- Transient ST-segment elevations

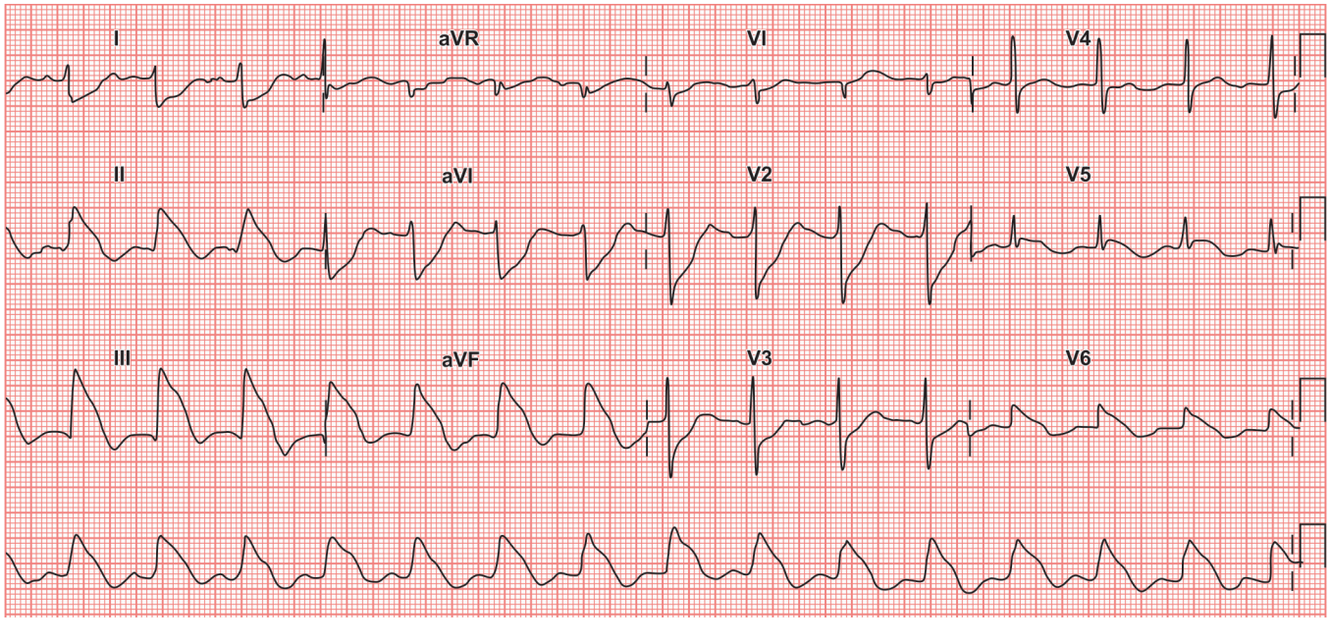

Fig. 3.16: Inferior wall MI—tombstone ST-elevation is an unusual morphological ECG appearance of acute myocardial infarction. The ST-segment is convexed upwards and the peak of the convexed ST-segment is often higher than the preceding R-wave, which is less than 0.04 s and small in amplitude

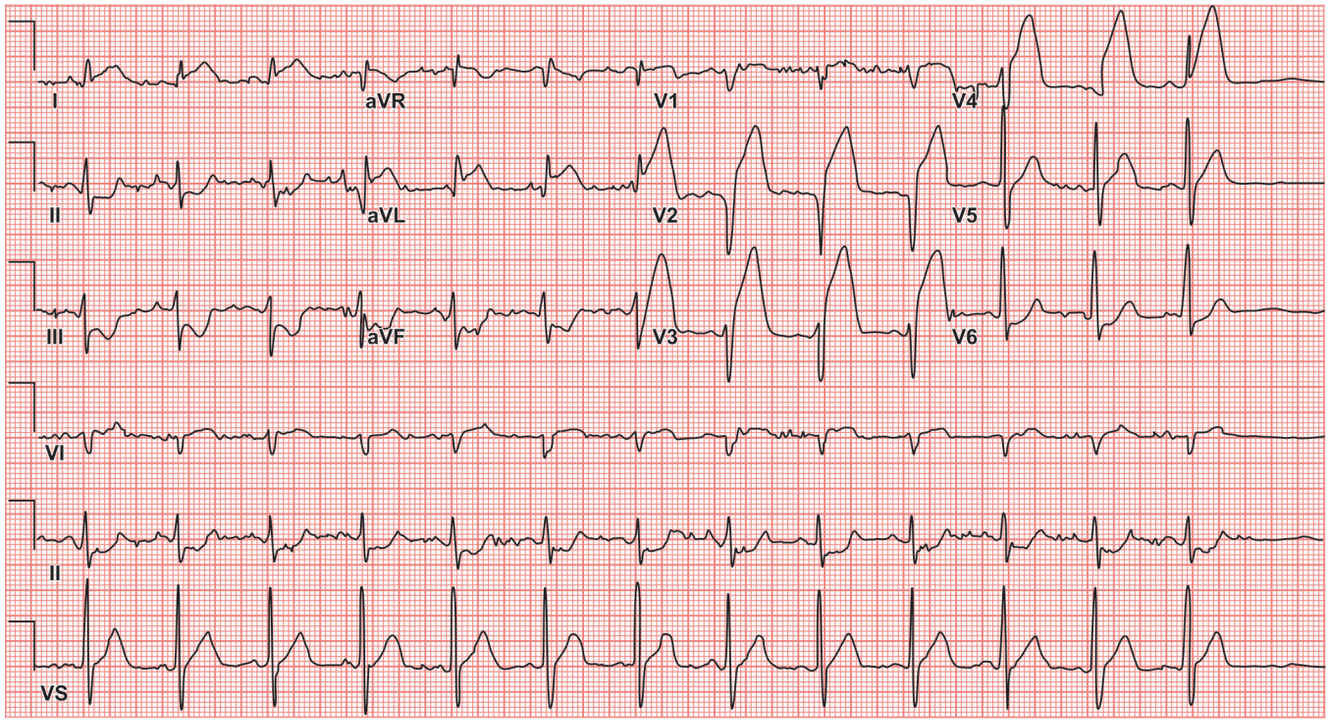

Fig. 3.17: Anterior wall MI—tombstone ST-elevation is an unusual morphological ECG appearance of acute myocardial infarction. The ST-segment is convexed upwards and the peak of the convexed ST-segment is often higher than the preceding R-wave, which is less than 0.04 s and small in amplitude. This type of tombstone pattern is associated with reperfusion polymorphous ventricular tachyarrhythmias and is thought to represent extensive and rapid myocardial damage after the ischemic episode. At coronary angiography, patients with tombstoning are likely to have high grade stenosis of the proximal left anterior descending artery

- Dynamic T-wave changes: Inversions, normalizations, or hyperacute changes
- ST-depressions: May be junctional, downsloping, or horizontal.

In patients with transient ST-segment elevations, consider LV aneurysm, pericarditis, Prinzmetal angina, early repolarization, and Wolff-Parkinson-White syndrome as possible diagnoses. Fixed changes suggest acute myocardial infarction.

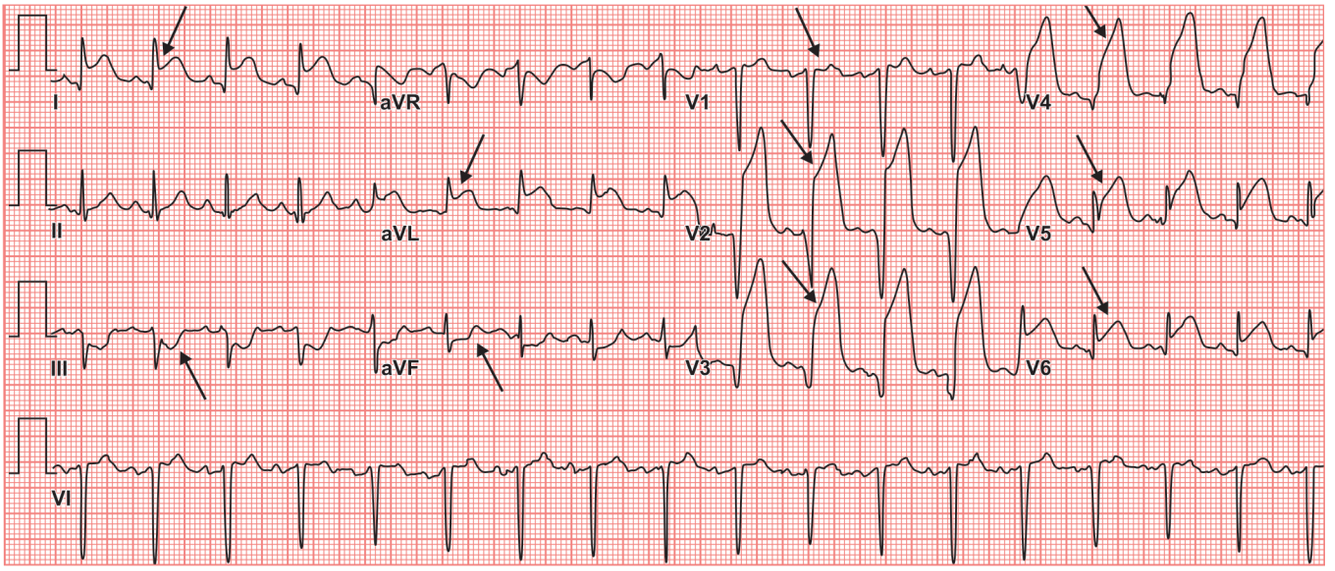

Fig. 3.18: ECG of ST-segment elevation myocardial infarction

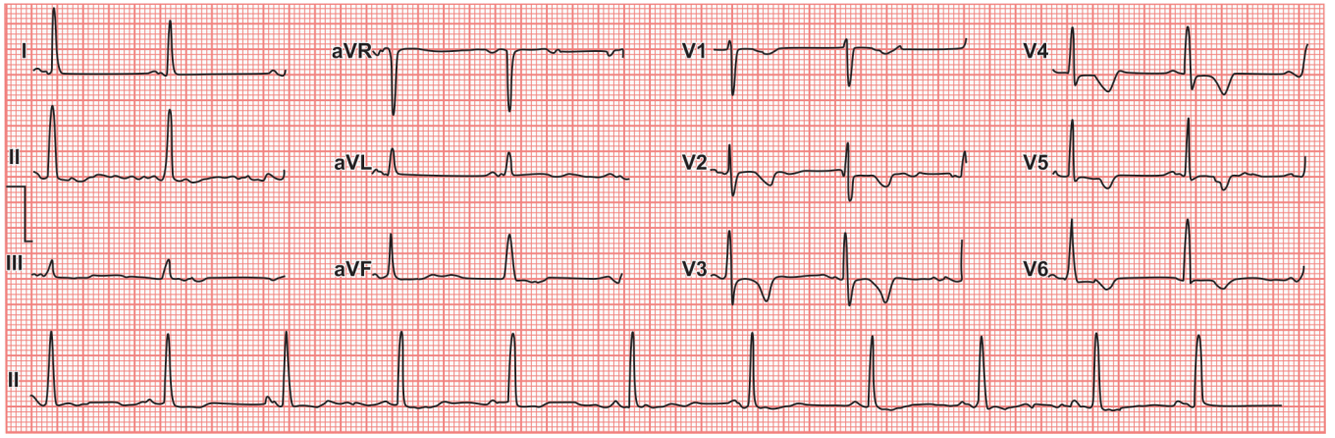

Fig. 3.19: ECG of non-ST-segment elevation myocardial infarction with ST-segment depression in precordial leads V2–V6

When deep T-wave inversions are present, consider the possibility of central nervous system (CNS) events or drug therapy with tricyclic antidepressants or phenothiazines as the cause.

Diagnostic sensitivity may be increased by performing right-sided leads (V4 R), posterior leads (V8, V9), and serial recordings.

In difficult cases with nondiagnostic ECGs, such as those involving a left bundle-branch block, early imaging is useful to assess wall-motion abnormalities.

An important use of noninvasive imaging is to classify a patient having NSTEMI or true STEMI.

Echocardiography

Echocardiograms (Figs 3.32–3.35) may play an important role in the setting of ACS. Regional wall-motion abnormalities can be identified with this modality, and echocardiograms are especially helpful if the diagnosis is questionable.

An echocardiogram can also help in defining the extent of an infarction and in assessing overall function of the left and right ventricles. In addition, an echocardiogram can help to identify complications, such as acute mitral regurgitation, LV rupture, and pericardial effusion.

Absence of segmental wall-motion abnormality on echocardiography during active chest discomfort is a highly reliable indicator of a nonischemic origin of symptoms; although, echocardiography is of limited value in patients whose symptoms have resolved or who have pre-existing wall-motion abnormalities.

Myocardial Perfusion Imaging

Radionuclide myocardial perfusion imaging has been shown to have favorable diagnostic and prognostic value in the emergent setting, with an excellent early sensitivity in the detection of acute myocardial infarction not found in other testing modalities (Figs 3.36–3.41).

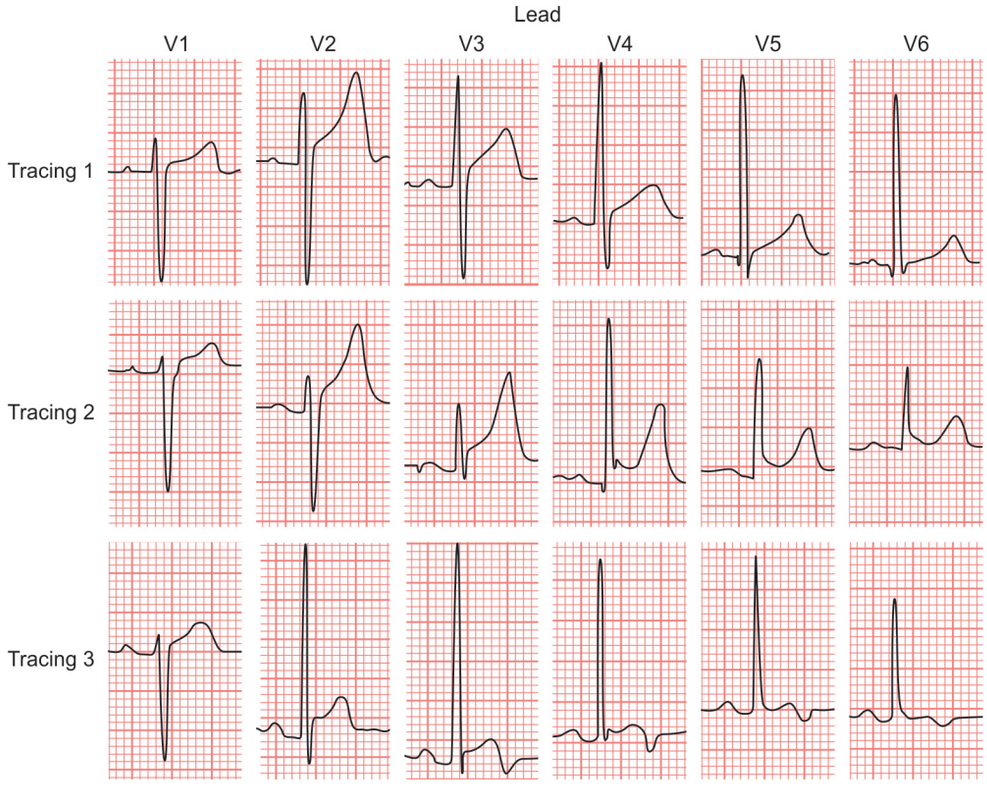

Fig. 3.20: Unstable angina (UA). Non-ST-elevation (non-Q-wave) myocardial infarction (NSTEMI) are part of the continuum of ACS

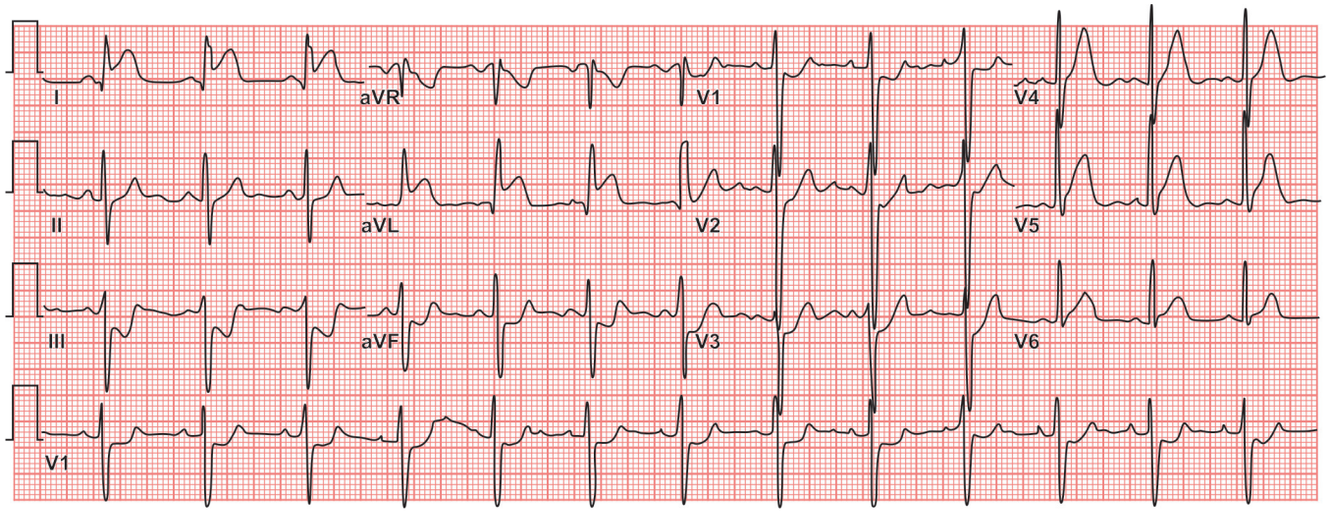

Fig. 3.21: ECG shows high lateral STEMI—ST-elevation is present in the high lateral leads (I and aVL). There is also subtle ST-elevation with hyperacute T-waves in V5–6. There is reciprocal ST depression in the inferior leads (III and aVF) with associated ST depression in V1–3 (which could represent anterior ischaemia or reciprocal change). This pattern is consistent with an acute infarction localised to the superior portion of the lateral wall of the left ventricle (high lateral STEMI). The culprit vessel in this case was an occluded first diagonal branch of the LAD

A normal resting perfusion imaging study has been shown to have a negative predictive value of more than 99% excluding myocardial infarction. Observational and randomized trials of rest and stress imaging in the ED evaluation of patients with chest pain have demonstrated reductions in unnecessary hospitalizations and cost savings compared with routine care.

Perfusion imaging has also been used in risk stratification after myocardial infarction and for measurement of infarct size to evaluate reperfusion therapies. Novel 'hot spot' imaging radiopharmaceuticals that visualize infarction or ischemia are currently undergoing evaluation and hold promise for future imaging of ACS.

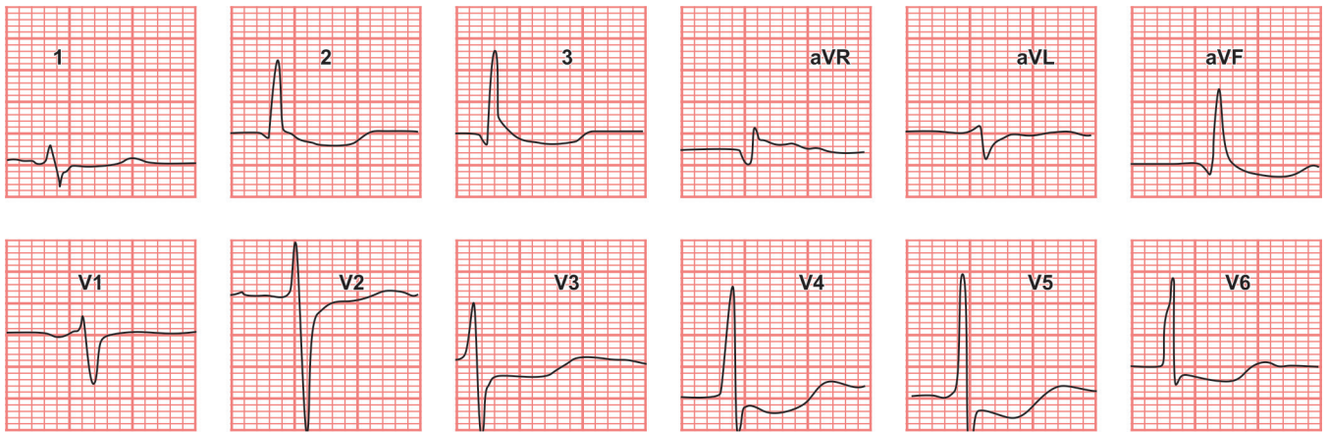

Fig. 3.22: ECG showing classical subendocardial (non-Q-wave) infarction manifested by abnormal ST-segment depressionin all leads except AVR, which showed ST-segment elevation

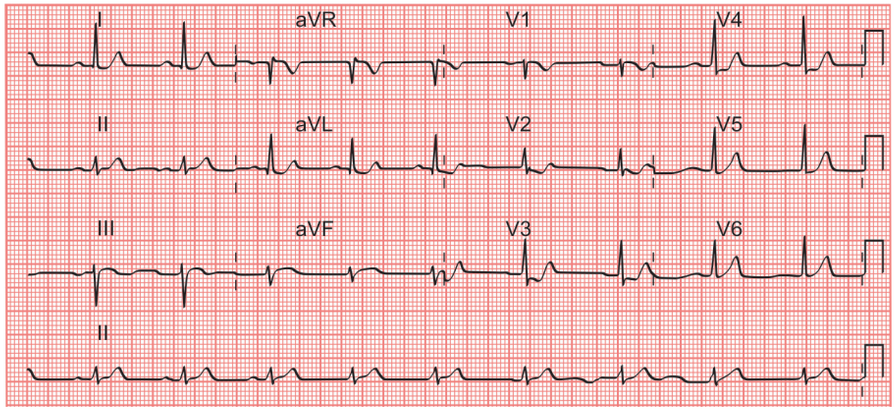

Fig. 3.23: ECG showing posterior MI. It is suggested by the presence of—ST-depression in V2–3 tall, broad R-waves (>30 ms) in V2–3, dominant R-wave (R/S ratio >) in V2, and upright terminal portions of the T-waves in V2–3

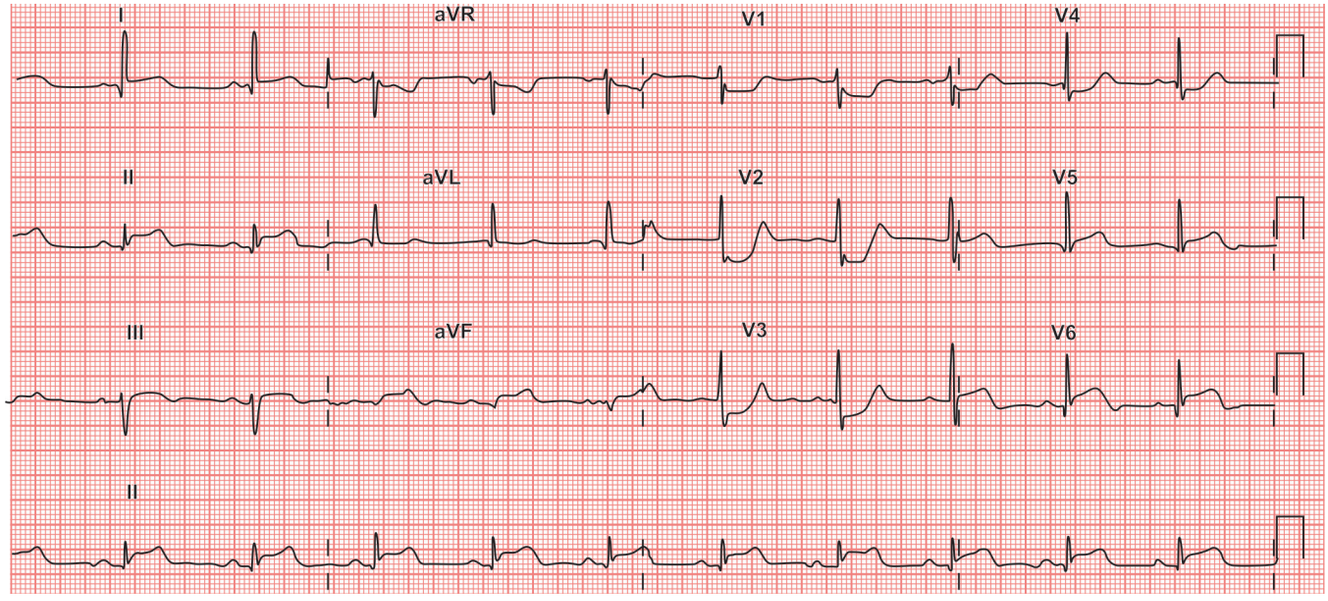

Fig. 3.24: ECG showing inferoposterolateral STEMI—ST-elevation is present in the inferior (II, III and aVF) and lateral leads (I, V5–6). ST-depression in V1–3 with tall, broad R-waves and upright T-waves and a R/S ratio >1 in V2 indicate concomitant posterior infarction (this patient also had ST-elevation in the posterior leads V7–9). These changes are consistent with a massive infarction involving the inferior, lateral, and posterior walls of the left ventricle.The culprit vessel is again very likely to be an occluded proximal circumflex artery

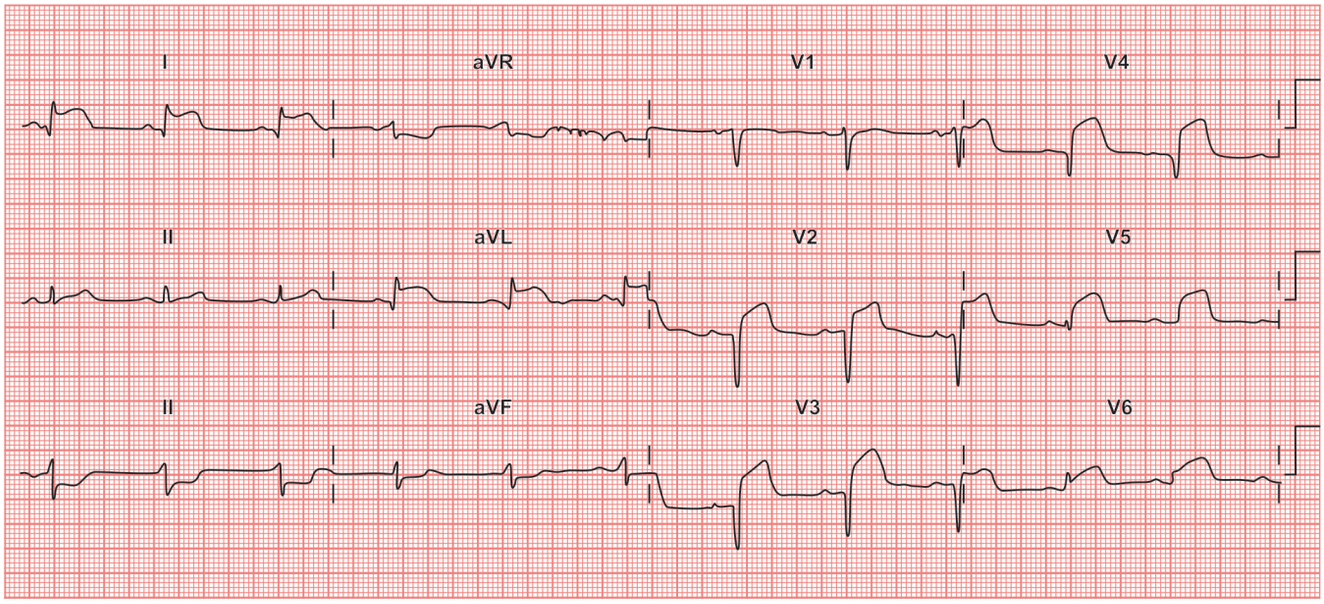

Fig. 3.25: ECG showing anterolateral STEMI—ST-elevation is present in the anterior (V2–4) and lateral leads (I, aVL, V5–6). Q-waves are present in both the anterior and lateral leads, most prominently in V2–4. There is reciprocal ST depression in the inferior leads (III and aVF). This pattern indicates an extensive infarction involving the anterior and lateral walls of the left ventricle. ST-elevation in the precordial leads plus the high lateral leads (I and aVL) is strongly suggestive of an acute proximal LAD occlusion (this combination predicts a proximal LAD lesion 87% of the time)

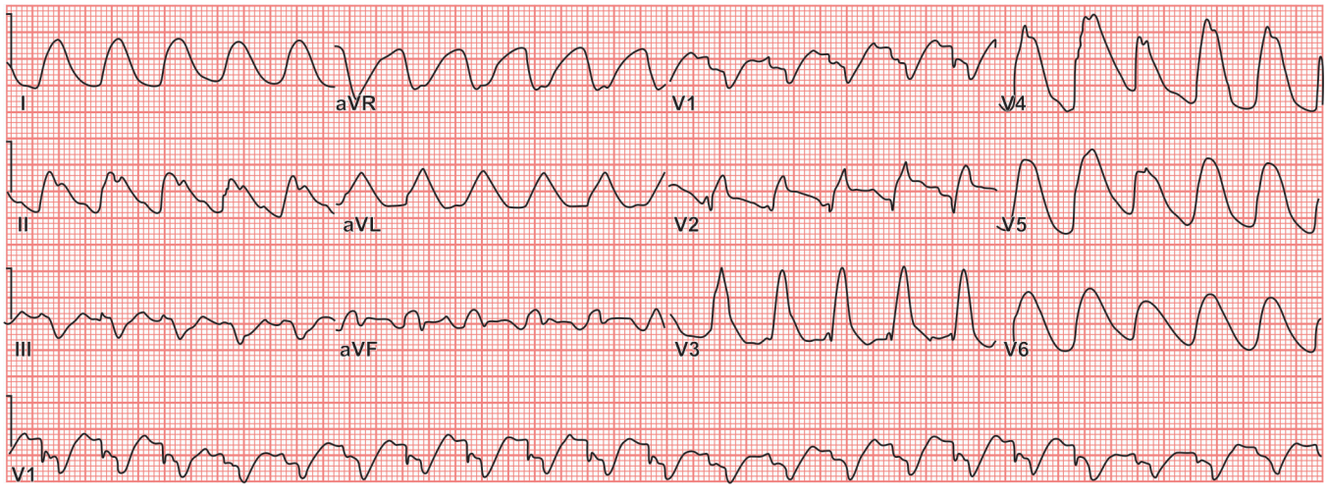

Fig. 3.26: Wide complex tachycardia, acute myocardial infarction

Cardiac Catheterization and Angiography

Cardiac catheterization helps in defining coronary anatomy and the extent of a patient's disease. Patients with cardiogenic shock, intractable angina (despite medication), severe pulmonary congestion, or right ventricular (RV) infarction should immediately undergo cardiac catheterization. (Cardiogenic shock is defined as a systolic BP of less than 90 mmHg in the presence of organ hypoperfusion) (Figs 3.42–3.48).

For high-risk patients with ACS without persistent ST-elevation, angiography with glycoprotein IIb/IIIa inhibition has been recommended. Earlier that coronary angiography is performed, the lower the risk of recurrent ischemia. This also shortens the hospital stay for those patients.

Most patients benefit from angiography when they have a thrombolysis in myocardial infarction (TIMI) risk score of <3 points.

Computed Tomographic, Coronary Artery Angiography and Calcium Scoring

Dual-source 64-slice CT scanners can do a full scan in 10 seconds and produce high-resolution images that allow fine details of the patient's coronary arteries to be seen. This technology allows for noninvasive and early diagnosis of CAD and thus earlier treatment before the coronary

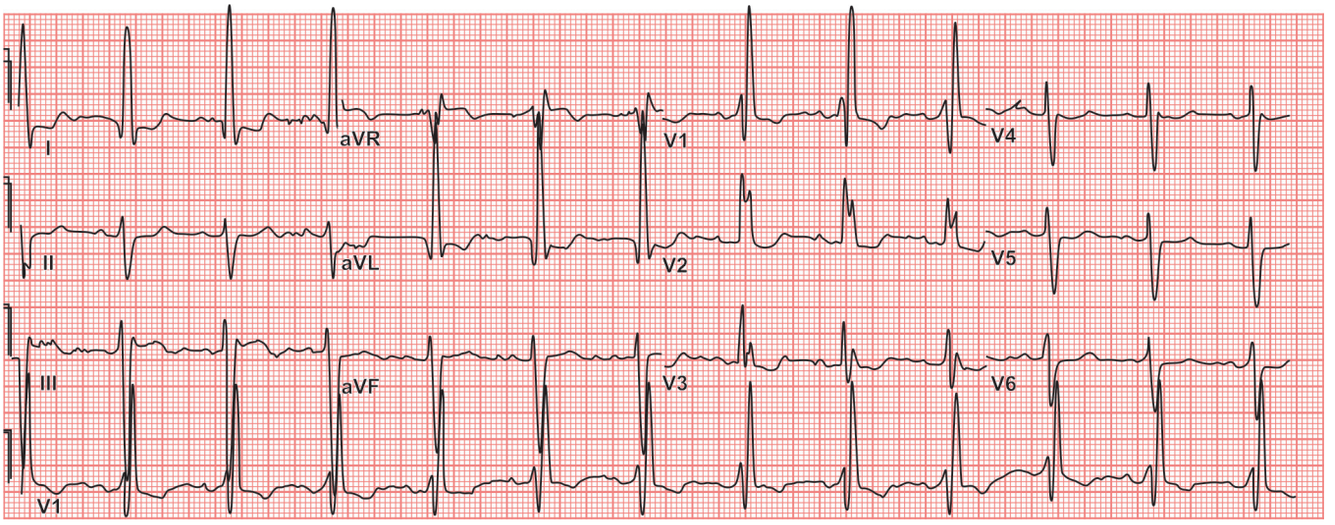

Fig. 3.27: Showing right bundle branch block, left anterior divisional block

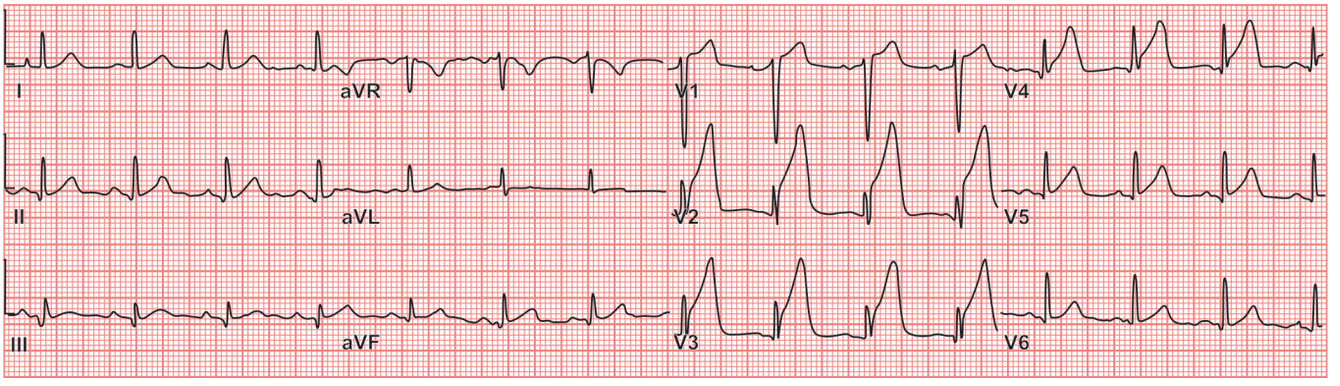

Fig. 3.28: Showing anteroseptal myocardial infarction

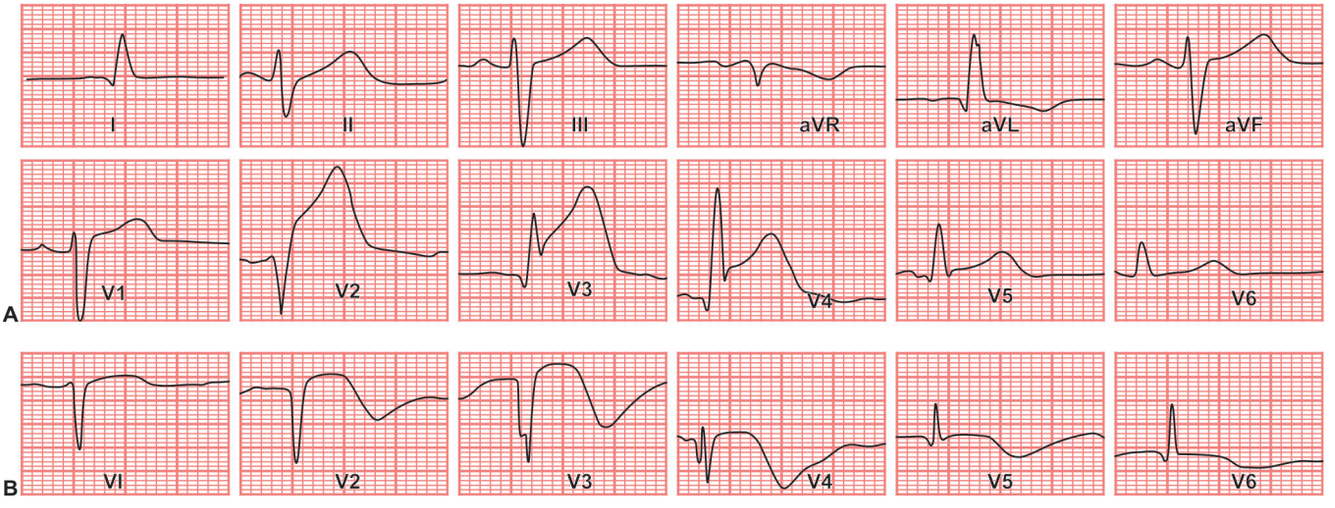

Fig. 3.29: Showing acute extensive anterior myocardial infarction

arteries become more or completely occluded. It permits direct visualization of not only the lumen of the coronary arteries but also plaque within the artery. Dual-source 64-slice CT scanning is being used with intravenous (IV) contrast to determine if a stent or graft is open or closed.

CT coronary artery scoring is emerging as an attractive risk stratification tool in patients who are at low risk for ACS. This imaging modality exposes the patient to very little radiation (1–2 msV). No contrast is needed, and the study does not have a requirement for heart rate (Figs 3.49–3.52).

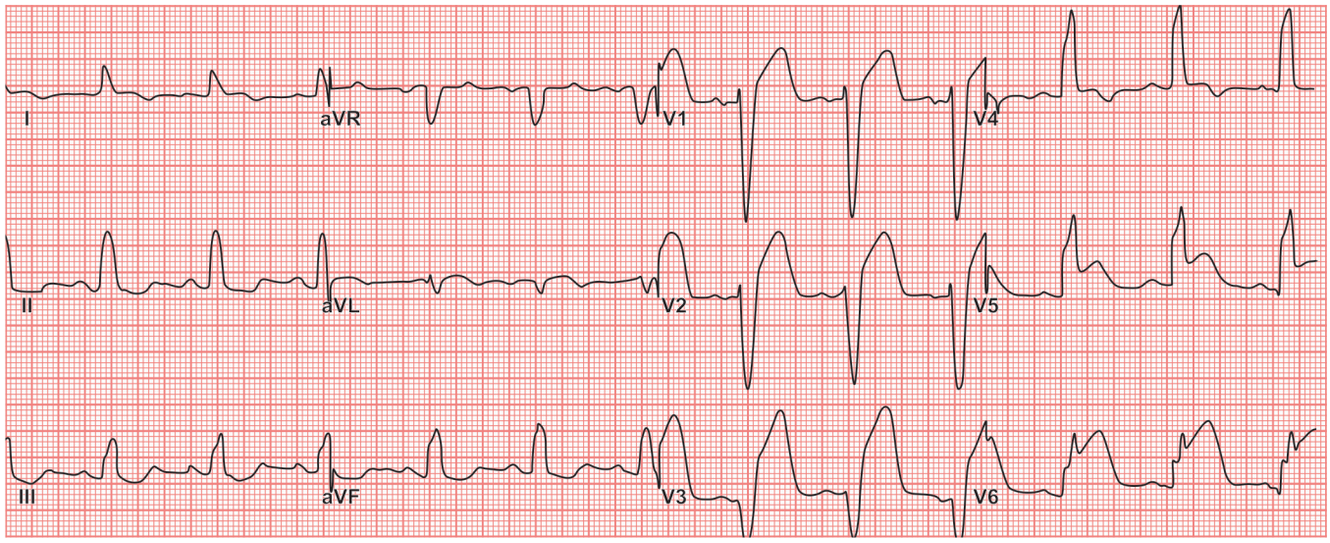

Fig. 3.30: Acute anteroseptal myocardial infarction—see the tall T-waves in V2–V4

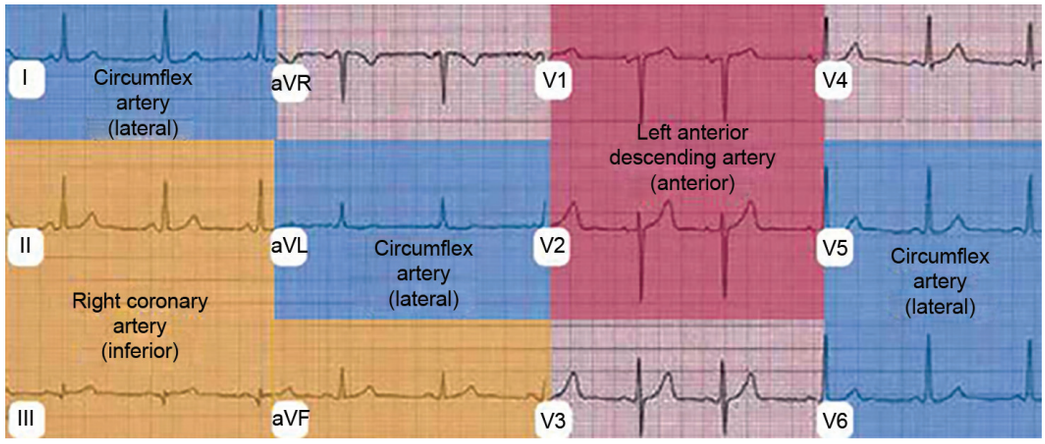

Fig. 3.31: Color map showing regional involvement of heart in relation to branches of coronary arteries involved

Table 3.2: ECG changes during myocardial infarction

Location of MI	Leads affected	Vessel involved	ECG changes
Anterior wall	V2–V4	• Left anterior descending artery (LAD) – Diagonal branch	• Poor R-wave progression • ST-segment elevation • T-wave inversion
Septal wall	V1 and V2	• Left anterior descending artery (LAD) – Septal branch	• R-wave disappears • ST-segment rises • T-wave inverts
Lateral wall	I, aVL, V5, V6	• Left coronary artery (LCA) – Circumflex branch	• ST-segment elevation
Inferior wall	II, III, aVF	• Right coronary artery (RCA) – Posterior descending branch	• T-wave inversion • ST-segment elevation
Posterior wall	V1–V4	• Left coronary artery (LCA) – Circumflex branch • Right coronary artery (RCA) – Posterior descending branch	• Tall R-waves • ST-segment depression • Upright T-waves

Coronary Angioscopy and Optical Coherence Tomography

These investigations are helpful when others fail to contribute in the final diagnosis of acute coronary syndrome (Figs 3.53–3.54).

Cardiac MRI in Acute Coronary Syndrome

Resting cardiac MRI exhibited diagnostic operating characteristics suitable for triage of patients with chest pain in the emergency department. Performed urgently to evaluate

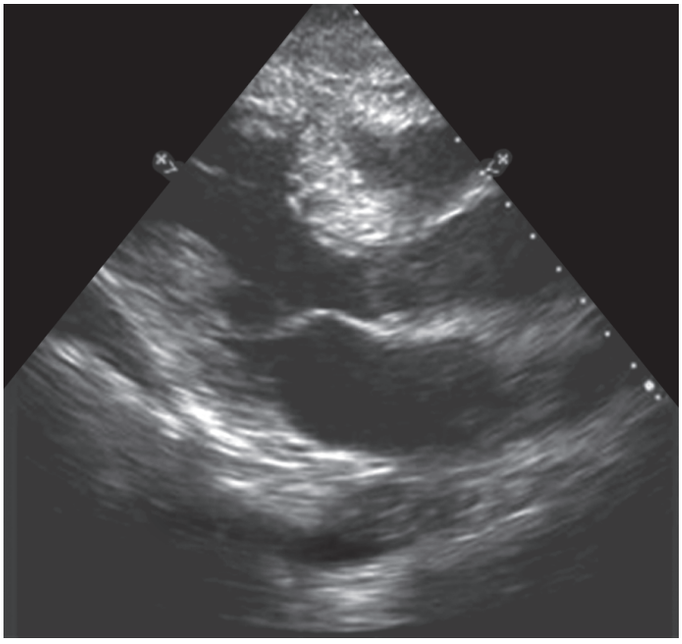

Fig. 3.32: Regional wall motion abnormalities in LAD territory in ACS

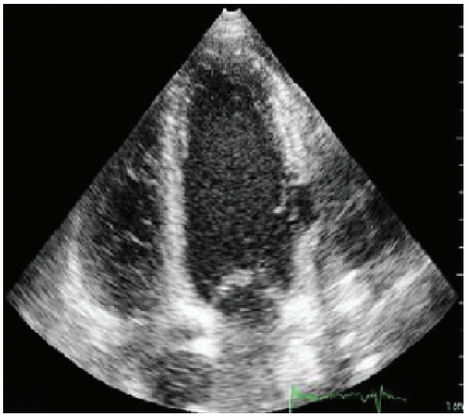

Fig. 3.33: This is a case of acute coronary syndrome in a patient with respiratory tract infection further complicated by a mechanical complication. The clinical setting led to the misdiagnosis of acute myocarditis and the proper treatment was delayed until a mechanical complication of the myocardial infarction appeared. This case indicates the multiplicity of clinical conditions that might complicate an acute coronary syndrome and obscure early diagnosis and treatment

chest pain, MRI accurately detected a high fraction of patients with acute coronary syndrome, including patients with enzyme-negative unstable angina (Figs 3.55–3.58).

Complications in ACS

Complications of ischemia include pulmonary edema, while those of myocardial infarction include rupture of the papillary muscle, left ventricular free wall, and ventricular septum (Figs 3.59–3.70).

Arrhythmias

Classification of peri-infarction arrhythmias: Peri-infarction arrhythmias can be broadly classified into the following categories (Figs 3.59–3.65 and Table 3.3):

- **Supraventricular tachyarrhythmias,** including sinus tachycardia, premature atrial contractions, paroxysmal supraventricular tachycardia, atrial flutter, and atrial fibrillation
- **Accelerated junctional rhythms**
- Bradyarrhythmias, including sinus bradycardia and junctional bradycardia
- **Atrioventricular (AV) blocks,** including first-degree AV block, second-degree AV block, and third-degree AV block
- **Intraventricular blocks,** including left anterior fascicular block, right bundle branch block (RBBB), and left bundle branch block (LBBB)
- **Ventricular arrhythmias,** including premature ventricular contractions (PVCs), accelerated idioventricular rhythm, ventricular tachycardia, and ventricular fibrillation
- **Reperfusion arrhythmias**

Ventricular Arrhythmias

Ventricular arrhythmias are a frequent cause of death in the earliest stages of acute myocardial infarction. The development of coronary care units, continuous ECG surveillance, and defibrillators in the 1960s led to a reduction in mortality from acute myocardial infarction through the prompt identification and treatment of ventricular arrhythmia; and emergency medical technicians have reduced outpatient mortality in the earliest minutes of myocardial infarction. In cities with well-developed emergency response systems, such as Seattle, Washington, and Rochester, Minnesota, where the average response time is less than 5 minutes, survival of patients with myocardial infarction complicated by cardiac arrest has increased. In fact, long-term survival of patients who have undergone rapid defibrillation after out-of-hospital cardiac arrest is similar to that of age-, sex-, and disease-matched patients who did not have out-of-hospital cardiac arrest; the quality of life of the majority of survivors is similar to that of the general population.

Ventricular Fibrillation

In the setting of acute myocardial infarction, ventricular fibrillation is often described as either primary, when it occurs in the absence of hypotension or heart failure, or secondary, when hypotension or heart failure is present. Primary ventricular fibrillation occurs in approximately 3–5% of patients with acute myocardial infarction; the peak incidence is in the first 4 hours of infarction. Primary ventricular fibrillation is infrequent more than 24 hours after symptom onset. Mortality is increased in patients who suffer this complication. In patients who are successfully resuscitated and survive to hospital discharge, however,

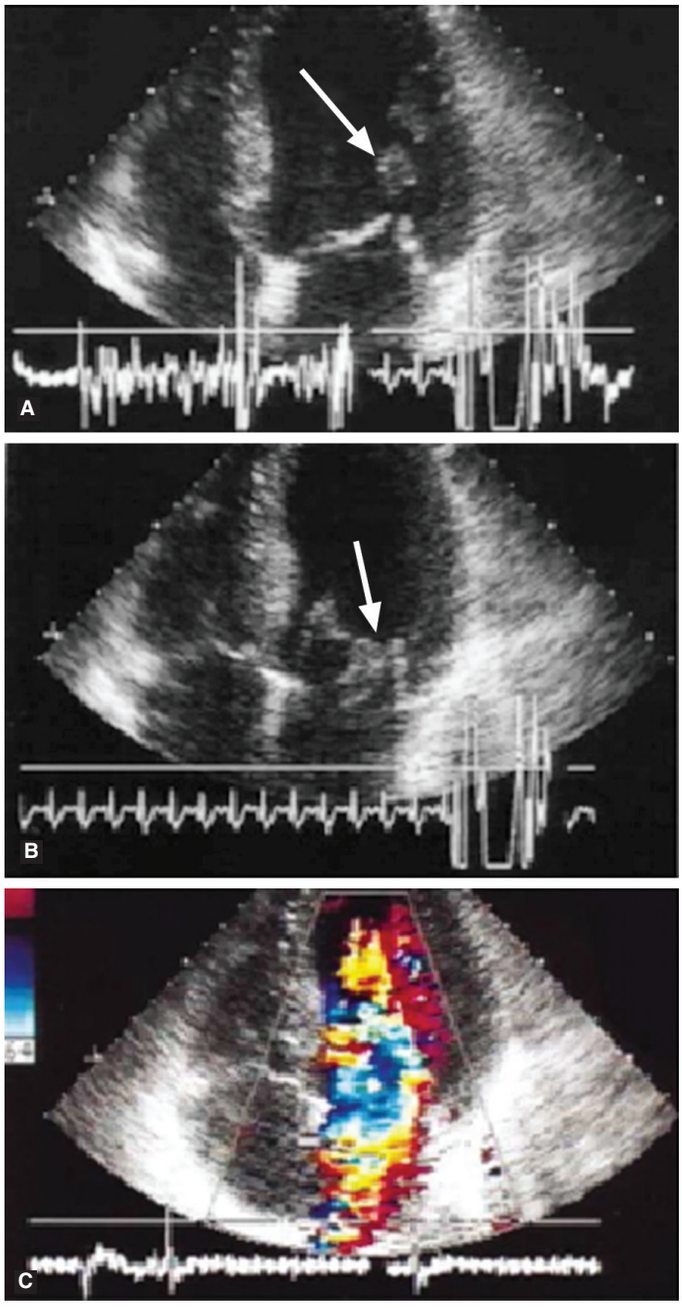

Fig. 3.34: Transthoracic echocardiography showed complete rupture of the anterolateral papillary muscle (arrow in A), prolapse of the muscle into the left atrium (arrow in BI), and severe mitral regurgitation (C)

the long-term prognosis does not appear to be affected. Although lidocaine was shown to reduce the occurrence of primary ventricular fibrillation, mortality in patients receiving lidocaine increased because of an increase in fatal bradycardia and asystole; therefore, prophylactic lidocaine is no longer recommended if defibrillation can rapidly be performed. Beta blockers may reduce the early occurrence of ventricular fibrillation and should be administered to patients who have no contraindications.

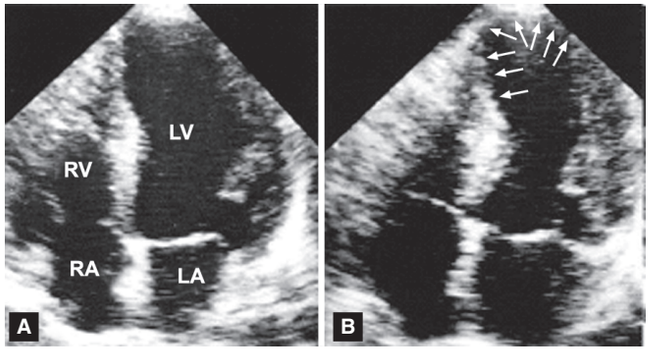

Fig. 3.35: Echocardiographic wall motion abnormality coronary artery disease. (A) Two-dimensional echocardiographic apical four-chamber view at end-diastole. (B) Two-dimensional echocardiographic apical four-chamber view at end-systole. The right ventricle (RV) and the septal and lateral walls at the base of the left ventricle (LV) demonstrate normal inward motion from diastole through systole; however, the distal septum and apex demonstrate akinesis (arrows in B). The wall motion. abnormality demonstrated in this frame was caused by ischemia from a lesion in the mid-left anterior descending artery. LA=left atrium; RA=right atrium

Hypokalemia is a risk factor for primary ventricular fibrillation and should be rapidly corrected if present. When ventricular fibrillation occurs, rapid defibrillation with 200–300 joules should be attempted, and repeated shocks of 360 joules should be administered. The advanced cardiac life support (ACLS) guidelines recommend medical therapy, including epinephrine, lidocaine, and bretylium; in addition, IV amiodarone should be considered in patients in whom defibrillation is initially unsuccessful. Secondary ventricular fibrillation is associated with a high mortality, in part because of the underlying hypotension and heart failure. Treatment must be aimed not only at terminating the arrhythmia but also at treating the hemodynamic abnormalities and their causes.

Ventricular Tachycardia

Ventricular tachycardia (three or more consecutive ventricular ectopic beats) is common in patients with acute myocardial infarction; however, short runs of nonsustained ventricular tachycardia are no longer believed to predispose a patient to sustained ventricular tachycardia or ventricular fibrillation. In patients in whom sustained or hemodynamically significant ventricular tachycardia occurs, prompt electrical cardioversion should be performed. If the ventricular tachycardia is monomorphic, synchronic cardioversion with 100 joules should first be attempted. As with ventricular fibrillation, polymorphic ventricular tachycardia should be treated with unsynchronized discharge. Prolonged runs of asymptomatic ventricular tachycardia can be initially treated with IV lidocaine, procainamide, or amiodarone. These medications may also be helpful in reducing recurrent ventricular tachycardia.

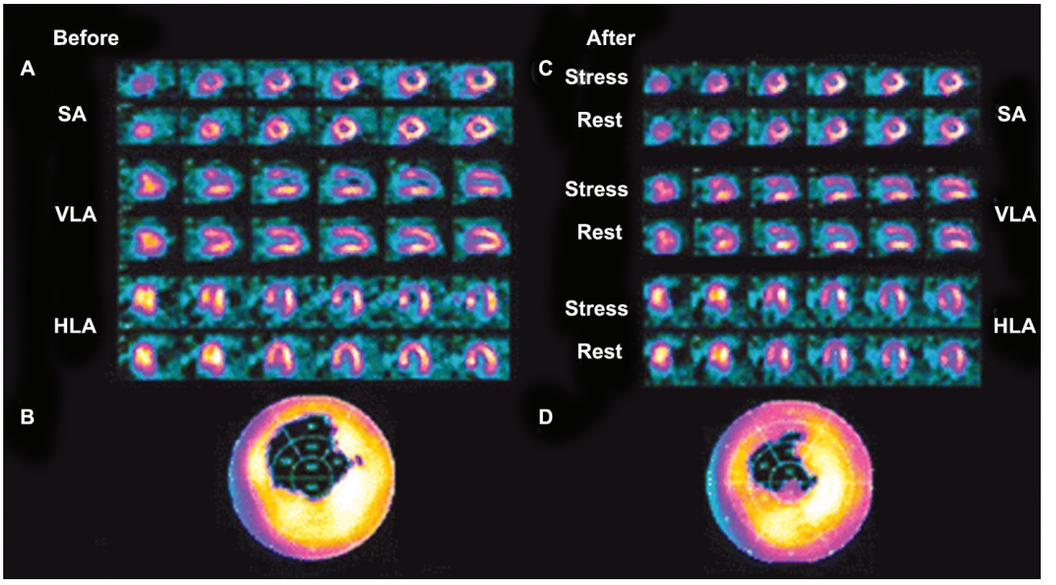

Fig. 3.36: Baseline and follow-up stress/rest SPECT sestamibi MPI after medical therapy. (A) A patient's baseline stress/rest SPECT sestamibi perfusion images showing large ischemia of the left anterior descending artery territory; the top rows show stress images and the bottom rows show rest images. (B) Polar maps estimated the extent of total ischemia to be 31% of left ventricular myocardium. The left ventricular ejection fraction was 62% by gated SPECT. (C) SPECT sestamibi MPI at 6-month follow-up with maximal medical therapy including statin, beta-blockers, and nitrates. The ischemia (same format as A) is less. (D) Polar maps estimated extent of total abnormality to be 21%, ischemia 16%, and scar 5%. The left ventricular ejection fraction was 67%. HLA=horizontal long axis; MPI=myocardial perfusion imaging; SAX=short axis; SPECT=single-photon emission computed tomography; VLA=vertical long axis

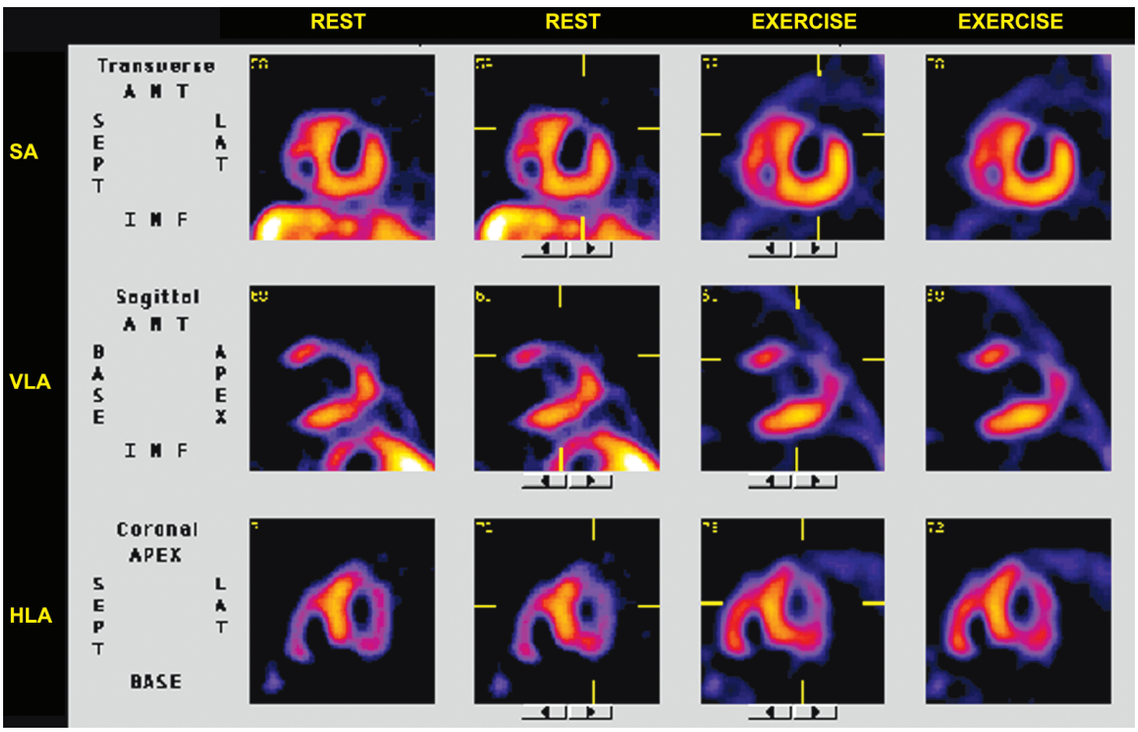

Fig. 3.37: Eleven days after PTCA, a second rest-exercise myocardial scintigraphy with Tc-99m sestamibi showed a fixed perfusion defect in the anterolateral segment of the left ventricle (shown by thin arrows) with no other significant abnormalities. Ischemia in the apical portion of the anterior wall is no longer seen (thick arrows). (The second study was obtained with different system than the first study.) A concomitant echocardiographic study demonstrated left ventricle hypertrophy with an ejection fraction of approximately 61%, hypokinesis of the anterolateral wall and abnormal septal motion

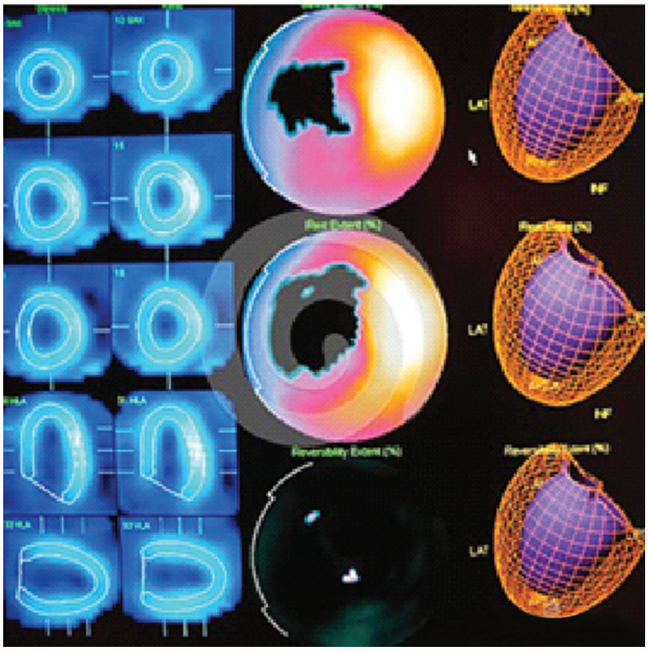

Fig. 3.38: Myocardial perfusion nuclear scan, rest and stress part presented myocardial scar as evidence of heart attack in past, the black spots are on both parts of test in the same areas of upper and lower circles of image

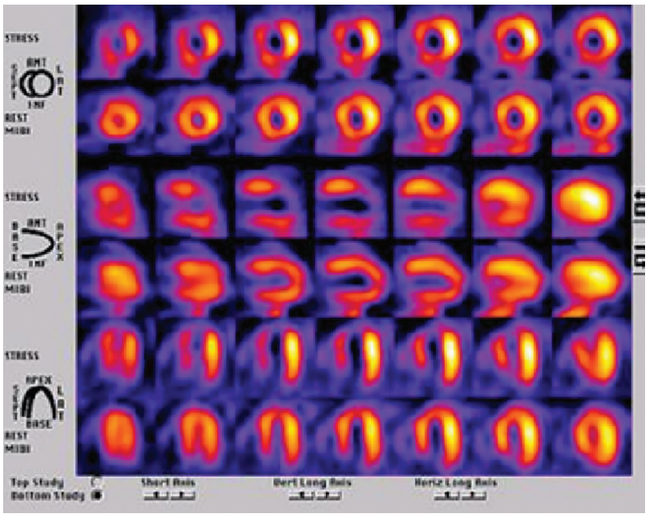

Fig. 3.39: A SPECT perfusion study in a patient with a large degree of tracer redistribution affecting the left anterior descending and right coronary artery territories

ATRIAL ARRHYTHMIA

Atrial Fibrillation

Atrial fibrillation is the most common atrial arrhythmia in acute myocardial infarction, occurring in 10–16% of patients. Atrial fibrillation may result either from an acute increase in left atrial pressure caused by left ventricular dysfunction or from atrial ischemia as a result of occlusion of a coronary artery (usually the right coronary artery) proximal to the origin of atrial branches. The incidence of

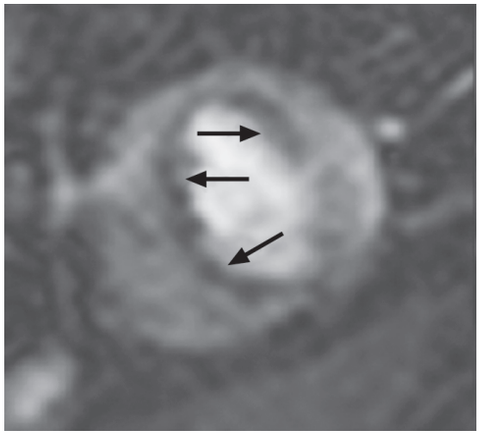

Fig. 3.40: Perfusion defect in myocardial infarction. Short-axis SSFP first-pass perfusion imaging at rest in a 43-year-old male with chest pain shows a perfusion defect (arrows) in the apical anterior, septal, and inferior segments (arrows), consistent with myocardial infarction in left anterior descending (LAD) artery territory

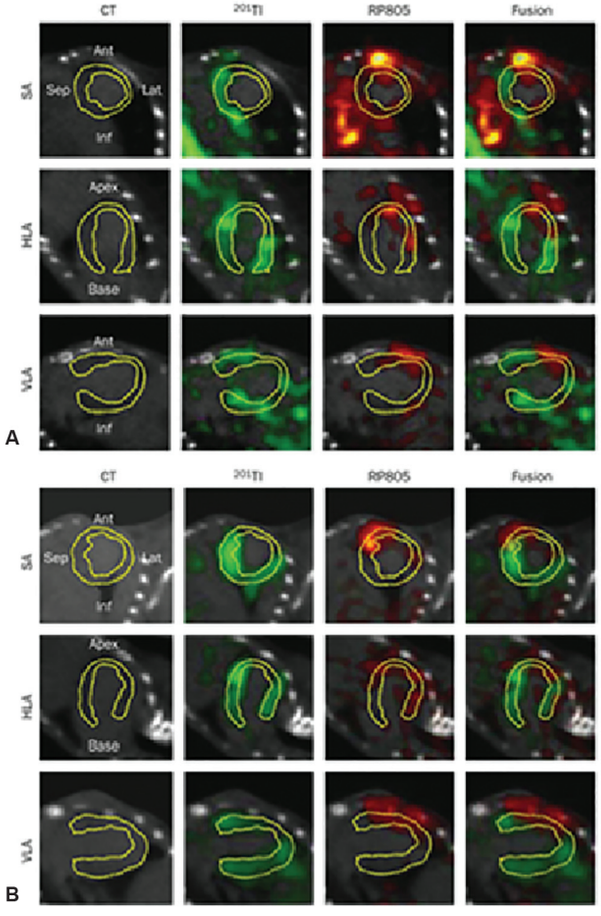

Fig. 3.41: The contrast agent permitted better definition of the left ventricular myocardium (highlighted by yellow line). Representative short-axis (SA), horizontal long-axis (HLA), and vertical long-axis (VLA) images are shown. Focal uptake of 99mTc-RP805 targeted at matrix metalloproteinases is seen within the central infarct and peri-infarct regions, which corresponds to 201Tl perfusion defect

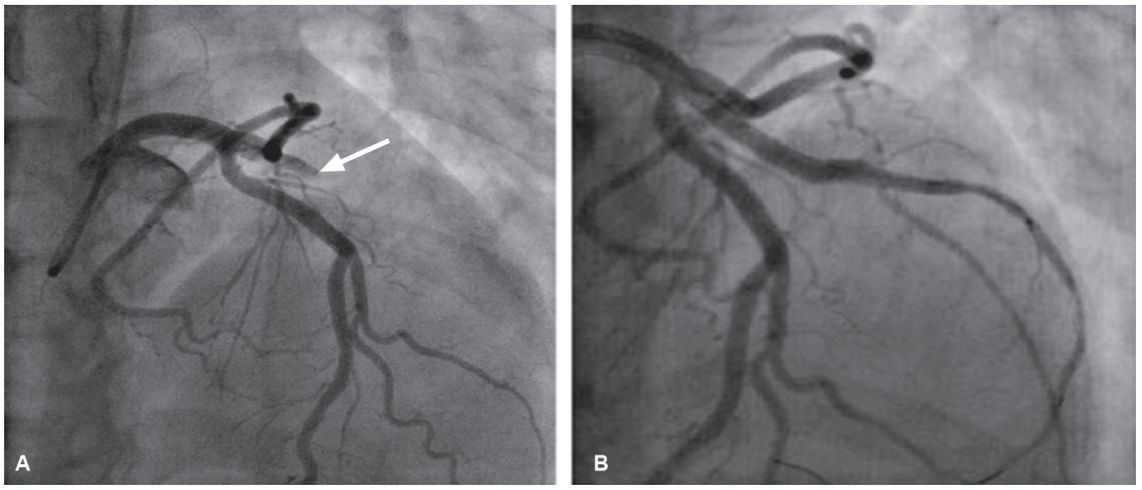

Fig. 3.42: Occlusive concomitant dissections of the carotid and coronary arteries treated with stent placement in a 60-year-old male with ACS

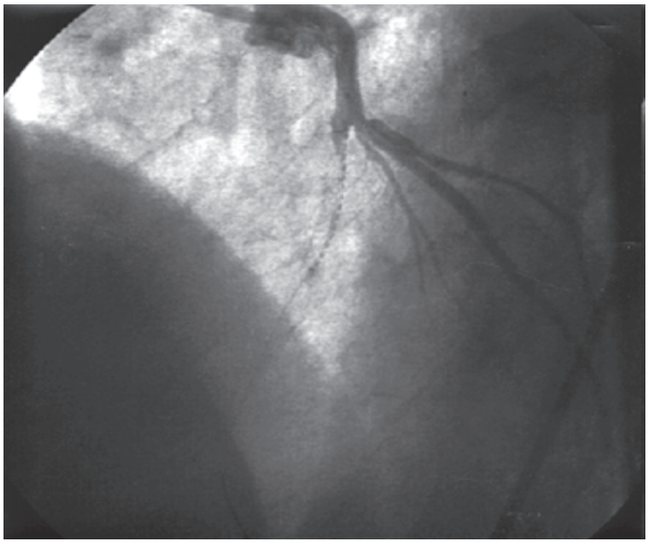

Fig. 3.43: Left selective coronary angiogram in left anterior oblique cranial projection (48° LAO, 33° ocranial) showing the no-reflow phenomenon in the LAD after stent deployment

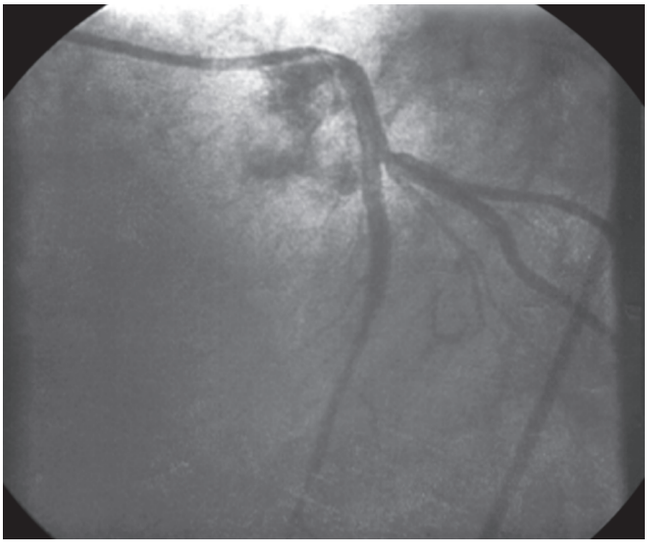

Fig. 3.44: Left selective coronary angiogram in left anterior oblique cranial projection (48° LAO, 33° cranial) showing TIMI 3 flow in LAD after balloon angioplasty and stenting of severe distal disease

atrial fibrillation is decreased in patients given thrombolytic therapy.

The treatment of atrial fibrillation in acute myocardial infarction should be similar to the treatment of atrial fibrillation in other settings. When there is hemodynamic compromise caused by loss of atrial systole or a rapid ventricular response with a reduction.

In cardiac output, cardioversion should be performed immediately. In patients with preserved left ventricular function in whom the atrial fibrillation is well tolerated, beta-blocker therapy is indicated. Verapamil and diltiazem may also be effective in such patients. In patients with congestive heart failure (CHF), digoxin is a reasonable alternative and may slow the ventricular response. If atrial fibrillation recurs, antiarrhythmic agents may be used, although their impact on clinical outcomes is unproved. The atrial fibrillation follow-up investigation of rhythm management (AFFIRM) investigators randomized 4,060 patients to either rhythm-control or rate-control treatment strategies. The rhythm-control strategy achieved no survival advantage over the rate-control strategy and there were both fewer hospital admissions and fewer adverse drug reactions in the rate-control group.

Bradyarrhythmias and Heart Block

Sinus bradycardia is common in acute myocardial infarction, particularly in patients with inferior myocardial infarction. However, treatment with atropine and a temporary pacemaker is required infrequently and, generally,

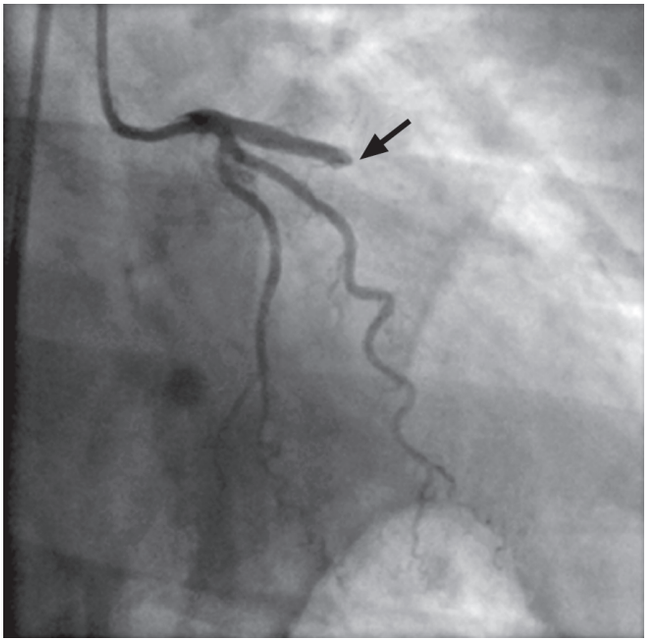

Fig. 3.45: Angiography revealed obstruction (arrow) in LAD artery in patient with acute myocardial infarction

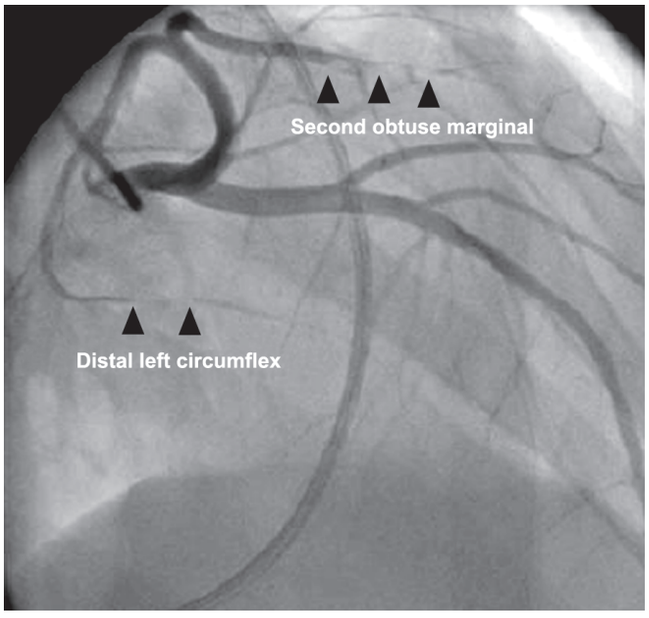

Fig. 3.47: Coronary angiogram showing an RAO cranial view of the left coronary artery and its branches, the left circumfled (LCX) and the left anterior descending arteries. Multiple thrombi are noted within the LCX arterial system (arrowheads)

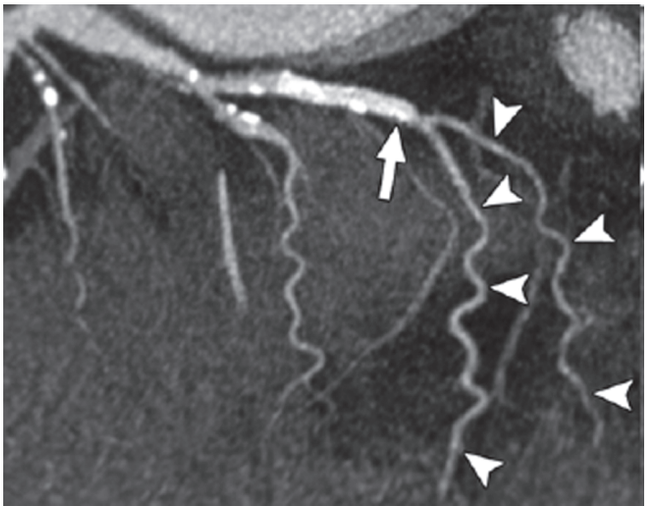

Fig. 3.46: Multiplanar reformation image of coronary artery shows stent implantation (arrow) and good enhancement over distal branches of circumflex artery (arrowheads)



Fig. 3.48: A 75-year-old woman with unstable angina pectoris and three-vessel disease. Coronary angiography image shows severe stenosis at proximal portion (arrowhead) and total occlusion of distal portion and collateral vessels to distal LAD branch. Coronary angiography could not clear culprit lesion because there were critical stenoses in three vessels

only in patients with significant hemodynamic compromise manifested by increased angina, hypotension, or congestive heart failure. High-degree (second- or third-degree) heart block occurs in approximately 20% of patients with inferior infarction; it is uncommon with infarction at other sites. About half of the cases of heart block seen with inferior infarction are Wenckebach-type second-degree heart block; the remainder are cases of third-degree heart block. The heart block is often easily treated with atropine, but a temporary pacemaker is required in as many as 50% of cases. The heart block generally lasts for hours to days; placement of a permanent pacemaker is needed in fewer than 1% of cases. However, the development of heart block with inferior infarction is associated with a threefold to fourfold increase in in-hospital mortality over inferior

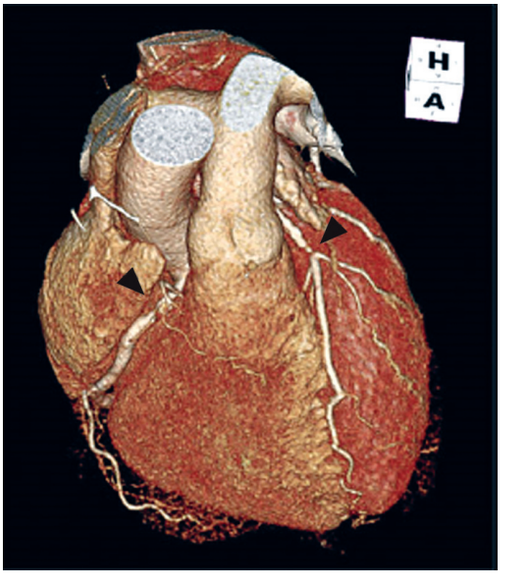

Fig. 3.49: 64-slice computed tomography can detect severe coronary artery stenosis (arrowheads)

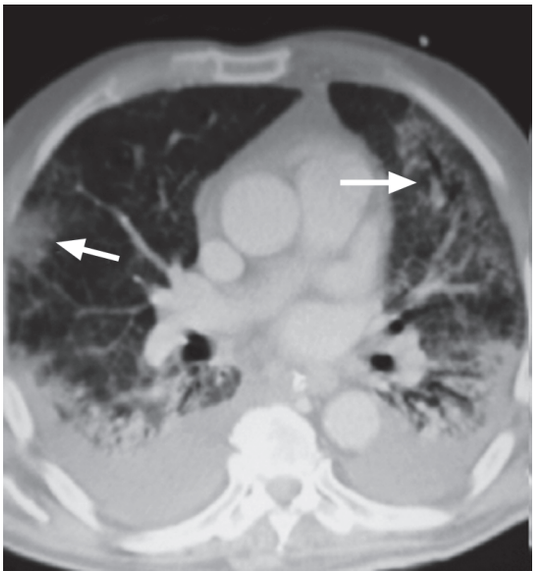

Fig. 3.50: An old man of 76 years with acute coronary syndrome. CT scan taken several days after showed ground-glass patch lesions (arrows) due to pulmonary hemorrhage and parenchymal opacifications interpreted as adult respiratory distress syndrome

infarction without heart block. The increased mortality appears to result from the association between heart block and more severe left and right ventricular infarction rather than from the heart block itself or treatment of the heart block. Heart block during anterior infarction is uncommon, occurring in fewer than 1% of cases. It is generally associated with extensive left ventricular myocardial infarction involving the conduction system below the atrioventricular node and carries a very poor prognosis.

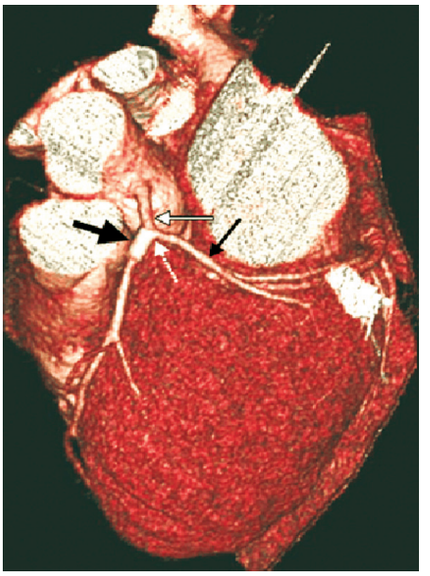

Fig. 3.51: A 59-year-old man 2 days after percutaneous transluminal coronary angioplasty and stent placement in proximal left anterior descending artery. Volume-rendered CT angiogram shows stent in proximal left anterior descending artery (thick black arrow). Note protrusion of proximal end of stent (dotted white arrow) into proximal left circumflex artery (thin black arrow). Also note left main coronary artery (solid white arrow)

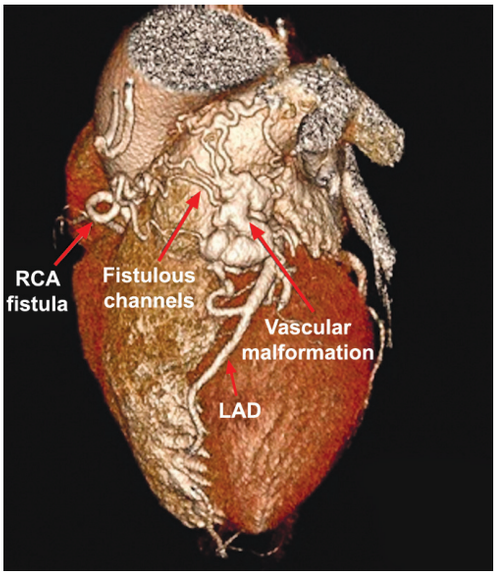

Fig. 3.52: Acute coronary syndrome in a patient with a large intercommunicating coronary vascular malformation: imaging with 320-slice CT

Mitral Regurgitation

Mitral regurgitation may result from injury to any of the components of the mitral valve apparatus, including the papillary muscles and ventricular walls to which they attach. Mild mitral regurgitation is common in acute myocardial infarction and is present in nearly 50% of patients. Severe mitral regurgitation caused by acute

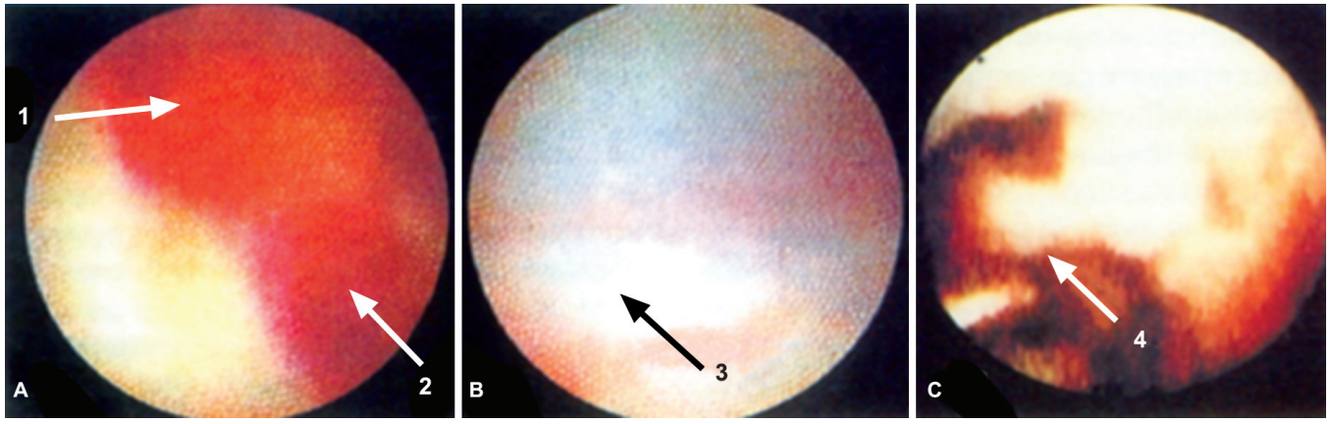

Fig. 3.53: Angioscopy shows (A) a red thrombus on a plaque (1) blocking a part of the lumen (2) after removal of thrombus and plaque with atherectomy, (B) a white flap is visible (3) post-angioplasty angioscopy, (C) can show a dissecting flap (4) within the lumen

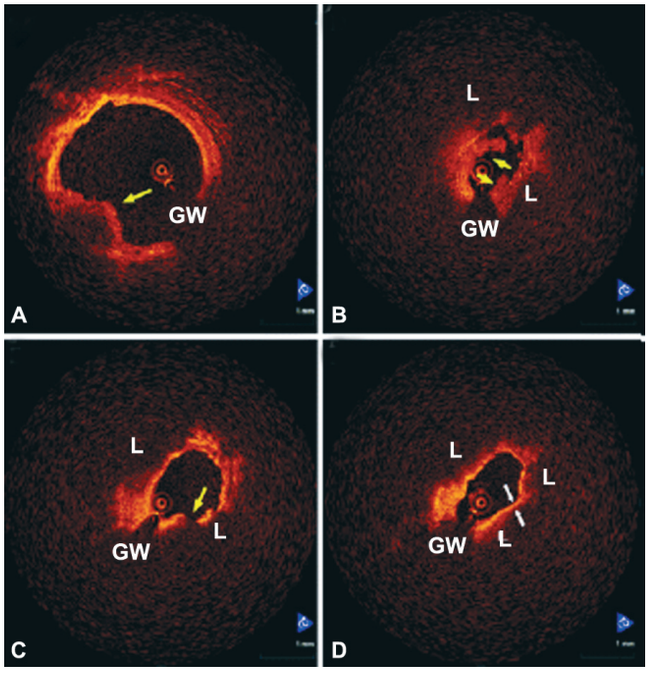

Fig. 3.54: Multiple plaque morphologies assessed by optical coherence tomography in a patient with acute coronary syndrome

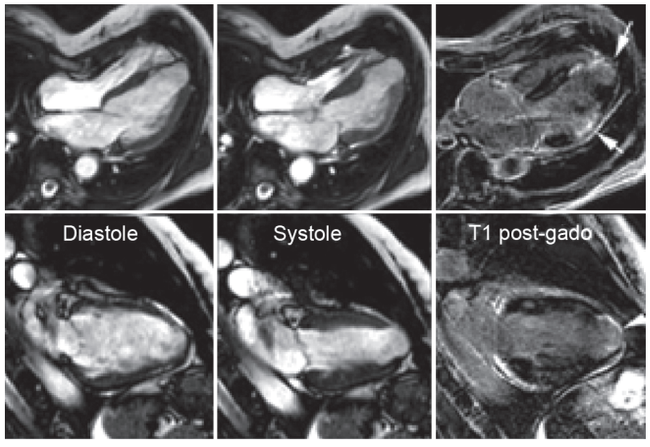

Fig. 3.55: Cine-MR four-chamber and vertical long-axis diastolic and systolic views, with marked left ventricular wall thinning and dyskinesia at the apex and at the mid-lateral part of the left ventricle. T1-weighted images 10 minutes after gadolinium injection (right panel) show transmural hyper-enhancement in the same apical and lateral segments, related to gadolinium retention in scarred infarcted tissue (arrows)

myocardial infarction is rare and generally results from partial or complete rupture of a papillary muscle. The characteristic murmur of severe chronic mitral regurgitation may not be present with acute rupture of a papillary muscle. Instead, a decrescendo systolic murmur is often present, extending less throughout systole as systemic arterial pressure falls and left arterial pressure rises. In many cases, the significance of the murmur is not recognized. The blood supply of the anterior papillary muscle arises from branches of both the left anterior descending and the circumflex arteries; therefore, rupture of the anterior papillary muscle is rare. However, the posterior papillary muscle receives blood only from the dominant coronary artery (the right coronary artery in nearly 90% of patients); thrombotic occlusion of this artery may cause rupture of the posterior papillary muscle, resulting in severe mitral regurgitation. Severe mitral regurgitation is 10 times more likely to occur with inferior infarction than with anterior infarction. Acute severe mitral regurgitation is poorly tolerated and generally results in pulmonary edema, often with cardiogenic shock. Prompt surgical repair is recommended. Although the mortality associated with mitral valve surgery is high in this setting, approaching 50%, survival appears to be greater than with medical therapy alone. Therapy aimed at reducing left ventricular afterload, such as use of IV nitroprusside and an intra-aortic balloon pump, reduces the regurgitant volume and increases forward blood flow and cardiac output and may be helpful as a temporizing measure.

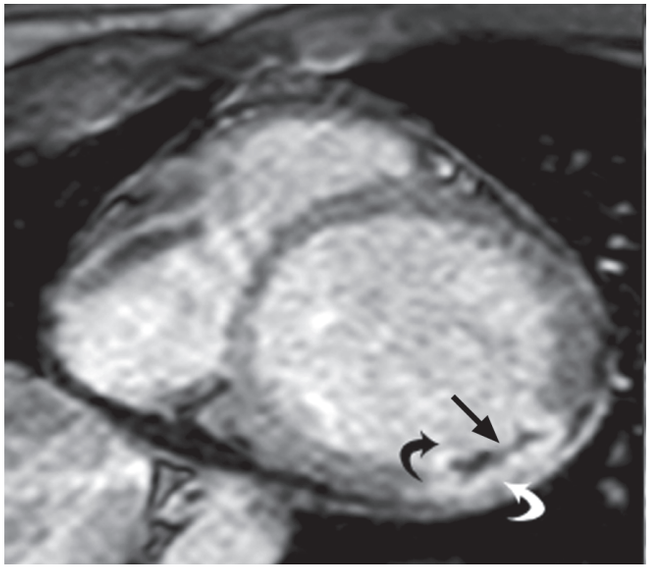

Fig. 3.56: Microvascular obstruction. Short-axis PSIR image in a 47-year-old male with acute chest pain and ST-segment elevation reveals dark nonenhancing tissue (straight arrow) located within bright enhancing scar (curved arrow), consistent with microvascular obstruction within an area of myocardial infarction in the left circumflex artery territory

Ventricular Septal Defects (Figs 3.66–3.68)

Ventricular septal defects are slightly more frequent in patients with anterior infarction than in patients with inferior infarction. The characteristic holosystolic murmur of ventricular septal defects may be difficult to distinguish from that of severe mitral regurgitation; however, ventricular septal defects are generally better tolerated and less frequently result in severe congestive heart failure. Surgical repair is recommended and results in the best outcome when repaired emergently in the hemodynamically compromised patient. As with acute severe mitral regurgitation, therapy aimed at reducing afterload, including IV nitroprusside and an intra-aortic balloon pump, may be beneficial. Repair of the septum is generally

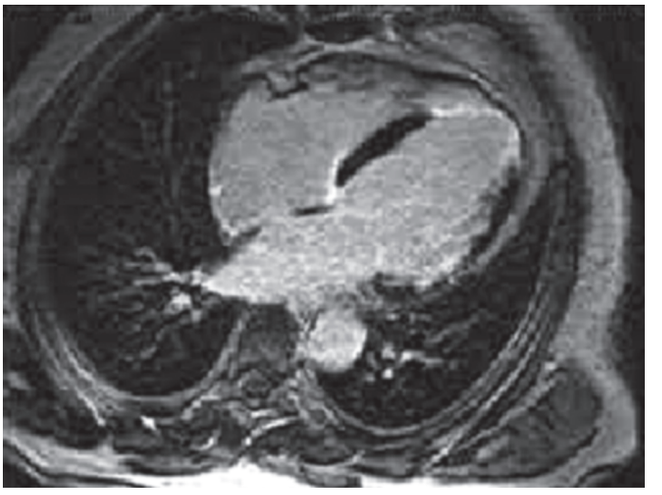

Fig. 3.58: Four-chamber view with the late enhancement technique in a patient with myocardial infarction. 10 minutes after contrast agent injection normal myocardium remains black, whereas fibrosis enhances due to the accumulation of contrast agent in the enlarged interstitial space. Note the transmural infarction in the apex and the subendocardial pronounciation of the infarction in the lateral wall

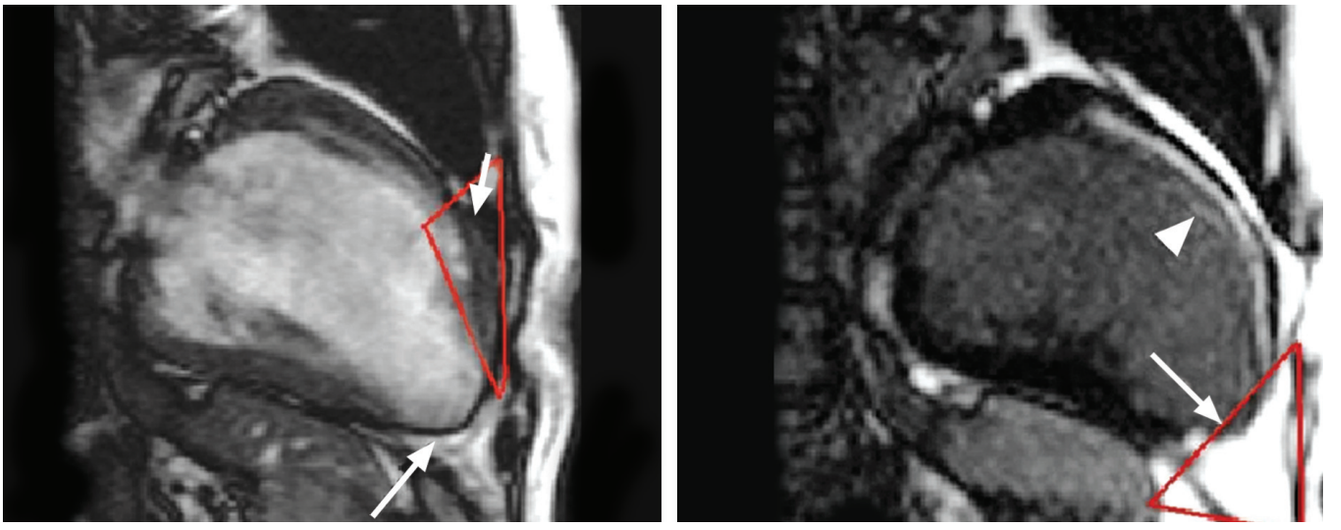

Fig. 3.57: Cardiac MRI to determine myocardium viability before revascularization. The whole concept of viability on cardiac MRI is based on the fact that all infarcts enhance vividly 10–15 minutes after intravenous contrast administration. Cardiac MRI shows the transmural extent of the infarct very reliably. It tells you that: *'white is dead' (all infarcts irrespective of age enhance)* in areas of hypokinesia, if there is a rim of 'black' or non-infarcted myocardium that is not contracting well, it indicates the presence of hibernating myocardium, which is likely to improve after revascularization of the artery supplying that particular territory. Viability imaging reliably allows identification of areas of hibernation and viable or nonviable myocardium. All infarcts irrespective of age enhance. The percentage involvement of the myocardial wall thickness by an infarct determines viability

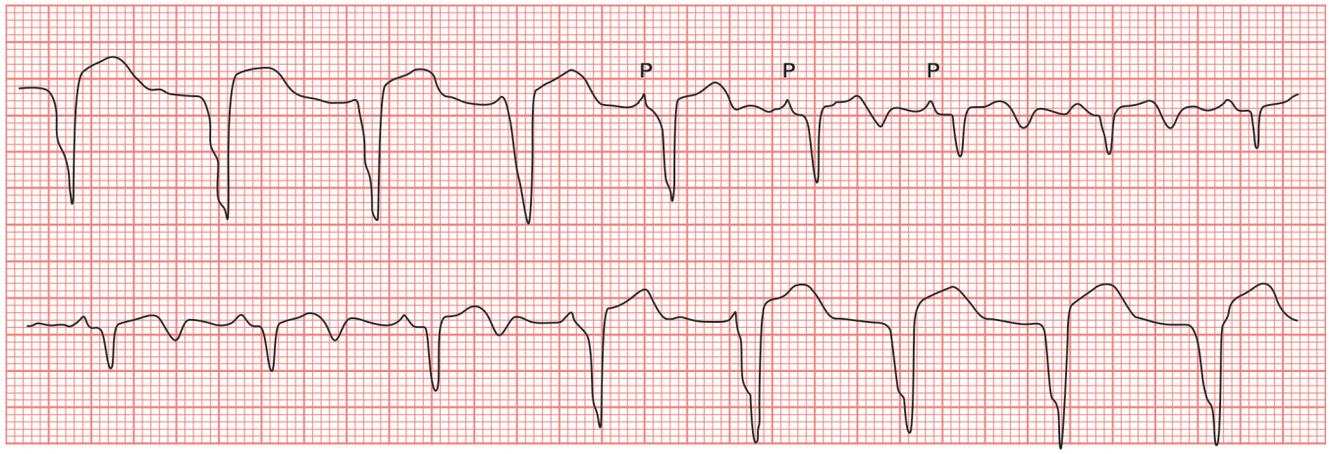

Fig. 3.59: Accelerated idioventricular rhythm (AIVR) in a patient with an acute inferior wall infarction. The first four beats show the typical pattern, followed by a return of sinus rhythm, then the reappearance of the AIVR. Notice that the fifth, sixth, twelfth, and thirteenth QRS complexes are 'fusion beats' because of the nearly simultaneous occurrence of a sinus beat and a ventricular beat (P/P-wave)

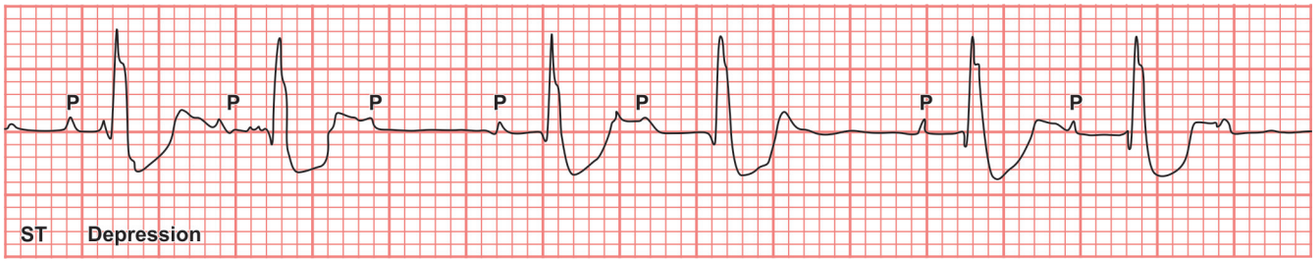

Fig. 3.60: Mobitz type 1 (Wenckebach) second-degree heart block in an acute myocardial infarction. The patient had a recent inferior infarct. The Wenckebach cycles are indicated in each of which progressive prolongation of the P–R interval culminates in a dropped beat

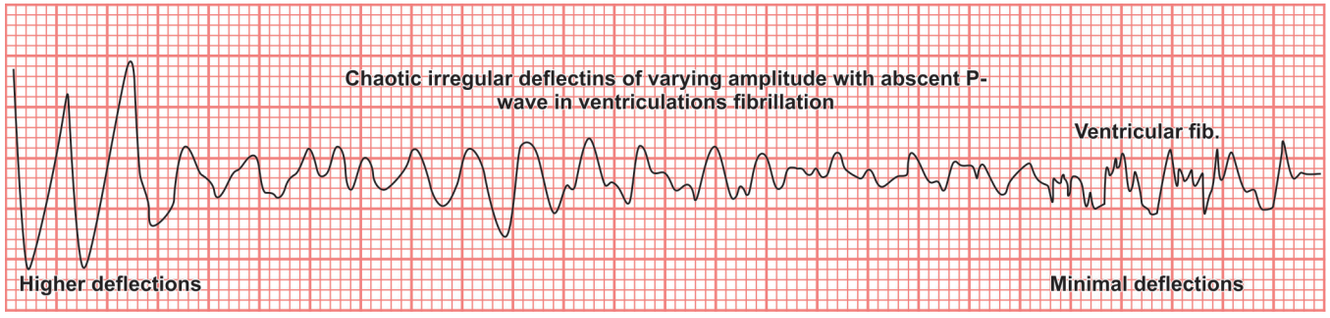

Fig. 3.61: Showing ventricular fibrillation. Chaotic irregular deflections of varying amplitude. No identifiable P-waves, QRS complexes or T-waves rate 150 to 500 per minute

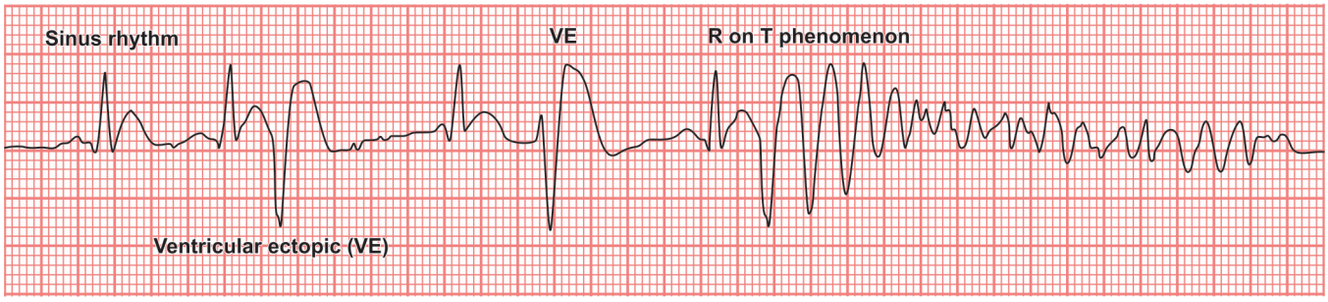

Fig. 3.62: ECG trace showing R on T phenomenon (arrow) giving rise to ventricular fibrillation (arrow) in AMI

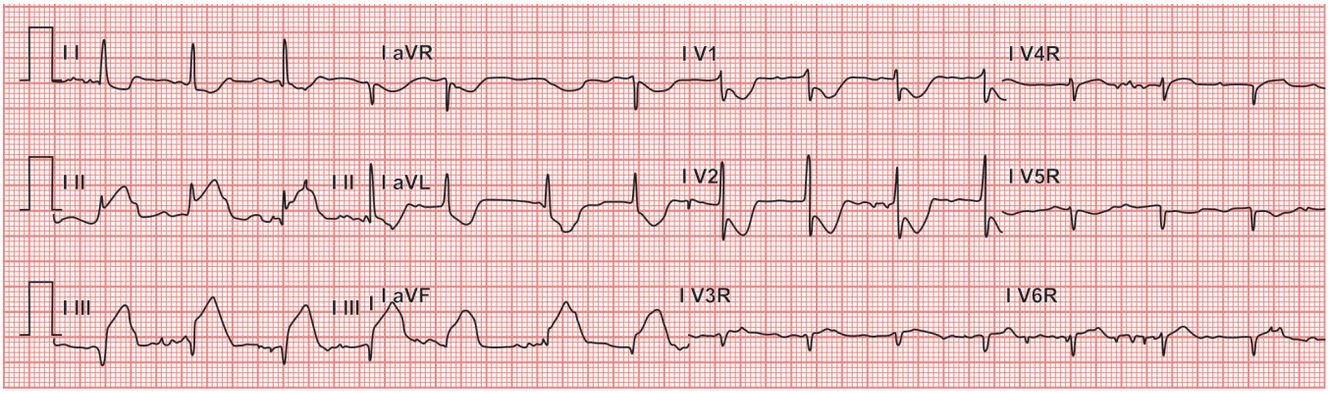

Fig. 3.63: ECG showing St-elevation in V3 and V4, II, III and aVF in a patient with right ventricular infarction

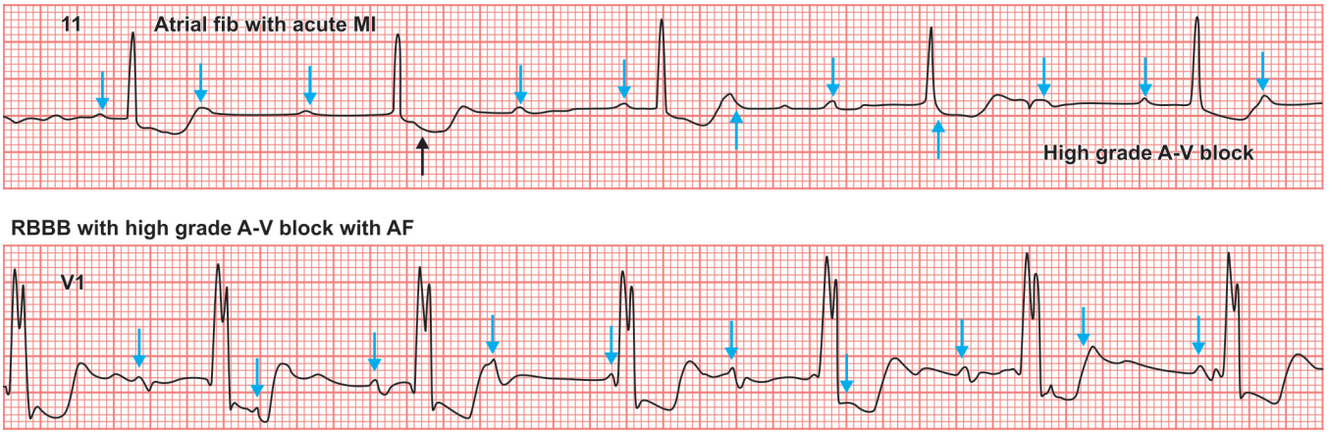

Fig. 3.64: ECG showing atrial fibrillation and high grade A-V block in patient with acute AMI who needed temporary pacemaker as an emergent life support

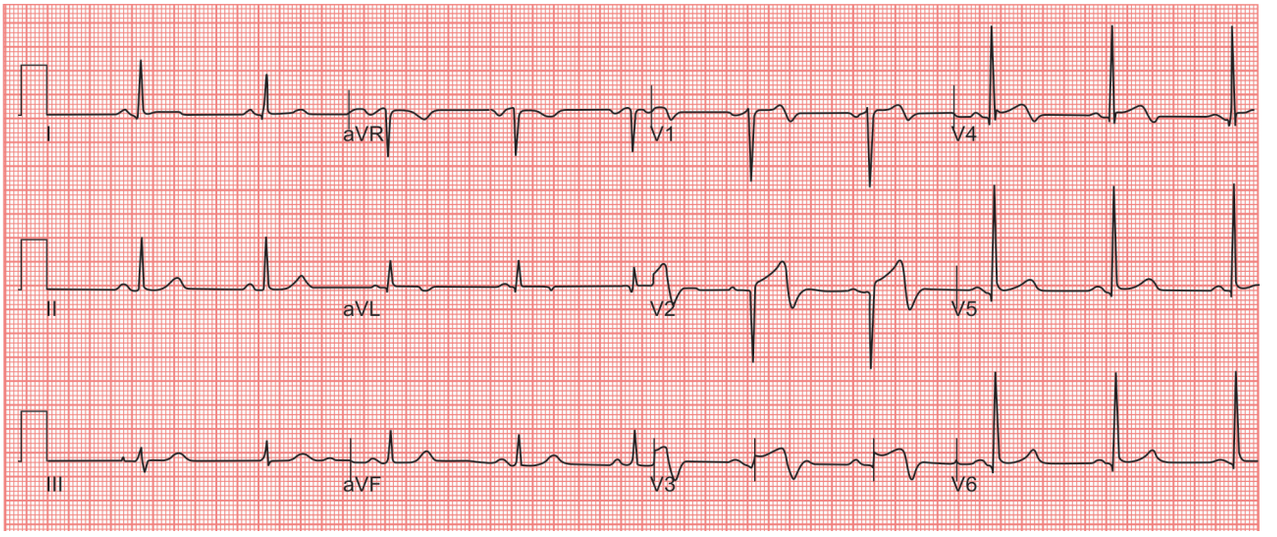

Fig. 3.65A: Wellens syndrome (type A pattern). Biphasic precordial T-waves with terminal negativity, most prominent in V2–3. Minor precordial ST elevation. Preserved R wave progression (R wave in V3 >3 mm)

more difficult when associated with inferior infarction, because there may not be a viable rim of myocardial tissue beneath the defect to facilitate repair. The surgical mortality associated with repair of a postinfarction ventricular septal defect is approximately 20%, but is largely related to the age of the patient, whether cardiogenic shock is present,

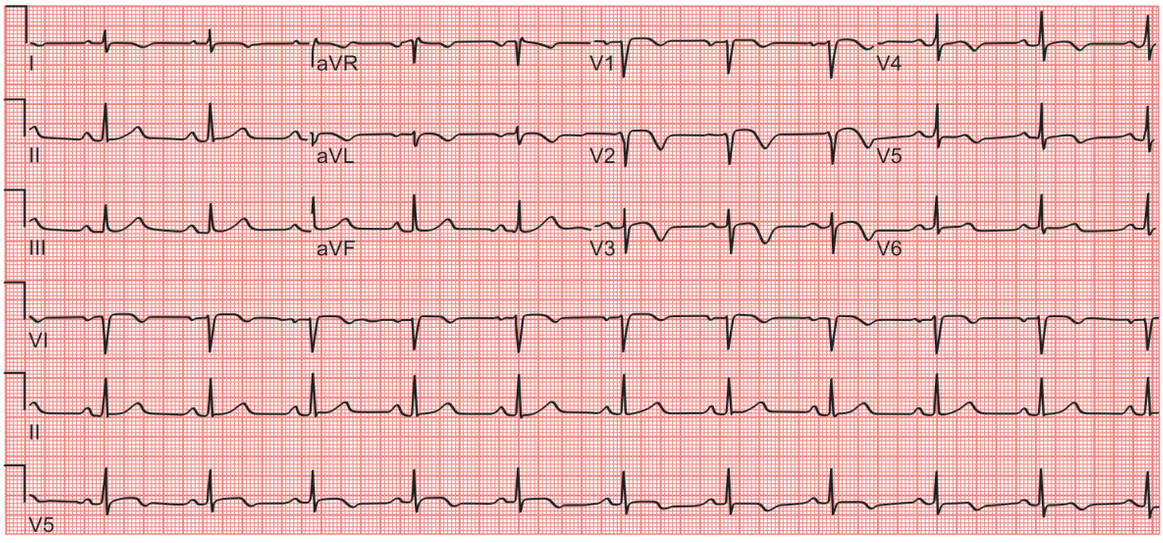

Fig. 3.65B: Wellens syndrome (type B pattern). There are deep, symmetrical T-wave inversions in leads V2–V3

Table 3.3: Indications of temporary pacing in acute MI

Class I

1. Asystole
2. Symptomatic bradycardia (includes sinus bradycardia with hypotension and type I second degree AV block with hypotension not responsive to atropine)
3. Bilateral bundle branch block [BBB; alternating BBB or right BBB (RBBB) with alternating left anterior fascicular block (LAFB) left posterior fascicular block (LPFB)] (any age)
4. New bundle branch block with Mobitz II second-degree AV block
5. RBBB plus fascicular block with Mobitz II second-degree AV block

Class IIa

1. Narrow QRS plus Mobitz II second-degree AV block
2. Old or new fascicular block with Mobitz II second degree AV block and anterior MI
3. Old bundle branch block and Mobitz II second degree AV block
4. New bundle branch block plus first-degree AV block
5. New bundle branch block plus Mobitz I second-degree AV block
6. RBBB plus LAFB or LPFB (new or indeterminate) with first-degree AV block
7. RBBB plus LAFB or LPFB (new or indeterminate) with Mobitz I second-degree AV block

Class IIb

1. Bifascicular block of indeteminate age and Mobitz II second-degree AV block
2. Old bundle branch block and first-degree AV block or second-degree AV block

Class III

1. First-degree heart block
2. Type I second-degree AV block
3. Accelerated idioventricular rhythm
4. BBB or fascicular block known to exist before acute myocardial infarction without conduction system disease

the infarction site, and the severity of the underlying coronary artery disease.

Myocardial Rupture

As more and more patients survive the acute phase of myocardial infarction because reperfusion therapy reduces myocardial infarct size, myocardial rupture has increased in frequency as a cause of early death. Myocardial rupture has been reported to account for more than 20% of in-hospital deaths in some series in the thrombolytic era. Physicians must have a heightened awareness of the diagnosis if a patient is to survive this catastrophic

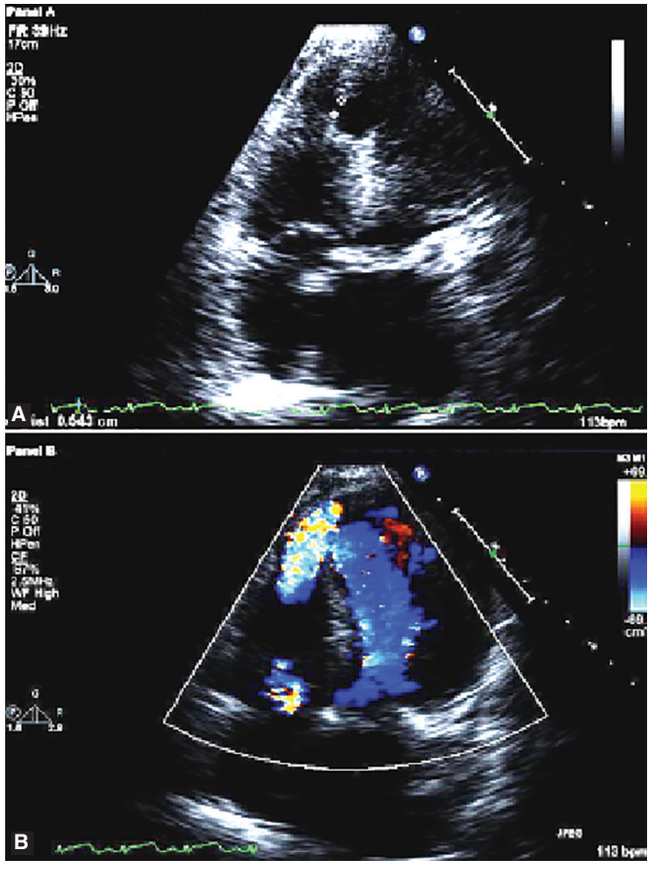

Fig. 3.66: Modified two-dimensional (A) echocardiogram and color flow Doppler image (B). Apical 4-chamber views show a breach in the interventricular septum and free communication between ventricles through a large apical septum ventricular septal defect in a patient who recently had an anterior myocardial infarction

occurrence, because emergency surgery is required. Symptoms suggestive of rupture include repetitive vomiting, pleuritic chest pain, restlessness, and agitation. ECG evidence of rupture includes a deviation from the normal pattern of ST-segment and T-wave evolution. Resolution of ST-segment elevation and T-wave inversion, with maximal T-wave negativity in the leads with maximal ST-segment elevation, should normally occur; however, in patients with rupture, there is progressive or recurrent ST-segment elevation and persistently positive T-wave deflections or reversal of initially inverted T-waves. Echocardiography can quickly confirm the diagnosis. Even when emergency surgery is performed, fewer than 50% of patients survive to discharge.

Right Ventricular Infarction

Right ventricular infarction occurs in approximately one-third of patients with acute inferior left ventricular infarction and is hemodynamically significant in approximately 50% of affected patients. Hemodynamically significant right ventricular infarction associated with anterior infarction or isolated right ventricular infarction is rare. The classic findings associated with hemodynamically significant right ventricular infarction are hypotension with clear lung fields and an elevated jugular venous pressure, often with the Kussmaul sign. Although, nearly all patients with right ventricular infarction suffer both right and left ventricular infarction, the characteristic hemodynamic findings of right ventricular infarction generally dominate the clinical course and must be the main focus of therapy. Right ventricular involvement during inferior myocardial infarction is associated with a significant increase in mortality, and aggressive attempts at early reperfusion should be pursued. Prompt recognition of right ventricular involvement is

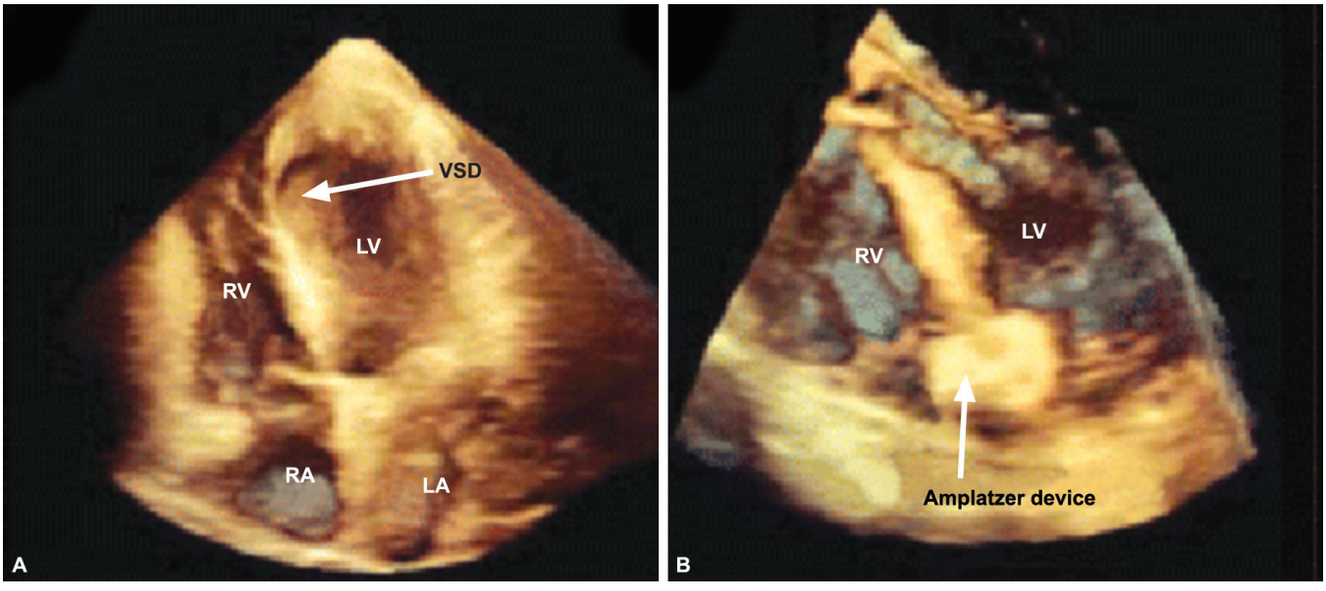

Fig. 3.67: Transcatheter closure of postmyocardial infarction muscular ventricular septal defects. Real-time 3D transthoracic echocardiography demonstrates the apical septal thinning and ventricular septal defect. (A) After the transcatheter closure, real-time 3D transoesophageal echocardiography demonstrates the final position of the deployed occluder device. (B) Adapted with permission from Halpern et al. LA, left atrium; LV=left ventricle; RA=right atrium; RV=right ventricle; VSD=ventricular septal defect

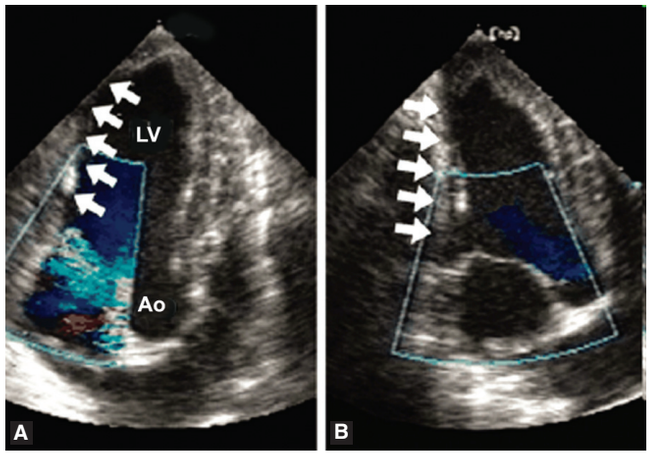

Fig. 3.68: Epicardial echocardiography 8 weeks after inferior infarction (A) and acutely after balloon-patch device placement (B). Before patching, the inferior wall bulges out, the posterior PM is displaced away from the annulus, and severe MR is seen. After patching, the inferior wall is straightened, the PM is realigned, and MR is absent. LV=left ventricle; Ao=aorta

clinically important because therapy that reduces right ventricular filling, such as use of nitrates or diuretics, should be avoided. Volume therapy should be administered to maintain cardiac output; in patients whose hypotension is refractory to volume therapy, dopamine may be beneficial. Heart block, which occurs in as many as 50% of patients with right ventricular infarction, should be treated rapidly, and maintenance of atrioventricular synchrony with dual atrial and ventricular pacing is often required to maintain filling of the ischemic noncompliant right ventricle and an adequate cardiac output.

Cardiogenic shock resulting from right ventricular infarction is generally reversible with these measures. Improvement in right ventricular function generally occurs over time, particularly in patients in whom reperfusion therapy was successful in achieving vessel patency. In patients who survive the initial hospitalization, left ventricular function is the most potent predictor of long-term outcome.

Stroke

Extensive infarction of the anterior wall and apex of the left ventricle leads to thrombus formation in the apex of the left ventricle in approximately 30% of patients; systemic embolization occurs in about 15% of these patients. Left ventricular thrombus formation is much less common after inferior infarction. The thrombus generally appears within the first several days after infarction; it is more likely to embolize and cause stroke if it is pedunculated, protrudes into the left ventricular cavity, or is mobile. Left ventricular thrombus is an indication for anticoagulation with IV heparin, followed by warfarin therapy for 3–6 months.

Therapy that reduces infarct size, such as thrombolytic therapy, reduces the frequency of thrombus formation and therefore the risk of systemic embolization and stroke. However, in 0.3–1.0% of patients, thrombolytic therapy causes hemorrhagic stroke, most commonly in the 24 hours after its administration, which is fatal in more than 50% of cases. Hemorrhagic stroke is rare in acute myocardial infarction except as a consequence of thrombolytic therapy, although an ischemic stroke may become hemorrhagic because of thrombolytic, antiplatelet, and anticoagulation therapy. Hemorrhagic stroke, the most feared complication of thrombolytic therapy, is more likely in elderly patients; in patients with low body weight, with hypertension, or who have previously had a stroke; and in those on warfarin. Although thrombolytic therapy decreases the risk of ischemic stroke, there is a slight net increase in the overall risk of stroke because of the risk of hemorrhagic stroke. Primary coronary angioplasty is believed to reduce the incidence of ischemic stroke without increasing the risk of hemorrhagic stroke.

Therapeutic Approaches in Acute Coronary Syndrome

Initial therapy for acute coronary syndrome should focus on stabilizing the patient's condition, relieving ischemic pain, and providing antithrombotic therapy to reduce myocardial damage and prevent further ischemia. Morphine (or fentanyl) for pain control, oxygen, sublingual and/or IV nitroglycerin, soluble aspirin 162–325 mg, and clopidogrel with a 300–600 mg loading dose are given as initial treatment.

In complete vessel occlusion without collateralization of the infarct-related vessel, there is a little utility in 'pushing nitrates'.

High-risk patients with non-ST-segment elevation myocardial infarction acute coronary syndrome (NSTEMI-ACS) should receive aggressive care, including aspirin, clopidogrel, unfractionated heparin or low-molecular weight heparin (LMWH), intravenous platelet glycoprotein IIb/IIIa complex blockers (e.g. tirofiban, eptifibatide), and a beta-blocker. The goal is early revascularization.

Intermediate-risk patients with NSTEMI-ACS should rapidly undergo diagnostic evaluation and further assessment to determine their appropriate risk category.

Low-risk patients with NSTEMI-ACS should undergo further follow-up with biomarkers and clinical assessment. Optimal medical therapies include use of standard medical therapies, including beta-blockers, aspirin, and unfractionated heparin or LMWH. The clopidogrel in unstable angina to prevent recurrent events (CURE) study showed that clopidogrel would be beneficial even in low-risk patients. If no further pain occurs, and follow-up studies are negative, a stress study should drive further management.

Monitor and immediately treat arrhythmias in the first 48 hours. Pay attention to exacerbating factors, such as disturbances in electrolytes (especially potassium and magnesium), hypoxemia, drugs, or acidosis. Correct these factors accordingly.

Humidified oxygen may reduce the risk of nosebleeds in patients with ACS who are receiving antiplatelet and antithrombin therapy.

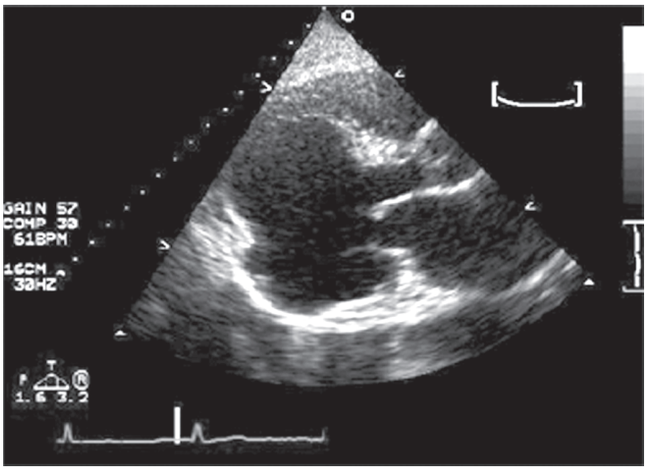

Fig. 3.69: Parasternal long-axis view of the left ventricle demonstrates a large inferobasal aneurysm. Note the wide neck and base of the aneurysm

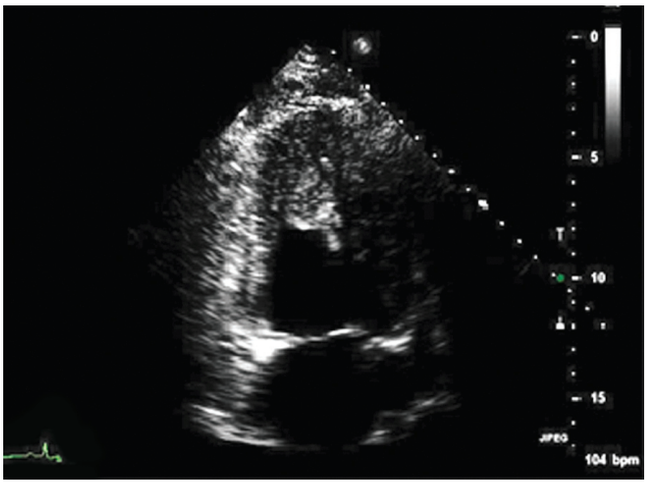

Fig. 3.70: Apical 2-chamber view depicts a large left ventricular apical thrombus with mobile extensions

Do not administer nitrates if the patient is hypotensive (systolic BP < 90 mmHg); if RV infarction, large pericardial effusion, or severe aortic stenosis is suspected; or if the patient recently received phosphodiesterase-5 inhibitors (e.g. sildenafil).

Patients with known hypersensitivity to antiplatelet agents, active internal bleeding, and bleeding disorders should not receive antiplatelet or antithrombotic therapy. Some patients with intractable chest pain or severe hypotension may require the insertion of an intra-aortic balloon pump. The EuroHeart survey showed a nearly 40% reduction in the risk of death in patients with ACS who received support with an intra-aortic balloon pump. This benefit was independent of the status of the ST-segment.

Congestive heart failure can be due to systolic dysfunction or diastolic dysfunction in the setting of myocardial infarction. Aggressive treatment is indicated to prevent worsening of the situation.

Patients presenting with cardiogenic shock should undergo percutaneous coronary intervention (PCI) as soon as possible. Cardiogenic shock is associated with a high mortality rate. Pressor agents, such as dopamine, and inotropic agents, such as dobutamine, may be needed. In a prospective, natural-history study of coronary atherosclerosis, patients underwent 3-vessel coronary angiography and gray-scale and radiofrequency intravascular ultrasonographic imaging after PCI.

Recurrent ischemia may be due to incomplete reperfusion. In the setting of PCI, consider stent thrombosis as a possible cause. Whether drug-eluting stents have an increased rate of thrombosis compared with bare metal stents is unclear.

Drug-eluting stents are linked with fewer periprocedural risks but tend to have high incidence of postprocedural complications including myocardial infarction, repeat procedures, and 12-month major adverse cardiac and brain complications, compared with coronary bypass surgery.

One study by Ribichini et al. suggests that prednisone treatment after bare metal stents or drug-eluting stent implantation results in a better event-free survival at 1 year.

In the final report of the HORIZONS-AMI trial, which assessed the 3 years outcomes of the effectiveness and safety of bivalirudin monotherapy and paclitaxel-eluting stenting, outcomes were sustained for patients with STEMI undergoing primary PCI.

Table 3.4: Differential diagnosis of ventricular septal defect and papillary muscle rupture

	Ventricular septal defect	Papillary muscle rupture
Murmur	Left stenal edge	Apex
Heart	Dominantly right-sided often with minimal pulmonary edema	Dominantly left-sided always with severe pulomnary edema
Infarct location	Anterior or inferior	Inferior
Right heart catheter	Step-up in oxygen saturation in right ventricle	Dominant V-wave in pulmonary artery wedge pressure trace
Echocardiography	Permits direct visualization of defect in some cases	Demonstrates flail valve leaflet
Doppler study	Demonstrates high-velocity jet across defect	Demonstrates high velocity regurgitant jet

In a study of 3031 patients, Mehta et al. found that early intervention (coronary angiography < or = 24-hour after randomization) in patients with ACS did not differ greatly from delayed intervention (coronary angiography > or = 36-hour randomization) in the prevention of primary outcomes (i.e. composite of death, myocardial infarction, or stroke at 6 months). Early intervention did reduce the rate of secondary outcomes (i.e. death, myocardial infarction, or refractory ischemia at 6 months) and improved primary outcomes in patients who were at highest risk (i.e. GRACE risk score >140).

In a Swedish registry of patients with STEMI from 1996–2007, reported an increase in the prevalence of evidence-based treatments. The use of aspirin, clopidogrel, beta- blockers, statins, and ACE inhibitors all increased. Clopidogrel increased from 0% to 82%, statins increased from 23% to 83%, and various ACE inhibitors increased by a large margin. A decrease was reported in 30-day and 1-year mortality that was sustained during long-term follow-up. By following the proper guidelines, patients who have experienced STEMI have higher survival rates.

PHARMACOLOGIC ANTI-ISCHEMIC THERAPY

The pharmacologic anti-ischemic therapy is listed in Table 3.5.

Nitrates

Nitrates do not improve mortality. However, they provide symptomatic relief by means of several mechanisms, including coronary vasodilation, improved collateral blood flow, decrease in preload (venodilation and reduced venous return), and decrease in afterload (arterial vasodilation). Care should be taken to avoid hypotension, because this can potentially reduce coronary perfusion pressure (diastolic BP-LV diastolic pressure).

Beta-blockers

Beta-blockers are indicated in all patients unless they have the following contraindications:

- Systolic blood pressure less than 90 mmHg
- Cardiogenic shock
- Severe bradycardia
- Second- or third-degree heart block
- Asthma or emphysema that is sensitive to beta agonists
- Peripheral vascular disease
- Uncompensated CHF

Beta-blockers reduce oxygen demand and ventricular wall tension. They also decrease mortality and adverse cardiovascular events. These drugs may prevent mechanical complications of myocardial infarction, including rupture of the papillary muscle, left ventricular free wall, and ventricular septum. Beta-blockers meliorate dynamic obstruction of the left ventricular outflow tract in patients with apical infarct and hyperdynamic basal segments.

The most frequently used regimen is IV metoprolol 2–5 mg given every 5 minutes (up to 15 mg total) followed by 25–100 mg given orally twice a day.

Beta-blockers should not be used acutely in patients with cardiogenic shock or signs of heart failure on presentation.

PHARMACOLOGIC ANTI-THROMBOTIC THERAPY

Aspirin

Aspirin permanently impairs the cyclooxygenase pathway of thromboxane A2 production in platelets, in this way inhibiting platelet function. Aspirin reduces morbidity and mortality and is continued indefinitely (Table 3.5).

Clopidogrel

Clopidogrel (thienopyridine) inhibits adenosine 5'-diphosphate (ADP) dependent activation of the glycoprotein IIb/IIIa complex, a necessary step for platelet aggregation. This process results in intense inhibition of platelet function, particularly in combination with aspirin. In the CURE trial, thienopyridine reduced the rate of myocardial infarction by 20%.

Clopidogrel is a class I recommendation for patients when an early noninterventional approach is planned in therapy for at least 1 month and ideally up to 1 year. When percutaneous coronary intervention (PCI) is planned, clopidogrel 300–600 mg should be given as early as possible before or at the time of PCI. Clopidogrel, 75 mg daily, is

Table 3.5: Therapeutic interventions in acute myocardial infarction

Immediate measures to incraease safety and comfort

- Intravenous access
- Access to advanced life support and defibrillation
- Analgsia
- Antiemetic
- Oxygen
- Nitrates

Immediate measures to initiate and maintain reperfusion of the ischemic myocardium

- Anti-platelet therapy
- Thrombolysis
- Primary angioplasty
- Heparin

Immediate measurs to protect ischemic myocardium

- β-adrenoceptor blockers
- Magnesium sulphate
- Insulin

Early adjunctive treatment for heart failure

- ACE inhibitors

Later measures to prevent reinfarction (secondary prevention)

- Aspirin
- β-adrenoceptor blockers
- ACE inhibitors
- Cholesterol-lowering drugs
- Lifestyle modifications (smoking, diet, weight, and exercise)
- Also to be considered: anticoagulants/amiodarone/oestrogens/antioxidants

continued for at least 12 months after PCI, if the patient is not at high risk for bleeding, according to 2011 ACCF/AHA guidelines (class I recommendation). Early discontinuation should be considered if the risk of bleeding-related morbidity outweighs the anticipated benefits.

The optimal loading dose for clopidogrel is still being evaluated. Reports show that a loading dose of 600 mg might be more beneficial than 300 mg. Withhold clopidogrel for at least 5 days before elective coronary artery bypass grafting (CABG). Since 12% of patients with non-ST-elevation ACS have coronary anatomy that favors CABG, the use of clopidogrel is withheld until coronary angiography at some institutions.

A meta-analysis of 34 studies analyzed the safety of CABG among patients with ACS continuing clopidogrel. The investigators found that although mortality is increased in those receiving clopidogrel, it is influenced by ACS status and case urgency in primarily nonrandomized studies. Among patients with ACS, no differences in mortality or postoperative myocardial infarction or stroke rates were found. This suggests that in patients with ACS who require urgent CABG, proceeding despite the continuation of clopidogrel is likely safe.

Clopidogrel can be considered an alternative to aspirin in patients with aspirin intolerance or who are allergic to aspirin.

Patients with chronic kidney disease who have low platelet response to clopidogrel tend to have worse outcomes after PCI. A consensus statement issued by the American College of Cardiology, American College of Gastroenterology, and American Heart Association in November 2010 addresses the issue of concomitant use of proton pump inhibitors (PPIs) and thienopyridine antiplatelet drugs.

Evidence has shown that dexlansoprazole and lansoprazole do not significantly reduce the conversion of clopidogrel to its active metabolite (reduced by 9% and 14%, respectively), and no dose adjustment of clopidogrel is required.

The group's findings and recommendations are listed as follows:

- Clopidogrel reduces major CV events compared with placebo or aspirin.
- Dual antiplatelet therapy with clopidogrel and aspirin, compared with aspirin alone, reduces major CV events in patients with established ischemic heart disease, and it reduces coronary stent thrombosis but is not routinely recommended for patients with prior ischemic stroke because of the risk of bleeding.
- Clopidogrel alone, aspirin alone, and their combination are all associated with increased risk of GI bleeding.
- Clopidogrel requires metabolic activation by cytochrome P450 2C19 (CYP2C19). PPIs that inhibit CYP2C19 are commonly coadministered with clopidogrel to reduce the risk of GI bleeding. A study by Simon et al. showed that PPI use is not associated with an increased risk of cardiovascular events or mortality in patients who have been treated with clopidogrel for a recent MI, regardless of CYP2C19 genotype.
- Patients with prior GI bleeding are at highest risk for recurrent bleeding on antiplatelet therapy; other risk factors include advanced age, concurrent use of anticoagulants, steroids, or NSAIDs including aspirin, and Helicobacter pylori infection; risk increases as the number of risk factors increases.
- Use of PPIs or histamine H2 receptor antagonists (H2RAs) reduces the risk of upper GI bleeding compared with no therapy; PPIs reduce upper GI bleeding to a greater degree than do H2Ras.
- PPIs are recommended to reduce GI bleeding among patients with a history of upper GI bleeding; PPIs are appropriate in patients with multiple risk factors for GI bleeding who require antiplatelet therapy.
- Routine use of either a PPI or an H2RA is not recommended for patients at lower risk of upper GI bleeding, who have much less potential to benefit from prophylactic therapy.
- Clinical decisions regarding concomitant use of PPIs and thienopyridines must balance overall risks and benefits, considering both CV and GI complications.
- Pharmacokinetic and pharmacodynamic studies, using platelet assays as surrogate endpoints, suggest that concomitant use of clopidogrel and a PPI reduces the antiplatelet effects of clopidogrel; the strongest evidence for an interaction is between omeprazole and clopidogrel; it is not established that changes in these surrogate endpoints translate into clinically meaningful differences.
- Observational studies and a single randomized clinical trial have shown inconsistent effects on CV outcomes of concomitant use of thienopyridines and PPIs; a clinically important interaction cannot be excluded, particularly in certain subgroups, such as poor metabolizers of clopidogrel.
- The role of either pharmacogenomic testing or platelet function testing in managing therapy with thienopyridines and PPIs has not yet been established.

Prasugrel

Like clopidogrel, prasugrel is a thienopyridine ADP receptor inhibitor that inhibits platelet aggregation. It has been approved in the United States and has been shown to reduce new and recurrent myocardial infarctions. The loading dose is 60 mg PO once and maintenance is 10 mg PO qd (given with aspirin 75–325 mg/d). Prasugrel is indicated for the reduction of thrombotic cardiovascular events (including stent thrombosis) with ACS that is managed with PCI.

The 2011 ACF/AHA guidelines advise that a loading dose of prasugrel be given as soon as possible, once coronary anatomy is defined and a decision is made to proceed with PCI. Prasugrel should be administered no later than 1 hour after PCI. Maintenance therapy with prasugrel is continued for at least 1 year after PCI. Early

discontinuation should be considered if the risk of bleeding-related morbidity outweighs the anticipated benefits.

One study, however, found that significant, sometimes fatal, bleeding occurred more frequently with prasugrel than with clopidogrel, although the overall mortality rate did not differ significantly between a treatment group receiving prasugrel and another receiving clopidogrel.

Ticagrelor

Ticagrelor (Brilinta) was approved by the US Food and Drug Administration in July 2011 and is the first reversible oral P2Y receptor antagonist. Results from the platelet inhibition and patient outcomes (PLATO) trial showed ticagrelor provides faster, greater, and more consistent ADP-receptor inhibition than clopidogrel.

The difference between treatments on the composite resulted from effects on CV death and MI; each was statistically significant when considered as a secondary endpoint and there was no beneficial effect on strokes. For all-cause mortality, the benefit was also statistically significant of 9.8% for ticagrelor and 11.7% for clopidogrel ($p = 0.0003$) with a hazard ratio of 0.78.

Bleeding risk was assessed in the PLATO trial and ticagrelor increased the overall risk of bleeding (major + minor) to a somewhat greater extent than did clopidogrel. The increase was seen for non-CABG-related bleeding but not for CABG-related bleeding. Fatal and life-threatening bleeding rates were not increased.

Abciximab, Eptifibatide, and Tirofiban

Glycoprotein IIb/IIIa receptor antagonists include abciximab, eptifibatide, and tirofiban. These drugs inhibit the glycoprotein IIb/IIIa receptor, which is involved in the final common pathway for platelet adhesion and aggregation.

Use of cardiac markers in the ED. Effect of time to use of cardiac markers in the ED. Effect of time to treatment in patients with acute coronary syndrome (ACS) who are treated with the GIIb/IIIa inhibitor eptifibatide.

Use eptifibatide or tirofiban in patients with high-risk features in whom invasive treatment is not planned.

The use of eptifibatide 12 hours or more before angiography was not superior to the provisional use of eptifibatide after angiography, according to results from the EARLY ACS trial. The study compared a strategy of early, routine administration of eptifibatide with delayed, provisional administration in patients who had ACS without ST-segment elevation and who were assigned to an invasive strategy. The study also found that early use of eptifibatide was associated with an increased risk of non-life-threatening bleeding and the need for transfusion.

Two trials with tirofiban and 1 trial with eptifibatide documented their efficacy in unstable angina/NSTEMI patients, only some of whom underwent interventions. These antagonists are a class I recommendation in patients in whom catheterization and PCI are planned. Intermediate- and high-risk patients appear to respond favorably to glycoprotein IIb/IIIa inhibitors. They include patients with ST-segment depression, elevated risk scores, elevated serum troponin levels, and/or diabetes mellitus.

Currently, IIb/IIIb antagonists in combination with aspirin are considered standard antiplatelet therapy for patients at high risk for unstable angina.

PHARMACOLOGIC ANTICOAGULATION THERAPY

Unfractionated Heparin

A study by Oler et al. found that unfractionated heparin was associated with a 33% reduction in the risk of myocardial infarction or death in patients with unstable angina who were treated with aspirin plus heparin, compared with patients who were treated with aspirin alone. The FUTURA/OASIS-8 randomized trial found that low-dose unfractionated heparin, 50 U/kg (regardless of use of glycoprotein (Gp) IIb/IIIa inhibitors), compared with standard-dose unfractionated heparin, 85 U/kg (60 U/kg with Gp IIb/IIIa inhibitors), did not reduce major peri-PCI bleeding and vascular access-site complications.

Low Molecular Weight Heparin

Low molecular weight heparins (LMWHs) might be superior to unfractionated heparin in reducing cardiovascular outcomes, with a safety profile similar to that of heparin in patients receiving medical care.

Conflicting results emerged from 9 randomized trials directly comparing LMWH with unfractionated heparin. Two trials evaluated dalteparin, another evaluated nadroparin, and 6 evaluated enoxaparin. Trials with dalteparin and nadroparin reported similar rates of nonfatal myocardial infarction or death compared with heparin, whereas 5 of 6 trials of enoxaparin found point estimates for death or nonfatal myocardial infarction that favored enoxaparin over heparin. The benefit of enoxaparin appeared to be driven largely by a reduction in nonfatal myocardial infarction, especially in the cohort of patients who had not received any open-label anticoagulant therapy before randomization.

In addition, a systematic review comparing LMWH with unfractionated heparin found no significant difference in benefits between the two drugs.

Aside from the possible medical benefits of using LMWH in place of unfractionated heparin, advantages of LMWH include ease of administration, absence of need for anticoagulation monitoring, and potential for overall cost savings. Although LMWHs are approved for use in the United States, only enoxaparin is currently approved for use in unstable angina. Lev et al. found that the combination of eptifibatide with enoxaparin appears to have a more potent antithrombotic effect than that of eptifibatide and unfractionated heparin.

The role of LMWHs in patients for whom PCI is scheduled is relatively ill defined. However, it is likely to be at least equivalent to that of heparin. It appears reasonable to minimize the risk of excessive anticoagulation during PCI by avoiding crossover of anticoagulants (i.e. maintain consistent anticoagulant therapy from the pre-

PCI phase throughout the procedure itself). Additional experience with regard to the safety and efficacy of the concomitant administration of LMWHs with Gp IIb/IIIa antagonists and fibrinolytic agents is currently being acquired.

Adding apixaban (5 mg twice daily) to antiplatelet therapy in high-risk patients after ACS may increase the number of major bleeding events without significantly reducing recurrent ischemic events.

Factor Xa Inhibitors

Use of the oral Xa inhibitor, rivaroxaban (Xarelto), in addition to dual antiplatelet therapy in patients with ACS was recently investigated in the ATLAS ACS2-TIMI 51 trial. Low-dose rivaroxaban (2.5 mg twice daily) resulted in a significant reduction in overall and cardiac mortality, whereas use of the higher dose (5 mg twice daily) did not result in a significant mortality reduction. However, both doses were associated with an increased risk of bleeding compared with placebo. Rivaroxaban is not currently approved by the US Food and Drug Administration (FDA) for use in ACS.

Another factor Xda inhibitor, fondaparinux (Arixtra), has been studied for use in patients with STEMI who do not undergo PCI. In the Fifth Organization to Assess Strategies in Ischemic Syndromes (OASIS-5) trial, fondaparinux reduced major bleeding and improved net clinical outcome compared with enoxaparin in patients receiving.

Glycoprotein IIb/IIIa inhibitors or thienopyridines for ACS. Fondaparinux is not currently FDA approved for use in ACS.

THROMBOLYSIS

Prehospital thrombolysis allows eligible patients to receive thrombolysis 30–60 minutes sooner than if treatment were given in the ED; however, prehospital thrombolysis is still under investigation and has not become a trend, as a result of unproven benefit and an increase in the availability of PCI in many medical centers as an alternative to thrombolysis for STEMI (Table 3.6).

The remodeling with erythropoietin after large myocardial infarction (REVEAL) trial evaluated the safety and efficacy of a single intravenous bolus of epoetin alfa in patients with STEMI who had successful reperfusion with primary or rescue PCI. A single intravenous bolus of epoetin alfa within 4 hours of PCI did not reduce infarct size and was associated with higher rates of adverse cardiovascular events.

Although PCI is the preferred treatment for STEMI, the distance to primary PCI centers and the inherent time delay in delivering primary PCI limits widespread use of this treatment. Pre-hospital electrocardiographic (ECG) diagnosis and direct referral for primary PCI enables patients with STEMI living far from a PCI center to achieve a system delay comparable to patients who are closer to a PCI center.

Table 3.6: Thrombolytic therapy for acute myocardial infarction

Standard indications

1. Chest pain typical of myocardial ischemia. Discomfort from peptic ulcer disease or aortic dissection is a contraindication.
2. Suspicion of Q-wave infarction, i.e. ST-segment elevation in two contiguous ECG leads (benefit of thrombolysis in non-Q-wave infarction and unstable angina is under investigation.
3. Therapy can be administered within 6 hours after onset (but later treatment may confer benefit; actual time constraint is unclear)

Contraindications

1. History of cerebrovascular accident
2. Surgery, invasive procedure, or prolonged cardiopulmonary resuscitation in preceding 2 weeks
3. Systolic blood pressure >180
4. Diastolic blood pressure >110
5. Bleeding risk

Dosage (intravenous)

1. *Streptokinase:* 1.5 million units over 1 hours
2. *Tissue plasminogen activator:* 10 mg/h/bolus, followed by 50 mg over first hour and 20 mg/h for next 2 hours
3. *Anisolyated plasminogen streptokinase activator complex:* 30 units over 5 minutes

Concomitant Therapy

Current guidelines for patients with moderate- or high-risk ACS recommend an early invasive approach with concomitant antithrombotic therapy, including aspirin, clopidogrel, and unfractionated or LMWH. The Acute Catheterization and Urgent Intervention Triage Strategy (ACUITY) trial evaluated the role of thrombin-specific anticoagulation with bivalirudin in this patient population. In patients with moderate- or high-risk ACS who were undergoing invasive treatment with glycoprotein IIb/IIIa inhibitors, bivalirudin was associated with rates of ischemia and bleeding that were similar to those with heparin. Bivalirudin alone was associated with similar rates of ischemia and significantly lower rates of bleeding. Further, glycoprotein IIb/IIIa inhibitors can be initiated at the time of angiography; routine administration 12–24 hours before the procedure carries an increased risk of bleeding and no improvement in outcome.

Kastrati et al. compared the combination of Gp IIb/IIIa inhibitors and heparin with bivalirudin, specifically among patients with NSTEMI undergoing PCI. In a double-blind manner, 1721 patients with acute NSTEMI were randomly assigned to receive abciximab plus unfractionated heparin (861 patients) or bivalirudin (860 patients). The study concluded that abciximab and unfractionated heparin, compared with bivalirudin, failed to reduce death, large recurrent myocardial infarction, urgent target-vessel revascularization, or major bleeding within 30 days. It also

increased the risk of bleeding among patients with NSTEMI who were undergoing PCI.

The goals of treatment are to preserve patency of the coronary artery, augment blood flow through stenotic lesions, and reduce myocardial oxygen demand. All patients should receive antiplatelet agents, and patients with evidence of ongoing ischemia should receive aggressive medical intervention until signs of ischemia, as determined by symptoms and ECG resolve.

ANTIPLATELET AGENTS

Antiplatelets inhibit the cyclooxygenase system, decreasing the level of thromboxane A2, which is a potent platelet activator. Antiplatelet therapy reduces mortality by reducing the risk of fatal strokes and fatal myocardial infarctions.

Aspirin (Anacin, Ascriptin and Bayer Aspirin)

Early administration of aspirin (e.g. anacin, ascriptin and Bayer aspirin) in patients with acute myocardial infarction may reduce cardiac mortality in the first month. The adult dose is 160–324 mg PO or chewed. It can be administered as a suppository if the patient is unable to take PO medications. Aspirin reduces morbidity and mortality and is continued indefinitely. If administered with ticagrelor (Brilinta), do not exceed 100 mg/day after a one-time loading dose of 325 mg.

Nitrates oppose coronary artery spasm and reduce myocardial oxygen demand by reducing preload and afterload.

Nitroglycerin Topical (Nitro-Bid)

Nitroglycerin (Nitro-Bid) causes relaxation of the vascular smooth muscle via stimulation of intracellular cyclic guanosine monophosphate production, causing a decrease in blood pressure. Nitrates do not improve mortality. However, they provide symptomatic relief by means of several mechanisms, including coronary vasodilation, improved collateral blood flow, decrease in preload (venodilation and reduced venous return), and decrease in afterload (arterial vasodilation). Care should be taken to avoid hypotension, because this can potentially reduce coronary perfusion pressure (diastolic BP-LV diastolic pressure).

ANALGESICS

These agents reduce pain which decreases sympathetic stress, in addition to providing some preload reduction.

Morphine sulfate (duramorph, astramorph and MS Contin) is the drug of choice for narcotic analgesia because of its reliable and predictable effects, safety profile, and ease of reversibility with naloxone. Morphine sulfate administered intravenously may be dosed in a number of ways and commonly titrated until the desired effect is obtained.

BETA-ADRENERGIC BLOCKERS

Beta-blockers have antiarrhythmic and antihypertensive properties, as well as the ability to reduce ischemia. They minimize the imbalance between myocardial supply and demand by reducing afterload and wall stress. In patients with acute MI, they decrease infarct size as well as short- and long-term mortality, which is a function of their anti-ischemic and antiarrhythmic properties. These drugs may prevent mechanical complications of myocardial infarction, including rupture of the papillary muscle, left ventricular free wall, and ventricular septum. Beta blockers ameliorate dynamic obstruction of the left ventricular outflow tract in patients with apical infarct and hyperdynamic basal segments. They should not be used acutely in patients with cardiogenic shock or signs of heart failure on presentation.

Metoprolol (Lopressor)

Metoprolol (lopressor) is a selective beta1-adrenergic receptor blocker that decreases the automaticity of contractions. During IV administration, blood pressure, heart rate, and ECG should be carefully monitored. The goal of treatment is to reduce the patient's heart rate to 60–90 beats/min.

Esmolol (Brevibloc)

Esmolol (brevibloc) is an excellent drug for use in patients at risk for complications from beta-blockers, particularly reactive airway disease, mild to moderate LV dysfunction, and peripheral vascular disease. Its short half-life of 8 minutes allows for titration to desired effect with the ability to stop quickly.

Glycoprotein IIB/IIIA Inhibitors

Glycoprotein IIb/IIIa receptor antagonists include abciximab eptifibatide, and tirofiban. Glycoprotein IIb/IIIa antagonists prevent the binding of fibrinogen, thereby blocking platelet aggregation. These drugs inhibit the glycoprotein IIb/IIIa receptor, which is involved in the final common pathway for platelet adhesion and aggregation. Currently, Gp IIb/IIIb receptor antagonists in combination with aspirin are considered standard antiplatelet therapy for patients at high risk for unstable angina.

Abciximab (ReoPro)

Abciximab (ReoPro) is a chimeric human-murine monoclonal antibody. It binds to receptors with high affinity and reduces platelet aggregation by 80%. Inhibition of platelet aggregation persists for up to 48 hours after the end of infusion. Abciximab has been approved for use in elective/urgent/emergent percutaneous coronary intervention.

Eptifibatide (Integrilin)

Eptifibatide (integrilin) is an antagonist of the platelet Gp IIb/IIIa receptor; it reversibly prevents von Willebrand factor, fibrinogen, and other adhesion ligands from binding to the Gp IIb/IIIa receptor. The end effect is the inhibition

of platelet aggregation. The effects persist over the duration of maintenance infusion and are reversed when infusion ends. Use eptifibatide (or tirofiban, see below) in patients with high-risk features in whom invasive treatment is not planned.

Tirofiban (Aggrastat)

Tirofiban (aggrastat) is a nonpeptide antagonist of the Gp IIb/IIIa receptor. It is a reversible antagonist of fibrinogen binding. When administered intravenously, more than 90% of platelet aggregation is inhibited. Tirofiban has been approved for use in combination with heparin for patients with unstable angina who are being treated medically and for patients undergoing percutaneous coronary intervention.

ANTICOAGULANTS

Anticoagulants are used to prevent recurrence of clot after a spontaneous fibrinolysis.

Heparin

Heparin augments the activity of antithrombin III and prevents the conversion of fibrinogen to fibrin. It does not actively lyse but is able to inhibit further thrombogenesis. This agent prevents recurrence of a clot after spontaneous fibrinolysis.

Low Molecular Weight Heparins

LMWH is indicated for treatment of ST-segment elevation myocardial infarction (STEMI) managed medically or with subsequent PCI. It is also indicated as prophylaxis for ischemic complications caused by unstable angina and non-Q-wave myocardial infarction.

Aside from the possible medical benefits of using LMWH in place of unfractionated heparin, advantages of LMWH include ease of administration, absence of need for anticoagulation monitoring, and potential for overall cost savings. Although LMWHs are approved for use in the United States, only enoxaparin is currently approved for use in unstable angina.

Enoxaparin (Lovenox)

Low molecular weight heparin (enoxaparin; lovenox), which is produced by partial chemical or enzymatic depolymerization of unfractionated heparin, binds to antithrombin III, enhancing its therapeutic effect. The heparin-antithrombin III complex binds to and inactivates activated factor X (Xa) and factor II (thrombin). LMWH differs from unfractionated heparin by having a higher ratio of antifactor Xa to antifactor IIa than does unfractionated heparin. Maximum antifactor Xa and antithrombin activities occur 3–5 hours after administration.

Direct Thrombin Inhibitors

Direct thrombin inhibitors bind directly to the anion binding site and the catalytic sites of thrombin to produce potent and predictable anticoagulation.

Hirudin (Lepirudin, Refludan)

Hirudin (lepirudin, refludan) is the prototype of direct thrombin inhibitors. Hirudin binds directly to the anion binding site and the catalytic sites of thrombin to produce potent and predictable anticoagulation. Currently, hirudin is indicated only in patients who are unable to receive heparin because of heparin-induced thrombocytopenia.

Bivalirudin (Angiomax)

Bivalirudin (angiomax) is a synthetic analogue of recombinant hirudin. It inhibits thrombin and is used for anticoagulation in unstable angina in patients undergoing PTCA. Potential advantages over conventional heparin therapy include more predictable and precise levels of anticoagulation, activity against clot-bound thrombin, absence of natural inhibitors (e.g. platelet factor 4, heparinase), and continued efficacy following clearance from plasma (because of binding to thrombin).

ADENOSINE DIPHOSPHATE RECEPTOR ANTAGONISTS

Thienopyridine adenosine 5′-diphosphate (ADP) antagonists approved for antiplatelet activity in the United States include clopidogrel, ticlopidine, prasugrel, and ticagrelor. All but ticagrelor have irreversible antiplatelet activity and take several days to manifest an effect, whereas ticagrelor is a reversible P2Y12 receptor inhibitor. A potential additive benefit exists when ADP antagonists are used in conjunction with aspirin. These drugs may be considered alternatives to aspirin in patients with aspirin intolerance or who are allergic to aspirin.

Clopidogrel (Plavix)

Clopidogrel (plavix) inhibits ADP-dependent activation of the glycoprotein IIb/IIIa complex, a necessary step for platelet aggregation. This process results in intense inhibition of platelet function, particularly in combination with aspirin.

Clopidogrel can be considered an alternative to aspirin in patients with aspirin intolerance or who are allergic to aspirin. The CURRENT-OASIS 7 trial suggests that a 7-day double-dose clopidogrel regimen can be considered for patients with acute coronary syndromes, as the efficacy and safety did not differ from that of a high- and low-dose aspirin regimen. However, there is no benefit in the double-dose treatment for patients who are undergoing an early invasive strategy.

Clopidogrel is a class I recommendation for patients when an early noninterventional approach is planned in therapy. When percutaneous coronary intervention (PCI) is planned, clopidogrel is started and continued for at least 1 month and for up to 9 months, if the patient is not at high risk for bleeding.

Clopidogrel is generally preferred over ticlopidine (ticlid), because it more rapidly inhibits platelets and appears to have a more favorable safety profile.

Clopidogrel has been suggested to be less effective in reducing the rate of cardiovascular events in individuals who carry the loss-of-function CYP2C19 alleles. However, a 2010 study concluded that patients with ACS or atrial fibrillation respond well to clopidogrel, regardless of CYP2C19 loss-of-function carrier status.

Ticlopidine (Ticlid)

Beneficial effects were noted in patients with unstable angina (UA) after 2 weeks of use in one randomized trial. When compared to controls, ticlopidine use decreased vascular deaths and nonfatal MIs.

Prasugrel (Effient)

Thienopyridine drug that inhibits platelet activation and aggregation through the irreversible binding of its active metabolite to ADP platelet receptors (specifically the P2Y12 receptor). Platelet inhibition is the result of this action.

Indicated to reduce thrombotic cardiovascular (CV) events (including stent thrombosis) with acute coronary syndrome (ACS) that is managed with percutaneous coronary intervention (PCI). Specifically for unstable angina or non-ST-elevation myocardial infarction (NSTEMI) or with ST-elevation myocardial infarction (STEMI) when managed with primary or delayed PCI.

Reduces rate of combined endpoint of CV death, nonfatal MI, or nonfatal stroke compared with clopidogrel.

Ticagrelor (Brilinta)

Ticagrelor and its major metabolite reversibly interact with the platelet P2Y12 ADP-receptor to prevent signal transduction and platelet activation. Indicated to reduce the rate of thrombotic cardiovascular events in patients with ACS (unstable angina, non-ST-elevation MI, or ST-elevation MI).

Clinical trial results showed a reduced rate of combined endpoint of cardiovascular death, MI, or stroke compared to clopidogrel. Difference between treatments was driven by CV death and MI with no difference in stroke. In patients treated with PCI, ticagrelor also reduces the rate of stent thrombosis.

The drug is administered with aspirin (loading dose of 325 mg PO once, then 75–100 mg/day). Note that exceeding an aspirin dose of 100 mg/day decreases ticagrelor effectiveness.

MANAGEMENT OF NON-ST-ELEVATION ACUTE CORONARY SYNDROMES (ACSS)

In 2015, the American College of Cardiology/American Heart Association (ACC/AHA) released the guidelines recommendations on the management of non-ST-elevation acute coronary syndromes (ACSs) to assist in maximizing patient outcomes, including the following:

Standard initial medical therapies include supplemental oxygen for arterial oxygen saturation < 90% or respiratory distress; sublingual nitroglycerin; oral beta-blocker therapy within the first 24 hours in the absence of heart failure, low output state, increased risk for cardiogenic shock, or other contraindications to beta-blockade; nondihydropyridine calcium channel blocker for continuing or recurrent ischemia and contraindication to beta-blockade (in the absence of clinically significant left ventricular dysfunction).

Nonsteroidal anti-inflammatory drugs (except aspirin) should not be initiated and should be discontinued during the hospitalization for NSTE-ACS, because of the increased risk of major adverse cardiac events associated with their use.

Initial antiplatelet/anticoagulant therapy includes 325 mg chewable aspirin at presentation, followed by a daily maintenance dose of aspirin at 81–126 mg daily. A P2Y12 inhibitor (clopidogrel or ticagrelor) should be used in addition to aspirin for up to 12 months in patients treated with either an early-invasive or ischemia-guided strategy. In addition to antiplatelet therapy, parenteral anticoagulation is indicated with enoxaparin, bivalirudin, fondaparinux, or unfractionated heparin.

A high-intensity statin should be initiated or continued in all patients without contraindications. Angiotensin-converting enzyme inhibitors should be started and continued indefinitely with a left ventricular ejection fraction = 40% or hypertension, diabetes, or stable chronic kidney disease unless contraindicated.

An early invasive strategy is indicated for patients with refractory angina or hemodynamic or electrical instability and those at elevated risk for clinical events. An early invasive strategy is not recommended for patients with extensive comorbidities (e.g. hepatic, renal, or pulmonary failure; cancer) in whom the risks of revascularization and comorbid conditions are likely to outweigh the benefits of revascularization. An ischemia-guided strategy is appropriate for low-risk score patients (thrombolysis in myocardial infarction or global registry of acute coronary events), for low-risk troponin-negative women, and by patient or clinician preference in the absence of high-risk features. When an ischemia-guided strategy is chosen, noninvasive stress testing is recommended prior to hospital discharge to detect severe ischemia occurring at a low-stress threshold.

Patients undergoing percutaneous coronary intervention (PCI) should be treated with a P2Y12 inhibitor: clopidogrel, prasugrel, or ticagrelor. Discharge planning should include detailed patient education about symptoms, lifestyle interventions, standard medication with dual antiplatelet therapy, cholesterol management, referral to cardiac rehabilitation, timely follow-up with the healthcare team, and influenza and pneumococcal vaccines.

Non-ST-elevation-ACS patients with prior revascularization PCI or coronary artery bypass grafting should receive antiplatelet and anticoagulant therapy and be strongly considered for an early invasive strategy because of their increased risk. Medical treatment in the acute phase of NSTE-ACS and decisions to perform stress testing, angiography, and revascularization should be similar in patients with and without diabetes mellitus.

Patients who develop NSTE-ACS following noncardiac surgery should receive guideline-directed medical therapy, with additional management directed at the underlying cause of the pathophysiologic process.

Older patients with NSTE-ACS, because of their high-risk status, should be treated with guideline-directed medical therapy and an early invasive strategy with revascularization as appropriate; pharmacotherapy should be individualized and dose adjusted by weight and creatinine clearance to reduce adverse events. Management decisions should be patient centered, incorporating patient preferences, comorbidities, functional and cognitive status, and life expectancy.

Women with NSTE-ACS should be managed with the same pharmacologic therapy as men for acute care and secondary prevention, with attention to weight and/or renally calculated doses of antiplatelet and anticoagulant agents to reduce bleeding risk. Women with NSTE-ACS and high-risk features (e.g. troponin positive) should undergo an early invasive strategy.

Initial therapy for ACS should focus on stabilizing the patient's condition, relieving ischemic pain, and providing antithrombotic therapy to reduce myocardial damage and prevent further ischemia. Morphine (or fentanyl) for pain control, oxygen, sublingual or intravenous (IV) nitroglycerin, soluble aspirin 162–325 mg, and clopidogrel with a 300–600 mg loading dose are given as initial treatment.

In complete vessel occlusion without collateralization of the infarct-related vessel, there is a little utility in 'pushing nitrates'.

High-risk patients with non-ST-segment elevation myocardial infarction (NSTEMI ACS) should receive aggressive care, including aspirin, clopidogrel, unfractionated heparin or low molecular weight heparin (LMWH), IV platelet Gp IIb/IIIa complex blockers (e.g. tirofiban and eptifibatide), and a beta-blocker. The goal is early revascularization.

Intermediate-risk patients with NSTEMI ACS should rapidly undergo diagnostic evaluation and further assessment to determine their appropriate risk category.

Low-risk patients with NSTEMI ACS should undergo further follow-up with biomarkers and clinical assessment. Optimal medical therapies include use of standard medical therapies, including beta blockers, aspirin, and unfractionated heparin or LMWH. The clopidogrel in Unstable Angina to Prevent Recurrent Events CURE study showed that clopidogrel would be beneficial even in low-risk patients. If no further pain occurs, and follow-up studies are negative, a stress study should drive further management.

Monitor and immediately treat arrhythmias in the first 48 hours. Pay attention to exacerbating factors, such as disturbances in electrolytes (especially potassium and magnesium), hypoxemia, drugs, or acidosis. Correct these factors accordingly.

Humidified oxygen may reduce the risk of nosebleeds in patients with ACS who are receiving antiplatelet and antithrombin therapy.

Do not administer nitrates if the patient is hypotensive (systolic BP < 90 mmHg); if RV infarction, large pericardial effusion, or severe aortic stenosis is suspected; or if the patient recently received phosphodiesterase-5 inhibitors (e.g. sildenafil).

Patients with known hypersensitivity to antiplatelet agents, active internal bleeding, and bleeding disorders should not receive antiplatelet or antithrombotic therapy.

Some patients with intractable chest pain or severe hypotension may require the insertion of an intra-aortic balloon pump. The EuroHeart survey showed a nearly 40% reduction in the risk of death in patients with ACS who received support with an intra-aortic balloon pump. This benefit was independent of the status of the ST-segment.

Congestive heart failure can be due to systolic dysfunction or diastolic dysfunction in the setting of myocardial infarction. Aggressive treatment is indicated to prevent worsening of the situation.

Patients presenting with cardiogenic shock should undergo percutaneous coronary intervention (PCI) as soon as possible. Cardiogenic shock is associated with a high mortality rate. Pressor agents, such as dopamine, and inotropic agents, such as dobutamine, may be needed. In a prospective, natural-history study of coronary atherosclerosis, patients underwent 3-vessel coronary angiography and gray-scale and radiofrequency intravascular ultrasonographic imaging after PCI.

Recurrent ischemia may be due to incomplete reperfusion. In the setting of PCI, consider stent thrombosis as a possible cause. Whether drug-eluting stents have an increased rate of thrombosis compared with bare metal stents is unclear.

The clinical significance of incomplete coronary revascularization (ICR) following PCI in patients with ACS was examined in 2,954 patients from the Acute Catheterization and Urgent Intervention Triage Strategy (ACUITS) trial. At one year follow-up, ICR was strongly associated with ischemia-driven unplanned revascularization, myocardial infarction and major adverse cardiac events.

Drug-eluting stents are linked with fewer periprocedural risks but tend to have high incidence of postprocedural complications including myocardial infarction, repeat procedures, and 12-month major adverse cardiac and brain complications, compared with coronary bypass surgery.

One study by Ribichini et al. suggests that prednisone treatment after bare metal stents or drug-eluting stent implantation results in a better event-free survival at 1 year.

In the final report of the HORIZONS-AMI trial, which assessed the 3-year outcomes of the effectiveness and safety of bivalirudin monotherapy and paclitaxel-eluting stenting, outcomes were sustained for patients with STEMI undergoing primary PCI.

In a study of 3031 patients, Mehta et al. found that early intervention (coronary angiography < or = 24 hours after randomization) in patients with ACS did not differ greatly from delayed intervention (coronary angiography > or = 36-hour randomization) in the prevention of primary

outcomes (i.e. composite of death, myocardial infarction, or stroke at 6 months). Early intervention did reduce the rate of secondary outcomes (i.e. death, myocardial infarction, or refractory ischemia at 6 months) and improved primary outcomes in patients who were at highest risk (i.e. GRACE risk score >140).

In a Swedish registry of patients with STEMI from 1996–2007, reported an increase in the prevalence of evidence-based treatments. The use of aspirin, clopidogrel, beta-blockers, statins, and ACE inhibitors all increased. Clopidogrel increased from 0% to 82%, statins increased from 23% to 83%, and various ACE inhibitors increased by a large margin. A decrease was reported in 30-day and 1-year mortality that was sustained during long-term follow-up. By following the proper guidelines, patients who have experienced STEMI have higher survival rates.



Fig. 3.71: A middle-aged-patient with acute myocardial infarction has been selected by doctors for primary angioplasty

CORONARY INTERVENTIONS

An early invasive strategy (i.e. diagnostic angiography with intent to perform revascularization) is indicated in unstable angina/NSTEMI patients who have refractory angina or hemodynamic or electrical instability without serious comorbidities or contraindications to such procedures. An early invasive strategy is also indicated in initially stabilized unstable angina/NSTEMI patients who do not have serious comorbidities or contraindications to such procedures and who have an elevated risk for clinical events (Figs 3.71–3.78 and Table 3.7).

According to the 2011 American College of Cardiology Foundation (ACCF)/American Heart Association (AHA) guidelines, an early invasive strategy (i.e. within 12–24 hours of admission) is a reasonable choice for initially stabilized high-risk patients with unstable angina/NSTEMI; for patients not at high risk, a delayed invasive approach is also reasonable (class IIa recommendation).

In NSTEMI ACS, early revascularization reduces myocardial infarction and death rates compared with a more selective strategy, particularly in high-risk patients. Use of Gp IIb/IIIa blockers followed by early invasive catheterization is the most logical approach. An early invasive strategy should be considered in patients with large myocardial infarction, hypotension, shock, RV infarction, and refractory chest pain.

In the invasive versus conservative treatment in unstable coronary syndromes (ICTUS) trial, an early invasive strategy had no apparent long-term benefit in reducing death or myocardial infarction. After stratification for risk, analysis of 5-year clinical outcomes in patients presenting with non-ST-segment elevation ACS and elevated troponin T (TnT) level showed that cumulative myocardial infarction or death rates were 22.3% in the early invasive group versus 18.1% in the selective invasive group. No difference was observed in mortality or myocardial infarction.

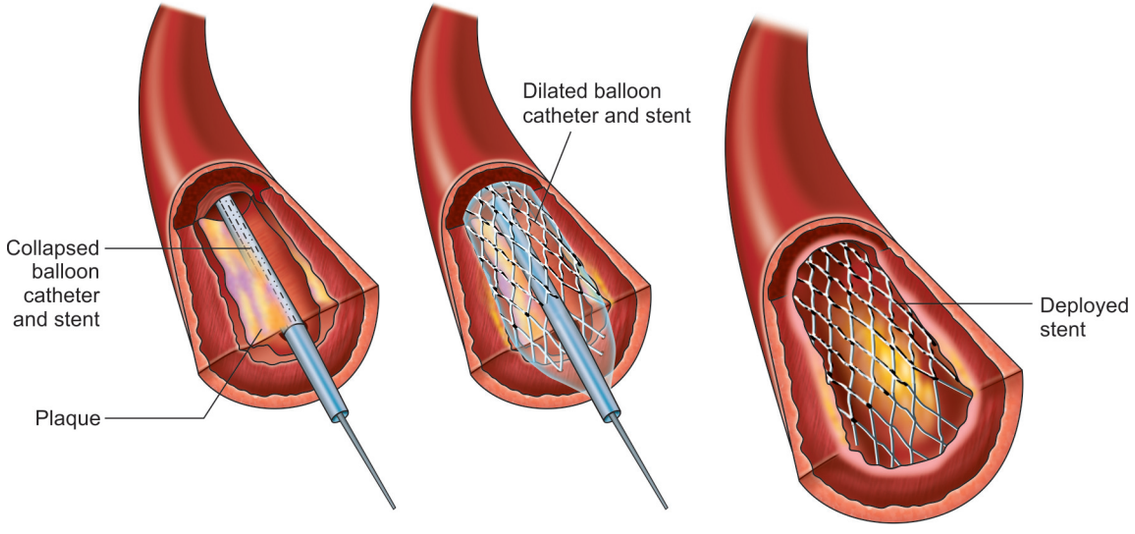

Fig. 3.72: The stent is a self-expanding—its shape and diameter can adapt to the anatomical changes of coronary arteries during the post-infarction phase, so as to stay permanently in contact with the vessel wall. It also avoids, thanks to a mesh made of micro-connectors, blocking the access to lateral branches

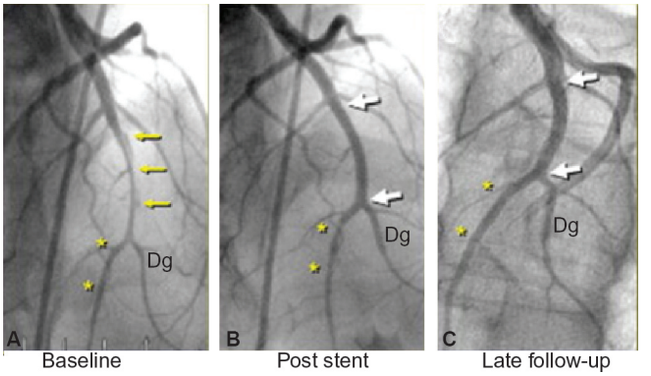

Fig. 3.73: SCD in the left anterior descending coronary artery requiring coronary stenting for ongoing ischemia. (A) Before intervention, a clear angiographic flap is detected (yellow arrows) together with a smooth vessel narrowing (asterisks) distal to the second diagonal branch (Dg). (B) Result after stenting (white arrows). The diagonal branch became transiently occluded and required additional stent implantation in its proximal segment. (C) Late angiographic follow-up. Notice the enlargement of lumen diameter at the distal vessel (asterisks), suggesting resolution of intramural hematoma. I-SCD=isolated spontaneous coronary artery dissection

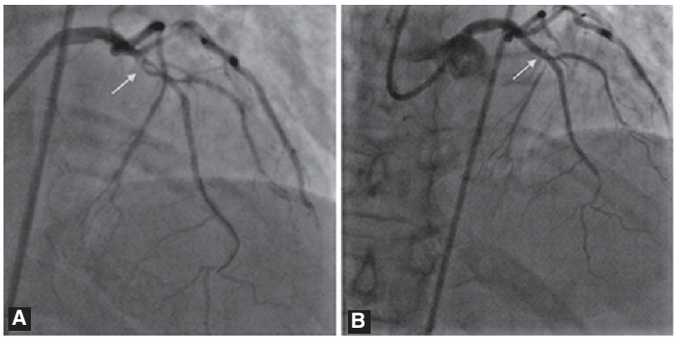

Fig. 3.74: (A) Left anterior descending coronary artery with type B dissection postangiosplasty. Note double lumen (arrow) without flow compromise. (B) Left anterior descending coronary artery after stenting (arrow)

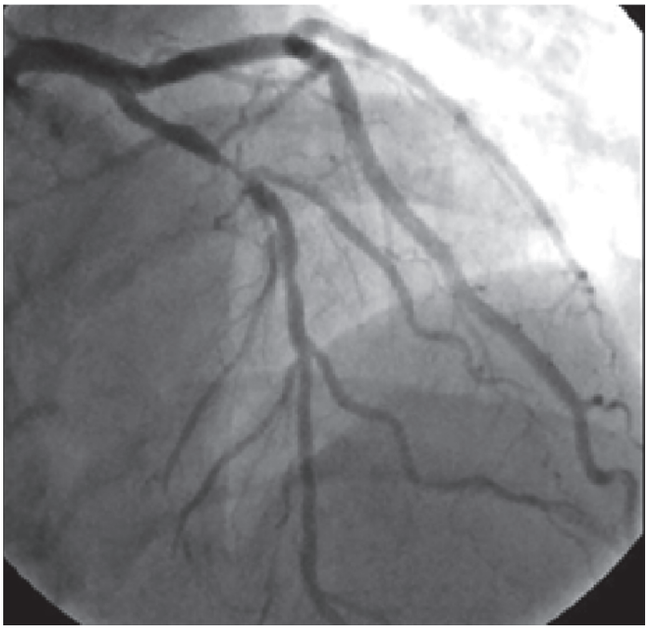

Fig. 3.75: UC San Diego performs first robotically assisted double vessel coronary stenting after a heart attack procedure in California by Dr Sie Hing Tanga and published on August 31, 2014

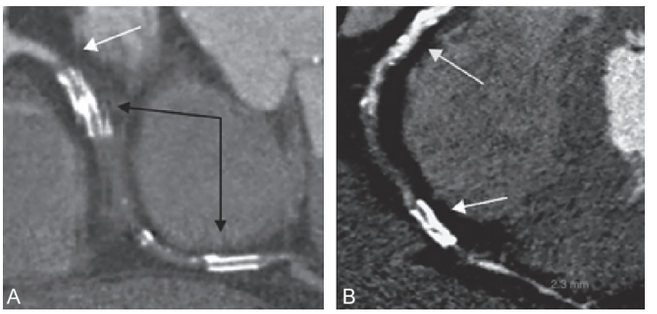

Fig. 3.76: Occluded coronary arteries with previously implanted stent. (A) Right coronary, middle and distal stent; high-density image (black arrows), occlusion of the artery immediately proximal to the first stent (white arrow). (B) Total chronic coronary occlusion difficult to evaluate because of an intense proximal calcification (yellow arrow) of the vessel, middle occlusion, and distal stent (white arrow)

Primary Coronary Angioplasty

Coronary angioplasty without antecedent thrombolytic therapy, termed primary or direct coronary angioplasty, has been studied in the treatment of acute myocardial infarction. In prospective, randomized trials comparing primary coronary angioplasty with different thrombolytic agents, primary coronary angioplasty was associated with a lower morbidity and mortality than thrombolytic therapy. Although most of the individual trials were too small to detect statistically significant differences in mortality, pooled data from these trials suggest that primary coronary angioplasty is the preferred therapy for acute myocardial infarction at institutions where it can be performed without delay. However, the degree of benefit associated with primary coronary angioplasty was much smaller than that seen in the earlier randomized studies; this finding was in part related to the lower frequency with which patients assigned to undergo angioplasty in GUSTO-IIb actually underwent the procedure and in part related to the lower frequency with which normal antegrade coronary blood flow was achieved in patients who did undergo coronary angioplasty.

The consistency of the results favoring primary coronary angioplasty and the greater speed and frequency with which coronary angioplasty can restore flow to an occluded coronary artery support the conclusion that primary coronary angioplasty is preferable to thrombolytic therapy



Fig. 3.77: All patients with acute coronary syndrome who are managed with angioplasty are being monitored in intensive coronary care unit

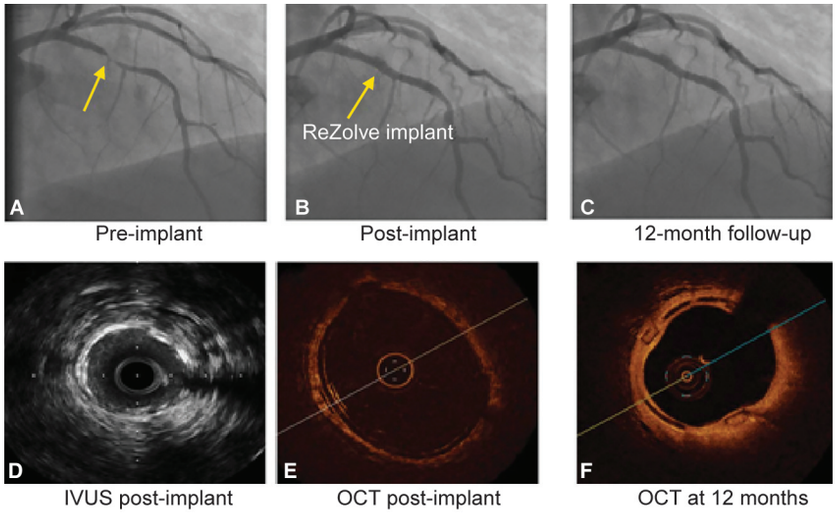

Fig. 3.78: Angiographic, intravascular ultrasound (IVUS), and optical coherence tomography (OCT) illustrations of a case with ReZolve® bioresorbable scaffold. Angiogram revealed a 90% stenosis (A) which was treated with implantation of ReZolve bioresorbable scaffold. (B) showed good angiographic results at 12-month follow-up. (C) Representative intravascular ultrasound. (D) Optical coherence tomography sections post-implant. (E) At 12 months, and (F) are shown (*Courtesy:* Alexandre Abizaid)

at institutions where it can be performed quickly with a high success rate. Studies have shown that excessive delay in performing primary coronary angioplasty and operator inexperience lead to a higher mortality than that seen when primary coronary angioplasty is performed rapidly by experienced operators. It has been recommended that primary angioplasty be performed only in hospitals where a high success rate and low complication rate can be demonstrated and where primary angioplasty is performed in at least 80–90% of patients in whom acute myocardial infarction is confirmed. The need for surgical backup is controversial, as excellent results have been obtained at centers without surgical backup. However, surgical backup is recommended because approximately 5% of patients with acute myocardial infarction who undergo immediate coronary angiography require emergency surgery either for angioplasty that has failed or, more commonly, because lethal coronary anatomy precludes primary angioplasty. Immediate transfer for primary angioplasty is an alternative treatment strategy for patients with STEMI initially assessed at a hospital without on-site cardiac surgery facilities.

Glycoprotein IIb/IIIa Inhibitor Therapy and Primary Angioplasty for Acute Myocardial Infarction

The role of the platelet glycoprotein inhibitor abciximab in conjunction with primary coronary angioplasty has been examined in the randomized, placebo-controlled trial of

Table 3.7: Recommendations for early conservative versus invasive treatment strategies

Class I

- An early invasive strategy is indicated in patients who have unstable angina/NSTEMI and any of the following high-risk indicators (level of evidence: A)
- Recurrent angina/ischemia at rest or with low-level activities despite intensive anti-ischemic therapy.
- Elevated troponin T or troponin I
- New or presumably new ST-segment depression
- Recurrent angina/ischemia with symptoms of chronic heart failure, an S3 gallop, pulmonary edema, worsening rales, or new or worsening mitral regurgitation
- High-risk findings on noninvasive stress testing
- Depressed left ventricular systolic function (e.g. ejection fraction <0.40 on noninvasive study)
- Hemodynamic instability
- Sustained ventricular tachycardia
- PCI within 6 months
- Prior coronary artery bypass graft surgery
- In the absence of these findings, either an early conservative or an early invasive strategy is indicated in hospitalized patients who do not have contraindications for revascularization (level of evidence: B)

Class IIa

- An early invasive strategy is indicated in patiets who have repeated presentations ofr ACS despite therapy and without evidence for ongoing ischemia or high risk (level of evidence: C)

Class III

- Coronary angiography is indicated in patients who have extensive comobidities (e.e. liver or pulmonary failure, cancer), in whom the risks of revascularization are not likely to outweigh the benefits (level of evidence: C)
- Coronary angiography is recommended in patients who have acute chest pain and a lowlikelihood of ACS (level of evidence: C)
- Coronary angiography is indicated in patients who will not consent to revascularization regardless of athe findings (level of evidence: C).

abciximab with primary angioplasty for acute myocardial infarction (RAPPORT), the intracoronary stenting and antithrombotic regimen-2 (ISAR-2) study, the abciximab before direct angioplasty and stenting in myocardial infarction adverse events, but the benefit appeared to be limited to patients undergoing balloon angioplasty without stent placement. This would suggest that glycoprotein IIb/IIIa inhibitors should be beneficial in this setting. Taken together, the results of these studies that are currently available suggest that abciximab is beneficial in patients with acute myocardial infarction but that the benefit in patients undergoing balloon angioplasty alone may differ from that in patients who undergo balloon angioplasty with stent placement. Clearly, however, stents markedly reduce the frequency with which a repeat revascularization procedure is needed in the months after the angioplasty procedure. The combined use of stents and platelet glycoprotein inhibitors may maximize the frequency with which normal antegrade blood flow is achieved while reducing the need for repeat procedures in the following year. One study compared the outcome of thrombolytic therapy using t-PA with that of primary angioplasty utilizing both stents and abciximab. The reduction in infarct size was far greater in the group undergoing primary angioplasty; the clinical outcome was also better in the patients who underwent angioplasty.

Rescue Coronary Angioplasty

Depending on the regimen used, only 33–60% of patients treated with thrombolytic therapy have restoration of normal antegrade flow in the infarct-related artery 90 minutes after the initiation of therapy. Accordingly, immediate coronary angiography has been studied to determine whether patients with persistent occlusion of the infarct-related artery benefit from coronary angioplasty; this procedure has been termed rescue angioplasty. A single small, randomized trial has examined the clinical outcome of patients with anterior infarction and coronary occlusion that persist despite thrombolytic therapy. Patients were randomized to either undergo rescue coronary angioplasty or receive continued medical therapy alone. The results of the trial suggested improved outcome with rescue angioplasty, although the benefits were not compelling. Three additional randomized trials evaluated the role of rescue angioplasty. Analyzed together, the four trials suggest that rescue angioplasty offers benefit, although the data are not compelling. Although use of coronary stents and platelet glycoprotein inhibitors improves the results of percutaneous revascularization procedures and would be expected to further increase the benefit of angioplasty after failed thrombolytic therapy, this has not yet been proved. There are insufficient data to recommend immediate angiography

and angioplasty in all patients early after thrombolytic therapy. Immediate angiography is most likely to be beneficial in patients with large myocardial infarctions in whom persistent pain, ST-segment elevation, or hemodynamic compromise is present more than 90 minutes after the administration of a thrombolytic agent. The routine performance of angioplasty immediately after the administration of thrombolytic therapy in all patients with a significant residual stenosis (not just those patients with occluded coronary arteries) has been well studied in three prospectives, randomized trials and has been found to be either of no benefit or deleterious. Angioplasty should not be routinely performed in such patients. Stents appear to improve the ability to achieve arterial patency early after thrombolytic therapy, as compared with balloon angioplasty alone, therapy with a glycoprotein IIb/IIIa inhibitor may also do so, although an increase in bleeding has been seen when glycoprotein IIb/IIIa inhibitors are used early after full-dose thrombolytic therapy. Data from several pilot studies suggest that the combination of a fibrin-specific thrombolytic agent, either t-PA or reteplase, combined with the glycoprotein IIb/IIIa inhibitor abciximab, may actually facilitate the performance of angioplasty rather than reduce its safety and efficacy, as was seen when balloon angioplasty was performed after thrombolytic therapy. Hence, the term facilitated angioplasty has been coined for the routine performance of angioplasty after the combination of half-dose thrombolytic therapy with a glycoprotein IIb/IIIa inhibitor.

The plasminogen-activator angioplasty compatibility trial (PACT) investigators randomized 606 patients to a reduced dose of a short-acting fibrinolytic regimen (50 mg bolus of reteplase) or a placebo followed by immediate angiography with angioplasty, if needed. In the group receiving reduced-dose reteplase, there was no increase in the incidence of stroke or major bleeding, and convalescent left-ventricular ejection fraction was higher, as evidenced by a patent infarct-related artery (TIMI-3 flow) on arrival in the catheterization laboratory (62%) or a TIMI-3 flow that was achieved by angioplasty within 1 hour after administration of the drug bolus (58%). However, only 12% of successful angioplasty procedures resulted in a patent infarct-related artery within 1 hour, because of routine delay in transfer to the catheterization laboratory, and there was no difference between the two treatment groups by a traditional intention-to-treat analysis. The Southwest German Study in Acute Myocardial Infarction III (SIAM III) investigators randomized 163 patients initially treated with thrombolysis at a community hospital with no on-site PCI facilities either to hospital transfer and immediate stenting within 6-hours of thrombolysis or to delayed, elective stenting approximately 2 weeks after acute myocardial infarction. Transfer and immediate stenting were associated with a statistically significant reduction in the incidence of the composite primary end-point (i.e. death, reinfarction, ischemic events, and target-lesion revascularization at 6 months), as compared with delayed stenting (25.6% versus 50.6%; $P = 0.001$). The difference in outcome was driven by events occurring during the 2 weeks that patients waited for elective stenting in the deferred PCI group. This trial design does not address whether PCI performed 1–2 days after thrombolytic therapy, as is usual in the United States, is as effective as PCI performed immediately after thrombolytic therapy. A randomized trial that analyzed the use of combination therapy (half-dose thrombolytic therapy with full-dose abciximab) before routinely performing primary PCI was recently reported. In the Bavarian reperfusion alternatives evaluation (BRAVE) trial, patients with STEMI were randomly assigned to receive either half-dose reteplase and full-dose abciximab or abciximab alone, and all patients underwent PCI as rapidly as possible. No advantage was seen with combination therapy; in fact, more bleeding complications occurred in this group. The results argue against the use of a facilitated PCI approach using the combination regimen of reteplase and abciximab.

Bioresorbable Scaffolds

Current generation of drug-eluting stents has significantly improved the outcomes of percutaneous coronary intervention by substantially reducing in-stent restenosis and stent thrombosis. However, a potential limitation of these stents is the permanent presence of a metallic foreign body within the artery, which may cause vascular inflammation, restenosis, thrombosis, and neoatherosclerosis. The permanent stents also indefinitely impair the physiological vasomotor function of the vessel and future potential of grafting the stented segment. Bioresorbable scaffolds (BRSs) have the potential to overcome these limitations as they provide temporary scaffolding and then disappear, liberating the treated vessel from its cage and restoring pulsatility, cyclical strain, physiological shear stress, and mechanotransduction. While a number of BRSs are under development, two devices with substantial clinical data have already received a Conformité Européenne marking. This review article presents the current status of these devices and evaluates the challenges that need to be overcome before BRSs can become the workhorse device in coronary intervention.

ADJUNCTIVE MEDICAL THERAPY

Intravenous Heparin

The need for IV heparin after thrombolytic therapy varies with the thrombolytic agents used. A retrospective analysis of the GUSTO-I trial suggested that IV heparin with a partial thromboplastin time of 50–70 seconds was associated with the best clinical outcome in patients treated with t-PA. Data from GUSTO-I also suggest that IV heparin is not required when IV streptokinase is used, although heparin is recommended in patients with large anterior infarctions to prevent the development of apical mural thrombus and embolization. In patients in whom IV heparin is not administered, subcutaneous heparin should

be administered during the period of bedrest to reduce the risk of deep vein thrombosis.

The optimal duration of IV heparin therapy is unclear. Standard practice was to administer IV heparin for 3–5 days, although patients are now often discharged after only 3 days. It is recommended that heparin be discontinued more than 24 hours before patient discharge from the hospital because of the possibility of a rebound effect and recurrent thrombosis within 24 hours after cessation of heparin therapy.

Randomized studies from the prethrombolytic era suggested that administration of IV heparin reduces mortality and reinfarction in patients not treated with thrombolytic agents. Aspirin and beta-blockers were not routinely administered in those early trials; consequently, the true benefits of heparin when these drugs are administered are unknown. However, on the basis of the early data, IV heparin is generally recommended for patients with suspected myocardial infarction who are not treated with thrombolytic therapy.

Low Molecular Weight Heparin

Low molecular weight heparins (depolymerized unfractionated heparin with a mean molecular weight of approximately 5,000) have a number of potential pharmacokinetic advantages over the parent molecule, including decreased binding to plasma proteins, decreased sensitivity to platelet factor 4, enhanced factor Xa activity, and improved bioavailability. These factors are associated with a predictable dose-response relationship and, combined with the ease of administration (once or twice daily SC dosing regimens) and lower rates of heparin-induced thrombocytopenia, have increased investigators' interest in low molecular weight heparins in preference to unfractionated heparin for the treatment of myocardial infarction. The results of four large randomized trials comparing three different low molecular weight heparins with unfractionated heparin have suggested that low molecular-weight heparin is at least as effective in reducing ischemic events in patients with NSTEMI acute coronary syndromes. Following patients with STEMI, the second trial of heparin and aspirin reperfusion therapy (HART II) and the Acute Myocardial Infarction-Streptokinase (AMI-SK) trial demonstrated evidence of improved rates of reperfusion when the low-molecular-weight heparin enoxaparin was combined with t-PA or streptokinase, respectively. The ASSENT-3 trial compared three regimens: full-dose tenecteplase and enoxaparin, full-dose tenecteplase and unfractionated heparin, and half-dose tenecteplase and abciximab for the treatment of thrombolytic-eligible STEMI; the study revealed that enoxaparin fared better than unfractionated heparin in terms of 30-day mortality, in-hospital reinfarction, and in-hospital refractory ischemia (P = 0.0001) at 30 days. However, at 1 year, the benefits had diminished, and the mortality with enoxaparin was identical to that with unfractionated heparin. In addition, when the data from ASSENT-3 and ASSENT-3-PLUS (a study examining the administration of tenecteplase with enoxaparin in the prehospital setting) were pooled, a marked and prohibitive increase in the risk of intracerebral hemorrhage was seen in the elderly. As a result, ongoing trials utilizing enoxaparin with a fibrinolytic agent have adjusted the dose of enoxaparin downward in elderly patients. At present, the adjunctive anticoagulant that should be administered with fibrinolytic therapy and its optimal dose is not known.

Direct Thrombin Inhibitors

Direct thrombin inhibitors are an attractive alternative to indirect thrombin inhibitors, such as heparin or low molecular weight heparins, particularly because they block both circulating and clot-bound thrombin. A collaborative meta-analysis of phase-3 trials of direct thrombin inhibitors for the treatment of acute coronary artery syndromes demonstrated superiority over unfractionated heparin for the prevention of the composite end-point of death or myocardial infarction. The Hirulog and early reperfusion or occlusion (HERO)-2 trial demonstrated a similar benefit in comparison to bivalirudin with heparin in patients with STEMI bivalirudin was associated with a 30% reduction in the incidence of reinfarction, but mortality did not decrease; however, the bivalirudin arm of the study exhibited a trend toward more bleeding events.

Beta-blockers

Numerous studies of beta-blocker therapy in patients with acute myocardial infarction have documented significant reductions in in-hospital and long-term mortality. Early administration of beta-blockers has been promoted because it may reduce infarct size by reducing heart rate, blood pressure, and myocardial contractility, all of which diminish myocardial oxygen demand. Meta-analysis of the effects of early administration of IV beta blockers in 27, 486 patients with acute myocardial infarction enrolled in 28 randomized trials revealed a 14% reduction in mortality during the first week of therapy; reinfarction was reduced by 18%.

The TIMI-II study compared immediate beta-blocker therapy with deferred beta-blocker therapy in acute myocardial infarction; all patients also received IV t-PA. Results indicated that immediate beta-blocker therapy reduced the incidence of nonfatal reinfarction and recurrent ischemia, compared with oral metoprolol therapy begun on the sixth hospital day; as in earlier studies, only about 40% of patients with acute myocardial infarction were eligible for acute beta-blocker therapy. There are also data suggesting that immediate beta-blocker therapy reduces the risk of intracranial hemorrhage after lytic therapy. It is recommended that all patients with acute myocardial infarction without contraindications receive IV beta-blockers as early as possible, whether or not they receive reperfusion therapy.

In patients in whom contraindications preclude early beta-blocker therapy, reevaluation should take place before discharge. Many patients will no longer have contraindications at the time of discharge. Patients without

contraindications should be routinely started on beta-blocker therapy before discharge from the hospital. The optimal duration of benefit remains unclear, but it appears that the benefit of beta-blocker therapy is maintained for years. Patients with the largest infarctions benefit the most from the use of beta-blockers. Current recommendations are that beta-blocker therapy be continued indefinitely in the absence of contraindications or side-effects.

Angiotensin-converting Enzyme Inhibitors

Several large randomized, controlled clinical trials evaluating the use of angiotensin-converting enzyme (ACE) inhibitors early after acute myocardial infarction have been performed; all but one trial revealed a significant reduction in mortality. Meta-analysis of these large trials and many smaller trials, which together included over 100,000 patients, suggested a 6.5% reduction in deaths, with an absolute reduction in mortality of 4.6 deaths per 1,000 patients among those treated with an ACE inhibitor. All patients with significant ventricular dysfunction (an ejection fraction < 40%) without contraindications should be treated with an ACE inhibitor; treatment should begin within the first 48 hours of infarction and be increased cautiously to avoid hypotension. If hypotension results from the early administration of ACE inhibitors, short-term mortality may be increased.

The benefit of ACE inhibitors is clear in patients with large anterior infarctions and an ejection fraction less than 40%; whether patients with an ejection fraction greater than 40% benefit from ACE inhibitor therapy is less clear. However, the results of two large trials suggest that patients with a normal ejection fraction after myocardial infarction, as well as even patients with coronary artery disease without a previous myocardial infarction, have a reduction in mortality when treated with an ACE inhibitor. Treatment with perindopril was associated with a highly statistically significant reduction in the incidence of fatal and nonfatal myocardial infarction at 4 years. Whether these favorable results are unique to tissue-specific ACE inhibitors or represent a class effect is unknown.

Intravenous Nitroglycerin

Randomized studies examining the role of IV nitroglycerin in acute myocardial infarction revealed beneficial effects on left ventricular function and a reduction in infarct size and mortality. However, these studies were small and were performed before the reperfusion era. To determine whether nitroglycerin therapy is beneficial in patients treated with reperfusion, 58,050 patients with acute myocardial infarction in the fourth International Study of Infarct Survival (ISIS-4) were randomized to receive either oral controlled-release mononitrate therapy or placebo; thrombolytic therapy was administered to patients in both groups. The results of this study revealed no benefit to the routine administration of oral nitrate therapy in this setting. Similar results were seen among 19, 000 patients in the third Gruppo Italiano per lo Studio della Sopravvivenza nell' Infarto Miocardico (GISSI-3) Study, in whom IV nitroglycerin was administered for the first 24 hours, followed by transdermal nitrates. Whether these disappointing results in the ISIS-4 and GISSI-3 trials were caused by the routes of administration of the nitroglycerin preparation or the administration of thrombolytic therapy is unknown. However, on the basis of existing data, it does not appear that the routine administration of nitroglycerin to patients receiving early thrombolytic therapy is beneficial. IV nitroglycerin is probably most likely to be beneficial in patients with persistent or recurrent chest pain after reperfusion therapy and in patients in whom reperfusion therapy is not administered.

Insulin Therapy

Diabetic patients have a significantly worse prognosis after myocardial infarction than those without diabetes, mainly because of greater left ventricular dysfunction and increased reinfarction rates. This applies to both patients who are newly diagnosed on the coronary care unit and those already diagnosed. Recent evidence from the DIGAMI study suggests that a more intensive approach to achieving metabolic control in patients presenting with hyperglycaemia may be beneficial. Six hundred and twenty patients presenting within 24 hours of a myocardial infarction with a blood glucose concentration greater than 11 mmol/L (whether known to have diabetes mellitus or not) were randomised to receive a glucose-insulin infusion followed by subcutaneous insulin four times daily for at least 3 months. Patients in the control group only received insulin if indicated by normal clinical practice. The mean time to randomisation was 13 hours after the onset of symptoms. The target range plasma glucose was 7–10.9 mmol/L, with 2 hours monitoring of plasma glucose for at least 24 hours. There were hypoglycaemic episodes in 15% of patients receiving intensive therapy. Mortality at 1 year was 29% lower in the intervention group than in the control group (95% CI 4%, 51%). After a mean follow-up of 3.4 years there was a 28% relative risk reduction in mortality in the glucose insulin treatment group (95% CI 8%, 45%). The benefit was particularly apparent in the low risk patients (age < 70, no previous infarct, no heart failure) who were not previously using insulin (51% reduction, 95% CI 19, 70%). In this group the benefit was already apparent at the time of hospital discharge and continued to 5 years of follow-up. The results suggest that diabetic patients are likely to benefit from an early intensive approach to metabolic control although this is likely to pose logistic problems for many units.

Prophylactic Antiarrhythmic Therapy

Previously, routine prophylactic antiarrhythmic therapy with IV lidocaine was recommended for all patients in the early stages of acute myocardial infarction. However, studies have revealed that prophylactic therapy with lidocaine does not reduce and may actually increase mortality because of an increase in the occurrence of fatal bradyarrhythmia and asystole. Neither IV lidocaine nor other antiarrhythmic agents are recommended as prophylactic therapy for patients without malignant ventricular ectopy.

Calcium Channel Antagonists

Calcium channel antagonists should not be routinely administered for acute myocardial infarction. Calcium channel antagonists have been studied in prospective, doubleblind, placebo-controlled trials; and neither verapamil nifedipine nor diltiazem appears to reduce postinfarction mortality. Verapamil and diltiazem may be useful in patients with preserved left ventricular function and no heart failure in whom contraindications to beta-blockers exist. However, the data are insufficient to recommend the routine administration of these agents. On the basis of existing data, treatment with calcium channel blockers should be reserved for patients with ischemia that persists despite use of aspirin, beta-blockers, nitrate therapy, and IV heparin and for patients with other indications for their administration.

Magnesium

Magnesium has been studied in many prospective, randomized trials of acute myocardial infarction, and the results have been conflicting. Magnesium is involved in hundreds of enzymatic steps and produces systemic and coronary vasodilatation, inhibits platelet function, and reduces reperfusion injury. Meta-analysis of seven prospective, randomized trials revealed a significant reduction in mortality with the use of magnesium. It is possible that magnesium is of benefit, particularly in patients not receiving reperfusion therapy. Magnesium is clearly indicated in patients with myocardial infarction who have torsade de pointes-type ventricular tachycardia and in patients with magnesium deficiency.

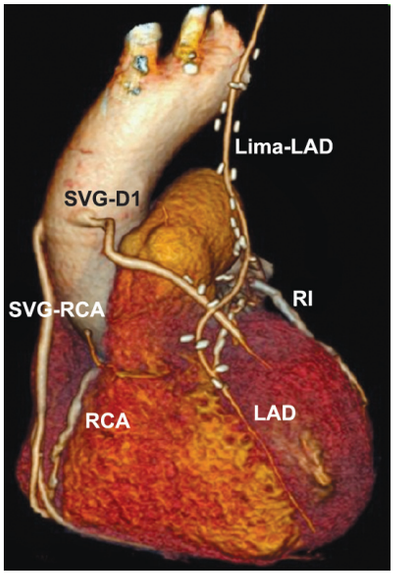

Fig. 3.79: CABG: MD.CT 64 slices of the LV and aorta showing CABG with intact grafts from ascending aorta to the proximal of of the obstructed right coronary artery and left anterior descending artery in the process of perfusion plan in the management of ischemic myocardiumas a result of myocardial infarction

Coronary Artery Bypass Surgery

Coronary artery bypass surgery can restore blood flow in an occluded infarct-related artery. However, because of the time required to perform coronary angiography and to transport patients to the operating room, reperfusion is achieved more slowly with bypass surgery than with thrombolytic therapy and primary coronary angioplasty. Emergency coronary artery bypass surgery should generally be reserved for patients in whom immediate angiography reveals coronary anatomy that precludes primary coronary angioplasty; for patients in whom angioplasty has failed; and for patients with a ventricular septal defect, severe mitral regurgitation, or myocardial rupture.

Prognosis in ACS

Six-month mortality rates in the global registry of acute coronary events (GRACE) were 13% for patients with NSTEMI ACS and 8% for those with unstable angina.

An elevated level of troponin (a type of regulatory protein found in skeletal and cardiac muscle) permits risk stratification of patients with ACS and identifies patients at high risk for adverse cardiac events (i.e. myocardial infarction, death) up to 6 months after the index event.

The PROVE IT-TIMI trial found that after ACS, a J-shaped or U-shaped curve association is observed between BP and the risk of future cardiovascular events.

LeLeiko et al. determined that serum choline and free F(2)-isoprostane are also predictors of cardiac events in ACS. The authors evaluated the prognostic value of vascular inflammation and oxidative stress biomarkers in patients with ACS to determine their role in predicting 30-day clinical outcomes. Serum F(2)-isoprostane had an optimal cutoff level of 124.5 pg/ml, and serum choline had a cutoff level of 30.5 µmol/L. Choline and F(2)-isoprostane had a positive predictive value of 44% and 57% and a negative predictive value of 89% and 90%, respectively.

Testosterone deficiency is common in patients with coronary disease and has a significant negative impact on mortality. Further study is needed to assess the effect of treatment on survival.

A study by Sanchis et al. suggests renal dysfunction, dementia, peripheral artery disease, previous heart failure, and previous myocardial infarction are the comorbid conditions that predict mortality in NSTEMI ACS. In patients with comorbid conditions, the highest risk period was in the first weeks after NSTEMI ACS. In-hospital management of patients with comorbid conditions merits further investigation.

Patients with end-stage renal disease often develop ACS, and little is known about the natural history of ACS in patients receiving dialysis.

NSTEMI ACS was the most common in patients receiving dialysis, occurring in 50% of patients (290 of 579) versus 33% of those not receiving dialysis. The in-hospital mortality rates were higher among patients receiving dialysis (12% vs 4.8%; $p < 0.0001$). Higher 6-month mortality

Table 3.8: Adverse prognostic features in myocardial infarction

- Advanced age
- Diabetes
- Left ventricular failure
- Systolic hypotension
- anterior full-thickness infarction
- Left bundle brench block
- History of previous myocardial infarction (complex ventricular arrhythmias, particulary those occuring late >36 hours) after myocardial infarction

rates (13% vs 4.2%; p <0.0001), recurrent myocardial infarction incidence (7.6% vs 2.9%; p <0.0001), and unplanned rehospitalizations (31% vs 18%; p <0.0001) were found among those who survived to discharge. Outcomes in patients who received dialysis was worse than was predicted by the calculated GRACE risk score for in-hospital mortality (7.8% predicted vs 12% observed; p <0.05). This suggests that the GRACE risk score underestimated the risk of major events in these patients (Table 3.8).

In a study that assessed the impact of prehospital time on STEMI outcome, Chughatai et al. suggest that 'total time to treatment' should be used as a core measure instead of 'door-to-balloon time'. This is because on-scene time was the biggest fraction of 'prehospital time'. The study compared groups with total time to treatment of more than 120 minutes compared with 120 minutes or less and found mortalities were 4 compared with 0 and transfers to a tertiary care facility were 3 compared with 1, respectively.

Telemedicine and Newer ECG Techniques in Fighting Acute Coronary Syndromes

Transmitting 12-lead ECGs from the community directly to attending cardiologists should become routine. Time to reperfusion in STEMI has decreased, explaining much of the observed decrease in STEMI mortality. This technology allows for increasingly complex and individualized prehospital medical care and could be expanded to a broader number of cardiovascular diagnoses (Figs 3.80–3.83).

Automated, Implantable Cardioverter-defibrillator (Fig. 3.84)

Automated implantable cardioverter-defibrillators are of proven benefit in patients with coronary artery disease, reduced left ventricular ejection fraction, nonsustained ventricular tachycardia, and inducible ventricular tachycardia. It has been proposed that patients with a prior myocardial infarction and advanced left ventricular dysfunction may benefit from prophylactic implantation of a defibrillator (in the absence of electrophysiologic testing to induce arrhythmias). Prophylactic implantation of a defibrillator is a recommended therapy in this patient population.



Fig. 3.80: Showing ECG 80 leads placement on patient with chest pain of recent onset



Fig. 3.81: Heartscape 80-lead 3D ECG system, Heartscape 80-lead 3D ECG system. The concept is not entirely new, as it is the successor to the PRIME ECG system which has the same amount of leads, and has been available since 2003. The Heartscape 3D ECG System aims to give a 360 degree electrocardiographic view of the heart, to helping in identifying myocardial infarcts without ST-segment elevation on traditional 12-lead ECGs, and in patients with left bundle branch block.Compared to traditional 12-lead ECG's, the system has shown to be more sensitive while retaining comparable specificity in detecting acute infarcts

Patient Education

Patient education of risk factors is important, but more attention is needed regarding delays in door-to-balloon time, and one major barrier to improving this delay is patient education regarding his or her symptoms. Lack of

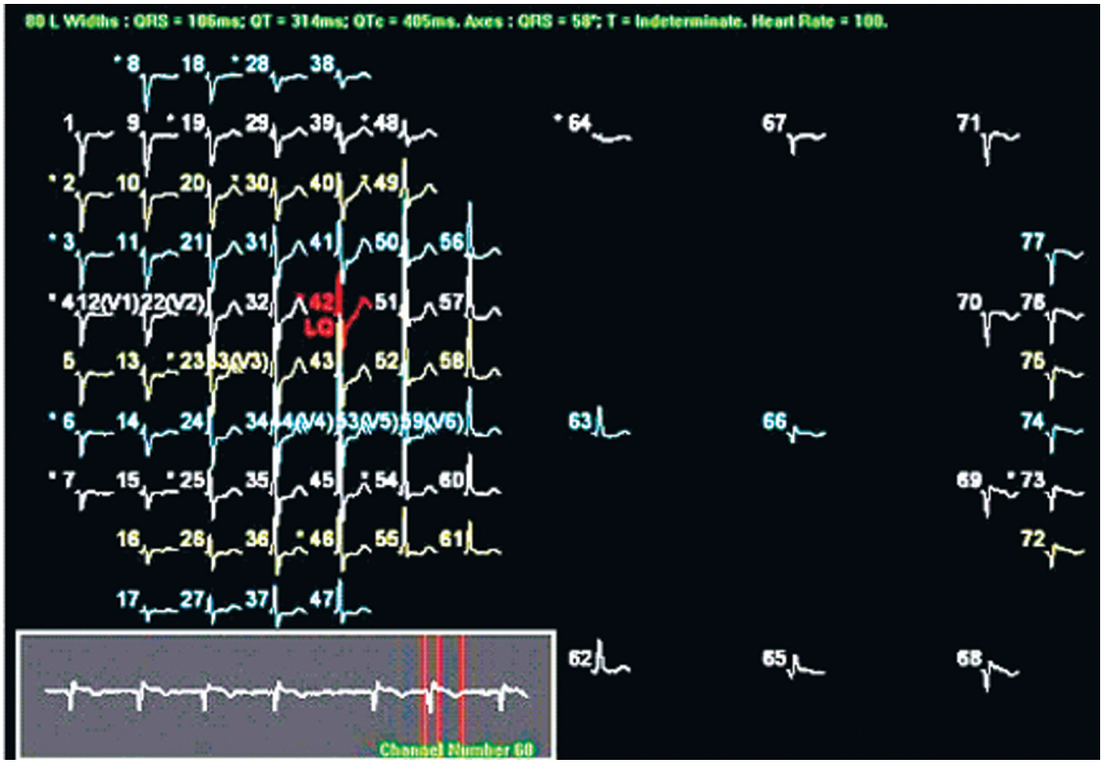

Fig. 3.82: Example of a STEMI missed on 12-lead EKG detected on 80-Lead EKG. An 80-lead EKG system shown to the right are the 80-EKG lead tracings displayed individually. The anterior leads is displayed on the left-hand side. The posterior or back of the heart leads are displayed on the right-hand side of the figure. For instance lead-68 shows ST-elevation. Posterior and right-sided leads reveal ST-elevation, where the 12-lead was silent



Fig. 3.83: Laboratory equipment in telemedicine

recognition of symptoms may cause tremendous delays in seeking medical attention.

Educate patients about the dangers of cigarette smoking, a major risk factor for coronary artery disease (CAD). The risk of recurrent coronary events decreases 50% at 1 year after smoking cessation. Provide all patients who smoke with guidance, education, and support to avoid smoking. Smoking-cessation classes should be offered to help patients avoid smoking after a myocardial infarction.

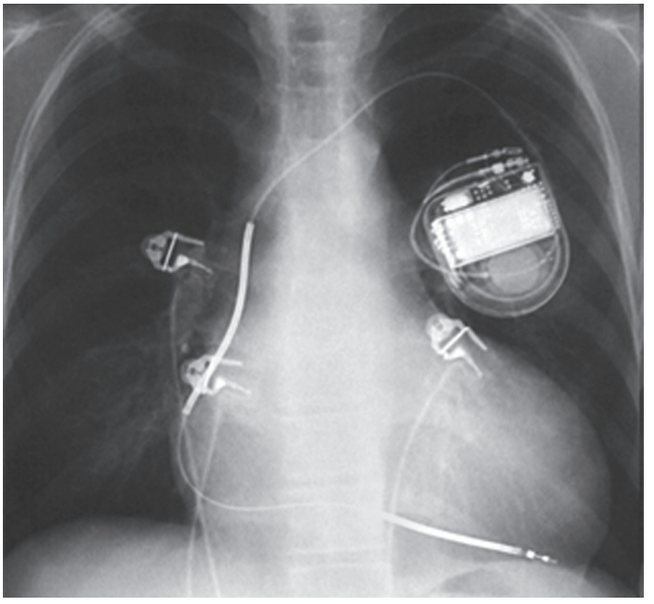

Fig. 3.84: Frontal view of the chest shows a typical automatic implantable cardioverter defibrillator

Bupropion increases the likelihood of successful smoking cessation.

Diet plays an important role in the development of CAD. Therefore, prior to hospital discharge, a patient who has

had a myocardial infarction should be evaluated by a dietitian. Patients should be informed about the benefits of a low-cholesterol, low-salt diet. In addition, educate patients about AHA dietary guidelines regarding a low-fat, low-cholesterol diet.

A cardiac rehabilitation program after discharge may reinforce education and enhance compliance.

The following mnemonic may useful in educating patients with CAD regarding treatments and lifestyle changes necessitated by their condition:

A = Aspirin and antianginals

B = Beta-blockers and blood pressure (BP)

C = Cholesterol and cigarettes

D = Diet and diabetes

E = Exercise and education

For patients being discharged home, emphasize the following:

- Timely follow-up with primary care provider
- Compliance with discharge medications, specifically aspirin and other medications used to control symptoms
- Need to return to the ED for any change in frequency or severity of symptoms

Current Techniques in the Revival of Myocardial Damage after Myocardial Infarction Under Trials

Myogenesis in the Heart Muscle

Myoblasts are super powerhouse cells that originate from human body's muscle stem cells. These cells have the ability to take on the properties of the other cells, such as cardiac muscle cells that make up the heart. The myoblasts can be transplanted from the skeletal muscles into heart and can stimulate myogenesis. Other trials, such as intracoronary stem cell implantation and genetic transformation into myocardfial cells are under review (Fig. 3.85).

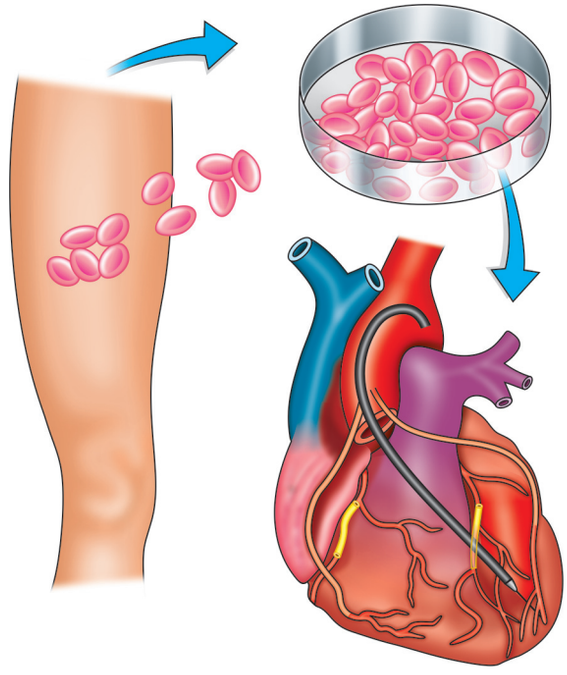

Fig. 3.85: Diagrammatic depiction of myogenesis in the heart muscle. Myoblasts are super powerhouse cells that originate from human body's muscle stem cells. These cells have the ability to take on the properties of the other cells, such as cardiac muscle cells that make up the heart. The myoblasts can be transplanted from the skeletal muscles into heart and can stimulate myogenesis. A biopsy of muscle cells from patient thigh is taken and isolated, and expanded in culture in a special cell laboratory for 3 weeks. These multiple cells are injected directly into the areas of heart where the muscle is damaged

Percutaneous Coronary Intervention Versus Optimal Medical Therapy in Stable Coronary Artery Disease (Systematic Review and Meta-analysis of Randomized Clinical Trials 2012)

In summary, in patients with stable CAD there is no definitive evidence of an added benefit of PCI to reduce the risk of mortality, cardiac death, nonfatal MI, and need for revascularization, when compared with medical therapy alone. PCI appeared to show a benefit for all-cause mortality and cardiac death that was attenuated when recent studies (with more aggressive medical therapy) with a high proportion of stent use were analyzed. However, PCI provides a benefit over medical therapy in symptom relief of angina in patients with stable CAD.

A greater understanding of the pathophysiology of atherosclerosis has led to advancements in PCI with the advent of DES and improvements in medical therapies. In addition, the prior strategy trials have been criticized for enrolling participants after cardiac catheterization (creating selection bias), enrolling lower risk individuals (without significant ischemia) and with the use of DES (only first generation) in a small fraction of the cohort. Ongoing trials, such as the International Study of Comparative Health Effectiveness with Medical and Invasive Approaches (ISCHEMIA), will test treatment strategies upstream of cardiac catheterization and involve patients with at least moderate ischemia, with the use of contemporary optimal medical and optimal revascularization strategies, with a sample size (N=8000) large enough to detect small differences in outcomes.

QUICK READINGS

BOX 3.1: Frequent questions to be asked by the reader in acute coronary syndrome

What is an acute coronary syndrome?

ACS includes myocardial infarction (MI), also known as a heart attack, and unstable angina, or sudden, severe chest pain that typically occurs when a person is at rest. Every year, ACS affects an estimated 1.4 million people in the United States and another 1.4 million people in Europe.

Contd...

Contd...

What is the most common cause of acute coronary syndrome?

Eventually, this buildup means that your heart cannot pump enough oxygen-rich blood to the rest of your body, causing chest pain (angina) or a heart attack. Most cases of acute coronary syndrome occur when the surface of the plaque buildup in your heart arteries ruptures and causes blood clot to form.

What is a NSTEMI heart attack?

A heart attack is a form of acute coronary syndrome (ACS), where there is a significant blockage in the coronary arteries. There are three main types of ACS: ST-segment elevation myocardial infarction (STEMI), non-ST-segment elevation myocardial infarction (NSTEMI) and unstable angina.

What is the difference between STEMI and NSTEMI?

There are two types, STEMI, which is the abbreviation of ST-elevation myocardial infarction, and NSTEMI, which stands for non-ST-elevation myocardial infarction. The names reflect differences in the ECG tracings—specifically whether a portion of the ECG called the ST-segment is elevated above baseline, or not.

BOX 3.2: Key points in heart attack treatment guidelines

The American College of Cardiology and the American Heart Association, in collaboration with the Society for Cardiovascular Angiography and Intervention, and the American Association of Cardiovascular and Pulmonary Rehabilitation, have developed a series of guidelines that address the treatment of heart attack. These guidelines apply to most patients, but also give your doctor the flexibility to tailor treatment to your specific clinical needs. Below is a summary of key information and recommendations.

Early hospital care

When you arrive at the hospital you will have blood tests called cardiac biomarkers to check for damage to your heart muscle.

- Have an **electrocardiogram (ECG)** to evaluate your heart's rhythm and look for abnormalities in the heart's electrical system
- Be treated with several medications that protect your heart and relieve pain. These may include a beta-blocker, nitroglycerin, and morphine. You will also be given an aspirin tablet to chew, if you have not taken one already.
- If your heart stopped beating during or after your heart attack (cardiac arrest), your doctor may use a treatment called therapeutic hypothermia. This involves infusion of a liquid into your blood vessels that cools your body to about 90°F for up to 24 hours. Cooling your body will help protect against brain damage that can occur when the brain is deprived of blood during cardiac arrest.
- The next steps in your treatment will depend on what type of heart attack you are having. There are two types, STEMI, which is short-hand for ST-elevation myocardial infarction, and NSTEMI, which stands for non-ST-elevation myocardial infarction. The names reflect differences in the ECG tracings—specifically whether a portion of the ECG called the ST-segment is elevated above baseline, or not. More important, there are differences in the underlying cause of these two types of heart attack and, therefore, in the initial treatment.

STEMI

A STEMI heart attack is caused when a blood clot suddenly forms, completely blocking an artery in the heart. This can result in damage that covers a large area of the heart and extends deep into the heart muscle. The priority in treating a STEMI heart attack is to open the artery quickly, saving as much heart muscle as possible. Treatment options include percutaneous coronary intervention (PCI), a term that encompasses both angioplasty and stenting; clot-busting medication; and coronary artery bypass graft surgery (CABG).

PCI

PCI is the first choice for the treatment of STEMI, if it is available. The goal is to open the artery within 90 minutes of the patient first receiving care by emergency medical workers, including ambulance personnel.

If your hospital does not have a PCI program, the next best option may be rapid transfer to a nearby medical center that is experienced and prepared to use PCI to treat heart attack. The goal in this case is to open the artery within 2 hours of the patient first receiving care by emergency medical workers. In many areas of the country, regional STEMI networks are being set up to make transport to a PCI hospital fast and efficient.

Clot-busting medication

Most hospitals do not have a cardiac catheterization laboratory available 24 hours a day to treat heart attack patients. If you seek emergency treatment at a hospital that is not equipped to perform PCI, and the nearest PCI-capable hospital is too far away to meet the goal of opening the artery within 2 hours, clot-busting medications are an effective treatment option. These medications, also called fibrinolytics, open the artery by dissolving the clot. The goal is to infuse clot-busting medications within 30 minutes of a patient's arrival at the hospital.

In some cases, your doctor may decide that you should have PCI in addition to treatment with clot-busting medication. With this 'pharmacoinvasive strategy', clot-busting medication is used at the first hospital to initially restore blood flow to your heart, then after transport to a PCI-capable hospital, PCI is performed within 24 hours to make sure the artery is fully open and supported with a stent.

Coronary Artery Bypass Graft Surgery (CABG)

In some cases, emergency **bypass surgery** may be the best option, especially if you are medically unstable and cannot be treated with PCI or clot-busting medications, or when these treatments fail. Emergency CABG may also be needed if serious complications develop after a heart attack, such as shock, life-threatening abnormalities of the heart rhythm, or rupture of heart tissues. Your doctor may also recommend having CABG surgery within the first 2 days of a heart attack if you have several clogged arteries and start experiencing a return of chest pain while resting quietly.

Contd...

Contd...

NSTEMI

NSTEMI heart attacks are different from STEMI heart attacks in several ways, not just how they appear on the ECG. With NSTEMI, the heart attack damage usually does not extend through the full depth of the heart muscle. Equally important, NSTEMI heart attacks are caused by different types of blood clots than STEMI heart attacks, with differing amounts of clotting proteins and platelet blood cells. Therefore, the treatment of NSTEMI heart attacks differs from the treatment of STEMI heart attacks. Clot-busting medications, for example, are not effective, and although PCI may be part of the treatment, opening the artery within 90 minutes is not a primary goal.

Diagnosis of NSTEMI can be complex, as the diagnostic signs do not always show up right away. Your doctor may repeat the ECG and cardiac biomarker blood tests several times, and carefully analyze the pattern and severity of your chest pain, your other symptoms, and your history of heart disease to determine your level of risk. You may be transferred to a special chest pain unit for observation for several hours. After that, if your chest pain has not returned and the diagnosis is still unclear, your doctor may order an imaging test of your heart (a **nuclear scan**, a type of ultrasound known as **echocardiography,** or a **treadmill stress test**). This will help to determine a final diagnosis.

Once the diagnosis of NSTEMI has been made, you will be admitted to the hospital. Medications to protect your heart and reduce its workload (beta-blockers, nitroglycerin, and possibly an angiotensin-converting-enzyme (ACE) inhibitor or angiotensin-receptor blocker) will be continued. Your doctors will also add one or more **anti-clotting medication**s to prevent blood clots.

Within the first 12–24 hours of your hospital stay, your doctor will select one of two main treatment strategies. One option is continued treatment with medications that protect your heart, reduce its workload, and prevent blood clots. This is a reasonable strategy if your condition is stable and you are not at high risk for serious cardiac complications.

The second treatment option is an 'early invasive' strategy. This means that you will go to the cardiac catheterization laboratory for **angiography,** a procedure that enables your doctor to see inside the arteries of your heart. Usually angiography is followed by PCI and stenting to widen clogged, inflamed portions of the arteries where blood clots may have formed. The 'invasive' strategy is a reasonable option if you are continuing to have chest pain, are medically unstable, or have a high-risk history of heart disease.

During your hospital stay

Whether you have a STEMI or NSTEMI heart attack, you will begin to take steps toward recovery and a healthy new lifestyle while you are still in the hospital. You will learn about your medications and begin eating a heart-healthy diet that is low in sodium, cholesterol, and fat (especially 'saturated' animal fats). As soon as it is safe, you will also begin mild exercise, such as walking in the hallway. In addition, your doctor will refer you to a cardiac rehab program, so that you can continue. You may have an imaging test while in the hospital, or shortly after discharge, to evaluate how efficiently your heart is pumping blood. This information, known as the ejection fraction or systolic function, will guide your doctor in prescribing medications and other treatments.

Discharge from the hospital

When you are ready to go home, you will be prescribed several medications that have been proven to protect the heart, help it to function better, and prevent repeat heart attacks. Your medications will include some or all of the following:

- Aspirin, to keep platelets in the blood from clumping together and forming blood clots
- Another anticlotting medication such as clopidogrel or prasugrel, or ticagrelor. How much anticlotting medication you take, which specific drug, and how long you take it will depend on your medical condition and whether you were treated with a stenting procedure.
- Beta-blocker
- Cholesterol-lowering therapy
- Angiotensin-converting-enzyme (ACE) inhibitor or angiotensin-receptor blocker (ARB), if your heart is not pumping as strongly as it should

Certain medications used to treat heartburn—called proton pump inhibitors—may reduce the effectiveness of anti-clotting medications. Talk to your doctor about what type of heartburn medication is safe to use.

Staying healthy after the hospital

Participating in a cardiac rehabilitation program a high priority for anyone who has had a heart attack. Not only will cardiac rehab help you to feel healthy and strong again, it can actually help you to live longer. Your cardiac rehab program will teach you to:

- Stop smoking and/or using tobacco products
- Follow a heart-healthy diet
- Exercise safely, guided by specially trained physical therapists, nurses, and doctors
- Manage stress and anxiety
- Safely resume your sex life
- Avoid a second heart attack
- In addition to participating in a cardiac rehab program, the following steps will help prevent a second heart attack and keep your arteries from becoming clogged with atherosclerotic plaque:
  - Quit smoking, and avoid second-hand smoke
  - Keep blood pressure under 140/90 mmHg (or lower, if you have diabetes or heart failure)
  - Keep LDL ('bad') cholesterol under 100 mg/dl, or under 70 mg/dl if you are at high risk. This is generally accomplished through the use of statin medications.
  - Exercise for 30–60 minutes at least 5 days a week. The exercise should be moderate-intensity, such as brisk walking.

Contd...

Contd...

- Maintain a normal body weight
- Maintain good diabetes control
- Take low-dose aspirin daily to prevent unwanted blood clots, plus additional anticlotting medication if advised by your doctor
- Take an ACE inhibitor or ARB, if your heart's pumping ability is abnormal or you have heart failure
- Take beta-blockers to protect the heart and reduce its workload
- Get an annual flu shot
- Seek treatment for depression

BIBLIOGRAPHY

1. Alpert JS, Thygesen K, Antman E, et al. Myocardial infarction redefined—a consensus document of The Joint European Society of Cardiology/American College of Cardiology Committee for the redefinition of myocardial infarction. J Am Coll Cardiol 2000;36(3):959–69.
2. Antman EM, Tanasijevic MJ, Thompson B, Schactman M, McCabe CH, Cannon CP, et al. Cardiac-specific troponin I levels to predict the risk of mortality in patients with acute coronary syndromes. N Engl J Med 1996;335(18):1342–9.
3. Bangalore S, Qin J, Sloan S, et al. What is the optimal blood pressure in patients after acute coronary syndromes?: Relationship of blood pressure and cardio-vascular events in the PRavastatin OR atorVastatin Evaluation and Infection Therapy—Thrombolysis In Myocardial Infarction (PROVE IT-TIMI) 22 trial. Circulation 2010;122(21):2142–51.
4. Chughtai H, Ratner D, Pozo M, et al. Prehospital delay and its impact on time to treatment in ST-elevation myocardial infarction. Am J Emerg Med 2011;29(4):396–400.
5. Damman P, Holmvang L, Tijssen JG, et al. Usefulness of the Admission Electrocardiogram to Predict Long-Term Outcomes After Non-ST-Elevation Acute Coronary Syndrome (from the FRISC II, ICTUS, and RITA-3 [FIR] Trials). Am J Cardiol 2012;109(1):6–12.
6. Gurm HS, Gore JM, Anderson FA Jr, et al. Comparison of Acute Coronary Syndrome in Patients Receiving Versus Not Receiving Chronic Dialysis (from the Global Registry of Acute Coronary Events [GRACE] Registry). Am J Cardiol 2012;109(1):19–25.
7. Hamm CW, Bassand JP, Agewall S, et al. ESC Guidelines for the management of acute coronary syndromes in patients presenting without persistent ST-segment elevation: The Task Force for the management of acute coronary syndromes (ACS) in patients presenting without persistent ST-segment elevation of the European Society of Cardiology (ESC). Eur Heart J 2011.
8. Heidenreich PA, Alloggiamento T, Melsop K, et al. The prognostic value of troponin in patients with non-ST-elevation acute coronary syndromes: a meta-analysis. J Am Coll Cardiol 2001;38(2):478–85.
9. Iliou MC, Fumeron C, Benoit MO, Tuppin P, et al. Prognostic value of cardiac markers in ESRD: Chronic Hemodialysis and New Cardiac Markers Evaluation (CHANCE) study. Am J Kidney Dis 2003;42(3):513–23.
10. Keller T, Zeller T, Ojeda F, et al. Serial changes in highly sensitive troponin I assay and early diagnosis of myocardial infarction. JAMA 2011;306(24):2684–93.
11. LeLeiko RM, Vaccari CS, Sola S, et al. Useful-ness of elevations in serum choline and free F2—isoprostane to predict 30-day cardiovascular outcomes in patients with acute coronary syndrome. Am J Cardiol 2009;104(5):638–43. [Best Evidence]
12. Lindahl B, Toss H, Siegbahn A, et al. Markers of myocardial damage and inflammation in relation to long-term mortality in unstable coronary artery disease. FRISC Study Group. Fragmin during Instability in Coronary Artery Disease. N Engl J Med 2000;343(16):1139–47.
13. Ma RC, Tong PC. Testosterone levels and cardiovascular disease. Heart 2010;96(22):1787–8 [Medline].
14. Newby LK, Christenson RH, Ohman EM, et al. Value of serial troponin T measures for early and late risk stratification in patients with acute coronary syndromes. The GUSTO-IIa Investigators. Circulation 1998;98(18):1853–9.
15. O'Connor RE, Bossaert L, Arntz HR, et al. Part 9: acute coronary syndromes: 2010 International Consensus on Cardiopulmonary Resuscitation and Emergency Cardio-vascular Care Science with Treatment Recommendations. Circulation 2010;122 (16 Suppl 2): S422–65.
16. Ohman EM, Armstrong PW, Christenson RH, et al. Cardiac troponin T levels for risk stratification in acute myocardial ischemia. GUSTO IIA Investigators. N Engl J Med 1996; 335(18):1333–41.
17. O'Neil BJ, Hoekstra J, Pride YB, et al. Incremental benefit of 80-lead electrocardio-gram body surface mapping over the 12-lead electro-cardiogram in the detection of acute coronary syndromes in patients without ST-elevation myocardial infarction: Results from the Optimal Cardiovascular Diag-nostic Evaluation Enabling Faster Treatment of Myocardial Infarction (OCCULT MI) trial. Acad Emerg Med2010;17(9): 932–9.
18. Sanchis J, Nunez J, Bodí V, et al. Influence of comorbid conditions on one-year outcomes in non-ST-segment elevation acute coronary syndrome. Mayo Clin Proc 2011;86(4):291–6.
19. Scheuermeyer FX, Innes G, Grafstein E, et al. Safety and efficiency of a chest pain diagnostic algorithm with selective outpatient stress testing for emergency department patients with potential ischemic chest pain. Ann Emerg Med 2012.
20. Than M, Cullen L, Reid CM, et al. A 2-h diagnostic protocol to assess patients with chest pain symptoms in the Asia-Pacific region (ASPECT): a pros-pective observational validation study. Lancet 2011;377(9771):1077–84.

4 Invasive and Noninvasive Coronary Angiography

HISTORICAL BACKGROUND

The technique of angiography was first developed in 1927 by the Portuguese physician Egas Moniz at the University of Lisbon to provide contrasted X-ray in order to diagnose nervous diseases, such as tumors, coronary heart disease and arteriovenous malformations. He is recognized as one of the pioneers in this field. Coronary catheterization was further explored in 1929 when the German physician Werner Forssmann inserted a plastic tube in his cubital vein and guided it to the right chamber of the heart. He took an X-ray to prove his success and published it on November 5th, 1929 with the title 'Über die Sondierung des rechten Herzens' (About probing of the right heart) (Fig. 4.1).

The coronarography of the left heart was introduced in 1953 with the report by a Portuguese group, published in Cardiologia, International Archives of Cardiology vol. 22, pp 45–61, by E. Coelho et al. entitled "Arteriografia das coronárias no homem vivo/L'artériograpie des coronaires chez l'homme vivant" (arteriography of the coronaries in the living man). They were the first to nonselectively inject radiocontrast in the coronary arteries. In 1960, F. Mason Sones, a pediatric cardiologist at the Cleveland Clinic, accidentally injected radiocontrast in a coronary artery instead of the left ventricle. Although the patient had a reversible cardiac arrest, Sones and Shirey developed the procedure further, and are credited with the discovery (Connolly 2002); they published a series of 1,000 patents in 1966 (Proudfit et al.). Since the late 1970s, building on the pioneering work of Charles Dotter in 1964 and especially Andreas Gruentzig starting in 1977, coronary catheterization has been extended to therapeutic uses.

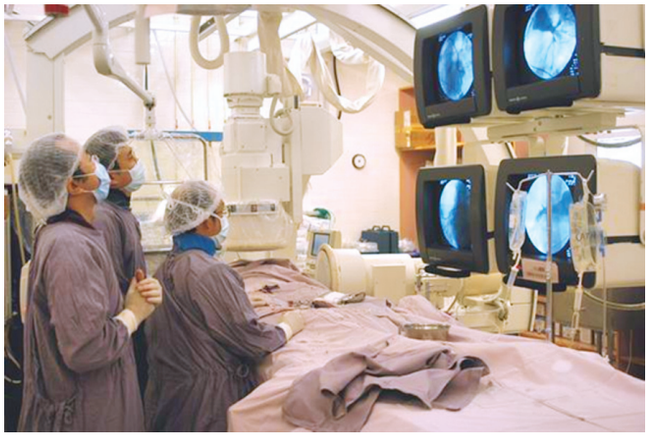

Fig. 4.1: Catheterization laboratory and busy medical personnel in preparing patient for heart catheterization

- The performance of less invasive physical treatment for angina and some of the complications of severe atherosclerosis
- Treating heart attacks before complete damage has occurred
- Research for better understanding of the pathology of coronary artery disease and atherosclerosis
- In the early 1960s, cardiac catheterization frequently took several hours and involved significant complications for as many as 2–3% of patients. With multiple incremental improvements over time, simple coronary catheterization examinations are now commonly done more rapidly and with significantly improved outcomes.

Basics of Coronary Anatomy

The trileaflet aortic valve gives rise to 3 cusp or sinuses in the aortic root. The left coronary and right coronary cusp give rise to their respective coronary arteries while the noncoronary cusp which arises from the posterior root usually does not give rise to a coronary artery (Fig. 4.2).

The major epicardial vessels supplying the myocardium are the left main coronary artery that divides into the left anterior descending artery and left circumflex artery, and the right coronary artery. These arteries lie on the epicardial surface and supply smaller branch vessels that eventually give rise to the microvascular network supplying the

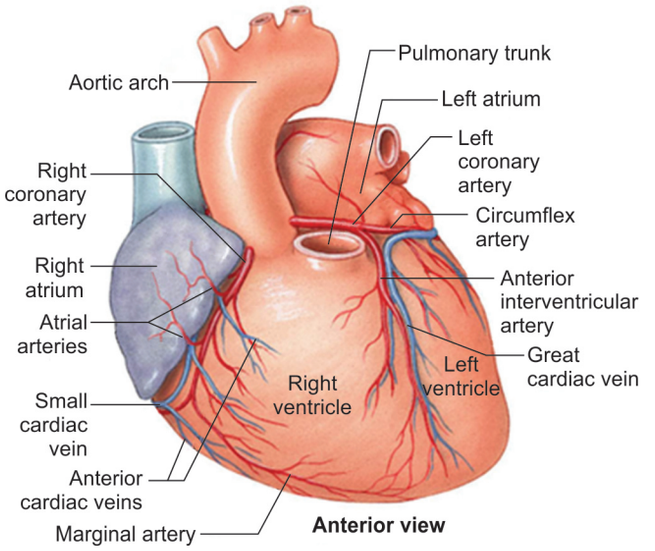

Fig. 4.2: Anatomy of main coronary arteries which are usually visualized by coronary angiography

myocardium. Coronary dominance is based on the vessel that gives rise to the posterior descending artery (PDA) which travels in the posterior interventricular groove and supplies the atrioventricular node (AV node). This vessel, which can be recognized by the presence of septal perforating branches, arises from the right coronary artery (RCA) in 80% of the population and the left circumflex (LCx) in 10% of the population. Co-dominance of the arterial circulation is found in 10% of the population where the posterior interventricular artery is formed by both the RCA and LCx. The left main coronary artery or left main trunk (LMT) originates from the left coronary cusp and bifurcates to give rise to the left anterior descending (LAD) and left circumflex (LCx) coronary arteries. Occasionally, a third branch vessel, the ramus intermedius (RI) arises from the LMT. The LMT varies in length in many patients and in a small number of patients, the two major branch vessels arise from separate origins.

The left anterior descending coronary artery provides blood supply to the anterior wall of the left ventricle. As it courses through the anterior intraventricular groove it provides multiple septal branches to the interventricular septum and diagonal branches to the anterior lateral wall. The LAD then courses to the ventricular apex and in some patients wraps around the apex to supply a small amount of the posterior apex.

The left circumflex coronary artery courses around the lateral or left atrioventricular groove and gives rise to multiple marginal or lateral branches. The branches are termed obtuse marginal (OM) or lateral branches depending on institutional preference. OM branches are sequentially numbered (OM1, OM2, etc.) while lateral branches are termed based on the segment of the lateral wall they supply (high lateral, lateral, and posterior lateral). As the LCx courses the AV groove it also gives rise to several atrial branches, and occasionally the sino-atrial branch (40% of the population).

The right coronary artery arises from the right coronary cusp. This vessel follows the right AV groove and provides branches to the right ventricle. The most proximal branches of the RCA are the conus-branch which supplies the right ventricular outflow tract and a branch that supplies the sinoatrial (SA) node (60% of patients). The RCA then courses through the interventricular and gives rise to marginal branches and branches to the atrium. Manipulation of the coronary arteries in 3-dimensions via spacial reconstructions of the coronary arteries is helpful in interpreting coronary angiographic images.

MAIN OBJECTIVE OF CORONARY ANGIOGRAPHY

1. Coronary luminal obstruction:
   - Guide revascularization decisions
   - Severity of luminal narrowing
   - Distribution of stenotic lesions
   - Identification of acute thrombotic lesion
2. Coronary blood flow
3. LV systolic and diastolic function, ejection fraction, and regional wall motion
4. Anomalous vessel
5. Coronary collateral circulation

The first attempts to visualize the coronary arteries in living humans were published in 1945 by Radner S, who used trans-sternal punctures to inject contrast material into the ascending aorta. High complication rate with poor results, the technique was abandoned. The first selective coronary angiogram was performed by Mason Sones in 1959 through the brachial cut-down technique. With the prior introduction of the Seldinger wire cannulation method for vascular cannulation percutaneous transfemoral catheterization technique was developed. Judkins, Amplatz, Abrams and others invented preformed catheters that could be passed with great ease from the femoral artery to the coronary ostium. Arterial access most commonly femoral, brachial or radial arteries can also be used. Catheter size depends on several patient variables including:

1. Aortic root size and shape
2. Aortic valve plane orientation
3. Angle of coronary ostial origin

Typically, left and right Judkins catheters are used to engage the left coronary artery (LCA) and the right coronary artery respectively.

Provides excellent delineation of coronary anatomy in vessels >400 um in diameter.

Major deficiencies include:

- Mainly shows the anatomy of the arterial lumen opposed to the wall of the artery.
- It is a 2D shadow of a 3D object.

Explanation of Test to the Patient

The patient being examined or treated is usually awake during coronary catheterization, ideally with only local anesthesia, such as lidocaine and minimal general sedation,

throughout the procedure. Performing the procedure with the patient awake is safer as the patient can immediately report any discomfort or problems and thereby facilitate rapid correction of any undesirable events. Medical monitors fail to give a comprehensive view of the patient's immediate well-being; how the patient feels is often a most reliable indicator of procedural safety. Death, myocardial infarction, stroke, serious ventricular arrhythmia, and major vascular complications, each occur in less than 1% of patients undergoing catheterization. However, though the imaging portion of the examination is often brief, because of setup and safety issues the patient is often in the lab for 20–45 minutes. Any of multiple technical difficulties, while not endangering the patient (indeed added to protect the patient's interests) can significantly increase the examination time.

Equipment required for the procedure

Coronary catheterization is performed in a cardiac catheterization lab, usually located within a hospital. With current designs, the patient must lie relatively flat on a narrow, minimally padded, radiolucent (transparent to X-ray) table. The X-ray source and imaging camera equipment are on opposite sides of the patient's chest and freely move, under motorized control, around the patient's chest so images can be taken quickly from multiple angles. More advanced equipment, termed a bi-plane cath lab, uses two sets of X-ray source and imaging cameras, each free to move independently which allows two sets of images to be taken with each injection of radiocontrast agent (Figs 4.3 and 4.4).

Standard Angiographic Views

For the beginner angiographer the anatomic landmarks formed by the spine, catheter and diaphragm, provide information to discern which tomographic view from which the image is obtained. In the left anterior oblique (LAO) view the catheter and spine are seen on the right side of the image, while in the right anterior oblique (RAO) they are found on the right. PA imaging places these landmarks in the center of the image. Cranial angulation can usually be distinguished from caudal angulation by the presence of the diaphragm. For cranial imaging, the patient should be asked to inspire to remove the diaphragmatic shadow from the image (Figs 4.5 and 4.6) .

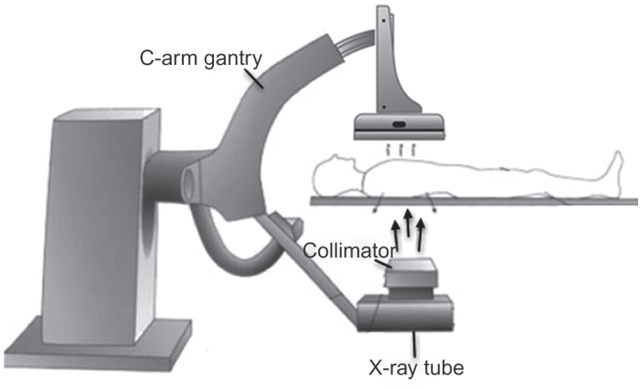

Fig. 4.3: Schematic of radiographic imaging system

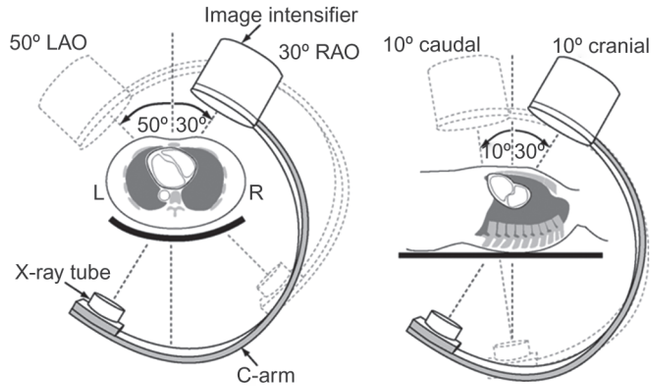

Fig. 4.4: Relationship among the patient, X-ray tube, and image intensifier during coronary angiography. LAO=left anterior oblique; RAO=right anterior oblique. The X-ray beam is generated by an X-ray tube. The beam passes through a collimator where lead apertures form and limit the beam. On intersection with the patient, most of the beam is reflected or absorbed. The remaining photons pass through the image intensifier. Thirty to sixty exposures are needed to give appearance of a live continuous image

INDICATIONS

1. Acute ST-segment elevation myocardial infarction (STEMI) to identify and reperfuse the infarct-related artery
2. Acute STEMI who have received lytic or medical therapy and have-recurrent angina-heart failure-Arrhythmia or for risk stratification purposes
3. Non-ST-segment elevation myocardial infarction (NSTEMI) or unstable angina in whom an invasive management strategy is chosen
4. Evaluation of select stable angina patients with or without a prior, abnormal noninvasive test
5. Evaluation of certain 'high-risk' asymptomatic patients
6. Patients with chest pain syndromes and abnormal or nondiagnostic noninvasive tests
7. Preoperative evaluation for select patients undergoing noncardiac surgery
8. Preoperative evaluation for select patients undergoing cardiac surgery
9. Evaluation of heart failure syndromes to exclude significant coronary disease
10. Other conditions (hypertrophic obstructive cardiomyopathy, aortic dissection, and chest trauma)

CONTRAINDICATIONS

These are listed in Table 4.1.

1. Patients who do not desire or who are not candidates for revascularization
2. Patients in whom revascularization is unlikely to improve quality/duration of life
3. As a screening test for CAD in asymptomatic patients
4. Routine angiography within 24 hours of lytic therapy in the absence of ongoing ischemia
5. Acute renal failure, marked electrolyte imbalance, or metabolic disarray

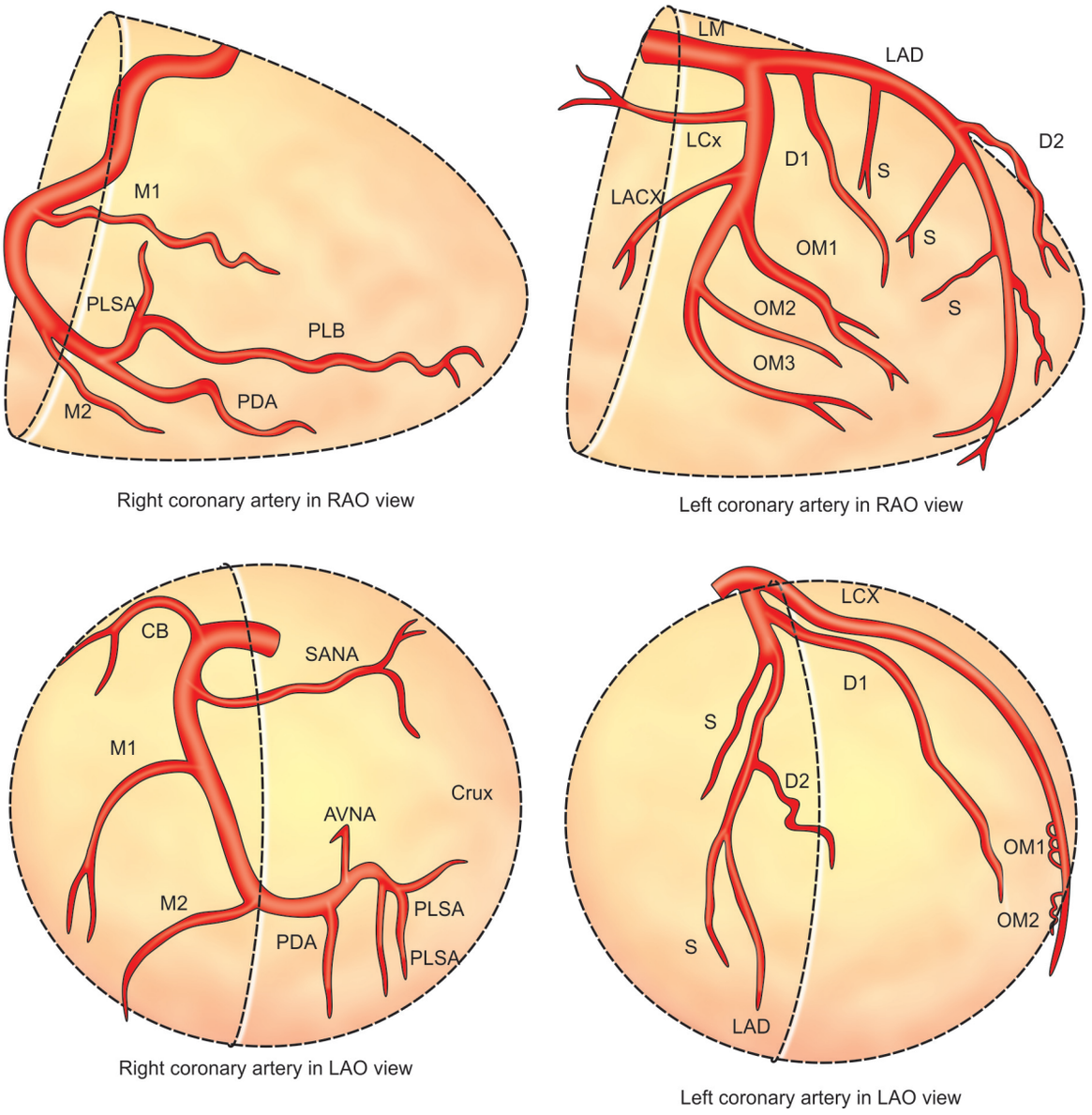

Fig. 4.5: Various branches of left and right major coronary arteries. LM=left main, SN=sinus node branch, D=diagnol, S=septal branches, LAD=left anterior descending, OM=obtuse marginal, RV=right-ventricular branch, AC=atrial circumflex, M=marginal, PDA=posterior descending artery, AVNA=atrioventricular nodal artery, LCX=left circumflex artery, SANA=Sinoatrial nodal artery

6. Active bleeding or severe coagulopathy
7. Prior cholesterol embolization syndrome or anaphylaxis to contrast
8. Active infection or unexplained fever
9. Decompensated respiratory status, heart failure, or uncontrolled hypertension
10. Changing mental status or inability to cooperate

Catheters

Catheter selection for a routine left heart catheterization is generally straight forward. Most often, Judkins catheter types are most routinely used (Figs 4.7 and 4.8). For engagement of the left main coronary artery, a Judkins left size 4 (JL4) catheter will generally engaged the left coronary artery in most patients with relative ease. Increasing catheter size (JL5) for tall patients or patients with dilated aorta or decreasing size (JL3.5) in small patients is sometimes required. Engagement of the LMT is usually most straightforward in the LAO projection. For extremely dilated roots or anomalous arteries other catheters such as Amplatz catheters can be used. For the right coronary artery, a Judkins right size 4 (JR4) is most often used. The right coronary artery is engaged in the LAO projection. Usually slow clockwise rotation of the JR4 in the aortic root will engage the ostium of the RCA. Specialized catheters are available to engage anomalous origins of coronary arteries and saphenous and internal mammary artery bypass grafts. Once the artery is engaged, it is important to examine the pressure waveform. Normally, the waveform should mimic

Table 4.1: Relative contraindications to coronary angiography

- Acute renal failure
- Chronic renal failure secondary to diabetes
- Active gastrointestinal bleeding
- Unexplained fever, which may be due to infection
- Untreated active infection
- Acute stroke
- Severe anemia
- Severe uncontrolled hypertension
- Severe symptomatic electrolyte imbalance
- Severe lack of cooperation by patient due to psychological or severe systemic illness
- Severe concomitant illness that drastically shortens life expectancy or increases risk of therapeutic interventions
- Refusal of patient to consider definitive therapy such as PTCA, CABG, or valve replacement
- Digitalis intoxication
- Documented anaphylactoid reaction to angiographic contrast media
- Severe peripheral vascular disease limiting vascular access
- Decompensated congestive heart failure or acute pulmonary edema
- Severe coagulopathy
- Aortic valve endocarditis

PTCA=percutaneous transluminal coronary angioplasty; CABG=coronary artery bypass graft.

aortic root pressure. Dampening or ventricularization of the pressure waveform may indicate over engagement of the catheter or significant vessel stenosis. Extreme care should be taken before instillation of contrast medium without normal pressure waveforms.

Technique in Coronary Angiography

Vascular Access (Figs 4.9 to 4.12)

Common femoral arterial access is the most common arterial access for performing left heart catheterization. The original catheterization procedure was performed via brachial access. This site is still commonly used in patients with lower extremity peripheral access issues. Arm access also facilitates internal mammary access, especially in patients with tortuous innominant or subclavian arteries. Radial artery access is also used commonly in some practice settings. Before radial access is performed, competence of the radial artery arch should be assessed with the Allen test. Use of pulse oximetry can facilitate interpretation of the test. Anatomic landmarks are used to identify the correct site of arterial puncture.

For the femoral artery access, the femoral head provides the best visible landmark. Arterial puncture at this site remains below the inguinal ligament, is generally above the bifurcation of the superfical femoral and deep femoral arteries, and allows for hemostasis. It is recommended that this site should be observed under floroscopy in any patient prior to access. In obese patients the inguinal skin crease is generally too low. After the administration of subcutaneous anesthetic, an 18G Cook® needle is used to puncture the

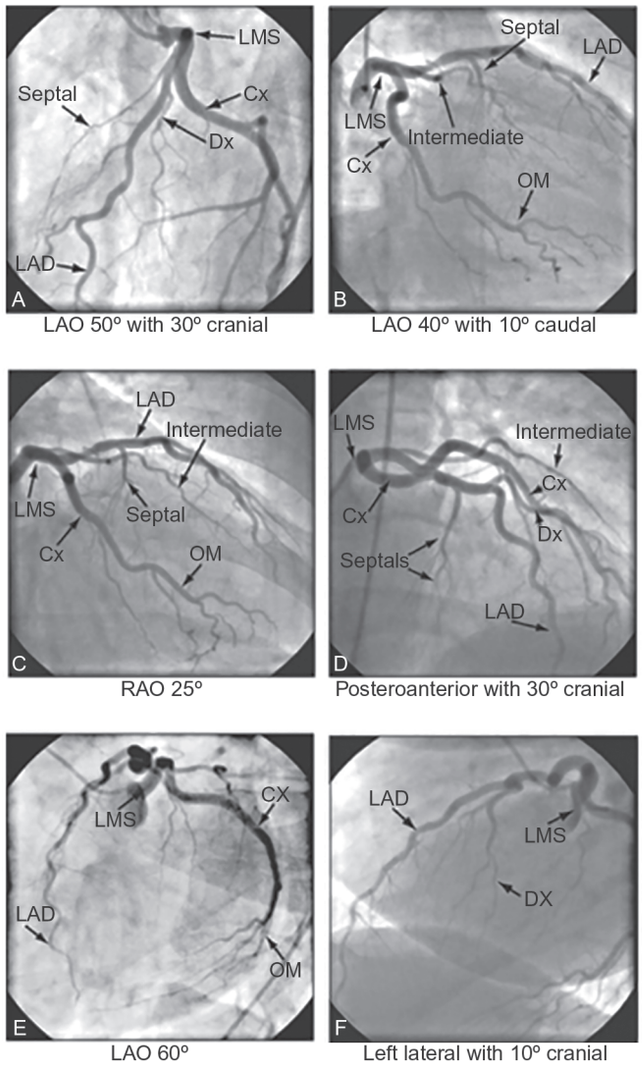

Fig. 4.6: (A–F) Angiography of the left coronary arterial system. Cx=circumflex coronary artery, Dx=diagonal coronary artery, LAD=left anterior descending coronary artery, LAO=left anterior oblique projection, LMS=left main stem coronary artery, OM=obtuse marginal coronary artery; RAO=right anterior oblique projection

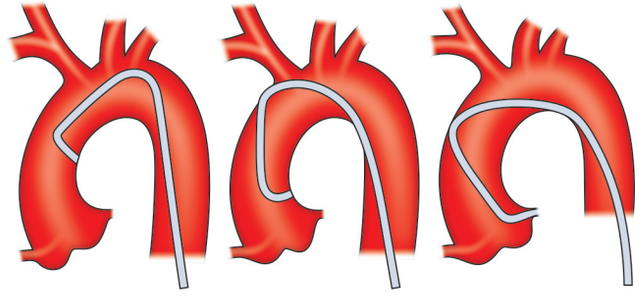

Fig. 4.7: Selective catheterization of the left coronary artery by the Judkins technique. In LAO position,the catheter is rotated so that it appears unfolded and enface; it is then slowly advanced until it engages the left coronary orifice. A size 4 (4 cm curve) catheter is adequate for most patients, but with moderate or severe aortic dilatation, a size 5 or 6 catheter may be required

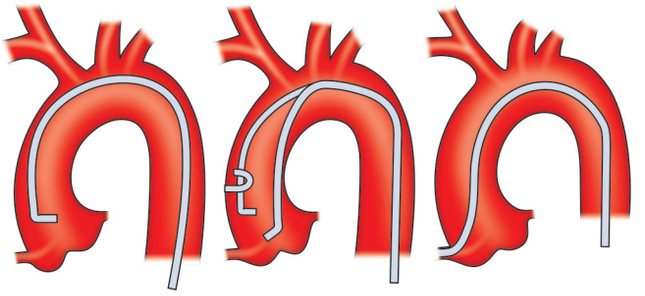

Fig. 4.8: Diagrammatic representation of selective catheterization of the right coronary artery by the Judkins technique (LAO projection)

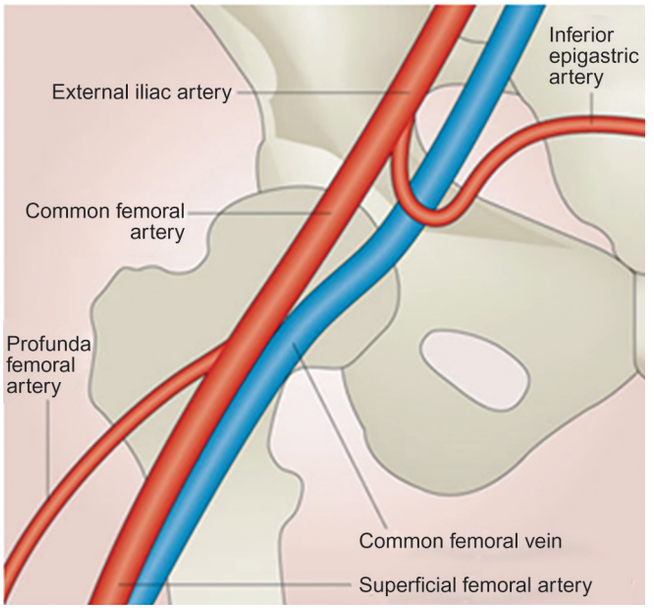

Fig. 4.9: Anatomy of the common femoral artery. The common femoral artery is the terminal branch of the external iliac artery, and provides the main arterial supply to the lower limb. The common femoral artery enters the femoral triangle deep to the midpoint of the inguinal ligament, posterior to the deep fascia, and overlying the head of the femur bone. These features facilitate arterial puncture, but necessitate deep pressure for compression hemostasis. At this point, the artery has adiameter of 7–10 mm and lies within the femoral sheath close to the common femoral vein and the femoral nerve and its branches. Just proximal to the inguinal ligament, the external iliac artery gives off the clinically important inferior epigastric artery, which courses superomedially and anastomoses with distal end of the internal mammary artery. Inferior to the neck of the femur, the common femoral artery divides into the profunda femoris and superficial artery end branches

front wall of the artery. This technique is known as the modified Seldinger technique and prevents posterior arterial bleeding or venous communication from the puncture. Complications from arterial access include arterial dissection, AV fistula formation, retroperitoneal hemmorrhage, and pseudoaneurysm formation. Once access is obtained, the Cook needle is steadied while the artery is accessed with a wire through the lumen of the Cook

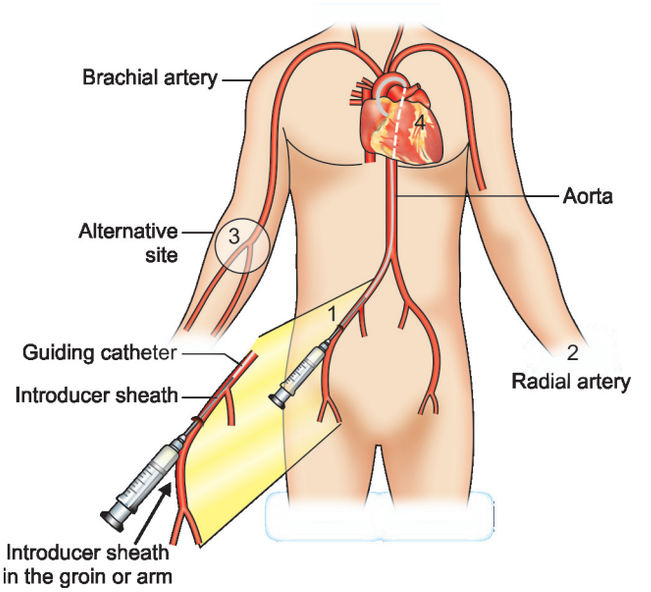

Fig. 4.10: Different catheter routes of cardiac catheterization including coronary angiography. Catheter in—(1) groin, (2) radial artery, (3) brachial artery, and (4) heart

needle. The Cook needle is then removed and a sheath is inserted into the artery. Under floroscopy, catheters are then introduced using an 0.35 J-tipped guide wire into the aortic root. The catheters are then attached to a 3-way manifold. Manifold used allows for continuous pressure monitoring, saline flush instillation, and contrast administration through the catheter tip (Figs 4.9–4.12).

LEFT CORONARY SYSTEM

LEFT CORONARY ARTERY

The left main coronary artery gives rise to the left anterior descending artery and the left circumflex coronary artery. Complete visualization of these arteries and their branches requires care and rigor to ensure complete anatomical documentation. Often bifurcations and vessel foreshortening and overlap cause errors in stenosis estimation. There are no steadfast rules in which tomographic views are most useful. Generally, for circumflex and proximal epicardial visualization the caudal views are most useful. For LAD and LAD/diagonal bifurcation visualization the cranial views are most useful. Overall, if there is not a significant limitation on contrast utilization, standard 'around the world' angiography using a selection of the following angiographic views will document left coronary anatomy (Figs 4.13–4.20).

- Left main stem
  - Best seen in posteroanterior (PA) view or very shallow oblique projection (either RAO or LAO)
- Left anterior descending coronary artery
  - RAO or PA view
  - Steep LAO view (40°) with severe cranial angulation (40°) for LAD and diagonal bifurcation

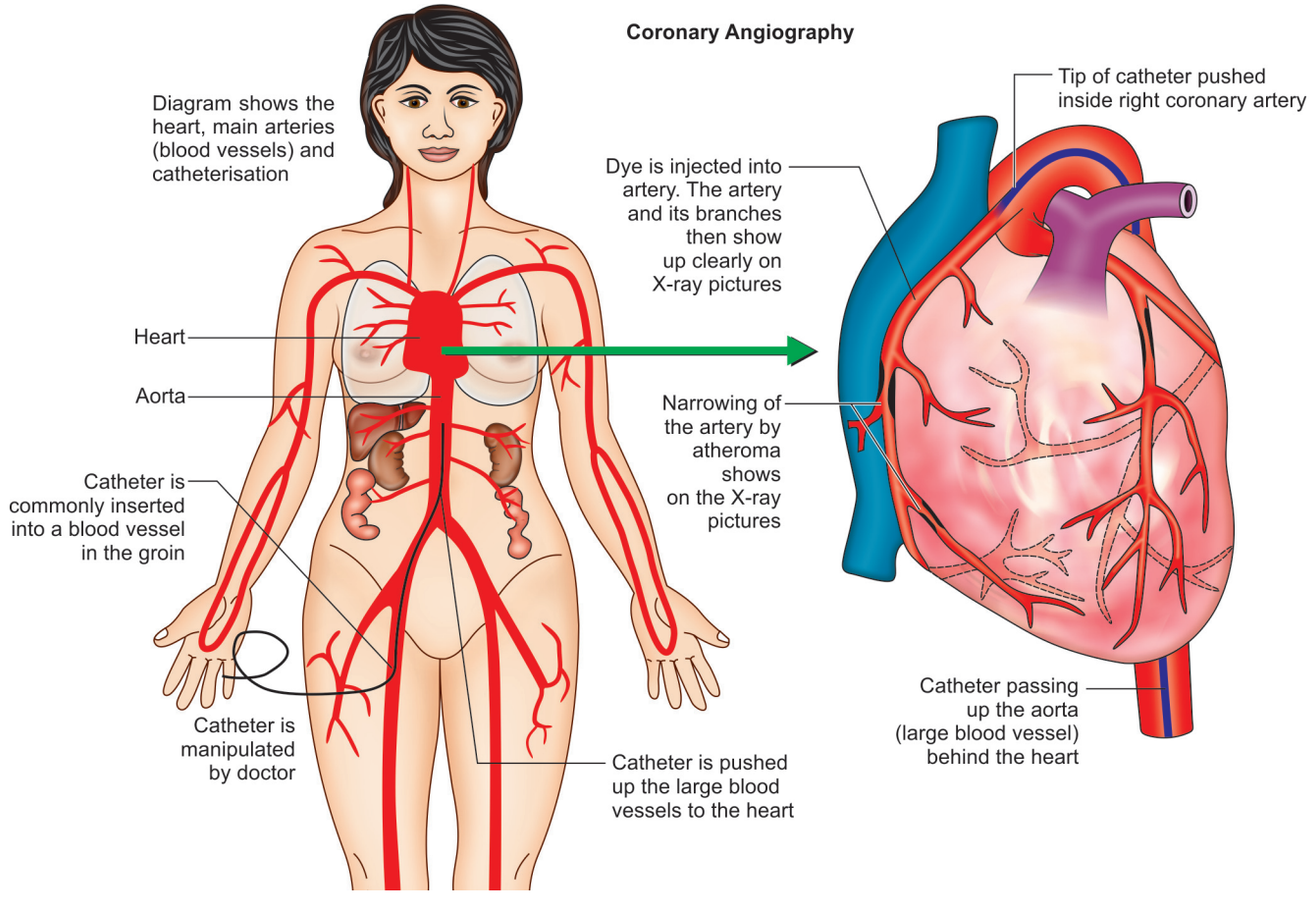

Fig. 4.11: Diagrammatic representation of procedure in coronary angiogram

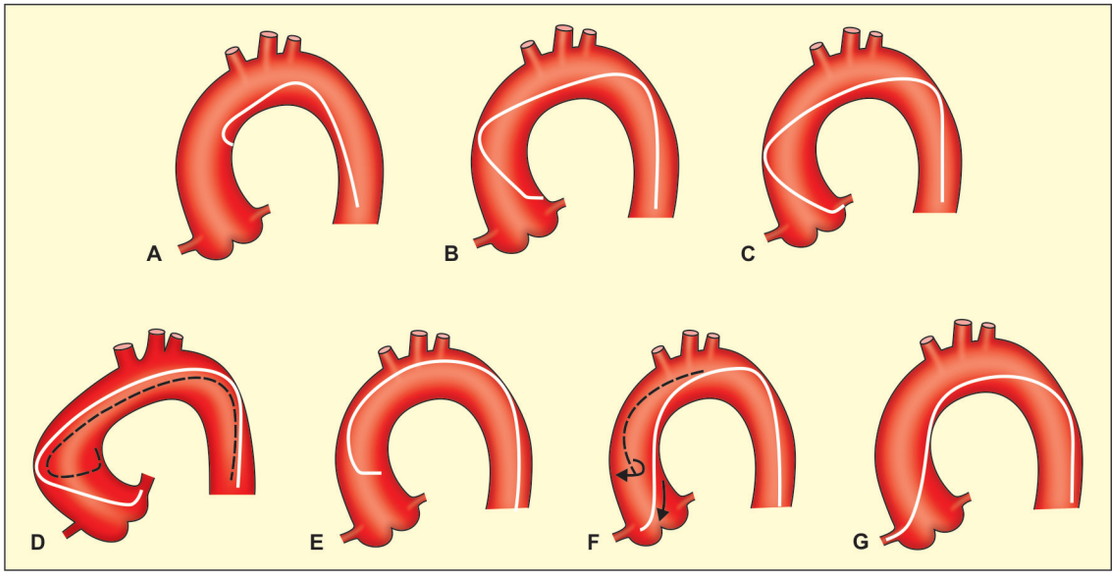

Fig. 4.12: (A–G) Left and right Judkins catheters engagement at the mouth of left and right coronary arteries in obtaining coronary angiogram

- LAO 40°, caudal 40° (spider view) for bifurcation of LMS, proximal circumflex and LAD and at times distal LAD

- Circumflex coronary artery
  - RAO 20° or 30° angulation with 20°–30° caudal angulation

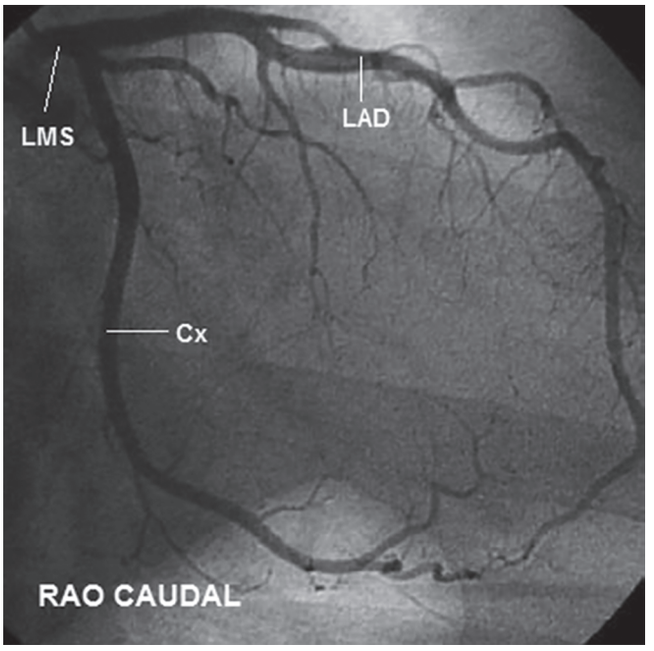

Fig. 4.13: RAO caudal-LCA

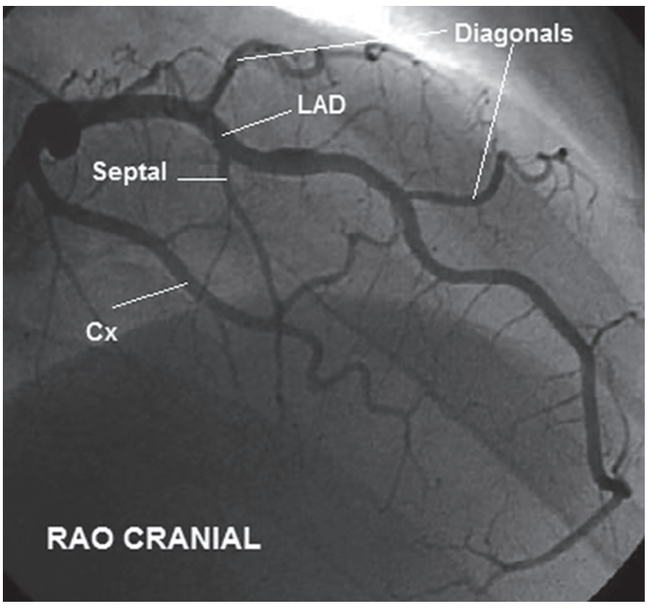

Fig. 4.14: RAO cranial-LCA

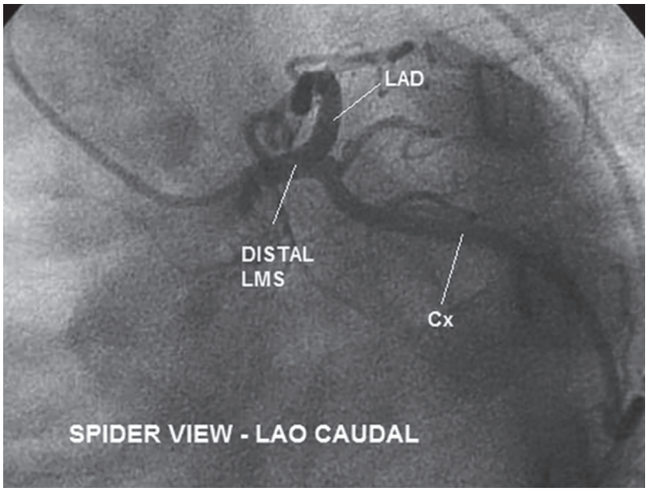

Fig. 4.15: Spider view-LAO caudal

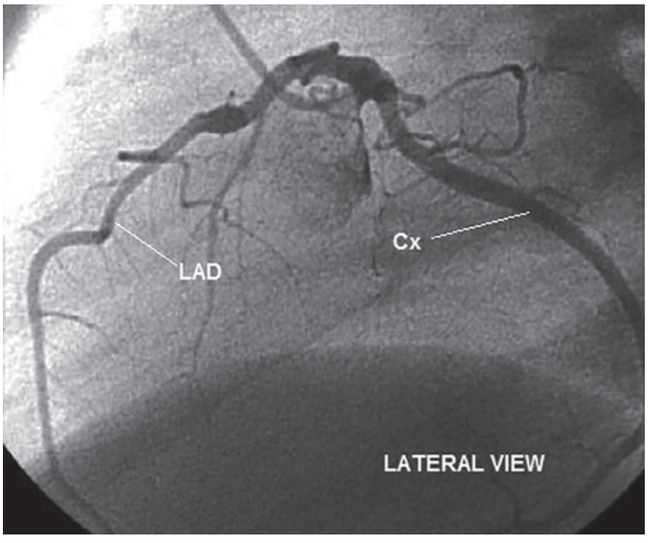

Fig. 4.16: Lateral view-LCA

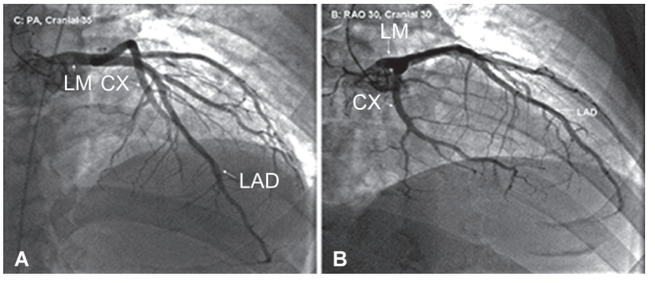

Fig. 4.17: (A) Normal left coronary artery viewed in the PA projection with 35° cranial angulation, (B) Left coronary angiogram viewed with 30° RAO and 30° cranial angulation delineating the course of the LAD

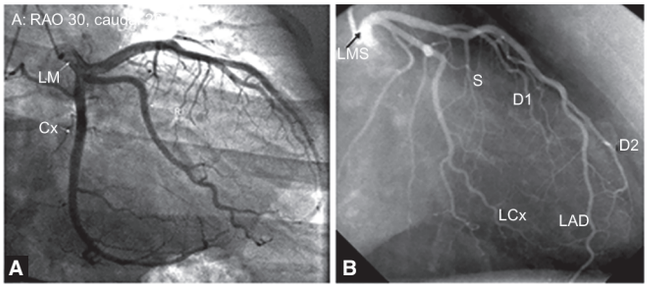

Fig. 4.18: (A) Selective left coronary angiogram viewed with 30° RAO and 20° caudal angulation viewing the circumflex artery, (B) LCA-RAO (30°) straight LCA-RAO (30°) straight

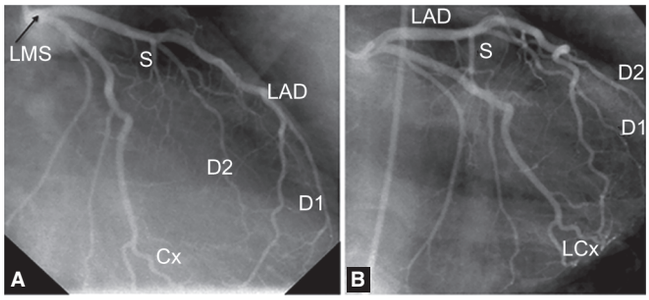

Fig. 4.19: (A) LCA-RAO (30°) caudal (30°),(B) LCA-AP caudal (30°)

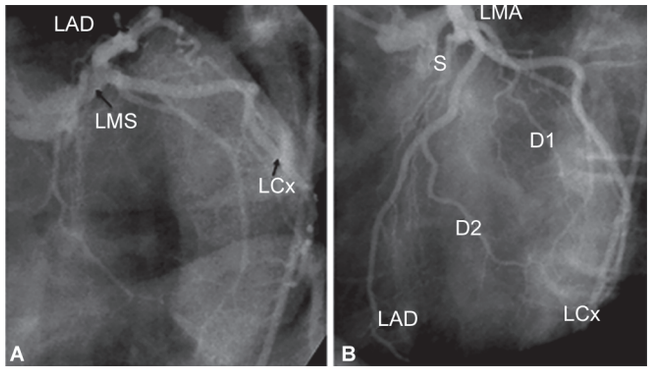

Fig. 4.20: (A) LCA-LAO (50°) caudal (30°), (B) LCA-LAO (60°) straight

RIGHT CORONARY SYSTEM

RIGHT CORONARY ARTERY

The right coronary artery is engaged in the LAO position (Figs 4.21–4.23). Initial angiographic imaging of the RCA in this view (LAO 30) gives the best view of significant ostial and proximal RCA disease. The mid-RCA is best visualized in the straight RAO 30 position.

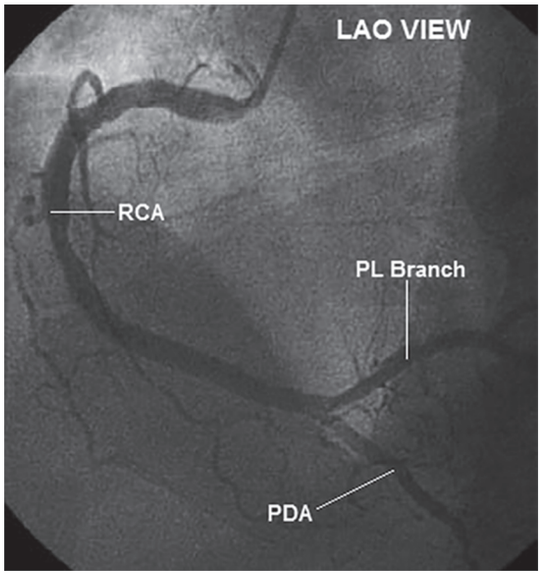

Fig. 4.21: LAO view—RCA

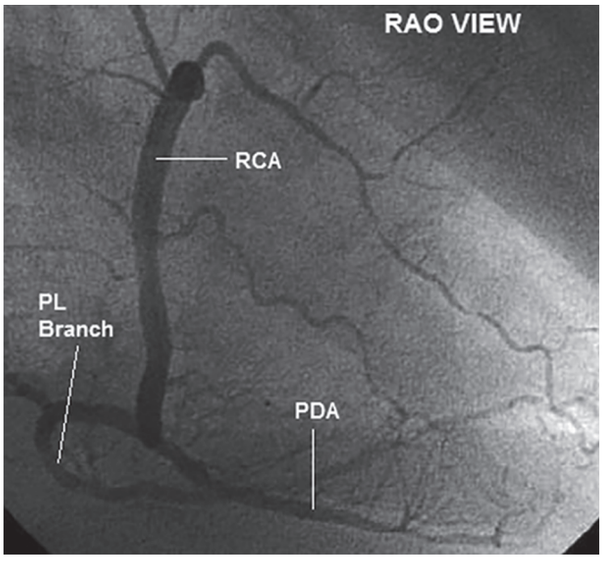

Fig. 4.22: RAO view—RC

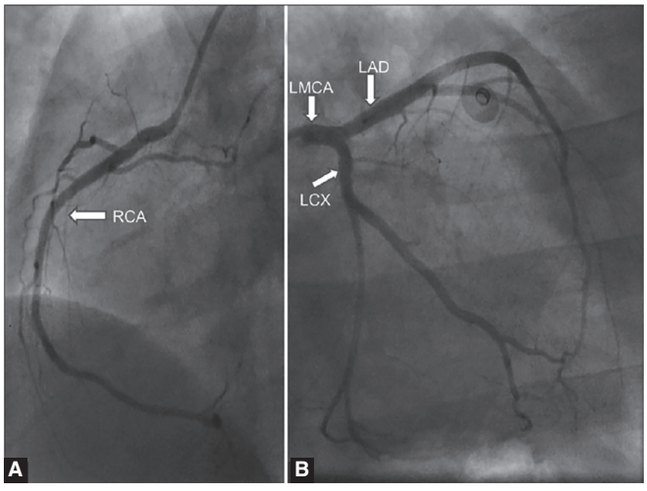

Fig. 4.23: Coronary angiogram showing normal filling of (A) right and (B) left coronary arteries. RCA=right coronary artery, LMCA=left main coronary artery, LAD=left anterior descending artery, LCX=left circumflex artery

COMPLICATIONS IN CORONARY ANGIOGRAPHY

Coronary arteriography is generally a safe procedure (Figs 4.24–4.30). The overall incidence of complications and mortality increases directly with:

1. Extent of coronary artery disease, particularly left main coronary stenosis
2. Presence of coexistent significant valvular disease
3. Reduced ventricular ejection fraction
4. Reduced functional state
5. Advancing age

This include:

- Arrhythmia
- Coronary artery dissection or embolization

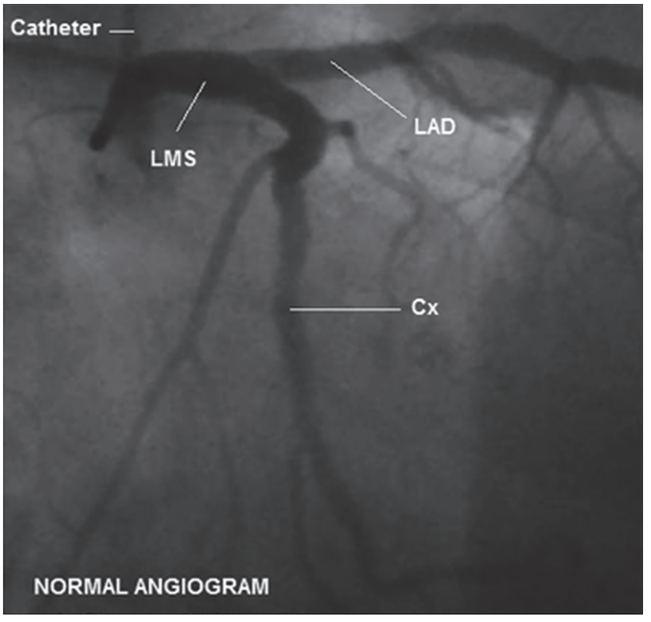

Fig. 4.24: Normal angiogram

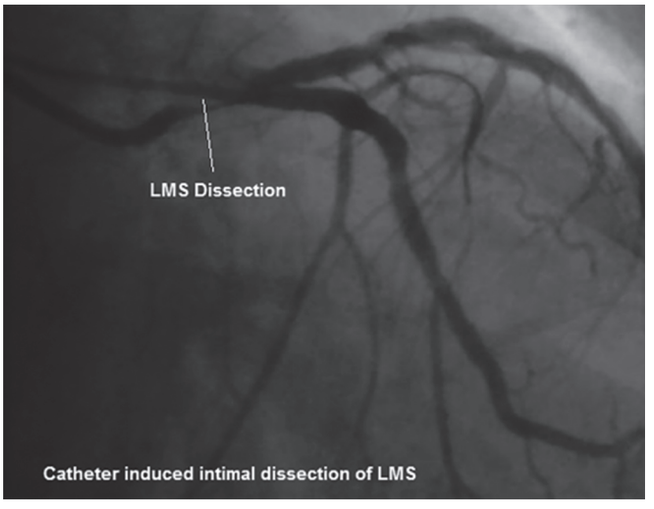

Fig. 4.25: Catheter-induced intimal dissection of left main artery



Fig. 4.26: RC arteriogram in frontal projection showing a fine line of radiolucency within the artery, suggesting a coronary arterial dissecting aneurysm

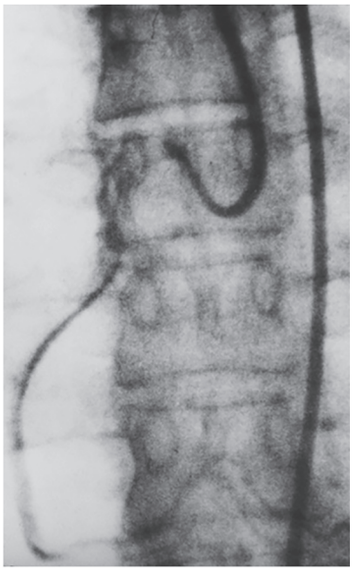

Fig. 4.27: RC arteriogram demonstrating slower flow in the false channel (dissection) than in the principal one

- Myocardial infarction
- Heart failure
- Death
- Stroke
- Contrast toxicity/reaction:
  - i. Hypotension and myocardial depression
  - ii. ST/T wave changes
  - iii. Allergic reaction (urticaria, bronchospasm, angioedema, laryngospasm, and anaphylaxis)
- Renal failure
- Vascular complications:
  - i. Hematoma, AV fistula, and pseudoaneurysm
  - ii. Local femoral or brachial artery injury from arterial cannulation and compression for hemostasis
- Neurologic:
  - i. Ulnar nerve compression from prolonged procedures
  - ii. Transient ischemic attacks and strokes: mostly embolic from the aorta

ACC and AHA Update Guidelines for Coronary Angiography

The American College of Cardiology (ACC) and the American Heart Association (AHA) have updated their guidelines for coronary angiography (Figs 4.31–4.36). The executive summary and recommendations are published

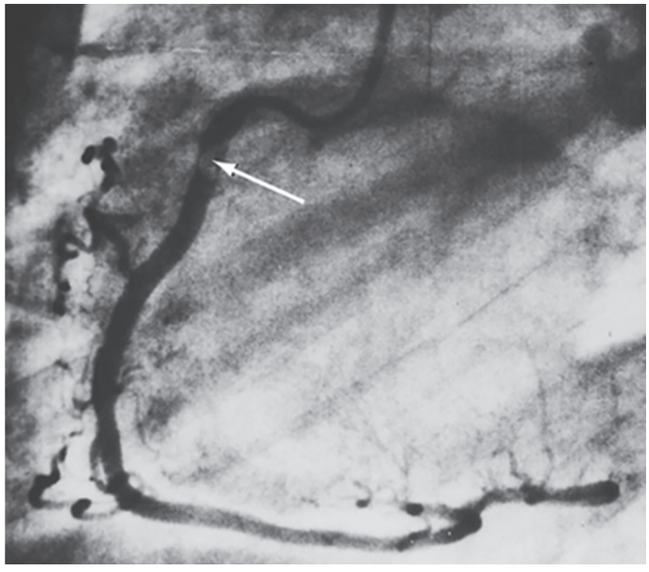

Fig. 4.28: LAO view of RC arteriogram. Evidence of embolic material probably from a catheter thrombus, or less likely, from an atherosclerotic plaque; large RCA

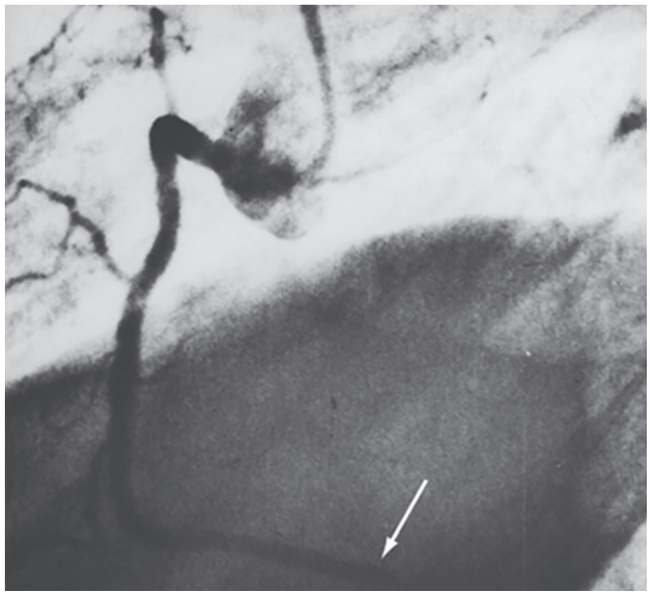

Fig. 4.29: LAO view of RC arteriogram. Repeat injection now shows occlusion (arrow) of the PDA filling defect (arrow) can be seen clearly and was observed to migrate toward the periphery

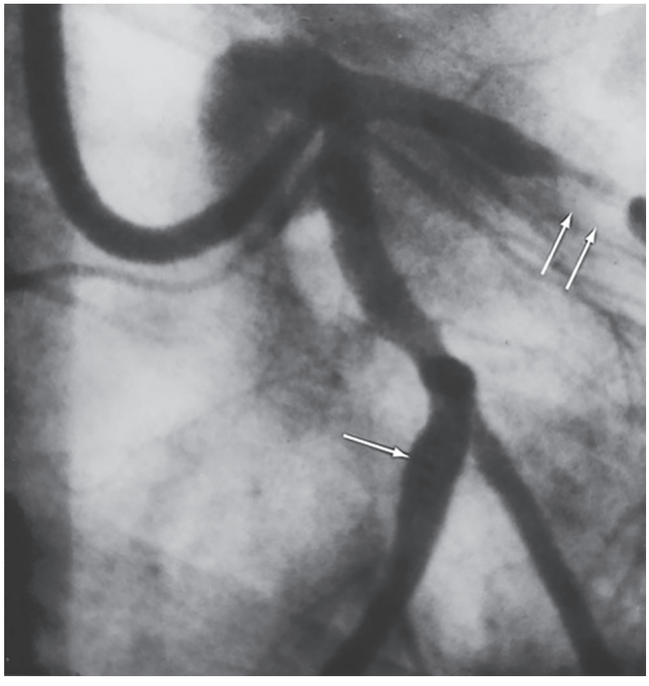

Fig. 4.30: Air embolism magnification coronary arteriography of a patient with localized stenosis of the LAD (double arrow). A small air bubble can be seen migrating through the Cx (arrow)

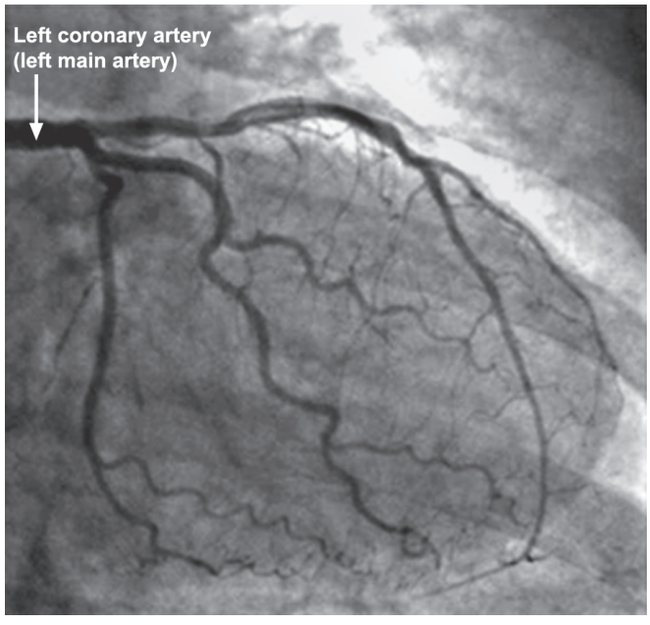

Fig. 4.31: Left coronary angiography showing left main coronary artery

in the May 4th, 1999, issue of Circulation. The entire guidelines are published in the May 1999 issue of the Journal of the American College of Cardiology. The ACC/AHA coronary angiography guidelines represent an update of the 1987 guidelines. In addition to reviewing the previous guidelines, the 12-member ACC/AHA Committee on coronary angiography also conducted a search of the pertinent literature for the previous 10 years. The weight of evidence in support of each recommendation was then ranked into three categories—(A) the presence of multiple randomized clinical trials; (B) the presence of a single randomized trial or nonrandomized studies; and (C) expert consensus.

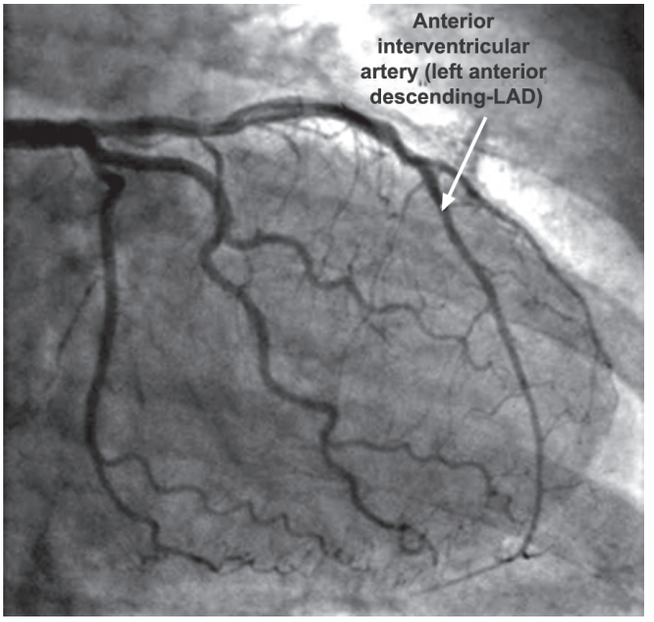

Fig. 4.32: Left coronary angiography showing left anterior descending artery

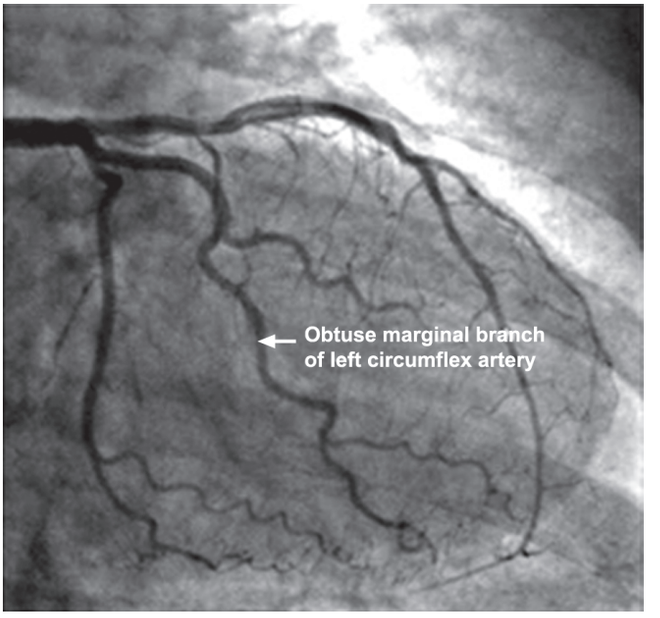

Fig. 4.34: Left coronary angiography showing obtuse marginal branch of left coronary artyery

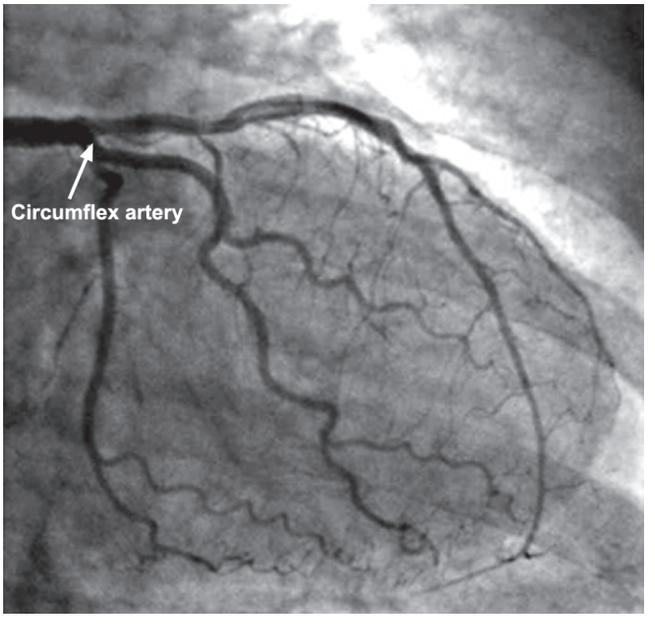

Fig. 4.33: Left coronary angiography showing circumflex artery

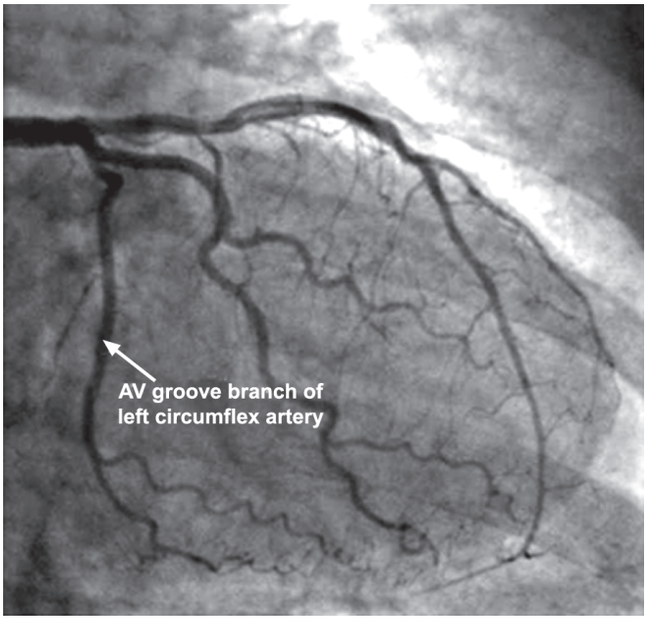

Fig. 4.35: Left coronary angiography showing AV groove branch of left coronary artyery

The Recommendations are also Classified on the Basis of Conditions for which Coronary Angiography has Demonstrated Usefulness/Efficacy.

The definitions of these categories are as follows:

- **Class I:** Conditions for which there is evidence and/or general agreement that this procedure is useful and effective
- **Class II:** Conditions for which there is conflicting evidence and/or a divergence of opinion about the usefulness/efficacy of the procedure
- **Class IIa:** The weight of evidence/opinion is in favor of usefulness/efficacy
- **Class IIb:** Usefulness/efficacy is less well established by evidence/opinion

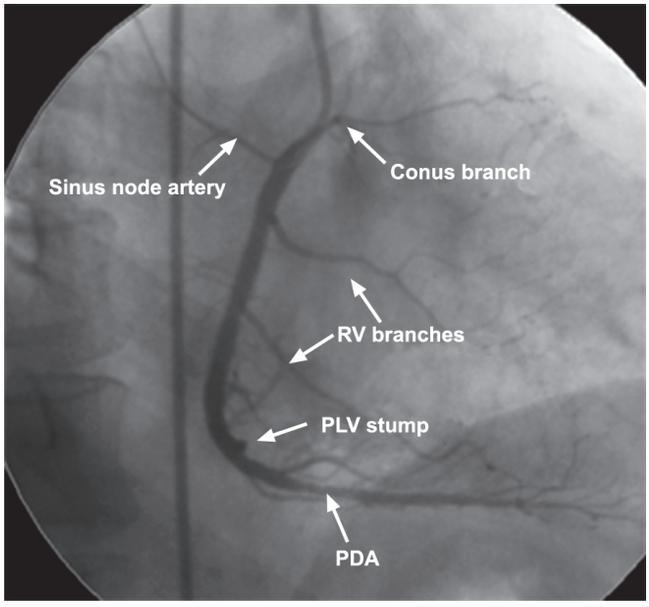

Fig. 4.36: Angiogram showing branches of the right coronary artery as indicated on the skiagram

- **Class III:** Conditions for which there is evidence and/or general agreement that the procedure is not useful/effective and in some cases may be harmful.

Recommendations for Coronary Angiography When Coronary Artery Disease is Suspected

The algorithm on the following page gives a scheme for the noninvasive evaluation of a patient with suspected coronary artery disease. The following is an excerpt of the recommendations for coronary angiography in the evaluation of patients with known or suspected coronary artery disease who are asymptomatic or have stable angina.

Class I

1. Canadian Cardiovascular Society (CCS) class III and class IV angina on medical treatment (level of evidence: B)
2. High-risk criteria on noninvasive testing regardless of angina severity (level of evidence: A)
3. Patients who have been successfully resuscitated from sudden cardiac death or have sustained (more than 30 seconds) monomorphic ventricular tachycardia or nonsustained (less than 30 seconds) polymorphic ventricular tachycardia (level of evidence: B).

Class IIa

1. CCS class III or IV angina, which improves to class I or II with medical therapy (level of evidence: C)
2. Serial noninvasive testing with identical testing protocols, at the same level of medical therapy, showing progressively worsening abnormalities (level of evidence: C).
3. Patients with angina and suspected coronary disease who because of disability, illness or physical challenge, cannot be adequately risk-stratified by other means (level of evidence: C)
4. CCS class I or II angina with intolerance to adequate medical therapy or with failure to respond, or patients who have recurrence of symptoms during adequate medical therapy (level of evidence: C)
5. Individuals whose occupation involves the safety of others (e.g. pilots, bus drivers) who have abnormal but not high-risk stress test results or multiple clinical features that suggest high risk (level of evidence: C).

Class IIb

1. CCS class I or II angina with demonstrable ischemia but no high-risk criteria on noninvasive testing (level of evidence: C)
2. An asymptomatic man or postmenopausal woman without known coronary heart disease with two or more major clinical risk factors and abnormal, but not high-risk criteria on noninvasive testing (performed for indications stated in the ACC/AHA noninvasive testing guidelines) (level of evidence: C)
3. Asymptomatic patients with prior myocardial infarction with normal resting left ventricular function and ischemia on noninvasive testing but without high-risk criteria (level of evidence: C)
4. Periodic evaluation after cardiac transplantation (level of evidence: C)
5. Candidate for liver, lung or renal transplant 40 years of age or older as part of the evaluation for transplantation (level of evidence: C).

Class III

1. Angina in patients who prefer to avoid revascularization even though it might be appropriate (level of evidence: C)
2. Angina in patients who are not candidates for coronary revascularization or in whom revascularization is not likely to improve the quality or duration of life (level of evidence: C)
3. As a screening test for coronary artery disease in asymptomatic patients (level of evidence: C)
4. After coronary artery bypass grafting or angioplasty when there is no evidence of ischemia on noninvasive testing, unless there is informed consent for research purposes (level of evidence: C)
5. Coronary calcification on fluoroscopy, electron-beam computed tomography or other screening tests without criteria listed above (level of evidence: C).

Coronary Angiography for Specific Conditions

*Known or suspected CAD**

Coronary atherosclerosis is a slowly progressive process that can be clinically inapparent for long periods of time. Coronary disease often becomes clinically evident because of the occurrence of symptoms, such as angina or those associated with MI. Patients with known coronary artery

disease (CAD) are those in whom the disease has been documented by either angiography or MI (i.e. using WHO criteria). 'Suspected coronary disease' means that a patient's symptoms or other clinical characteristics suggest a high likelihood for significant CAD and its related adverse outcomes but that evidence of CAD has not yet been documented as defined above (Figs 4.37–4.53).

Patients may develop symptoms at one point in time but may become asymptomatic thereafter as the result of a change in the disease or as the result of therapy. For instance, many patients are asymptomatic after an uncomplicated MI, as patients with mild angina, can be rendered asymptomatic by medications. The severity of clinical presentations and the degree of provokable ischemia on noninvasive testing are the principal factors used in determining the appropriateness of coronary angiography. Although the extent of coronary disease defined by coronary angiography does predict outcome, use of coronary angiography as a 'screening tool' in unselected populations is neither prudent nor cost-effective. The same can be stated regarding the routine use of exercise testing, radionuclide imaging and stress echocardiography in unselected patients. With only a few exceptions, coronary angiography is not clearly indicated in asymptomatic

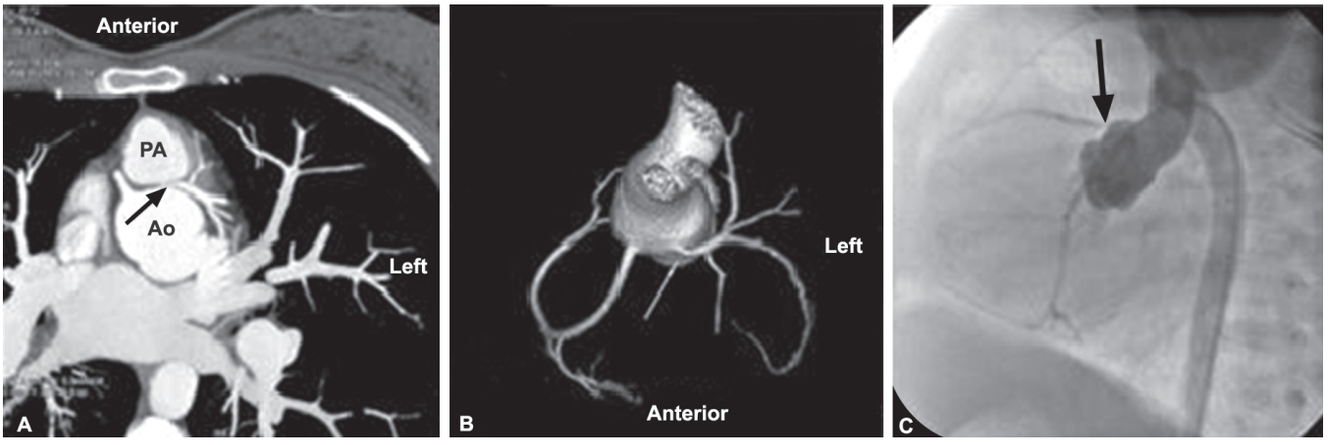

Fig. 4.37: Ostial stenosis of the left main coronary artery. Axial cross-section (A) and 3-dimensional reconstructed image in anterosuperior orientation, (B) showing a tight stenosis (arrow) at the ostium of the left coronary artery. Please note that the left ostium is reimplanted at an anterior 12 o'clock position so that it is localized between the great arteries. (C) corresponding invasive aortography showing the tight stenosis of the left coronary artery ostium

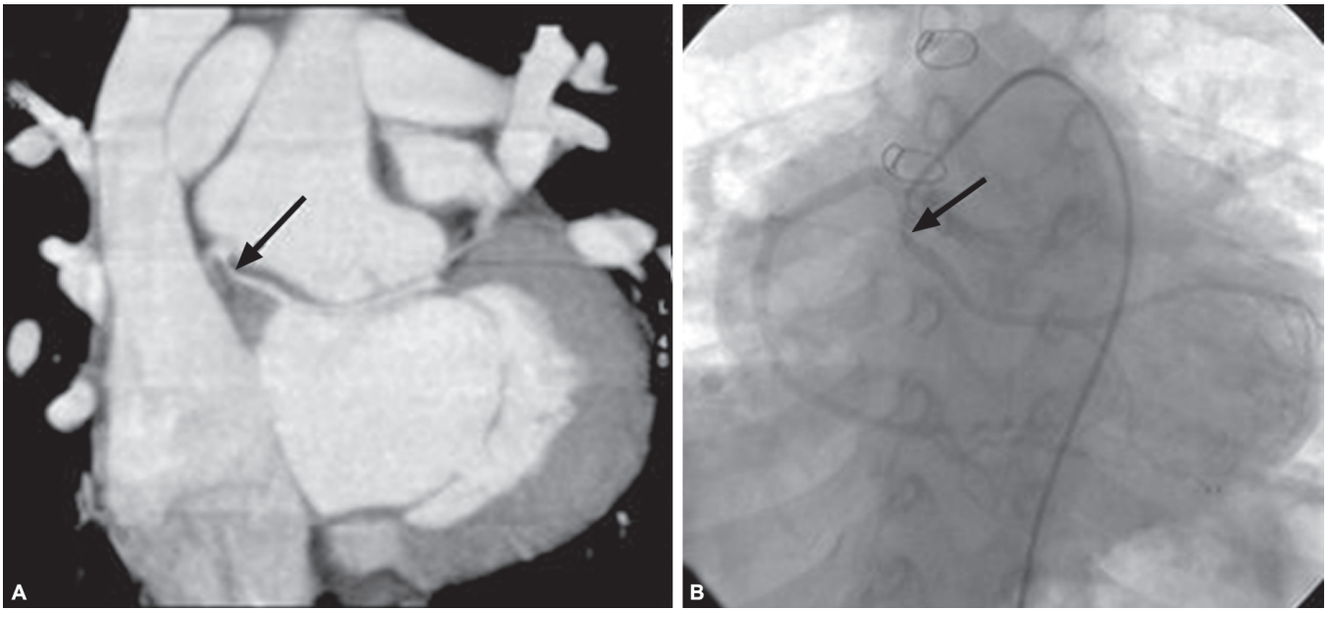

Fig. 4.38: Stretching of the circumflex artery. Oblique multiplanar reconstruction (A) showing the origin of the right coronary artery in a child presenting with a Yacoub type D coronary distribution. The left circumflex artery arises from the right neosinus and follows a long retroaortic course with substantial stretching of its proximal segment (arrow). A neosinus had been surgically created to treat a stenosis of the right ostium, (B) Corresponding invasive angiogram: selective catheterization of the right neosinus, showing the right coronary artery and the stenosis (arrow) of the proximal segment of the retroaortic circumflex artery

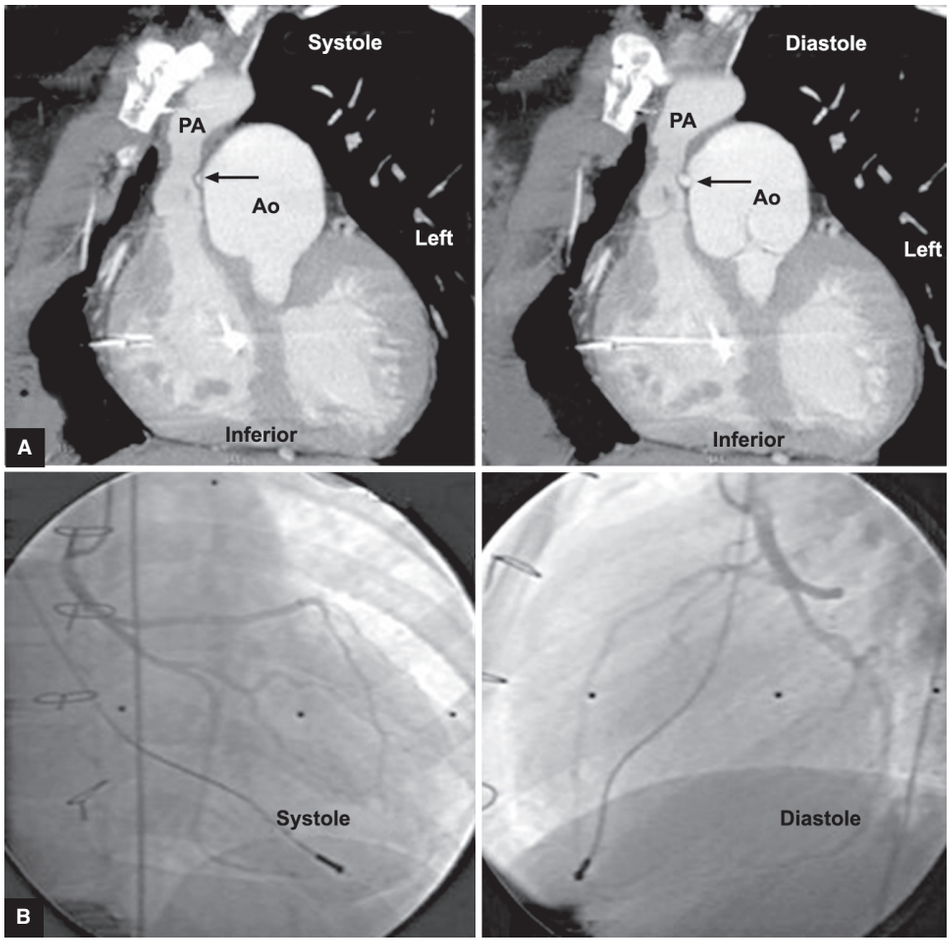

Fig. 4.39: Systolic compression of the left coronary artery (A) sagittal oblique cross-section on CT. Note the banana-shape of the left coronary artery (arrow) caused by systolic compression between the anterior pulmonary artery and the posterior aorta (left panel). During diastole, caliber and shape of the coronary artery are normal (right panel), (B) corresponding invasive angiogram: the systolic compression of the proximal segment of the left coronary artery appears nonsignificant

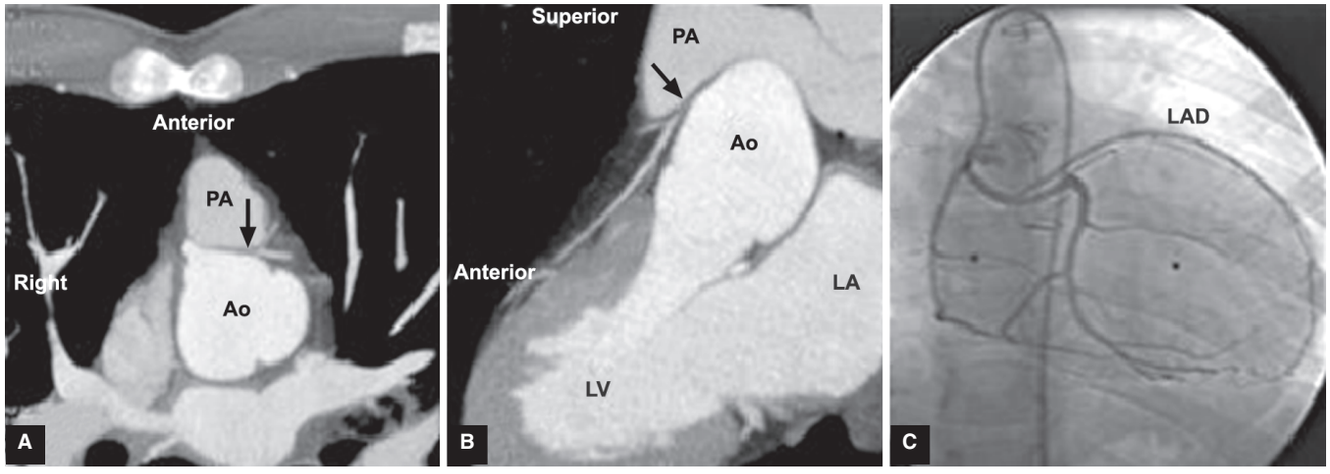

Fig. 4.40: Left main coronary artery with a course between aorta and pulmonary artery axial (A) and sagittal oblique (B) cross-section through the origin of the left coronary artery. The left coronary artery displays a tight stenosis (arrow) and follows a course between the aorta and pulmonary artery. (C) Corresponding invasive angiogram: selective catheterization of the left coronary ostium was not achieved. Selective right coronary angiography shows a dominant right coronary artery giving rise to a circumflex artery retrogradely filling the left anterior descending artery. Ao=aorta; LA=left atrium; LAD=left anterior descending coronary artery; LV=left ventricle, PA=pulmonary artery

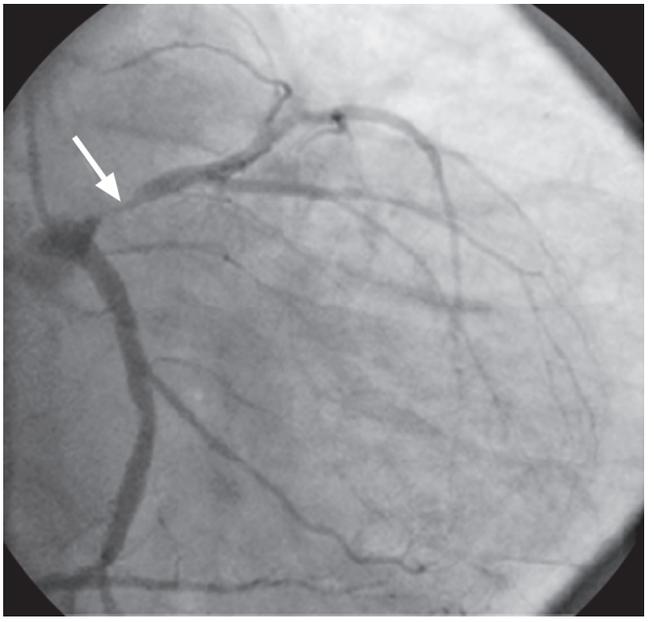

Fig. 4.41: Caudal view in selective coronary angiogram showing subtotal paraosteal occlusion of LAD

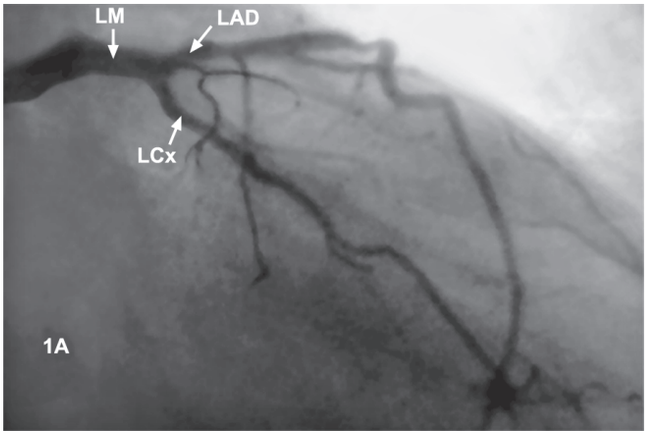

Fig. 4.42: 1A showing the origin of left circumflex artery from left main coronary artery LCx=left circumflex artery, LAD=left anterior descending artery, LM=left main

patients with either known or suspected CAD, unless noninvasive testing (performed as recommended in the ACC/AHA noninvasive guidelines), reveals findings that suggest a high risk for adverse outcome. Coronary angiography is also frequently done during evaluation for other cardiac conditions, such as valvular heart disease, congestive heart failure, or assessment of congenital heart disease. In this setting, angiography may be performed in asymptomatic patients. The details of indications for coronary angiography in specific conditions are described ahead.

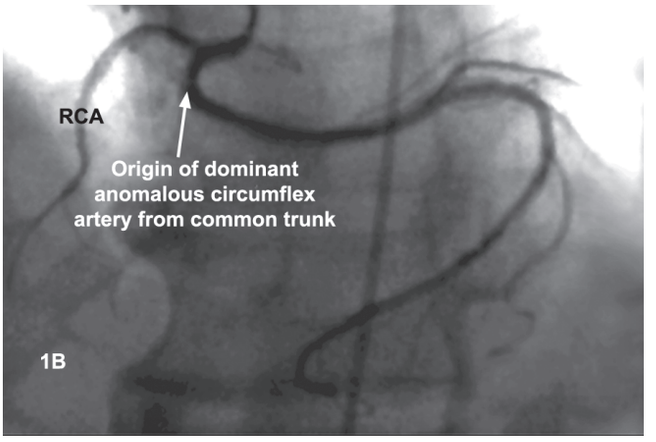

Fig. 4.43: 1B showing the origin of dominant anomalous circumflex artery from a common trunk originating from the right coronary cusp. RCA=right coronary artery

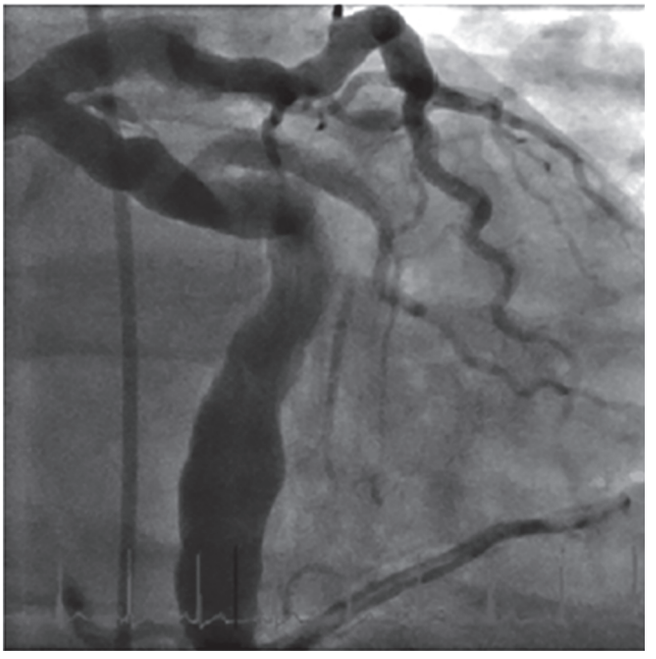

Fig. 4.44: Heart catheterization image showing severe diffuse coronary artery ectasia with left circumflex dominant circulation in a patient with adult Kawasaki's disease

Recommendations for Use of Coronary Angiography in Patients with Congestive Heart Failure

Class I

1. Congestive heart failure due to systolic dysfunction with angina or with regional wall motion abnormalities and/or scintigraphic evidence of reversible myocardial ischemia when revascularization is being considered (level of evidence: B).

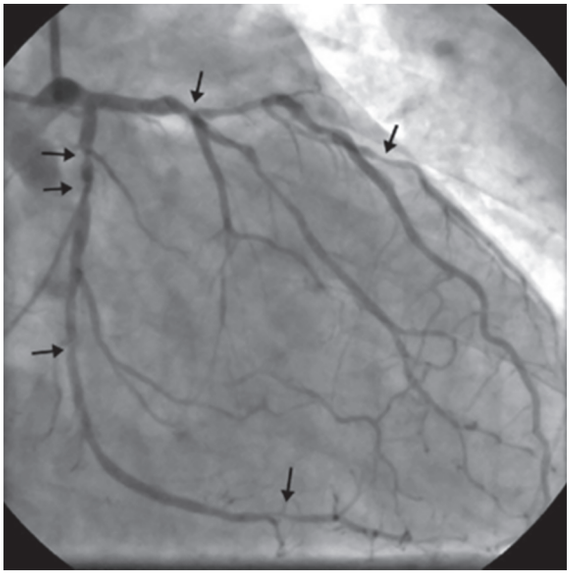

Fig. 4.45: Extensive coronary artery disease. Multiple stenoses are present; they involve the left anterior descending coronary artery and the circumflex coronary artery and their branches. Some of the more severe lesions are identified by arrows. Projection: RAO 2

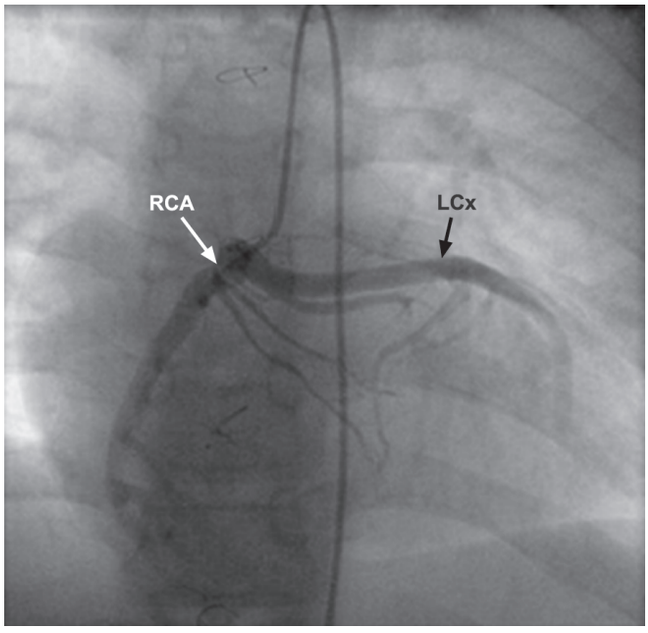

Fig. 4.47: Selective right coronary angiography, early phase, the left circumflex artery (LCx) originating from the right coronary artery (RC)

2. Before cardiac transplantation (level of evidence: C)
3. Congestive heart failure secondary to postinfarction ventricular aneurysm or other mechanical complications of MI (level of evidence: C).

Class IIa

1. Systolic dysfunction with unexplained cause despite noninvasive testing (level of evidence: C).

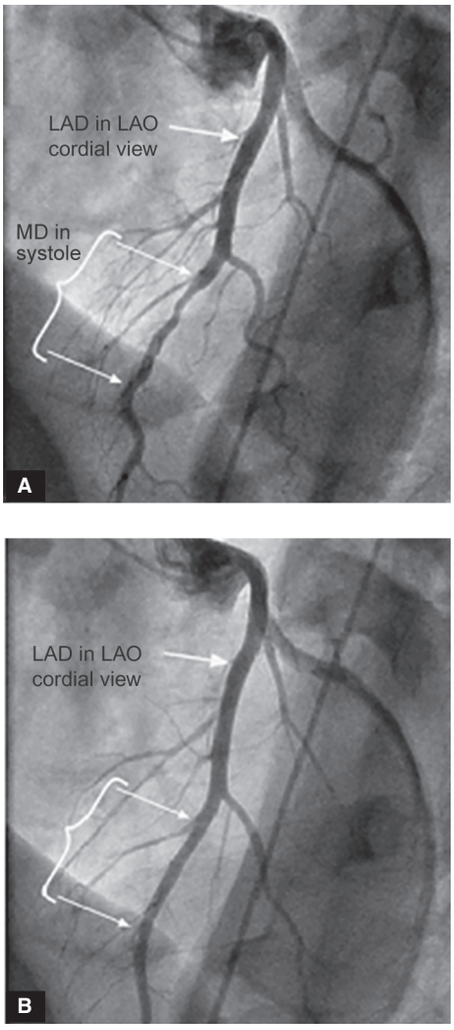

Fig. 4.46: (A) Selective angiography showing coronary constriction (terminal part of LAD) during systole and normal lumen during diastole, (B) in a patient who presented with angina pectoris, HT and nonspecific ECG alterations in anterolateral leads and finally found to have muscular banding of LAD

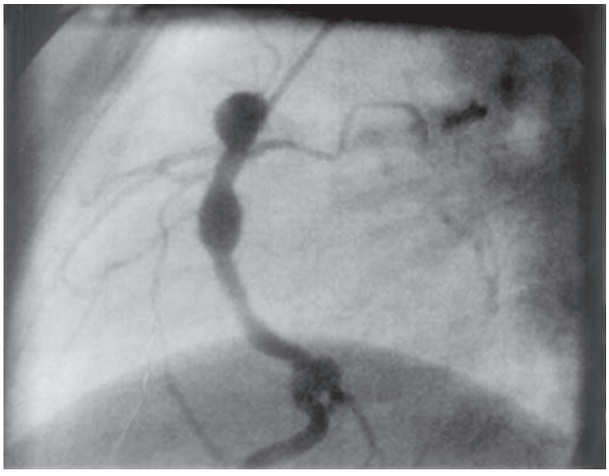

Fig. 4.48: Aneurysm and stenosis affecting right coronary artery and obliterated left anterior descending

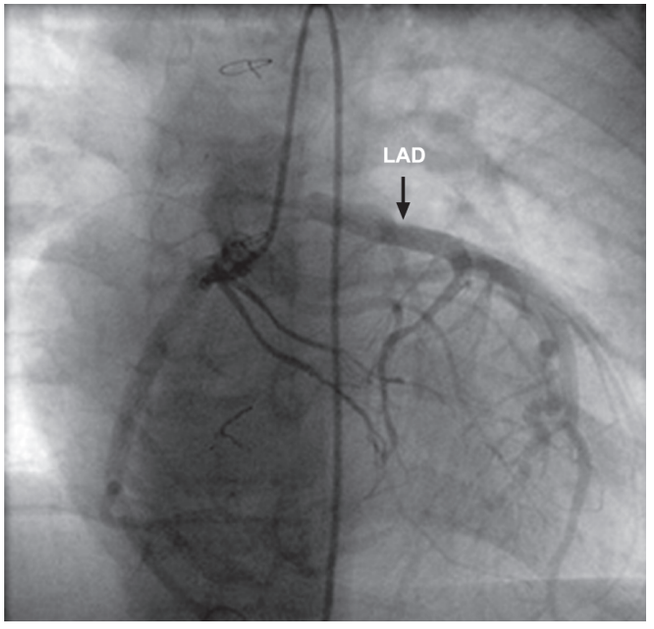

Fig. 4.49: Late phase of contrast injection to the right coronary artery demonstrated retrograde filling of the left anterior descending coronary artery (LAD) via intramyocardial collaterals and shunting to pulmonary artery

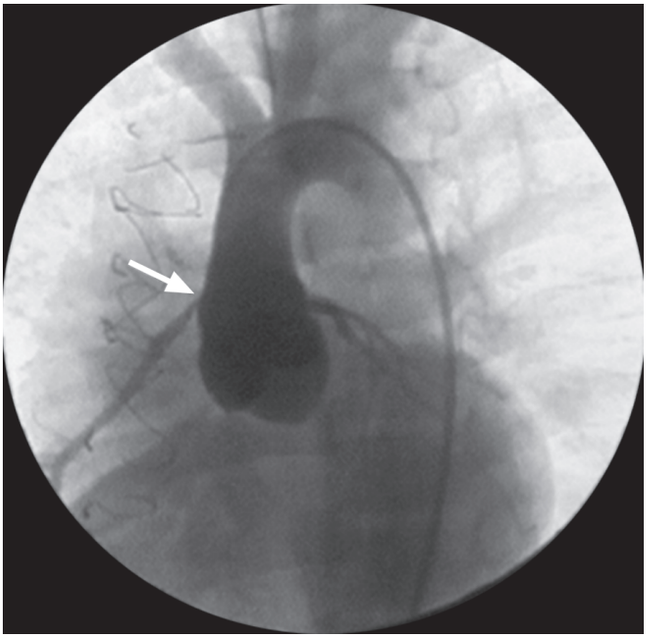

Fig. 4.51: Late assessment after the arterial switch operation for transposition of the great arteries, coronary angiogram shows lumen reduction at the origin of the right coronary artery

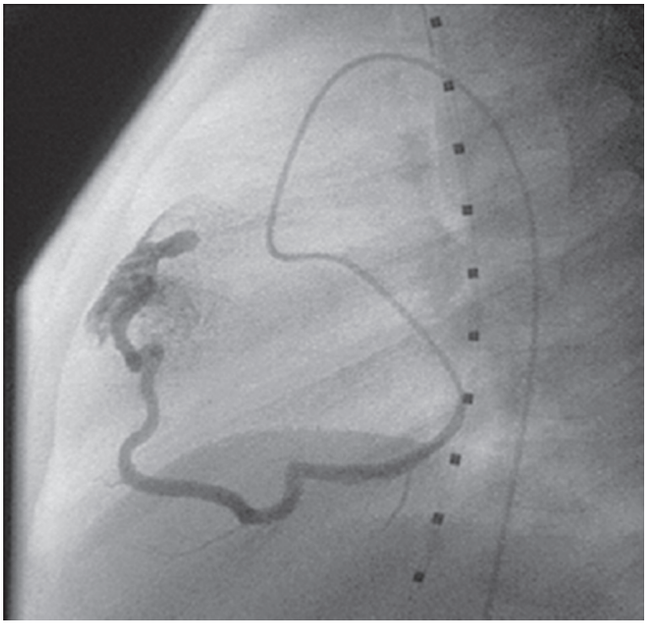

Fig. 4.50: Coronary angiogram during interventional catheterisation in a patient with coronary artery fistula

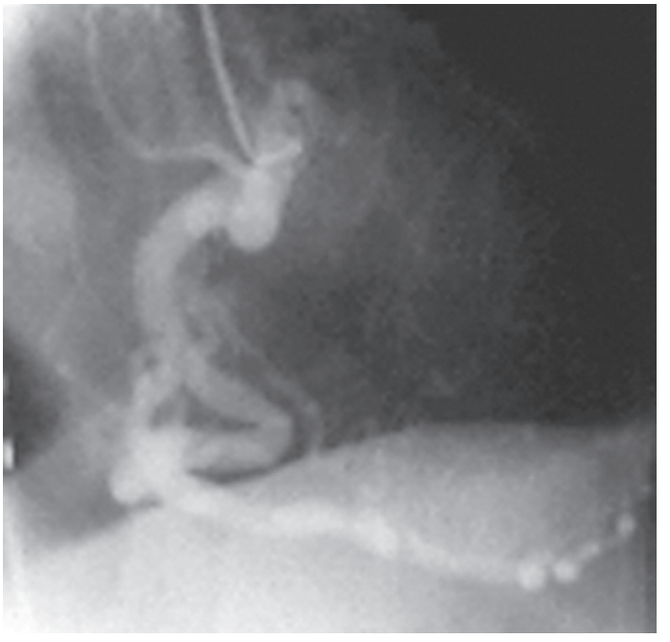

Fig. 4.52: Dilated right coronary artery associated with ALCAPA

2. Normal systolic function, but episodic heart failure raises suspicion of ischemically mediated left ventricular dysfunction (level of evidence: C).

Class III

Congestive heart failure with previous coronary angiograms showing normal coronary arteries, with no new evidence to suggest ischemic heart disease (level of evidence: C).

Conditions Associated with Coronary Artery Involvement

Aortic Dissection

The need for coronary angiography before surgical treatment for aortic dissection remains controversial

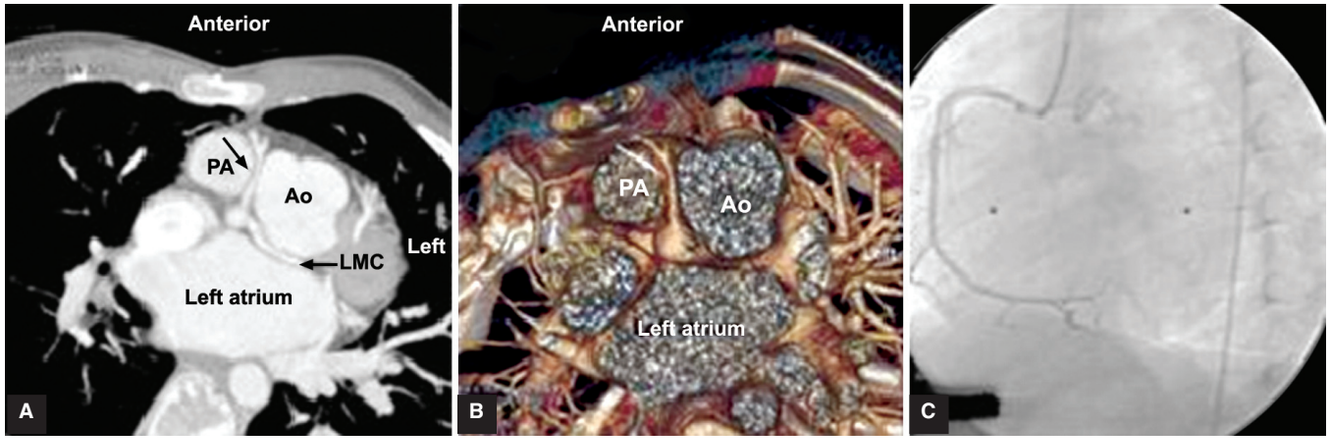

Fig. 4.53: Mild compression of the right coronary artery axial cross-section (maximum intensity projection). (A) 3-dimensional reconstruction, (B) showing a single coronary ostium from which both the right and left coronary arteries arise. There is mild compression of a long segment of the right coronary artery between the great arteries. The left coronary artery has a retroaortic loop with no stretching or compression, and (C) selective invasive angiogram of the right coronary artery: the proximal segment was classified as normal

because there are no large trials to support its use. In young patients with dissection due to Marfan syndrome or in dissection in peripartum females, coronary angiography is unnecessary unless there is suspicion that the dissection has affected one or both coronary ostia. In older patients, in whom dissection is usually related to hypertension, coronary angiography is often necessary, especially if patients are suspected of having coronary disease because of a history of angina or objective evidence of myocardial ischemia. In patients who have no history of coronary disease, the indications for coronary angiography are much less certain. Because of the high incidence of coronary disease in older patients with dissection, some studies have advocated routine coronary angiography, whereas others have found increased mortality when angiography is performed (Fig. 4.54).

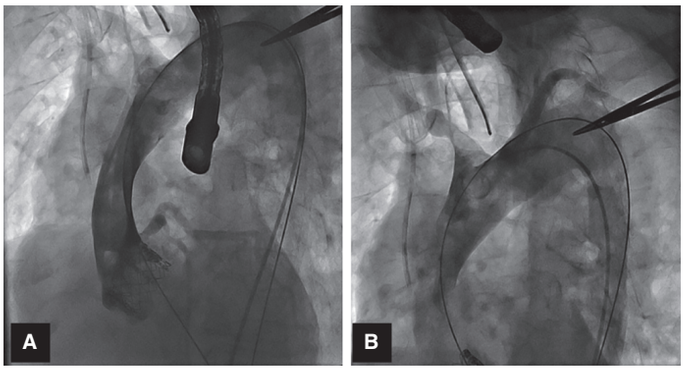

Fig. 4.54: Intraprocedural angiography demonstrating typical findings of ascending aortic dissection. Early phase of the injection of contrast medium into the proximal ascending aorta through a pigtail catheter showed only antegrade perfusion of the true lumen and smooth walls excluding the presence of the intimal tear ('entry') in the ascending aorta (A). The late phase revealed no malperfusion of the great vessels of the aortic arch and their perfusion from the true lumen (B)

Arteritis

Some patients with inflammatory processes affecting the aorta, such as Takayasu arteritis, may have coronary artery involvement requiring coronary artery revascularization. In such patients, coronary angiography is required before the surgical procedure. Kawasaki disease can result in coronary artery aneurysm and coronary artery stenosis producing myocardial ischemia or silent occlusion and may require coronary angiographic assessment (Fig. 4.55).

Hypertrophic Cardiomyopathy

Significant CAD due to atherosclerosis is found in 25% of patients aged >45 years with hypertrophic cardiomyopathy.

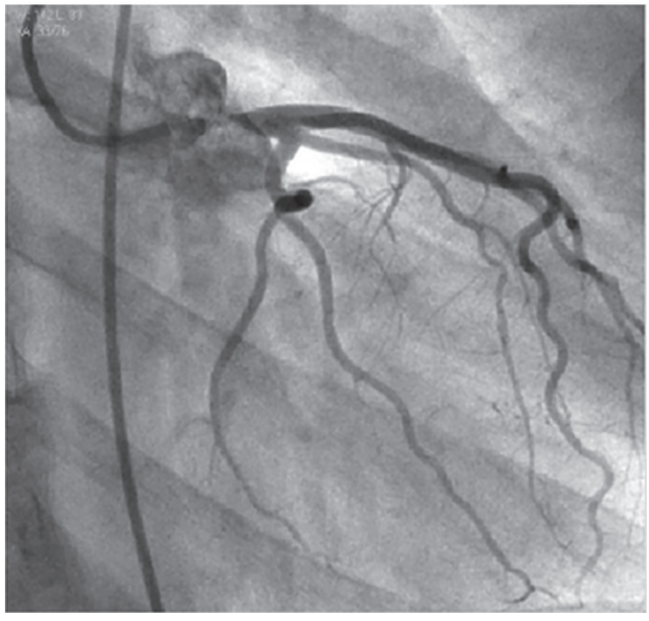

Fig. 4.55: A coronary angiography was performed, which showed in-stent restenosis with 90% obstruction in the left main coronary artery in a patient with Takayasu arteritis

Because symptoms due to CAD and hypertrophic cardiomyopathy are similar, patients with ischemic symptoms not well controlled with medical therapy may require coronary angiography to resolve the cause of chest pain. Coronary angiography also is indicated in patients with chest discomfort and hypertrophic cardiomyopathy in whom a surgical procedure is planned to correct outflow tract obstruction (Fig. 4.56).

Chest Trauma

Patients who have an acute MI shortly after blunt or penetrating chest trauma may have atherosclerotic CAD, but coronary artery obstruction or damage has been reported in the absence of coronary atherosclerosis. Furthermore, myocardial contusion may simulate acute MI. Infrequently, coronary angiography is indicated in the management of such patients (Fig. 4.57).

Miscellaneous Conditions

Preoperative coronary angiography may be indicated in patients undergoing cardiac operations such as pericardiectomy or removal of chronic pulmonary emboli if they have 1 risk factor for coronary disease, especially advanced age. Because of the concern about transplanting a donor heart affected by coronary disease, many advocate coronary angiography before transplantation, at least for those donors with a significant likelihood of CAD (Figs 4.58–4.60) .

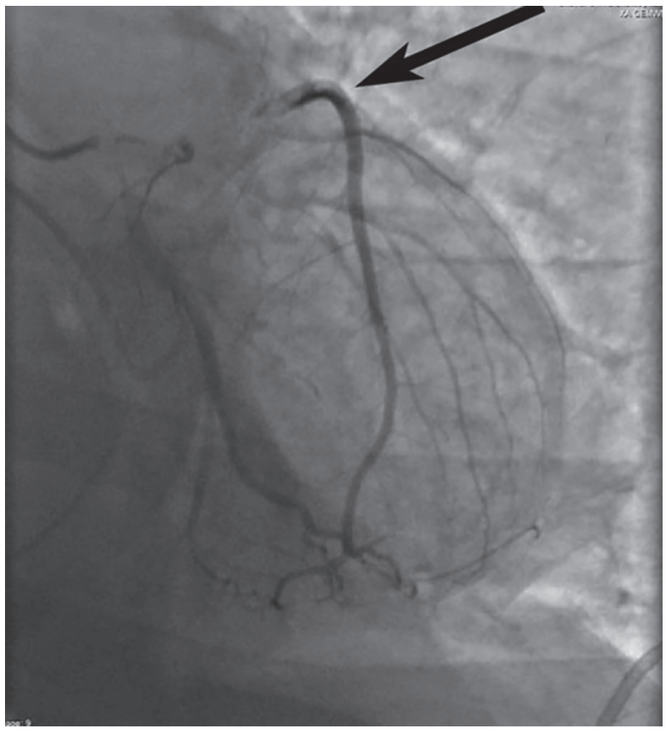

Fig. 4.57: Coronary artery dissection and acute myocardial infarction following blunt chest trauma. Coronary angiogram showing dissection of the middle part of the left anterior descending coronary artery (arrow)

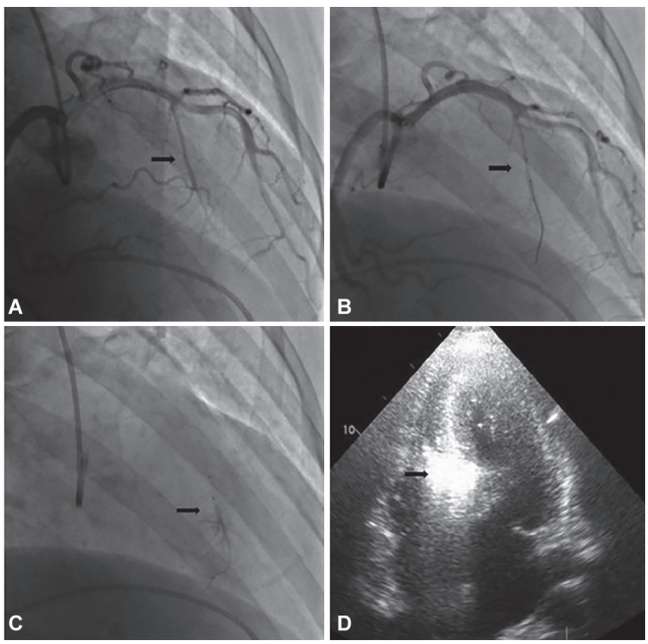

Fig. 4.56: Procedure: (A) angiography, right oblique cranial view of the left coronary artery, showing the target vessel; (B) selective catheterization of the target vessel and placement of balloon catheter; (C) selective angiography of the target vessel, showing injection of contrast through the lumen of the balloon catheter; (D) transthoracic echocardiography, 4-chamber view, showing hyperechogenic basal septum after injection of contrast

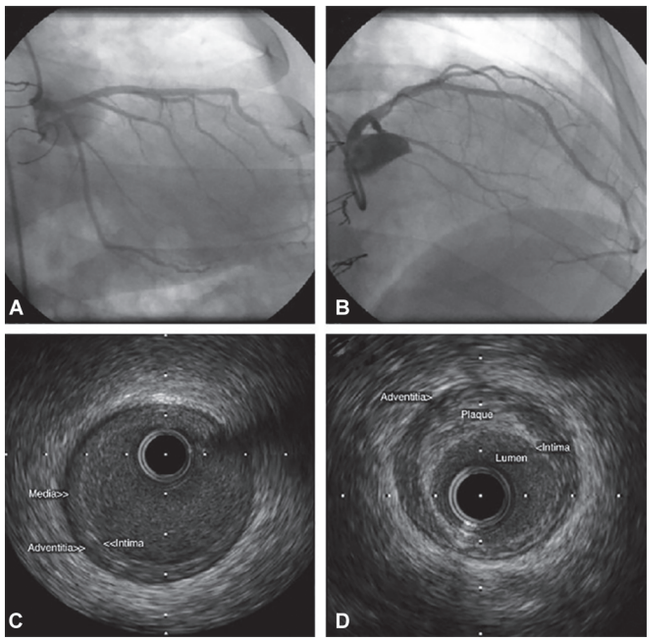

Fig. 4.58: Intravascular ultrasound images of the anterior descending artery in a patient transplanted 5 years previously, showing both the concentric intimal thickening typical of cardiac allograft vasculopathy (A) and an eccentric plaque typical of atherosclerotic coronary disease (B). Coronary angiography did not suggest disease in this artery (C and D)

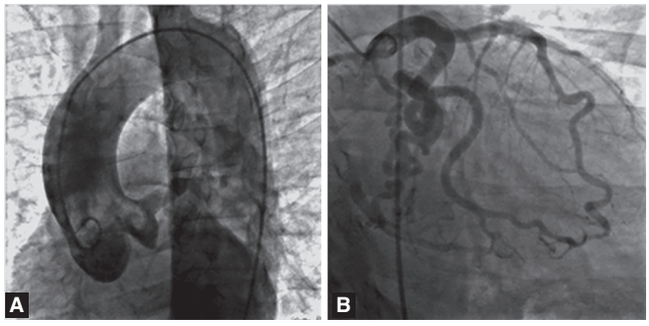

Fig. 4.59: Anomalous right coronary artery arising from the pulmonary artery. Aortography demonstrated the absence of a right coronary system but the presence of left coronary system. (A) Selective coronary angiography illustrated a dilated left coronary system with large collaterals to the right coronary territory. (B) A subsequent pulmonary angiogram showed constrast entering the right coronary artery from the main pulmonary trunk

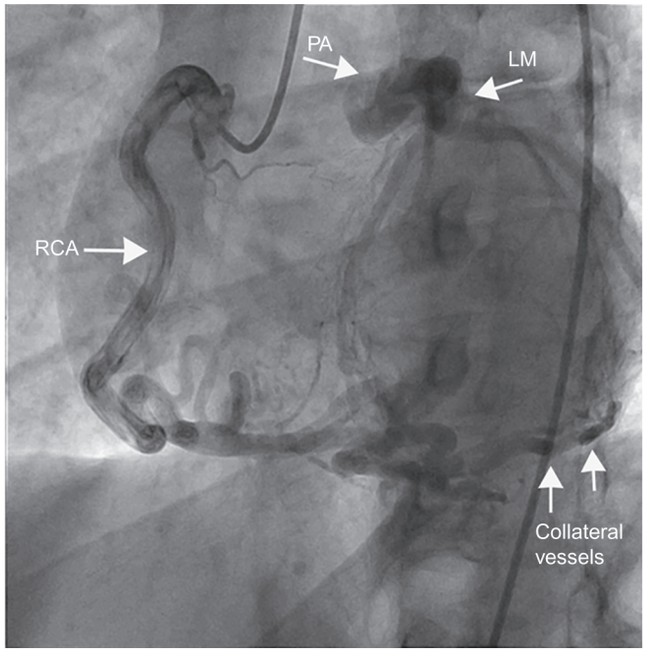

Fig. 4.60: Coronary angiography. Coronary angiography of the right coronary artery with collateral filling of the left coronary vascular territory, which connects directly to the pulmonary trunk

Recommendations for Intracoronary Doppler Ultrasound

Following are the recommendations for intracoronary Doppler ultrasound (Fig. 4.61):

- Class I: None.
- Class IIa: Assessment of the physiological effects of intermediate coronary stenoses (30–70% luminal narrowing) in patients with anginal symptoms. Doppler velocimetry may also be useful as an alternative to performing a noninvasive functional study to determine whether an intervention is warranted for intermediate lesions (or when the functional study is ambiguous) (level of evidence: C)

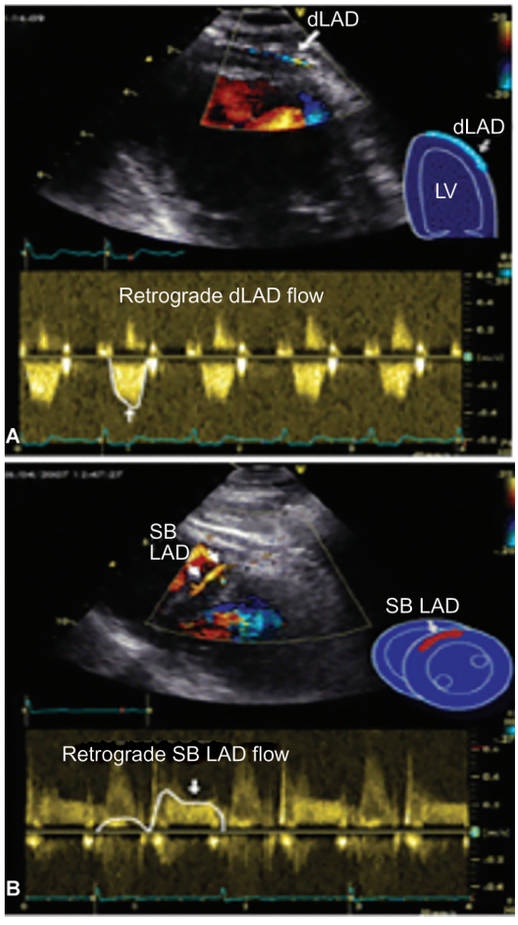

Fig. 4.61: Proximal occlusion of the left anterior descending coronary artery (LAD). Examples of color Doppler mapping (top) and Doppler spectrum (bottom) of the retrograde coronary blood flow. (A) Epicardial collateral vessel: distal LAD (dLAD); (B) intramyocardial collateral vessel: septal branch of the LAD (SB LAD)

- Class IIb:
  1. Evaluation of the success of percutaneous coronary revascularization in restoring flow reserve and to predict the risk of restenosis (level of evidence: C).
  2. After cardiac transplantation, diagnosis of impaired CFR in patients with anginal symptoms but no apparent angiographic culprit lesion (level of evidence: C)
  3. Assessment of the severity of coronary flow abnormalities in patients with anginal symptoms and a positive noninvasive functional study but no apparent angiographic lesion (level of evidence: C)
- Class III: Routine assessment of the severity of angiographic disease in patients with a positive noninvasive functional study (level of evidence: C).

Coronary Angioscopy

Coronary angioscopy uses visible light conducted through fiberoptic filaments to provide direct visual assessment of the surface characteristics and intraluminal morphology in vivo (Figs 4.62–4.63A, B and Table 4.2). The images appear

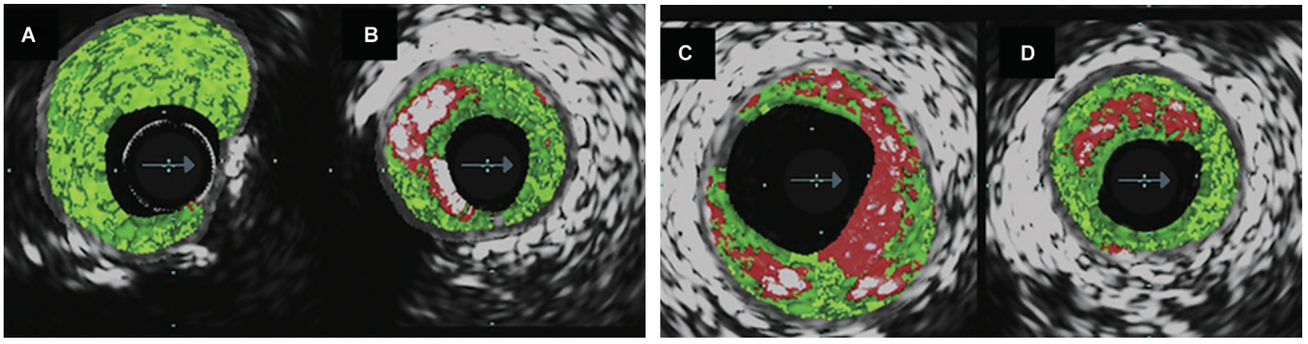

Fig. 4.62: Types of atherosclerotic plaque characterized by intravascular ultrasound virtual histology: (A) fibrotic plaque, (B) fibrocalcific plaque, (C) thin-cap fibroatheroma, (D) thick-cap fibroatheroma

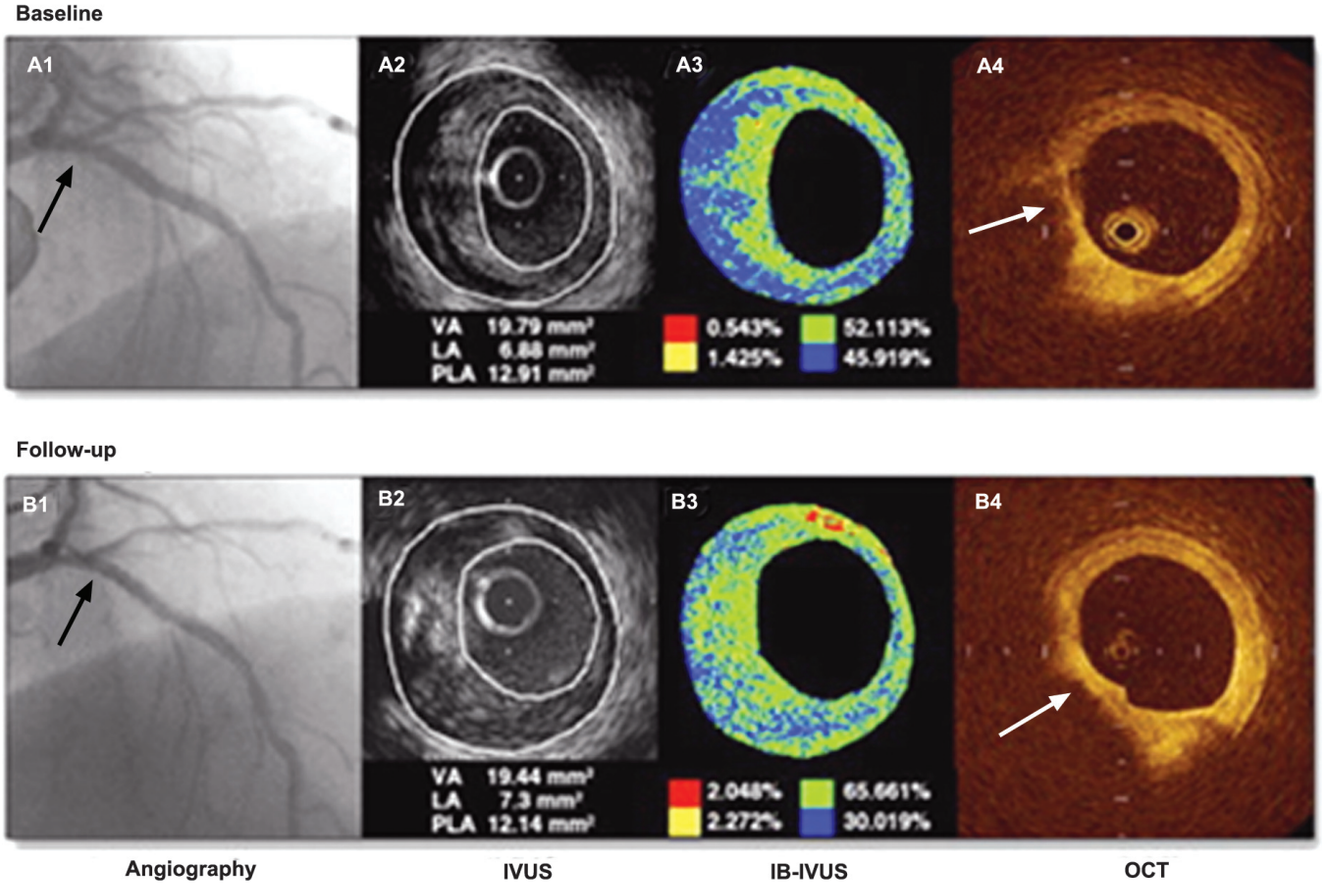

Fig. 4.63A: Coronary angiographic, grayscale IVUS, IB-IVUS, and OCT at baseline and follow-up for the pitavastatin group, while no significant difference was found between baseline and follow-up angiography (A1, B1), plaque volume index (i.e. plaque area in this slice) decreased from 12.9 mm^2 to 12.1 mm^2 by grayscale IVUS during follow-up (A2 and B2). Lipid (blue) volume index decreased from 45.9% to 30.0%, while fibrous (green) volume index increased from 52.1% to 65.6% by IB-IVUS (A3 and B3). OCT revealed that the fibrous cap thickness increased from 80 micm to 220 micm during follow-up (arrows in A4 and B4). IB-IVUS=integrated backscatter-intravascular ultrasound, IVUS=intravascular ultrasound, LA=lumen area, OCT=optical coherence tomography, PLA=plaque area; VA=vessel area

in color on a television monitor, which enables examination of the hue of the target lesion and associated plaques. Although difficult to use, angioscopy allows the differentiation of platelet-rich from fibrin-rich thrombus, and it may provide evidence of atheroma rupture, intraplaque hemorrhage, and coronary dissection. Accordingly, this diagnostic imaging modality yields information on the pathogenesis of acute coronary syndromes.

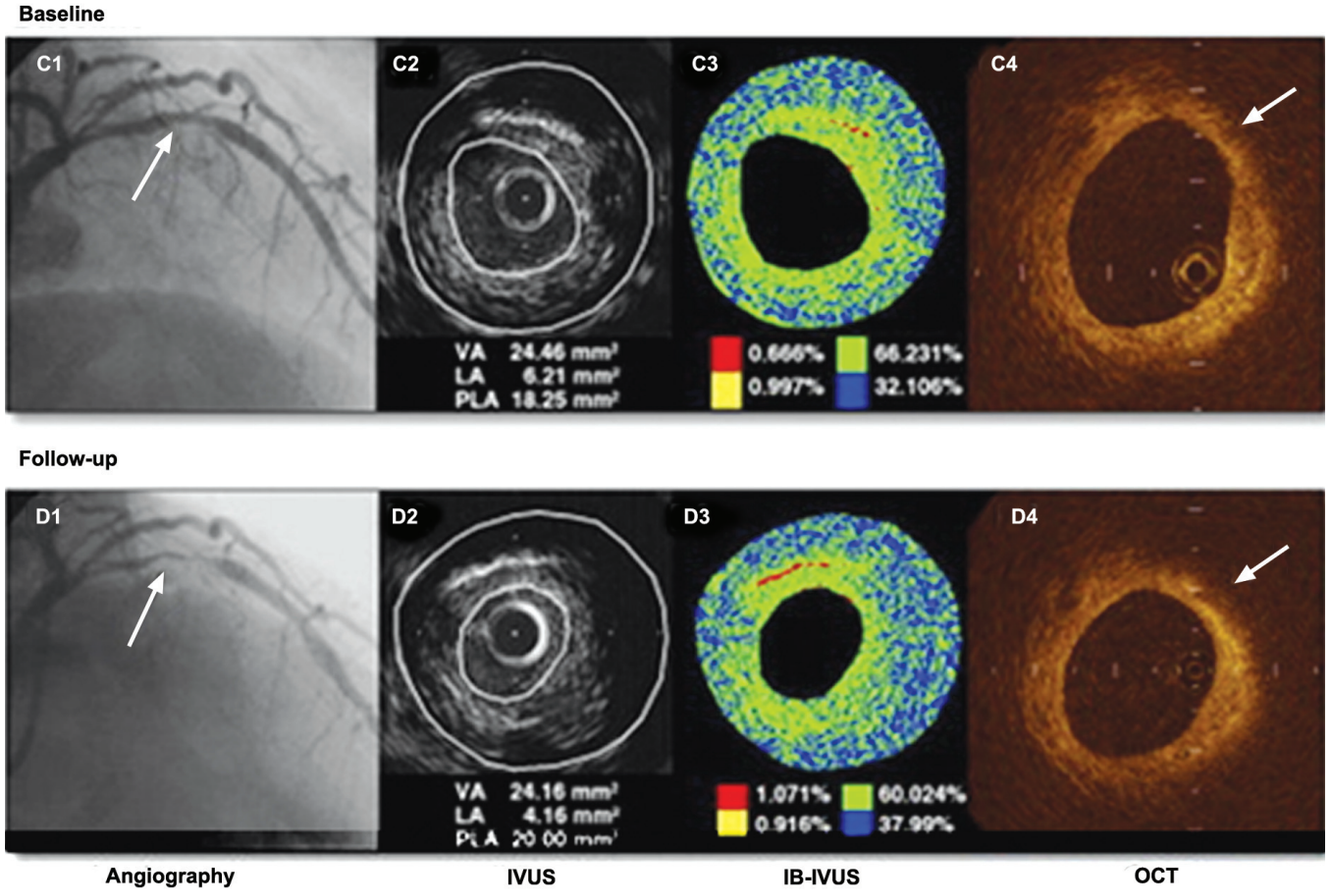

Fig. 4.63B: Coronary angiographic, grayscale IVUS, IB-IVUS, and OCT at baseline and follow-Up for the dietary group, whilst significant progression was observed by angiography during follow-up (C1 and C2), plaque volume index (e.g. plaque area in this slice) increased from 18.2 mm^2 to 20.0 mm^2 by grayscale IVUS during follow-up (C2 and D2). Lipid (blue) volume index increased from 32.1% to 37.9%, whereas fibrous (green) volume index decreased from 66.2% to 60.0% by IB-IVUS (C3 and D3). OCT revealed that the fibrous cap thickness of 110 micm did not change during follow-up (arrows in C4 and D4)

Table 4.2: Differences between cardiac allograft vasculopathy and atherosclerotic coronary disease

	Cardiac allograft vasculopathy	Atherosclerotic coronary disease
Location	Distal epicardial and intramyocardial vessels	Proximal epicardial vessels
Plaque type	Diffuse, concentric	Focal, eccentric
Inflammation	Yes	Rarely
Vasculitis	Infrequently	Never
Internal elastic lamina	Intact	Disrupted
Calcium deposits	No	Yes

Angioscopy Equipment and Technique

All angioscopes require a blood-free field for clear visualization of the arterial wall. This is obtained by inflating a proximal balloon to temporarily occlude blood flow, followed by continuous saline irrigation, which requires a second catheter lumen. Two additional lumens are required for the optical fibers, one for visualization and another to serve as a light source. Videotape recording allows for more detailed offline analysis. A commonly used device is a 120-cm-long 4.5 monorail catheter with an imaging bundle containing 3,000 fibers that permits a viewing arc of 55° and a depth-of-field of 0.5 mm. A video camera displays the images in real time on a color monitor, while videotape recording allows for more detailed offline analysis.

Angioscopy of Unstable Coronary Syndromes

Small-scale studies of fiberoptic angioscopy demonstrate differences in the intraluminal appearance of stable versus unstable coronary lesions. An intraoperative study of

32 patients showed distinctive intimal abnormalities in all 10 patient's with unstable angina: four patients had 'complex plaque' and seven had overt intraluminal thrombus. Neither complex plaques nor thrombi were observed by angioscopy in any patient with stable coronary disease. These findings were later confirmed by percutaneous angioscopy. In 16 patients with unstable angina, 50% had thrombus and 14% had overt dissection. Neither thrombus nor dissection was seen in any of the 4 patients with stable angina.

In addition to identifying the presence of thrombus, angioscopy can differentiate platelet-rich from fibrin-rich thrombi. Mizuno et al. performed angioscopy in 15 patients with unstable angina and 16 patients with acute MI. Angioscopy identified intraluminal thrombus in 29 of 31 patients. However, the typical thrombus in patients with unstable angina was grayish-white in color, suggesting the predominance of platelets, whereas in patients with acute MI, angioscopy identified a preponderance of red thrombi, suggesting an erythrocyte and fibrin-rich clot. Angioscopy can distinguish other surface features of coronary atheromata. Stable plaques are recognized by their elevated contour, smooth configuration, and yellowish-white color. In a study of 199 patients, those with predominantly yellow plaques were found to have higher low-density lipoprotein (LDL) cholesterol and apolipoprotein B levels.

Angioscopy during Interventions

Assessment of lesions before or after coronary intervention represents the most commonly reported application of coronary angioscopy. Angioscopy after balloon angioplasty demonstrates that dissections and thrombus are present in almost all cases. However, no prospective data exist that demonstrate a different outcome for patients on the basis of angioscopic findings. The preprocedural identification of thrombus may also prove useful in selecting candidates for coronary stenting and for the use of any of the new antiplatelet agents. Although the value of angioscopy in identifying thrombus is well established, no data exist to suggest that angioscopy can reduce stent-related complications.

Limitations of Coronary Angioscopy

Despite recent technical advances, angioscopy is still limited to the proximal and midportions of relatively straight, large epicardial coronary arteries. Furthermore, the rapid development of ischemia during balloon inflation limits the time of examination. For successful imaging, lesions need to be located 20 mm distal to the balloon site, which makes it impossible to visualize ostial or very proximal lesions. Angioscopy shows only the surface characteristics of plaques and cannot discern the underlying atheroma morphology. Accordingly, it remains unproved whether visualization of surface anatomy alone warrants the time, expense and risk of angioscopy. In addition, occlusion of coronary flow may produce important imaging artifacts. A recently published study of the European Working Group on Coronary Angioscopy demonstrated that the identification of red thrombus and dissection has relatively close interobserver agreement. However, other angioscopic diagnoses have wide interobserver variability.

Recommendations for Coronary Angioscopy

- Class I: None
- Class II: None
- Class III: Coronary angioscopy should be considered a research tool for which there are no established clinical indications.

Pharmacologic Assessment of Coronary Spasm

a. **Coronary artery spasm:** Epicardial coronary arteries exhibit vasoactivity similar to that of many systemic arteries of a similar caliber. The presence of atherosclerotic plaque is associated with endothelial dysfunction, which can increase or decrease segmental responses to endogenous and exogenous vasoactive substances. Thus, patients with coronary atherosclerosis may have spontaneous increases in coronary vasomotor tone, resulting in myocardial ischemia. These regional coronary vasospastic events can cause ischemia associated with a variety of ST and T-wave changes. Tobacco and cocaine abuse are important risk factors for the provocation of vasospasm. Provocative testing with either methylergonovine or acetylcholine often demonstrates the presence of coronary spasm. Although vasomotion can result in as much as a 20% change in lumen diameter, coronary spasm is considered to be present when a reduction in lumen caliber of >50% occurs during a provocative test and reversal is achieved with intracoronary nitroglycerin. Prinzmetal variant angina is a clinical syndrome occurring in a small percentage of patients without angiographic evidence of significant stenosis or normal angiograms in whom ischemia is caused by severe spasm of an epicardial coronary artery. Variant angina, as described by Prinzmetal in 1959 is an unusual syndrome characterized by ischemic myocardial pain that usually occurs at rest, with accompanying ECG ST-segment elevation.

Basal coronary artery vasoreactivity and tone are increased in variant angina. Studies using ^{123}I metaiodobenzylguanidine (^{123}I MIBG) SPECT demonstrate regional myocardial sympathetic dysinnervation in patients with variant angina. Tobacco and cocaine may cause episodes of variant angina, the latter because it blocks presynaptic uptake of norepinephrine and dopamine, thereby facilitating alpha-adrenergically mediated vasospasm. Cardiac arrhythmias, including ventricular tachycardia and fibrillation, heart block, acute infarction and sudden death, may occur in association with variant angina. Studies using ^{123}I BMIPP, a branched fatty acid, have demonstrated

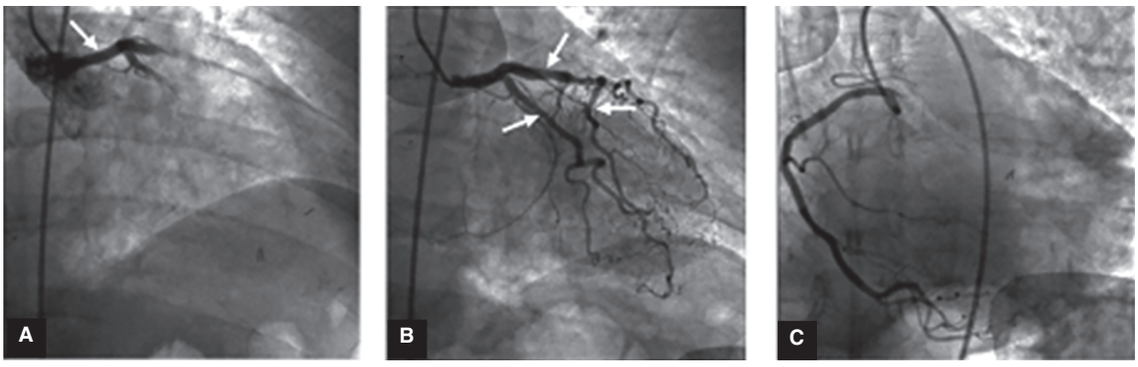

Fig. 4.64: (A) angiography of the left coronary arterial system showed total occlusions of the proximal left anterior descending coronary artery (LAD) and left circumflex artery (LCX). (B) An immediate left coronary artery angiography revealed complete restoration of coronary artery occlusion, suggesting resolution of the acute coronary spasm C. Her proximal LAD had mild luminal irregularities, with up to 30% luminal stenosis, near the site of the previously seen spasm. Her right coronary angiogram was widely patent at the stent site, with only a 20–30% eccentric luminal narrowing at the distal end of the stent

myocardial injury in association with some episodes of variant angina (Fig. 4.64).

b. **Provocative testing for spasm:** Of the tests available to demonstrate coronary spasm, provocation by ergonovine maleate, methylergonovine maleate, acetylcholine or hyperventilation are the most useful (Figs 4.65 and 4.66). Ergonovine maleate for injection is no longer available, and the availability of methylergonovine is limited. The intravenous administration of incremental doses of methylergonovine starting at 0.05 mg to a maximum of 0.40 mg is both sensitive and specific, and there is an inverse relationship between the dose required to provoke spasm in the laboratory and the frequency of spontaneous episodes experienced by the patient. To ensure a valid test, nitrates and calcium antagonists must be withdrawn for 48 hours before testing. Women are more sensitive than men to methylergonovine The intracoronary route of administration of methylergonovine for provocation of spasm is safe, sensitive, and specific. This route is preferable in hypertensive patients and affords the opportunity to evaluate the left and right coronary circulations separately. Small dosing increments of 5–10 µg are used, with a total dose not to exceed 50 µg.

Absolute contraindications to methylergonovine include pregnancy, severe hypertension, severe left ventricular dysfunction, moderate to severe aortic stenosis and high-grade left main coronary stenosis. Relative contraindications include uncontrolled or unstable angina, uncontrolled ventricular arrhythmia, recent MI and advanced coronary disease. Alternatively, intracoronary acetylcholine can be used as a provocative test for spasm, and its effectiveness is comparable to methylergonovine. Acetylcholine is infused over 1 minute into a coronary

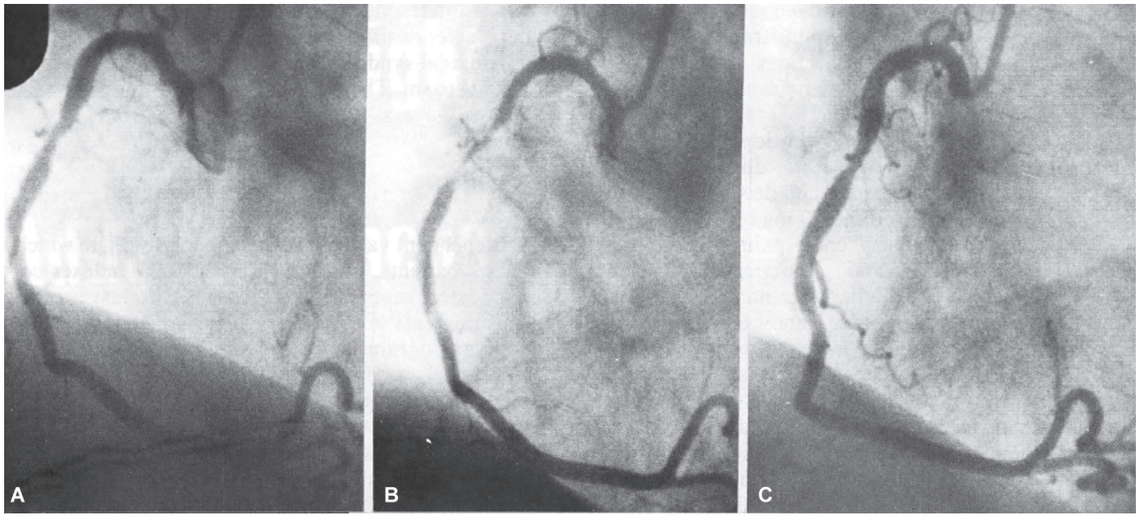

Fig. 4.65: A sequence of right coronary arteriograms in the 60° left anterior oblique projection which demonstrates (A) approximately 60% narrowing of the diameter of the right coronary artery before ergonovine maleate (EM), (B) greater than 95% focal narrowing following a cumulative dose of 0.40 mg EM at the site of narrowing demonstrated in (A), and (C) diffuse dilatation and dilatation at the site offocal spasm after 0.40 mg sublingual nitroglycerin

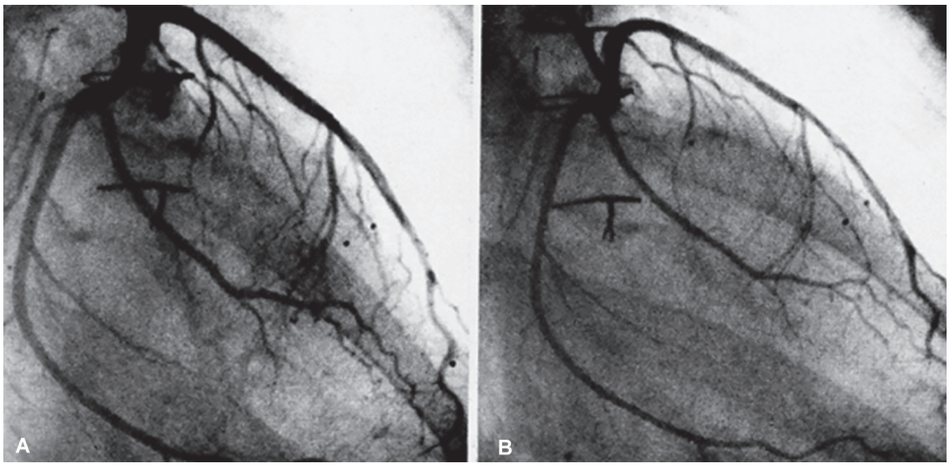

Fig. 4.66: Left coronary artery arteriograms of a heart transplant recipient in the 30° right anterior oblique view: (A) before administering ergonovine maleate (EM) and (B) 3 minutes after a cumulative dose of 0.40 mg EM, which demonstrates the same degree of mild, diffuse narrowing of coronary arteries observed after EM administration in patients with normally innervated hearts. The small densities which outline the left ventricle are tantallum markers within the left ventricular myocardium

artery in incremental doses of 10, 25, 50 and 100 µg. Doses should be separated by 5-minute intervals. The same procedural safeguards must be used with acetylcholine and methylergonovine. In patients with 1 episode of variant angina per day, the hyperventilation provocative test is nearly as effective as methylergonovine in causing vasospasm. In patients with less frequent attacks, hyperventilation is less sensitive. The test requires a patient to hyperventilate vigorously at 30 respirations per minute for 5 minutes. With this degree of hyperventilation, arterial pH will increase to 7.60 and pCO_2 will decrease to 20 mmHg. Variant angina, if provoked, will occur during hyperventilation and will subside more rapidly than after methylergonovine infusion. The cold presser test can also provoke coronary spasm but is less reliable than pharmacologic techniques.

In patients with ST-segment elevation during episodes of chest pain and a normal coronary angiogram, provocative tests are usually not necessary, because ample clinical evidence is present to confirm the diagnosis of coronary spasm.

FRACTIONAL FLOW RESERVE

The measurement of pressure gradients across coronary stenoses was the earliest method used to assess the

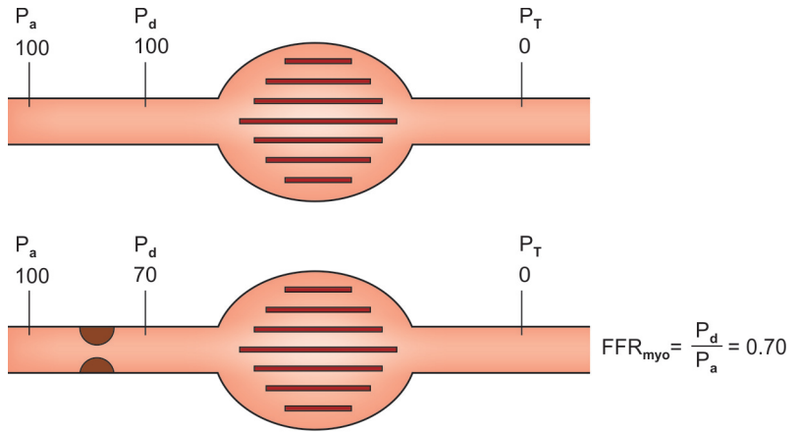

Fig. 4.67: Simplified illustration of a coronary artery and the dependent myocardial bed. If that system is studied under conditions of maximum arteriolar vasodilatation, myocardial resistance will be minimal and equal to Rmin. Under such circumstances the flow limiting effect of the epicardial stenosis is maximal, as is the pressure drop across the lesion, expressed as the ratio of driving pressure to resistance, maximum attainable blood flow through the myocardium equals the ratio of the perfusion pressure across the myocardium (distal coronary pressure minus central venous pressure) and the resistance Rmin. If there is no epicardial stenosis, the perfusion pressure across the myocardium equals PaPv where Pa is mean aortic pressure and Pv is central venous pressure. In the presence of a coronary stenosis, the perfusion pressure across the myocardium has decreased to PdPv, where Pd represents hyperaemic coronary pressure distal to the stenosis

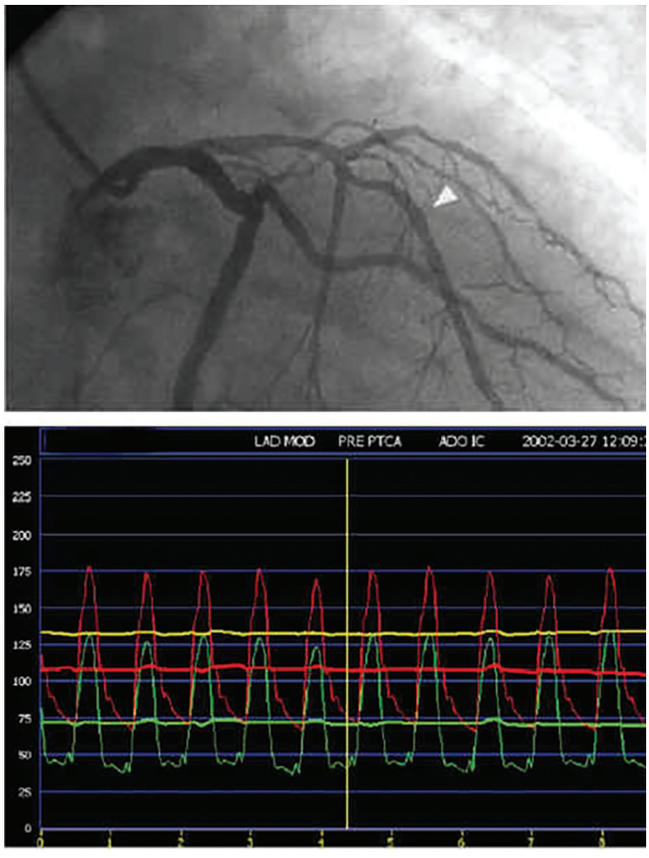

Fig. 4.68: Anterior right oblique projection showing an intermediate lesion in the middle third of the anterior descending coronary artery, distal to a well-developed septal branch. There is also another mild lesion close to the septal branch. After positioning the transducer of the pressure guidewire distal to the stenosis (arrowhead) and inducing maximum hyperemia with intravenous adenosine, a mean pressure of 71 mmHg was recorded by the pressure guidewire transducer and 108 mmHg by the catheter guidewire. The ratio of the two values for myocardial fractional flow reserve (MFFR) was 0.66, indicating a significant lesion

adequacy of coronary angioplasty. However, because of the size of the catheter and changes in technology, angiographic and now ultrasonic assessments are more commonly used. Recently, small catheters and guidewires have been developed to more accurately measure pressure gradients across stenoses before and after interventional procedures. Pijls and colleagues demonstrated that just as with CFR measurements by Doppler ultrasound, fractional flow reserve (FFR) is useful in assessing the severity of a coronary stenosis (Figs 4.67 and 4.74). The ratio of the mean pressure distal to a coronary stenosis to that proximal to the stenosis, usually measured through the guiding catheter after maximal vasodilation induced by adenosine or papaverine, can assess the severity of the stenosis. When this ratio falls below 75%, there is an 88% sensitivity and an 84% specificity for an abnormal exercise test. Similar correlations have been made with positron emission tomography (PET) and CFR measured by Doppler ultrasound. The technique is easier

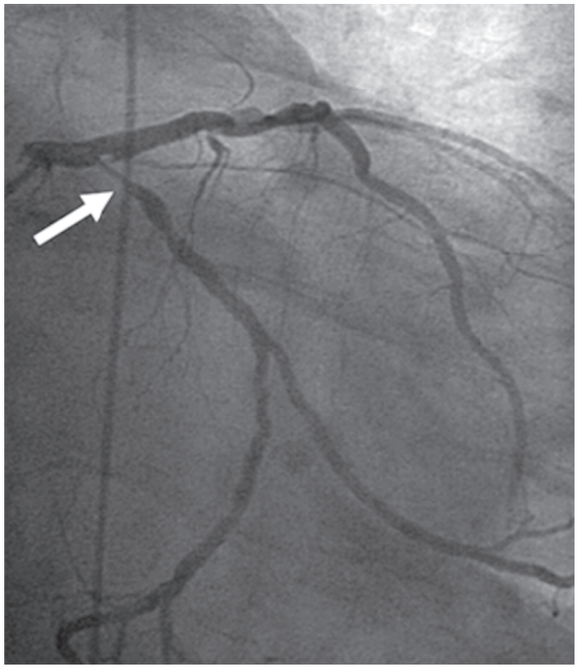

Fig. 4.69: Invasive coronary angiogram in a patient demonstrates moderate lesion in the proximal left circumflex coronary artery (arrow), which was hemodynamically significant (FFR, 0.67)

to use than Doppler ultrasound. Although it is still in development and validation, it appears likely to be a useful tool in the future to assess coronary stenoses.

What is Fractional Flow Reserve?

Myocardial fractional flow reserve is a new index of the functional severity of a coronary stenosis that is calculated from pressure measurements made during coronary arteriography. This new approach enables an 'on the spot' diagnosis as to what extent a given stenosis (coronary blockage) contributes to reversible myocardial ischemia and the decision whether revascularization of the stenosis is warranted.

How does FFR work?

- Fractional flow reserve (FFR) closely relates distal coronary pressure to myocardial blood flow during maximum arteriolar vasodilatation.
- The functional state of a patient with a coronary artery stenosis is determined by the maximum blood flow that can reach the heart muscle. As soon as maximum achievable blood flow, at a given level of exercise, is no longer sufficient to match oxygen demand, myocardial ischemia and angina will occur.

How are FFR measurements performed?

- FFR can be measured during a routine cardiac catheterization
- The stenosis is crossed with an 0.014 inch pressure guidewire for recording the trans-stenotic pressure, and administering a maximum hyperemic stimulus (intracoronary adenosine 12–20 µg or intravenous adenosine 140 µg/kg/min infused into the femoral vein).

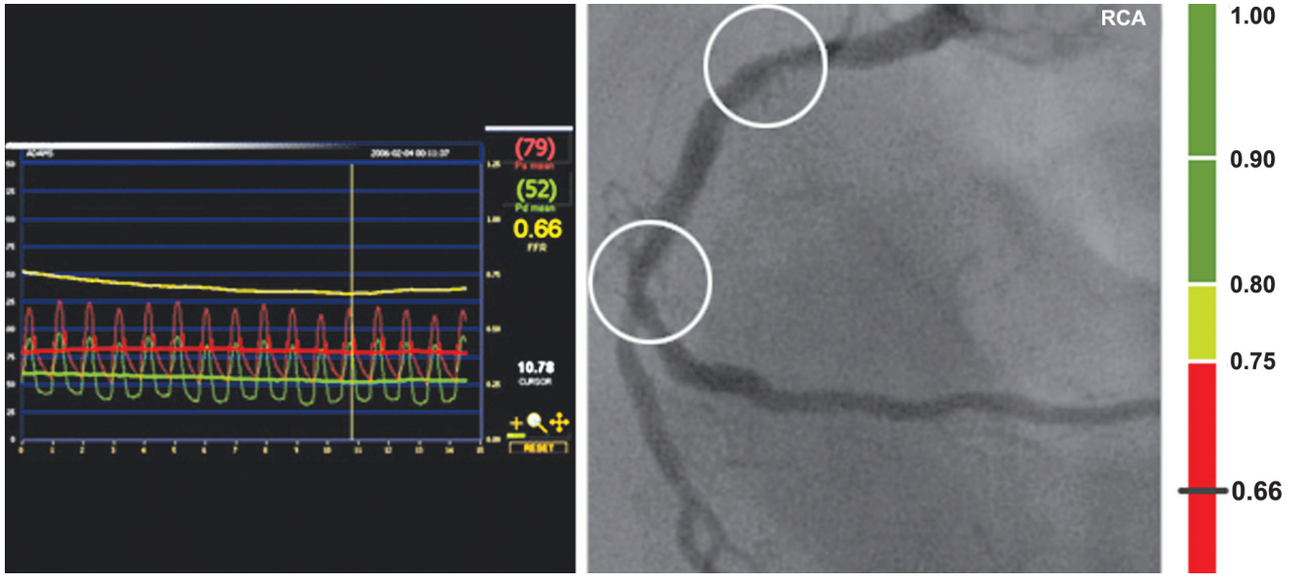

Fig. 4.70: The FFR in the RCA was well below 0.75. The most proximal stenosis was stented first and a new FFR measurement was performed. A continued low FFR prompted stenting of the distal lesion as well

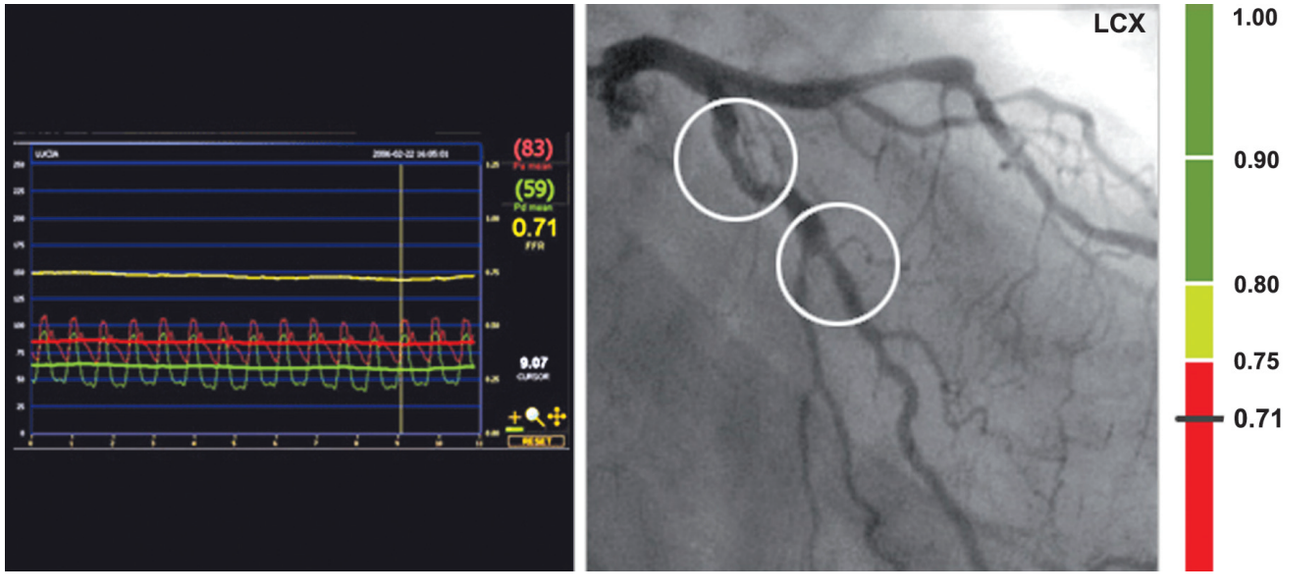

Fig. 4.71: The FFR in the LCX was below 0.75 and a pressure pullback recording showed both lesions to be significant. Two stents were placed satisfactorily as confirmed by FFR >0.90

What do the FFR values mean?

- FFR value <0.75 discriminates functionally significant lesions
- FFR >0.75 means the blockage is not severe enough to limit blood flow to the heart
- FFR <0.75 means that the blockage is severe enough to limit blood flow to the heart and should be opened if possible.

What are the benefits of FFR?

- FFR is a specific index for the epicardial stenosis and therefore better indicates to what degree a patient can be helped by revascularization
- FFR has a normal value of 1.0 in every patient and every coronary artery
- FFR is independent of changes in heart rate, blood pressure, and contractility
- FFR takes into account the contribution of the collateral flow
- FFR can be applied in multivessel disease and for serial lesions within one vessel.

How are FFR measurements performed?

- FFR can be measured during a routine cardiac catheterization

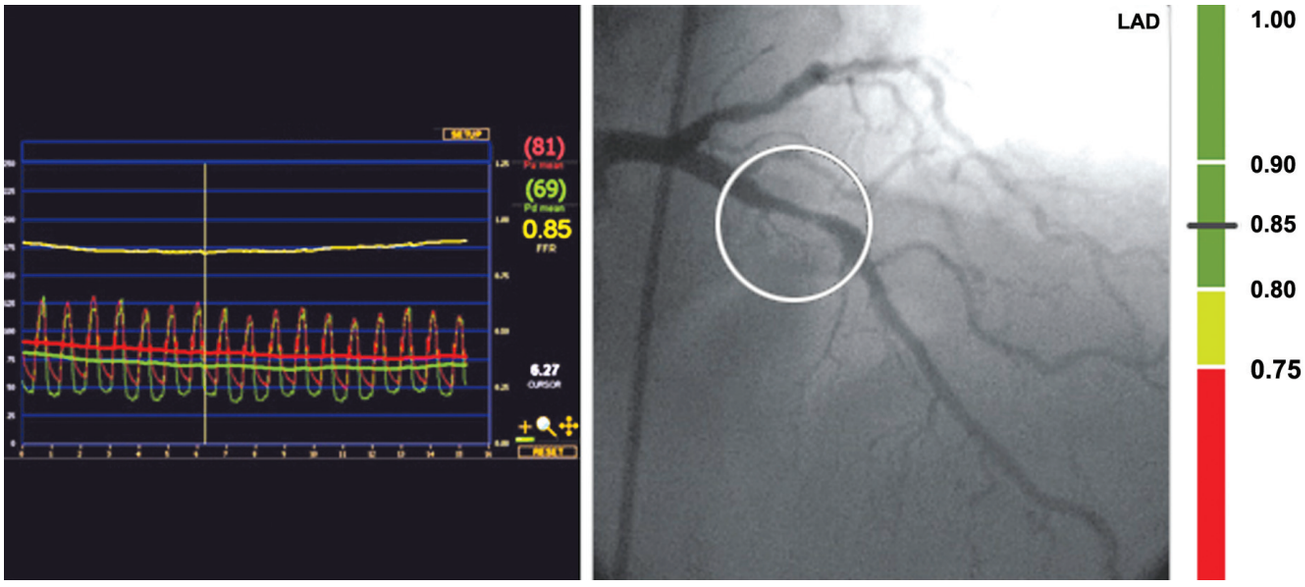

Fig. 4.72: Angiography showed three diseased vessels. FFR helped to identify which lesions required treatment. A pressure pullback in the long disease segment of the LAD revealed that there was no significant reduction in flow in this vessel (FFR >0.75)

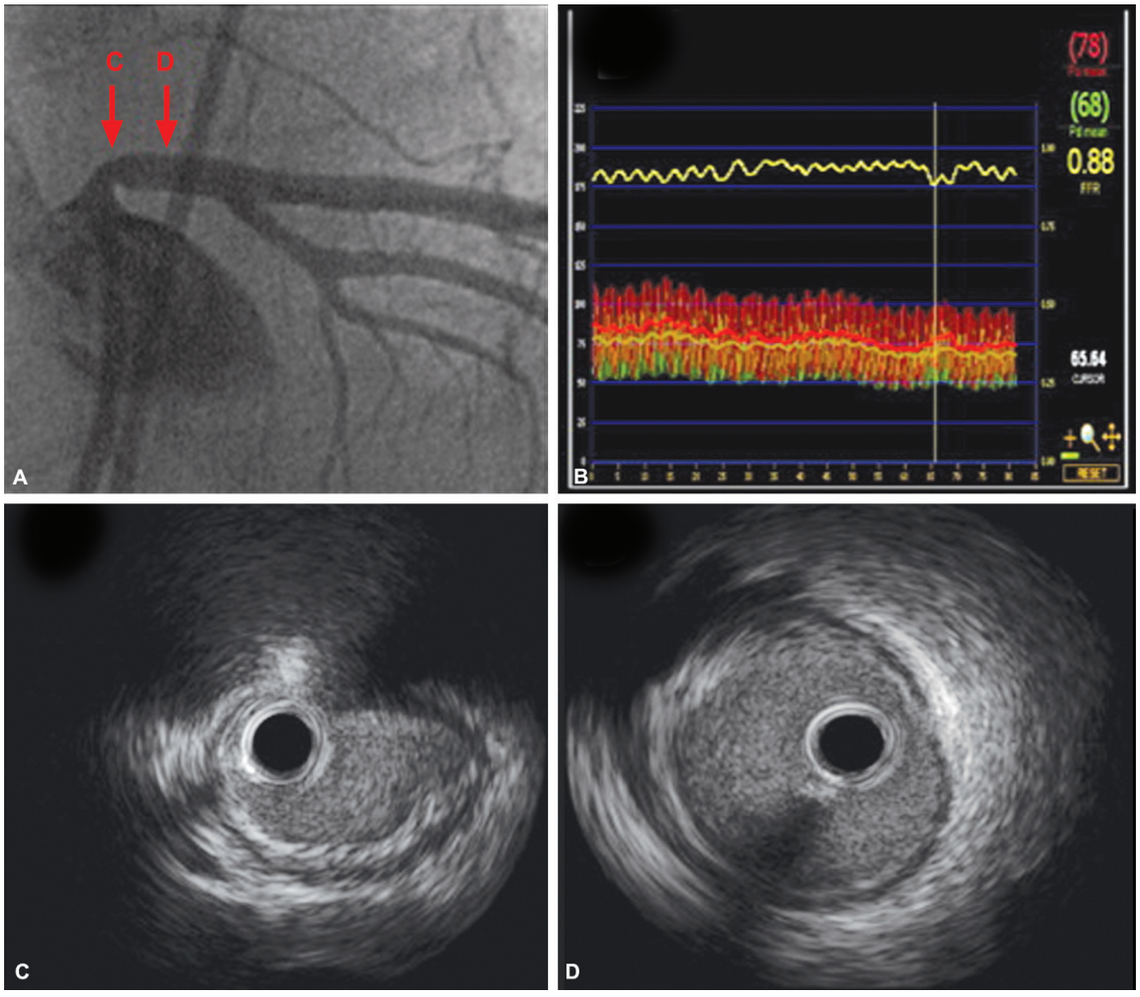

Fig. 4.73: Angiographic intermediate ostial left main lesion. An example of an angiographic intermediate ostial left main lesion (A) that was investigated by FFR (B), and IVUS (C, D). FFR was 0.88, and IVUS demonstrated mild plaque with significant negative remodeling resulting in an MLA of 8.9 mm^2. The red arrows (A) indicate the location of IVUS frames displayed in C and D. The patient was medically managed and revascularization was deferred

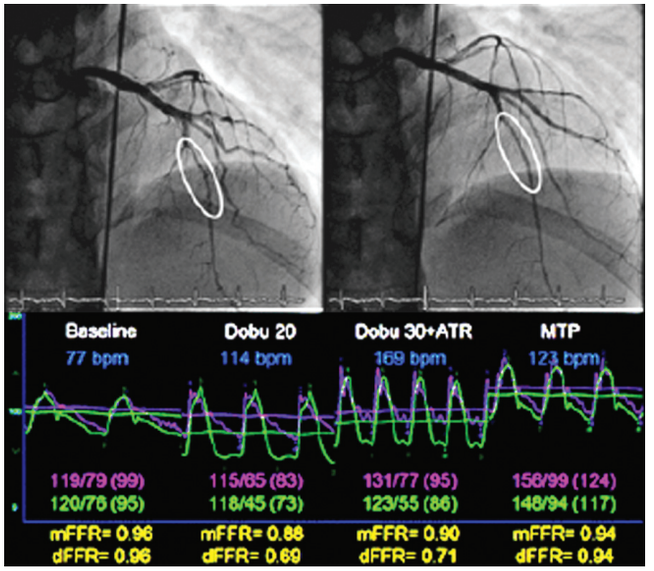

Fig. 4.74: Left, midsystolic image of the left coronary artery in anteroposterior view, with 20° of cranial inclination. Just distal to a septal branch, myocardial bridging and 'milking' is observed in the left anterior descending artery (encircled in white). Right, end-diastolic view in the same incidence. The segment just distal to the septal branch is smooth and free of atherosclerotic disease. The lower insert of the figure depicts the pressure tracings and their respective values in mmHg at the level of the aorta (in purple) and in the left anterior descending artery distal to the segment with systolic compression (in green). The ratio of distal pressure to aortic pressure (FFR) is depicted in yellow. Values are mentioned for mean and diastolic pressures (mFFR and dFFR, respectively). The distal measurements were obtained using a 0.014 inch pressure wire, after induction of maximum hyperemia with an intracoronary bolus of adenosine. Left to right—measurements in baseline condition, during intravenous infusion of dobutamine at 20 micg/kg/min, during intravenous infusion of dobutamine at 30 micg/kg/min and administration of 1 mg of atropine, and finally after intravenous administration of 10 mg of metoprolol. The respective heart rates (bpm) are mentioned in blue. At a dose of 20 micg/kg/min of dobutamine, systolic pressure overshoots distally to the dynamic lesion with a diastolic pressure gradient <0.75. At the highest dose of dobutamine and after administration of atropine, an important diastolic pressure gradient is seen (55/77=0.71), indicating impaired myocardial perfusion by the myocardial bridge. This gradient disappeared almost instantly after the intravenous administration of metoprolol, despite a higher heart rate than that during the intravenous infusion of dobutamine at a dose of 20 micg/kg/min

- The stenosis is crossed with an 0.014″ pressure guidewire for recording the trans-stenotic pressure, and administering a maximum hyperemic stimulus (intracoronary adenosine 12–20 µg or intravenous adenosine 140 µg/kg/min infused into the femoral vein).

When is FFR used?

- FFR is used as a diagnostic tool to determine whether a particular coronary stenosis, found at angiography, is responsible for reversible ischemia (and consequently should be dilated or bypassed if medical treatment fails)
  - Specifically in respect to intermediate stenosis
  - Identification of the culprit lesion in case of multivessel disease
  - Justification to perform (or avoid) angioplasty in a patient without documented evidence of ischemia at noninvasive testing
  - To indicate the exact location of a lesion in case of overprojection and other situations where the angiographic image is unclear.
- Coronary intervention
  - A high value of FFR after regular balloon angioplasty is associated with a favorable long term outcome.
- Coronary stenting
  - Evaluation of optimum stent deployment.

Computed Fractional Flow Reserve Derived from Coronary CT Angiography

Recent advances in image-based modeling and computational fluid dynamics permit the calculation of coronary artery pressure and flow from typically acquired coronary computed tomography (CT) scans. Computed fractional flow reserve (FFRCT) is the ratio of mean coronary artery pressure divided by mean aortic pressure under conditions of simulated maximal coronary hyperemia, thus providing a noninvasive estimate of fractional flow reserve (FFRCT) at every point in the coronary tree. Prospective multicenter clinical trials have shown that computed FFRCT improves diagnostic accuracy and discrimination compared to CT stenosis alone for the diagnosis of hemodynamically significant coronary artery disease (CAD), when compared to invasive FFR as the reference gold standard. This promising new technology provides a combined anatomic and physiologic assessment of CAD in a single noninvasive test that can help select patients for invasive angiography and revascularization or best medical therapy. Further evaluation of the clinical effectiveness and economic implications of noninvasive FFRCT are now being explored (Fig. 4.75).

Noninvasive Coronary Artery Disease with Multidetector CT Angiography in Patients with Noncoronary Cardiovascular Surgery (Figs 4.76 and 4.94)

Preoperative evaluation of patients scheduled to undergo noncoronary cardiovascular surgery includes the use of invasive coronary angiography (ICA) to rule out the coexistence of significant coronary artery disease Despite the absence of apparent clinical symptoms of angina, prevalence of significant CAD in this population has been reported to be between 8% and 41%. The relevance of this finding lies in the observation that revascularization in these patients in addition to the procedure of noncoronary cardiovascular surgery reduces the occurrence of peri- and postoperative adverse major clinical events.

Multidetector coronary computed tomographic angiography of the coronary arteries is nowadays a reliable technique to rule out significant CAD, with a proved high negative predictive value, particularly in patients with low

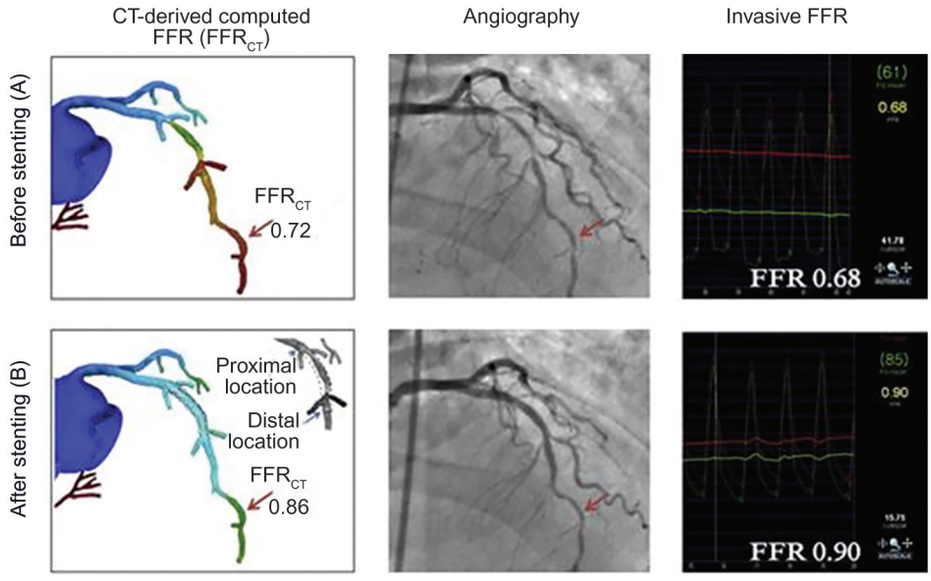

Fig. 4.75: Invasive and noninvasive functional assessment before and after revascularization. (A) Noninvasive fractional flow reserve (FFR) from coronary computed tomographic angiography data (FFRCT) of the left anterior descending (LAD) coronary artery was 0.72. Invasive coronary angiography and FFR confirmed the functionally significant LAD stenosis. (B) FFRCT demonstrated no ischemia in the LAD after virtual stenting, with a computed value of 0.86. Invasive FFR after stent implantation was 0.90



Fig. 4.76: Photograph of a CT scan machine. Noninvasive coronary multidetector CT angiography in patients with noncoronary cardiovascular surgery

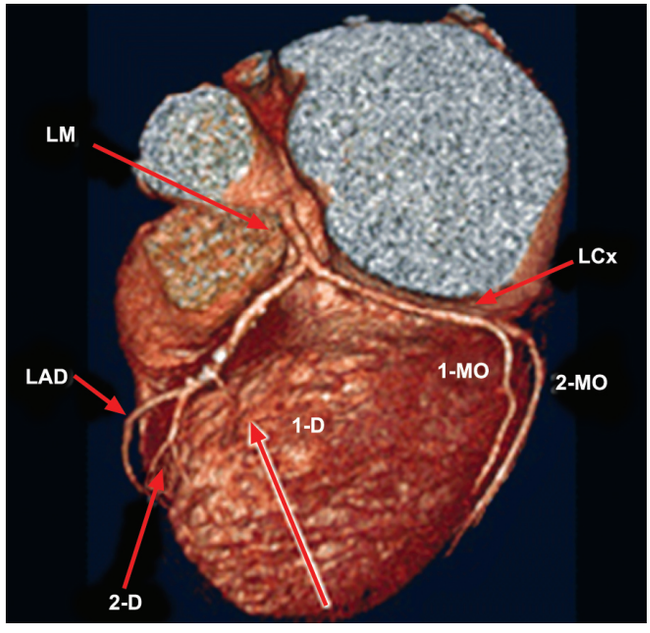

Fig. 4.77: Coronary CT angiographic results in patient with a dilated left atrium and atrial fibrillation with mean heart rate of 73 beats per minute at coronary CT angiographic acquisition. Volume-rendered CT image (left anterior oblique view with cranial angulation) shows the arteries—left main (LM), left anterior descending (LAD), first diagonal (1-D), second diagonal (2-D), left circumflex (LCx), and first and second marginal obtuse branches (1-MO, 2-MO)

or intermediate pretest probability of disease. Thus, the technique has been applied in the preoperative screening of noncoronary cardiovascular surgery, although initial reports are limited to patients with valvular heart disease, in regular sinus rhythm. In the largest study to date, patients with atrial fibrillation also were included. All these studies, however, consist basically of a comparison between ICA and coronary CT angiography, without testing the actual value of coronary CT angiography in terms of avoiding routine ICA in these patients.

The findings of the various studies can be summarized as—first, preoperative routine ICA can be safely avoided in a considerable number of patients scheduled to undergo noncoronary cardiovascular surgery by use of coronary CT

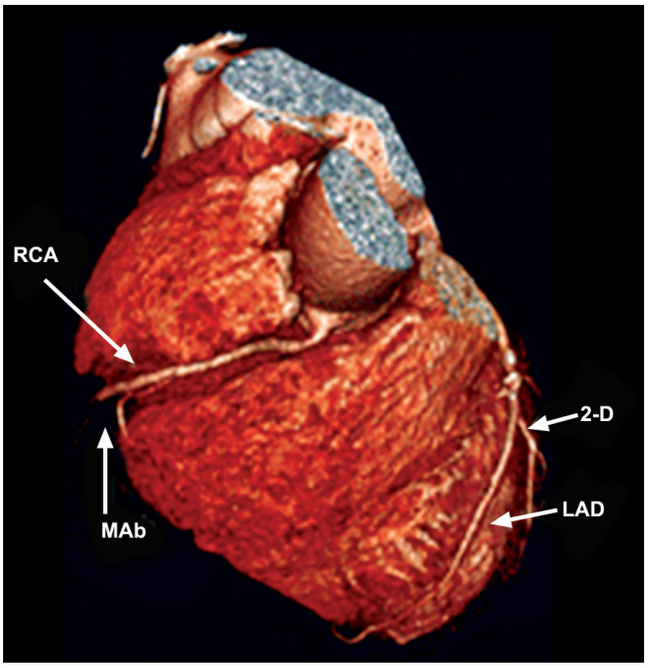

Fig. 4.78: Coronary CT angiographic results in patient with a dilated left atrium and atrial fibrillation with mean heart rate of 73 beats per minute at coronary CT angiographic acquisition. Volume-rendered CT image (right anterior oblique view with cranial angulation) shows the arteries—right coronary artery (RCA), marginal acute branch (MAb), left anterior descending (LAD), and second diagonal (2-D)

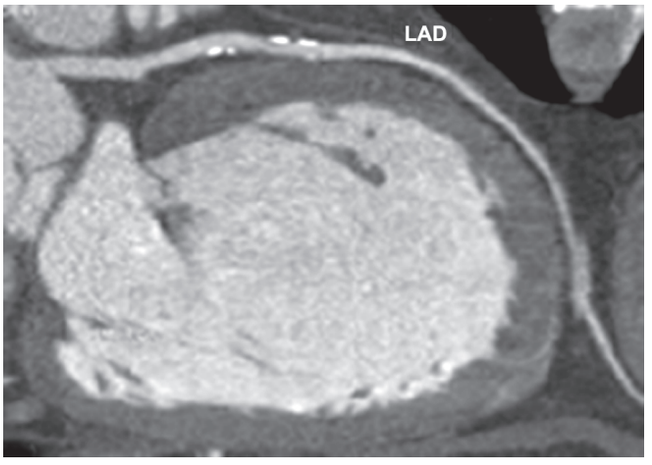

Fig. 4.79: Coronary CT angiographic results in patient with a dilated left atrium and atrial fibrillation with mean heart rate of 73 beats per minute at coronary CT angiographic acquisition. Curved multiplanar reconstruction of left anterior descending coronary

angiography; second, the presence of a controlled atrial fibrillation does not preclude performing diagnostic coronary CT angiographic examination; third, an Agatston score of coronary calcification higher than 579 significantly increases the likelihood of a subsequent nondiagnostic coronary CT angiography.

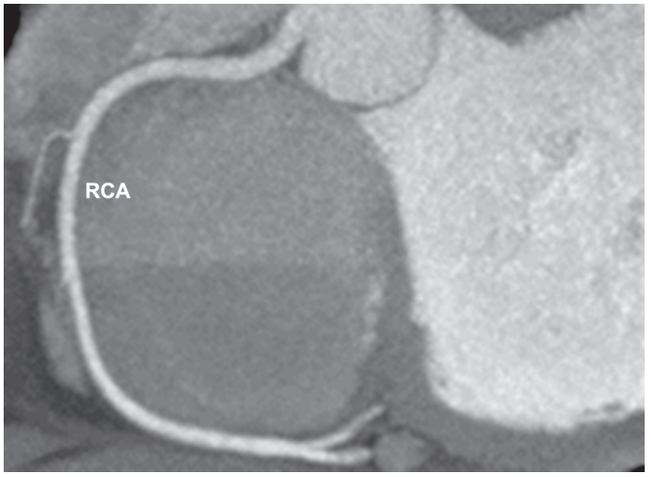

Fig. 4.80: Coronary CT angiographic results in patient with a dilated left atrium and atrial fibrillation with mean heart rate of 73 beats per minute at coronary CT angiographic acquisition. Maximum intensity projection of right coronary artery

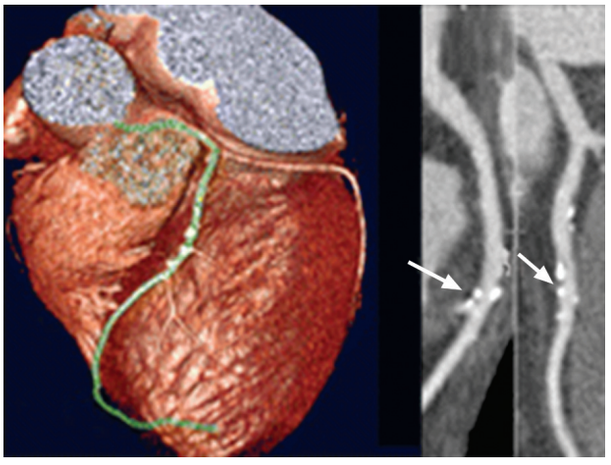

Fig. 4.81: Noninvasive coronary multidetector CT angiographic images of diagnostic categories. Left anterior descending coronary artery with nonsignificant stenosis (arrows)

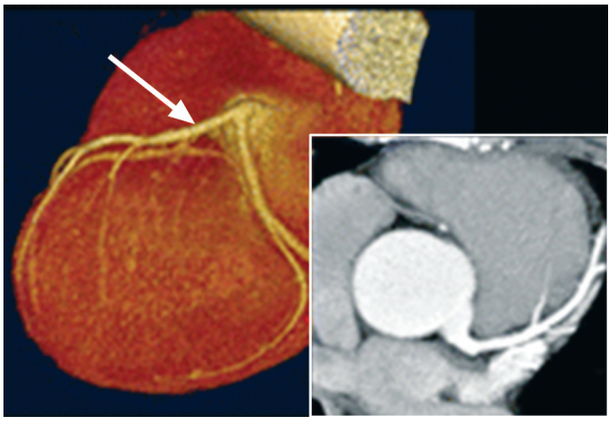

Fig. 4.82: Noninvasive coronary multidetector CT angiographic images of diagnostic categories. Normal left anterior descending coronary artery (arrow)

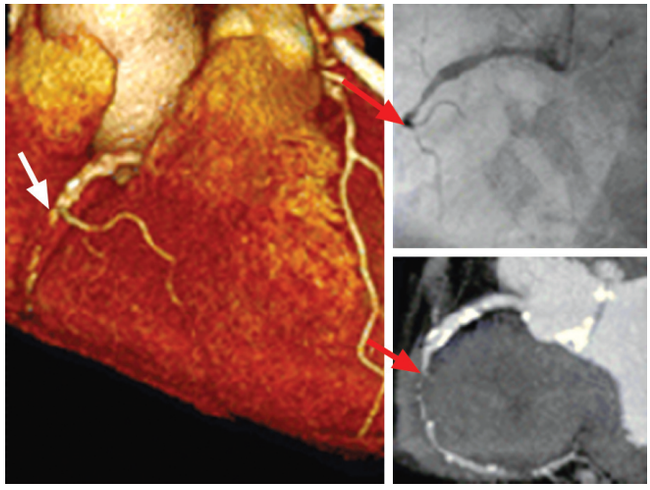

Fig. 4.83: Noninvasive coronary multidetector CT angiographic images of diagnostic categories. Right coronary artery with a significant stenosis; a total occlusion of the midpart of the right coronary artery (arrows). Top right—ICA image

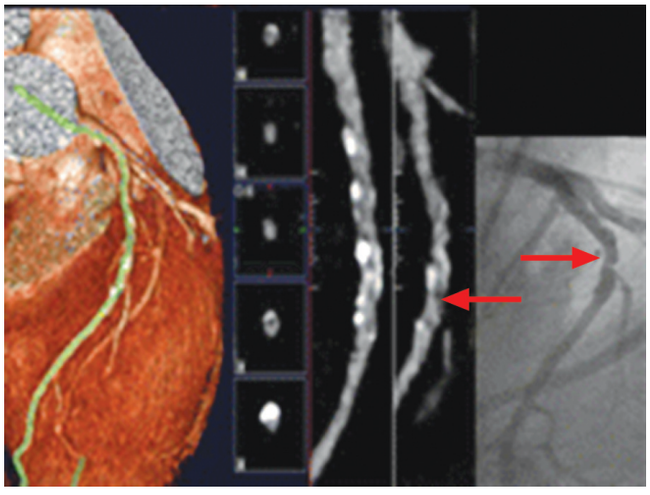

Fig. 4.84: Noninvasive coronary multidetector CT angiographic images of diagnostic categories. Coronary CT angiogram is nondiagnostic because of severe calcification and shows significant stenosis (arrows) on ICA image (far right)

The performance of ICA as a screening preoperative test before major noncoronary cardiovascular surgery in patients at risk for CAD is recommended. The rationale for this approach lies in the proved adverse prognosis after surgery in patients with undetected CAD and in the reduction in terms of mortality observed when coronary revascularization is performed simultaneously with non-coronary cardiovascular surgery Although noninvasive tests for inducible ischemia could represent an alternative to ICA, its usefulness is limited in practice because of a proved suboptimal predictive value of postoperative complications in these patients.

As an invasive procedure, ICA is costly and carries a small but definite risk of complications (1.5%) and even a certain mortality risk (0.15%), and these numbers are higher when the population involved has an increased associated comorbidity, as is the case in those patients scheduled to

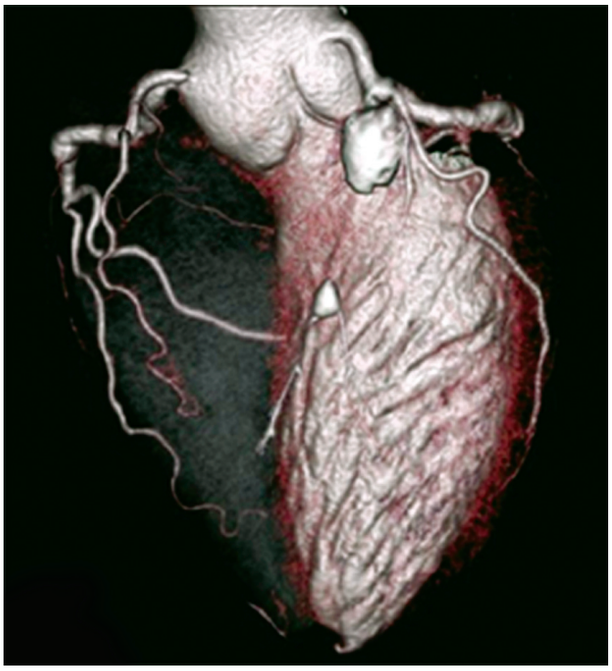

Fig. 4.85: 20-year-adolescent with Kawasaki disease. VR image show partly calcified thrombosed saccular aneurysm in proximal LAD. He has another fusiform aneurysm in the right coronary artery

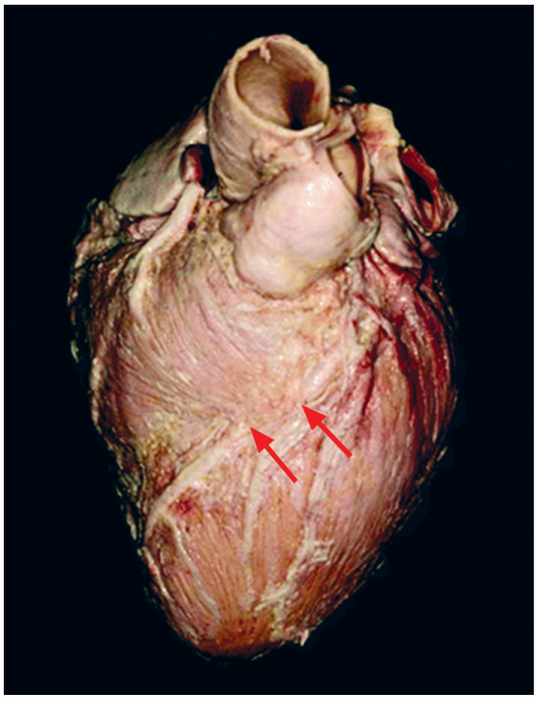

Fig. 4.86: MB in the LAD of an autopsied heart. The epicardial adipose tissues were manually removed after fixation with formaldehyde. The two arrows indicate the entrance and exit of the MB, respectively

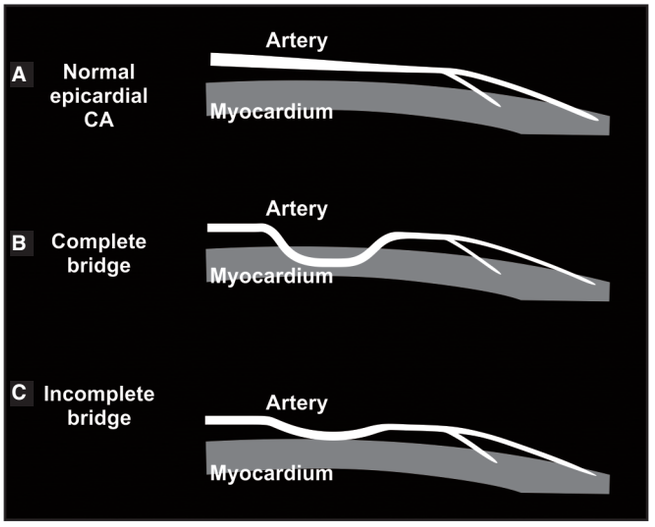

Fig. 4.87: (A) Normal epicardial artery. (B) Complete bridging of the artery. (C) Incomplete bridging of the epicardial artery

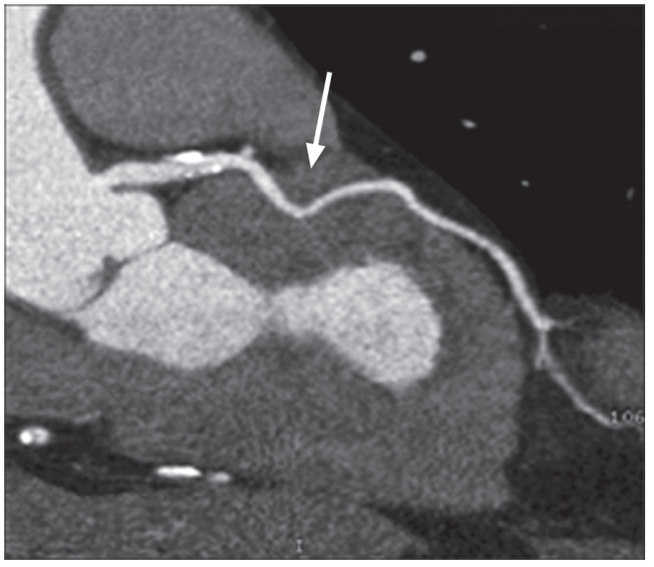

Fig. 4.88: An adolescent with suspected coronary artery disease. Curved MPR shows long segment of myocardial bridging of mid LAD

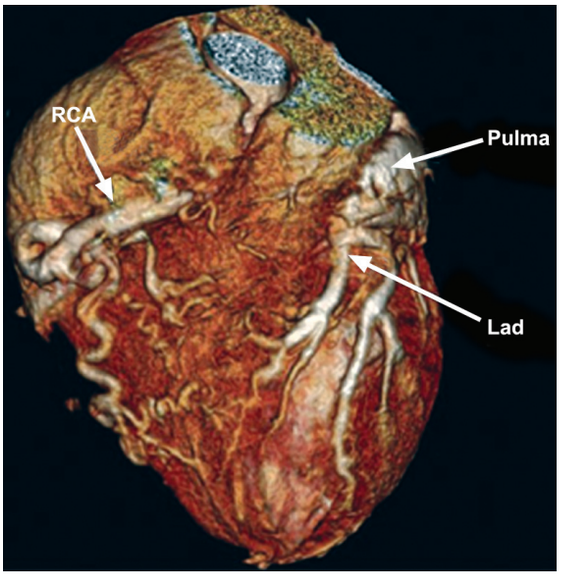

Fig. 4.89: CT angiography volume rendered image. Right coronary artery is dilated and tortious with a large number of collaterals feeding the left coronary system. Left coronary artery is emerging from pulmonary artery trunk. The left anterior descending artery and their diagonal branches are also dilated and tortuous

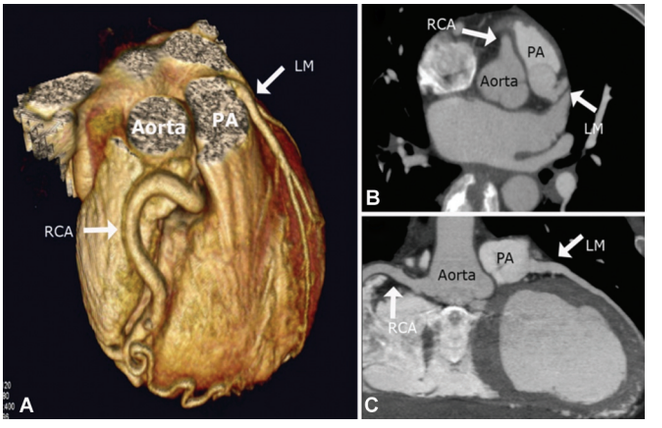

Fig. 4.90: CT-angiography before operation. Coronary CT-angiography showing an anomalous origin of the left main coronary artery (LM) from the pulmonary artery (PA). Normal course of a very large right coronary artery (RCA) is seen. Volume-rendered reformation (A), axial (B), and curved multiplanar reconstruction (C)

undergo noncoronary cardiovascular surgery. Furthermore, most of these patients will have normal results at ICA examination; the prevalence of significant CAD in these patients has been reported to range between 10% and 20%.

Because coronary CT angiography has recently emerged as a valuable noninvasive tool for the diagnosis of CAD in symptomatic patients with low to intermediate pretest risk, it seems appropriate to apply the technique to rule out CAD in patients scheduled to undergo noncoronary cardiovascular surgery. Some previous studies have shown a good correlation between coronary CT angiographic and ICA results in selected groups of patients submitted to undergo noncoronary cardiovascular surgery. Of note, in our study, patients did not undergo preoperative ICA if deemed to be free of significant CAD after diagnostic coronary CT angiographic examination. Most important, none of these patients had peri- or postoperative complications potentially because of CAD, thus proving the safety of this approach. ICA was performed, in addition to coronary CT angiography, in a total of 40 patients. In those with nondiagnostic coronary CT angiographic studies, ICA

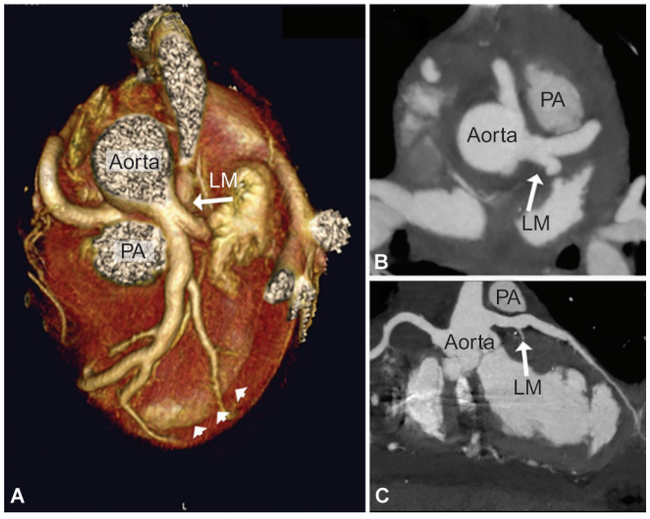

Fig. 4.91: CT-angiography after operation. Coronary CT-angiography after aortic reimplantation of the left coronary artery confirms patency. Note the myocardial wall thinning in the apical anterior part of the left ventricle demonstrating the old infarction (arrowheads). Volume-rendered reformation (A), axial (B) and curved multiplanar reconstruction (C)

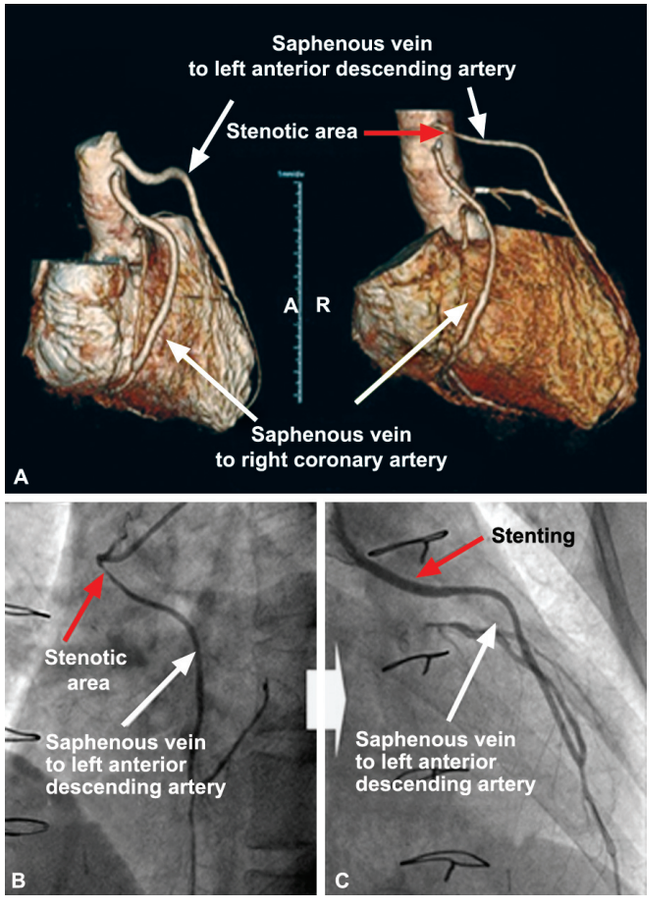

Fig. 4.92: Chronic occlusion of left saphenous vein graft (SVG). (A–left panel) Immediate after CABG surgery, three-dimensional volume-rendered image showed that left saphenous vein graft (SVG) was patent with its anastomosis to the mid-portion of left anterior descending (LAD) artery. There was a patent right saphenous vein graft (SVG), which was attached to the distal-portion of right coronary artery (RCA). (A–right panel) At 8 months after CABG surgery, three-dimensional volume-rendered image showed severe stenosis at proximal-portion of left saphenous vein graft (SVG), which was attached to the midportion of left anterior descending (LAD) artery. Right saphenous vein graft (SVG) was still patent despite the graft had diffuse mild narrowing from proximal anastomosis site to distal anastomosis site, (B) invasive coronary angiography showed the proximal-portion of left saphenous vein graft (SVG) was severely occluded, and (C) percutaneous coronary intervention was performed successfully. Note that the findings of invasive coronary angiography is similar to those of three-dimensional volume-rendered images of 64-MDCT

results showed a relatively low (5 of 25) prevalence of significant CAD. In most of those patients catheterized because of apparently significant CAD at coronary CT angiography (11 of 15), severity of CAD was confirmed. This is in agreement with the reported suboptimal positive predictive value of coronary CT angiography for defining significant coronary artery lesions. In practice, however, this is not a major limitation in the setting of noninvasive preoperative screening for CAD, where it is more relevant to avoid underdiagnosis of CAD rather than overdiagnosis. The consequence will be that a small proportion of patients without significant CAD will still be referred to undergo ICA.

Most important, preoperative coronary CT angiography provides additional information about the thoracic aorta and other mediastinal structures, which is relevant for the cardiac surgeon's choice of cannulation and cross-clamping sites.

The consecutive recruitment of subjects without exclusions due to atrial fibrillation, which was present in nearly half of our population, is also important. Atrial fibrillation has been traditionally considered a relative contraindication to coronary CT angiographic examination. However, when the mean heart rate is appropriately controlled by means of medical therapy, the deleterious effect of an irregular heart rhythm on the quality of the images is notably minimized. The availability of systems for editing ECG synchronization improves the retrospective reconstruction in cases of arrhythmia. This is proved by the results of our study, which showed a similar proportion of nondiagnostic studies in patients with sinus rhythm and in those with controlled atrial fibrillation.

Nondiagnostic coronary CT angiography accounted for 19% of patients studied. The amount of coronary artery calcium, quantified by means of the Agatston score, was the determinant for a diagnostic study, with a cutoff of 579 being the best predictor. In view of these data, it could be questionable to proceed with noninvasive coronary CT angiography after coronary calcium scanning yielded an Agatston score higher than this value. For example, a rise

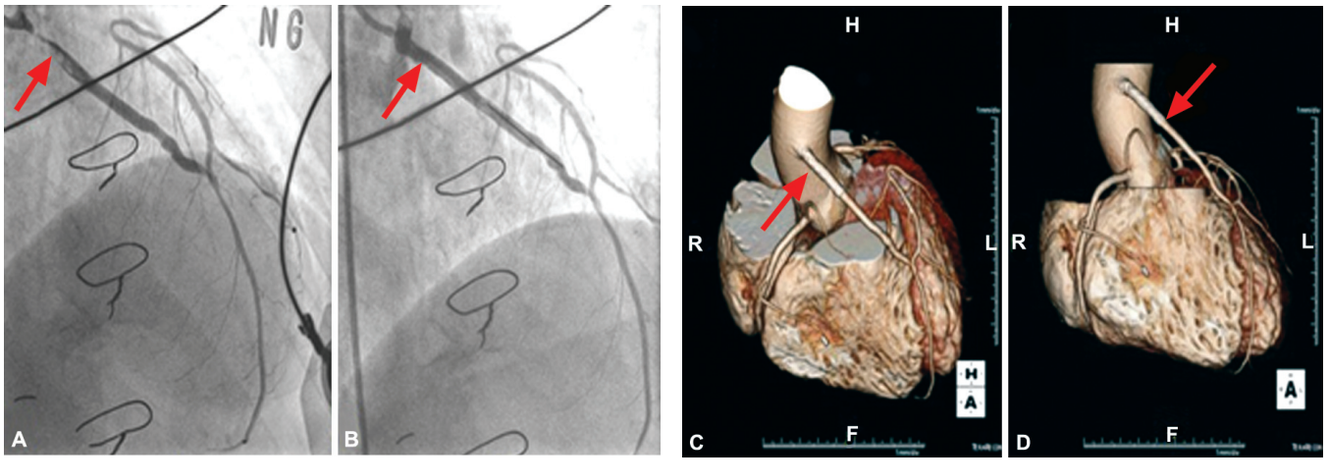

Fig. 4.93: Acute occlusion of saphenous vein graft (SVG). (A) Invasive coronary angiography showed the proximal-portion of saphenous vein graft (SVG) was severely occluded with thrombi. (B) After successful percutaneous coronary intervention (PCI), invasive coronary angiography showed the proximal portion of saphenous vein graft (SVG) with stenting was patent. (C, D) At 6-month follow-up, three-dimensional volume-rendered image showed the proximal portion of saphenous vein graft (SVG) with stenting was still patent. Note that the findings of invasive coronary angiography is similar to those of three-dimensional volume-rendered images of 64-MDCT. The figures also demonstrate that 64-MDCT has a useful role to follow-up of patients who have undergone percutaneous intervention for bypass graft stenosis and occlusion

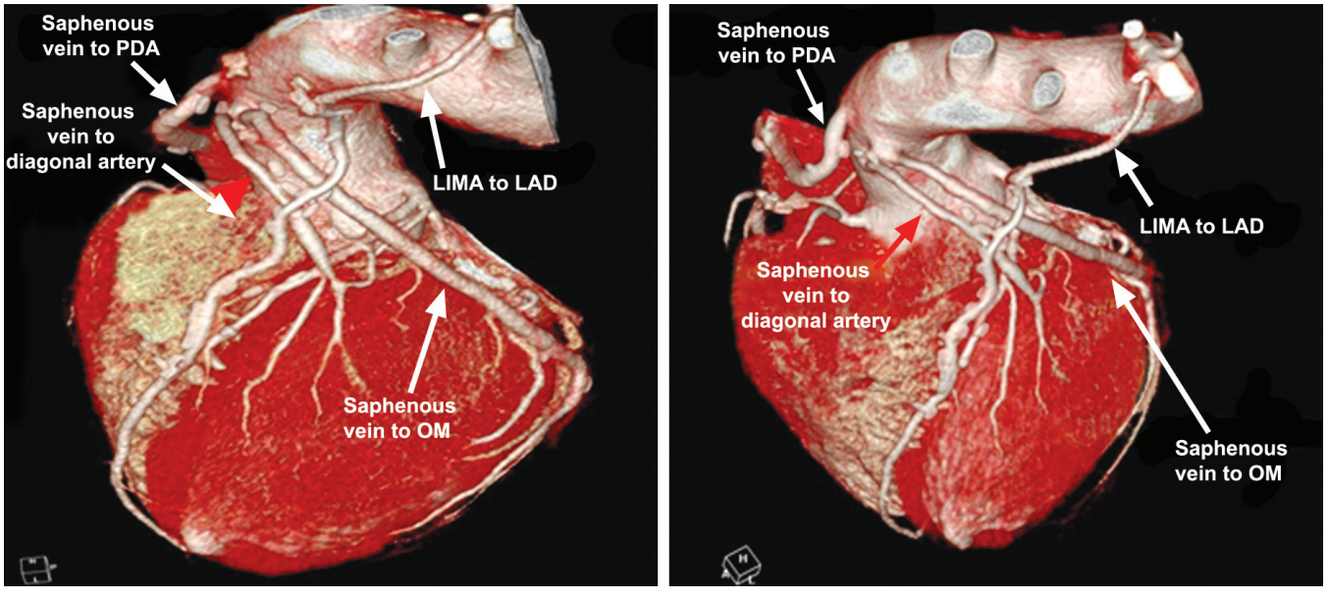

Fig. 4.94: Left internal mammary artery (IMA) graft. Three-dimensional volume-rendered images show the left IMA graft from its origin at the left subclavian artery to its anastomosis with the left anterior descending (LAD) artery. There is also a right saphenous vein graft (SVG) sutured to the anterior aorta with its anastomosis with the posterior descending artery (PDA). The left saphenous vein grafts (SVG) are attached to diagonal artery and the obtuse marginal (OM) artery

in the Agatston score from 579 to 1000 or 1500 increases two- and sixfold, respectively, the risk of nondiagnostic coronary CT angiography. As with any other procedure that involves CT, radiation associated with coronary CT angiography is an issue of concern. In particular, the estimated doses of radiation in our study proved to be significantly higher than those reported for diagnostic ICA. Strategies to limit radiation dose include reduction of tube current or voltage, which is not always feasible in patients with large body mass, and the use of prospective X-ray tube current modulation, which cannot be used in patients with atrial fibrillation, which is a frequent occurrence in this clinical setting. The new generation of CT systems already available, which are based on a single heart beat volume acquisition, will greatly overcome this limitation by means of an important reduction of radiation.

A potential limitation of the study was that its results cannot be extrapolated to other populations of patients usually submitted to preoperative ICA, as those scheduled to undergo major vascular surgery, in whom the presumably higher prevalence of significant CAD would probably lead to a lower number of avoided ICA studies. A further study particularly addressing this issue is warranted.

SUMMARY

In conclusion, in patients scheduled to undergo noncoronary cardiovascular surgery, including those with controlled atrial fibrillation, the presence or absence of CAD can be reliably assessed preoperatively by using coronary CT angiography in a majority of cases. Preoperative ICA was safely avoided in those patients without significant CAD. A proportion of nondiagnostic coronary CT angiographic studies still remained, mainly because of severe coronary calcification, and a high Agatston score was the only predictor of an adequate coronary CT angiographic examination.

Advances in Knowledge

- In patients scheduled to undergo noncoronary cardiovascular surgery, coronary CT angiograms are of diagnostic image quality in 81% of cases.
- The presence of atrial fibrillation is not a limitation for performing diagnostic coronary CT angiography, provided that the ventricular heart rate is adequately controlled to less than 70 beats per minute.
- The presence of severe coronary artery calcification is the only independent predictor of nondiagnostic coronary CT angiography; an Agatston score cutoff of about 600 shows the best predictive accuracy for performing diagnostic coronary CT angiography.
- Preoperative invasive coronary angiography can be safely omitted in patients without significant CAD (defined as >50% stenosis) by using coronary CT angiography.

Implications for Patient Care

- Coronary CT angiography is a useful preoperative test for safely avoiding ICA in most of the patients scheduled to undergo noncoronary cardiovascular surgery.
- Coronary CT angiography provides additional anatomic information on extracoronary structures that may be relevant in relation to the surgical procedure.

BIBLIOGRAPHY

1. American Heart Association. Heart and Stroke Facts: 1996 Statistical Supplement. Dallas, TX: American Heart Association. 1996;22.
2. Bates DW, Bernstein SJ. Coronary Angiography in Acute Myocardial Infarction: A Review of the Literature Regarding Efficacy and Risks. Boston, MA: Harvard Medical School, Department of Health Care Policy; 1995.
3. Bettencourt N, Rocha J, Carvalho M, et al. Multislice computed tomography in the exclusion of coronary artery disease in patients with presurgical valve disease. Circ Cardiovasc Imaging 2009;2(4):306–13.
4. Bettmann MA. Safety and efficacy of iodinated contrast agents. Invest Radiol 1994;29:S33–S36.
5. Blustein J. High-technology cardiac procedures: the impact of service availability on service use in New York State. JAMA 1993;270:344–9.
6. Bonow RO, Carabello BA, Chatterjee K, et al. ACC/AHA 2006 guidelines for the management of patients with valvular heart disease: a report of the ACC/AHA Task Force on Pactice guide-lines (Writing Committee to revise the 1998 Guidelines for the Management of Patients With Valvular Heart Disease) developed in collaboration with the Society of Cardiovascular Anesthesiologists endorsed by the Society for Cardiovascular Angiography and Interventions and the Society of Thoracic Surgeons. J Am Coll Cardiol 2006;48:e1-e148.
7. Budoff MJ, Dowe D, Jollis JG, et al. Diagnostic performance of 64-multidetector row coronary computed tomographic angiography for evaluation of coronary artery stenosis in individuals without known coronary artery disease: results from the prospective multicenter ACCURACY (Assessment by Coronary Computed Tomographic Angiography of Individuals Undergoing Invasive Coronary Angiography) trial. J Am Coll Cardiol 2008;52(21):1724–32.
8. Califf RM, Phillips HR III, Hindman MC, et al. Prognostic value of a coronary artery jeopardy score. J Am Coll Cardiol 1985;5:1055–63.
9. Czer LS, Gray RJ, Stewart ME, De Robertis M, Chaux A, Matloff JM. Reduction in sudden late death by concomitant revascularization with aortic valve replacement. J Thorac Cardiovasc Surg 1988;95(3):390–401.
10. Deray G, Jacobs C. Radiocontrast nephrotoxicity: a review. Invest Radiol 1995;30:221–5.
11. DiSalvo TT, Paul SD, Lloyd-Jones D, et al. Care of acute myocardial infarction by noninvasive and invasive cardiologists: procedure use, cost and outcome. J Am Coll Cardiol 1996;27:262–9.
12. Emond M, Mock MB, Davis KB, et al. Long-term survival of medically treated patients in the Coronary Artery Surgery Study (CASS) Registry. Circulation 1994;90:2645–57.
13. Every NR, Larson EB, Litwin PE, et al. The association between on-site cardiac catheterization facilities and the use of coronary angiography after acute myocardial infarction: Myocardial Infarction Triage and Intervention Project Investigators. N Engl J Med 1993;329:546–51.
14. Gaur S, Achenbach S, Leipsic J, et al. Rationale and design of the Heart Flow NXT (Heart Flow analysis of coronary blood flow using CT angiography: NeXt sTeps) study. J Cardiovasc Comput Tomogr 2013;7:279–88.
15. Gensini GG. Coronary Angiography. Mount Kisco, NY: Futura Publishing; 1996.
16. Graves EJ. National hospital discharge survey: annual summary, 1993. Vital Health Stat 13 1995;1–63.
17. Greenberger PA, Patterson R, Tapio CM. Prophylaxis against repeated radiocontrast media reactions in 857 cases: adverse experience with cimetidine and safety of beta-adrenergic antagonists. Arch Intern Med 1985;145:2197–200.

18. Greenberger PA, Patterson R. Adverse reactions to radiocontrast media. Prog Cardiovasc Dis 1988;31:239–48.
19. Grossman WB, Baim DS. Cardiac Catheterization, Angiography and Intervention. Philadelphia, Pa: Lea & Febiger; 1991.
20. Guadagnoli E, Hauptman PJ, Ayanian JZ, et al. Variation in the use of cardiac procedures after acute myocardial infarction. N Engl J Med 1995;333:573–8.
21. Guidelines for professional staff privileges in the cardiac catheterization laboratory: Laboratory Performance Standards Committee. Cathet Cardiovasc Diagn 1990;21: 203–4.
22. Hanley PC, Vlietstra RE, Fisher LD, Smith HC. Indications for coronary angiography: changes in laboratory practice over a decade. Mayo Clin Proc. 1986;61:248–53.
23. Hirshfeld JW Jr, Ellis SG, Faxon DP. Recommendations for the assessment and maintenance of proficiency in coronary interventional procedures: statement of the American College of Cardiology. J Am Coll Cardiol 1998;31:722–743.
24. Johnson LW, Lozner EC, Johnson S, et al. Coronary arterio-graphy 1984–1987: a report of the Registry of the Society for Cardiac Angiography and Interventions, I: results and complications. Cathet Cardiovasc Diagn 1989;17:5–10.
25. Kimmel SE, Berlin JA, Laskey WK. The relationship between coronary angioplasty procedure volume and major compli-cations. JAMA 1995;274:1137–42.
26. Koo BK, Erglis A, Doh JH, et al. Diagnosis of ischemia-causing coronary stenoses by noninvasive fractional flow reserve computed from coronary computed tomographic angiograms. Results from the prospective multicenter DISCOVER-FLOW (Diagnosis of Ischemia-Causing Stenoses Obtained Via Noninvasive Fractional Flow Reserve) study. J Am Coll Cardiol 2011;58:1989-97.
27. Laskey W, Boyle J, Johnson LW. Multivariable model for prediction of risk of significant complication during diag-nostic cardiac catheterization: the Registry Committee of the Society for Cardiac Angiography and Interventions. Cathet Cardiovasc Diagn 1993;30:185–90.
28. Lasser EC, Berry CC, Talner LB, et al. Pretreatment with corticosteroids to alleviate reactions to intravenous contrast material. N Engl J Med 1987;317:845–9.
29. Leape LL, Park RE, Solomon DH, et al. Does inappropriate use explain small-area variations in the use of health care services? JAMA 1990;263: 669–72.
30. Marcus ML, Schelbert HR, Skorton DJ, et al. Cardiac Imaging: A Companion to Braunwald's Heart Disease. Philadelphia, Pa: WB Saunders; 1991.
31. Mark DB, Naylor CD, Hlatky MA, et al. Use of medical resources and quality of life after acute myocardial infarction in Canada and the United States. N Engl J Med 1994;331: 1130–35.
32. Matthai WH Jr, Kussmaul WG III, Krol J, Goin JE, Schwartz JS, Hirshfeld JW Jr. A comparison of low-with high-osmolality contrast agents in cardiac angiography: identification of criteria for selective use. Circulation 1994;89:291–301.
33. Medicare claims data. Provided by the Physician Payment Review Commission. 1996.
34. Meijboom WB, Mollet NR, Van Mieghem CA, et al. Preoperative computed tomography coronary angiography to detect significant coronary artery disease in patients referred for cardiac valve surgery. J Am Coll Cardiol 2006;48(8): 1658–65.
35. Meijboom WB, van Mieghem CA, Mollet NR, et al. 64-slice computed tomography coronary angiography in patients with high, intermediate, or low pretest probability of significant coronary artery disease. J Am Coll Cardiol 2007;50(15): 1469–75.
36. Mikkonen R, Kontkanen T, Kivisaari L. Acute and late adverse reactions to low-osmolal contrast media. Acta Radiol 1995;36:72–6.
37. Min JK, Leipsic J, Pencina MJ, et al. Diagnostic accuracy of fractional flow reserve from anatomic CT angiography. JAMA 2012;308:1237–45.
38. Myers GE, Bloom FL. Cimetidine (Tagamet) combined with steroids and H1 antihistamines for the prevention of serious radiographic contrast material reactions. Cathet Cardiovasc Diagn 1981;7:65–9.
39. National Heart, Lung, and Blood Institute Coronary Artery Surgery Study. A multicenter comparison of the effects of randomized medical and surgical treatment of mildly sympto-matic patients with coronary artery disease and a registry of consecutive patients undergoing coronary angiography. Circulation 1981;63:I-1–I-81 Monograph 79.
40. Norgaard BL, Leipsic J, Sengupta S, et al. Quantitative assess-ment of image quality for determination of FFR by coronary computed tomography angiography (abstr). J Cardiovasc Comput Tomogr 2013;3(Suppl):233.
41. Noto TJ Jr, Johnson LW, Krone R, et al. Cardiac catheterization 1990: a report of the Registry of the Society for Cardiac Angiography and Interventions (SCA&I). Cathet Cardiovasc Diagn 1991;24:75–83.
42. Parfrey PS, Griffiths SM, Barrett BJ, et al. Contrast material-induced renal failure in patients with diabetes mellitus, renal insufficiency, or both: a prospective controlled study. N Engl J Med 1989;320:143–9.
43. Pashos CL, Newhouse JP, McNeil BJ. Temporal changes in the care and outcomes of elderly patients with acute myocardial infarction, 1987 through 1990. JAMA 1993;270: 1832–6.
44. Pepine CJ, Allen HD, Bashore TM, et al. ACC/AHA guidelines for cardiac catheterization and cardiac catheterization laboratories: American College of Cardiology/American Heart Association Ad Hoc Task Force on Cardiac Catheterization. J Am Coll Cardiol 1991;18:1149–82.
45. Pilote L, Califf RM, Sapp S, et al. Regional variation across the United States in the management of acute myocardial infarction: GUSTO-1 Investigators. Global Utilization of Streptokinase and Tissue Plasminogen Activator for Occluded Coronary Arteries. N Engl J Med 1995;333:565–72.
46. Potter DD, Sundt TM 3rd., Zehr KJ, et al. Operative risk of reoperative aortic valve replacement. J Thorac Cardiovasc Surg 2005;129(1):94–103.
47. Ringqvist I, Fisher LD, Mock M, et al. Prognostic value of angiographic indices of coronary artery disease from the Coronary Artery Surgery Study (CASS). J Clin Invest 1983;71:1854–66.
48. Ritchie JL, Phillips KA, Luft HS. Coronary angioplasty: statewide experience in California. Circulation 1993;88:2735–43.
49. Ross J Jr, Brandenburg RO, Dinsmore RE, et al. ACC/AHA Guidelines for coronary angiography. A report of the

American College of Cardiology/American Heart Association Task Force on Assessment of Diagnostic and Therapeutic Cardiovascular Procedures (Subcommittee on Coronary Angiography). J Am Coll Cardiol 1987;10:935–9502.
50. Rouleau JL, Moye LA, Pfeffer MA, et al. A comparison of management patterns after acute myocardial infarction in Canada and the United States: the SAVE investigators. N Engl J Med 1993;328:779–84.
51. Rudnick MR, Goldfarb S, Wexler L, et al. Nephrotoxicity of ionic and nonionic contrast media in 1,196 patients: a randomized trial. The Iohexol Cooperative Study. Kidney Int 1995;47:254–61.
52. Russo V, Gostoli V, Lovato L, et al. Clinical value of multidetector CT coronary angiography as a preoperative screening test before non-coronary cardiac surgery. Heart 2007; 93(12):1591–8.
53. Salas-Lara VM, Rangel-Abundis A, Solorio-Meza S, Albarrán-López H. Assessment of a predictive index for coronary artery disease in patients with rheumatic valvular disease. Cir Cir 2005;73(2):85–9.
54. Schwab SJ, Hlatky MA, Pieper KS, et al. Contrast nephro-toxicity: a randomized controlled trial of a nonionic and an ionic radiographic contrast agent. N Engl J Med 1989;320:149–53.
55. Selby JV, Fireman BH, Lundstrom RJ, et al. Variation among hospitals in coronary-angiography practices and outcomes after myocardial infarction in a large health maintenance organization. N Engl J Med 1996;335:1888–96.
56. Selker HP, Zalenski RJ, Antman EM, et al. An evaluation of technologies for identifying acute cardiac ischemia in the emergency department: executive summary of a National Heart Attack Alert Program Working Group Report. Ann Emerg Med 1997;29:1–12.
57. Solomon R, Werner C, Mann D, et al. Effects of saline, mannitol, and furosemide to prevent acute decreases in renal function induced by radiocontrast agents. N Engl J Med 1994;331:1416–20.
58. Spertus JA, Weiss NS, Every NR, Weaver WD. The influence of clinical risk factors on the use of angiography and revascularization after acute myocardial infarction: Myocardial Infarction Triage and Intervention Project Investigators. Arch Intern Med 1995;155:2309–16.
59. Taliercio CP, Vlietstra RE, Fisher LD, et al. Risks for renal dysfunction with cardiac angiography. Ann Intern Med 1986;104:501–4.
60. Tommaso CL. Contrast-induced nephrotoxicity in patients undergoing cardiac catheterization. Cathet Cardiovasc Diagn 1994;31:316–321.
61. Tu JV, Pashos CL, Naylor CD, et al. Use of cardiac procedures and outcomes in elderly patients with myocardial infarction in the United States and Canada. N Engl J Med 1997;336: 1500–05.
62. Vahanian A, Baumgartner H, Bax J, et al. Guidelines on the management of valvular heart disease: The Task Force on the Management of Valvular Heart Disease of the European Society of Cardiology. Eur Heart J 2007;28(2):230–68.
63. Wittbrodt ET, Spinler SA. Prevention of anaphylactoid reactions in high-risk patients receiving radiographic contrast media. Ann Pharmacother 1994;28:236–41.

5 Right Ventricular Infarction

Right ventricular infarction was first recognized in a subgroup of patients with inferior wall myocardial infarctions who demonstrated right ventricular failure and elevated right ventricular filling pressures despite relatively normal left ventricular filling pressures. Increasing recognition of right ventricular infarction, either in association with left ventricular infarction or as an isolated event, emphasizes the clinical significance of the right ventricle to total cardiac function.

Interest in recognizing right ventricular infarction noninvasively has grown because of the therapeutic implications of distinguishing patients with right ventricular dysfunction from those with the more usual clinical presentation of left ventricular dysfunction. Patients with right ventricular infarctions associated with inferior infarctions have much higher rates of significant hypotension, bradycardia requiring pacing support, and in-hospital mortality than isolated inferior infarctions.

PATHOPHYSIOLOGY (Figs 5.1 and 5.2)

The right ventricle is a thin-walled chamber that functions at low oxygen demands and pressure. It is perfused throughout the cardiac cycle in both systole and diastole, and its ability to extract oxygen is increased during hemodynamic stress. All of these factors make the right ventricle less susceptible to infarction than the left ventricle.

The posterior descending branch of the right coronary artery usually supplies the inferior and posterior walls of the right ventricle. The marginal branches of the right coronary artery supply the lateral wall of the right ventricle. The anterior wall of the right ventricle has a dual blood supply—the conus branch of the right coronary artery and the moderator branch artery, which courses from the left anterior descending artery.

Interestingly, right ventricular infarction noted at necropsy usually involves the posterior septum and posterior wall rather than the right free wall. The relative sparing of the right ventricular anterior wall apparently arises from a high degree of collateralization. This collateral blood flow is thought to be derived from the thebesian veins and diffusion of oxygen directly from the ventricular cavity. A direct correlation exists between the anatomic site of right coronary artery occlusion and the extent of right ventricular

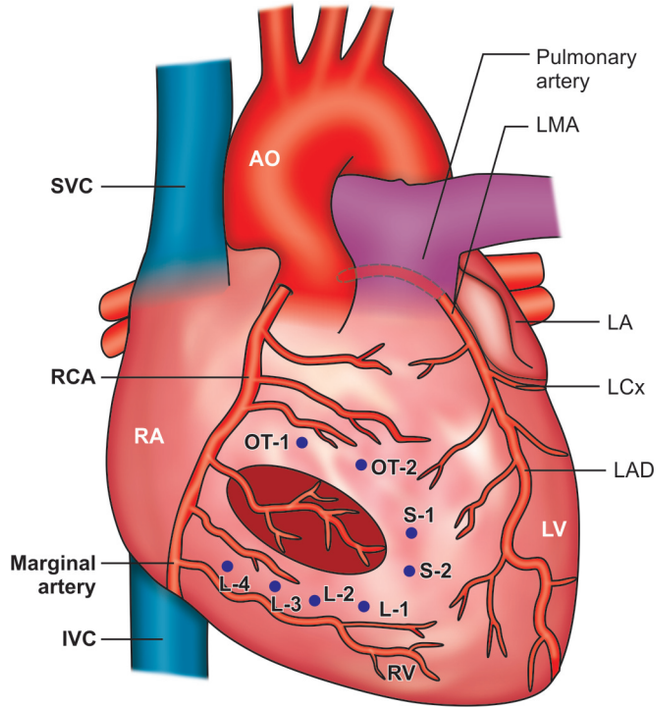

Fig. 5.1: Diagram showing heart viewed from the right anterolateral aspect. Sites of electrode placement; shaded area, region of infarction. Ao=aorta; SVC=superior vena cava; IVC=inferior vena cava; RA=right atrium; OT=outflow tract; S=septal; L=lateral; LMA=left main coronary artery; LCx=left circumflex coronary artery; and LA=left atrium

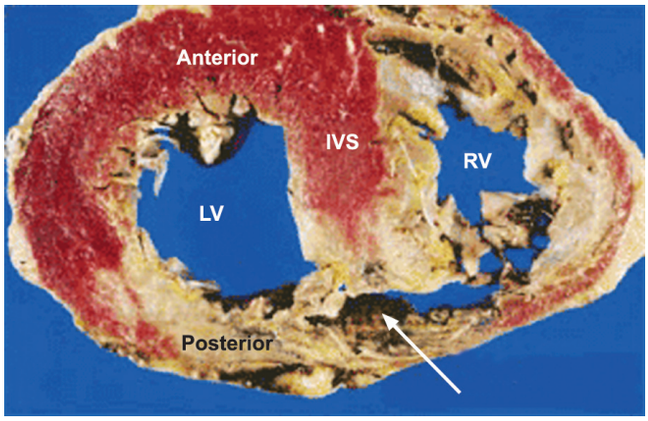

Fig. 5.2: Gross findings in a patient with a posterior ventricular septal rupture. There is an infarction involving the basal inferior septum, the basal posteroinferior wall, and the right ventricle (RV). The ventricular septal rupture (arrow) is complex, with an irregular, serpiginous tract at the junction of the inferior wall and the interventricular septum (IVS). LV denotes left ventricle

infarction. Studies have demonstrated that more proximal right coronary artery occlusions result in larger right ventricular infarctions. On occasion, the right ventricle can be subjected to infarction from occlusion of the left circumflex coronary artery.

Because the right ventricle is considered a low-pressure volume pump, its contractility is highly dependent on diastolic pressure. Hence, when contractility and associated diastolic dysfunction are impaired attendant to right ventricular infarction, the right ventricular diastolic pressure increases substantially and systolic pressure decreases. In such a scenario, concomitant left ventricular dysfunction, with increase in right ventricular afterload, is possible. In such a setting, right ventricular output can decrease dramatically, and the only driving force remaining is elevated right atrial pressure. In such a circumstance, the right ventricle serves as a poorly functioning conduit between the right atrium and the pulmonary artery.

Elevation of right atrial pressure secondary to right ventricular infarction has been noted to serve as a stimulus for secretion of atrial natriuretic factor. Increased levels of this polypeptide can be detrimental to normal left ventricular filling pressures. This occurs by virtue of the potent vasodilating, natriuretic, diuretic, and aldosterone-inhibiting properties of atrial natriuretic factor. Inappropriately elevated levels of atrial natriuretic factor may worsen the clinical syndrome of right ventricular infarction. The potential hemodynamic derangements associated with right ventricular infarction render the afflicted patient unusually sensitive to diminished preload (i.e. volume) and loss of atrioventricular synchrony. These two circumstances can result in a severe decrease in right and, secondarily, left, ventricular output.

Early thrombolysis or mechanical reperfusion of an occluded coronary artery resulting in right ventricular infarction is associated with prompt reduction in right atrial pressure. This is extremely important because persistently elevated right atrial pressure has been associated with increased in-hospital mortality rate when associated with myocardial infarction. The extent of right ventricular infarction varies greatly and is dependent on the site of occlusion of the right ventricular arterial supply. If occlusion occurs before the right ventricular marginal branches, and collateral blood flow from the left anterior descending coronary artery is absent, then the size of infarction generally is greater. Extent of infarction depends somewhat on flow through the thebesian veins.In general, any major reduction in blood supply to the right ventricular free wall portends an adverse prognosis in association with this disorder.

FREQUENCY

Isolated infarction of the right ventricle is extremely rare; right ventricular infarction usually is noted in association with inferior wall myocardial infarction. The incidence of right ventricular infarction in such cases ranges from 10% to 50%, depending on the series.

The frequency of right ventricular infarction, which can be detected by right-sided precordial leads, in association with non-ST-segment elevation or non-Q-wave myocardial infarction is not known and currently is being investigated. Although right ventricular infarction is clinically evident in a sizable number of cases, the incidence is considerably less than that found at autopsy. A major reason for the discrepancy is the difficulty in establishing the presence of right ventricular infarction in living subjects. Additionally, right ventricular dysfunction and stunning frequently is of a transient nature, such that estimation of its true incidence is even more difficult.

Criteria have been set forth to diagnose right ventricular infarction; even when strictly employed, however, the criteria lead to underestimation of the true incidence of right ventricular infarction.

HISTORY

- Although right ventricular infarction occurs in more than 30% of patients with inferior posterior left ventricular myocardial infarction, hemodynamically significant right ventricular infarction occurs in less than 10% of these patients.
- A right ventricular infarct should be considered in all patients who present with an acute inferior wall myocardial infarction, especially in the setting of a low cardiac output.
- Patients may describe symptoms consistent with hypotension.
- A subtle clue to the presence of hemodynamically significant right ventricular infarction is a marked sensitivity to preload-reducing agents such as nitrates, morphine, or diuretics.
- Other presentations include high-grade atrioventricular block, tricuspid regurgitation, cardiogenic shock, right ventricular free wall rupture, and cardiac tamponade.
- Should a patient with right ventricular infarction experience unexplained hypoxia despite administration of 100% oxygen, right-to-left shunting at the atrial

level in the presence of right ventricular failure and increased right atrial pressure must be considered. Despite its rarity, this complication of right ventricular infarction must always be considered when a patient with myocardial infarction is thought to have hypoxia secondary to clinically silent pulmonary emboli. The mechanism for right-to-left shunting in the absence of increased pulmonary arterial pressure resides in patency of the foramen ovale in association with poor right ventricular compliance and increased right atrial filling pressures.

- Patients with extensive right ventricular necrosis are at risk for right ventricular catheter-related perforation, and passage of a floating balloon catheter or pacemaker must always be performed with great care in such a setting.

PHYSICAL EXAMINATION

The clinical triad of hypotension, clear lung fields, and elevated jugular venous pressure has been traditionally considered as a maker of RV infarction in patients with inferior wall myocardial infarction (IWMI). However, this triad has high specificity (96%) but very low sensitivity (25%). Kussmaul's venous sign (distension of the jugular vein on inspiration), a feature of constrictive pericarditis, may also occur with RV infarction. Electrocardiography and other noninvasive imaging modalities continue to be the cornerstones of the diagnosis of RV infarction because of the high specificity but low sensitivity associated with physical examination.

IMAGING STUDIES

Electrocardiography

In clinical practice, RV infarction is frequently diagnosed electrocardiographically. An ST-segment elevation of >1 mm in lead V4R is considered significant and correlates closely with other noninvasive evidences of RV dysfunction. This electrocardiographic finding is also a strong independent predictor of major complications and in-hospital mortality. This ST-segment elevation is thought to represent an ischemic injury of the posterobasal septum, since this area of contiguous myocardium is invariably damaged in patients who have pathological evidence of IWMI involving the RV (Figs 5.3–5.11).

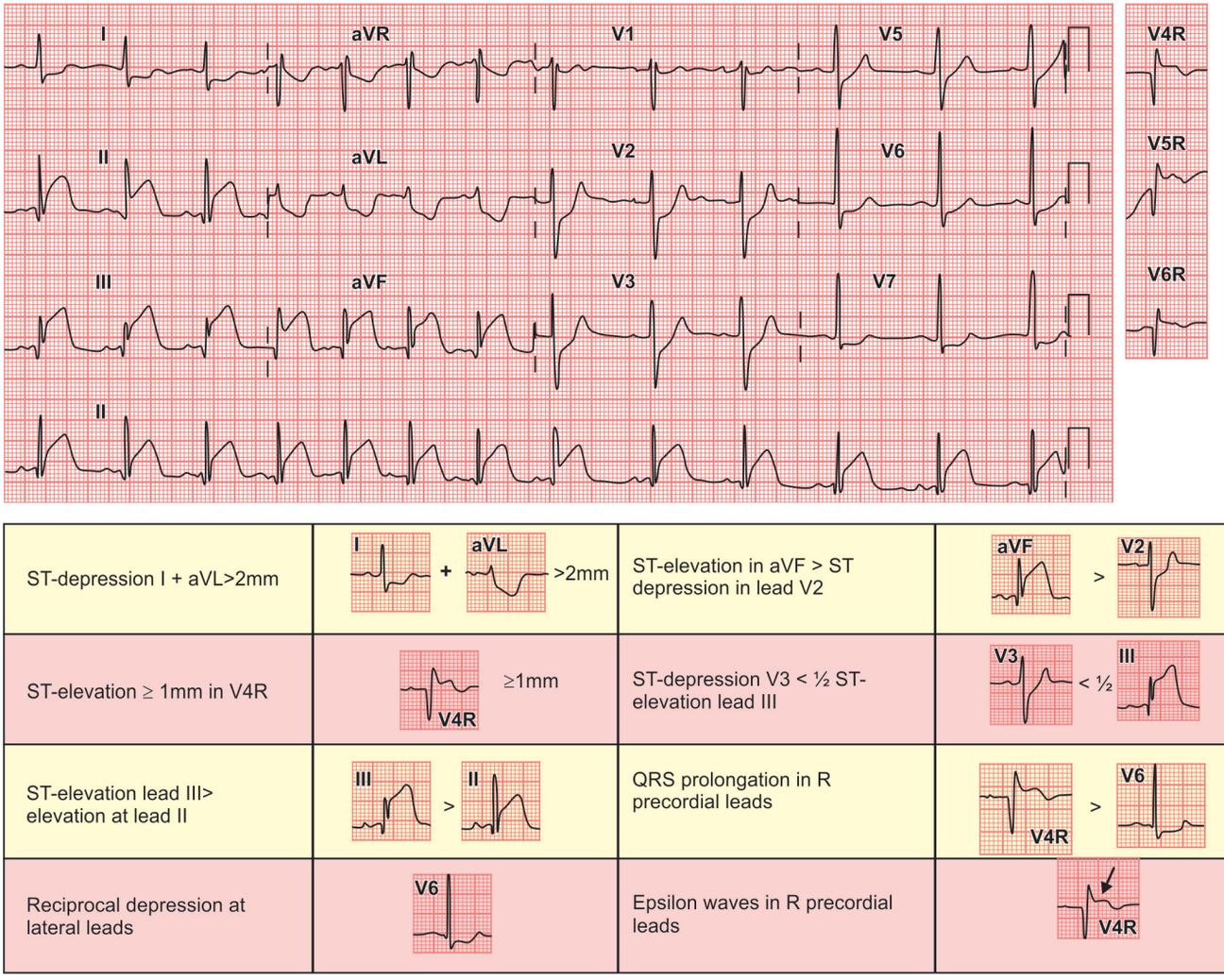

Fig. 5.3: Illustration showing various ECG criteria in the diagnosis of right ventricular myocardial infarction

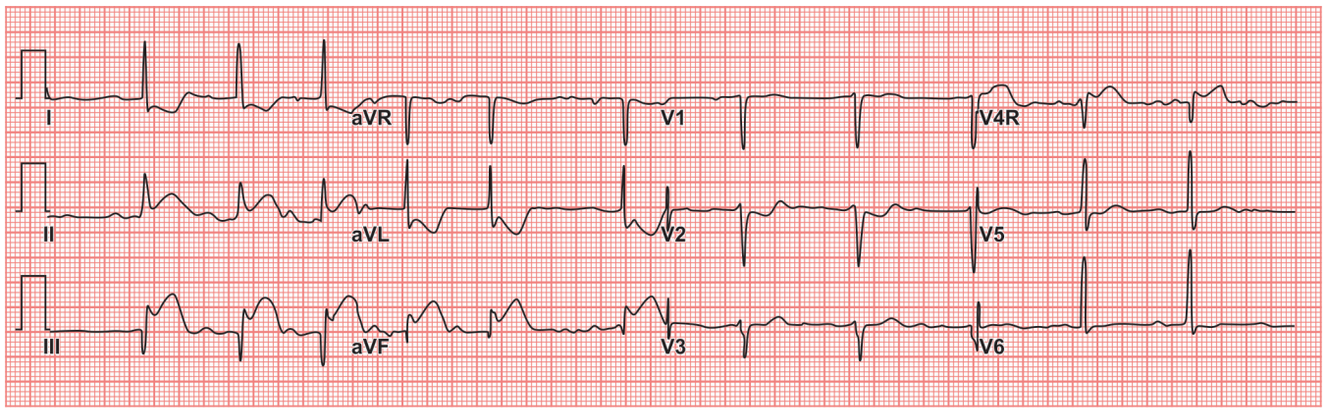

Fig. 5.4: ECG showing right ventricular MI—there is an inferior STEMI with ST-elevation in lead III >lead II. There is subtle ST-elevation in V1 with ST-depression in V2. There is ST-elevation in V4R

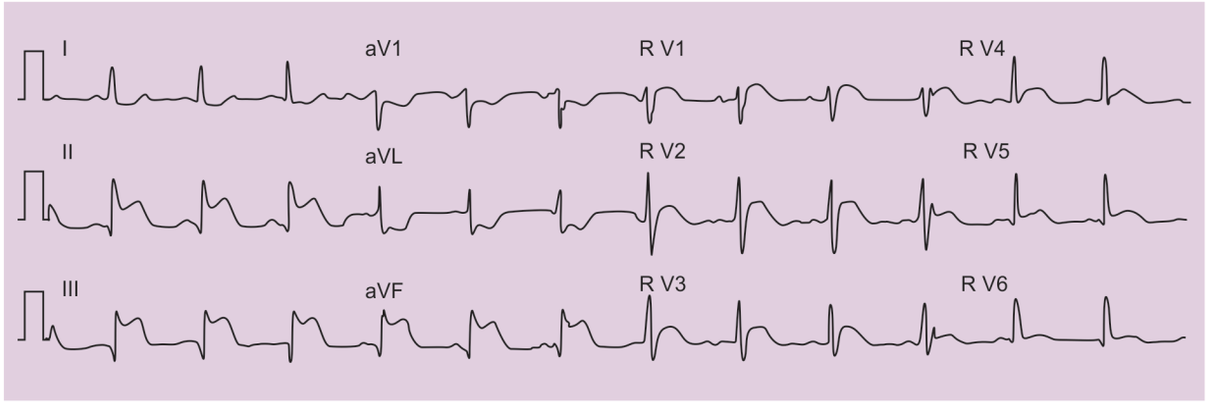

Fig. 5.5: ECG suggestive of RV infarction-ST-segment elevation (0.1 mV) in lead II, III and aVF (inferior leads)-coexistent ST-segment elevation in lead VR1–VR6 suggests right ventricular involvement pathological Q-waves formation in inferior leads—reciprocal ST-segment depression in lead I and aVL

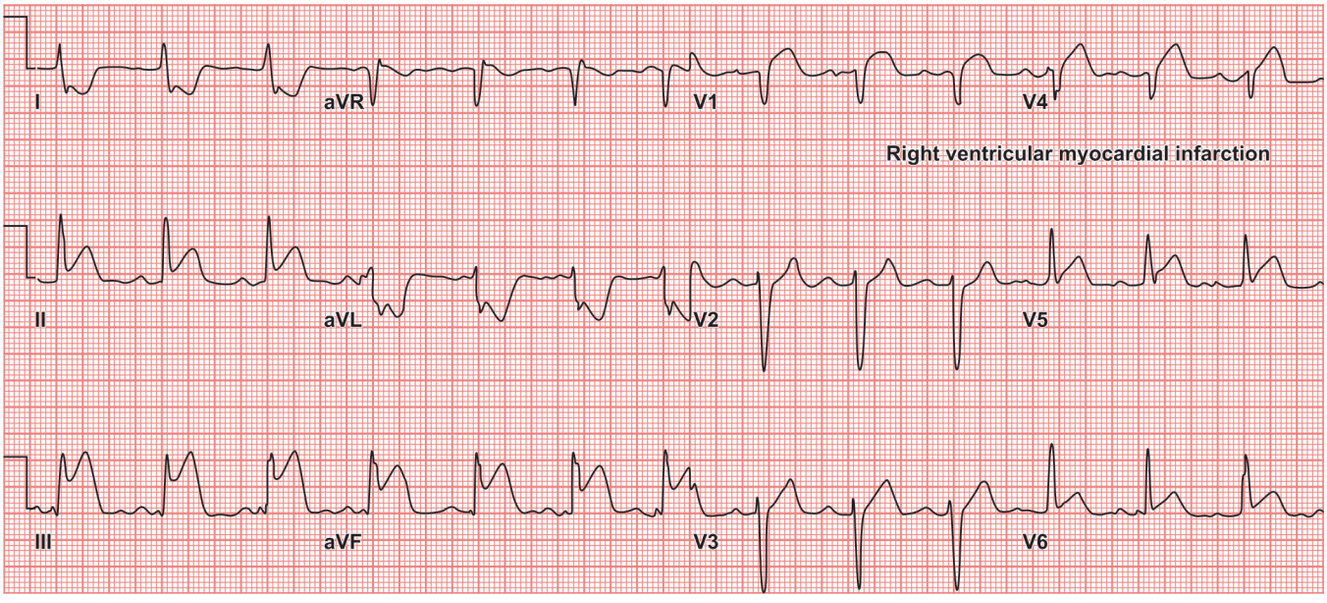

Fig. 5.6: ECG showing right ventricular myocardial infarction. ST-elevation in lead V1 and high R/S ratio in V1

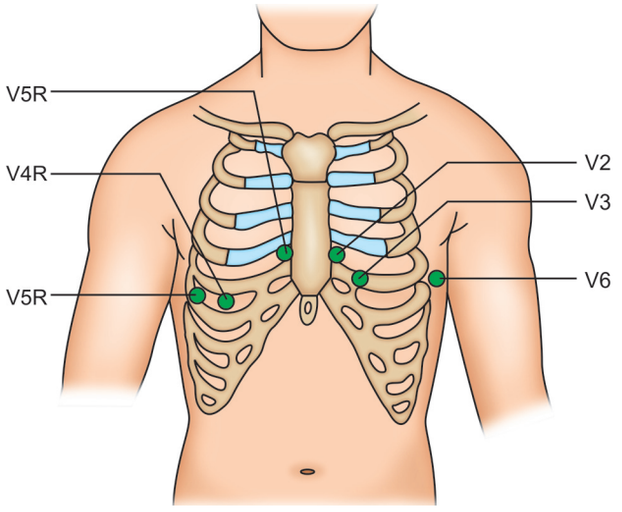

Fig. 5.7: Right-sided ECG leads placement on chest for diagnosis of RV infarct

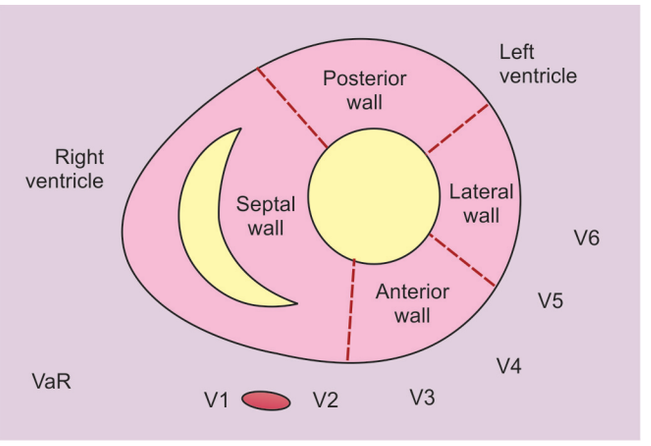

Fig. 5.9: Different regions of right and left ventricles and lead placement over the chest for diagnosis of myocardial injury



Fig. 5.8: ECG 80 leads placement on patient with chest pain of recent onset

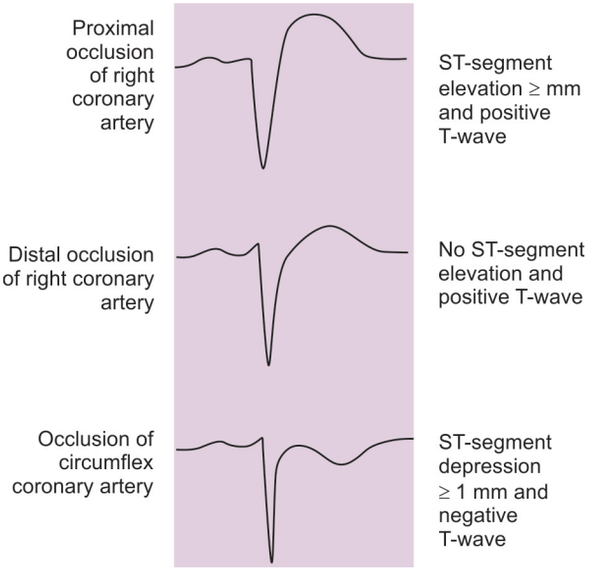

Fig. 5.10: ECG morphologies of segmental occlusion of right coronary and circumflex arteries

Notably, most of the so-called RV 'infarctions', indicated by right-sided ST-segment changes or pathological Q-waves, do not progress to an actual infarction (e.g. myocardial necrosis and scar formation); these electrocardiographic findings usually represent an early, transient phenomenon. This has been demonstrated recently in a study with sequential cardiac magnetic resonance (CMR) imaging. Several unique anatomic and physiological characteristics of the right ventricle contribute to recovery from RV infarction. First, pulmonary circulation is approximately one-tenth the length of systemic circulation, and a 5 mmHg perfusion gradient is sufficient to propel blood across the pulmonary circuit. Second, unlike diastolic flow in the left ventricle (LV), the thin RV free wall allows the biphasic perfusion of coronary blood, with approximately equal contributions during systole and diastole. Third, the right ventricle has rich collaterals from the left anterior descending artery in addition to right coronary artery (RCA) blood flow. Thus, RV infarcts may be clinically suspected in many patients with a stunned or hibernating RV free wall.

Chest X-ray

Chest X-ray is shown in Fig. 5.12.

Echocardiography

Since the late 1980s, considerable progress has been achieved in echocardiography and radionuclide techniques; these modalities revealed that RV involvement may be present in as much as 59% of the patients with IWMI at the initial presentation (Figs 5.13–5.15). In particular, echocardiography is a widely available and inexpensive

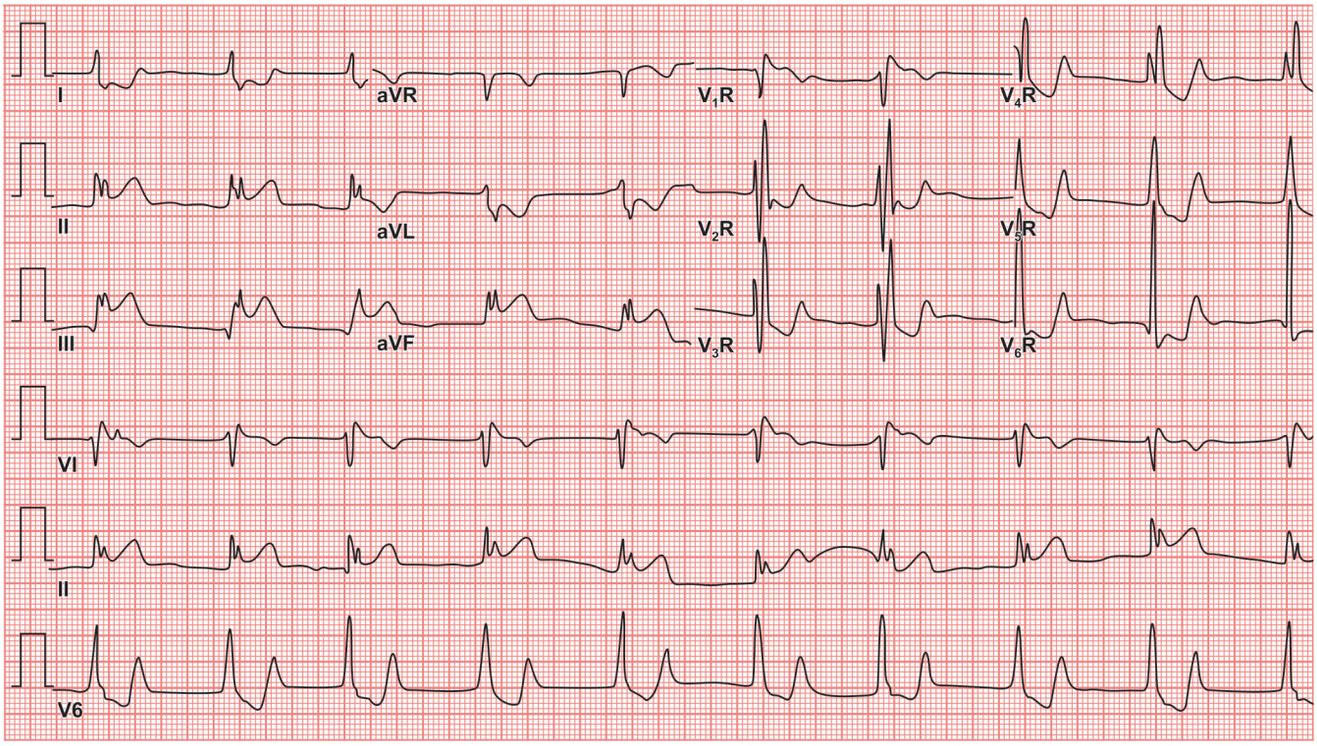

Fig. 5.11: ECG shows an inferior wall infarct, i.e. ST-segment elevation in leads II, III and aVF. The precordial V leads are actually right sided on this ECG. This is evident because the tracing in V6 does not resemble lead I and aVL. Also the P-waves in V4 to V6 are flat. ST-depression in I and aVL along with ST-elevation in right sided V3–V6 indicates right ventricular infarct



Fig. 5.12: Skiagram of chest PA view showing cardiomegaly with pulmonary edema in RV infarction

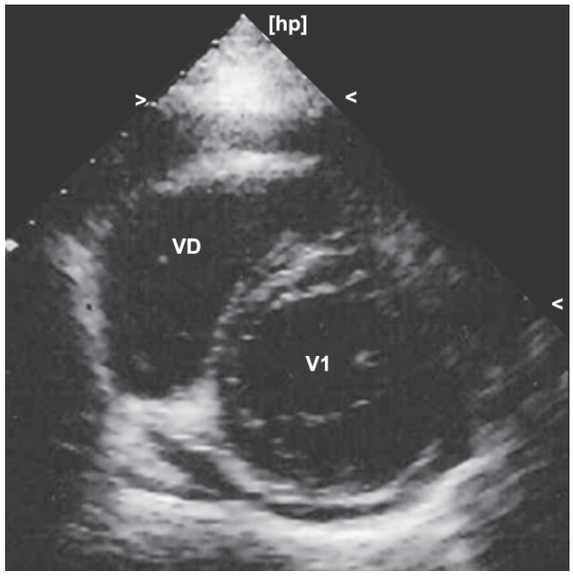

Fig. 5.13: Parasternal echocardiogram in the short axis. The right ventricle appears dilated, with a crescent-moon morphology. Real-time images revealed reduced motion and/or a lack of systolic thickening in the compromised walls in a patient with RV infarction

tool for the comprehensive evaluation of the size and function of the right ventricle. However, echocardiographic imaging of the RV has technical challenges due to the chamber's complex shape; the RV cannot be completely visualized in any single two-dimensional (2D) echocardiographic view. Furthermore, although RV infarction inherently complicates the initial management in cases of acute infarction, echocardiographic abnormalities can be temporary and resolve within a few hours. Therefore, information from all available acoustic windows is necessary for the complete assessment of the RV. Although not validated in acute situations, three-dimensional (3D)

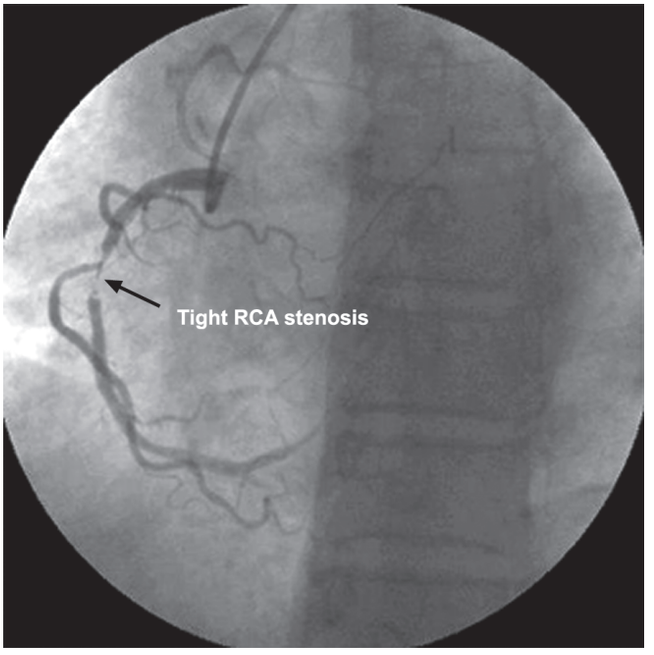

Fig. 5.14: Tissue Doppler imaging is useful in determining myocardial velocities and for ventricular function evaluation. In RVMI, the systolic and early diastolic velocities, myocardial velocities for the free right wall are decreased. Tissue Doppler echocardiography can also demonstrate ventricular asynchrony by using septal and left ventricular free wall measurements. In RVMI, the typical apex-base gradient is inverted and high flow velocities are found at the apex and in the outflow tract. In PE, an increase in myocardial strain-rate is noticed with the decrease of maximal systolic strain indicating a reduction in cardiac output. The profile changes from protomezosystolic to telesystolic and even protodiastolic (postsystolic shortening)

echocardiographic RV volumes are comparable to those derived by CMR and are probably more accurate than 2D echocardiographic volumes.

Cardiac Magnetic Resonance

Cardiac magnetic resonance (CMR) using late gadolinium enhancement imaging enables the accurate characterization of ischemic myocardial injury. CMR studies have indicated that RV infarction occurs in a high number of cases in patients with IWMI (47–57%) and that some patients with anterior MI (11–65%) also have RV involvement to some extent. Indeed, two observational reports comparing the frequency of RV involvement between different modalities in patients with acute MI indicated that RV involvement was detected significantly more frequently with CMR than with electrocardiography or echocardiography. Although the recent advances in CMR may contribute to understanding the pathology as well as providing a more accurate diagnosis of RV infarction, further investigations are essential to establish the usefulness of the CMR technique, since the numbers of patients included in these observational studies were limited (Fig. 5.16).

Cine-angiography: It would be helpful in profiling coronary arteries (Fig. 5.17).

MANAGEMENT

The management of RV infarction should be started with volume replacement, and recent studies have highlighted the adverse effect of excessive volume loading. Early revascularization is also applied to RV infarction, in which the complete revascularization of the affected vessels, including the major RV branch, plays an important role in the recovery of RV function. Electrical stabilization, including adequate heart rate and the maintenance of atrioventricular synchrony, is another key factor for preserving cardiac output in RV infarction. Furthermore, various extracorporeal support devices have been used to support RV failure secondary to RV infarction and contributed to the improvement of RV shock.

Volume Replacement

When RV infarction is complicated by acute MI, it is widely recognized that adequate therapy can be achieved only by expanding the plasma volume, ideally with the aid of invasive monitoring. However, fluid replacement can be challenging in some patients with RV infarction, particularly in the presence of severe RV dysfunction. The

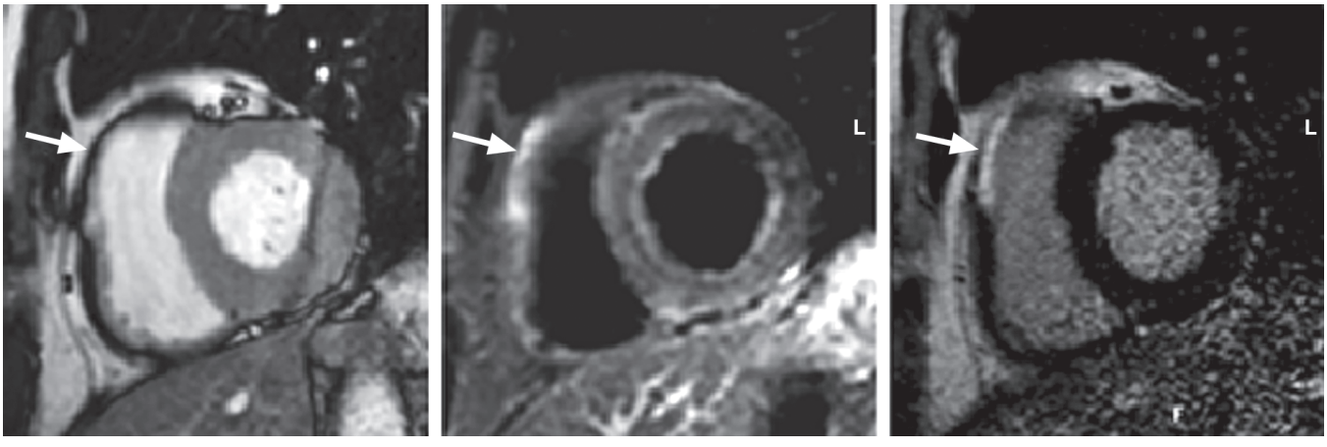

Fig. 5.15: RV failure. (A) Showing speckle tracking of 2D echocardiographic image of the right ventricle. (B) Strain vs time plotted for various regions of the RV. It shows delay in time to peak strain in the septum compared to the RV free wall

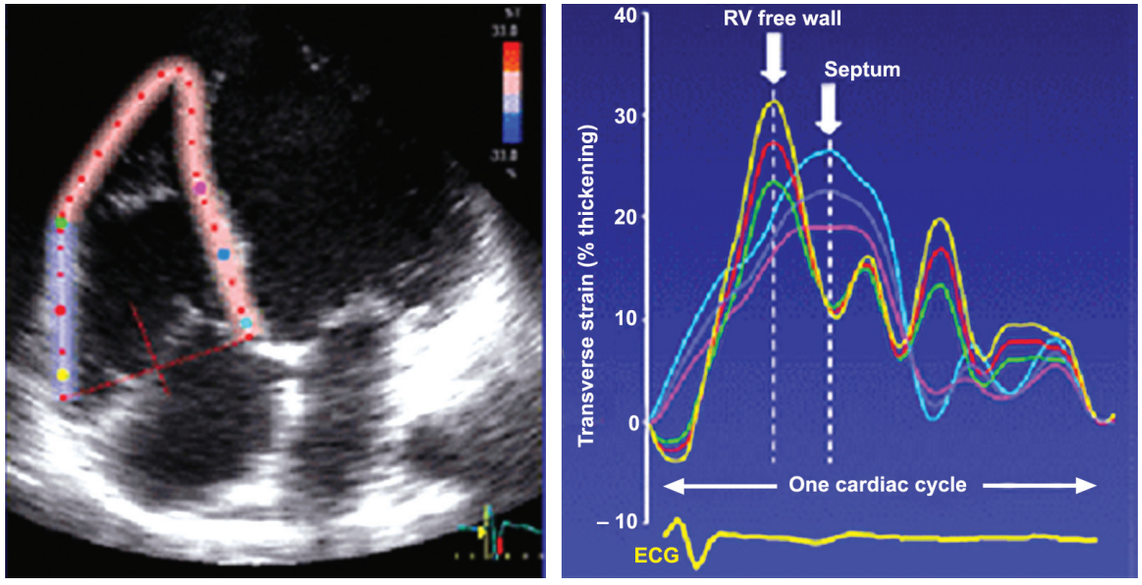

Fig. 5.16: CMR images from a patient with acute non-STEMI, evidenced by a rise in cardiac enzymes and nonspecific ST-segment changes on an ECG. Invasive coronary angiography revealed 3-vessel CAD with an occluded proximal RV branch of the right coronary artery. A cine CMR image (A) in systole shows a subtle wall motion abnormality in the anterior RV free wall (arrow). The T2-weighted image (B) shows high signal in this area with corresponding high signal on the late gadolinium-enhanced image. There is no evidence of scar in the left ventricle, suggesting isolated RV infarction

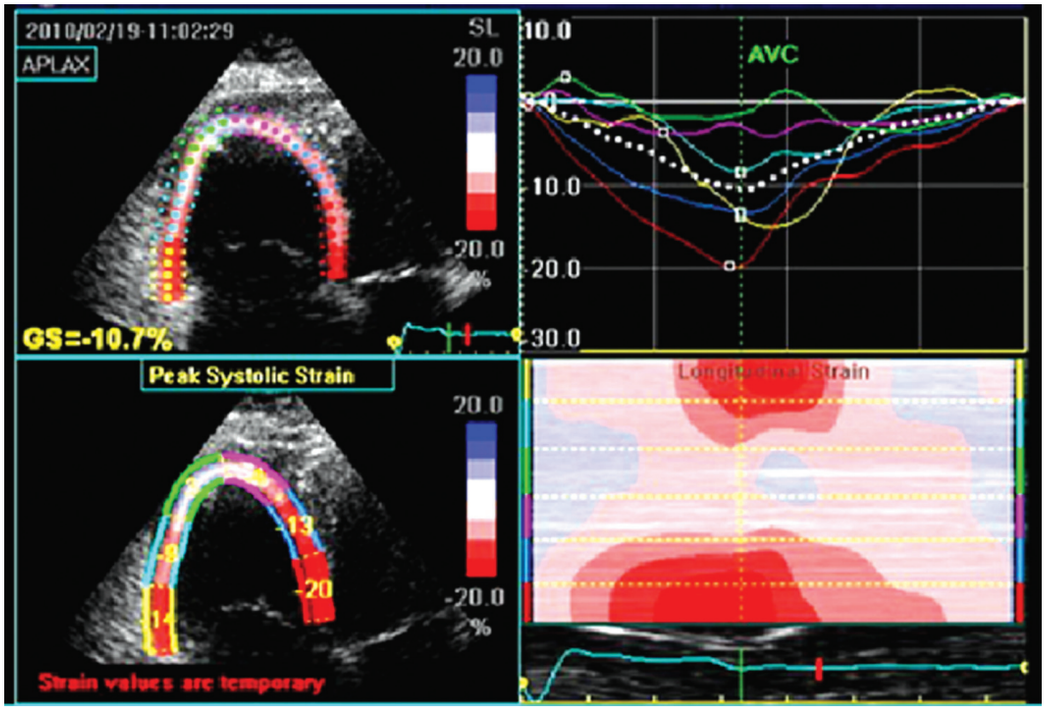

Fig. 5.17: Angiography showing tight stenosis of right coronary artery disease in RV infarction

concept of fluid replacement was first described as a treatment option approximately 25 years ago with the development of pulmonary artery catheterization. Since then, several studies have validated the usefulness of volume loading for ischemic RV dysfunction. Therefore, the initial therapy for hypotension in patients with RV infarction without pulmonary congestion has traditionally been volume expansion, particularly if the estimated central venous pressure was <15 mmHg. In previous studies, maintenance of the RV preload with volume loading and

normal saline alone was thought to resolve the accompanying hypotension and improve the cardiac output. The typical regimen consisted of normal saline (40 ml/min, up to total of 2 l, intravenously), while maintaining the right atrial pressure (RAP) at <18 mmHg to prevent volume overload. However, later clinical studies reported variable responses to aggressive fluid therapy with a target pulmonary wedge pressure (PWP) of 18–24 mmHg. Some studies, including two prospective ones, showed that volume loading further elevates the right-sided filling pressure without improving cardiac output Berisha and associates in a study of 41 patients who fulfilled the diagnostic electrocardiographic and hemodynamic criteria for RV infarction, reported that the maximal RV stroke work index occurred when the filling pressure was 10–14 mmHg, and a mean RAP of >14 mmHg was almost always associated with a reduced RV stroke work index. Although, the hemodynamic characteristics of RV infarction may be extremely variable, depending on the patient's state of hydration and the degree of concomitant LV involvement, this study indicated that the mean optimal PWP, which corresponds to the maximum LV stroke work index in each patient, was 16 mmHg.

Clinical Implications of Biventricular Interdependence

Two physiological concepts explain the detrimental effect of excessive volume loading in patients with RV infarction. First, data from animal studies suggest that excessive RV dilatation can further compromise LV output because of pericardial restraining effects. Biventricular interdependence is mediated by the shared interventricular septum and the surrounding pericardium. The disproportionate elevation of RV filling pressure because of surplus volume loading can lead to marked RV dilatation, elevation of intrapericardial pressure, and subsequent equalization of RV and LV diastolic pressures. By compromising LV filling, this situation will precipitate a low-output state. The resultant impairment of interventricular septal motion can further aggravate this condition.

In addition, in isolated RV infarction, RV performance can be largely attributed to a force generated by the interventricular septum. Patients with intact LV-septal contraction would be expected to manifest a pattern of paradoxical septal motion with preserved septal thickening portending a better prognosis. Damage to the interventricular septum significantly impairs RV emptying and exacerbates diastolic dysfunction, with an increase in the filling pressure. In RV infarction associated with septal dysfunction, compensation from LV-septal contraction transmitted through systolic ventricular interaction is lacking, and these patients usually present with hypotension and low cardiac output that are refractory to initial volume loading. Under these circumstances, inotropic stimulation of contractility, usually with dobutamine, has consistently improved RV performance by enhancing global LV contraction and increasing paradoxical septal displacement into the right ventricle. These important impacts of the interventricular septum on RV performance after acute MI were observed in a study using echocardiography, in which the recovery of RV function was best correlated with the improvement of the interventricular septum wall. In earlier studies, RV infarction was defined by hemodynamic criteria, such as an elevated RAP or PWP. At present, in most coronary units, physicians are able to identify RV infarction more precisely using noninvasive imaging techniques (e.g. echocardiography, radionuclide imaging, cardiac magnetic resonance), as discussed earlier. With these noninvasive modalities, the extent of interventricular involvement is essential for the precise assessment of fluid balance, early risk stratification, and prognostic evaluation.

Early Revascularization

In the typical situation of a hemodynamically significant RV infarction, RCA occlusion compromises right atrial and RV branch perfusion, resulting in RV ischemic dysfunction related to the loss of the critical compensatory contribution of augmented right atrial contraction. Patients with proximal RCA culprit lesions have worse baseline characteristics, less spontaneous recanalization, and a greater clot burden than those without occlusion.

Although the relative prognostic impact of RV infarction has been more prominent, successful mechanical reperfusion has improved the absolute clinical outcome as a whole, in relation to RV infarction. Because of the higher reperfusion rate achieved with primary angioplasty, the mortality among patients treated with this method has been relatively low. In addition, the clinical outcomes have been acceptable in patients with proximal RCA culprit lesions, despite their worse baseline characteristics; these outcomes have been similar to those of patients with nonproximal RCA culprit lesions. Technically, a shorter time taken to reperfusion and complete revascularization of the affected vessels, including the major RV branch, play an important role in the recovery of RV function. Early revascularization leads to an immediate recovery of RV function; conversely, late revascularization is associated with higher RV dysfunction and complications. Asalli and colleagues reported that complete revascularization of the RCA, including the major RV branch, was more closely associated with a higher recovery rate of RV function by echocardiography and better 30-day mortality than incomplete revascularization in patients with RV infarction. Further, in cases of complication with ventricular arrhythmia, reperfusion results in a better prognosis. Thus, prompt, successful, complete revascularization seems to benefit all patients with RV infarction.

Surgical Intervention

The current treatment of RVMI patients, other than the optimization of RV and LV preload with intravenous fluids, the administration of inotropic agents, and revascularization, includes the maintenance of atrioventricular synchrony, intra-aortic balloon pump counterpulsation, and more intensive mechanical support, including an emergent cardiopulmonary bypass and use of a ventricular

assist device (VAD). In this section, we summarize the newly developing modalities for patients with RV shock as follows: (1) electrical stabilization device, including adequate heart rate and the maintenance of atrioventricular synchrony; (2) percutaneous implantable VAD (especially focused on Tandem-Heart); and (3) percutaneous cardiopulmonary support (PCPS).

An adequate heart rate and the maintenance of atrioventricular synchrony can play an important role in sustaining a sufficient cardiac output. Patients with RV infarction tend to have bradyarrhythmia. In addition, the ischemic right ventricle and, consequently, the preload-deprived left ventricle have a relatively fixed stroke volume, and cardiac output strongly depends on the heart rate Therefore, an adequate heart rate with pacing is essential for patients with RV infarction, regardless of the presence or absence of bradyarrhythmia. Moreover, several investigators have shown that atrioventricular sequential pacing in patients with a complete atrioventricular block associated with RV infarction leads to a significant improvement in the cardiac output and recovery from shock when ventricular pacing alone has no benefit. Unfortunately, transvenous pacing may prove problematic due to ventricular sensing failure from the ischemic right ventricle and difficulties with lead positioning after right atrial enlargement.

Surgically implanted right VADs have been used mostly for the support of surgical or pretransplant patients. They have been less commonly used in the management of shock or for the post-cardiopulmonary arrest syndrome. However, in recent years, very few papers have described the use of percutaneous VAD implantation using Tandem-Heart (Cardiac Assist, Pittsburgh, PA, USA) for RV infarction Tandem-Heart is a temporary, external, continuous-flow, centrifugal pump that is placed nonsurgically in the catheterization laboratory through the femoral vein; it was originally intended for stabilizing critically ill patients who require short-term left heart support. The cannulas can be placed in the right atrium and pulmonary artery to support the right ventricle, as indicated in case reports. Percutaneous VADs are expected to allow time for the recovery of RV function in acute conditions or to serve as a bridge to other interventions, such as surgical VAD implantation.

PCPS has also been used successfully to provide support for patients with refractory RV failure secondary to RV infarction. A PCPS is a compact, portable heart-lung machine that can be quickly installed using a thin-walled cannula inserted via the femoral vessels. Cannulas are advanced in the right atrium and femoral artery, and oxygenated blood is transmitted from the femoral artery in a retrograde fashion. Although the installation of the Tandem Heart for left ventricular support requires a transseptal puncture to place the blood removal cannula into the left atrium, such techniques are not required to install a PCPS, which has been used to apply shock or for cardiopulmonary arrest due to accessibility issues. Suguta and colleagues reported the first case of cardiogenic shock caused by RV infarction treated with a PCPS, which is now recognized as one of the therapeutic options.

SUMMARY

In patients with MI, especially those with IWMI, RV involvement is an important contributor to shock, which significantly increases the risk of mortality. The recent advances in noninvasive modalities, such as CMR, provide a more accurate diagnosis of RV infarction, which in turn helps elucidate the precise pathophysiology. Although volume loading has long been considered the cornerstone of management in these cases, we can apprehend the harmful aspects of this therapy by understanding its effect on the interventricular septum. Early successful reperfusion, especially using revascularization, contributes to the recovery from shock associated with RV infarctions, which thus results in an improved prognosis. On the other hand, the importance of RV infarction is highlighted in this mechanical reperfusion era. The maintenance of an adequate heart rate and atrioventricular synchrony is another key factor for sustaining a sufficient cardiac output in patients with RV infarction. In refractory cases, more intensive mechanical support, including Tandem-Heart or PCPS, has been applied and is recognized as new therapeutic options.

Cardiovascular Agents

Dobutamine is an inotropic agent used to improve right ventricular contractility and maintain cardiac output. Sodium nitroprusside reduces afterload.

- **Dobutamine:** Produces vasodilation and increases inotropic state. At higher dosages, may cause increased heart rate, exacerbating myocardial ischemia.
- **Adult:** 0.5 mcg/kg/min IV initial; titrate until desired effect attained
- **Beta-adrenergic blockers**: They antagonize effects; general anesthetics may increase toxicity
- ***Documented hypersensitivity***: Idiopathic hypertrophic subaortic stenosis; atrial fibrillation or flutter
- **Pregnancy:** B-Fetal risk not confirmed in studies in humans but has been shown in some studies in animals

Precautions

Caution following MI; hypovolemic state should be corrected before using:

- **Nitroprusside (nitropress):** Produces vasodilation and increases inotropic activity of heart. At higher doses, may exacerbate myocardial ischemia by increasing heart rate. Infusion rates >10 mcg/kg/min may lead to cyanide toxicity.
- **Adult:** 0.3–0.5 mcg/kg/min IV initial infusion; use 0.5 mcg/kg/min increments and titrate to desired effect; average dose is 1–6 mcg/kg/min
- Coadministration with other hypotensive agents may have additive effects

- **Documented hypersensitivity:** Subaortic stenosis; idiopathic hypertrophic subaortic stenosis; decreased cerebral perfusion; arteriovenous shunt or coarctation of aorta (e.g. compensatory hypertension); atrial fibrillation or flutter
- **Pregnancy:** C-Fetal risk revealed in studies in animals but not established or not studied in humans; may use if benefits outweigh risk to fetus.

Precautions

Caution in increased intracranial pressure, hepatic failure, severe renal impairment, and hypothyroidism; in renal or hepatic insufficiency, nitroprusside levels may increase and can cause cyanide toxicity; sodium nitroprusside has ability to lower blood pressure and should be used only in patients with mean arterial pressures >70 mmHg.

Tissue Plasminogen Activators

These agents bind to fibrin and convert plasminogen to plasmin, which in turn initiates local fibrinolysis with limited systemic proteolysis.

- ***Alteplase (Activase):*** Tissue plasminogen activator (t-PA) used in management of acute myocardial infarction, acute ischemic stroke, and pulmonary embolism. May administer heparin or aspirin with and after alteplase infusions to reduce risk of rethrombosis. Safety and efficacy of concomitant administration of heparin or aspirin during first 24 h after symptom onset have not been investigated.
- ***Adult:*** 0.9 mg/kg (not to exceed 90 mg) IV infusion over 60 minutes with 10% of total dose administered as initial IV bolus over 1 minute.

BIBLIOGRAPHY

1. Andersen HR, Falk E, Nielsen D. Right ventricular infarction: frequency, size and topography in coronary heart disease: a prospective study comprising 107 consecutive autopsies from a coronary care unit. J Am Coll Cardiol 1987;10(6): 1223–32.
2. Andersen HR, Nielsen D, Falk E, et al. Right ventricular infarction: larger enzyme release with posterior than with anterior involvement. Int J Cardiol 1989;22(3):347–55.
3. Andersen HR, Nielsen D, Lund O. Prognostic significance of right ventricular infarction diagnosed by ST-elevation in right chest leads V3R to V7R. Int J Cardiol 1989;23(3): 349–56.
4. Bates ER. Revisiting reperfusion therapy in inferior myocardial infarction. J Am Coll Cardiol 1997;30(2):334–42.
5. Birnbaum Y, Wagner GS, Barbash GI. Correlation of angiographic findings and right (V1 to V3) versus left (V4 to V6) precordial ST-segment depression in inferior wall acute myocardial infarction. Am J Cardiol 1999;83(2):143–8.
6. Braat SH, Brugada P, de Zwaan C. Value of electrocardiogram in diagnosing right ventricular involvement in patients with an acute inferior wall myocardial infarction. Br Heart J 1983;49(4):368–72.
7. Braat SH, Brugada P, den Dulk K. Value of lead V4R for recognition of the infarct coronary artery in acute inferior myocardial infarction. Am J Cardiol 1984;53(11):1538–41.
8. Chockalingam A, Gnanavelu G, Alagesan R, Subramaniam T. Myocardial performance index in evaluation of acute right ventricular myocardial infarction. Echocardiography 2004; 21(6):487–94.
9. Chockalingam A, Gnanavelu G, Subramaniam T, et al. Right ventricular myocardial infarction: presentation and acute outcomes. Angiology 2005;56(4):371–6.
10. Dokainish H, Abbey H, Gin K, et al. Usefulness of tissue Doppler imaging in the diagnosis and prognosis of acute right ventricular infarction with inferior wall acute left ventri-cular infarction. Am J Cardiol 2005;95(9):1039–42.
11. Elkayam U, Halprin SL, Frishman W. Echocardiographic findings in cardiogenic shock due to right ventricular myocardial infarction. Cathet Cardiovasc Diagn 1979;5(3): 289–94.
12. Forman MB, Goodin J, Phelan B. Electrocardiographic changes associated with isolated right ventricular infarction. J Am Coll Cardiol 1984;4(3):640-3.
13. Garty I, Barzilay J, Bloch L. The diagnosis and early complications of right ventricular infarction. Eur J Nucl Med 1984;9(10):453–60.
14. Giannitsis E, Potratz J, Wiegand U. Impact of early accelerated dose tissue plasminogen activator on in-hospital patency of the infarcted vessel in patients with acute right ventricular infarction. Heart 1997;77(6):512–6.
15. Haupt HM, Hutchins GM, Moore GW. Right ventricular infarction: role of the moderator band artery in determining infarct size. Circulation 1983;67(6):1268–72.
16. Hirsowitz GS, Lakier JB, Goldstein S. Right ventricular function evaluated by radionuclide angiography in acute myocardial infarction. Am Heart J 1984;108(4 Pt 1):949–54.
17. Hurst JW. Comments about the electrocardiographic signs of right ventricular infarction. Clin Cardiol 1998;21(4): 289–91.
18. Iqbal MZ, Liebson PR. Counterpulsation and dobutamine. Their use in treatment of cardiogenic shock due to right ventricular infarct. Arch Intern Med 1981;141(2):247–9.
19. Kinn JW, Ajluni SC, Samyn JG. Rapid hemodynamic improvement after reperfusion during right ventricular infarction. J Am Coll Cardiol 1995;26(5):1230–4.
20. Lisbona R, Sniderman A, Derbekyan V. Phase and amplitude imaging in the diagnosis of acute right ventricular damage in inferior infarction. Clin Nucl Med 1983;8(11):517–20.
21. Martin W, Tweddel A, McGhie I. The evaluation of right ventricular function in acute myocardial infarction by xenon-133. Nucl Med Commun 1989;10(1):35–43.
22. Mavric Z, Zaputovic L, Matana A. Prognostic significance of complete atrioventricular block in patients with acute inferior myocardial infarction with and without right ventri-cular involvement. Am Heart J 1990;119(4):823–8.
23. Mittal SR. Isolated right ventricular infarction. Int J Cardiol 1994;46(1):53–60.
24. Nader DA, Ceretto WJ, Vieweg WV. Atrial pacing in the manage-ment of right ventricular infarction. South Med J 1981;74(3):362–3.
25. Pfisterer M, Emmenegger H, Muller-Brand J. Prevalence and extent of right ventricular dysfunction after myocardial

infarction—relation to location and extent of infarction and left ventricular function. Int J Cardiol 1990;28(3):325–32.
26. Robalino BD, Petrella RW, Jubran FY. Atrial natriuretic factor in patients with right ventricular infarction. J Am Coll Cardiol 1990;15(3):546–53.
27. Roth A, Miller HI, Kaluski E. Early thrombolytic therapy does not enhance the recovery of the right ventricle in patients with acute inferior myocardial infarction and predominant right ventricular involvement. Cardiology 1990; 77(1):40–9.
28. Singhal AM, Ilangovan S, Mehta S. Isolated right ventricular infarction followed by posterior left ventricular infarction after a few days. Acta Cardiol 1984;39(4):307–12.
29. Strauss HD, Sobel BE, Roberts R. The influence of occult right ventricular infarction on enzymatically estimated infarct size, hemodynamics and prognosis. Circulation 1980;62(3): 503–8.
30. Sugimoto T, Ogawa K, Asada T. Surgical treatment of ventricular septal perforation with right ventricular infarction. J Cardiovasc Surg (Torino) 1996;37(1):71–4.

6 Percutaneous Coronary Interventions (Balloon Angioplasty and Stentoplasty)

Grüntzig's first successful coronary angioplasty treatment on a human was performed in 1977, in Zurich, Switzerland. He expanded a short, about 3 mm, nonbranching section of the left anterior descending (LAD) artery (the front branch of the left coronary artery) which supplies the front wall and tip of the heart which had a high grade stenosis, about 80%, of the lumen. Dr Grüntzig presented the results of his first four angioplasty cases at the 1977 American Heart Association (AHA) meeting, which led to widespread acknowledgement of his pioneering work (Fig. 6.1).

The immediate results of this treatment, despite using only a carefully *kitchen built* catheter (crude by current standards), was quite good. The patient became and remained angina free after this treatment. This initial patient's result was electively rechecked, by angiography at Emory University, on the 10 year anniversary of the initial treatment. The LAD narrowing, after this 10 year timespan, remained almost perfectly expanded. There was minimal residual narrowing, probably less than 10%, as seen in similar angle and multiple different views comparing with photographs of the original, 10 years earlier, before and after results. The excellent results of this initial and subsequent patients were critical to the rapid development and growing acceptance of the angioplasty treatment option. Dr Grüntzig recognized multiple important issues early—(a) the treatment would not be readily accepted by most physicians, especially bypass surgeons, (b) it could easily lead to bad outcomes without great care in selection of which patients/lesions to treat and of the treating physicians, and (c) it required careful teaching of the technique and its potential difficulties and pitfalls to other physicians, so as to proactively reduce the occurrence of poor results. Understanding these issues and tireless effort on his part are widely recognized in cardiology for being of fundamental importance to the ultimate success of the technique.



Fig. 6.1: Andreas Roland Grüntzig (June 25, 1939–October 27, 1985) was a German cardiologist who first developed successful balloon angioplasty for expanding lumens of narrowed arteries

By about 1990, lumen stenosis of the coronary arteries was more commonly treated by the angioplasty technique than by coronary artery bypass surgery. This treatment approach is now referred to as plain old balloon angioplasty (POBA).

In the 1990s, further major improvements, both immediate and especially long term became possible with better understanding of disease as a result of clinical research trials using intravascular ultrasonography (IVUS) and the development of stents to mechanically support POBA results. Since the later 1990s, most angioplasties also involve a stent over the angioplasty balloon; the balloon is hydraulically (typically 6 up to 25 atmospheres of internal pressure) expanded, then deflated and removed while the

stent remains behind to mechanically support the lumen remaining in the new, more open shape as created by the hydraulically expanded balloon. Grüntzig's success remains a major breakthrough and great contribution to the field of medicine in demonstrating that doctors could work inside of the arteries safely, without the need for open surgery. By utilizing the arterial circulation as a 'therapeutic highway', many types of devices and drugs can now be delivered directly to the heart, kidneys, carotid arteries, brain, legs, and aorta without the need for major surgery and general anesthesia.

Since the first human percutaneous transluminal coronary angioplasty (PTCA) procedure was performed in 1977, the use of percutaneous coronary intervention (PCI) has increased dramatically, becoming one of the most common medical interventions performed. The technique, originally developed in Switzerland by Andreas Gruentzig, has transformed the practice of revascularization for coronary artery disease (CAD). Initially used in the treatment of patients with stable angina and discrete lesions in a single coronary artery, coronary angioplasty has multiple indications today, including unstable angina, acute myocardial infarction (MI), and multivessel coronary artery disease. With the combination of sophisticated equipment, experienced operators, and modern drug therapy, PCI has evolved into an effective nonsurgical modality for treating patients with coronary artery disease. Recent advances in guidewires, stents, and devices to cross chronically occluded arteries are evolving, so that more patients with chronic total occlusions (CTOs) are now being successfully treated percutaneously. Improvements in catheter technique and the development of new devices, wires, stents, drug-eluting stents, and medications have occurred parallel to advances in the understanding of cardiovascular physiology, the pathogenesis of atherosclerosis, and the body's response to vascular injury. Intracoronary stents and atherectomy devices were developed to increase the success rate of, and decrease the complications associated with, conventional balloon dilation and to expand the indications for revascularization. These devices have enabled the interventionalist to safely treat more complex coronary lesions and restenosis. Stents have evolved to a level where the problems of restenosis seen with bare metal stents are a les frequent occurrence after drug-eluting stents are implanted. At the same time, advances in intravascular ultrasonography and fractional flow reserve evaluation have improved the understanding of coronary plaque morphology, plaque vulnerability, and coronary physiology. Furthermore, many of these technologies are able to help identify patients who will benefit most from PCI, coronary bypass surgery, or medical therapy. Adjunctive pharmacologic therapies aimed at preventing acute reocclusion have also improved the safety and efficacy of coronary angioplasty. The growth of PCIs has been remarkable andwill likely be sustained, as new technologies have resulted in improved outcomes. Since 1994, the use of intracoronary stents has risen dramatically, and now with drug-eluting stents, stents are used in more than 80% of PCI cases in the United States. Innovations in PCIs over the past 2 decades have been paralleled by a dramatic reduction in 30-day death, myocardial infarction, and target-vessel revascularization rates.

INDICATIONS FOR PCI

Clinical indications for PCI include the following:

1. Acute ST-elevation myocardial infarction (STEMI)
2. Non ST-elevation acute coronary syndrome
3. Stable angina
4. Anginal equivalent (e.g. dyspnea, arrhythmia, dizziness/syncope)
5. Asymptomatic or mildly symptomatic patients with objective evidence of a moderate to large area of viable myocardium or moderate to severe ischemia on noninvasive testing
6. Angiographic indications include hemodynamically significant lesions in vessels serving viable myocardium (vessel diameter >1.5 mm)

CONTRAINDICATIONS TO PCI

Clinical contraindications include significant comorbidities (relative contraindication).

Angiographic contraindications include the following:

- Left main stenosis in a patient who is a surgical candidate (coronary artery bypass graft [CABG] surgery is still the preferred treatment for left main stenosis; however, this area is rapidly evolving toward safe and feasible PCI options)
- Diffusely diseased small-caliber artery or vein graft
- Other coronary anatomy not amenable to percutaneous intervention

PREPARATION IN PERCUTANEOUS CORONARY BALLOON ANGIOPLASTY EQUIPMENT (Figs 6.2 to 6.4)

The original description of angioplasty by Dotter and Judkins described enlargement of the vessel lumen through a mechanism of atheromatous plaque compression. This mechanism is also partially responsible for luminal enlargement with balloon angioplasty. In addition, however, improvement in luminal diameter following balloon angioplasty also results from stretching of the vessel wall by the balloon. Balloon inflation actually results in overstretching of the vessel wall and partial disruption of not only the intimal plaque but also the media and adventitia, resulting in enlargement of the lumen and the outer diameter of the vessel.

Axial redistribution of plaque material also contributes to improvements in lumen diameter. Atherectomy devices and, subsequently, intracoronary stents were developed, in part, to decrease the early and late loss in luminal diameter observed with conventional balloon angioplasty. Several different balloon catheter designs have existed (over-the-wire, monorail, and fixed wire) with balloon materials that have different compliance characteristics allowing various degrees of expansion with increasing pressure. Irrespective of the balloon design, a steerable



Fig. 6.2: Interventional laboratory for conducting percutaneous coronary interventions

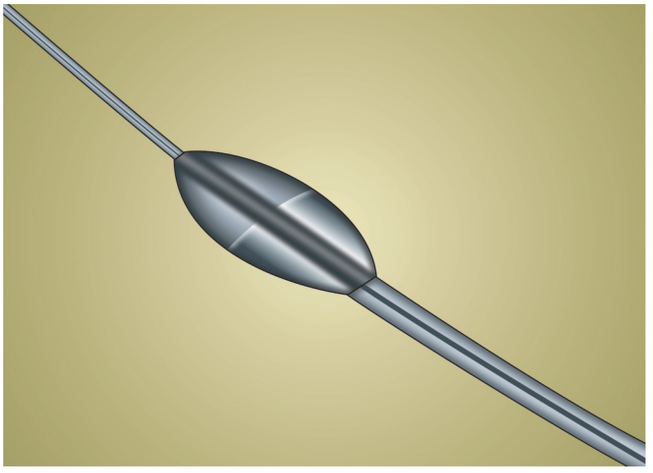

Fig. 6.3: Percutaneous transluminal coronary angioplasty (PTCA). The rotational atherectomy catheter (rotablator) is a device designed for the removal of plaque from coronary arteries. This tip, rotates at about 160,000 rpm and is particularly well suited for ablation of calcific or fibrotic plaque material

guidewire precedes the balloon into the artery and allows navigation through a considerable portion of the coronary tree. The development of balloon catheters that bend, allowing easy advancement through tortuous vascular segments (trackability), and that have increased shaft stiffness (pushability), allowing the catheter to be forced through stenotic lesions, has increased their versatility significantly. Another evolving feature of catheter design

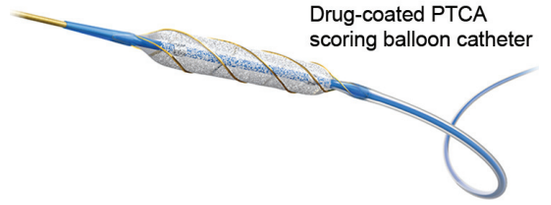

Fig. 6.4: Features of drug-coated PTCA scoring balloon catheter

has been a reduction in the diameter of the deflated balloon, allowing easier passage through very stenotic lesions. Improvements in catheter design have been partially responsible for the improved success rates of PCIs.

The balloon catheter also serves as an adjunctive device for many other interventional therapies, including atherectomy and coronary stents.

Technique of percutaneous coronary intervention: Different technical stepts (Fig. 6.5) which are employed in cardiac catheterization laboratory are described below as:

- **Angioplasty procedure, step 1:** While the patient is awake and pain-free (local anesthesia), a catheter is inserted into an artery at the top of the leg (the femoral artery). The procedure begins with the doctor injecting some local anesthesia into the groin area and putting a needle into the femoral artery (the blood vessel that runs from the heart down the leg). Once the needle is inserted, a guide wire is placed through the needle, into the blood vessel. Following this step, the guide wire is left in the blood vessel and the needle is removed. A large needle

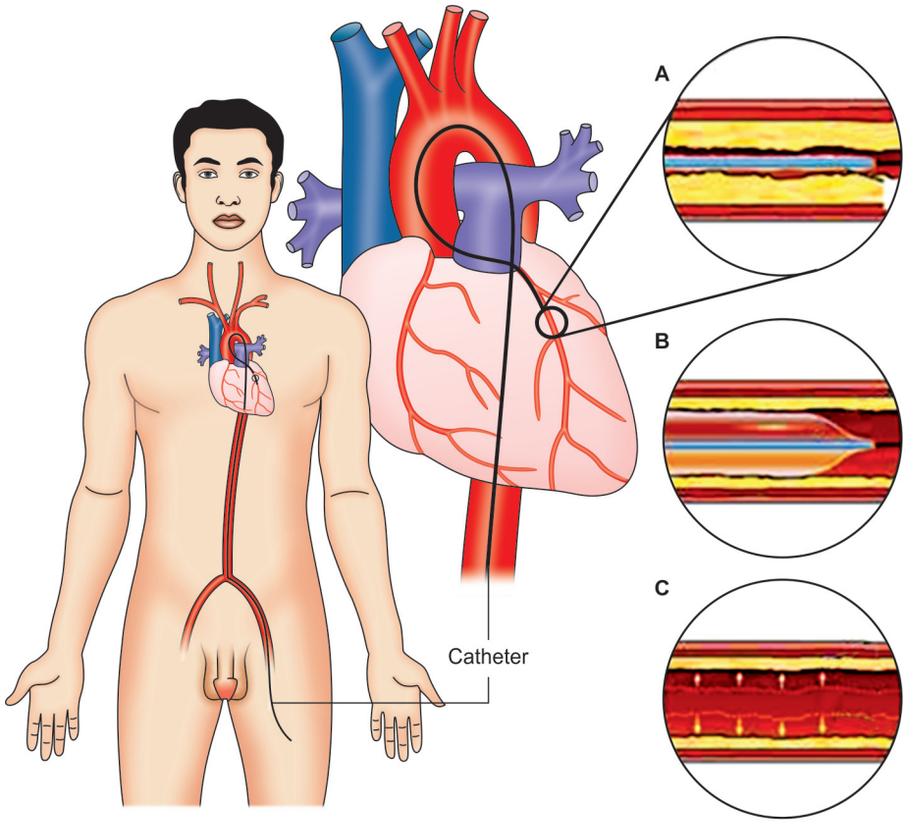

Fig. 6.5: Technique of percutaneous coronary angioplasty

called an introducer is then placed over the guide wire and the guide wire is removed.

- **Angioplasty procedure, step 2:** Next, a diagnostic catheter, which is a long narrow tube, is advanced through the introducer over a .035" guidewire, into the blood vessel. This catheter is then guided to the aorta and the guidewire is removed. Once the catheter is placed in the opening or ostium of one of the coronary arteries, the doctor injects dye and takes a series of X-rays films.
- **Angioplasty procedure, step 3:** After visualising the culprit vessel an appropriate sized balloon over the catheter is inserted and the vessel is then dilated with desired pressure to its fullest intraluminal size. This procedure can greatly improve the blood flow through the coronary arteries and to the heart tissue in about 90% of patients and may eliminate the need for coronary artery bypass surgery. The outcome is relief from chest pain symptoms and an improved exercise capacity. In 2 out of 3 cases, the procedure is considered successful with complete elimination of the narrowing or blockage.

Coronary Physiologic Assessment

Intracoronary Doppler pressure wires are able to characterize coronary lesion physiology and to estimate lesion severity. Comparison of pressure distal to a lesion with aortic pressure enables determination of fractional flow reserve (FFR) (see the Fig. 6.6). A measurement below 0.75–0.80 during maximal hyperemia (induced via administration of adenosine) is consistent with a hemodynamically significant lesion. This determination is useful in deciding whether to perform PCI in an angiographic intermediate lesion. Clinical data, namely the DEFER study, support using this approach, with a low event rate seen in medically managed patients with angina and an FFR measurement greater than 0.75. Fractional flow ratio (FFR). Pressure wire is advanced across left anterior descending (LAD) stenosis and intracoronary adenosine is given. FFR ratio is recorded at baseline and then after adenosine push is given. Here, LAD lesion and FFR postadenosine is shown.

The fractional flow reserve versus angiography for guiding PCI in patients with multivessel coronary artery disease (FAME) trial showed that routine measurement of FFR during angioplasty reduced the risk of death, myocardial infarction, or repeat revascularization by 30% and death or myocardial infarction by 35%, compared with the current practice of using angiography to guide stenting decisions. In this study, a cut-off of FFR greater than 0.80 was used to define a nonischemic lesion. Two-year follow-up of the FAME trial showed continuing significant reductions in the combined endpoint of death and myocardial infarction with the use of FFR compared with standard angiography-guided PCI.

This form of physiologic lesion assessment is also useful for defining optimal stenting, assessing the angiographic severity of jailed side branch lesions, helping guide the decision for multivessel percutaneous coronary intervention or coronary artery bypass graft in multiple intermediate lesions, and assessing the severity of instant restenosis. FFR measurements have excellent correlation with IVUS analysis, especially when determining lesion severity, such as in ambiguous left main coronary artery anatomy (Fig. 6.6).

TYPES OF INTERVENTIONS EMPLOYED IN CORONARY ARTERY DISEASE

1. Percutaneous Transluminal Coronary Angioplasty

Angioplasty (or balloon angioplasty) is an *endovascular procedure* to widen narrowed or obstructed arteries or veins, typically to treat arterial *atherosclerosis*. An empty, collapsed balloon, known as a *balloon catheter*, is passed over a wire into the narrowed locations and then inflated to a fixed size. The balloon forces expansion of the *stenosis* (narrowing) within the vessel and the surrounding muscular wall, opening up the blood vessel for improved flow, and the balloon is then deflated and withdrawn. A *stent* may or may not be inserted at the time of ballooning to ensure the vessel remains open (Figs 6.7–6.12).

2. Stentoplasty

Coronary stents were first developed in the mid 1980s to overcome the inherent limitations of balloon angioplasty, including elastic recoil and vessel closure in the acute phase, as well as constrictive remodeling and restenosis in the late phase. In the 1990s, this technology became widely accepted as a promising treatment strategy for patients with coronary artery disease after the landmark Belgian Netherlands Stent trial, which demonstrated the superiority of the bare metal stent (BMS) over balloon angioplasty (Figs 6.13–6.31 and Table 6.1). Although coronary stenting improved angiographic results and clinical outcomes, neointimal hyperplasia and restenosis continued to be major limitations of this technology. In order to minimize neointimal hyperplasia and thereby reduce repeat revascularization, drug-eluting stents (DES) were developed. Early pivotal trials of the first generation DES showed excellent results with respect to the reduction of in-stent restenosis, such that they rapidly replaced BMS. In the year 2006, safety concerns were raised with DES following reports linking their use to an increased risk of stent thrombosis (ST). First generation DES, with permanent polymers, have been associated with delayed endothelialization, endothelial dysfunction, and local hypersensitivity reactions, resulting in an increased risk of ST and the need for prolongation of

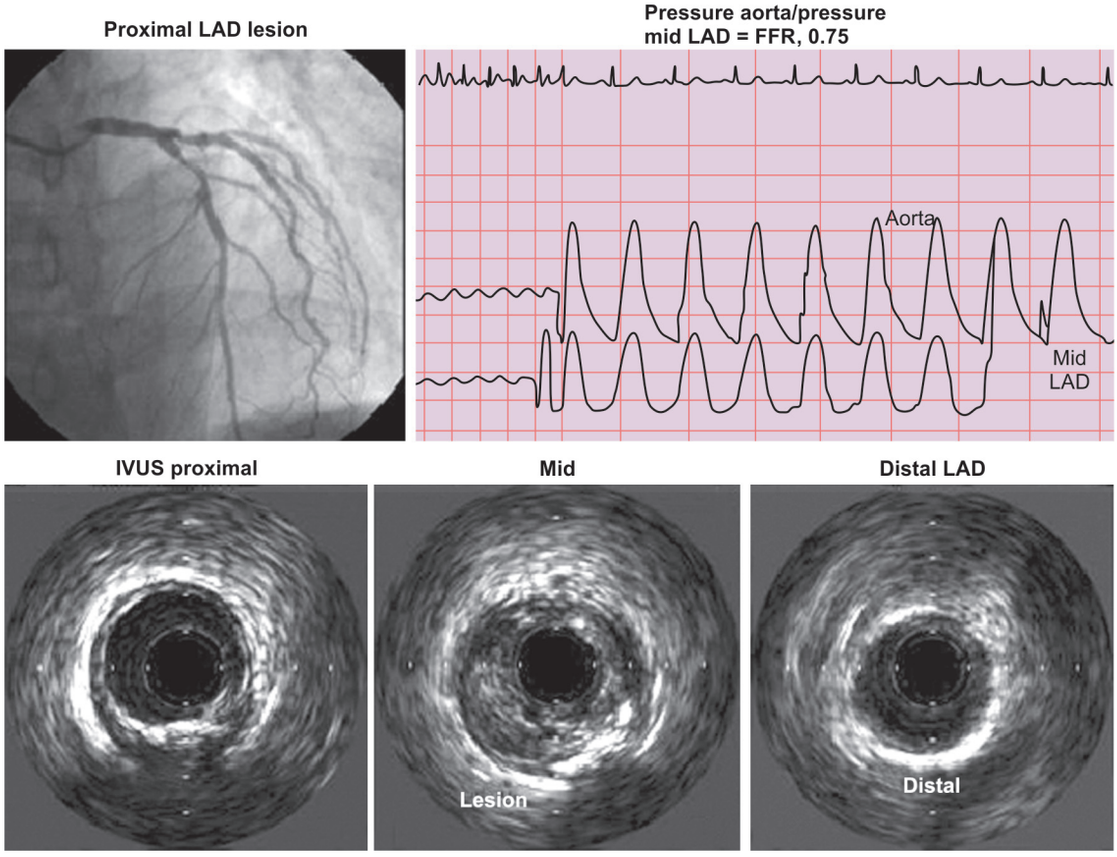

Fig. 6.6: Fractional flow ratio (FFR). Pressure wire is advanced across left anterior descending (LAD) stenosis and intracoronary adenosine is given. FFR ratio is recorded at baseline and then after adenosine push is given. Here, LAD lesion and FFR postadenosine is shown

Table 6.1: Types of coronary stents and selected antirestenosis devices

Stent type	Description
Drug-eluting stent	A stent that slowly releases a drug to block cell proliferation and/or restenosis
Bare metal stent, stainless steel	A vascular thin metal wire or mesh stent without a coating, typically first-generation technology
Bare metal stent, CoCr	A vascular thin metal wire or mesh without a coating, typially next-generation technology
Absorbable stent	Completely biodegradable, bioabsorbable stent, typically polymer or magnesium, sometimes coated with anti-restenotic agent
Bioactive stent	A stent that reacts with the body's natural processes to achieve an antirestenotic effect
Radioactive stent	Stent with a radiation-emitting coating
Drug-eluting balloon	Angioplasty balloon that, after deflation, leaves behind an antirestenotic drug

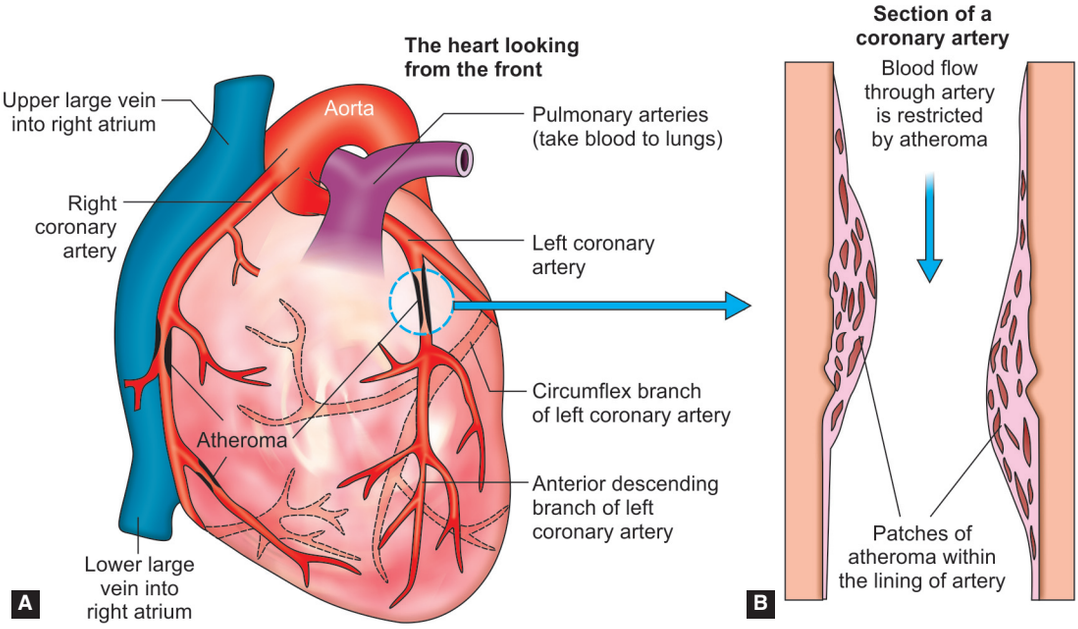

Fig. 6.7: (A) Anatomical localisation of atherosclerosed coronary arteries, and (B) morphology of section of atheromatous coronary artery

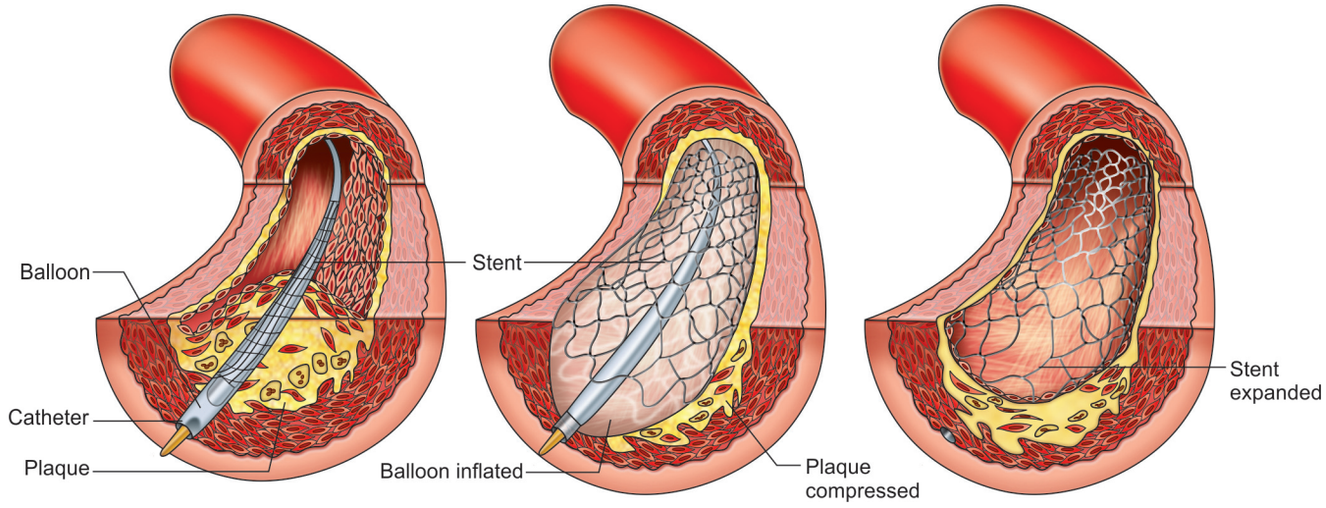

Fig. 6.8: Stepwise opening of obstructed coronary artery after stent has been installed in the lumen of the artery

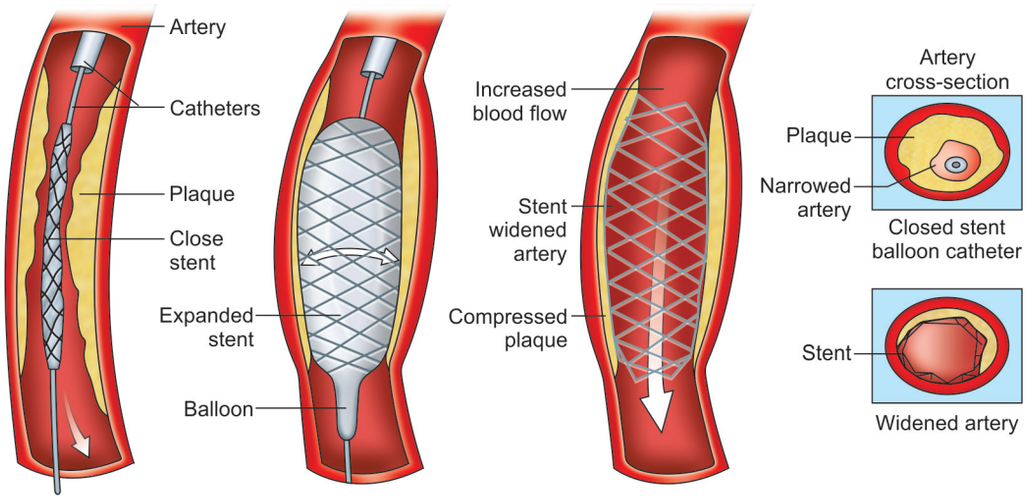

Fig. 6.9: Balloon angioplasty. Angioplasty is a minimally invasive procedure used to open up clogged arteries in almost any part of the body. In balloon angioplasty, a small balloon is guided to the site of blockage, and inflated to compress the plaque and thus widen the artery. A small incision is made in the groin or wrist, following the administration of local anesthesia. A balloon-tipped catheter (balloon catheter) is then inserted into an artery of the leg or arms. The balloon catheter is threaded to the blockage site under X-ray guidance. Once at the site of blockage, a dye may be inserted at the site so as to determine the exact location of the blockage. The balloon catheter is then positioned at the precise location, and the balloon is inflated. As a result the surrounding plaque gets compressed, thus widening the arterial lumen. The balloon is then deflated and removed along with the catheter

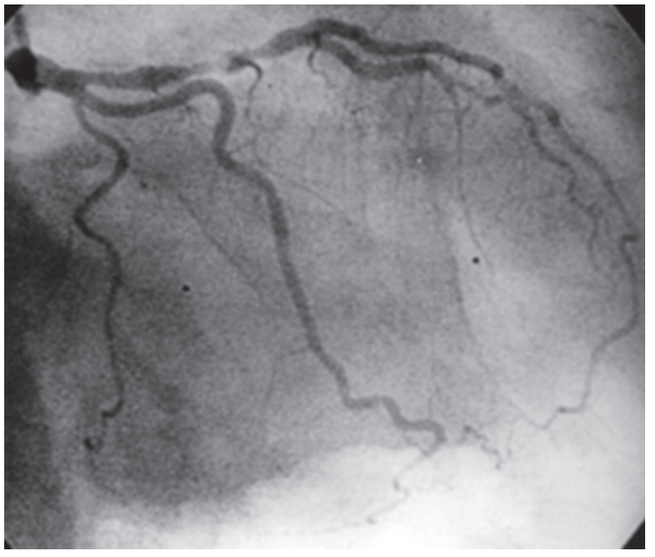

Fig. 6.10: Coronary angiography revealed diffuse irregular 73% luminal narrowing of the proximal left anterior descending coronary artery

dual antiplatelet therapy. Newer generation DES, with thinner struts and more biocompatible polymers, have considerably improved their safety profile. However, concerns still persist over the presence of durable polymers, as evidence from animal and human studies still suggest that these durable polymers may cause persistent arterial wall inflammation and delayed vascular healing, both of which may subsequently have a potential role in precipitating ST and delayed in-stent restenosis (i.e. late catch-up phenomenon). Newer generation DES, coated with biodegradable polymers, offer the attractive combination of controlled drug elution in parallel with biodegradation of the polymer into inert monomers. After the completion of biodegradation, only a BMS remains, thereby reducing the long-term risks associated with the presence of a permanent polymer. An extension of this concept has brought the development of newer DES that are completely free of polymer, or come with novel coatings. In addition, bioresorbable metallic (i.e. magnesium) and polymeric scaffolds have been developed, which initially safeguard the patency of the treated vessel and then disappear. The aim of this article is to review new stent technologies that are currently undergoing clinical investigation and discuss their future perspectives in interventional cardiology.

Intracoronary stents have been used widely since the early 1990s [the original Food Drug Administration (FDA) approval for intracoronary stents in the US was 1994]. Many different stents are available and differ in composition (e.g. stainless steel, cobalt chromium, and nickel chromium), architectural design, and stent delivery system (i.e. the balloon catheter that delivers it). The development of drug-eluting stents has revolutionized coronary intervention to the extent that balloon angioplasty and bare metal stents did in the 1980s and 1990s.

Today, four types of drug-eluting stents are available in the United States, the sirolimus-eluting stent (Cypher), the paclitaxel-eluting stent (Taxus), and the newer-generation zotarolimus-eluting stent (Endeavor) and everolimus-eluting stent (Xience V). These stents comprise a metal stent with a polymer that elutes a drug that reduces neointimal hyperplasia. Drug-eluting stents have been extensively tested in a wide spectrum of coronary lesions, all of which have demonstrated significant reductions in restenosis and

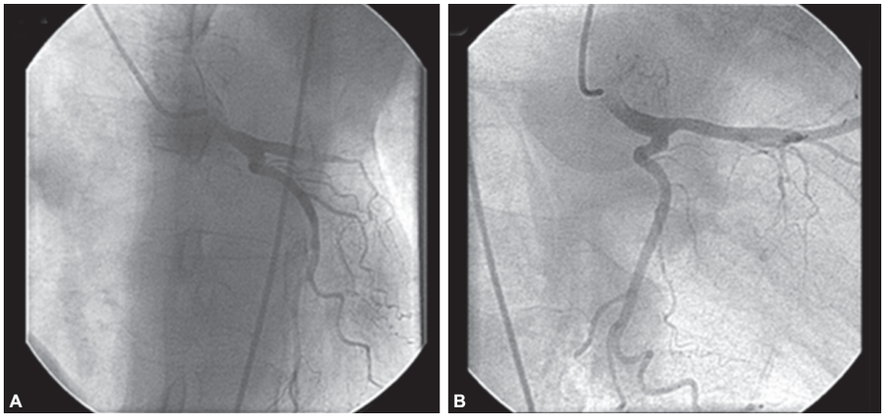

Fig. 6.11: (A) Coronary angiogram confirming a severe ostial stenosis of the LMCA, with extensive right-to-left collaterals to the left anterior descending (LAD) and left anterior circumflex (LCX) vessels. (B) Coronary angiogram showing the final result of the percutaneous coronary intervention

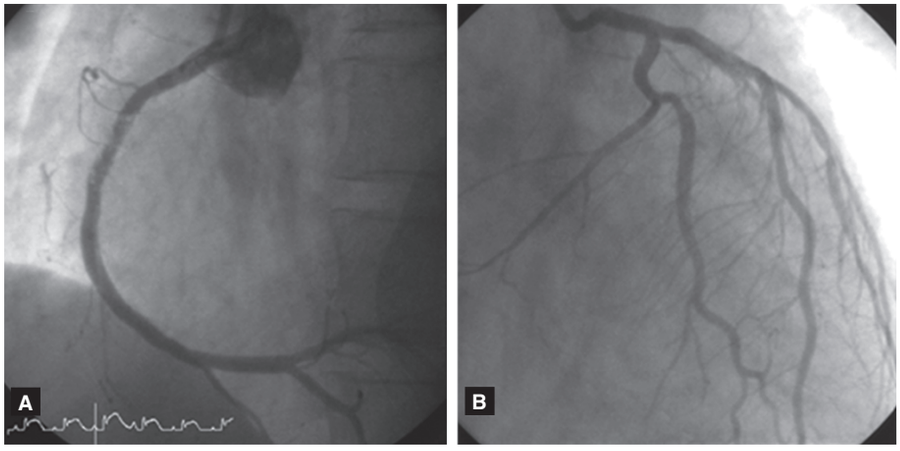

Fig. 6.12: After balloon angioplasty, the distal flow was restored to TIMI III in both coronary artery, but some residual thrombi were remained. (A) LAO view of RCA, (B) RAO caudal view of LAD



Fig. 6.13: Promus premier stent system is designed to provide physicians improved drug-eluting stent performance in treating patients with coronary artery disease. It is the only platform to feature a customised platinum chromium stent architecture, the market-leading everolimus drug coating and fluorinated co-polymer, and an enhanced stent delivery system

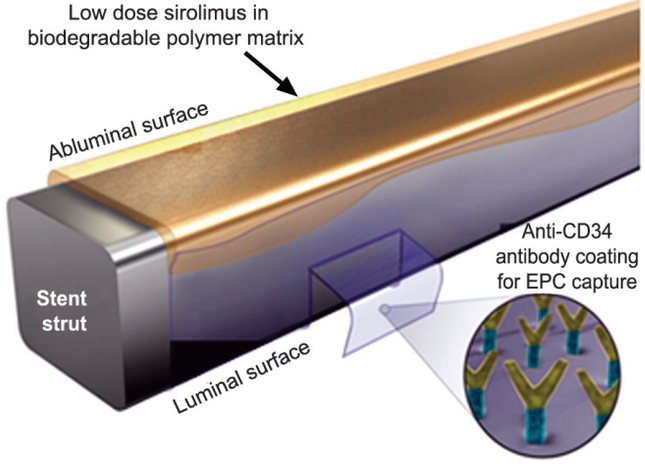

Fig. 6.14: The combo dual therapy device is hailed by OrbusNeich (Hoevelaken, Netherlands) as the first example of a dual therapy stent. The product combines abluminal sirolimus drug elution for the control of neointimal proliferation with the company's proprietary Genous prohealing technology to promote endothelial coverage. On the luminal side of the stent are immobilized antibodies that capture circulating endothelial progenitor cells



Fig. 6.15: Self-expanding Nitinol stent Pulsar-18 Fracture Resistant by Design Asymmetrical s-shape articulations and peak-to-valley design prevent fish-scaling. Small design modifications allow for better fatigue resistance through improved axial and bending flexibility

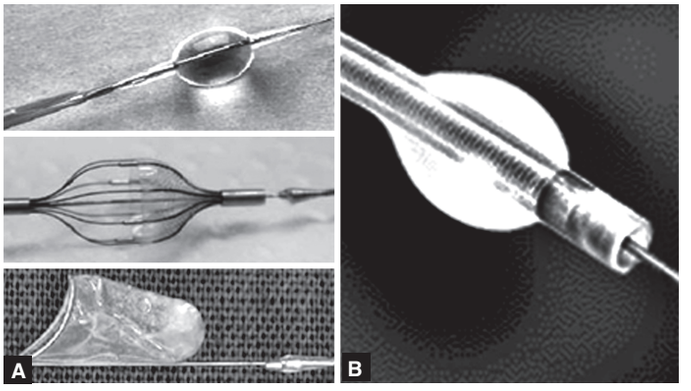

Fig. 6.16: The commonly used protection devices during vein graft interventions—(A) Percu-Surge (Guardwire Medtronic), Angioguard XP (Cordis), Filterwire EX (Boston). (B) The Proxis Embolic Protection System (St. Jude)

target-lesion revascularization rates when compared with bare metal stents. The zotarolimus-eluting stent and everolimus-eluting stent have improved deliverability, thinner struts, and a thinner polymer layer, and they may have clinical advantages over sirolimus-eluting and paclitaxel-eluting stents. Studies with drug-eluting stents are ongoing and include efforts to define safety and outcomes in every range of PCI setting, such as stable and unstable lesions, small vessels, vein grafts, chronic total occlusions, primary PCI, and comparing drug-eluting stent technologies with a coronary artery bypass graft in left main coronary artery disease and in diabetes patients with multivessel coronary artery disease. Although stents are conventionally placed after balloon predilation, a meta-analysis by Piscione et al. suggests that, in selected coronary lesions, direct stenting may lead to better outcomes. Myocardial infarction rates were lower with direct stenting (3.16% *vs* 4.04% with conventional stenting), while rates of target vessel revascularization were similar.

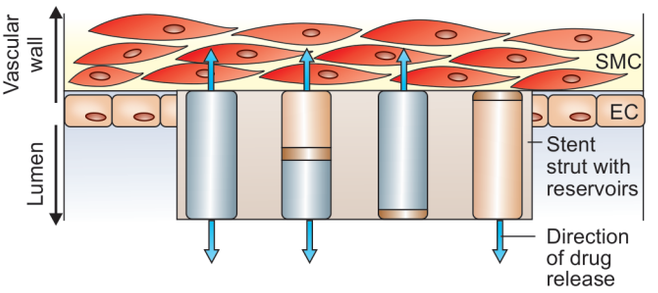

Fig. 6.17: This technology allows a targeted therapeutic approach, for example, by delivery of an agent that inhibits SMC proliferation via the ablumenal route of the stent surface. Concomitantly, an agent that promotes endothelial recovery can be released via the lumenal route. Furthermore, downstream drug delivery to tissue seems to be feasible (preferably at the lumenal side). The lateral view of a stent strut in the blood vessel exemplifies the diversity of drug delivery options (from left to right)— bidirectional delivery of one drug to both the ablumenal and lumenal side (blue), ablumenal delivery of one drug (orange) and lumenal delivery of a different drug (blue) where the drugs are separated in the reservoir to avoid mixing, or ablumenal delivery of one drug only (blue) and lumenal delivery of one drug only (orange). Reservoirs are sealed and drugs are separated by a layer of biodegradable polymer (brown disk). (EC=endothelial cell; SMC=smooth muscle cell)

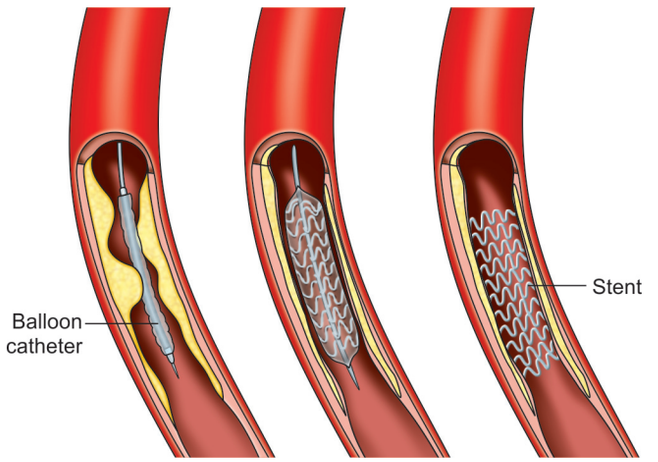

Fig. 6.18: Atheromated blocked coronary artery opened with stentoplasty

The Stent of the Future

First generation drug-eluting stents have considerably reduced in-stent restenosis and broadened the applications of percutaneous coronary interventions for the treatment of coronary artery disease. The polymer is an integral part of drug-eluting stents in that, it controls the release of an antiproliferative drug. The main safety concern of first generation drug-eluting stents with permanent polymers (stent thrombosis) has been caused by local hypersensitivity, delayed vessel healing, and endothelial dysfunction. This has prompted the development of newer generation drug-eluting stents with biodegradable polymers or even polymer-free drug-eluting stents. Recent clinical trials have shown the safety and efficacy of drug-eluting stents with

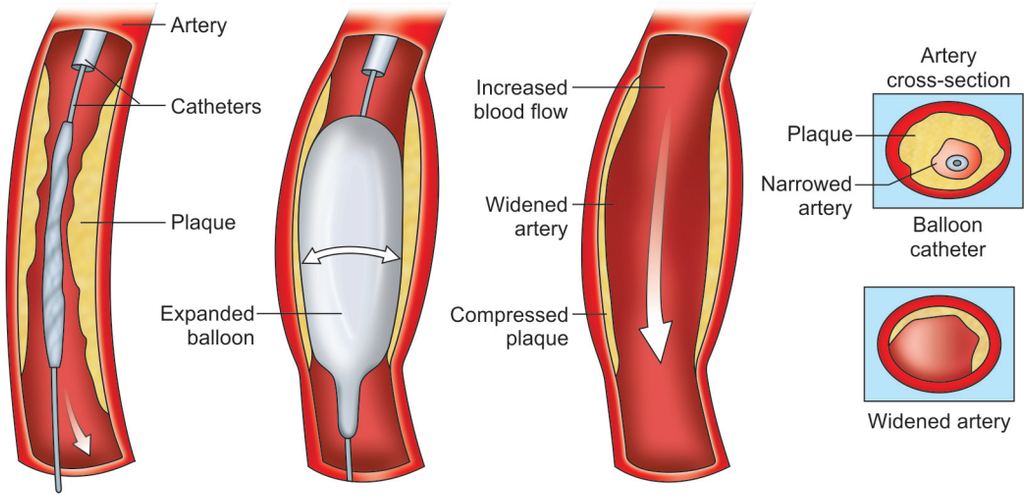

Fig 6.19: Stent angioplasty. This procedure is similar to balloon angioplasty, but involves the use of a small, expandable metallic mesh called 'stent', along with the balloon. The stent is placed around the balloon in a compressed form, and this assembly is placed at the tip of a catheter. It is then guided to the site of blockage as done during a balloon angioplasty. When the balloon is inflated, the stent expands and compresses the plaque. The balloon is then deflated and removed, leaving behind the stent which acts as a support and helps to keep the artery open

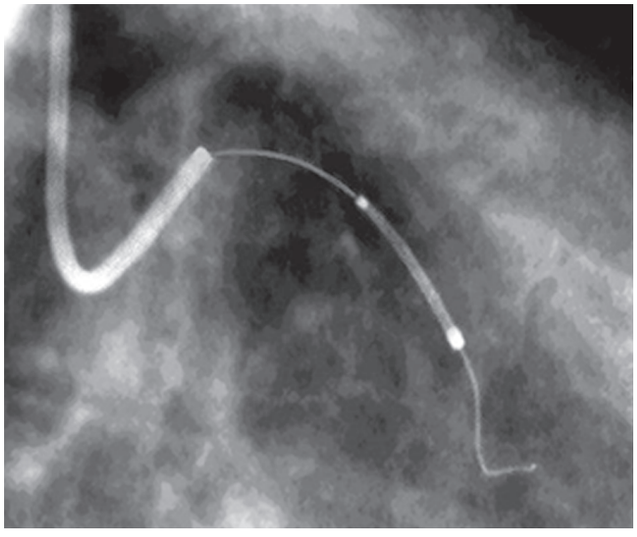

Fig. 6.20: Coronary angioplasty. X-ray angiogram of a balloon catheter and stent (white tipped tube, centre right) being placed within a coronary artery of a heart. They will be used to treat stenosis (narrowing) of the artery. The flexible catheter used to place them there is seen snaking down from top left. The inflation of the balloon catheter will expand the artery and restore normal blood flow. The stent is a hollow tube mesh, expanded by the balloon catheter, that stays in the artery and supports it after the balloon catheter has been withdrawn. Arterial stenosis may arise from arterial disease. X-ray angiography injects a radio-opaque contrast medium to highlight blood vessels on X-rays

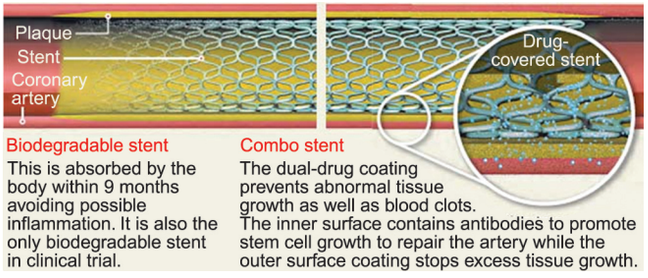

Fig. 6.21: Biodegradable coronary stents

biodegradable polymer, with proven reductions in very late stent thrombosis as compared to first generation drug-eluting stents. However, the concept of using a permanent metallic prosthesis implies major drawbacks, such as the presence of a foreign material within the native coronary artery that causes vascular inflammation and neoatherosclerosis, and also impedes the restoration of the vasomotor function of the stented segment. Bioresorbable scaffolds have been introduced to overcome these limitations, since they provide temporary scaffolding and then disappear, liberating the treated vessel from its cage.

Future Perspectives in Stents

Newer generation DES, with biodegradable polymers, have shown an impressive reduction in very late stent thrombosis (VLST), contributing to improved long-term outcomes, as compared to first generation DES. The polymer-free DES or BRS are relatively new technologies, with many trials still in progress. The currently available angiographic, intravascular imaging, and clinical data, suggest acceptable safety and efficacy of these new technologies. However, it remains unclear as to whether biodegradable-polymer DES or polymer-free DES can minimize late ST events, particularly as these late events have also been observed in patients receiving BMS. Furthermore, considering the fatal consequences of ST, focus should be maintained on the eradication, rather than the minimization of this serious complication. There is a fundamental difference in concept between the DES and

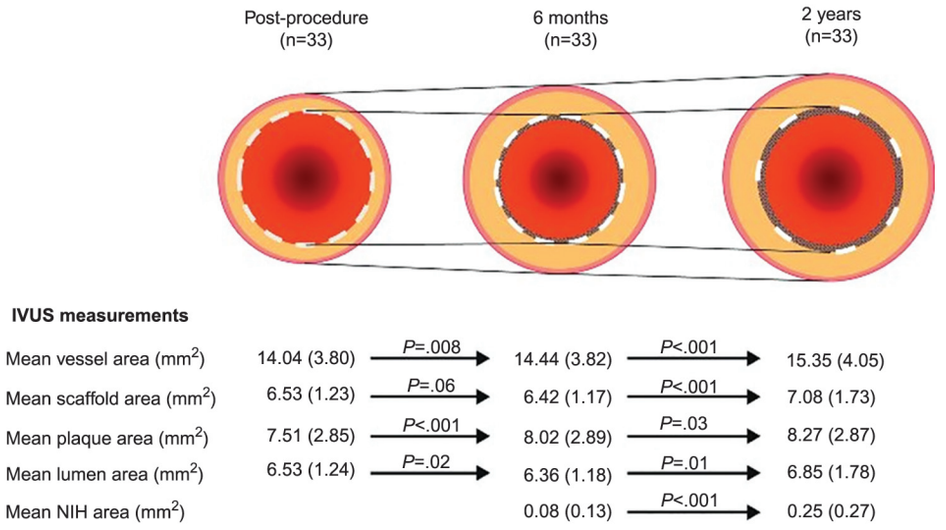

Fig. 6.22: Serial changes in intravascular ultrasound measurements over postprocedure, 6 months, and 2 years after absorb BVS implantation (NIH=neointimal hyperplasia, IVUS=intravascular ultrasound)



Fig. 6.23: Bioresorbable scaffolds under clinical or preclinical investigation

the BRS technologies, with the latter having a capability of liberating the vessel from a permanent metallic cage. Therefore, BRS technology has a theoretical advantage in reducing ST by means of endoluminal prosthesis elimination. BRS also facilitates the restoration of vasomotor function, which indirectly results in the completeness of vessel healing. The entire process of this treatment has been hence named as vascular reparative therapy.

Stents, particularly stents coated with materials to reduce inflammatory and cell growth responses, have resulted in greatly improved outcomes.

Technique of Atherectomy

As a result of technical challenges, suboptimal clinical outcomes, and the significant rates of restenosis following percutaneous coronary artery balloon angioplasty, two innovative types of devices were developed: those used for atherectomy and coronary stents.

The idea behind atherectomy devices was to physically remove atheroma, calcium, and excess cellular material from the site of a coronary occlusion or stenosis (Figs 6.32–6.34). Both mechanical and laser-based approaches are used. An alternative approach developed at about the same time was intracoronary stent placement, based on the notion that permanent implantation of a scaffold to hold open the coronary artery at the site of an intervention would improve outcomes. Long-term outcomes from atherectomy alone have been disappointing and, in most cases, little better than balloon angioplasty. The rotational atherectomy catheter (Rotablator) is designed for the removal of plaque from coronary arteries. This device, which has a diamond-studded burr at its tip, rotates at about 160,000 rpm and is particularly well-suited for ablation of calcific or fibrotic plaque material. Unlike other atherectomy devices that rely on tissue cutting, the rotational atherectomy device relies on plaque abrasion and pulverization. Rotational atherectomy is successful in 92–97% of these cases, with a low incidence of major complications. It causes dislodgement of particles into the microcirculation, which occasionally may lead to infarction and no reflow (impaired distal coronary flow). Currently, the use of rotational atherectomy is largely confined to fibrotic or heavily calcified lesions that can be wired but not crossed or dilated by a balloon catheter.

Long-term outcomes from atherectomy alone have been disappointing and little better than balloon angioplasty in most cases. Stents, particularly stents coated with materials to reduce inflammatory and cell growth responses, have resulted in greatly improved outcomes. Atherectomy is still used for specific, niche indications, but the most common intracoronary device used today is a stent.

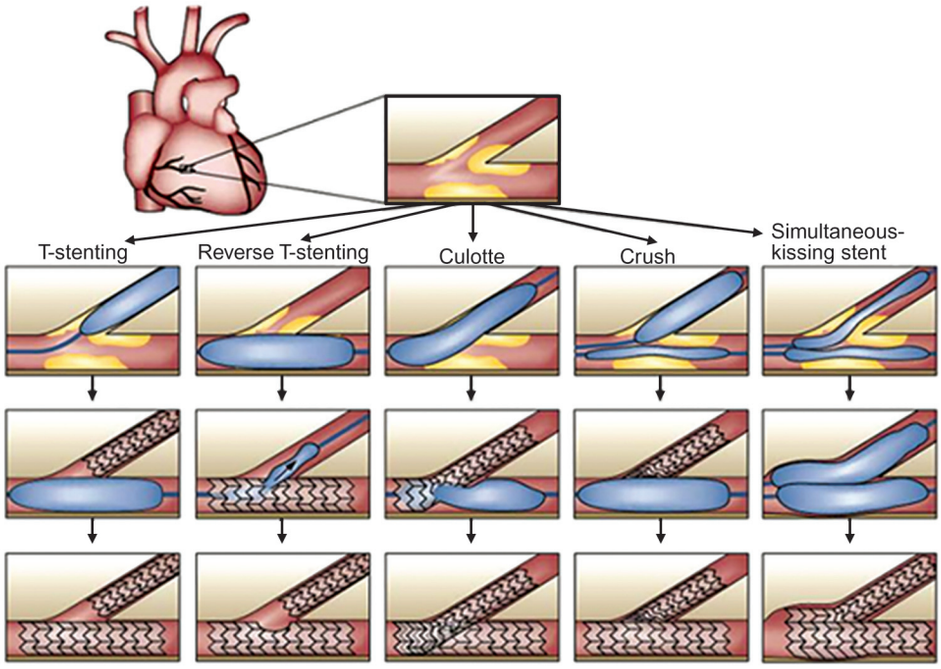

Fig. 6.24: Features of a bifurcated self-expanding coronary stent

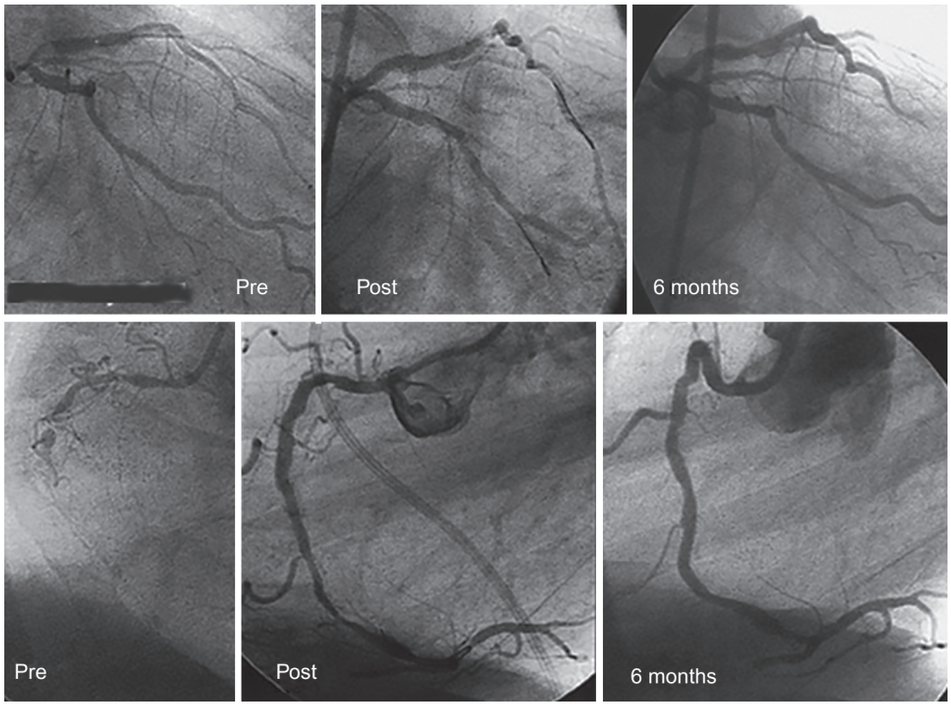

Fig. 6.25: A patient recently revascularized 20 years after the first angioplasty. The patient presents a severe bifurcation lesion in the left main coronary artery that is severely calcified. The right coronary artery also contains an occlusion that is more than 3 months old. The bifurcation of the artery is resolved by implantation of a rapamycin-coated stent close to the anterior descending artery and balloon angioplasty at the origin of the circumflex artery. The occlusion of the right coronary artery was crossed using a Safe-Cross radio frequency guidewire and the procedure was completed through implantation of rapamycin-coated stents. Excellent results were seen in both treated lesions by angiography at 6 months. The results obtained during follow-up would have been unthinkable 20 years earlier using percutaneous revascularization techniques

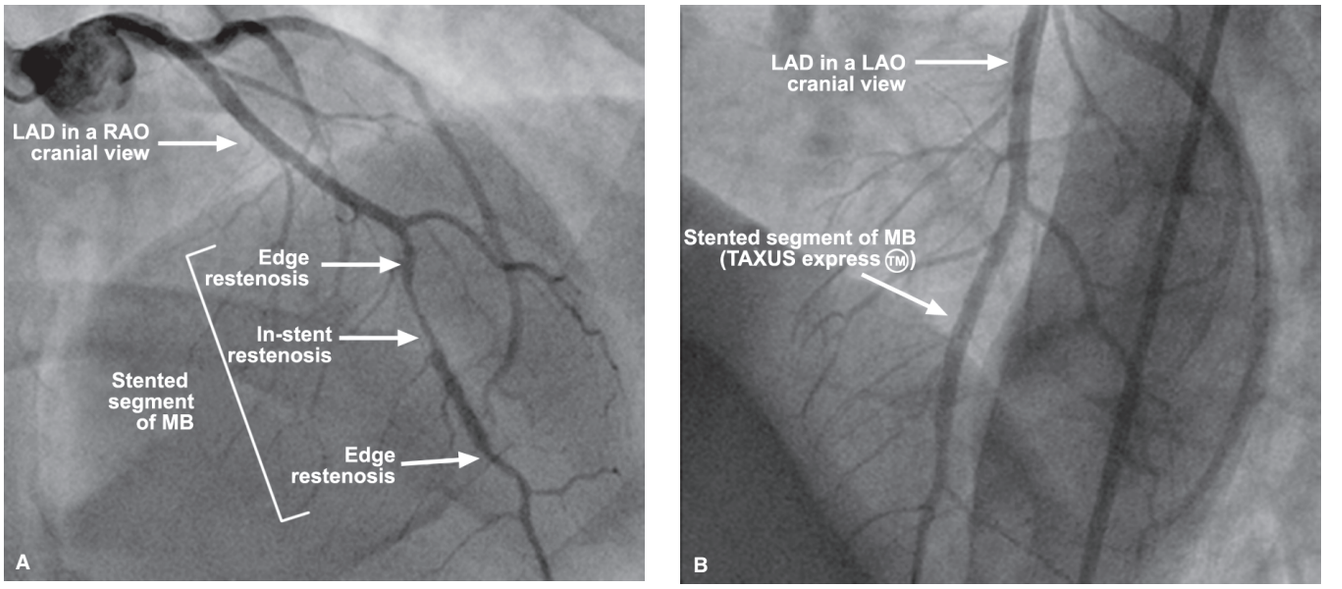

Fig. 6.26: (A) Stent restenosis of LAD artery in myocardial bridging, (B) successful stenting of segment in myocardial bridging (MB)

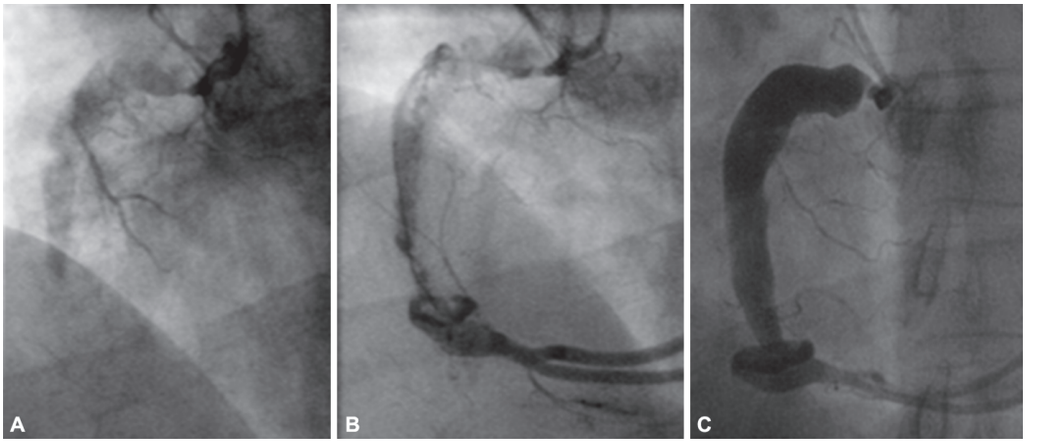

Fig. 6.27: Occlusion of the RCA. Angiogram of occluded right coronary artery (RCA) aneurysm in a 33-year-old man who experienced a Kawasaki disease—compatible illness at age 6 years (diagnosed as nonspecific viral illness) and was asymptomatic until his myocardial infarction. (A) Injection of the occluded RCA, (B) RCA after percutaneous transluminal coronary angioplasty with reestablished distal flow. Note smooth appearance of distal branches of the RCA, (C) Patent RCA aneurysm 1 month after percutaneous transluminal coronary angioplasty, aspirin, and warfarin therapy maintaining an international normalized ratio of 2–2.5

Intravascular Ultrasonography

Coronary angiography provides a display of luminal narrowing in multiple planes and is useful in guiding coronary interventions. However, angiography cannot provide information about the vessel wall, which is where the atherosclerotic process resides. Intravascular ultrasonography (IVUS) was developed to provide information about the plaque, the vessel wall, and the degree of luminal narrowing. It provides a tomographic cross-section of the vessel, allowing operators to gather significant qualitative and quantitative information that is potentially valuable in assessing stenosis severity and the true extent of atherosclerotic involvement of main vessel (Figs 6.35–6.38).

Identification of the lumen border and the media-adventitia interface form the key landmarks during interpretation. Plaque can be distinguished from the lumen by differences in echogenicity. In addition to providing information about the amount and distribution of plaque, IVUS can identify features of plaque composition, such as calcification and lipid collections, which may not be appreciated by angiography alone. Frequent uses of IVUS include the assessment of indeterminate lesions and the evaluation of adequate stent deployment. The latter has become increasingly important, since proper deployment of drug-eluting stents is critical to reduction in rates of thrombosis. Recent developments in ultrasonography (e.g.



Fig. 6.28: Youngest child to receive coronary stent Deepa alongwith her parents (street bender) in whom bioabsorable stent was fitted to open her coronary artery blocked due to familial hypercholesterolemia

virtual histology) and other technologies (e.g. optical coherence tomography, plaque thermography) have led to ways of characterizing and identifying vulnerable segments of plaque that may pose a risk for future cardiac events.

Comparison of (ERBAC), Excimer Laser, Rotational Atherectomy, and Balloon Angioplasty Study (Fig. 6.39)

This showed that rotational atherectomy was associated with a higher short-term success rate than balloon angioplasty (90% *vs* 80%), but major ischemic complications and repeat revascularization were higher 6 months after

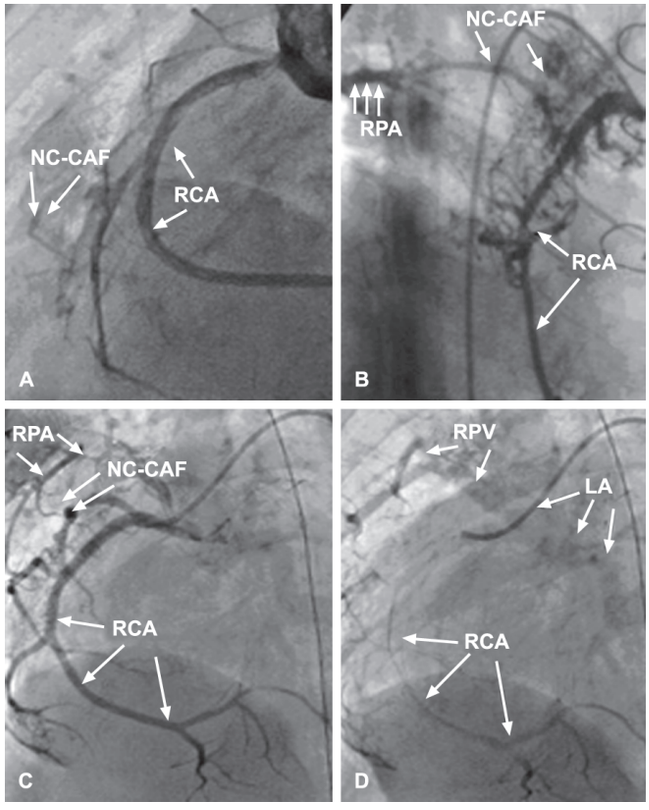

Fig. 6.29: Examples of noncameral coronary artery fistulae (NC-CAFs) are shown in 3 patients—(A) a small NC-CAF from the right coronary artery (RCA) with flow into the right lung field, but no clear identification of a pulmonary vessel; (B) a moderate NC-CAF with a diffuse connection originating from the RCA and filling an identifiable right pulmonary artery (RPA) branch; and (C–D) a large NC-CAF from the RCA (C) filling a RPA branch, (D) and then on levophase of the same angiogram

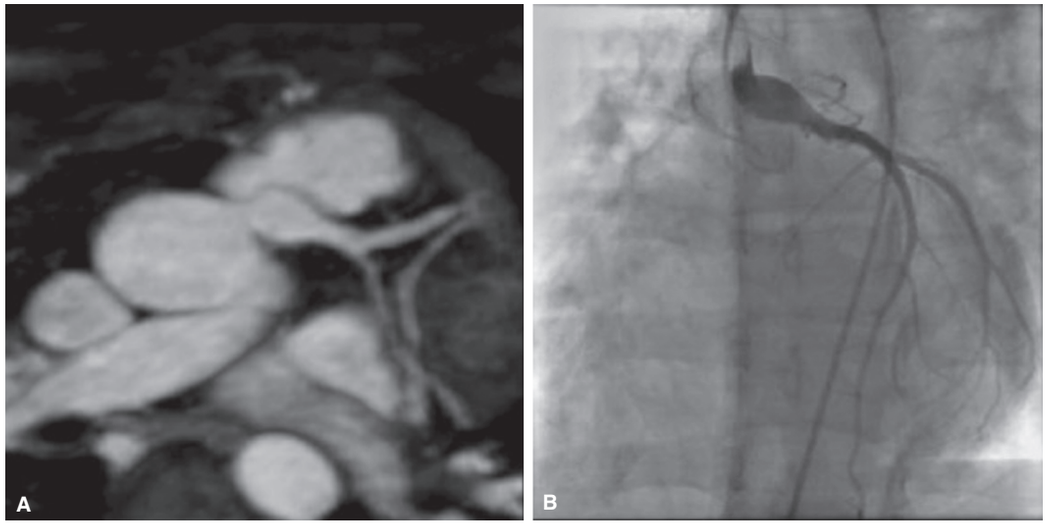

Fig. 6.30: 3D b-SSFP whole heart images, magnetic resonance coronary angiography (MRCA)—(A) shows large patent, reconstructed, reimplanted left coronary artery into the left coronary sinus. (B) Findings confirmed on X-ray coronary angiography

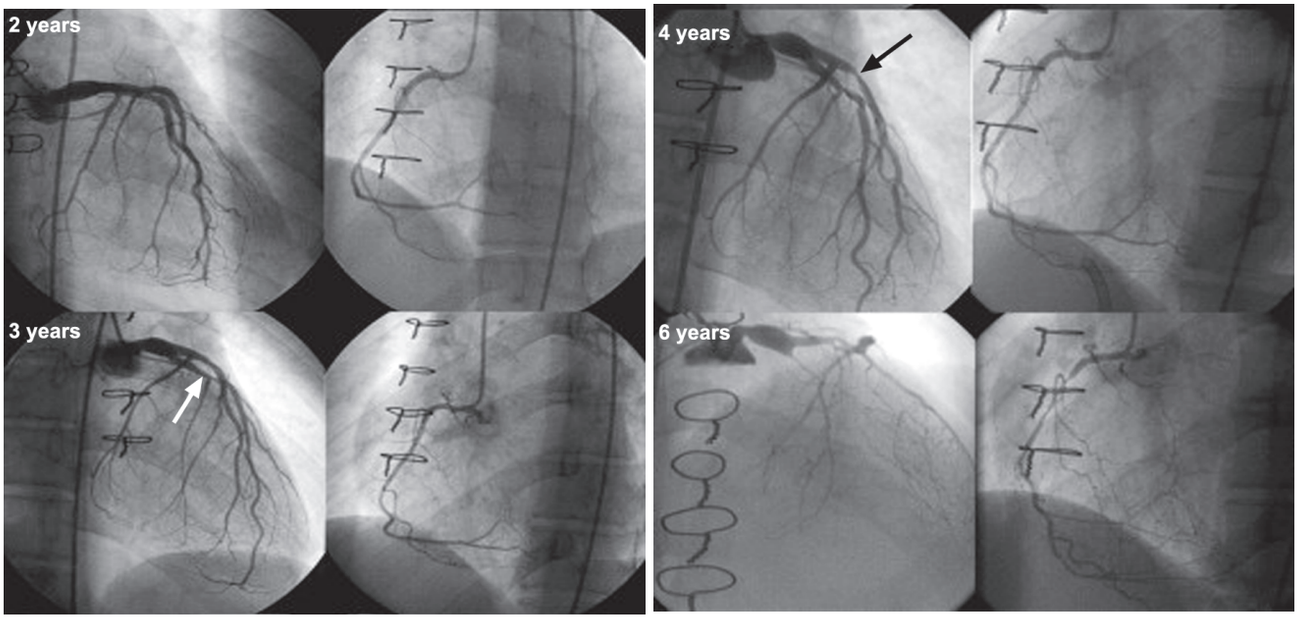

Fig. 6.31: The progressive nature of allograft vasculopathy. At 2 years after heart transplantation, there is ectasia of the left main coronary artery but no evidence of allograft vasculopathy. At 3 years, the left anterior descending coronary artery developed mild disease at the bifurcation of the septal artery (white arrow). At 4 years, the first obtuse marginal branch of the circumflex has an additional lesion (black arrow). At 6 years, the left anterior descending coronary artery is occluded totally and the circumflex is diseased severely. The right coronary artery is also diseased diffusely, including the smaller secondary branches, with abrupt cut-off in some of them. Unfortunately, this patient had a fatal myocardial infarction a few weeks after

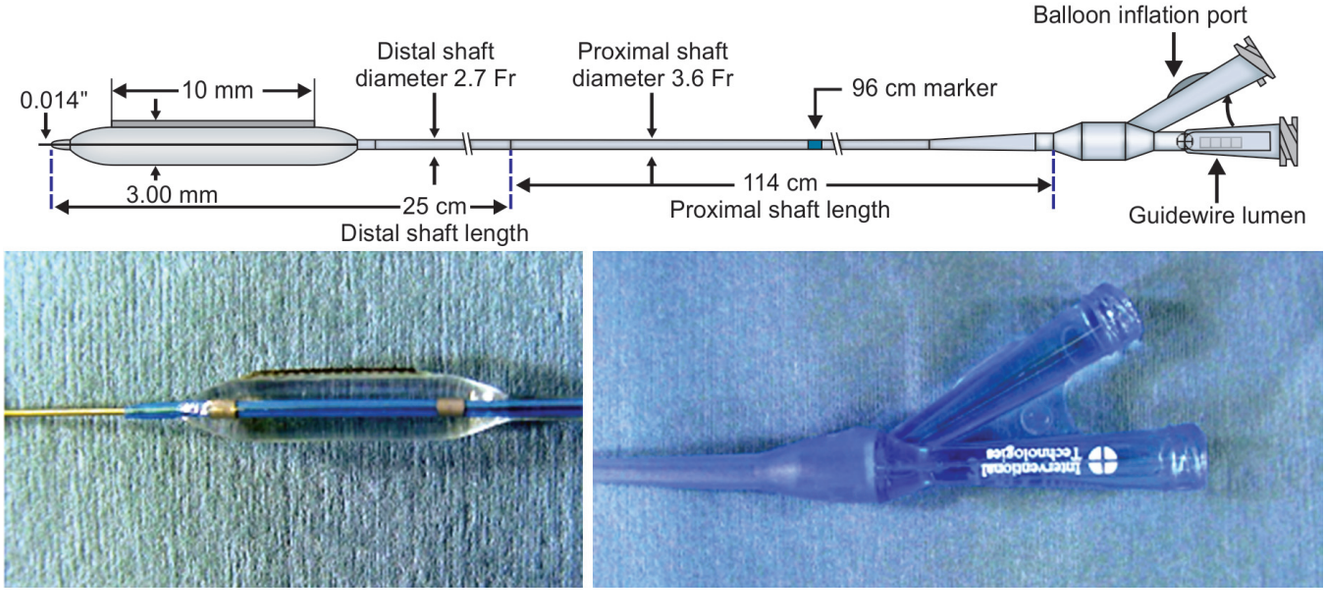

Fig. 6.32: Atherotomy device. The SBC is an over-the-wire type catheter with a single blade attached to the surface of a noncompliant balloon. The blade is 10 mm in length and runs along the same side and axis as the balloon inflation port. The polysulfone balloon shaft is 3.6 Fr proximal and 2.7 Fr distal and is compatible with a 6 Fr guiding catheter. The working height and width of the blade are identical to those used for the current cutting balloon, namely 0.005-0.006 inches in height and 0.003 inches thick

treatment (46% vs 37%). A meta-analysis failed to show any significant difference in mortality, major adverse cardiovascular events (MACE), or revascularization rates in patients treated with rotational atherectomy, laser, or cutting balloon angioplasty when compared with balloon angioplasty alone. In some cases, rotational atherectomy was actually associated with an increase in periprocedural myocardial infarction. However, none of these trials compared stent-related outcomes. In fact, many of these devices may be used to facilitate stent delivery in complex lesions, especially when balloon angioplasty alone has failed. Since 1987, directional coronary atherectomy (DCA) has been used to debulk coronary plaques. A steel fenestrated cage housing a cup-shaped blade is positioned

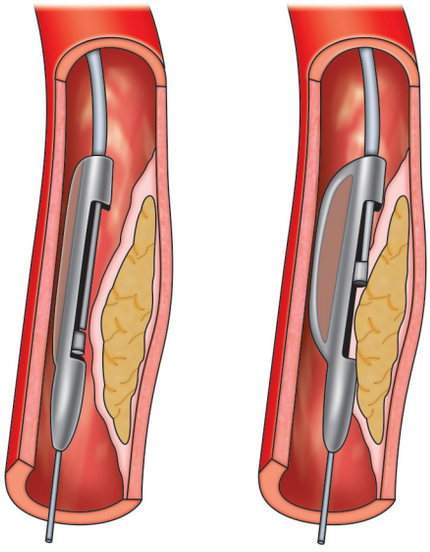

Fig. 6.33: Working of directional atherotomy device in removing the plaque from the occluded artery

against the coronary lesion by a low-pressure positioning balloon, allowing any protruding plaque to be removed.

Atherectomy is typically followed by balloon dilation and stenting. The acute gain, therefore, is a combination of the removal of atheromatous plaque and radial displacement of plaque from dilation. Major complication rates associated with directional atherectomy are low and similar to those associated with conventional balloon angioplasty. Other complications (e.g. distal embolization of plaque, transient side-branch occlusion, coronary vasospasm, the no-reflow phenomenon, non-Q-wave myocardial infarction) are greater with DCA than with balloon angioplasty. Because of the increased complication rates and the greater technical demands of DCA compared with balloon angioplasty or stenting, the use of DCAs has greatly decreased in recent years. A 2006 meta-analysis demonstrated that DCA is superior to stenting alone with regard to acute angiographic results and target-lesion revascularization with a similar prevalence of late MACEs. There was, however, a higher prevalence of early MACEs with DCA before stenting, which probably related to distal embolization Although initial excitement about the development of laser atherectomy was considerable, it is not used widely because of the technical demands of this device and no clear improvements in outcome over therapy with other devices.

POST-PROCEDURE OUTCOME OF PCI

A major 2009 task force report viewed favorably, in general, the use of coronary revascularization for patients with acute coronary syndromes and combinations of significant symptoms and/or ischemia. However, revascularization of asymptomatic patients or patients with low-risk findings on noninvasive testing and minimal medical therapy were viewed less favorably (Figs 6.40–6.44).

FIRST-IN-HUMAN EVALUATION OF A NOVEL ROBOT-ASSISTED CORONARY ANGIOPLASTY SYSTEM

The main aim of a novel robotic-assisted coronary angioplasty is to evaluate the safety and feasibility of a robotic angioplasty system in delivery and manipulation of coronary guidewires, balloons, and stents in patients undergoing elective percutaneous coronary intervention (PCI) (Fig 6.45).

Background

A remote-control, robotic-assisted angioplasty system is under development to address some of the procedural challenges and occupational hazards associated with traditional PCI.

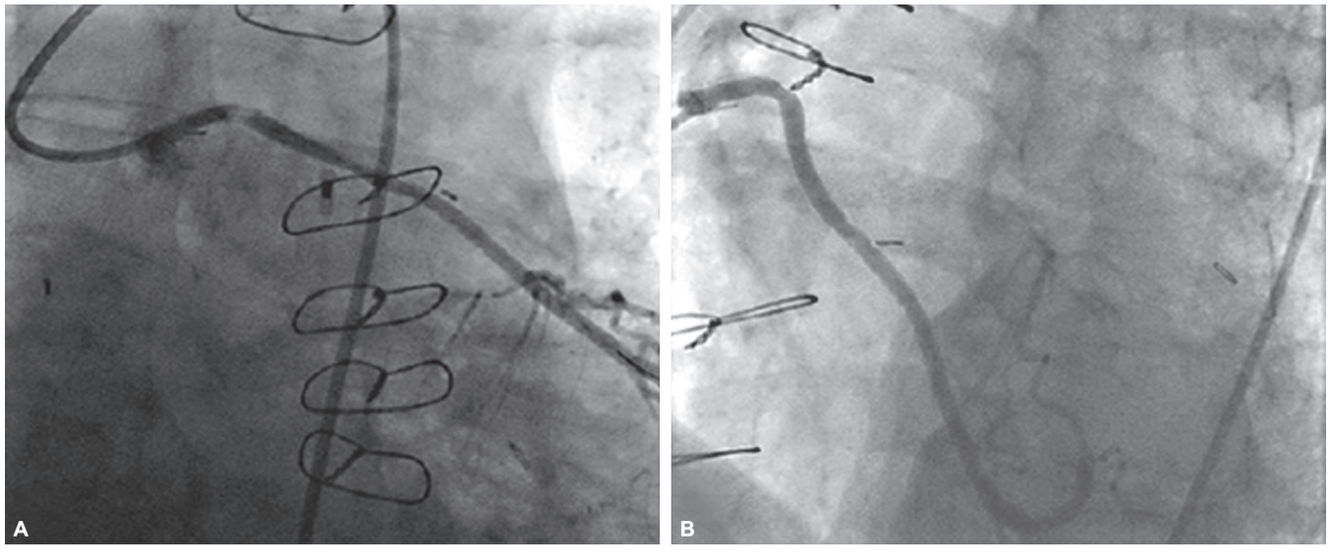

Fig. 6.34: (A) Vein graft deply intubated to allow the Rotablator burr to be advanced, (B) final result after rotational atherectomy and stent placement

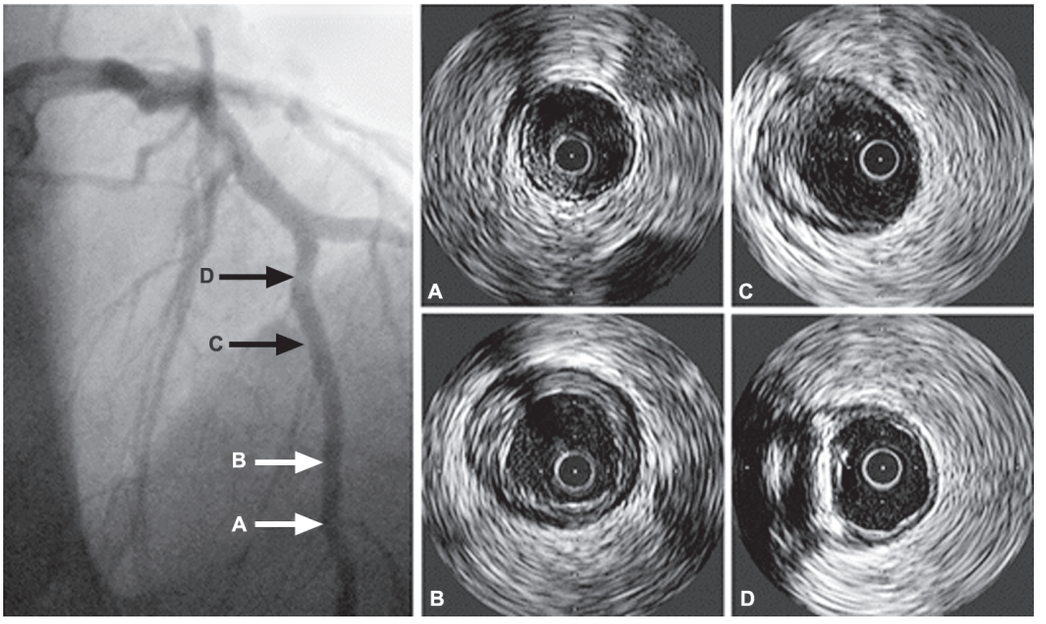

Fig. 6.35: Intravascular ultrasound (IVUS) at multiple sites in an angiographically normal artery. The 4 images obtained from sites A through D exhibit various degrees of atherosclerotic involvement, despite a normal-appearing angiogram. The IVUS images were obtained via a motorized pullback

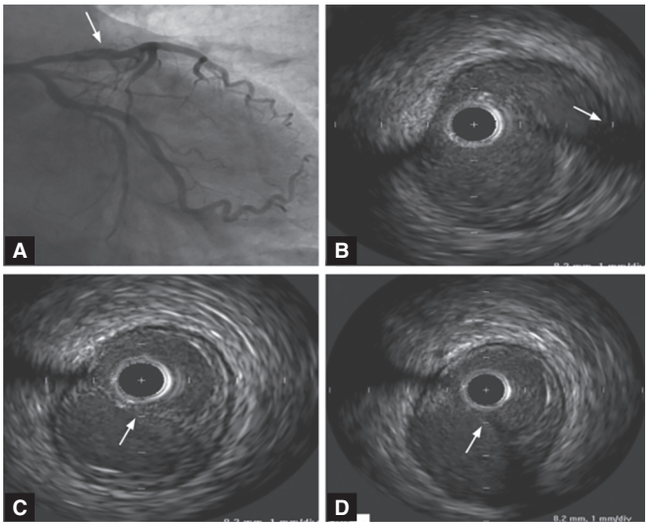

Fig. 6.36: (A) Intimal dissection (arrow) in proximal left anterior descending artery (LAD) by coronary angiography, (B) entry (arrow) of intimal tear of the proximal to dissection site in the LAD by intravascular ultrasonography (IVUS), (C) intimal flap (arrow) dividing between true lumen and false lumen in the dissection site by IVUS, (D) reentry (arrow) of intimal tear of the distal to dissection site by IVUS

Clinical Utility of Robotic Systems

Robotic systems have been suggested to enhance the precision of cardiovascular procedures with increased accuracy. One of the technical features of the robotic system is the capability to control and accurately position (1 mm steps) the stent delivery system. The recent stent deployment techniques on clinical outcomes of patients treated with the cypher stent (STLLR) trial highlighted the impact on clinical outcomes of geographic miss and stent misplacement. Although endovascular imaging guidance is likely necessary to improve the precision of stent placement, the robotically assisted system facilitates the positioning of the stent delivery system with a high degree of accuracy. In addition, robotic systems have been suggested to reduce radiation exposure.

Despite the significant evolution in interventional device technologies, the actual procedural methodology and workflow in the catheterization laboratory has remained unchanged in the last 25 years. As the current practice of interventional cardiology evolves into more complex PCI procedures, interventional cardiologists, the professional societies US Food and Drug Administration, and International Atomic Energy Agency called for enhanced catheterization laboratory safety by reducing radiation exposure to both patients and operators and making the overall catheterization laboratory environment more ergonomically friendly through technological innovations. Incorporating a remote-control, robotic-assisted PCI system into the catheterization laboratory might address some of the procedural deficiencies and occupational hazards associated with traditional PCI in addition to contributing to a higher degree of precision and control for the interventional procedure.

Technique of Robot-assisted Coronary Angioplasty

Patients with coronary artery disease and clinical indication for elective PCI were enrolled. The coronary angioplasty procedure was performed with the CorPath 200 robotic system (Corindus, Inc., Natick, Massachusetts).

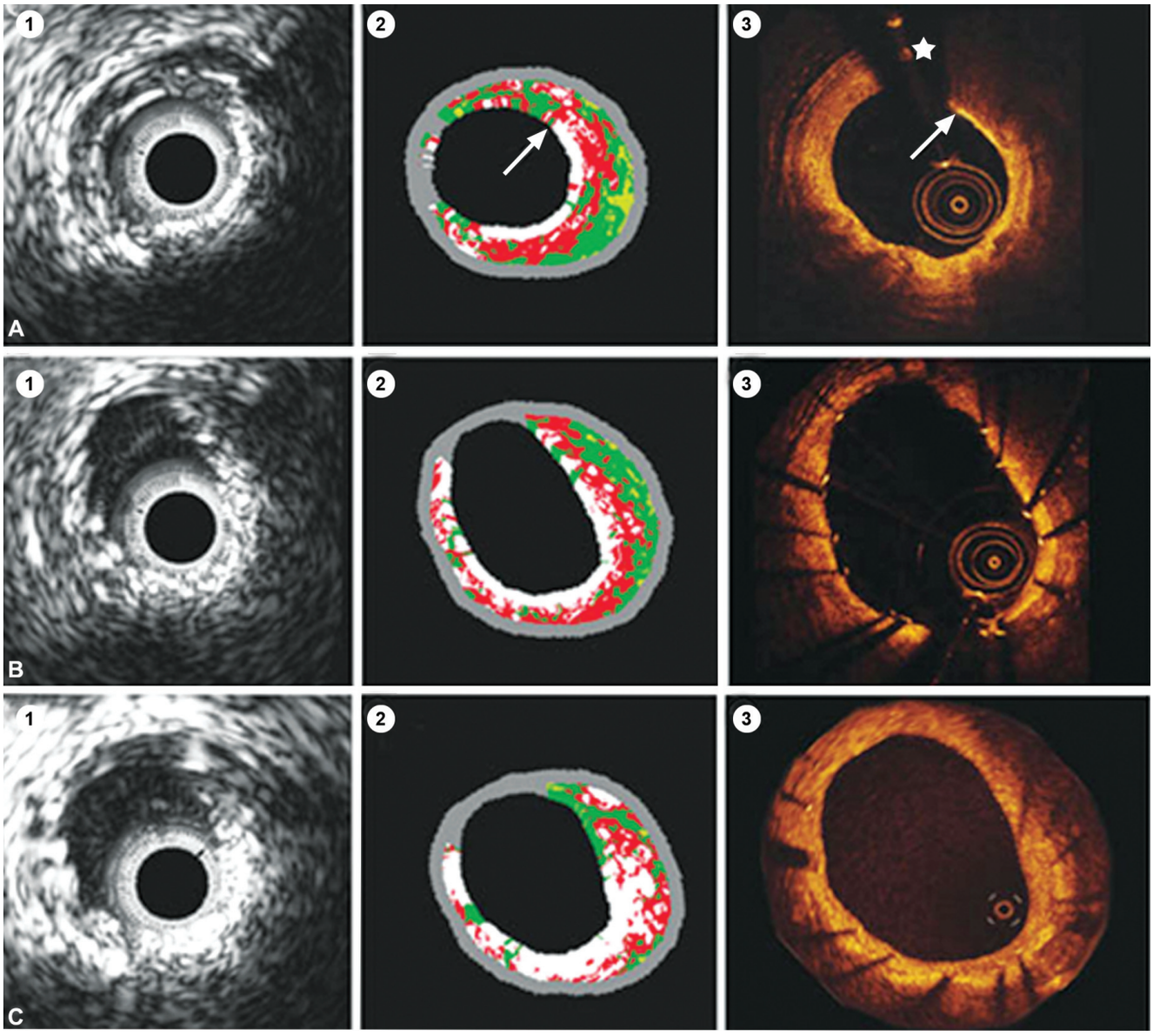

Fig. 6.37: Matched grayscale IVUS (1), IVUS-VH (2) and OCT (3) images of the IVUS-derived, thin-capped fibroatheroma (A) before stenting with the vProtect® Luminal Shield, (B) immediately after treatment with the vProtect® Luminal Shield and (C) at the 6-month follow-up appointment. The arrow in panel-A part 2 indicates the necrotic core in contact with the lumen. The arrow in panel-A part 3 indicates the thin fibrous cap, and the asterisk indicates a guidewire artifact. In the IVUS-VH images (parts 2): red, necrotic core; dark green, fibrotic tissue; light green, fibrofatty tissue; and white, dense calcium. IVUS=intravascular ultrasound; IVUS-VH=intravascular ultrasound virtual histology; OCT=optical coherence tomography

The system consists of a remote interventional cockpit and a multicomponent bedside unit that enables the operator to advance, retract, and rotate guidewires and rapid exchange catheters. The primary endpoint was device clinical success (30% residual stenosis) without in-hospital major adverse cardiac events. Technical success was defined as the ability of the system to complete all the planned angioplasty steps on the basis of procedural segments. Patients were followed up to 30 days after angioplasty procedure.

The retrospective evaluation study of lens injuries and dose (RELID) study revealed that interventional cardiologists have cataract-type eye opacities 3 times more often than age-matched controlled group. The mean fluoroscopy time from this study compares favorably with the results of the study of 9,650 patients undergoing single-vessel PCI (11.5 min *vs* 18.3 min) and with a subgroup of 7,242 patients whose fluoroscopy time was 23 minutes (11.5 min *vs* 12.7 min). Shorter fluoroscopy time translated into reduced radiation exposure for the patient and the

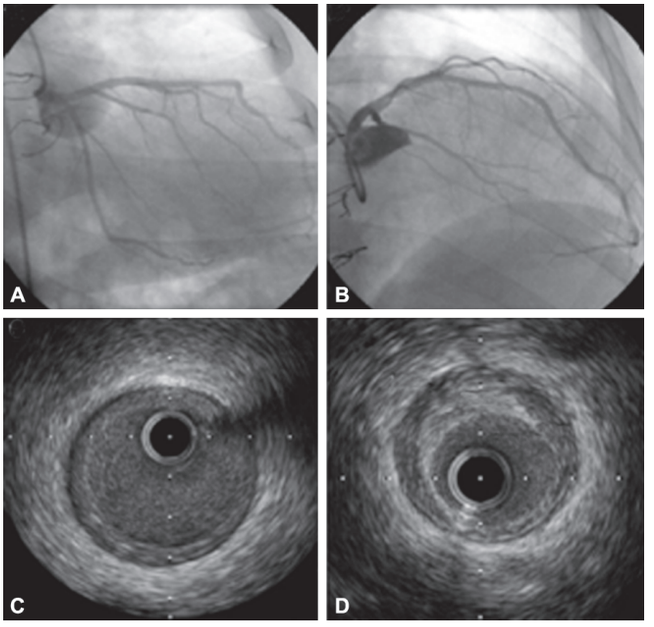

Fig. 6.38: (A and B) Coronary angiography did not suggest disease in this artery, (C) intravascular ultrasound images of the anterior descending artery in a patient transplanted 5 years previously, showing both the concentric intimal thickening typical of cardiac allograft vasculopathy and (D) an eccentric plaque typical of atherosclerotic coronary disease

operator and reduced contrast fluid usage. In our study, 1 of the most important findings was the significant (97.1%) reduction in radiation exposure to the operator performing the robotic PCI procedure. The patient radiation exposure was within the normal reported limits—2.1 Gy *vs* 1.9 Gy. Also, although the study was not designed to show differences in contrast volume usage, the total volume of contrast agents used in this study seemed to be less, compared with what has been reported in other clinical series. The lower contrast usage might be attributed to the complete procedure control enabled by the interventional cockpit environment. Another subjective but still important finding was the level of technical 'comfort' expressed by the operators. Although no specific measurement of this variable was used in this study, both operators perceived this system to be more comfortable compared with the typical technique used for coronary intervention. Most of the cases were performed under a controlled environment, in which the operator had the opportunity to focus on the performance of the procedure, having a close proximity of the monitors and not distracted by the physical strain of the lead apron and standing position.

In early clinical experience, the use of the robotic system seems not to reduce the overall periprocedural times compared with manual PCI of single lesions. However, we believe that, as this technology underwent initial clinical

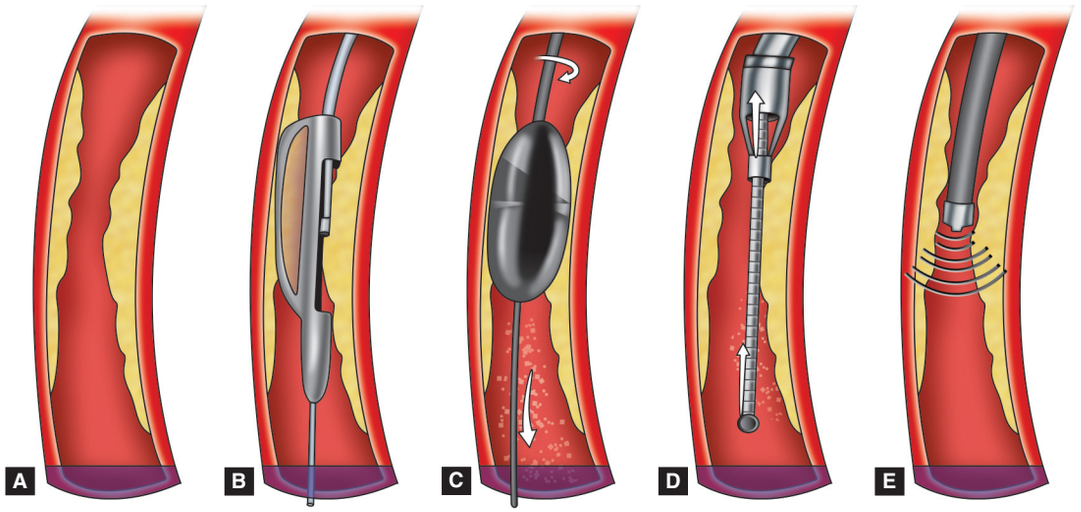

Fig. 6.39: (A) Atherectomy—this is a minimally invasive procedure that involves the use of specialized catheters for mechanical removal of plaque from the arterial walls. The plaque is either scraped out or pulverized with the help of tiny blades. The design and working of these devices ensures that the arterial wall remains damage-free. The catheter is inserted into an artery in the leg or arm, through an incision in the groin or wrist. It is then routed to the blockage site, and the plaque is mechanically scraped out. Depending on the type of device or catheter used, atherectomy procedures employed are: (B) Directional—here, the catheter has a scraping blade attached to it along with a low pressure balloon on the opposite side. Once at the blockage site the balloon is inflated, as a result of which the blade is pushed towards the plaque. The plaque is then scraped out, and the catheter is rotated to ensure complete plaque removal. The plaque fragments are collected in a chamber present at the tip of the device. (C) Rotational—a rotational atherectomy catheter has small, diamond-tipped, rotating edges which disintegrate the plaque into microscopic fragments. These fragments flow through the circulatory system, and are removed from the body through normal waste-removal processes. (D) Transluminal extraction—the catheter used in this procedure has two stainless steel, rotating blades attached to a hollow tube. At the site of blockage, the rotating blades grind the plaque, and the resultant fragments are collected into the hollow tube by vacuum suction. (E) Laser—in this procedure, a laser-tipped catheter is used to vaporize the plaque. The resultant molecules are removed by the body via liver and kidneys

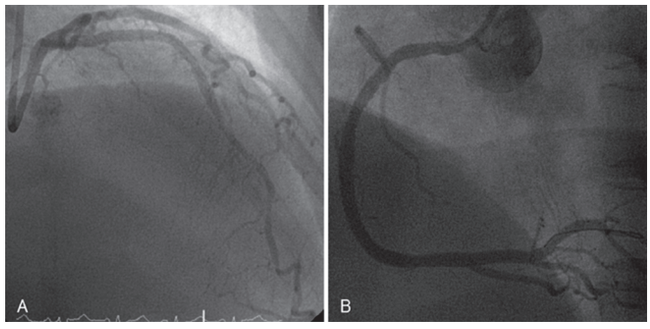

Fig. 6.40: CAG showed no residual stenosis in each lesion after two Cypher stents (Cordis/Johnson & Johnson, USA) were implanted in the lesions. (A) Post-PCI angiography revealed well-deployed SES in midportion of the LAD. (B) post-PCI angiography revealed well-deployed SES in mid-portion of the RCA. CAG=coronary angiography, PCI=percutaneous coronary intervention

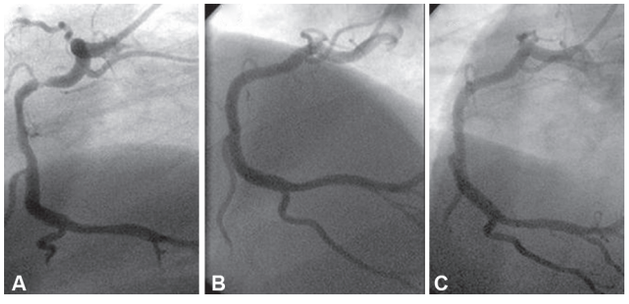

Fig. 6.41: (A) Severe lesion in the middle right coronary artery, (B) immediate direct postimplantation of a 4 × 15 mm driver stent, (C) angiographic control at 6 months' follow-up

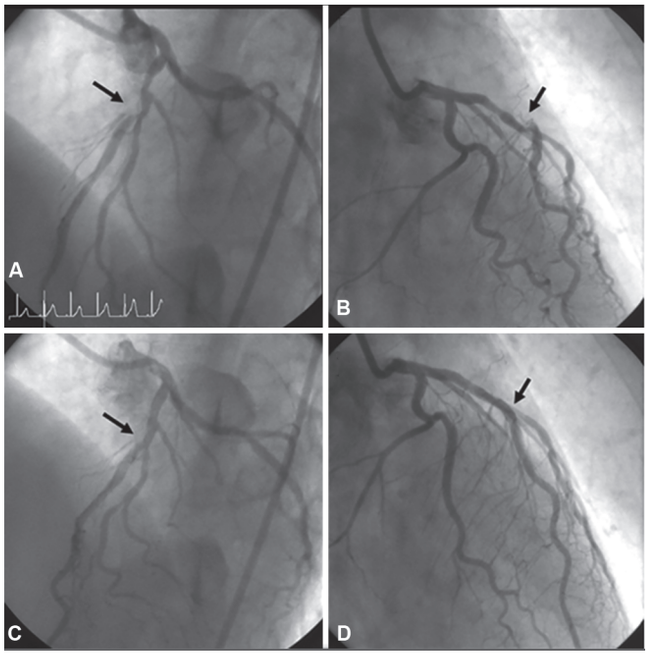

Fig. 6.42: (A and B) The left coronary angiography showed significant stenosis in m-LAD, (C and D) After deployment of 3.0 × 28 mm Cypher stent in this lesion, angiography showed no residual stenosis with good distal flow

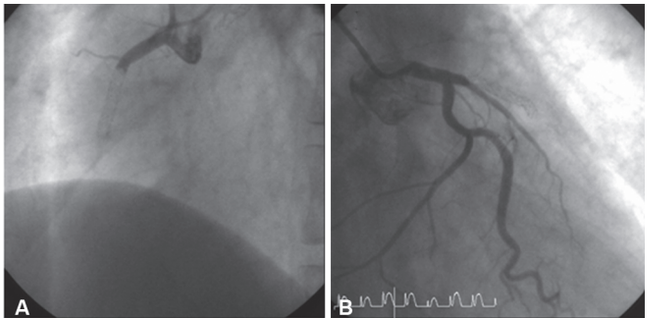

Fig. 6.43: The emergency coronary angiography revealed totally occluded proximal LAD and proximal RCA at the same time, the sites of the implantation of sirolimus-eluting stents. (A) LAO view of RCA, (B) RAO caudal view of LAD

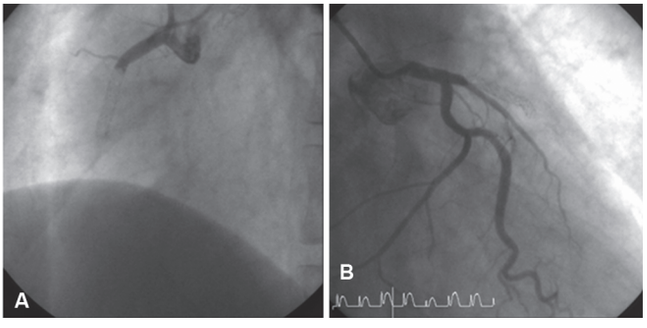

Fig. 6.44: A 28 mm stent deployment in a patient specific right coronary artery. The expansion is projected to the angiographic image

evaluation, the rigor of the study procedure in addition to the time required to register the data added additional procedural time. In addition, from the operator point of view, there was an initial learning and technology adaptation curve that we believe will improve over time, leading to shorter procedural times. However, this study still represents an early feasibility study in a small cohort of patients, and the use of this technology in more challenging anatomies including the presence of severe tortuosity, severe calcification, or interventions requiring multiple wires and balloons needs to be further studied. A larger, prospective, multicenter pivotal clinical trial designed to test the robotic angioplasty system in a larger number of patients is underway.

Ancillary Devices

Thrombus extraction catheters: In addition to balloons, stents, and atherectomy devices, other devices such as thrombus extraction catheters and distal embolic protection devices have found roles in PCI. In the TAPAS trial (thrombus aspiration during percutaneous coronary intervention in acute myocardial infarction), which studied the use of thrombus aspiration during primary PCI for ST-elevation myocardial infarction, thrombus aspiration with an export catheter before stenting had a reduced all-cause mortality (4.7% *vs* 7.6%) and reduced cardiac death (3.6% *vs* 6.7%) at 1 year compared with conventional PCI.

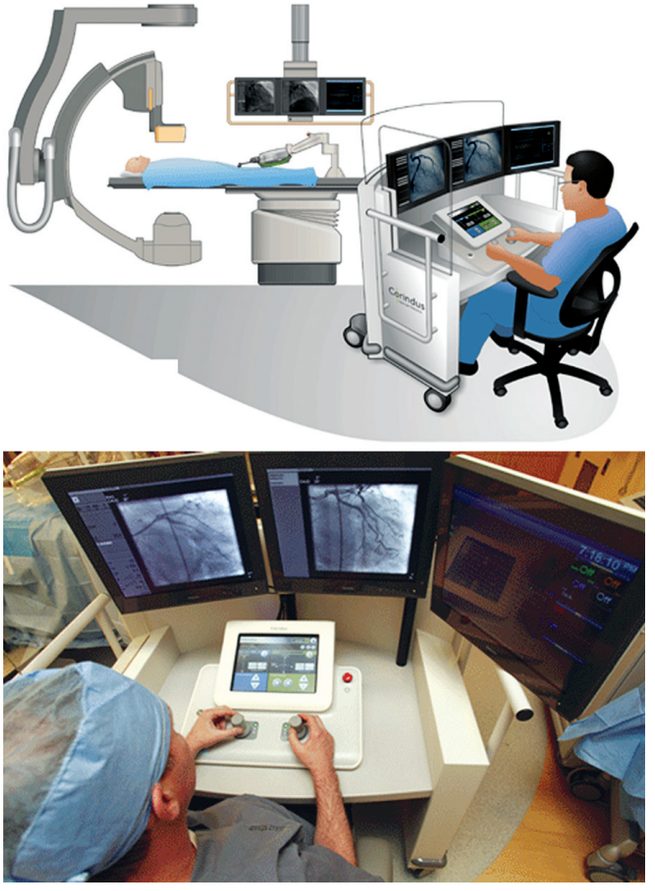

Fig. 6.45: Method of performing robot-assisted coronary angioplasty

In a pooled analysis of data from 3 prospective randomized trials, De Vita et al. found that although increasing time to treatment was associated with a decreased rate of optimal reperfusion in patients receiving standard PCI, this trend was not seen in patients treated with thrombus aspiration. De Vita et al. concluded that the use of thrombus aspiration limits the adverse effects that prolonged time to treatment has on myocardial reperfusion. The use of distal embolic protection during saphenous vein graft intervention has become the standard of care. The SAFER trial (saphenous vein graft angioplasty free of emboli randomized) initially proved the benefit of embolic protection in reducing 30-day rates of major adverse cardiac events (MACE) (9.6% *vs* 16.5%, P=0.004), myocardial infarction (8.6% *vs* 14.7%), and no reflow (3% *vs* 9%) (Figs 6.46–6.48).

Stable Angina (PCI *vs* Medical Therapy)

Early trials demonstrated the benefit of percutaneous coronary intervention over medical therapy for symptomatic angina in single and multivessel coronary artery disease, with improvements in symptoms, reduction in need to take antianginal medications, improvement in exercise duration, and similar survival rates to medical therapy.

The randomized intervention in the treatment of angina (RITA-II) study demonstrated that balloon angioplasty results in better control of ischemic symptoms and greater improvement in exercise capacity than does medical therapy, but balloon angioplasty is associated with an increased incidence of the combined endpoint of death and myocardial infarction.

In RITA-II, in which 1018 patients with stable angina were randomized to balloon angioplasty or medical therapy, death or definite myocardial infarction occurred in 6.3% of the balloon angioplasty patients and in 3.3% of the medical patients; only 44% of the deaths were actually due to heart disease. Angina improved in both groups, but a 16.5% absolute excess of grade 2 or worse angina occurred in the medical group 3 months following randomization.

In the RITA-II study, 23% of the medical group required revascularization during follow-up. During follow-up, 7.9% of the angioplasty patients required bypass surgery,

The GuardWire system for coronary thrombosis aspiration

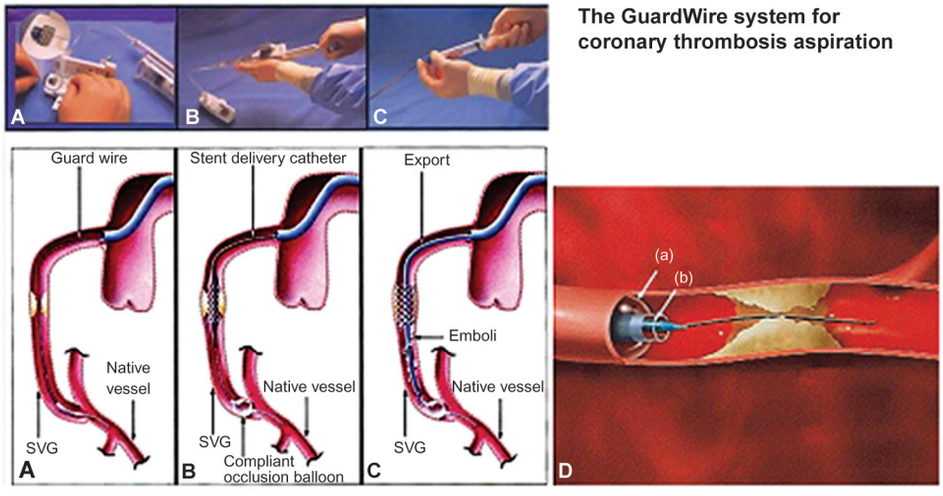

Fig. 6.46: The GuardWire system. Upper panel corresponds to lower panel—the GuardWire, used to cross the lesion, is inserted into the microseal adapter (A), connected to the EZ flator, which is inflated to occlude the vessel (B), debris is aspirated using the export aspiration catheter (C), SVG=saphenous vein graft (D). The Proxis system is delivered through a guiding catheter, and the sealing balloon (a) is inflated proximal to the stenosis, arresting flow, and debris aspirated through the Proxis system (b)

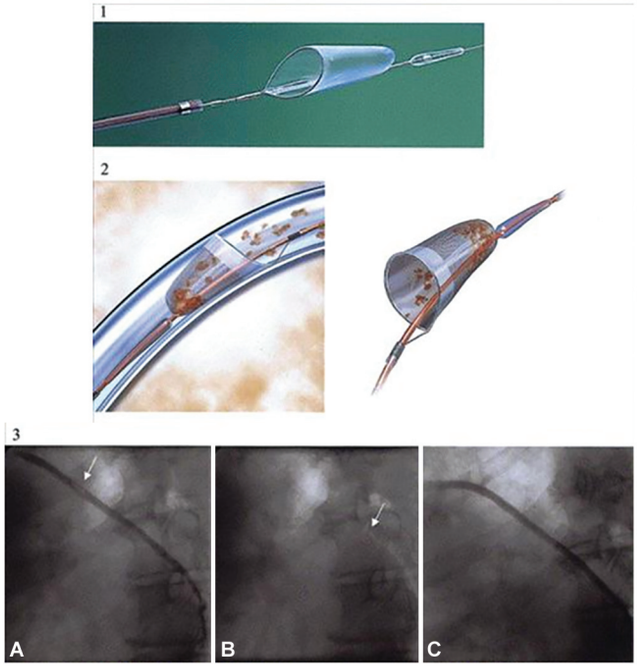

Fig. 6.47: The Filterwire system (Panel 1). The polyurethane porous membrane filter attached to a nitinol loop (Panel 2). The filter is deployed distal to the lesion, and the nitinol loop self-expands to fit the vessel upon retraction of the delivery sheath (Panel 3). (A) Saphenous vein graft containing thrombus, seen as intraluminal filling defect, (B) treated with percutaneous coronary intervention using filterwire protection, (C) achieving a good result after stenting

compared with 5.8% of the medically treated patients. Although the patients in RITA-II were asymptomatic or mildly symptomatic, it is important to emphasize that most had severe anatomic coronary artery disease; 62% had multivessel coronary artery disease, and 34% had important disease of the proximal left anterior descending artery.

In the atorvastatin versus revascularization treatment (AVERT) trial, after 18 months of follow-up, 13% of the medically treated group had ischemic events, compared with 21% of the angioplasty group, suggesting that in low-risk patients with stable coronary artery disease, aggressive lipid-lowering therapy may be as effective as balloon angioplasty in reducing ischemic events. In the study, 341 patients with stable coronary artery disease symptoms, normal left ventricle (LV) function, and class I or II angina were assigned randomly to balloon angioplasty or medical therapy with atorvastatin.

Based on the limited data available from randomized trials comparing medical therapy with balloon angioplasty, considering medical therapy seems prudent for the initial management of most patients with Canadian Cardiovascular Society Classification Class I and II symptoms, and reserving percutaneous or surgical revascularization is appropriate for patients with more severe symptoms and ischemia.

The clinical outcomes utilizing revascularization and aggressive drug evaluation (COURAGE) trial demonstrated that in patients with stable angina symptoms and coronary artery stenosis, medical therapy alone may be an appropriate strategy if medical therapy can control the angina symptoms. The trial randomized the addition of percutaneous coronary intervention to intensive pharmacological therapy, with the endpoints of death from any cause and nonfatal myocardial infarction during a median follow-up period of 4.6 years. Inclusion criteria for the study included patients with a 70% or greater lesion in onr or more proximal epicardial arteries, AHA/ACC Class I or II indications for PCI, and objective evidence of myocardial ischemia on stress testing. Both primary endpoints demonstrated no statistical benefit between those patients who received PCI with medical therapy and those who received only medical therapy (19.0% *vs* 18.5%).

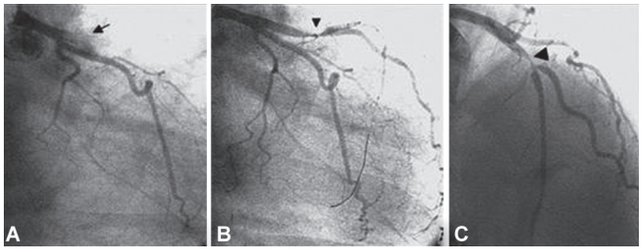

Fig. 6.48: Coronary angiogram in acute anterior myocardial infarction. The basal angiogram (A) shows total occlusion of the left anterior descending artery (LAD) with thrombus image bulging into the left main artery (arrow). After thrombus removal (B and C), the culprit lesion (arrowheads) is observed in the mid-LAD more than 20 mm distal to the original occlusion site

Teo et al. found that in older patients with stable coronary artery disease, optimal medical treatment without percutaneous coronary intervention remains an appropriate initial management strategy. Analysis of 904 patients aged 65 years or older showed that, during a median 4.6 year follow-up, clinical outcome in patients randomized to optimal medical treatment plus PCI was no better or worse than in patients who received optimal medical treatment alone. Compared with 1381 patients younger than 65 years with coronary artery disease, older patients had similar success in achieving treatment targets and similar rates of myocardial infarction, stroke, and major cardiac events, although the death rate was 2- to 3-fold higher in the older patients.

This analysis was done from patients enrolled in the COURAGE trial, and thus the limitations of that study have to be kept in mind, including the following:

- All patients had angiography prior to enrollment
- Only 1 in 12 patients who were screened were actually enrolled
- At the time of enrollment, most patients were either asymptomatic or had minimal symptoms overall, medical therapy is recommended as first-line therapy in patients with stable angina unless the following occur: a change in symptom severity, failed medical therapy, high-risk coronary anatomy, or worsening LV dysfunction, which provide an indication for cardiac catheterization and PCI of coronary artery bypass graft.

Stable Angina (PCI *vs* Surgical Revascularization)

Two prospective clinical trials have evaluated balloon angioplasty versus surgery for revascularization of isolated left anterior descending coronary artery disease. Using a combined endpoint (cardiac death, myocardial infarction, or refractory angina requiring revascularization by surgery), the medicine, angioplasty, or surgery study (MASS) showed, after 3 years of follow-up, that endpoint events occurred in 24% of angioplasty patients, 17% of medical patients, and 3% of surgical patients. However, overall survival rates between the 3 groups were similar.

The other trial compared balloon angioplasty and bypass surgery with an internal mammary artery graft to the LAD artery and also showed no difference in survival during follow-up. Although 94% of the angioplasty patients and 95% of the bypass patients were free of limiting symptoms, those treated by angioplasty required more antianginal drugs. At median follow-up of 2.5 years, 86% of the surgery patients were free from late events, compared with 43% of angioplasty patients. This difference was primarily due to restenosis requiring a second revascularization procedure. Emphasizing that balloon angioplasty, rather than stent placement, was used in these trials is important; thus, current rates of restenosis with stenting should be lower.

Five large (>300 patients) randomized trials comparing balloon angioplasty with bypass surgery in patients with multivessel coronary artery disease all showed that in appropriately selected patients, the incidence rates of death or of myocardial infarction were similar regardless of whether balloon angioplasty or bypass surgery was used. However, more patients treated with angioplasty required a second revascularization procedure.

In the bypass angioplasty revascularization investigation (BARI), 5-year survival was 86.3% for those assigned to angioplasty versus 89.3% for those assigned to surgery, and 5-year freedom from Q-wave myocardial infarction was 78.7% and 80.4%, respectively. However, after 5 years of follow-up, 54% of those assigned to angioplasty required an additional revascularization procedure, compared with only 8% of those assigned to surgery.

In a similar manner, the 3-year follow-up of the argentine randomized trial of percutaneous transluminal coronary angioplasty versus coronary artery bypass surgery in multivessel disease (ERACI) showed that freedom from combined cardiac events was significantly better for bypass surgery (77% *vs* 47%) than for angioplasty. However, no differences occurred in overall and cardiac mortality rates or in the frequency of myocardial infarction between the 2 groups. Patients who had bypass surgery were free of angina more frequently (79% *vs* 57%) and had fewer additional revascularization procedures (6% *vs* 37%) than patients treated with angioplasty.

Patients with diabetes mellitus are an exception regarding equivalent mortality rate results of balloon angioplasty and bypass surgery in multivessel disease. Among diabetic patients in the BARI trial, 5-year survival was 65.5% in those treated by balloon angioplasty and 80.6% for those having bypass surgery. The improved survival with surgery was due to a reduced cardiac mortality rate (5.8% *vs* 20.6%) and was confined to those receiving at least 1 internal mammary artery graft. Better survival among diabetic patients with multivessel disease treated with bypass surgery rather than angioplasty also was observed in a large retrospective study.

The bypass angioplasty revascularization investigation 2 diabetes (BARI 2D) trial randomized 2364 men and women with type 2 diabetes mellitus, documented coronary artery disease, stable symptoms, and myocardial ischemia treated with optimal medical therapy to an initial strategy of coronary revascularization (REV) or watchful waiting with the option of subsequent revascularization (MED). At 5 years, rates of survival or the composite of cardiovascular death, myocardial infarction, and stroke did not differ significantly between the groups. A substudy of the BARI 2D trial reports that the REV strategy improved outcomes at the 3-year follow-up, with patients experiencing a lower rate of worsening angina, new angina, and subsequent coronary revascularizations, and a higher rate of angina-free status.

Long-term mortality rates are similar after CABG and PCI in most patient subgroups with multivessel coronary artery disease; therefore, the choice of treatment should depend on patient preferences for other outcomes. In a collaborative analysis of individual patient data from 10 randomized trials, Hlatky and colleagues found CABG to be a superior option for patients with diabetes and patients aged 65 years or older because mortality was lower in these subgroups.

Bare Metal Stents and Coronary Artery Bypass Grafting

The major limitations of balloon angioplasty have been acute vessel closure and restenosis. Early studies with intracoronary stents showed that these devices were highly effective for treating or preventing acute or threatened vessel closure and, thus, avoiding emergency bypass surgery. Two randomized trials, STRESS and BENESTENT, demonstrated that coronary stenting of de novo lesions in native vessels reduced angiographic restenosis by approximately 30%, compared with conventional balloon angioplasty. Stenting produces a larger lumen diameter than conventional balloon angioplasty immediately following the procedure (acute gain) and at follow-up (net gain), resulting in less restenosis.

The use of stenting, instead of balloon angioplasty, was compared with bypass surgery for the treatment of multivessel coronary artery disease in the arterial revascularization therapies study (ARTS), and after 1 year of follow-up, no difference was noted between the groups in the rate of death, stroke, or myocardial infarction. Event-free survival was better in the surgery group than in the stent group (87.8% *vs* 73.8%), and only 3.5% in the surgery group required a second revascularization procedure, versus 16.8% in the stent group.

In the ERACI and BARI trials, 37% and 54%, respectively, needed a second revascularization when treated by balloon angioplasty. Overall, patients with diabetes and those who

received incomplete surgical revascularization did worse. The cost of the initial revascularization procedure was $4212 less for those treated by stent placement, but because of the need for more repeat revascularization procedures in the stent group, the cost advantage for stenting was reduced to $2973 after 1 year.

The stent or surgery (SoS) trial compared base metal stents (BMS) with CABG in similar patients and reported a 21% 2 year target vessel revascularization rate in stent patients, versus 6% in CABG patients, with similar death and myocardial infarction rates in the 2 groups. However, the SoS trial had a higher noncardiac death rate in the PCI arm, thought to be attributed to a type II error that may have affected the study results. Few stent patients in the SoS trial received glycoprotein (GP) IIb/IIIa receptor inhibitors. Still, this and the ARTS study do point to the safety of PCI treatment in multivessel disease. Mortality risk is low (discounting the noncardiac deaths), and the rates for repeat target vessel revascularization have been halved.

Drug-eluting Stents and Coronary Artery Bypass Grafting

Sirolimus-eluting stents were associated with an 8% MACE rate (13% for CABG in ARTS I) and an 8.5% target vessel revascularization rate (4% for CABG and 21% for PTCA in ARTS I), according to the ARTS II trial. The use of drug-eluting stents was compared with CABG in stable angina populations in the ARTS II trial, which was a registry comparing sirolimus-eluting stent (Cypher) with the PTCA and CABG arms of the ARTS I trial. The 1-year MACE rate was 10.5% for sirolimus-eluting stent patients.

The New York Cardiac Registry, as previously reported with data from bare metal stents, also found that patients who underwent PCI had a higher rate of target vessel revascularization than those who underwent CABG (30.6% *vs* 5.2%). They analyzed 17,400 patients who either received a drug-eluting stent (9,963) or CABG (7,437) and observed them for 18 months. Unadjusted survival curves did not demonstrate a statistical significance in survival for 2- or 3-vessel disease. However, when adjusted for several factors (age; sex; ejection fraction; hemodynamic state; history or no history of myocardial infarction before the procedure; the presence or absence of cerebrovascular disease, peripheral arterial disease, congestive heart failure, chronic obstructive pulmonary disease, diabetes, and renal failure; and involvement of the proximal LAD artery), there was statistically significant 18-month survival benefit of CABG over PCI with drug-eluting stents.

The SYNTAX study assessed differences in quality of life and angina score in 1,800 patients undergoing bypass surgery or PCI. Patients with 3-vessel or left main coronary artery disease were randomized to CABG or PCI with paclitaxel-eluting stents. Quality of life and angina scores were improved in both groups at 6 and 12 months. Angina score improved more in the CABG group, but the between-group differences were small.

The ongoing FREEDOM trial will compare drug-eluting stents and CABG in patients with diabetes and multivessel coronary artery disease.

Acute Coronary Syndromes (Unstable Angina and NSTEMI)

The management of patients with non–Q-wave myocardial infarction and unstable angina has changed considerably over the past 5 years. Before the widespread use of stents and GP IIb/IIIa receptor inhibitors, conventional balloon angioplasty in this subgroup of patients was associated with substantial risks, including myocardial infarction (as much as 9%), restenosis (as much as 50%), need for emergency coronary bypass surgery (as much as 12%), and death (as much as 5%). The optimal strategy in patients presenting with acute coronary syndromes remains a controversial issue in contemporary cardiology. Several studies have investigated the use of a conservative strategy versus an early invasive strategy of revascularization for patients with unstable coronary syndromes.

To better assess the natural history of coronary artery disease, 697 patients with an acute coronary syndrome treated with PCI were evaluated at the time of the procedure with multivessel intravascular ultrasonography (grey scale and radiofrequency) in the PROSPECT study. The major findings included the following: In patients with ACS treated with PCI, adverse events during a median follow-up of 3.4 years were divided evenly between recurrence at the site of culprit lesions and to nonculprit lesions. Intravascular ultrasonography predictors of nonculprit lesions that will progress include a large plaque burden, small luminal area, and thin-cap fibroatheroma.

The veterans affairs non-Q-wave infarction strategies in hospital (VANQWISH) trial compared an invasive strategy with conservative medical treatment in patients with non-Q-wave myocardial infarction and found that the rates of death or nonfatal myocardial infarction were higher in the invasive strategy group than in the conservative strategy group before hospital discharge, at 1 month, and at 1 year. Criticisms of this study include the exclusion of patients at very high risk; the lack of current aggressive medical therapies; a high rate of crossover to angiography in the conservative arm; a higher surgical mortality rate than expected compared with contemporary standards; and the observation that most of the complications at 30 days occurred in patients who underwent coronary artery bypass surgery and very few occurred in patients who underwent balloon angioplasty.

In contrast to the VANQWISH trial, 3 randomized studies found that an early invasive approach in patients with acute coronary syndromes was associated with improved outcomes.

The thrombolysis in myocardial infarction (TIMI) IIIb study showed less ischemia, shorter hospital stays, fewer readmissions, and fewer symptoms in patients treated by an early invasive approach.

The fragmin and fast revascularization during instability in coronary artery disease (FRISC) II trial prospectively randomized 2457 patients to an early invasive treatment versus a noninvasive treatment strategy and used intracoronary stenting; they found that at 6 months, the composite endpoint of death or myocardial infarction was

higher in the noninvasive treatment group than in patients undergoing an early invasive approach to management. Additionally, symptoms of angina and hospital readmissions in the noninvasive arm were twice that observed using the invasive treatment strategy.

The randomized intervention in the treatment of angina (RITA-III) study reported improved outcomes with early invasive therapy in 1810 patients at 5 years of follow-up. There was a statistically significant difference for all-cause mortality (15.1% *vs* 12.1%) and cardiac death/myocardial infarction (15.9% *vs* 12.2%) when comparing an interventional strategy and conservative medical therapy.

Based on various results, the American Heart Association/American College of Cardiology (AHA/ACC) guidelines recommended that an early (within 48 h) invasive approach should be used to treat patients presenting with the following higher-risk features—PCI or CABG in the past 6 months, new ST-segment depression, elevated cardiac biomarkers, recurrent angina at rest or low level of activity, left ventricular systolic function of less than 40%, or TIMI score greater than 2. In lower-risk patients (TIMI score of $\leq$2), evidence has shown that invasive therapy and medical therapy provide similar outcomes.

Acute Myocardial Infarction (STEMI)

The recognition that intracoronary thrombosis is the primary mechanism of vessel occlusion in acute myocardial infarction and that prompt restoration of vessel patency provides significant clinical benefit has led to the development of aggressive new treatments for this disorder.

Thrombolytic therapies, such as front-loaded tissue plasminogen activator (tPA), reteplase (r-PA), and tenecteplase (TNK), open approximately 80% of infarct-related vessels within 90 minutes, but only 50% will have normal (TIMI grade 3) flow. In addition, 10% of vessels opened by thrombolysis either reocclude or are the source for recurrent symptoms of angina. Because of these limitations to thrombolytic therapy, several randomized trials have evaluated mechanical revascularization, so-called primary angioplasty, in the setting of acute myocardial infarction.

An analysis of 23 trials confirms the superiority of primary angioplasty over fibrinolytic therapy in terms of adverse events and mortality reduction in both the short term and long term. Overall, primary PCI was associated with significant reductions in death, recurrent myocardial infarction, reinfarction, and the combined endpoint of death, myocardial infarction, and stroke.

In the situation where patients are transferred from outside hospitals, primary angioplasty is often preferred to onsite fibrinolytic therapy for patients with the following—expected door-to-balloon time less than 90 minutes and symptom duration less than 3 hours, symptom duration more than 3 hours, cardiogenic shock, contraindications to fibrinolytic therapy, and age older than 75 years. The use of thrombolytic therapy and then referral for intentional PCI (facilitated PCI) has not been shown to be superior to primary PCI and may actually worsen outcomes with increased risk of stroke and bleeding (ASSENT 4).

Recent data suggest that early use of GP IIb/IIIa inhibitors may help to achieve earlier infarct vessel patency and better outcomes during PCI. Whether this is so for all of these agents is being assessed in several studies. One meta-analysis has shown that abciximab is associated with a 46% reduction in death and reinfarction in primary PCI patients and the AHA/ACC STEMI guidelines currently recommend early use of abciximab in these patients. When fibrinolytic therapy is given but fails to produce ST resolution, then immediate PCI (rescue PCI) is recommended.

Some of the most important considerations in providing effective primary PCI relate to the logistical issues and barriers that are known to exist. The PCI system or network, ambiguity of leadership and organization, protocols/care, pathways/interfacility transfer, and reimbursement issues are the main areas of contention. Studies of the US primary PCI sites that are considered the best (those sites that deliver door-to-balloon times consistently within 90 minutes, which is currently about 5% of the US myocardial infarction population) have identified the key determinants of shorter door-to-balloon times as the following—ECG being performed within 10 minutes, the emergency department independently making the decision to engage the catheterization laboratory team, and interdisciplinary teamwork.

The key factor for effective primary PCI is timely reperfusion therapy. Studies from the National Registry of Myocardial Infarction (NRMI) data have shown that shortening door-to-balloon time to less than 90 minutes is associated with a reduction in mortality. In certain situations, timely reperfusion may be best achieved with fibrinolytic therapy if delays are likely in accessing primary PCI.

From a procedural perspective, because primary PCI involves a thrombotic plaque, the potential risk of more complications exists, especially no reflow and distal embolization. These patients should achieve final TIMI 3 flow. Stenting plus GP IIb/IIIa inhibition has been shown to improve outcomes, reducing target vessel revascularization and myocardial infarction rates in comparison with balloon angioplasty. The use of adjunctive antithrombotic approaches, including early GP IIb/IIIa inhibition use and mechanical thrombectomy, has shown benefit. Important issues remain as to which type of stent to use (drug-eluting or bare metal), and timing of antiplatelet therapy (both IV and oral) might provide better outcomes for certain patients.

Stone and colleagues studied the safety and efficacy of drug-eluting stents and bare-metal stents in patients with STEMI undergoing primary PCI. Patients (n=3006) were assigned in a 3:1 ratio to receive paclitaxel-eluting stents or otherwise identical bare-metal stents. Paclitaxel-eluting stents significantly reduced angiographic evidence of restenosis and recurrent ischemia necessitating repeat revascularization, compared with bare-metal stents, at 12-month follow-up. Rates of death and stent thrombosis were similar for the 2 groups.

General Comparison of PCI and CABG

A 2007 research review by the Agency for Healthcare Research and Quality (AHRQ) examined 23 randomized

controlled trials of PCI versus CABG (9963 patients) and found that short-term survival was high for both procedures and did not differ significantly. However, freedom from procedural stroke was significantly higher after PCI than after CABG.

In the AHRQ study, there was no significant difference in long-term survival (1–5 years of follow-up) between the 2 procedures. However, survival was significantly better after PCI in patients with single-vessel disease that did not involve the proximal LAD and was significantly better after CABG in patients with extensive triple-vessel or left main artery disease. Long-term freedom from angina was significantly greater after CABG than after PCI, as was the need for repeat coronary revascularization procedures. The use of coronary artery stents narrowed, but did not close, the gap between PCI and CABG in repeat revascularization procedures. Although PCI initially was less costly than CABG, the cost difference narrowed substantially over time, to roughly 5%.

Optical Coherence Tomography

The technique is based on optical technology and commercially available fiberoptic components adapted for ophthalmic use (Figs 6.49–6.51). OCT is a noninvasive technique that does not utilize ionizing radiation to provide in vivo images. OCT has numerous potential clinical applications and, in effect, creates 'optical biopsies' of tissues. It has also been used in the detection, characterization and management of skin tumors and other dermatological diseases, cardiology, and intravascular disease. OCT may be able to contribute to early diagnosis of vulnerable atherosclerotic lesions. Noninvasive imaging modalities such as magnetic resonance and computerized tomography are currently under intense investigation. Catheter-based diagnostic techniques, however, can provide structural information with higher resolution than noninvasive methods. Intravascular magnetic resonance is being actively investigated for plaque detection and characterization. Intravascular ultrasound magnetic resonance is being actively investigated for plaque detection and characterization. Intravascular ultrasound is widely used in interventional cardiology. A recent publication suggests a correlation between the presence of echolucent zones in coronary plaques on IVUS images and acute coronary events. Preliminary angioscopic studies have suggested that the presence of yellow plaques with a glistening surface correlates with acute events. More quantitative approaches which measure molecular absorption overtones of lipid or the Raman shift of cholesterol, may provide unique signals from vessel walls to identify large lipid pools. Based on the hypothesis that local inflammation within vulnerable

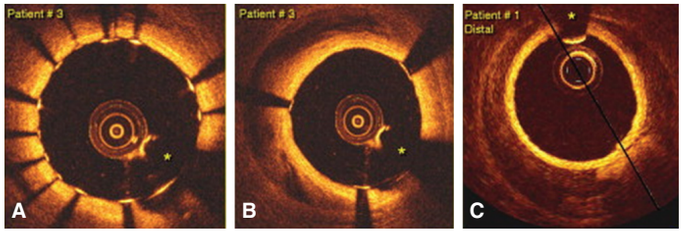

Fig. 6.49: OCT findings after coronary stenting. (A) Well-expanded and apposed stent. (B) Residual abluminal hematoma at the stented segment. (C) Residual intramural hematoma distal to the stented segment (*=shadow caused by the wire artifact)

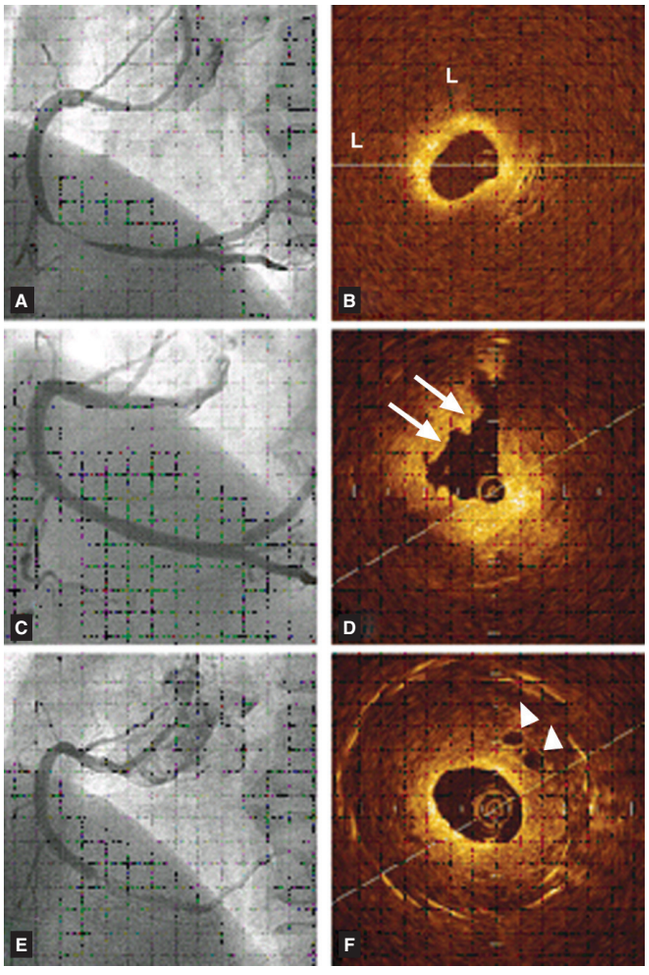

Fig. 6.50: Coronary angiography showed a 90%; stenosis in the mid-right coronary artery (A) and optical coherence tomography (OCT: Light Lab TM) was performed to assess plaque morphology. OCT revealed diffusely bordered signal poor region with overlying signal-rich band at the culprit site (L indicates lipid core in B). Two sirolimus-eluting stents (Cypher TM; 3.0 × 33 and 3.0 × 33 mm) were deployed in the culprit lesion and excellent angiographic results were obtained (C). The final intravascular ultrasound also demonstrated the well-expanded and apposed stents with no plaque protrusion. The patient was prescribed aspirin 100 mg and ticlopidin 200 mg orally daily for 1 year. 12 months follow-up coronary angiography showed a 99%; stenosis with contrast filling defect in the stents (Panel D). At this site, OCT revealed a low-backscattering projections irregular mass protruding into the lumen (white arrows in E) with some microchannels (white arrow heads in F). This finding may suggest that organized thrombus was the main component of restenotic tissue 12 months after sirolimus-eluting stent implantation

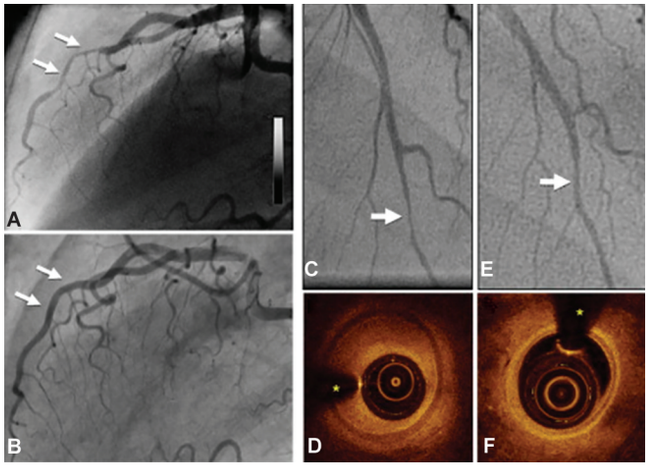

Fig. 6.51: Late spontaneous resolution of angiographic images corresponding to SCAD on OCT. (A) Diffuse, confined lesion in the mid-left anterior descending coronary artery (arrows) (note normal proximal and distal segments) with complete resolution at late angiographic follow-up (B). (C) Diffuse lesion (arrow) on the distal left anterior descending coronary artery where OCT revealed an intramural hematoma (D). (E) At late follow-up, the angiographic image significantly improved, and a normal vessel wall was demonstrated by OCT (F). *shadow caused by the wire artifact; SCAD=spontaneous coronary artery dissection

plaques may lead to local elevations in temperature, a temperature-sensing catheter has been used to study temperature heterogeneity and temperature differences between atherosclerotic plaque and healthy vessel walls Intravascular optical coherence tomography (OCT) has recently been proposed as a high-resolution imaging method for plaque characterization. Optical coherence tomography is an optical analog of ultrasound imaging because it measures the amplitude of backscattered light (optical echoes) returning from a sample as a function of delay. *In vitro* studies have shown that the resolution of OCT (10–20 μm) can resolve the thin fibrous caps thought to be responsible for plaque vulnerability. Additionally, the intrinsic optical properties of typical plaque constituents have provided sufficient contrast in these studies for OCT to differentiate between lipid, calcium and fibrous tissue. Recent experiments performed in vivo have demonstrated intravascular OCT imaging of normal rabbit aortas and swine coronary arteries. Here we present the first application, to our knowledge, of intracoronary OCT in living patients. The goals of this study were:

1. To demonstrate the feasibility and safety of OCT imaging in patients
2. To assess OCT images of human coronary pathology acquired in vivo by comparison with IVUS images obtained from corresponding locations

A catheter-based imaging technology called optical coherence tomography can successfully identify the characteristics of coronary plaques in patients with various cardiac symptoms. The ability to identify dangerous plaques before they rupture and produce a heart attack or sudden cardiac death will be crucial to innovative preventive therapies. Plaques are deposits of fats, cholesterol and other materials that collect in major arteries, restricting or sometimes blocking blood flow. While some plaques are relatively stable, others are vulnerable to rupture and release their contents into the bloodstream, causing a blood clot to form. Heart attacks and other acute coronary events usually result from the rupture of high-risk, vulnerable plaques in coronary arteries, and the characteristics of those plaques have been determined primarily by autopsy studies. OCT uses infrared light delivered via fiberoptic catheter to produce high-resolution, cross-sectional images of blood vessels. The OCT images showed that the heart attack and ACS patients had more lipid in their plaques and significantly thinner fibrous caps than did the stable angina patients. Overall, vulnerable plaques were identified in 72% of the heart attack patients, 50% of those with ACS and only 20% of stable angina patients. 'This is the first technique that allows to study the structural changes underlying vulnerable plaques in living patients, and it supports the conclusions of previously reported postmortem studies,' says Jang. We still need to gather more data to confirm these characteristics, and our group will carry out further studies of how plaques develop and rupture. Some day OCT may provide information that will guide treatments to prevent plaque rupture and its disastrous consequences.

COMPLICATIONS ASSOCIATED WITH PCI

Early registries of balloon angioplasty results showed complication rates that were much higher than those typically observed today (Figs 6.52–6.59). With advancements in technique, devices, and adjuvant medical therapy, percutaneous transluminal coronary intervention is now associated with mortality and emergency bypass rates of less than 1%. The rate of nonfatal myocardial infarction following coronary angioplasty ranges from 5–15%, whereas the rate following stent placement is



Fig. 6.52: One day after percutaneous transluminal coronary angioplasty with stenting, a follow-up coronary angiography revealed the patent stents of the left main coronary artery and proximal left anterior descending coronary artery with remaining thrombotic occlusion of the distal intermediate branch

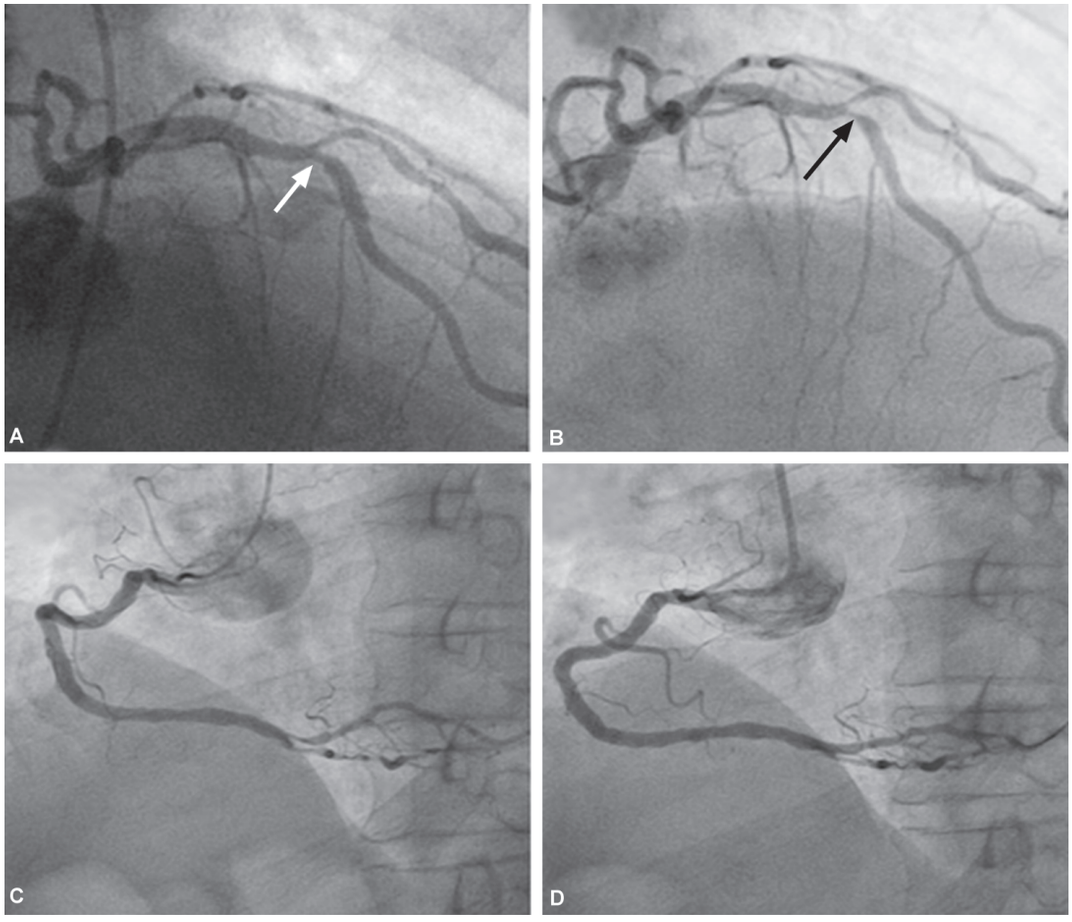

Fig. 6.53: (A and B) Follow-up coronary angiogram showed stent fracture with abundant movement and displacement of fractured fragment over 1 mm during cardiac cycle (type 4) was shown compared to previous coronary angiogram (A) 3 years ago, (B) severe stenosis at the fracture site. (C and D) After 2 years, his symptoms returned due to RCA obstruction, (C) he was then stented successfully (D)

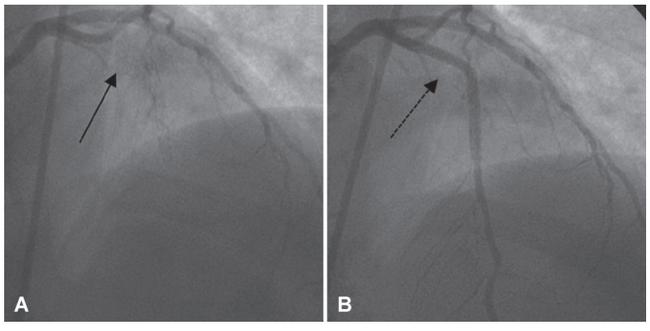

Fig. 6.54: Second findings of coronary angiogram. The second CAG showed total occlusion (dark arrow) in the previous stent-implanted area of the LAD (A) and restored lesion (dotted arrow) after successful PCI with ReoPro (abciximab) infusion (B). CAG=coronary angiography, LAD=left anterior descending artery, PCI=percutaneous coronary intervention

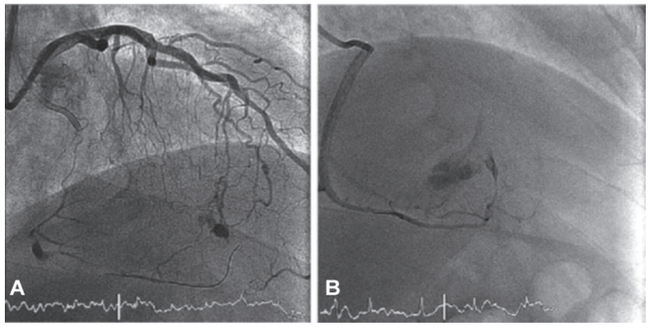

Fig. 6.55: (A) Passage of an angioplasty balloon has caused rupture of the septal branch used. (B) In the final angiography after the procedure, the right coronary artery is patent with several stents implanted in the region of the occlusion and a fistula from septal rupture to the right ventricle. This complication did not lead to hemodynamic deterioration and the patient was discharged 4 days later

2–5%. Restenosis after balloon angioplasty requiring a second revascularization procedure is a major limitation occurring in about 15–30% of patients, depending on the definition of restenosis applied. However, with drug-eluting stents, restenosis rates are now less than 10%.

Reduction in the complications of balloon angioplasty has been complemented by improvements in the acute success rate. Registries, such as the National Heart, Lung, and Blood Institute (NHLBI) Coronary Angioplasty

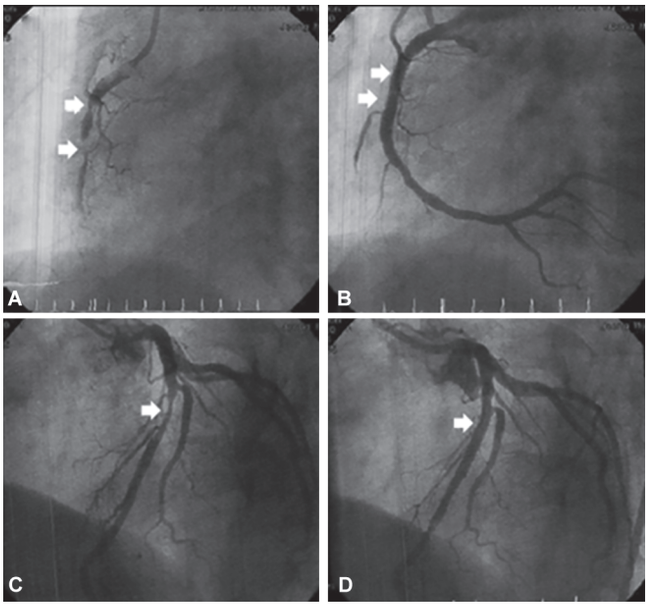

Fig. 6.56: Initial coronary angiography in September 2004. (A) Thrombotic near total occlusion of the mid-RCA (Type C, 99%, TIMI flow I), (B) 3.5 × 32 mm paclitaxel-eluting stent (Taxus Express^2, Boston Scientific Corporation) was deployed in RCA. (C) Critical stenosis in mid-LAD (Type B2, 90%, TIMI flow III). (D) 3.0 × 20 mm Taxus-eluting stent in the LAD. Final CAG showed good distal flow without residual stenosis

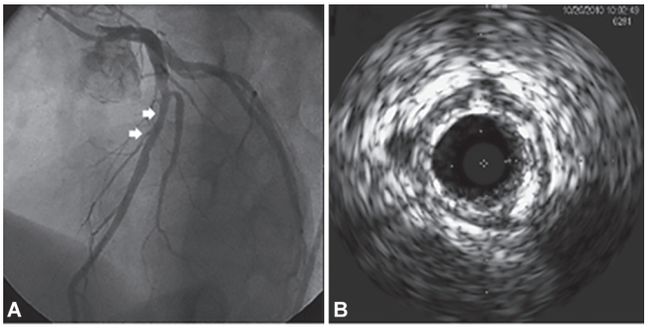

Fig. 6.57: (A) Left coronary angiography showed mild type II in-stent restenosis in LAD, (B) IVUS showed plaque in LAD stent

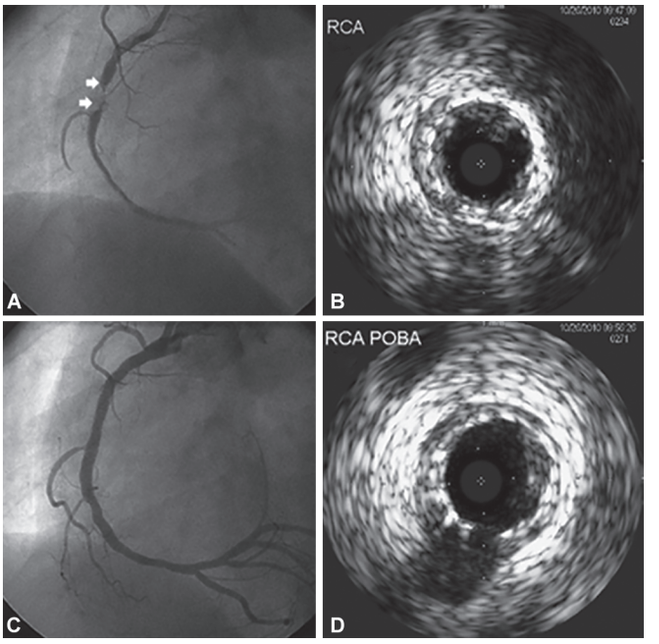

Fig. 6.58: (A) Right coronary angiogram showed very late stent thrombosis in RCA stent, (B) IVUS showed neointima breakdown and ruptured plaque within the RCA stent, (C) Coronary angiography after plain old balloon angioplasty (POBA). Final coronary angiogram showed good distal flow, and (D) IVUS showed markedly decreased residual stenosis

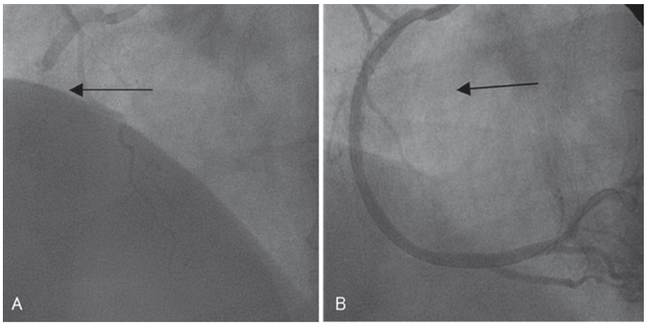

Fig. 6.59: The coronary angiogram. (A and B) CAG showed total occlusion (dark arrow) in the earlier stent-implanted lesion of the RCA and recanalized lesion (dotted arrow) after successful PCI. CAG=coronary angiography, RCA=right coronary artery, PCI=percutaneous coronary intervention

Registry from the early 1980s, reported primary success rates of 61%. Today, success rates are 95–99% with the use of stents and adjunctive pharmacotherapy.

The mechanism by which balloon angioplasty or stenting improves luminal diameter is associated with significant local trauma to the vessel wall, which can, in turn, lead to occlusive complications in a minority of patients. Coronary artery dissection typically results from the vessel injury secondary to balloon expansion. Animal and postmortem studies have shown that localized dissection at the site of balloon expansion is a common occurrence, detected angiographically in as many as 50% of patients immediately following the procedure. Such small dissections probably are necessary to obtain adequate lumen expansion, rarely interfere with antegrade blood flow, or are important. Angiographic follow-up typically shows no residual evidence of a dissection as early as 6 weeks after angioplasty in most of the cases studied. However, larger dissections can lead to complications.

Abrupt Vessel Closure

It may occur in as many as 5% of balloon angioplasty cases and typically develops when there is compression of the true lumen by a large dissection flap, thrombus formation, superimposed coronary vasospasm, or a combination of these processes. The presence of large coronary dissections immediately after balloon angioplasty is associated with a 5-fold increase in the risk of abrupt closure. This underscores the importance of a good postprocedure angiographic result on clinical outcomes.

Since the introduction and use of intracoronary stents and newer antiplatelet drugs, the incidence of abrupt closure has significantly decreased (to <1%). Microembolization of plaque debris or adherent thrombus may also cause acute complications during angioplasty and may contribute to postprocedure cardiac enzyme elevation and chest pain in some patients.

In less than 1% of patients undergoing angioplasty, microembolization of the platelet-rich thrombus may cause diffuse distal arteriolar vasospasm secondary to the release of vasoactive agents, resulting in the phenomenon of no-reflow. This complication is difficult to treat but may respond to intracoronary calcium channel antagonists, adenosine, or nitroprusside. Patients undergoing balloon angioplasty of saphenous vein graft lesions and primary angioplasty in the setting of acute myocardial infarction with a large amount of adherent thrombus are at greatest risk of distal embolization.

Coronary perforation or rupture following balloon angioplasty: It is very rare (<1%) and is typically associated with the use of ablative devices or oversized balloons.

Restenosis

Following balloon angioplasty or stent implantation, the vessel wall undergoes a number of changes. Platelets and fibrin adhere to the site within minutes of vessel injury. Within hours to days, inflammatory cells infiltrate the site and vascular smooth muscle cells begin to migrate toward the lumen.

The vascular smooth muscle cells then hypertrophy and excrete an extensive extracellular matrix. During this period of vascular smooth muscle cell proliferation, endothelial cells colonize the surface of the lumen and regain their normal function. Over the course of several weeks to months, multiple forces interact to cause remodeling of the vessel wall with either a decrease in lumen diameter (negative remodeling) or an increase in lumen diameter (positive remodeling). The amount of late loss in lumen diameter is dependent on the amount of neointimal proliferation and the degree of remodeling following intervention. After 6 months, the repair process stabilizes and the risk of restenosis decreases significantly.

Mechanism of restenosis following percutaneous transluminal coronary angioplasty (PTCA): Several studies have shown that the lumen diameter or area after treatment is one of the major predictors of restenosis. The use of coronary artery stents has decreased the rate of restenosis by improving the acute gain achieved and by minimizing negative remodeling. Depending on the definition used, angiographic restenosis has been reported in as many as 50% of patients within 6 months after balloon angioplasty, necessitating repeat target vessel revascularization (TVR) in approximately 20–30% of patients. Drug-eluting stents have reduced restenosis rates to less than 10%. Poststent lumen diameter and lesion complexity are still the major predictors of restenosis with these newer stents.

Stent Thrombosis

While drug-eluting stents have significantly reduced restenosis events, concerns of stent thrombosis with these newer stents still exist. In fact, the rate of thrombosis with a drug-eluting stent is virtually identical to that for a bare metal stent at 1 year (0.5–0.7%). However, late stent thrombosis (>1 year) continues to occur with a drug-eluting stent, while it is exceedingly rare for a bare metal stent.

The biggest factor contributing to stent thrombosis is interruption of antiplatelet therapy. Current guidelines recommend a minimum of 1 year of dual antiplatelet therapy for drug-eluting stents and a month for bare metal stents. Drug-eluting stents take longer to endothelialize on the coronary vessel wall than bare metal stents, and discontinuing dual antiplatelet therapy may expose patients to an increased risk for stent thrombosis over time. In some clinical situations (such as before urgent noncardiac surgery where antiplatelet therapy may have to be discontinued and in patients with known or potential medicine compliance issues), implanting a bare metal stent may be preferred during PCI rather than using a drug-eluting stent. Another important factor is final stent diameter and area.

Underdeployment or incomplete apposition of the drug-eluting stent may also increase the risk for stent thrombosis. This is not to say that drug-eluting stents are unsafe. In fact, there is no difference in long-term rates of death and myocardial infarction between drug-eluting and bare metal stents; however, there is a striking reduction in restenosis. Stone and colleagues found that although stent thrombosis is infrequent, it results in higher rates of myocardial infarction and death. The more frequent target lesion revascularization results in a lower rate of myocardial infarction and death. Although late stent thrombosis is a risk with drug-eluting stents, the noticeable reduction in restenosis may offset the risk.

KEY POINTS

- Permanent intracoronary scents have demonstrated considerable efficacy in the treatment of PTCA-induced abrupt arterial occlusion, suboptimal dilatation, and restenosis. Despite their benefit, permanent stents have significant limitations including subacute thrombosis, need for anticoagulation with resultant vascular complications, prolonged hospitalization, and high costs.
- Temporary stem's have the potential for achieving many of the beneficial effects of permanent stenting without some of the iatrogenic complications.
- The heat activated removable temporary stent (HARTS) removable stent employs the shape memory alloy Nitinol, and has the properties of being balloon deployable, but recoverable to a preset 'memory' shape by heating it with warmed crystalloid solution.
- Preclinical experience first with a wire stent design and more recently with a slotted tubular design, has demonstrated the

Contd...

Contd...

feasibility of implanting and recovering the HARTS device. Speculative applications of this technology include treatment of acute postangioplasty occlusion and suboptimal angioplasty results; 'stentoplasty'—the application of a temporary stent for several hours at the time of a primary angioplasty; and reduction of restenosis rate by inhibition of elastic recoil following short-term (hours) stenting. Further, the HARTS device may be an important vehicle for local delivery of drugs or other biologically active agents to the arterial wall. All research to date has been preclinical and controlled clinical trials will be necessary to define the safety, efficacy, and potential applications of the HARTS removable stent.

- New generation of DES, dedicated bifurcation stents, and improvement of procedural techniques will probably improve the clinical outcome.
- The new antiplatelet agents (prasugrel and ticagrelor) could improve the safety of PCI in complex LM lesions, but they need to be evaluated in this particular setting.
- The future EXCEL trial (evaluation of Xience Prime or Xience V-eluting stent *vs* CABG for effectiveness of LM revascularization) will evaluate the safety and efficacy of PCI with Xience Prime or Xience V EES *vs* CABG in patients with ULMCA disease with a low or intermediate SYNTAX score (<33). The composite measure of all-cause mortality, MI, or stroke at an anticipated median follow-up duration of 3 years will be the primary endpoint. The need for repeat revascularization will be considered as a secondary endpoint. The results of the trial might impact the current guidelines.

BIBLIOGRAPHY

1. Argenziano M, Katz M, Bonatti J, et al. Results of the prospective multicenter trial of robotically assisted totally endoscopic coronary artery bypass grafting Ann Thorac Surg 2006;81:1666–74, discussion: 1674–75.
2. Barlis P, Schmitt JM. Current and future developments in intracoronary optical coherence tomography imaging. Euro Intervention 2009;4:529–33.
3. Beyar R, Gruberg L, Delleanu D, et al. Remote-control percutaneous coronary interventions. Concept, validation, and first-in-humans clinical trial. J Am Coll Cardiol 2006; 47: 296–300.
4. Beyar R, Wenderow T, Lindner D, et al. Concept, design and pre-clinical studies for remote control percutaneous coronary interventions EuroIntervention 2005;1:340–345.
5. Boden WE, O'Rourke RA, et al. Optimal medical therapy with or without PCI for stable coronary disease. N Engl J Med 2007;356(15):1503–16.
6. Camenzind E, Steg PG, Wijns W. Stent thrombosis late after implantation of first-generation drug-eluting stents: a cause for concern. Circulation 2007;115:1440–55, discussion: 55.
7. Di Biase L, Wang Y, Horton R, et al. Ablation of atrial fibrillation utilizing robotic catheter navigation in comparison to manual navigation and ablation: single-center experience J Cardiovasc Electrophysiol 2009;20:1328–35.
8. Dotter CT, Judkins MP. Transluminal treatment of arteriosclerotic obstruction. Circulation 1964;30(5):654–70.
9. Duran AD, Duran GD, Ramirez RR, et al. Cataracts in interventional cardiology personnel. Retrospective evaluation study of lens injuries and dose (RELID Study). Eur Heart J 2009;30:872.
10. European Society of Cardiology Science News, 2007 Thrombosis is the price for the success of drug-eluting stents
11. Gruntzig AR, Senning A, Siegenthaler WE. Nonoperative dilatation of coronary-artery stenosis: percutaneous transluminal coronary angioplasty. N Engl J Med 1979;301:61–8.
12. Guagliumi G, Sirbu V, Costa M, et al. Long-term Strut Coverage of Paclitaxel Eluting Stents Compared to Bare-Metal Stents Implanted During Primary PCI in Acute Myocardial Infarction. A Prospective, Randomized, Controlled Study Performed with Optical Coherence Tomo-graphy. HORIZONS-OCT. Paper presented at: Late Breaking Trials, American Heart Association Annual Meeting, November 15, 2008; New Orleans, LA.
13. Guagliumi G, Sirbu V. Optical coherence tomography: high resolution intravascular imaging to evaluate vascular healing after coronary stenting. Catheter Cardiovasc Interv 2008;72: 237–47.
14. Hannan EL, Wu C, Walford G, et al. Drug-eluting stents vs coronary-artery bypass grafting in multivessel coronary disease. N Engl J Med 2008;358(4):331–41.
15. Hoffmann R, Mintz GS, Dussaillant GR, Popma JJ, et al. Patterns and mechanisms of in-stent restenosis. A serial intravascular ultrasound study. Circulation 1996;94:1247–54.
16. Joner M, Finn AV, Farb A, Mont EK, Kolodgie FD, et al. Pathology of drug-eluting stents in humans: delayed healing and late thrombotic risk. J Am Coll Cardiol 2006;48:193–202.
17. Kedhi E, Joesoef KS, McFadden E, t al. Second-generation everolimus-eluting and paclitaxel-eluting stents in real-life practice (COMPARE): a randomised trial. Lancet 2010;375: 201–9.
18. Kline LW, Miller DL, Balter S, et al. Occupational hazards in the interventional laboratory: time for a safer environment Catheter Cardiovasc Interv 2009;73:432–8.
19. Kolata, Gina. New Heart Studies Question the Value Of Opening Arteries. The New York Times, March 21, 2004. Retrieved January 29, 2011.
20. Kubo T, Imanishi T, Kitabata H. Comparison of vascular response after sirolimus-eluting stent implantation between patients with unstable and stable angina pectoris: a serial optical coherence tomography study. J Am Coll Cardiol Img. 2008;1:475–84.
21. Marescaux J, Leroy J, Gagner M, et al. Transatlantic robot-assisted telesurgery Nature 2001;413:379–80.
22. Mauri L, Hsieh WH, Massaro JM, et al. Stent thrombosis in randomized clinical trials of drug-eluting stents. The New England Journal of Medicine 2007;356(10):1020–9.
23. Meier B, Bachmann D, Lüscher T. 25 years of coronary angioplasty: almost a fairy tale. Lancet 2003;361(9356):527.
24. Mercado, N, Flather, MD, Boersna, E, et al. On Behalf of the Trial Investigators CABG vs Stenting for Multivessel Disease: a Meta-analysis of ARTS-1, SoS, ERACI-2, and MASS-2, Presentation at European Society of Cardiology Congress 2003;(23): 2093–8.
25. Michaels AD, Chatterjee K. Cardiology patient pages. Angioplasty versus bypass surgery for coronary artery disease. Circulation 2002;106(23):e187–90.

26. Morice MC, Serruys PW, Sousa JE, et al. A randomized comparison of a sirolimuseluting stent with a standard stent for coronary revascularization. N Engl J Med 2002;346: 1773–80.
27. Nordmann AJ, Briel M, Bucher HC. Mortality in randomized controlled trials comparing drug-eluting vs. bare metal stents in coronary artery disease: a meta-analysis. Eur Heart J 2006;27:2784–814.
28. Rasmussen K, Maeng M, Kaltoft A, et al. Efficacy and safety of zotarolimus-eluting and sirolimus-eluting coronary stents in routine clinical care (SORT OUT III): a randomised controlled superiority trial. Lancet 2010;375:1090–9.
29. Schaar JA, Muller JE, Falk E. Terminology for high-risk and vulnerable coronary artery plaques. Report of a meeting on the vulnerable plaque, June 17 and 18, 2003, Santorini, Greece. Eur Heart J 2004;25:1077–82.
30. Serruys PW, De Jaegere P, Kiemeneij F, Macaya C, et al. A comparison of balloon-expandable-stent implantation with balloon angioplasty in patients with coronary artery disease. Benestent Study Group. N Engl J Med 1994;331:489–95.
31. Serruys PW, Ormiston JA, Onuma Y. A bioabsorbable everolimus-eluting coronary stent system (ABSORB): 2-year out-comes and results from multiple imaging methods. Lancet. 373;2009:897–910.
32. Sigwart U, Puel J, Mirkovitch V, Joffre F, Kappenberger L. Intravascular stents to prevent occlusion and restenosis after transluminal angioplasty. N Engl J Med 1987;316:701–6.
33. Sigwart U, Urban P, Golf S, Kaufmann U, Imbert C, et al. Emergency stenting for acute occlusion after coronary balloon angioplasty. Circulation 1988;78(5 Pt 1):1121–7.
34. Solomon SB, Patriciu A, Bohlman ME, Kavoussi LR, Stoianovici D. Robotically driven interventions: a method of using CT fluoroscopy without radiation exposure to the physician Radiology 2002;225:277–82.
35. SoS Investigators. Coronary artery bypass surgery versus percutaneous coronary intervention with stent implantation in patients with multivessel coronary artery disease (the Stent or Surgery trial): a randomised controlled trial. Lancet 2004; 360;(9338):965–70.
36. Stefanini GG, Kalesan B, Serruys PW, Heg D, Buszman P, Linke A, et al. Long-term clinical outcomes of biodegradable polymer biolimus-eluting stents versus durable polymer sirolimus-eluting stents in patients with coronary artery disease (LEADERS): 4 year follow-up of a randomised non-inferiority trial. Lancet 2011;378:1940–8.
37. Stone GW, Ellis SG, Cox DA, Hermiller J, O'Shaughnessy C, Mann JT, et al. A polymer-based, paclitaxel-eluting stent in patients with coronary artery disease. N Engl J Med 2004;350: 221–31.
38. Stone GW, Rizvi A, Newman W, et al. Everolimus-eluting versus paclitaxel-eluting stents in coronary artery disease. N Engl J Med 2010;362: 1663–74.
39. Stroupe KT, Morrison DA, Hlatky MA, Barnett PG, Cao L, Lyttle C, Hynes DM, Henderson WG. Cost-effectiveness of coronary artery bypass grafts versus percutaneous coronary intervention for revascularization of high-risk patients. Circulation 2006;114(12):1251–57.
40. Subramanian VA, Patel NU, Patel NC, Loulmet DF. Robotic assisted multivessel minimally invasive direct coronary artery bypass with port-access stabilization and cardiac positioning: paving the way for outpatient coronary surgery? Ann Thorac Surg 2005;79:1590–6, discussion: 1596.
41. UK's NHS endorsed 'Best Treatments' advice on 'clinical evi-dence for patients from the BMJ' on Coronary angioplasty and its risks.
42. Virmani R, Guagliumi G, Farb A, Musumeci G, Grieco N, Motta T, et al. Localized hypersensitivity and late coronary thrombosis secondary to a sirolimus-eluting stent: should we be cautious? Circulation 2004;109:701–5.
43. Weintraub WS, Spertus JA, Kolm P, et al. Effect of PCI on quality of life in patients with stable coronary disease. The N Engl J Med 2008;359(7):677–87.
44. Yamaguchi T, Terashima M, Akasaka T. Safety and feasibility of an intravascular optical coherence tomography image wire system in the clinical setting. Am J Cardiol 2008;101:562–67.
45. Yang EH, Gumina RJ, Lennon RJ, et al. 2003 Journal of the American College of Cardiology 2005;46(11):2004–2009.

7 Acute Pulmonary Edema

INTRODUCTION

Pulmonary edema is the term used when edema happens in the lungs. The immediate area outside of the small blood vessels in the lungs is occupied by very tiny air sacs called the alveoli. This is where oxygen from the air is picked up by the blood passing by, and carbon dioxide in the blood is passed into the alveoli to be exhaled out. Alveoli normally have a thin wall that allows for this air exchange, and fluids are usually kept out of the alveoli unless these walls lose their integrity (Fig. 7.1).

Pulmonary edema occurs when the alveoli fill up with excess fluid seeped out of the blood vessels in the lung instead of air. This can cause problems with the exchange of gas (oxygen and carbon dioxide), resulting in breathing difficulty and poor oxygenation of blood. Sometimes, this can be referred to as 'water in the lungs' when describing the condition to patients.

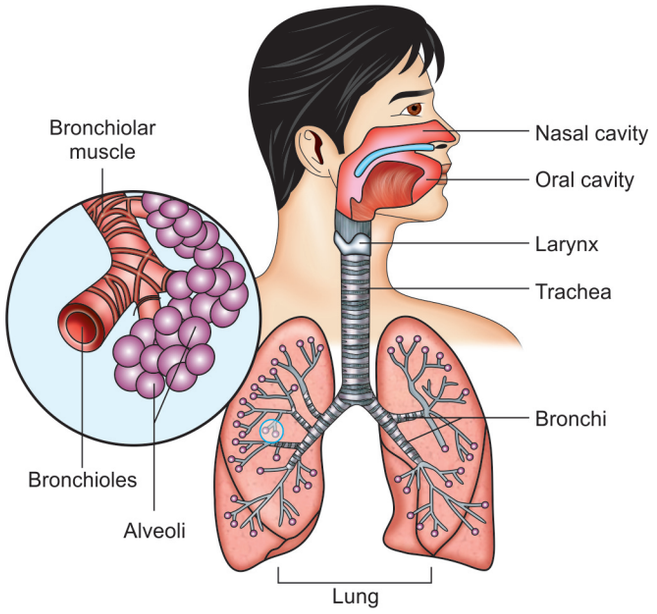

Fig. 7.1: Illustration showing anatomy of airway system involved in pulmonary edema

Pulmonary edema can be caused by many different factors. It can be related to heart failure, called cardiogenic pulmonary edema, or related to other causes, referred to as non-cardiogenic pulmonary edema.

TYPES AND CAUSES OF PULMONARY EDEMA

As mentioned earlier, pulmonary edema can be broadly divided into cardiogenic and non-cardiogenic causes. Some of the common causes are listed below.

1. **Cardiogenic:** Cardiogenic causes of pulmonary edema results from high pressure in the blood vessels of the lung due to poor heart function. Congestive heart failure due to poor heart pumping function (arising from various causes such as arrhythmias and diseases or weakness of the heart muscle), heart attacks, or abnormal heart valves can lead to accumulation of more than the usual amount of blood in the blood vessels of the lungs. This can, in turn, cause the fluid from the blood vessels to be pushed out to the alveoli as the pressure builds up.
2. **Non-cardiogenic:** Non-cardiogenic pulmonary edema can be commonly caused by the following:
   - Acute respiratory distress syndrome (ARDS), a potentially serious condition caused by severe infections, trauma, lung injury, inhalation of toxins, lung infections, cocaine smoking, or radiation to the lungs. In ARDS, the integrity of the alveoli become compromised as a result of underlying inflammatory response, and this leads to leaky alveoli that can fill up with fluid from the blood vessels.
   - Kidney failure and inability to excrete fluid from the body can cause fluid build-up in the blood vessels, resulting in pulmonary edema. In people with advanced kidney disease, dialysis may be necessary to remove the excess body fluid.

- High altitude pulmonary edema, which can happen due to rapid ascent to high altitudes of more than 10,000 feet.
- Brain trauma, bleeding in the brain (intracranial hemorrhage), severe seizures, or brain surgery can sometimes result in fluid accumulation in the lungs, causing neurogenic pulmonary edema.
- A rapidly expanding lung can sometimes cause re-expansion pulmonary edema. This may happen in cases when the lung collapses (pneumothorax) or a large amount of fluid around the lung (pleural effusion) is removed, resulting in rapid expansion of the lung. This can result in pulmonary edema on the affected side only (unilateral pulmonary edema).
- Rarely, an overdose on heroin or methadone can lead to pulmonary edema.
- Aspirin overdose or chronic high dose use of aspirin can lead to aspirin intoxication, especially in the elderly, which may cause pulmonary edema.
- Other more rare causes of non-cardiogenic pulmonary edema may include pulmonary embolism (blood clot which has traveled to the lungs), transfusion-related acute lung injury (TRALI), some viral infections, or eclampsia in pregnant women.

AETIOLOGICAL FACTORS IN PULMONARY EDEMA

Pulmonary edema is often caused by congestive heart failure. When the heart is not able to pump blood to the body efficiently, it can back up into the veins that take blood through the lungs to the left side of the heart.

As the pressure in these blood vessels increases, fluid is pushed into the air spaces (alveoli) in the lungs. This fluid reduces normal oxygen movement through the lungs. This and the increased pressure can lead to shortness of breath.

- Heart attack, or any disease of the heart that weakens or stiffens the heart muscle (*cardiomyopathy*)
- Leaking or narrowed heart valves (mitral or aortic valves)
- Sudden, severe high blood pressure (hypertension)

Pulmonary edema may also be caused by:

- Certain medications
- High altitude exposure
- Kidney failure
- Narrowed arteries that bring blood to the kidneys
- Lung damaged by poisonous gas or severe infection
- Major injury

SYMPTOMS IN PULMONARY EDEMA

Symptoms of pulmonary edema may include:

- Coughing up blood or bloody froth
- Difficulty breathing when lying down (orthopnea) — you may notice the need to sleep with your head propped up or use extra pillows.
- Feeling of 'air hunger' or 'drowning' (if this feeling wakes you from sleep and causes you to sit up and try to catch your breath, it is called 'paroxysmal nocturnal dyspnea').
- Grunting, gurgling, or wheezing sounds with breathing.
- Inability to speak in full sentences because of shortness of breath.

Other Symptoms

- Anxiety or restlessness
- Decrease in the level of alertness (consciousness)
- Leg swelling
- Pale skin
- Sweating (excessive)

CLINICAL EXAMINATION IN PULMONARY EDEMA

The healthcare provider will perform a physical examination and use a stethoscope to listen to your lungs and heart. The following may be detected:

- Abnormal heart sounds
- Crackles in your lungs, called rales
- Increased heart rate (tachycardia)
- Pale or blue skin color (pallor or cyanosis)
- Rapid breathing (tachypnea)

Laboratory Tests

- Blood chemistries
- Blood oxygen levels (oximetry or arterial blood gases)
- Complete blood count (CBC)

Imaging Studies

1. **Chest X-ray** (Figs 7.2 and 7.3).
2. **Echocardiogram (ultrasound of the heart)** (Figs 7.4–7.6) to see if there are problems with the heart muscle (such as weakness, thickness, failure to relax properly,



Fig. 7.2: Radiograph shows acute pulmonary edema in a patient known to have ischemic cardiomyopathy. Findings are Kerley B lines (1 mm thick and 1 cm long) in the lower lobes and Kerley A lines in the upper lobes

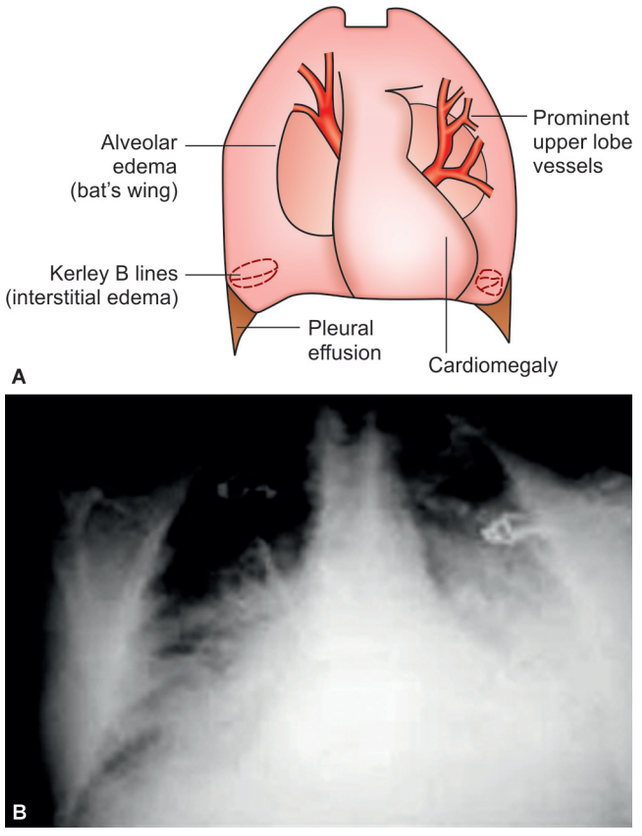

Fig. 7.3: (A) Classic signs of acute heart failure that can be seen on a chest X-ray of left ventricular failure, (B) pleural effusion on a chest X-ray

leaky or narrow heart valves, or fluid surrounding the heart).

3. **Electrocardiogram (ECG)** (Figs 7.7 and 7.8) to look for signs of a heart attack or problems with the heart rhythm
4. **Aortography** (Fig. 7.9)

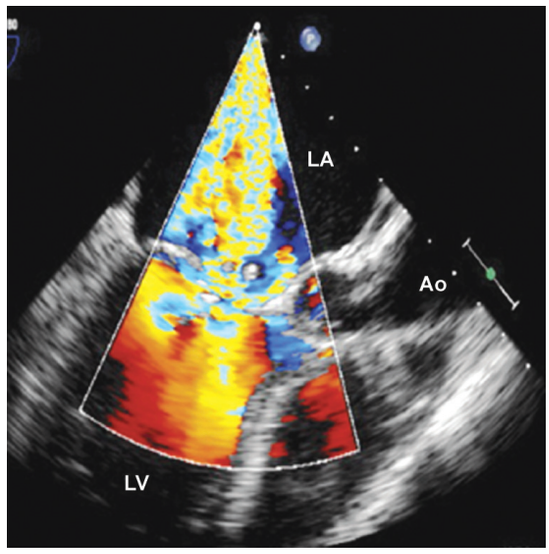

Fig. 7.4: Color imaging reveals severe mitral regurgitation (LA=left atrium; LV=left ventricle; Ao=aorta)

MANAGEMENT OF PULMONARY EDEMA

The initial management of patients with cardiogenic pulmonary edema (CPE) should address the ABCs of resuscitation, that is, airway, breathing, and circulation. Oxygen should be administered to all patients to keep oxygen saturation at greater than 90%. Any associated arrhythmia or MI should be treated appropriately.

Methods of oxygen delivery include the use of a face mask, noninvasive pressure-support ventilation [which includes bilevel positive airway pressure (BiPAP) and continuous positive airway pressure (CPAP)], and intubation and mechanical ventilation. Which method is used depends on the presence of hypoxemia and acidosis and on the

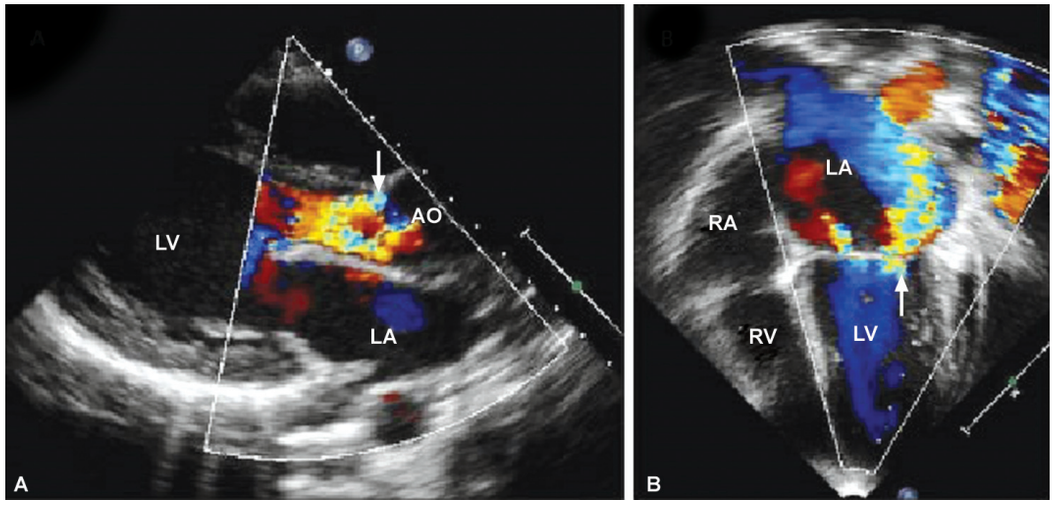

Fig. 7.5: (A) Two-dimensional color and spectral Doppler echocardiographic studies of patients with rheumatic heart disease show moderate to severe aortic valve insufficiency with no stenosis (A. arrow) and bowing of the anterior mitral leaflet with severe insufficiency and no stenosis (B. arrow)

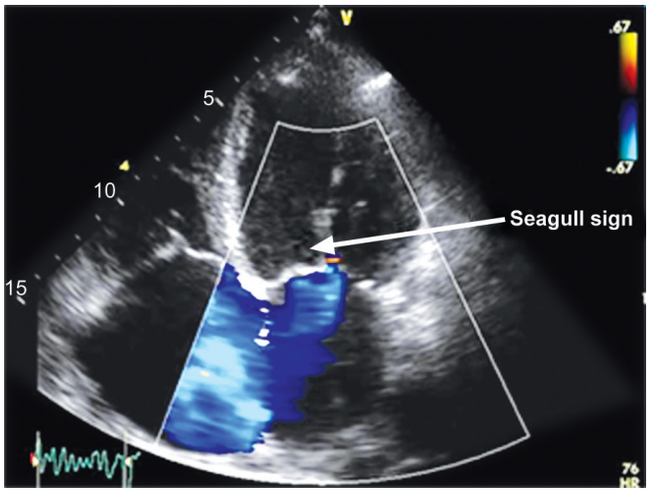

Fig. 7.6: 'Seagull sign' on transthoracic echocardiography of moderate-severe IMR. A transthoracic echocardiographic image demonstrating the 'seagull sign' present in moderate-severe IMR. The shape of the anterior mitral valve leaflet is distorted by tethering of secondary strut chordae tendineae. This tethering impairs leaflet coaptation resulting in MR

patient's level of consciousness. For example, intubation and mechanical ventilation may become necessary in cases of persistent hypoxemia, acidosis, or altered mental status. Following initial management, medical treatment of CPE focuses on three main goals:

1. Reduction of pulmonary venous return (preload reduction),
2. Reduction of systemic vascular resistance (afterload reduction), and, in some cases,
3. Inotropic support.

Preload reduction decreases pulmonary capillary hydrostatic pressure and reduces fluid transudation into the pulmonary interstitium and alveoli. Afterload reduction increases cardiac output and improves renal perfusion, which allows for diuresis in the patient with fluid overload.

Patients with severe LV dysfunction or acute valvular disorders may present with hypotension. These patients may not tolerate medications to reduce their preload and afterload. Therefore, inotropic support is necessary in this subset of patients to maintain adequate blood pressure.

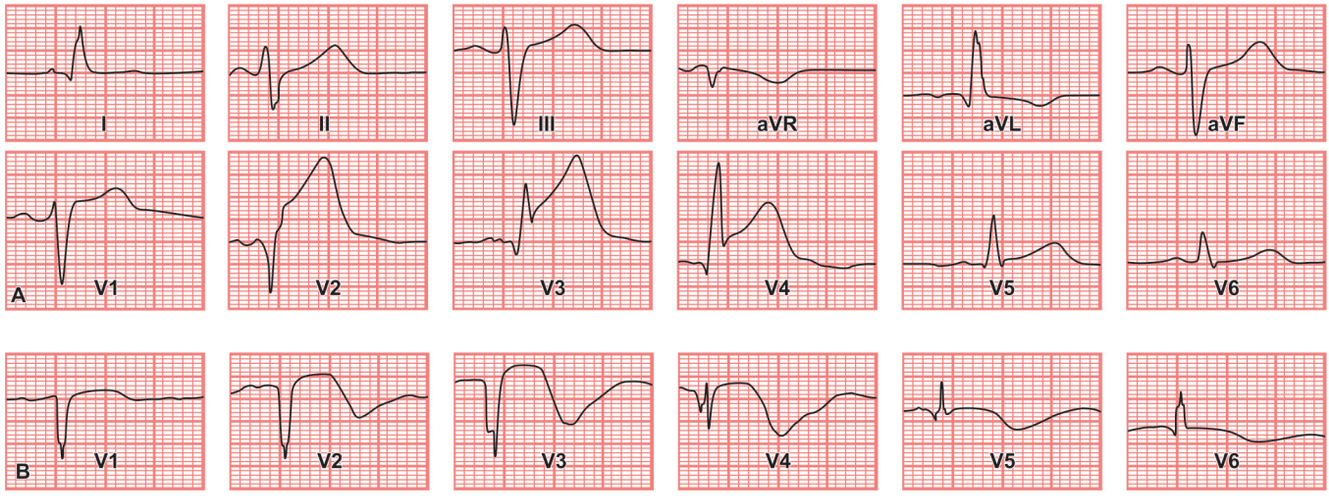

Fig. 7.7: Acute extensive anterior myocardial infarction—see in (A) probable LAH in the limb leads with high ST

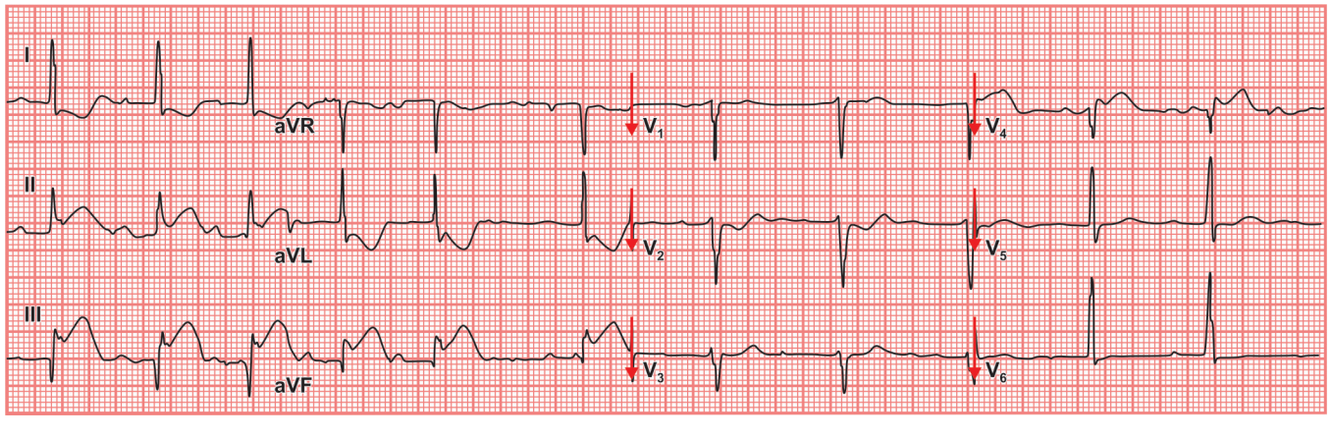

Fig. 7.8: ECG showing right ventricular MI. There is an inferior STEMI with ST-elevation in lead III > lead II. There is subtle ST-elevation in V1 with ST-depression in V2. There is ST-elevation in V4R

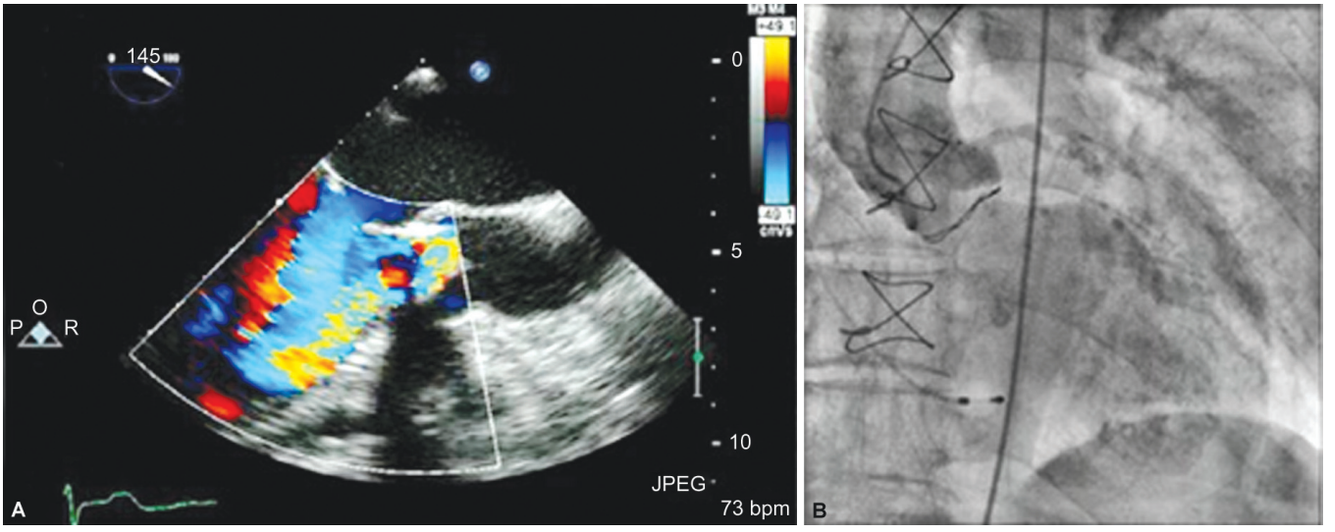

Fig. 7.9: Aortic regurgitation documented by transesophageal echocardiography (A) and aortography (B). The patient was referred for aortic valve replacement surgery for worsening of LV functions

Patients who remain hypoxic despite supplemental oxygenation and patients who have severe respiratory distress require ventilatory support in addition to maximal medical therapy.

Ultrafiltration

Ultrafiltration is a fluid removal procedure that is particularly useful in patients with renal dysfunction and expected diuretic resistance (Fig. 7.10).

Intra-aortic Balloon Pumping

Intra-aortic balloon pumping (IABP) can be employed to achieve hemodynamic stabilization in the patient before definitive therapy. The IABP decreases afterload as the pump deflates; during diastole, the pump inflates to improve coronary blood flow.



Fig. 7.10: Venovenous ultrafiltration technique, in patients with acute decompensated heart failure with worsening of kidney function, a condition referred to as acute cardiorenal syndrome (type 1). Diuretics are commonly used to treat persistent congestion in these patients, but these drugs might worsen kidney function. An alternative therapeutic approach is venovenous ultrafiltration, which can improve control over the rate and volume of fluid removal, increases net loss of sodium, and reduces neurohormonal activation

Diet

Patients admitted with heart failure or pulmonary edema should be given a low-salt diet to minimize fluid retention. Closely monitor their fluid balance.

Ventilatory Support

Noninvasive Pressure-support Ventilation

Consider noninvasive pressure-support ventilation (NPSV) early when treating patients with severe CPE.

In NPSV, the patient breathes through a face mask against a continuous flow of positive airway pressure. NPSV maintains the patency of the fluid-filled alveoli and prevents them from collapsing during exhalation. As a result, the patient saves energy that would have been spent trying to reopen collapsed alveoli. NPSV improves pulmonary air exchange, and it increases intrathoracic pressure with reduction in preload and afterload.

Several studies suggest that NPSV is associated with decreased length of stay in the ICU, decreased need for mechanical ventilation, and decreased hospital costs. A few clinical trials showed that in patients with CPE—mainly defined as having severe dyspnea, oxygen saturation of less than 90%, and basal rales—early and prehospital NPSV treatment by paramedics is safe and associated with faster improvement of oxygen saturation. However, the mortality and the need for intensive care did not differ between the patients who were treated with NPSV and those who were treated with a Venturi face mask in most of those studies.

CPAP and BiPAP

Two types of NPSV are CPAP and BiPAP. In CPAP, a single airway pressure is maintained throughout all phases of the

respiratory cycle. In BiPAP, high pressures can be applied during inspiration and low pressures, during expiration, increasing the patient's comfort.

A randomized trial comparing CPAP, noninvasive intermittent positive pressure ventilation (NIPPV), and standard oxygen therapy in 1069 patients with acute cardiogenic pulmonary edema demonstrated no mortality benefit from noninvasive ventilation, but improvements were seen in symptomatology and oxygenation.

In one small study, researchers compared CPAP with BiPAP and found that BiPAP was associated with more rapid improvement in vital signs but also with an increased rate of MIs. Moreover, patients who received BiPAP initially had more chest pain than did patients who received CPAP. Other randomized clinical trials, however, did not show an increased rate of MI in patients who received CPAP or BiPAP compared with those who received oxygen by means of a face mask.

As of now, the data are insufficient to compare the efficacy and safety of BiPAP with those of CPAP. Therefore, the authors suggest that CPAP be the preferred method employed when NPSV is used unless the patient has obstructive airway disease (Fig. 7.11).

Mechanical Ventilation

In general, use endotracheal intubation and mechanical ventilation when patients with CPE remain hypoxic despite maximal noninvasive supplemental oxygenation, when patients have evidence of impending respiratory failure (e.g. lethargy, fatigue, diaphoresis, worsening anxiety), or when patients are hemodynamically unstable (e.g. hypotensive, severely tachycardic).

Mechanical ventilation maximizes myocardial oxygen delivery and ventilation. Positive end-expiratory pressure is generally recommended to increase alveolar patency and to enhance oxygen delivery and carbon dioxide exchange.



Fig. 7.11: A middle-aged patient with acute pulmonary edema was fitted with CPAP and got relief after its application

Preload Reduction

Nitroglycerin: Nitroglycerin (NTG) is the most effective, predictable, and rapidly-acting medication available for preload reduction. Several studies demonstrated greater efficacy and safety and a faster onset of action with NTG than with furosemide or morphine sulfate. The use of sublingual NTG is associated with preload reduction within 5 minutes and with some afterload reduction.

Topical NTG may be as effective as sublingual NTG in most patients with CPE, but it should be avoided in patients with severe LV failure, because of poor skin perfusion (manifesting as skin pallor or mottling) and resultant poor absorption.

Intravenous (IV) NTG at high dosages provides rapid and titratable preload and afterload reduction and is excellent monotherapy for patients with severe CPE. IV NTG can be started with 10 mcg/min and then rapidly uptitrated to more than 100 mcg/min. The other alternative is NTG given as 3 mg IV boluses every 5 minutes.

The antianginal dose of NTG of 0.4 mg every 5 minutes has the bioequivalence of an NTG IV infusion of less than 80 mcg/min. Therefore, the dosage of NTG for patients with CPE is higher than the standard antianginal dosage would be.

Considering the short half-life of nitrates, physicians should be comfortable with the high dosage for CPE, especially in most patients with CPE, who present with a hyperadrenergic state and moderately elevated blood pressure. However, nitrates should not be used in hypotensive patients, and they should be used with extreme caution in patients with aortic stenosis and pulmonary hypertension.

Diuretics: Loop diuretics have been considered the cornerstone of CPE treatment for many years. Furosemide is used most commonly. Loop diuretics are presumed to decrease preload through two mechanisms—diuresis and direct vasoactivity (venodilation).

In most patients, diuresis does not occur for at least 20–90 minutes; therefore, the effect is delayed. Loop diuretics affect the ascending loop of Henle; therefore, the diminished renal perfusion in CPE may delay the onset of effects of loop diuretics.

Many patients with CPE do not have fluid overload. Continued use of diuretics in these patients after their acute symptoms have resolved may be associated with adverse outcomes, including electrolyte derangements, hypotension, and worsening renal function (GFR, glomerular filtration rate) as a result of tubuloglomerular feedback.

The presumption that these medications have a direct vasoactive (venodilating) effect has been questioned. Some studies demonstrated initial adverse hemodynamic consequences (e.g. elevations of PCWP, LV filling pressure, heart rate, and systemic vascular resistance) after the administration of IV furosemide.

Premedication with drugs that decrease preload (e.g. NTG) and afterload [e.g. angiotensin-converting enzyme (ACE) inhibitors] before the administration of loop diuretics can prevent potential adverse hemodynamic changes.

Morphine sulfate: The use of morphine sulfate in CPE for preload reduction has been commonplace for many years, but good evidence supporting a beneficial hemodynamic effect is lacking. Data suggest that morphine sulfate may contribute to a decrease in cardiac output and that it may be associated with an increased need for ICU admission and endotracheal intubation.

Adverse effects (e.g. nausea and vomiting, local or systemic allergic reactions, respiratory depression) may outweigh any potential benefit, especially given the availability of medications that are more effective than morphine in reducing preload (e.g. NTG).

Any beneficial hemodynamic effect from morphine is probably due to anxiolysis, with a resulting decrease in catecholamine production and a decrease in systemic vascular resistance. An alternative can be low-dose benzodiazepines (e.g. lorazepam 0.5 mg IV) in patients who are extremely anxious. This alternative reduces the risk of respiratory depression in patients whose condition responded to initial therapy.

Nesiritide: Nesiritide is recombinant human BNP that decreases PCWP, pulmonary artery pressure, RA pressure, and systemic vascular resistance while increasing the cardiac index and stroke volume index. Therapy with nesiritide has decreased plasma renin, aldosterone, norepinephrine, and endothelin-1 levels and has reduced ventricular ectopy and ventricular tachycardia. Heart-rate variability also improves with nesiritide.

Most of the beneficial effects of nesiritide were shown in the landmark vasodilation in the management of acute congestive heart failure (VMAC) study. Investigators compared IV nesiritide with IV NTG. IV nesiritide was associated with some hypotension but was otherwise well tolerated.

However, the VMAC study also showed a trend toward increased mortality in the IV nesiritide group compared with the patients receiving IV NTG, although the difference was not statically significant (90-day mortality, 19% for nesiritide *vs* 13% for NTG). The most important limitation of this study was the use of suboptimal dosages of IV NTG (mean 30–40 mcg/min) because the dosage was based on physician's decision and not on a protocol.

A later meta-analysis of 3 randomized trials of 485 patients receiving nesiritide and 377 patients not receiving nesiritide showed a 7.2% 30-day mortality with nesiritide versus 4% without nesiritide.

Another analysis, which included 5 randomized trials, showed that patients who received nesiritide were more likely than others to have significant renal failure.

In the largest study of nesiritide to date, the acute study of clinical effectiveness of nesiritide in decompensated heart failure (ASCEND HF), nesiritide had a neutral effect on survival and rehospitalization and a small effect on dyspnea when used in combination with other treatments. In the study, powered to show the effects of the drug on survival and renal function, no association was found between the drug and deteriorating renal function, although nesiritide was associated with a slight increase in hypotension. The authors recommended against the routine use of nesiritide in the broad population of patients with acute heart failure.

Afterload Reduction

ACE inhibitors: ACE inhibitors are generally considered the cornerstones for treating CHF, and studies have demonstrated excellent results with ACE inhibitors for the treatment of acute decompensated CHF and CPE. The use of ACE inhibitors in CPE is associated with reduced admission rates to ICUs and decreased endotracheal intubation rates and length of ICU stay.

The hemodynamic effects of ACE inhibitors include reduced afterload, improved stroke volume and cardiac output, and a slight reduction in preload. The last effect happens when renal perfusion improves after cardiac output improves and diuresis occurs.

Enalapril 1.25 mg IV or captopril 25 mg, given sublingually, result in hemodynamic and subjective improvements within 10 minutes. Improvements occur much more slowly with the oral route.

Angiotensin II receptor blockers: Angiotensin II receptor blockers (ARBs) have comparable beneficial effects in heart failure. Studies have proposed a role for ACE inhibitors and ARBs in preventing structural and electrical remodeling of the heart, resulting in a reduced incidence of arrhythmias.

The valsartan heart failure trial (Val-HeFT) showed that valsartan reduces the incidence of atrial fibrillation (AF) by 37%. (BNP level and advanced age were the strongest independent predictors for AF occurrence.) Similarly, the candesartan in heart failure: assessment in reduction of mortality and morbidity (CHARM) trial showed a reduction in the onset of AF in patients who were treated with Candesartan compared with placebo, with a median follow-up period of 37.7 months.

Nitroprusside: Nitroprusside results in simultaneous preload and afterload reduction by causing direct smooth-muscle relaxation, with an increased effect on afterload. Afterload reduction is associated with increased cardiac output. The potency and rapidity of onset and offset of effect make this an ideal medication for patients who are critically ill. It may induce precipitous falls and labile fluctuations in blood pressure; intra-arterial blood pressure monitoring is often recommended.

Nitroprusside should generally be avoided in the setting of acute MI. Its use is associated with the shunting of blood away from ischemic myocardium toward healthy myocardium (i.e. coronary steal syndrome), which potentiates ischemia.

If nitroprusside is used, convert therapy to oral or alternative IV vasodilator therapy as soon as possible because prolonged use is associated with thiocyanate toxicity. Use in pregnancy is associated with fetal thiocyanate toxicity. Prolonged infusion can induce tolerance, and reflex tachycardia may occur.

Catecholamines: Inotropic support is usually used when preload and afterload-reduction strategies are not successful or when hypotension precludes the use of these strategies. Two main classes of inotropic agents are available—catecholamine agents and phosphodiesterase inhibitors (PDIs). Calcium-sensitizer agents are a new class of medications that have notably beneficial effects in acute decompensated heart failure; these drugs are under investigation.

Dobutamine: Dobutamine, a catecholamine agent, mainly serves as a beta1-receptor agonist, though it has some beta2-receptor and minimal alpha-receptor activity. IV dobutamine induces significant positive inotropic effects, with mild chronotropic effects. It also induces mild peripheral vasodilation (decrease in afterload). The combination effect of increased inotropy with decreased afterload significantly increases cardiac output. Combination use with IV NTG may be ideal for patients with MI and CPE and mild hypotension to simultaneously reduce preload and increase cardiac output. In general, avoid dobutamine in patients with moderate or severe hypotension (e.g. systolic BP <80 mmHg), because of the peripheral vasodilation.

Dopamine: The vascular and myocardial receptor effects of dopamine, a catecholamine agent, are dose dependent. Low dosages of 0.5–5 mcg/kg/min stimulate dopaminergic receptors in the renal and splanchnic vascular beds, causing vasodilation and increasing diuresis. Moderate dosages of 5–10 mcg/kg/min stimulate beta-receptors in the myocardium, increasing cardiac contractility and heart rate.

High dosages of 15–20 mcg/kg/min stimulate alpha-receptors, resulting in peripheral vasoconstriction (increased afterload), increased blood pressure, and no further improvement in cardiac output.

Moderate and high dosages are arrhythmogenic and increase myocardial oxygen demand (with the potential for myocardial ischemia). Therefore, use these dosages only in patients with CPE who cannot tolerate dobutamine because of severe hypotension (e.g. systolic blood pressure 60–80 mmHg).

Norepinephrine: Norepinephrine, a catecholamine agent, primarily stimulates alpha receptors, significantly increasing afterload (and the potential for myocardial ischemia) and reducing cardiac output. Norepinephrine is generally reserved for patients with profound hypotension (e.g. systolic blood pressure <60 mmHg). After blood pressure is restored, add other medications to maintain cardiac output.

Phosphodiesterase inhibitors: PDIs increase the level of intracellular cyclic adenosine monophosphate (cAMP) by preventing the breakdown of cAMP to 5'AMP. This results in a positive inotropic effect on the myocardium, in peripheral vasodilation (decreased afterload), and in a reduction in pulmonary vascular resistance (decreased preload). Unlike the catecholamine inotropes, PDIs do not depend on adrenoreceptor activity. Therefore, patients are less likely to develop tolerance to PDIs than they are to other medications (tolerance to catecholamine inotropes can rapidly develop by means of a down-regulation of adrenoreceptors.)

PDIs are less likely than catecholamine inotropes to cause the adverse effects that are typically associated with adrenoreceptor activity (e.g. increased myocardial oxygen demand, myocardial ischemia).

Several direct comparisons of PDIs (milrinone) to dobutamine in patients with CPE demonstrated that milrinone produced equal or greater improvements in stroke volume, cardiac output, PCWPs (preload), and systemic vascular resistance (afterload). However, milrinone was associated with the same or more tachycardia and with an increased incidence of tachyarrhythmias.

Furthermore, the use of milrinone in the outcomes of a prospective trial of intravenous milrinone for exacerbations of chronic heart failure (OPTIME-CHF) study did not reduce hospital length of stay and was associated with a significant increase in adverse events compared with placebo.

All known IV inotropic agents are associated with an increased long-term mortality compared with placebo and therefore should be reserved for patients with heart failure and a markedly depressed cardiac index and stroke volume.

Calcium sensitizers: Levosimendan is a calcium sensitizer that is used in several European countries to manage moderate to severe heart failure. It has inotropic, metabolic, and vasodilatory effects. Levosimendan increases contractility by binding to troponin C. It does not increase myocardial oxygen demand, and it is not a proarrhythmogenic agent.

Levosimendan opens potassium channels sensitive to adenosine triphosphate (ATP), causing peripheral arterial and venous dilatation. It also increases coronary flow reserve. Moreover, studies have shown levosimendan to have an anti-inflammatory effect.

Overall, levosimendan has been an effective and safe alternative to dobutamine. The most common adverse effects of levosimendan treatment are hypotension and headache. A randomized clinical study—the survival of patients with acute heart failure in need of intravenous inotropic support (SURVIVE) trial—demonstrated no mortality benefit from levosimendan in comparison with dobutamine in patients with acute decompensated CHF.

Tolvaptan: Tolvaptan is an oral vasopressin V2-receptor antagonist that was evaluated in a large (4133 patients), randomized, double-blind, placebo-controlled trial in patients with acute clinically decompensated CHF. This study, the efficacy of vasopressin antagonism in heart failure outcome study with tolvaptan (EVEREST), demonstrated no mortality or CHF hospitalization benefit at a median follow-up of 9.9 months. However, patients randomized to tolvaptan demonstrated early (1–7 d)

improvements in body weight, dyspnea, serum sodium, and edema, as compared with placebo.

Intra-aortic Balloon Pumping

Kantrowitz initially described intra-aortic balloon pumping in 1953, but IABP was first used clinically in 1969 in a patient with cardiogenic shock. Since the 1980s, IABP has been increasingly applied in various clinical situations as a life-saving intervention to achieve hemodynamic stabilization before definitive therapy. The IABP decreases afterload as the pump deflates, and it improves coronary blood flow as it inflates during diastole.

The intra-aortic balloon pump is inserted percutaneously through the femoral artery using a modified Seldinger technique. The distal end of the pump is placed just distal to the aortic knob and the origin of the left subclavian artery. Fluoroscopy may be used for correct positioning of the balloon, and a subsequent radiograph should be obtained to document satisfactory placement of the balloon. Helium, a low-density gas with minimal water solubility, is used to inflate the balloon.

Proper timing of counterpulsation is necessary for maximum hemodynamic support. The timings of balloon inflation and deflation are best evaluated and adjusted at a pump ratio of 1:2. Inflation of the balloon should occur in early diastole, just after the aortic valve closes, and it should correspond to the dicrotic notch of the aortic pressure waveform. Balloon deflation should occur in early systole, just before the aortic valve opens.

Proper inflation leads to an assisted peak diastolic pressure higher than the unassisted peak systolic arterial pressure. Proper deflation results in assisted aortic end-diastolic pressure of approximately 10 mmHg lower than the unassisted end-diastolic pressure.

Diastolic augmentation enhances perfusion of the coronary circulation and carotid arteries. The reduction in end-diastolic pressure decreases aortic impedance (afterload) and augments systole.

By reducing aortic impedance and systolic pressure, IABP leads to a 15–25% reduction in LV wall stress. This level of afterload reduction improves LV volume, LV emptying, and myocardial oxygen consumption.

Diastolic aortic pressure augmentation improves myocardial perfusion and coronary blood flow. The effects on coronary blood flow may be variable but generally consist of a boost of 10–20% in the ischemic territories.

IABP decreases LV filling pressures by 20–25% and improves cardiac output by 20% in patients with cardiogenic shock. Therefore, IABP substantially reduces myocardial oxygen demand, although increased oxygen supply to the myocardium may also be a beneficial effect in some clinical situations.

IABP is effective in providing temporary support to patients in cardiogenic shock and end-stage cardiomyopathy while definite therapies, such as angioplasty, cardiac bypass surgery, or cardiac transplantation, are undertaken. In this case, the use of IABP is considered a bridge to a definitive revascularization procedure or implementation of an LV-assist device.

IABP is effective in stabilizing patients with unstable angina refractory to medical therapy before a definitive revascularization procedure.

IABP may be a life-saving intervention in patients with acute mitral regurgitation secondary to papillary muscle rupture or in patients with ventricular septal defect as a complication of MI. IABP reduces afterload and thereby reduces the severity of mitral regurgitation. It enhances forward cardiac output, reduces LA pressure, and improves pulmonary edema. Furthermore, IABP decreases LV afterload and improves cardiac output.

IABP can also provide hemodynamic support in the perioperative and postoperative period in high-risk patients, such as those with severe coronary disease, severe LV dysfunction, or recent MI (Fig. 7.12).

Contraindications: Absolute contraindications for IABP counterpulsation are a dissecting aortic aneurysm, severe aortic regurgitation, a large arteriovenous shunt, and severe coagulopathy. Relative contraindications are severe

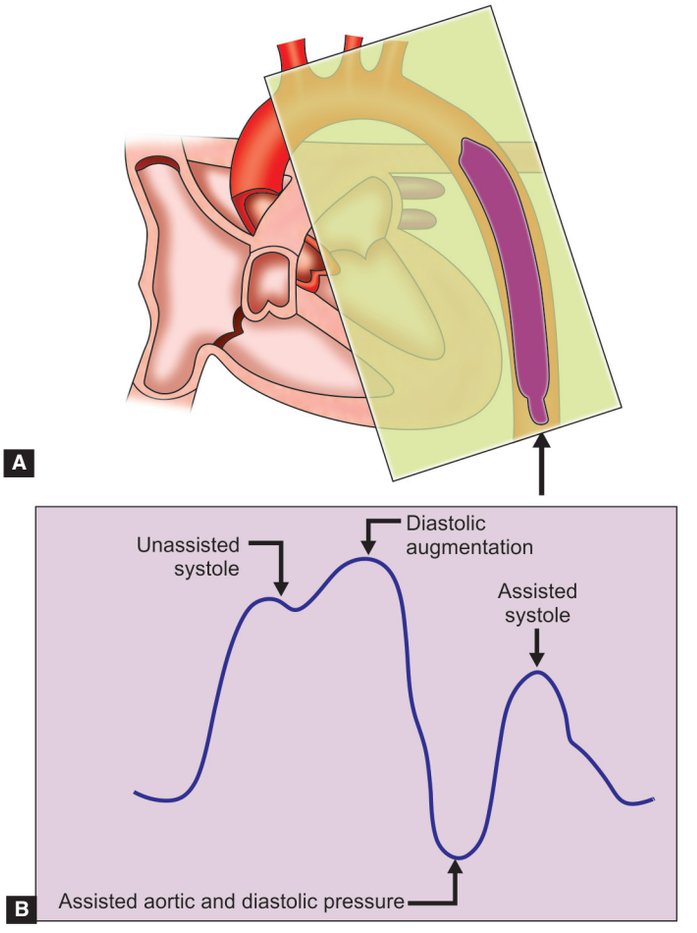

Fig. 7.12: (A) Showing introduction of intra-aortic balloon in aorta. (B) improvement in diastolic blood pressure in cardiogenic shock with heart failure

peripheral vascular disease, recent thrombolytic therapy, bleeding diathesis, and descending aortic and peripheral vascular grafts.

Complications: IABP can cause several complications, which should be monitored while the patient is receiving IABP support. In general, the patient's platelet counts are mildly reduced; however, the counts usually do not fall below 100×10^9/L.

Complications also may occur during cannulation of the femoral artery. These include perforation, laceration, or dissection of the artery (1–6%). Thrombosis of the iliofemoral artery and distal emboli may also occur (1–7%), and limb ischemia is reported in up to 40% of patients. Limb ischemia is reversible by removing the intra-aortic balloon pump, unless thrombosis develops; if thrombosis does occur, embolectomy is required to save the limb.

The other complications are localized bleeding (3–5%), infection (2–4%), thrombocytopenia (<1%), and intestinal ischemia (<1%).

Ultrafiltration: Ultrafiltration (UF) is a method of fluid removal that is particularly useful in patients with renal dysfunction and expected diuretic resistance.

The randomized ultrafiltration versus intravenous diuretics for patients hospitalized for acute decompensated heart failure (UNLOAD) trial demonstrated that ultrafiltration was superior to the use of IV diuretics in controlling net fluid loss and rehospitalization in hypervolemic patients with heart failure. These results indicated that UF should be considered in patients with volume overload and acute CHF who have not responded well to moderate to large doses of diuretic treatment or in whom the adverse effects of such treatment (e.g. renal dysfunction) do not allow initiation or continuation of the therapy. Broader application of UF needs further investigation with larger clinical trials to determine the efficacy and safety of this method.

Inpatient care: After the patient's condition has been stabilized, further inpatient care depends on the underlying cause of the episode of CPE.

Admit patients to a telemetry unit to monitor for acute dysrhythmias. Pay strict attention to the patient's fluid balance and closely monitor fluid input and output. Maintain a negative fluid balance in patients who are fluid overloaded by using diuretics or hemodialysis (in patients with renal failure).

Check cardiac enzyme levels to evaluate for MI. Stress testing can also be performed during hospitalization to evaluate for reversible ischemia as the cause of pulmonary edema.

Consider electrocardiography to evaluate for evidence of acute valvular dysfunction and wall-motion abnormalities and to assess the patient's ejection fraction. Patients with poor ejection fractions or severe dilated cardiomyopathies are often given digoxin.

In general, begin with oral vasodilator therapy, most commonly ACE inhibitors. If the patient was initially treated with inotropic medications, wean the patient off of these as soon as his or her condition is stable, to minimize adverse effects.

Patients in whom pulmonary edema is due to dietary factors or medication noncompliance need strict counseling and education to help prevent recurrences.

Transfer of patient: Transfer of patients to a tertiary receiving hospital is generally indicated if the initial hospital lacks adequate resources to care for the patient. Most patients with CPE can be treated well at community hospitals. However, if definitive surgery is required to stabilize the cause of CPE, transfer is often indicated.

Examples of patients who may require transfer include the following:

- Patients with CPE due to acute valvular dysfunction requiring urgent valve replacement
- Patients with acute MI that results in cardiogenic shock manifesting as CPE with hypotension (thrombolysis may be attempted at the initial hospital, but outcomes are generally poor without percutaneous coronary intervention or coronary artery bypass surgery)
- Patients with CPE who require inotropic support

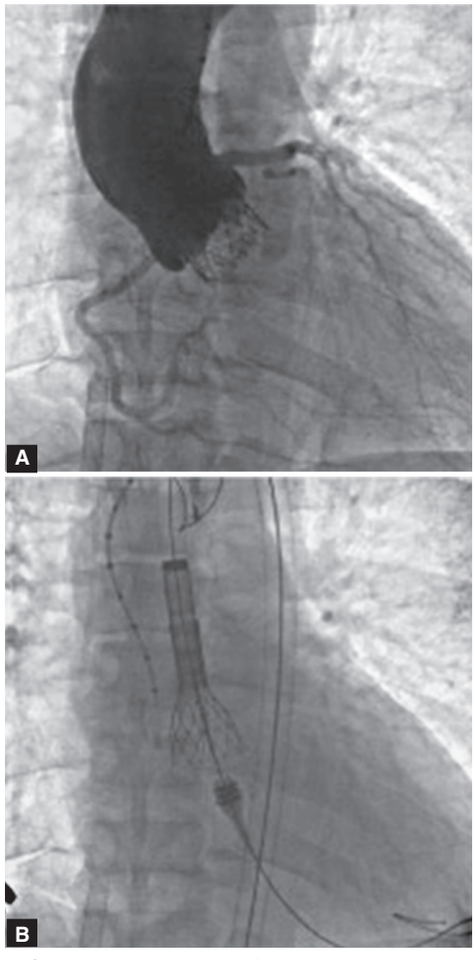

Fig. 7.13: (A) Controlled expansion of the aortic prosthesis. (B) Angiogram after successful implantation of aortic valve in an elderly patient with severe aortic stenosis and AR with heart failure

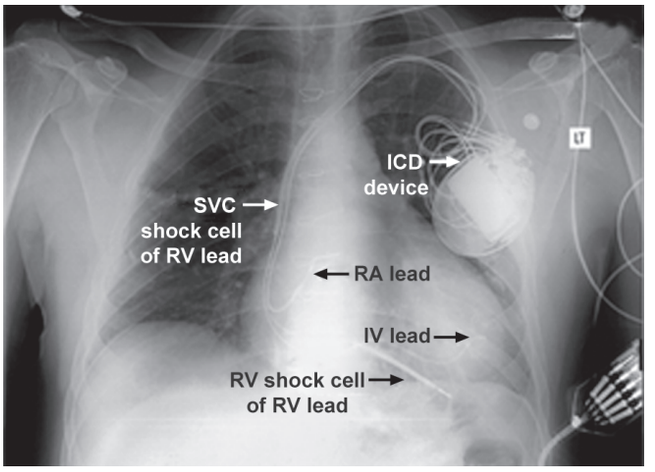

Fig. 7.14: X-ray chest showing ICD device fitted in a patient with cardiac arrhythmias and heart failure

Consultations: Consultations with subspecialists depend on the underlying cause of the episode of CPE. If the acute episode is attributed to an acute MI, acute cardiac ischemia, or an acute dysrhythmia, consultation with a cardiologist is often warranted.

If the episode is attributed to fluid overload in a patient with renal failure, consultation with a nephrologist is indicated for emergency or urgent hemodialysis.

If CPE results from acute valvular dysfunction, consultation with a cardiothoracic surgeon (including a cardiologist) for urgent valve replacement may be indicated, depending on the integrity of the valve (Figs 7.13 and 7.14).

In patients who develop cardiogenic shock, consultation with a cardiologist and/or critical care specialist is generally indicated to assist with titrating inotropic medication and, in some cases, to place an intra-aortic balloon pump as a temporizing measure before surgery (e.g. valve replacement or coronary revascularization).

QUICK READINGS IN MANAGEMENT OF ACUTE PULMONARY EDEMA

Because of the fundamental differences between cardiogenic and non-cardiogenic pulmonary edema, each requires different management and has a different prognosis. Treatment should be directed at reversing the specific cause although this may not be possible.

Management is otherwise supportive and directed at improving oxygenation, perfusion and haemodynamics, and preventing further cardiac and/or renal damage.

Prehospital Treatment

Resuscitation—as necessary: Sit the patient up; give oxygen (if available) by face mask—100% if no pre-existing lung disease (but even in patients with chronic obstructive pulmonary disease (COPD), give high oxygen flow initially but monitor with blood gases to ensure hypercapnia is avoided). Aim for oxygen saturations =95% (>90% in those with COPD).

Judge clinical severity: Some patients do not require hospital admission, e.g. those with mild and stable pulmonary edema with a known cause that is treatable without admission. However, most patients require urgent admission to hospital.

Insert an intravenous cannula and give nitrates are first-line vasodilators where systolic blood pressure is >90 mmHg and there is no serious obstructive valvular disease. Give sublingual or buccal nitrate, e.g. glyceryl trinitrate (GTN) spray two puffs sublingual, or 1–3 mg buccal isosorbide dinitrate.

Furosemide 20–40 mg intravenously (slowly) produces transient venodilation and subsequent diuresis. This may need to be repeated based on response of clinical symptoms—diuretic effectiveness is greatly reduced in the presence of hypotension and when patients have been taking oral diuretics for a long time.

Opiates: The use of opiates is controversial and opiates should not be given to patients with acute decompensated heart failure (see 'initial treatment', below). However, analgesia and sedation may be appropriate where the patient is in pain or distressed.

Diamorphine 2.5–5 mg intravenously slowly (or morphine 5–10 mg intravenously slowly) can be used to relieve anxiety, pain and distress.

Persistent coughs: Have a heart for your health.

Acute Heart Failure with Pulmonary Congestion/Edema without Shock

Initial Treatment

An intravenous loop diuretic is recommended to improve breathlessness and relieve congestion. Symptoms, urine output, renal function and electrolytes should be monitored regularly during use of the intravenous diuretic.

High-flow oxygen is recommended in patients with a capillary oxygen saturation <90% or PaO_2 <60 mmHg (8.0 kPa) to correct hypoxaemia. Oxygen should not be used routinely in non-hypoxaemic patients, as it causes vasoconstriction and a reduction in cardiac output.

Thrombo-embolism prophylaxis [e.g. with low molecular weight heparin (LMWH)] is recommended in patients not already anticoagulated and with no contra-indication to anticoagulation, to reduce the risk of deep venous thrombosis and pulmonary embolism.

Opiates, e.g. *morphine* may be useful in some patients with acute pulmonary edema, as they reduce anxiety and relieve distress associated with dyspnoea.

However, opiates depress respiratory drive, potentially increasing the need for invasive ventilation. Alertness and ventilatory effort should be monitored frequently after administration.

Some studies have suggested a strong association between the use of opiates and increased mortality and morbidity (e.g. intensive care unit admissions or intubation

rates) and opiates should not be used routinely in the treatment of acute pulmonary edema.

Opiates should be avoided in acute decompensated heart failure.

Vasodilators: An intravenous infusion of a nitrate should be considered in patients with pulmonary congestion/edema and a systolic blood pressure >110 mmHg, who do not have severe mitral or aortic stenosis, to reduce pulmonary capillary wedge pressure and systemic vascular resistance.

Nitrates may also relieve dyspnoea and congestion. Symptoms and blood pressure should be monitored frequently during administration of intravenous nitrates.

Inotropic agents are NOT recommended unless the patient is hypotensive (systolic blood pressure <85 mmHg), hypoperfused, or shocked because of safety concerns (atrial and ventricular arrhythmias, myocardial ischemia, and death).

Inotropes cause sinus tachycardia and may induce myocardial ischemia and arrhythmias. There is concern that inotropes may increase mortality.

Levosimendan (or a phosphodiesterase III inhibitor such as milrinone) may be used to counteract the effect of a beta-blocker.

Phosphodiesterase inhibitors (milrinone and enoximone) may be preferred to dobutamine in patients on beta-blocker therapy or with inadequate response to dobutamine. They are peripheral vasodilators and should only be used if systolic blood pressure is adequate. They may increase mortality in those with coronary artery disease.

Levosimendan is a calcium sensitiser that appears effective in patients with decompensated chronic heart failure already on beta-blockers.

Patients with hypotension, hypoperfusion or shock: *Electrical cardioversion* is recommended if an atrial or ventricular arrhythmia is thought to be contributing to hemodynamic compromise.

An intravenous infusion of an inotrope (e.g. dobutamine) should be considered in patients with hypotension (systolic blood pressure <85 mmHg). The ECG should be monitored continuously because inotropic agents can cause arrhythmias and myocardial ischemia.

Short-term mechanical circulatory support should be considered in patients remaining severely hypoperfused despite inotropic therapy and with a potentially reversible cause (e.g. viral myocarditis) or a potentially surgically correctable cause (e.g. acute interventricular septal rupture).

An intravenous infusion of levosimendan (or a phosphodiesterase inhibitor) may be considered to reverse the effect of beta-blockade if beta-blockade is thought to be contributing to hypoperfusion.

A vasopressor (e.g. dopamine or noradrenaline (norepinephrine) may be considered in patients who have cardiogenic shock, despite treatment with an inotrope. Intra-arterial blood pressure measurement should be considered.

Short-term mechanical circulatory support may be considered in patients deteriorating rapidly before a full diagnostic and clinical evaluation can be made.

Monitoring: Systolic blood pressure, heart rhythm and rate, saturation of peripheral oxygen (SpO_2) using a pulse oximeter, and urine output should be monitored on a regular and frequent basis until the patient is stabilised.

It is important to examine the patient repeatedly, including assessment for any new heart murmurs, e.g. a patient who has severe pulmonary edema following a myocardial infarction may go on to develop a ventricular septal defect or mitral regurgitation (confirm with an echocardiogram).

Renal function, electrolytes, serial ECGs and cardiac enzymes should also be closely monitored.

Intra-arterial line—insertion of an intra-arterial line should only be considered in patients with persistent heart failure and a low systolic blood pressure despite treatment.

Pulmonary artery catheterisation: *Right heart* catheterisation does not have a general role in the management of acute heart failure, but may help in the treatment of a minority of selected patients with acute heart failure.

After Stabilisation

Angiotensin-converting enzyme (ACE) inhibitor/angiotensin-II receptor antagonist (AIIRA): In patients with reduced EF not already receiving an ACE inhibitor (or AIIRA), this treatment should be started as soon as possible, blood pressure and renal function permitting.

Beta-blocker: In patients with reduced EF not already receiving a beta-blocker, this treatment should be started as soon as possible after stabilisation, blood pressure and heart rate permitting.

Mineralocorticoid (aldosterone) receptor antagonist (MRA): in patients with reduced EF not already receiving an MRA, this treatment should be started as soon as possible, renal function and potassium permitting. As the dose of MRA used to treat heart failure (HF) has a minimal effect on blood pressure, even relatively hypotensive patients may be started on this therapy during admission.

Digoxin: In patients with reduced EF, digoxin may be used to control the ventricular rate in atrial fibrillation, especially if it has not been possible to up-titrate the dose of beta-blocker. Digoxin may also provide symptom benefit and reduce the risk of hospital admission for heart failure in patients with severe systolic heart failure.

It is common to restrict sodium intake to <2 g/day and fluid intake to <1.5–2.0 L/day, especially during the initial management of an acute episode of heart failure associated with volume overload, although there is no firm evidence to support this practice.

Noninvasive ventilation: Continuous positive airway pressure and noninvasive positive pressure ventilation relieve dyspnoea and improve certain physiological measures (e.g. oxygen saturation) in patients with acute pulmonary edema.

Noninvasive ventilation should be considered in dyspnoeic patients with pulmonary edema and a respiratory rate >20 breaths/minute to improve breathlessness and reduce hypercapnia and acidosis.

Noninvasive ventilation can reduce blood pressure and should not generally be used in patients with a systolic blood pressure of <85 mmHg (and blood pressure should be monitored regularly when this treatment is used).

A recent large RCT showed that neither type of noninvasive ventilation reduced mortality or the rate of endotracheal intubation when compared with standard therapy, including nitrates and opiates.

Endotracheal intubation and invasive ventilation: The primary indication for endotracheal intubation and invasive ventilation is respiratory failure leading to hypoxaemia, hypercapnia, and acidosis.

Physical exhaustion, diminished consciousness, and inability to maintain or protect the airway are other reasons to consider intubation and ventilation.

Mechanical circulatory support: The conventional indications for an intra-aortic balloon pump are to support the circulation before surgical correction of specific acute mechanical problems, during severe acute myocarditis and in selected patients with acute myocardial ischemia or infarction before, during, and after percutaneous or surgical revascularisation. There is no good evidence that an IABP is of benefit in other causes of cardiogenic shock. More recently, balloon pumps (and other types of short-term, temporary circulatory support) have been used to bridge patients until implantation of a ventricular assist device or heart transplantation.

Ventricular assist devices and other forms of mechanical circulatory support (MCS) may be used as a 'bridge to decision' or longer term in selected patients.

Ultrafiltration: Venovenous isolated ultrafiltration is sometimes used to remove fluid in patients with heart failure, although it is usually reserved for those unresponsive or resistant to diuretics.

Other Treatments

Arrhythmias: Pacing is recommended in patients hemodynamically compromised by severe bradycardia or heart block.

Renal dysfunction may limit the use of ACE inhibitors and AIIRAs; progressive acute kidney injury and volume overload may require renal replacement therapy.

Surgical options include coronary revascularisation, correction of anatomical lesions, valve replacement or reconstruction, mechanical assist devices for temporary circulatory support and heart transplantation.

In severe cases of refractory cardiogenic shock, consider early transfer of appropriate patients to a tertiary medical center where, if clinically indicated, more advanced treatments, such as implantation of a left ventricular assist device and or cardiac transplantation, may be performed.

BIBLIOGRAPHY

1. Bauer JB, Randazzo MA. Nesiritide for outpatient treatment of heart failure. Am J Health Syst Pharm 2005;15;62(24): 2639–2642.
2. Binanay C, Califf RM, Hasselblad V, et al. Evaluation study of congestive heart failure and pulmonary artery catheterization effectiveness: the ESCAPE trial. JAMA 2005;294(5): 1625–33.
3. Cheng JW, Merl MY, Nguyen HM. Effect of nesiritide on renal function: a retrospective review. Curr Med Res Opin 2005;21(11):1857–63.
4. Ducharme A, Swedberg K, Pfeffer MA, et al. Prevention of atrial fibrillation in patients with symptomatic chronic heart failure by candesartan in the Candesartan in Heart failure: Assessment of Reduction in Mortality and morbidity (CHARM) program. Am Heart J 2006;152(1):86–92.
5. Earl GL, Fitzpatrick JT. Levosimendan: a novel inotropic agent for treatment of acute, decompensated heart failure. Ann Pharmacother 2005;39(11):1888–96.
6. Follath F, Franco F, Cardoso JS. European experience on the practical use of levosimendan in patients with acute heart failure syndromes. Am J Cardiol 2005;96(6A):80G–5G.
7. Frontin P, Bounes V, Houze-Cerfon CH, et al. Continuous positive airway pressure for cardiogenic pulmonary edema: a randomized study. Am J Emerg Med. 2011;29(7):775–81.
8. LHer E, Duquesne F, Girou E, de Rosiere XD, et al. Noninvasive continuous positive airway pressure in elderly cardiogenic pulmonary edema patients. Intensive Care Med 2004;30(5):882–8.
9. Maggioni AP, Latini R, Carson PE, et al. Valsartan reduces the incidence of atrial fibrillation in patients with heart failure: results from the Valsartan Heart Failure Trial (Val-HeFT). Am Heart J 2005;149(3):548–57.
10. Mehta S, Jay GD, Woolard RH. Randomized, prospective trial of bilevel versus continuous positive airway pressure in acute pulmonary edema. Crit Care Med 1997;25(4):620–8.
11. Mehta S, Nava S. Mask ventilation and cardiogenic pulmonary edema: another brick in the wall. Intensive Care Med 2005;31(6):757–9.
12. Newby D. Efficacy of non-invasive ventilation in patients with acute cardiogenic pulmonary edema: The 3CPO trial. Presented at the ESC meeting. Sept 2007.
13. O'Connor CM, Starling RC, Hernandez AF, et al. Effect of nesiritide in patients with acute decompensated heart failure. N Engl J Med 2011;365(1):32–43.
14. Parissis JT, Filippatos G, Farmakis D, et al. Levosimendan for the treatment of acute heart failure syndromes. Expert Opin.
15. Ray P, Arthaud M, Birolleau S, et al. Comparison of brain natriuretic peptide and probrain natriuretic peptide in the diagnosis of cardiogenic pulmonary edema in patients aged 65 and older. J Am Geriatr Soc 2005;53(4):643–8.
16. Scroggins N, Edwards M, Delgado R (3rd). Increased cost effectiveness with nesiritide vs. milrinone or dobutamine in the treatment of acute decompensated heart failure. Congest Heart Fail 2005;11(6):311–4.
17. Weitz G, Struck J, Zonak A, et al. Prehospital noninvasive pressure support ventilation for acute cardiogenic pulmonary edema. Eur J Emerg Med 2007;14(5):276–9.

8 Recognition and Management of Heart Failure

Heart failure is the pathophysiologic state in which the heart, via an abnormality of cardiac function (detectable or not), fails to pump blood at a rate commensurate with the requirements of the metabolizing tissues or is able to do so only with an elevated diastolic filling pressure. Heart failure is a common condition, affecting up to 3 per cent of the population aged 45 and older, and is associated with high mortality and poor quality of life. Major diagnostic and therapeutic advances have been made over the past three decades, but international and national audits suggest that many patients are incompletely investigated and treated.

Heart failure may be caused by myocardial failure, but may also occur in the presence of near-normal cardiac function under conditions of high demand. Heart failure always causes circulatory failure, but the converse is not necessarily the case, because various noncardiac conditions (e.g. hypovolemic shock, septic shock) can produce circulatory failure in the presence of normal, modestly impaired, or even supranormal cardiac function. To maintain the pumping function of the heart, compensatory mechanisms increase blood volume, cardiac filling pressure, heart rate, and cardiac muscle mass. However, despite these mechanisms, there is progressive decline in the ability of the heart to contract and relax, resulting in worsening heart failure.

Signs and symptoms of heart failure include tachycardia and manifestations of venous congestion (e.g. edema) and low cardiac output (e.g. fatigue). Breathlessness is a cardinal symptom of left ventricular (LV) failure that may manifest with progressively increasing severity (Figs 8.1 and 8.2).



Fig. 8.1: A 40-year-old male patient showing generalized edema of the body, ascites and semiconscious state of mind in severe form of heart failure

CLASSIFICATION IN HEART FAILURE

Heart failure can be classified according to a variety of factors (*see* heart failure criteria and classification).

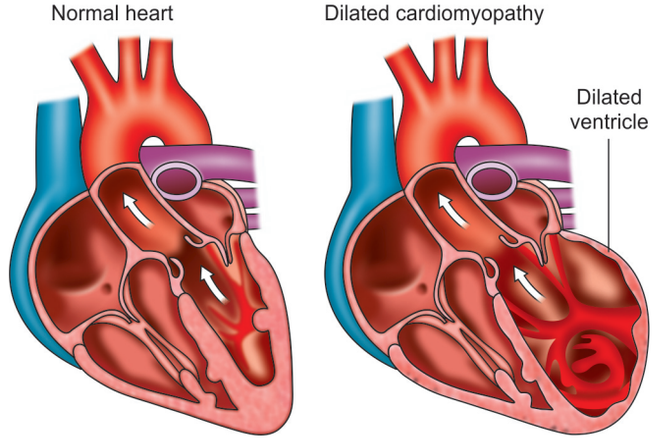

Fig. 8.2: Normal heart (left) and dilated cardiomyopathy as one of the causes of heart failure

Table 8.1: NYHA functional classification of heart failure

Class	Functional capacity
I	Patients without limitation of physical activity
II	Patients with slight limitation of physical activity, in which ordinary physical activity leads to fatigue, palpitation, dyspnea, or anginal pain; they are comfortable at rest
III	Patients with marked limitation of physical activity, in which less than ordinary activity results in fatigue, palpitation, dyspnea, or anginal pain; they are comfortable at rest
IV	Patients who are not only unable to carry on any physical activity without discomfort but also have symptoms of heart failure or the anginal syndrome even at rest; the patient's discomfort increases if any physical activity is undertaken

Source: American Heart Association. Classes of heart failure. Available at:http://www.heart.org/HEARTORG/Conditions/HeartFailure/AboutHeartFailure/Classes-of-Heart-Failure_UCM_306328_Article.jsp. Accessed: September 6, 2011.

The New York Heart Association (NYHA) classification for heart failure comprises four classes, based on the relationship between symptoms and the amount of effort required to provoke them, as follows (Table 8.1):

- Class I patients have no limitation of physical activity
- Class II patients have slight limitation of physical activity
- Class III patients have marked limitation of physical activity
- Class IV patients have symptoms even at rest and are unable to carry on any physical activity without discomfort

The American College of Cardiology/American Heart Association (ACC/AHA) heart failure guidelines complement the NYHA classification to reflect the progression of disease and are divided into four stages, as follows:

- **Stage A** patients are at high risk for heart failure but have no structural heart disease or symptoms of heart failure
- **Stage B** patients have structural heart disease but have no symptoms of heart failure
- **Stage C** patients have structural heart disease and have symptoms of heart failure
- **Stage D** patients have refractory heart failure requiring specialized interventions

PATHOPHYSIOLOGY OF HEART FAILURE

The common pathophysiologic state that perpetuates the progression of heart failure is extremely complex, regardless of the precipitating event. Compensatory mechanisms exist on every level of organization, from subcellular all the way through organ-to-organ interactions. Only when this network of adaptations becomes overwhelmed does heart failure ensue (Fig. 8.3).

Adaptations

Most important among the adaptations are the following:

- The Frank-Starling mechanism, in which an increased preload helps to sustain cardiac performance
- Alterations in myocyte regeneration and death
- Myocardial hypertrophy with or without cardiac chamber dilatation, in which the mass of contractile tissue is augmented.

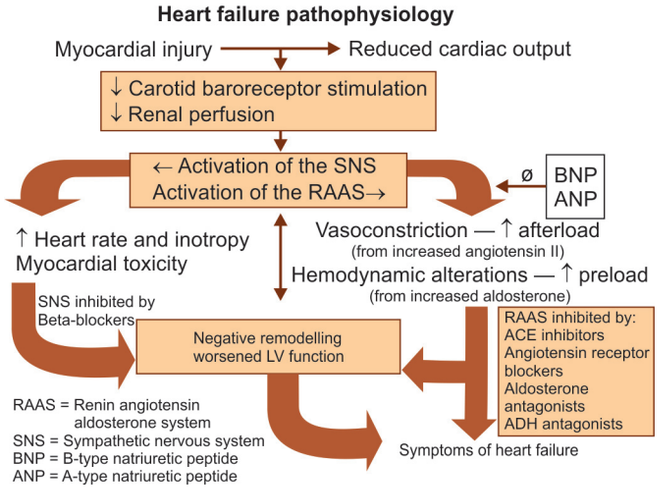

Fig. 8.3: Various steps in the pathophysiology of heart failure

Activation of Neurohumoral Systems

The release of norepinephrine by adrenergic cardiac nerves augments myocardial contractility and includes activation of the renin-angiotensin-aldosterone system (RAAS), the sympathetic nervous system (SNS), and other neurohumoral adjustments that act to maintain arterial pressure and perfusion of vital organs.

- In acute heart failure, the finite adaptive mechanisms that may be adequate to maintain the overall contractile performance of the heart at relatively normal levels become maladaptive when trying to sustain adequate cardiac performance.
- The primary myocardial response to chronic increased wall stress is myocyte hypertrophy, death/apoptosis, and regeneration. This process eventually leads to remodeling, usually the eccentric type. Eccentric remodeling further worsens the loading conditions on the remaining myocytes and perpetuates the deleterious cycle. The idea of lowering wall stress to slow the process of remodeling has long been exploited in treating heart failure patients.
- The reduction of cardiac output following myocardial injury sets into motion a cascade of hemodynamic and neurohormonal derangements that provoke activation of neuroendocrine systems, most notably the above-mentioned adrenergic systems and RAAS.

- The release of epinephrine and norepinephrine, along with the vasoactive substances endothelin-1 (ET-1) and vasopressin, causes vasoconstriction, which increases calcium afterload and, via an increase in cyclic adenosine monophosphate (cAMP), causes an increase in cytosolic calcium entry. The increased calcium entry into the myocytes augments myocardial contractility and impairs myocardial relaxation (lusitropy).
- The calcium overload may induce arrhythmias and lead to sudden death. The increase in afterload and myocardial contractility (known as inotropy) and the impairment in myocardial lusitropy lead to an increase in myocardial energy expenditure and a further decrease in cardiac output. The increase in myocardial energy expenditure leads to myocardial cell death/apoptosis, which results in heart failure and further reduction in cardiac output, perpetuating a cycle of further increased neurohumoral stimulation and further adverse hemodynamic and myocardial responses.
- In addition, the activation of the RAAS leads to salt and water retention, resulting in increased preload and further increases in myocardial energy expenditure. Increases in renin, mediated by decreased stretch of the glomerular afferent arteriole, reduce delivery of chloride to the macula densa and increase beta1-adrenergic activity as a response to decreased cardiac output. This results in an increase in angiotensin II (Ang II) levels and, in turn, aldosterone levels, causing stimulation of the release of aldosterone. Ang II, along with ET-1, is crucial in maintaining effective intravascular homeostasis mediated by vasoconstriction and aldosterone-induced salt and water retention.
- The concept of the heart as a self-renewing organ is a relatively recent development.This new paradigm for myocyte biology has created an entire field of research aimed directly at augmenting myocardial regeneration. The rate of myocyte turnover has been shown to increase during times of pathologic stress. In heart failure, this mechanism for replacement becomes overwhelmed by an even faster increase in the rate of myocyte loss. This imbalance of hypertrophy and death over regeneration is the final common pathway at the cellular level for the progression of remodeling and heart failure.

Ang II

Research indicates that local cardiac Ang II production (which decreases lusitropy, increases inotropy, and increases afterload) leads to increased myocardial energy expenditure. Ang II has also been shown *in vitro* and *in vivo* to increase the rate of myocyte apoptosis. In this fashion, Ang II has similar actions to norepinephrine in heart failure.

Ang II also mediates myocardial cellular hypertrophy and may promote progressive loss of myocardial function. The neurohumoral factors above lead to myocyte hypertrophy and interstitial fibrosis, resulting in increased myocardial volume and increased myocardial mass, as well as myocyte loss. As a result, the cardiac architecture changes, which, in turn, leads to further increase in myocardial volume and mass.

Myocytes and Myocardial Remodeling

In the failing heart, increased myocardial volume is characterized by larger myocytes approaching the end of their life cycle. As more myocytes drop out, an increased load is placed on the remaining myocardium, and this unfavorable environment is transmitted to the progenitor cells responsible for replacing lost myocytes.

Progenitor cells become progressively less effective as the underlying pathologic process worsens and myocardial failure accelerates. These features namely, the increased myocardial volume and mass, along with a net loss of myocytes are the hallmark of myocardial remodeling. This remodeling process leads to early adaptive mechanisms, such as augmentation of stroke volume (Frank-Starling mechanism) and decreased wall stress (Laplace's law), and, later, to maladaptive mechanisms such as increased myocardial oxygen demand, myocardial ischemia, impaired contractility, and arrhythmogenesis.

As heart failure advances, there is a relative decline in the counterregulatory effects of endogenous vasodilators, including nitric oxide (NO), prostaglandins (PGs), bradykinin (BK), atrial natriuretic peptide (ANP), and B-type natriuretic peptide (BNP). This decline occurs simultaneously with the increase in vasoconstrictor substances from the RAAS and the adrenergic system, which fosters further increases in vasoconstriction and thus preload and afterload. This results in cellular proliferation, adverse myocardial remodeling, and antinatriuresis, with total body fluid excess and worsening of heart failure symptoms.

Systolic and Diastolic Failure

Systolic and diastolic heart failure each results in a decrease in stroke volume. This leads to activation of peripheral and central baroreflexes and chemoreflexes that are capable of eliciting marked increases in sympathetic nerve traffic (Tables 8.2–8.4).

Table 8.2: Causes of systolic heart failure

- Coronary artery disease
- Hypertension
- Alcohol
- Valvular heart disease
- Familial genetic cardiomyopathy
- Myocarditis
- Toxins (chemotherapy, cocaine)
- Collagen vascular disease
- Metabolic disorders
- Endocrine disorders
- Electrolyte disorders
- Acidosis
- Sepsis
- Hypoxia
- Severe sleep apnea

Table 8.3: Criteria for diagnosis of diastolic heart failure

European study group

1. Evidence of CHF
2. Normal or mildly abnormal LV systolic function
3. Evidence of abnormal LV relaxation, filling, distensibility or stiffness

Framingham heart study

1. Definitive diagnosis of CHF (signs and symptoms; CXR; response to diuretics)
2. LVEF greater than or equal to 50% within 72 hours of episode
3. Objective evidence of LV diastolic dysfunction (abnormal LV relaxation/filling distensibility indices by catheterization)

While there are commonalities in the neurohormonal responses to decreased stroke volume, the neurohormone-mediated events that follow have been most clearly elucidated for individuals with systolic heart failure. The ensuing elevation in plasma norepinephrine directly correlates with the degree of cardiac dysfunction and has significant prognostic implications. Norepinephrine, while directly toxic to cardiac myocytes, is also responsible for a variety of signal-transduction abnormalities, such as down-regulation of beta1-adrenergic receptors, uncoupling of beta2-adrenergic receptors, and increased activity of inhibitory G-protein. Changes in beta1-adrenergic receptors result in overexpression and promote myocardial hypertrophy.

PATHOPHYSIOLOGY OF DIASTOLIC HEART FAILURE (DHF)

Diastole is the process by which the heart returns to its relaxed state; it is also the time for cardiac perfusion. Drastic changes occur in cardiac pressure-volume relationships during diastole. The diastolic process has four identifiable phases: isovolumetric relaxation time, the time of aortic valve closure to mitral valve opening; early rapid filling after mitral valve opening; diastasis, a period of low flow during mid-diastole and late filling of the ventricles by atrial contraction.Diastole is a complex process that is affected by a number of factors, including hypertension, ischemia, heart rate, velocity of relaxation, cardiac compliance (i.e. elastic recoil and stiffness), hypertrophy and segmental wall coordination of the heart muscle. The pathophysiology of diastolic dysfunction includes delayed relaxation, impaired LV filling and/or increased stiffness. These conditions result typically in an upward displacement of the diastolic pressure-volume relationship with increased end-diastolic, left atrial and pulmocapillary wedge pressure leading to DHF.Chronic hypertension is the most common cause of diastolic dysfunction and failure. It leads to left ventricular hypertrophy and increased connective tissue content, both of which decrease cardiac compliance.

The hypertrophied ventricle has a steeper diastolic pressure-volume relationship; therefore, a small increase

Table 8.4: Clues for differentiating between systolic and diastolic dysfunction in patients with heart failure

Clues from the evaluation	Systolic dysfunction	Diastolic dysfunction
History		
Hypertension	XX	XXX
Coronary artery disease*	XXX	X
Diabetes mellitus	XXX	XX
Valvular heart disease*	XXX	—
Physical examination		
Third heard sound (S 3) gallop*	XXX	X
Fourth heart sound (S 4) gallop*	X	XXX
Rales	XX	XX
Jugular venous distention	XX	X
Edema	XX	X
Displaced point of maximal impulse*	XX	—
Mitral regurgitation*	XXX	X
Chest radiograph		
Cardiomegaly*	XXX	X
Pulmonary congestion	XXX	XXX
Electrocardiogram Q-wave	XX	X
Left ventricular hypertrophy*	X	XXX
Echocardiogram Decreased ejection fraction*	XXX	—
Dilated left ventricle*	XX	—
Left ventricle hypertrophy*	X	XXX

X=suggestive; the number of Xs reflects the relative weight; —=not suggestive. *=Particularly helpful in distinguishing systolic from diastolic dysfunction in heart failure. Adapted with permission from Young JB. Assessment of heart failure. In: Braunwald E. Atlas of heart disease. Vol 4. Philadelphia: Current Medicine, 1995:7.1–7.2

in left ventricular end-diastolic volume causes a marked increase in left ventricular end diastolic pressure. Another most common cardiac disease associated with abnormal LV diastolic function is myocardial ischemia. Relaxation of the ventricles involves the active transport of calcium ions into the sarcoplasmic reticulum, which allows the dissociation of myosin-actin cross bridges. Myocardial ischemia deprives the system of adequate adenosine triphosphate, which in turn inhibits the dissociation process by altering the balance of the adenosine triphosphate to adenosine diphosphate ratio, which may contribute to diastolic dysfunction. The heart rate determines the time that is available for diastolic filling, coronary perfusion and ventricular relaxation. In DHF, increase in cardiac output relatively depends upon heart rate but a rapid heart rate may further elevate abnormal LV filling pressures.

Tachycardia adversely affects diastolic function by several mechanisms; it decreases left ventricular filling and coronary perfusion times, increases myocardial oxygen consumption and causes incomplete relaxation because the stiff heart cannot increase its velocity of relaxation as heart rate increases. In effect, the ventricle may never fully relax to receive blood adequately. Similarly, atrial fibrillation completely eliminates the late diastolic atrial contribution to LV filling, upon which patients with diastolic dysfunction are dependent, often precipitating pulmonary edema.

Diastolic dysfunction is more common in elderly persons, partly because of increased collagen cross-linking, increased smooth muscle content and loss of elastic fibers. These changes tend to decrease ventricular compliance it making more susceptible to the adverse effects of hypertension, tachycardia and atrial fibrillation.

In last two decades there is a substantial increase in prevalence of diastolic heart failure from 38–54%. The prognosis of patients suffering from DHF is as ominous as prognosis of patients suffering from systolic heart failure (SHF). The various predisposing factors are old age, female gender, metabolic syndrome, diabetes, arterial hypertension and left ventricular hypertrophy. Elderly patients usually present with DHF in the setting of acute myocardial infarction. As there is epidemiological evolution towards DHF in the population all over the world, a reappraisal of original established set of criteria is necessary for diagnosis of DHF. However, newer modalities of Echo-Doppler strain techniques may help in predicting the precursors of DHF. These echo variables include left atrial (LA) strain and strain rate, LA stiffness and LA ejection fraction. Segmental left ventricular (LV) deformation analysis for calculating contractile parameters such as strain and strain rate is now possible using noninvasive echo-Doppler techniques. It has been reported that LA systolic and diastolic function can also be assessed using these Doppler strain techniques. Although LA enlargement increases with the severity of diastolic dysfunction, the ability of LA volume measurements to discriminate asymptomatic LV diastolic dysfunction from early DHF heart failure has not been possible. However, the concept that an alteration in LA function or stiffness may be the early indicators of occult diastolic dysfunction and is therefore novel and worth exploring.

Diagnosis of Diastolic Heart Failure

The working group for the european society of cardiology proposed that diagnosis of DHF requires three obligatory diagnostic criteria to be simultaneously satisfied; signs and symptoms of congestive heart failure; normal or mildly abnormal systolic LV systolic function and evidence of LV diastolic dysfunction (abnormal LV relaxation, filling, diastolic distensibility or diastolic stiffness).

1. Signs and symptoms of congestive heart failure signs include lung crepitations, pulmonary edema, ankle swelling, hepatomegaly, dyspnea on exertion and fatigue.
2. Normal or mildly abnormal systolic left ventricular function.

The presence of normal or mildly abnormal systolic LV function constitutes the second criterion for the diagnosis of heart failure (HF) with normal left ventricular ejection fraction (LVEF)-HFNLVEF. In the present consensus document, an LVEF >50% is also considered consistent with the presence of normal or mildly abnormal systolic LV function. LVEF needs to be assessed in accordance to the recent recommendations for cardiac chamber quantification of the American Society of Echocardiography and the European Association of Echocardiography. It is of importance to note that in DHF reduced long-axis shortening is frequently compensated for by increased short-axis shortening. As already demonstrated by Frank, Starling, and Wiggers and later re-appraised, LV relaxation depends on endsystolic load and volume. The criterion of presence of normal or mildly abnormal LV function therefore needs to be implemented with measures of LV volumes. To exclude significant LV enlargement 25, LVEDVI and LV end-systolic volume index cannot exceed 97 ml/m^2 and 49 ml/m^2, respectively.

ANP and BNP

ANP and BNP are endogenously generated peptides activated in response to atrial and ventricular volume/pressure expansion. ANP and BNP are released from the atria and ventricles, respectively, and both promote vasodilation and natriuresis. Their hemodynamic effects are mediated by decreases in ventricular filling pressures, owing to reductions in cardiac preload and afterload. BNP, in particular, produces selective afferent arteriolar vasodilation and inhibits sodium reabsorption in the proximal convoluted tubule. It also inhibits renin and aldosterone release and, therefore, adrenergic activation. ANP and BNP are elevated in chronic heart failure. BNP, in particular, has potentially important diagnostic, therapeutic, and prognostic implications.

Other Vasoactive Systems

Other vasoactive systems that play a role in the pathogenesis of heart failure include the ET receptor system, the

adenosine receptor system, vasopressin, and tumor necrosis factor-alpha (TNF-alpha). ET, a substance produced by the vascular endothelium, may contribute to the regulation of myocardial function, vascular tone, and peripheral resistance in heart failure. Elevated levels of ET-1 closely correlate with the severity of heart failure. ET-1 is a potent vasoconstrictor and has exaggerated vasoconstrictor effects in the renal vasculature, reducing renal plasma blood flow, glomerular filtration rate (GFR), and sodium excretion. TNF-alpha has been implicated in response to various infectious and inflammatory conditions. Elevations in TNF-alpha levels have been consistently observed in heart failure and seem to correlate with the degree of myocardial dysfunction. Some studies suggest that local production of TNF-alpha may have toxic effects on the myocardium, thus worsening myocardial systolic and diastolic function.

In individuals with systolic dysfunction, therefore, the neurohormonal responses to decreased stroke volume result in temporary improvement in systolic blood pressure and tissue perfusion. However, in all circumstances, the existing data support the notion that these neurohormonal responses contribute to the progression of myocardial dysfunction in the long term.

Heart Failure with Normal Ejection Fraction

In diastolic heart failure [heart failure with normal ejection fraction (HFNEF)], the same pathophysiologic processes occur that lead to decreased cardiac output in systolic heart failure, but they do so in response to a different set of hemodynamic and circulatory environmental factors that depress cardiac output.

In HFNEF, altered relaxation and increased stiffness of the ventricle (due to delayed calcium uptake by the myocyte sarcoplasmic reticulum and delayed calcium efflux from the myocyte) occur in response to an increase in ventricular afterload (pressure overload). The impaired relaxation of the ventricle then leads to impaired diastolic filling of the left ventricle (LV). Morris et al. found that RV subendocardial systolic dysfunction and diastolic dysfunction, as detected by echocardiographic strain rate imaging, are common in patients with HFNEF. This dysfunction is potentially associated with the same fibrotic processes that affect the subendocardial layer of the LV and, to a lesser extent, with RV pressure overload. This may play a role in the symptomatology of patients with HFNEF.

LV Chamber Stiffness

An increase in LV chamber stiffness occurs secondary to any one of, or any combination of, the following three mechanisms:

Rise in Filling Pressure

- Shift to a steeper ventricular pressure-volume curve
- Decrease in ventricular distensibility
- A rise in filling pressure is the movement of the ventricle up along its pressure-volume curve to a steeper portion, as may occur in conditions such as volume overload secondary to acute valvular regurgitation or acute LV failure due to myocarditis.
- A shift to a steeper ventricular pressure-volume curve results, most commonly, not only from increased ventricular mass and wall thickness (as observed in aortic stenosis and long-standing hypertension) but also from infiltrative disorders (e.g. amyloidosis), endomyocardial fibrosis, and myocardial ischemia.
- Parallel upward displacement of the diastolic pressure-volume curve is generally referred to as a decrease in ventricular distensibility. This is usually caused by extrinsic compression of the ventricles.

Concentric LV Hypertrophy

Pressure overload that leads to concentric LV hypertrophy (LVH), as occurs in aortic stenosis, hypertension, and hypertrophic cardiomyopathy, shifts the diastolic pressure-volume curve to the left along its volume axis. As a result, ventricular diastolic pressure is abnormally elevated, although chamber stiffness may or may not be altered.

Increases in diastolic pressure lead to increased myocardial energy expenditure, remodeling of the ventricle, increased myocardial oxygen demand, myocardial ischemia, and eventual progression of the maladaptive mechanisms of the heart that lead to decompensated heart failure.

Arrhythmias

While life-threatening rhythms are more common in ischemic cardiomyopathy, arrhythmia imparts a significant burden in all forms of heart failure. In fact, some arrhythmias even perpetuate heart failure. The most significant of all rhythms associated with heart failure are the life-threatening ventricular arrhythmias. Structural substrates for ventricular arrhythmias that are common in heart failure, regardless of the underlying cause, include ventricular dilatation, myocardial hypertrophy, and myocardial fibrosis. At the cellular level, myocytes may be exposed to increased stretch, wall tension, catecholamines, ischemia, and electrolyte imbalance. The combination of these factors contributes to an increased incidence of arrhythmogenic sudden cardiac death in patients with heart failure.

AETIOLOGICAL FACTORS

Most patients who present with significant heart failure do so because of an inability to provide adequate cardiac output in that setting. This is often a combination of the causes listed below in the setting of an abnormal myocardium. The list of causes responsible for presentation of a patient with heart failure exacerbation is very long, and searching for the proximate cause to optimize therapeutic interventions is important.

From a clinical standpoint, classifying the causes of heart failure into the following four broad categories is useful:

1. **Underlying causes:** Underlying causes of heart failure include structural abnormalities (congenital or acquired) that affect the peripheral and coronary arterial circulation, pericardium, myocardium, or cardiac valves, thus leading to increased hemodynamic burden or myocardial or coronary insufficiency.

2. **Fundamental causes:** Fundamental causes include the biochemical and physiologic mechanisms, through which either an increased hemodynamic burden or a reduction in oxygen delivery to the myocardium results in impairment of myocardial contraction.
3. **Precipitating causes:** Overt heart failure may be precipitated by progression of the underlying heart disease (e.g. further narrowing of a stenotic aortic valve or mitral valve) or various conditions (fever, anemia and infection) or medications [chemotherapy, (NSAIDs)] that alter the homeostasis of heart failure patients.
4. **Genetics of cardiomyopathy:** Dilated, arrhythmic right ventricular and restrictive cardiomyopathies are known genetic causes of heart failure.

UNDERLYING CAUSES

Specific underlying factors cause various forms of heart failure, such as systolic heart failure (most commonly, left ventricular systolic dysfunction), heart failure with preserved LVEF, acute heart failure, high-output heart failure, and right heart failure.

Underlying causes of systolic heart failure include the following:

- Coronary artery disease
- Diabetes mellitus
- Hypertension
- Valvular heart disease (stenosis or regurgitant lesions)
- Arrhythmia (supraventricular or ventricular)
- Infections and inflammation (myocarditis)
- Peripartum cardiomyopathy
- Congenital heart disease
- Drugs (either recreational, such as alcohol and cocaine, or therapeutic drugs with cardiac side effects, such as doxorubicin)
- Idiopathic cardiomyopathy
- Rare conditions (endocrine abnormalities, rheumatologic disease, neuromuscular conditions).

Underlying causes of diastolic heart failure include the following:

- Coronary artery disease
- Diabetes mellitus
- Hypertension
- Valvular heart disease (aortic stenosis)
- Hypertrophic cardiomyopathy
- Restrictive cardiomyopathy (amyloidosis, sarcoidosis)
- Constrictive pericarditis

Underlying causes of acute heart failure include the following:

- Acute valvular (mitral or aortic) regurgitation
- Myocardial infarction
- Myocarditis
- Arrhythmia
- Drugs (e.g. cocaine, calcium channel blockers, or beta-blocker overdose)
- Sepsis

Underlying causes of high-output heart failure include the following:

- Anemia
- Systemic arteriovenous fistulas
- Hyperthyroidism
- Beriberi heart disease
- Paget disease of bone
- Albright syndrome (fibrous dysplasia)
- Multiple myeloma
- Pregnancy
- Glomerulonephritis
- Polycythemia vera
- Carcinoid syndrome.

Underlying causes of right heart failure include the following:

- Left ventricular failure
- Coronary artery disease (ischemia)
- Pulmonary hypertension
- Pulmonary valve stenosis
- Pulmonary embolism
- Chronic pulmonary disease
- Neuromuscular disease.

Precipitating Causes of Heart Failure

A previously stable, compensated patient may develop heart failure that is clinically apparent for the first time when the intrinsic process has advanced to a critical point, such as with further narrowing of a stenotic aortic valve or mitral valve. Alternatively, decompensation may occur as a result of failure or exhaustion of the compensatory mechanisms but without any change in the load on the heart in patients with persistent, severe pressure or volume overload. In particular, consider whether the patient has underlying coronary artery disease or valvular heart disease (Table 8.5).

The most common cause of decompensation in a previously compensated patient with heart failure is

Table 8.5: Decompensated advanced heart failure, precipitating factors

- Poor medication or dietary compliance (sodium, fluid)
- Uncontrolled hypertension
- Cardiac arrhythmias
  - New onset sustained tachy or brady arrhythmias
  - Paroxysmal atrial fibrillation/flutter
- Envioronmental factors/stresses
- Inadequate chronic therapy
  - Inadequate ACE inhibition
- Myocardial infarction/ischemia
- Progression of underlying cardiac disease
- Superimposed new disease
  - Pulmonary infection
  - Pulmonary thromboembolism
  - Thyroid disease (amiodarone)
  - Anemia

inappropriate reduction in the intensity of treatment, such as dietary sodium restriction, physical activity reduction, or drug regimen reduction. Uncontrolled hypertension is the second most common cause of decompensation, followed closely by cardiac arrhythmias (most commonly, atrial fibrillation). Arrhythmias, particularly ventricular arrhythmias, can be life threatening. Also, patients with one form of underlying heart disease that may be well compensated can develop heart failure when a second form of heart disease ensues. For example, a patient with chronic hypertension and asymptomatic LVH may be asymptomatic until a myocardial infarction (MI) develops and precipitates heart failure.

Systemic infection or the development of unrelated illness can also lead to heart failure. Systemic infection precipitates heart failure by increasing total metabolism as a consequence of fever, discomfort, and cough, increasing the hemodynamic burden on the heart. Septic shock, in particular, can precipitate heart failure by the release of endotoxin-induced factors that can depress myocardial contractility.

Cardiac infection and inflammation can also endanger the heart. Myocarditis or infective endocarditis may directly impair myocardial function and exacerbate existing heart disease. The anemia, fever, and tachycardia that frequently accompany these processes are also deleterious. In the case of infective endocarditis, the additional valvular damage that ensues may precipitate cardiac decompensation. Patients with heart failure, particularly when confined to bed, are at high risk of developing pulmonary emboli, which can increase the hemodynamic burden on the right ventricle by further elevating right ventricular (RV) systolic pressure, possibly causing fever, tachypnea, and tachycardia. Intense, prolonged physical exertion or severe fatigue, such as may result from prolonged travel or emotional crisis, is a relatively common precipitant of cardiac decompensation. The same is true of exposure to severe climate change (i.e. the individual comes in contact with a hot, humid environment or a bitterly cold one).

Excessive intake of water and/or sodium and the administration of cardiac depressants or drugs that cause salt retention are other factors that can lead to heart failure. Because of increased myocardial oxygen consumption and demand beyond a critical level, the following high-output states can precipitate the clinical presentation of heart failure:

- Profound anemia
- Thyrotoxicosis
- Myxedema
- Paget disease of bone
- Albright syndrome
- Multiple myeloma
- Glomerulonephritis
- Cor pulmonale
- Polycythemia vera
- Obesity
- Carcinoid syndrome
- Pregnancy
- Nutritional deficiencies (e.g. thiamine deficiency, beriberi)

Longitudinal data from the Framingham Heart Study suggests that antecedent subclinical left ventricular systolic or diastolic dysfunction is associated with an increased incidence of heart failure, supporting the notion that heart failure is a progressive syndrome. Another analysis of over 36,000 patients undergoing outpatient echocardiography reported that moderate or severe diastolic dysfunction, but not mild diastolic dysfunction, is an independent predictor of mortality.

Genetics of Cardiomyopathy

Autosomal dominant inheritance has been demonstrated in dilated cardiomyopathy and in arrhythmic right ventricular cardiomyopathy. Restrictive cardiomyopathies are usually sporadic and associated with the gene for cardiac troponin I. Genetic tests are available at major genetic centers for cardiomyopathies.

In families with a first-degree relative who has been diagnosed with a cardiomyopathy leading to heart failure, the at-risk patient should be screened and followed. The recommended screening consists of an electrocardiogram and an echocardiogram. If the patient has an asymptomatic left ventricular dysfunction, it should be treated.

The Heart Failure Society of America (HFSA) also has the following recommendations for genetic evaluation of cardiomyopathy:

- For all patients with cardiomyopathy, take a detailed family history for at least three generations [hypertrophic cardiomyopathy (HCM), dilated cardiomyopathy (DCM), arrhythmic right ventricular dysplasia (ARVD), left ventricular noncompaction (LVNC), restrictive cardiomyopathy (RCM), and cardiomyopathies associated with extra-cardiac manifestations].
- Carefully assess the patient's medical history as well as that of asymptomatic first-degree relatives, with special focus on heart failure symptoms, arrhythmias, presyncope, and syncope.
- Screen asymptomatic first-degree relatives for cardiomyopathy (HCM, DCM, ARVD, LVNC, RCM, and cardiomyopathies associated with extra-cardiac manifestations).
- Screen for cardiomyopathy at intervals in asymptomatic at-risk relatives who are known to carry the disease-causing mutation(s).
- Screen for cardiomyopathy in asymptomatic at-risk first-degree relatives who have not undergone genetic testing or in whom a disease-causing mutation has not been identified.

Note: Due to the complexity of genetic evaluation, testing, and counseling of patients with cardiomyopathy, it is recommended that patients be referred to centers with expertise in these matters and in family-based management.

Medical History

In evaluating heart failure patients, the clinician should ask about the following comorbidities and/or risk factors:

- Myopathy
- Previous MI
- Valvular heart disease
- familial heart disease
- Alcohol use
- Hypertension
- Diabetes
- Dyslipidemia
- Coronary/peripheral vascular disease
- Sleep-disordered breathing
- Collagen vascular disease, rheumatic fever
- Pheochromocytoma
- Thyroid disease
- Substance abuse history
- History of chemotherapy/radiation to the chest

The New York Heart Association (NYHA) classification of heart failure: It is widely used in practice and in clinical studies to quantify clinical assessment of heart failure. Breathlessness, a cardinal symptom of LV failure, may manifest with progressively increasing severity as the following:

- Exertional dyspnea
- Orthopnea
- Paroxysmal nocturnal dyspnea
- Dyspnea at rest
- Acute pulmonary edema

Other cardiac symptoms of heart failure include chest pain/pressure and palpitations. Common noncardiac signs and symptoms of heart failure include anorexia, nausea, weight loss, bloating, fatigue, weakness, oliguria, nocturia, and cerebral symptoms of varying severity, ranging from anxiety to memory impairment and confusion. Findings from the Framingham Heart Study suggest that subclinical cardiac dysfunction and noncardiac comorbidities are associated with increased incidence of heart failure, supporting the idea that heart failure is a progressive syndrome and that noncardiac factors are extremely important.

Exertional Dyspnea

The principal difference between exertional dyspnea in patients who are healthy and exertional dyspnea in patients with heart failure is the degree of activity necessary to induce the symptom. As heart failure first develops, exertional dyspnea may simply appear to be an aggravation of the breathlessness that occurs in healthy persons during activity, but as LV failure advances, the intensity of exercise resulting in breathlessness progressively declines; however, subjective exercise capacity and objective measures of LV performance at rest in patients with heart failure are not closely correlated. Exertional dyspnea, in fact, may be absent in sedentary patients.

Orthopnea

Orthopnea is an early symptom of heart failure and may be defined as dyspnea that develops in the recumbent position and is relieved with elevation of the head with pillows. As in the case of exertional dyspnea, the change in the number of pillows required is important. In the recumbent position, decreased pooling of blood in the lower extremities and abdomen occurs. Blood is displaced from the extrathoracic compartment to the thoracic compartment. The failing LV, operating on the flat portion of the Frank-Starling curve, cannot accept and pump out the extra volume of blood delivered to it without dilating. As a result, pulmonary venous and capillary pressures rise further, causing interstitial pulmonary edema, reduced pulmonary compliance, increased airway resistance, and dyspnea. Orthopnea occurs rapidly, often within a minute or two of recumbency, and develops when the patient is awake. Orthopnea may occur in any condition in which the vital capacity is low. Marked ascites, regardless of its aetiology, is an important cause of orthopnea. In advanced LV failure, orthopnea may be so severe that the patient cannot lie down and must sleep sitting up in a chair or slumped over a table.

Cough, particularly during recumbency, may be an 'orthopnea equivalent.' This nonproductive cough may be caused by pulmonary congestion and is relieved by the treatment of heart failure.

Paroxysmal Nocturnal Dyspnea

Paroxysmal nocturnal dyspnea usually occurs at night and is defined as the sudden awakening of the patient, after a couple of hours of sleep, with a feeling of severe anxiety, breathlessness, and suffocation. The patient may bolt upright in bed and gasp for breath. Bronchospasm increases ventilatory difficulty and the work of breathing and is a common complicating factor of paroxysmal nocturnal dyspnea. On chest auscultation, the bronchospasm associated with a heart failure exacerbation can be difficult to distinguish from an acute asthma exacerbation, although other clues from the cardiovascular examination should lead the examiner to the correct diagnosis. Both types of bronchospasm can be present in a single individual.

In contrast to orthopnea, which may be relieved by immediately sitting up in bed, paroxysmal nocturnal dyspnea may require 30 minutes or longer in this position for relief. Episodes may be so frightening that the patient may be afraid to resume sleeping, even after the symptoms have subsided.

Dyspnea at Rest

Dyspnea at rest in heart failure is the result of the following mechanisms (Fig. 8.4):

- Decreased pulmonary function secondary to decreased compliance and increased airway resistance
- Increased ventilatory drive secondary to hypoxemia due to increased pulmonary capillary wedge pressure (PCWP); ventilation/perfusion (V/Q) mismatching due to increased PCWP and low cardiac output; and increased carbon dioxide production

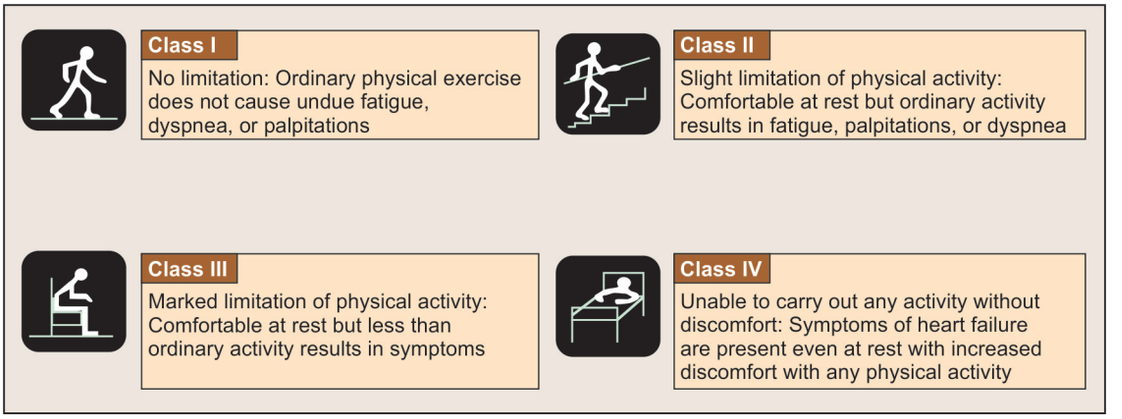

Fig. 8.4: Classification of heart status according to physical activity

- Respiratory muscle dysfunction, with decreased respiratory muscle strength, decreased endurance, and ischemia.

Pulmonary Edema

Acute pulmonary edema is defined as the sudden increase in PCWP (usually more than 25 mmHg) as a result of acute and fulminant left ventricular failure. It is a medical emergency and has a very dramatic clinical presentation. The patient appears extremely ill, poorly perfused, restless, sweaty, tachypneic, tachycardic, hypoxic, and coughing, with an increased work of breathing and using respiratory accessory muscles and with frothy sputum that on occasion is blood tinged.

Chest Pain/Pressure

Chest pain/pressure may occur as a result of either primary myocardial ischemia from coronary disease or secondary myocardial ischemia from increased filling pressure, poor cardiac output (and therefore poor coronary diastolic filling), or hypotension and hypoxemia.

Palpitations are the sensation a patient has when the heart is racing. It can be secondary to sinus tachycardia due to decompensated heart failure, or more commonly, it is due to atrial or ventricular tachyarrhythmias.

Fatigue and Weakness

Fatigue and weakness are often accompanied by a feeling of heaviness in the limbs and are generally related to poor perfusion of the skeletal muscles in patients with a lowered cardiac output. Although they are generally a constant feature of advanced heart failure, episodic fatigue and weakness are also common in earlier stages.

Nocturia and Oliguria

Nocturia may occur relatively early in the course of heart failure. Recumbency reduces the deficit in cardiac output in relation to oxygen demand, renal vasoconstriction diminishes, and urine formation increases. Nocturia may be troublesome for patients with heart failure because it may prevent them from obtaining much-needed rest. Oliguria is a late finding in heart failure and is found in patients with markedly reduced cardiac output from severely reduced LV function.

Cerebral Symptoms

The following may occur in elderly patients with advanced heart failure, particularly in those with cerebrovascular atherosclerosis:

- Confusion
- Memory impairment
- Anxiety
- Headaches
- Insomnia
- Bad dreams or nightmares
- Rarely, psychosis with disorientation, delirium, or hallucinations.

Physical Examination

Patients with mild heart failure appear to be in no distress after a few minutes of rest, but they may be obviously dyspneic during and immediately after moderate activity. Patients with LV failure may be dyspneic when lying flat without elevation of the head for more than a few minutes. Those with severe heart failure appear anxious and may exhibit signs of air hunger in this position (Figs 8.5–8.10).

Patients with recent onset of heart failure are generally well nourished, but those with chronic severe heart failure are often malnourished and sometimes even cachectic. Chronic marked elevation of systemic venous pressure may produce exophthalmos and severe tricuspid regurgitation and may lead to visible pulsation of the eyes and of the neck veins. Central cyanosis, icterus, and malar flush may be evident in patients with severe heart failure.

In mild or moderate heart failure, stroke volume is normal at rest; in severe heart failure, it is reduced, as reflected by a diminished pulse pressure and a dusky discoloration of the skin. With very severe heart failure, particularly if cardiac output has declined acutely, systolic arterial pressure may be reduced. The pulse may be weak, rapid, and thready; the proportional pulse pressure (pulse pressure/systolic pressure) may be markedly reduced. The



Fig. 8.5: A middle aged patient with dilated cardiomyopathy with class III–IV is being examined by the attending doctor



Fig. 8.7: Pitting edema in a patient with heart failure



Fig. 8.9: Ascites in a patient with congestive heart failure



Fig. 8.6: Rough, dry hair, skin, facial puffiness, edema of whole body and cardiomegaly in a middle-aged lady with hypothyroidism and heart failure



Fig. 8.8: Pitting edema over foot in a patient with heart failure

proportional pulse pressure correlates reasonably well with cardiac output. In one study, when pulse pressure was less than 25%, it usually reflected a cardiac index of less than 2.2 L/min/m^2.

Ascites occurs in patients with increased pressure in the hepatic veins and in the veins draining into the peritoneum and usually reflects long-standing systemic venous hypertension. Fever may be present in severe decompensated heart failure because of cutaneous vasoconstriction and impairment of heat loss.

Increased adrenergic activity is manifested by tachycardia, diaphoresis, pallor, peripheral cyanosis with pallor and coldness of the extremities, and obvious distention of the peripheral veins secondary to venoconstriction. Diastolic arterial pressure may be slightly elevated.

Rales heard over the lung bases are characteristic of heart failure of at least moderate severity. With acute pulmonary edema, rales are frequently accompanied by wheezing and

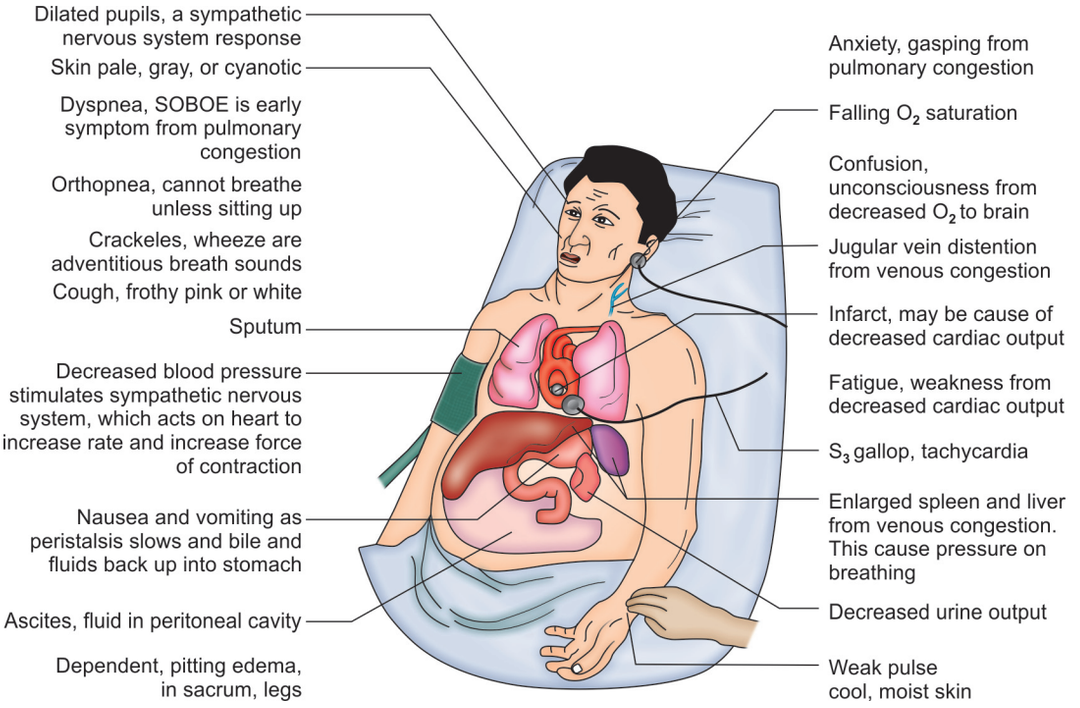

Fig. 8.10: Various signs and symptoms in heart failure

expectoration of frothy, blood-tinged sputum. The absence of rales certainly does not exclude elevation of pulmonary capillary pressure due to LV failure.

Systemic venous hypertension is manifested by jugular venous distention. Normally, jugular venous pressure declines with respiration; however, it increases in patients with heart failure, a finding known as the Kussmaul sign (also found in constrictive pericarditis). This reflects an increase in right atrial pressure and therefore right-sided heart failure.

Hepatojugular reflux is the distention of the jugular vein induced by applying manual pressure over the liver; the patient's torso should be positioned at a 45° angle. Hepatojugular reflux occurs in patients with elevated left-sided filling pressures and reflects elevated capillary wedge pressure and left-sided heart failure.

Although edema is a cardinal manifestation of heart failure, it does not correlate well with the level of systemic venous pressure. In patients with chronic LV failure and low cardiac output, extracellular fluid volume may be sufficiently expanded to cause edema in the presence of only slight elevations in systemic venous pressure. Usually, a substantial gain of extracellular fluid volume (i.e. a minimum of 5 L in adults) must occur before peripheral edema develops. Edema in the absence of dyspnea or other signs of LV or RV failure is not solely indicative of heart failure and can be observed in many other conditions, including chronic venous insufficiency, nephrotic syndrome, or other syndromes of hypoproteinemia or osmotic imbalance (Figs 8.12 and 8.13).

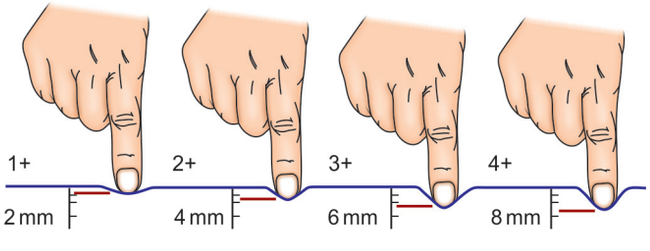

Fig. 8.11: Assessment of the severity of peripheral edema



Fig. 8.12: Still photograph showing distended elevated jugular venous pressure with prominent V-wave in a patient with heart failure

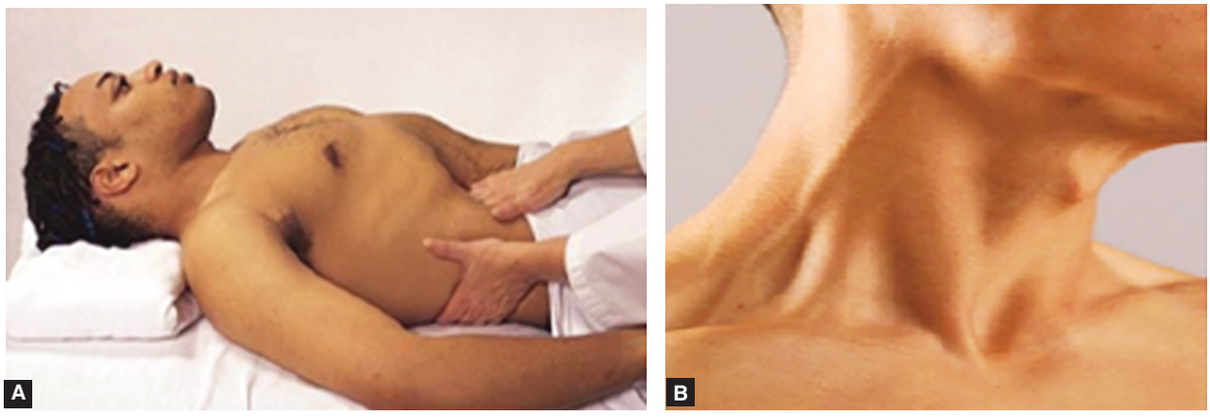

Fig. 8.13: (A) A patient with an elevated JVP after compressing over the liver for 30 seconds (hepatojugular reflux), (B) the JVP increases by 3 cm and remains there for >10 cardiac cycles

Hepatomegaly is prominent in patients with chronic right-sided heart failure, but it may occur rapidly in acute heart failure. When hepatomegaly occurs acutely, the liver is usually tender. In patients with considerable tricuspid regurgitation, a prominent systolic pulsation of the liver, attributable to an enlarged right atrial V wave, is often noted. A presystolic pulsation of the liver, attributable to an enlarged right atrial A wave, can occur in tricuspid stenosis, constrictive pericarditis, restrictive cardiomyopathy involving the right ventricle, and pulmonary hypertension (primary or secondary).

Hydrothorax is most commonly observed in patients with hypertension involving both the systemic and pulmonary circulation. It is usually bilateral, although when unilateral, it is usually confined to the right side of the chest. When hydrothorax develops, dyspnea usually intensifies because of further reductions in vital capacity.

Cardiac Findings

Protodiastolic (S3) gallop is the earliest cardiac physical finding in decompensated heart failure in the absence of severe mitral or tricuspid regurgitation or left-to-right shunts. The presence of an S3 gallop in adults is important, pathologic, and often the most apparent finding on cardiac auscultation in patients with significant heart failure.

Cardiomegaly is a nonspecific finding that nonetheless occurs in most patients with chronic heart failure. Notable exceptions include heart failure from acute MI, constrictive pericarditis, restrictive cardiomyopathy, valve or chordae tendineae rupture, or heart failure due to tachyarrhythmias or bradyarrhythmias.

Pulsus alternans (during pulse palpation, this is the alternation of 1 strong and 1 weak beat without a change in the cycle length) occurs most commonly in heart failure due to increased resistance to LV ejection, as occurs in hypertension, aortic stenosis, coronary atherosclerosis, and dilated cardiomyopathy. Pulsus alternans is usually associated with an S3 gallop, signifies advanced myocardial disease, and often disappears with treatment of heart failure.

Accentuation of P2 heart sound is a cardinal sign of increased pulmonary artery pressure; it disappears or improves after treatment of heart failure. Mitral and tricuspid regurgitation murmurs are often present in patients with decompensated heart failure because of ventricular dilatation. These murmurs often disappear or diminish when compensation is restored. Note that correlation between the intensity of the murmur of mitral regurgitation and its significance in patients with heart failure is poor. Severe mitral regurgitation may be accompanied by an unimpressively soft murmur.

Cardiac cachexia is found in long-standing heart failure, particularly of the right ventricle, because of anorexia from hepatic and intestinal congestion and sometimes because of digitalis toxicity. Occasionally, impaired intestinal absorption of fat occurs, and rarely, protein-losing enteropathy occurs. Patients with heart failure may also exhibit increased total metabolism secondary to augmentation of myocardial oxygen consumption, excessive work of breathing, low-grade fever, and elevated levels of circulating tumor necrosis factor (TNF).

Predominant Right-sided Heart Failure

Ascites, congestive hepatomegaly, and anasarca due to elevated right-sided heart pressures transmitted backward into the portal vein circulation may result in increased abdominal girth and epigastric and right upper quadrant (RUQ) abdominal pain. Other gastrointestinal symptoms, caused by congestion of the hepatic and gastrointestinal venous circulation, include anorexia, bloating, nausea, and constipation. In preterminal heart failure, inadequate bowel perfusion can cause abdominal pain, distention, and bloody stools. Distinguishing right-sided heart failure from hepatic failure is often clinically difficult.

Dyspnea, prominent in LV failure, becomes less prominent in isolated right-sided heart failure because of the absence of pulmonary congestion. On the other hand, when cardiac output becomes markedly reduced in patients with terminal right-sided heart failure (as may occur in isolated RV infarction and in the late stages of primary

pulmonary hypertension and pulmonary thromboembolic disease), severe dyspnea may occur as a consequence of the reduced cardiac output, poor perfusion of respiratory muscles, hypoxemia, and metabolic acidosis.

Heart Failure in Children

In children, manifestations of heart failure vary with age. Signs of pulmonary venous congestion in an infant generally include tachypnea, respiratory distress (retractions), grunting, and difficulty with feeding. Often, children with heart failure have diaphoresis during feedings, which is possibly related to a catecholamine surge that occurs when they are challenged with eating while in respiratory distress (Figs 8.14–8.16 and Table 8.6).



Fig. 8.14: Generalised edema of the an infant with heart failure



Fig. 8.15: Edema of various parts of the body such as face, eyelids, feet and scrotum



Fig. 8.16: Treatment of heart failure with administration of intranasal oxygen in an older child with ASD septum primum defect

Table 8.6: Leading causes of CHF in relation to age

Birth to first week

Aoratic atresia
Transposition of great vessels
Coarctation of aorta

1 week to 1 month

Coarctation of aorta
TGA
Endocardial fibroelastosis

1 month to 2 months

TGA
Endocardial fibroelastosis

2 months to 3 months

Coarctation of aorta
Total anomalous pulmonary venous return
VSD

3 months to 6 months

VSD

6 months to 12 months

VSD
ASD (Ostium primum)

CHF is rarely present in utero with exception of paroxysmal surpraventricular tachycardia and anemia due to Rh incompatibility. It is often interpreted as intrauterine asphyxia and mother is subjected to cesarean section.

After first year of life, CHF is much less frequent and it is due to variety of causes

- Arrhythmias
- Viral myocarditis
- Acute rheumatic carditis
- Cardiomyopathy

Right-sided venous congestion is characterized by hepatosplenomegaly and, less frequently, with edema or ascites. Jugular venous distention is not a reliable indicator of systemic venous congestion in infants, because the jugular veins are difficult to observe. Also, the distance from the right atrium to the angle of the jaw may be no more than 8–10 cm, even when the individual is sitting upright. Uncompensated heart failure in an infant primarily manifests as a failure to thrive. In severe cases, failure to thrive may be followed by signs of renal and hepatic failure. In older children, left-sided venous congestion causes tachypnea, respiratory distress, and wheezing (cardiac asthma). Right-sided congestion may result in hepatosplenomegaly, jugular venous distention, edema, ascites, and/or pleural effusions. Uncompensated heart failure in older children may cause fatigue or lower-than-usual energy levels. Patients may complain of cool extremities, exercise intolerance, dizziness, or syncope cesarean section.

Heart Failure Criteria, Classification, and Staging

Framingham system for diagnosis of heart failure: In the Framingham system, the diagnosis of heart failure requires that either two major criteria or 1 major and 2 minor criteria be present concurrently, as minor criteria are accepted only if they cannot be attributed to another medical condition.

NYHA Classification of Functional Heart Failure

The New York Heart Association (NYHA) functional classification of heart failure is based on the patient's symptom severity and the amount of exertion that is needed to provoke their symptoms.

ACC/AHA Stages of Heart Failure

The American College of Cardiology/American Heart Association (ACC/AHA) developed a classification that described the development and progression of heart failure and that 'recognizes that there are established risk factors and structural prerequisites for the development of HF and that therapeutic interventions introduced even before the appearance of LV dysfunction or symptoms can reduce the population morbidity and mortality of HF.'

ACC/AHA Staging

Stage A

ACC/AHA stage A patients are at high risk for heart failure but do not have structural heart disease or symptoms of heart failure. Thus, management in these cases focuses on prevention, through reduction of risk factors. Measures include the following:

- Treat hypertension
- Encourage smoking cessation
- Treat lipid disorders
- Encourage regular exercise
- Discourage alcohol intake and illicit drug use
- Patients who have a family history of dilated cardiomyopathy should be screened with a comprehensive history and physical examination together with echocardiography and transthoracic echocardiography every 2–5 years.

Stage B

ACC/AHA stage B patients are asymptomatic, with LV dysfunction from previous MI, LV remodeling from LV hypertrophy, and asymptomatic valvular dysfunction, which includes patients with New York Heart Association (NYHA) class I heart failure. In addition to the heart failure education and aggressive risk factor modification used for stage A, treatment with an ACEI/ARB and/or beta-blockade is indicated.

- Evaluation for coronary revascularization either percutaneously or surgically, as well as correction of valvular abnormalities, may be indicated. Treatment with an ICD for primary prevention of sudden death in patients with an LVEF of less than 30% that is more than 40 days post-MI is reasonable if expected survival is more than 1 year.
- There is less evidence for implantation of an ICD in patients with nonischemic cardiomyopathy, an LVEF less than 30%, and no heart failure symptoms. There is no evidence for use of digoxin in these populations. Aldosterone receptor blockade with eplerenone is indicated for post-MI LV dysfunction.

Stage C

ACC/AHA stage C patients have structural heart disease and current or previous symptoms of heart failure; ACC/AHA stage C corresponds with NYHA class II and III heart failure. The preventive measures used for stage A disease are indicated, as is dietary sodium restriction.

- Drugs routinely used in these patients include ACEI/ARBs, beta-blockers, and loop diuretics for fluid retention. For selected patients, therapeutic measures include aldosterone receptor blockers, hydralazine and nitrates in combination, and cardiac resynchronization with or without an ICD (see electrophysiologic intervention).
- A meta-analysis performed by Badve et al. suggested that the survival benefit of treatment with beta-blockers extends to patients with chronic kidney disease and systolic heart failure (risk ratio 0.72).

Stage D

ACC/AHA stage D patients have refractory heart failure (NYHA class IV) that requires specialized interventions. Treatment includes all the measures used in stages A, B, and C. Treatment considerations include heart transplantation or placement of an LV assist device in eligible patients; pulmonary catheterization; and options for end-of-life care. For palliation of symptoms, continuous intravenous infusion of a positive inotrope may be considered.

Differential Diagnoses

- Acute renal failure
- Acute respiratory distress syndrome

Table 8.7: Prevalence of signs and symptoms in systolic and and diastolic heart failure

	Diastolic HF (LVEF >50%)	Systolic HF (LVEF <50%)
Symptoms		
Dyspnea on exertion	85%	96%
Paroxysmal nocturnal dyspnea	55%	50%
Orthopnea	60%	73%
Physical examination		
Jugular venous distension	35%	46%
Rales	72%	70%
Displaced apical impulse	50%	60%
S3	45%	65%
S4	45%	66%
Hepatomegaly	15%	16%
Edema	30%	40%
Chest film		
Cardiomegaly	90%	96%
Pulmonary venous hypertension	75%	80%

Table 8.8: Abnormalities resulting in systolic dysfunction

Myocyte compartment
• Myocyte loss (necrosis, apoptosis and aging)
• Abnonnal force transduction (e.g. dystrophin mutations)
• Abnonnal force generation (calcium release, substrate deficiency)
• Abnonnal relaxation (abnormal calcium reuptake)
• Excessive myocyte hypertrophy
Myocardial load
• Volume overload (mitral or aortic regurgitation, renal or hepatic failure) Pressure overload (hypertension, increased arterial stiffness)
Heart rate and conduction
• Excessive tachycardia (weeks)
• Discoordinate contraction (right ventricular pacing)
Extracellular matrix compartment
• Fibrosis
• Altered metabolism (cardiofibroblast function, protein Synthesis and degradation, paracrine/autocrine signaling)
Cardiac structure
• Abnonnal myocardial fiber "wrapping" or alignment
• Focal infarction or aneurysm.
• Advanced remodeling (increased sphericity)

- Chronic obstructive pulmonary disease
- Cirrhosis
- Emphysema
- Goodpasture syndrome
- Myocardial infarction
- Nephrotic syndrome
- Pneumonia, bacterial
- Pneumonia, community-acquired
- Pneumonia, viral
- Pneumothorax
- Pulmonary edema, cardiogenic
- Pulmonary edema, neurogenic
- Pulmonary embolism
- Pulmonary fibrosis, idiopathic
- Pulmonary fibrosis, interstitial (nonidiopathic)
- Respiratory failure
- Venous insufficiency

ROUTINE LABORATORY TESTS

Laboratory studies should include a complete blood count (CBC), serum electrolytes (including calcium and magnesium), and renal and liver function studies. Other tests may be indicated in specific patients. The CBC aids in the assessment of severe anemia, which may cause or aggravate heart failure. Leukocytosis may signal underlying infection. Otherwise, CBCs are usually of little diagnostic help.

Serum electrolyte values are generally within reference ranges in patients with mild to moderate heart failure before treatment. In cases of severe heart failure, however, prolonged, rigid sodium restriction, coupled with intensive diuretic therapy and the inability to excrete water, may lead to dilutional hyponatremia, which occurs because of a substantial expansion of extracellular and intravascular fluid volume and a normal or increased level of total body sodium.

Potassium levels are usually within reference ranges, although the prolonged administration of diuretics may result in hypokalemia. Hyperkalemia may occur in patients with severe heart failure who show marked reductions in glomerular filtration rate (GFR) and inadequate delivery of sodium to the distal tubular sodium-potassium exchange sites of the kidney, particularly if they are receiving potassium-sparing diuretics and/or angiotensin-converting enzyme inhibitors (ACEIs).

Renal Function Tests

Blood urea nitrogen (BUN) and creatinine levels can be within reference ranges in patients with mild to moderate heart failure and normal renal function, although BUN levels and BUN/creatinine ratios may be elevated.

Patients with severe heart failure, particularly those on large doses of diuretics for long periods, may have elevated BUN and creatinine levels indicative of renal insufficiency because of chronic reductions of renal blood flow from reduced cardiac output. Diuresing this group of patients is complex. In some individuals, diuretics will improve renal congestion and renal function, whereas in others, over aggressive diuresis may aggravate renal insufficiency due to volume depletion.

Liver Function Tests

Congestive hepatomegaly and cardiac cirrhosis are often associated with impaired hepatic function, which is characterized by abnormal values of aspartate aminotransferase (AST), alanine aminotransferase (ALT), lactic

dehydrogenase (LDH), and other liver enzymes. Hyperbilirubinemia secondary to an increase in the directly and indirectly reacting bilirubin is common. In severe cases of acute RV or LV failure, frank jaundice may occur.

Acute hepatic venous congestion can result in severe jaundice, with a bilirubin level as high as 15–20 mg/dL, elevation of AST to more than 10 times the upper reference range limit, elevation of the serum alkaline phosphatase level, and prolongation of the prothrombin time. The clinical and laboratory pictures may resemble viral hepatitis, but the impairment of hepatic function is rapidly resolved by successful treatment of heart failure. In patients with long-standing heart failure, albumin synthesis may be impaired, leading to hypoalbuminemia and intensifying the accumulation of fluid. Fulminant hepatic failure is an uncommon, late, and sometimes terminal complication of cardiac cirrhosis.

Natriuretic Peptides

Clinical findings and routine diagnostic tests are not always sufficient to diagnose heart failure. In such ambiguous cases, rapid measurement of B-type natriuretic peptide (BNP) or N-terminal proBNP (NT-proBNP) levels can aid clinicians in differentiating between cardiac and noncardiac causes of dyspnea. That is, BNP is mostly limited to the differentiation of heart failure versus other causes of dyspnea in patients with an atypical presentation (Table 8.9).

BNP is a 32-amino-acid polypeptide containing a 17-amino-acid ring structure common to all natriuretic peptides. The major source of plasma BNP is the cardiac ventricles, and the release of BNP appears to be in direct proportion to ventricular volume and pressure overload. BNP is an independent predictor of high LV end-diastolic pressure and is more useful than atrial natriuretic peptide (ANP) or norepinephrine levels for assessing mortality risk in patients with heart failure. Although BNP has been determined to be the strongest predictor of systolic versus nonsystolic heart failure (followed by oxygen saturation, history of myocardial infarction, and heart rate), BNP does not reliably differentiate between heart failure with preserved ejection fraction and heart failure with reduced ejection fraction. Increased NT-proBNP was found to be the strongest independent predictor of a final diagnosis of acute heart failure. Measurement of B-type natriuretic peptide (BNP) and its precursor, N-terminal proBNP (NT-proBNP), in the urgent care setting can be used to establish the diagnosis of heart failure when the clinical presentation is ambiguous or when confounding comorbidities are present BNP and NT-proBNP assays have different cutoff values for ruling in and ruling out heart failure. The American College of Cardiology/American Heart Association (ACC/AHA),the Heart Failure Society of America (HFSA), and the European Society of Cardiology (ESC) recommend measuring BNP or NT-proBNP in the workup of heart failure when the diagnosis is unclear. The HFSA recommends this test in all cases of suspected heart failure, particularly in ambiguous cases.

BNP levels correlate closely with the NYHA classification of heart failure.BNP levels greater than 100 pg/ml have a specificity greater than 95% and a sensitivity greater than 98% when comparing patients without heart failure to all patients with heart failure. Even BNP levels greater than 80 pg/ml have a specificity greater than 95% and a sensitivity greater than 98% in the diagnosis of heart failure. BNP and NT-proBNP levels are higher in older patients, women, and patients with renal dysfunction or sepsis. Atrial fibrillation has also been associated with increased BNP levels in the absence of acute heart failure. However, BNP levels may be disproportionately lower in patients who are obese due to fat metabolism or who have hypothyroidism or advanced end-stage heart failure (the latter due to increased fibrosis). NT-proBNP plasma levels are also lower in obese heart failure patients relative to nonobese patients with heart failure, regardless of whether the aetiology is ischemic or nonischaemic.

However, NT-proBNP may be elevated in severely obese patients (BMI >40 kg/m^2) due to an increased cardiac

Table 8.9: Evidence-based BNP and NT-proBNP cutoff values for diagnosing HF

		BNP, pg/ml		NT-proBNP, pg/ml	
Criterion		**HF unlikely (LR-negative)**	**HF unlikely (LR-positive)**	**HF unlikely (LR-negative)**	**HF unlikely (LR-positive)**
Age (year)	>17	<100 (0.13)*	>500 (8.1)*	–	–
	>21	–	–	<300 (0.2)†	–
	21–50	–	–	–	>450 (14)†
	50–75	–	–	–	>900 (5.0)†
	>75	–	–	–	>1800 (3.1)†
Estimated GFR <60 ml/min		<200 (0.13)	>500 (9.3)	–	–

BNP=B-type natriuretic peptide; GRF=glomerular filtration rate; HF=heart failure; LR=likelihood ratio; NPV=negative predictive value; NT-pro-BNP=N-terminal proNBP; PPV=positive predictive value; –=not specifically defined.

*Derived from breathing not properly data (1586 emergency department [ED] patients, prevalence of HF=47%. †Derived from PRIDE data (1256 ED patients, prevalence of HF=57%).

burden in these individuals. NT-proBNP may be a better marker for detecting cardiac dysfunction than BNP, because its chemical stability is better in circulating blood than that of BNP, and it is a sensitive marker of cardiac function even in early cardiac decompensation. BNP measurement not indicated with nesiritide therapy.

Nesiritide is a synthetic BNP analogue; therefore, the measurement of BNP is not indicated in patients who are receiving nesiritide. If BNP is used as a diagnostic marker to rule in heart failure, the level must be determined before nesiritide therapy is started. In a study by Miller et al. levels of NT-proBNP and BNP decreased in patients with advanced heart failure after therapy with nesiritide, but the majority of the patients did not have biochemically significant decreases in these markers even with a clinical response. The investigators were unable to give a definitive reason for their results, and they indicated that nesiritide therapy should not be guided by the use of levels of both markers. Fitzgerald et al. also found decreased levels of both natriuretic peptides following nesiritide therapy in patients with decompensated heart failure.

GENETIC TESTING

Cardiomyopathy phenotypes that have known genetic cause(s) include hypertrophic (HCM), dilated (DCM), restrictive (RCM), arrhythmogenic right ventricular dysplasia/cardiomyopathy (ARVD/C), and left ventricular noncompaction (LVNC). Because most cases of cardiomyopathy are treatable which is not the case in many genetic diseases and screening for genetic risk of cardiomyopathy before the onset of disease can guide the recommendations for early detection of disease and therapy, it is recommended that consideration be given for patients with cardiomyopathy to be referred to centers with expertise in these matters and in family-based management. These specialized centers will have a better understanding of the complexities involved in genetic evaluation, testing, and counseling of patients with cardiomyopathy.

To establish specific gene testing and laboratories offering tests, please visit www.genetests.org for further information and larger e–views. Genetic testing has the highest yield in three types of cardiomyopathy—DCM, HCM, and autosomal dominant ARVD/C. The diagnosis must be established using the specific criteria for each type of cardiomyopathy, as the genetic testing is different for each type.

ASSESSMENT OF HYPOXEMIA

Arterial and Venous Blood Gases

Although arterial blood gas (ABG) measurement is more accurate than pulse oximetry for measuring oxygen saturation, it is unclear if ABG results add any clinical utility to pulse oximetry. In the setting of acute heart failure, ABG measurement is rarely performed. Indications include severe respiratory distress, documented hypoxemia by pulse oximetry not responsive to supplemental oxygen, and evidence of acidosis by serum chemistry or elevated lactate level (Table 8.10).

In general, heart failure patients who do not have comorbid lung disease do not manifest hypoxemia except in severe acute decompensation. Patients with severe heart failure may have signs and symptoms ranging from severe hypoxemia, or even hypoxia, along with hypercapnia, to decreased vital capacity and poor ventilation.

ABG measurement helps assess the presence of hypercapnia, a potential early marker for impending respiratory failure. Hypoxemia and hypocapnia occur in stages 1 and 2 of pulmonary edema because of V/Q mismatch. In stage 3 of pulmonary edema, right-to-left intrapulmonary shunt develops secondary to alveolar flooding and further contributes to hypoxemia. In more severe cases, hypercapnia and respiratory acidosis are usually observed. The decision regarding intubation and the use of mechanical ventilation is frequently based on many clinical parameters, including oxygenation, ventilation, and mental status. ABG values in isolation are rarely useful, but they may add to the entire clinical picture.

Mixed venous oxygen saturation (obtained from the main pulmonary artery in the absence of an intracardiac shunt) is a good marker of the blood circulation time and therefore of cardiac output and cardiac performance. Patients who have advanced heart failure have low cardiac output and slower circulation time, which translate into an increased oxygen extraction by the tissue and therefore lower saturation of oxygen (<60% saturation).

Pulse Oximetry

Pulse oximetry is highly accurate at assessing the presence of hypoxemia and, therefore, the severity of acute heart failure presentations. Patients with mild to moderate acute heart failure may show modest reductions in oxygen saturation, whereas patients with severe heart failure may have severe oxygen desaturation, even at rest. Pulse oximetry is also useful for monitoring the patient's response to supplemental oxygen and other therapies.

Patients with mild to moderate heart failure may have normal oxygen saturations at rest, but they may exhibit marked reductions in oxygen saturations during physical exertion or recumbency. In general, arterial desaturation during exercise is not expected in heart failure and suggests the presence of comorbid lung disease. The use of continuous oxygen may be needed until compensation returns oxygen saturation to normal during exertion and recumbency or on a permanent basis if oxygen desaturation during exertion and/or recumbency exists during compensated severe chronic heart failure.

Chest Radiography

Chest radiographs are used in cases of heart failure to assess heart size, pulmonary congestion, pulmonary or thoracic causes of dyspnea, and the proper positioning of any implanted cardiac devices. Posterior-anterior and lateral views are recommended (Figs 8.17–8.19).

Although up to 50% of patients with heart failure and documented elevation of PCWP do not manifest typical radiographic findings of pulmonary congestion, the

Table 8.10: Recommendations for the evaluation of patients with heart failure

Class I
• Thorough history and physical examination
• Initial and ongoing assessment of ability to perform routine and desired activities of daily living. Initial and ongoing assessment of volume status
• Initial measurement of complete blood count, urinalysis, serum electrolytes, blood urea nitrogen, serum creatinine, blood glucose, liver function tests, thyroid-stimulating hormone
• Serial monitoring of serum electrolytes and renal function
• lnitial l2-lead EKG and chest radiograph
• Initial 2-dimensional echocardiography with Doppler or radionuclide ventriculography to assess left ventricular systolic function
• Cardiac catheterization with coronary angiography in patients with angina who are candidates for revascularization
Class IIa
• Cardiac catheterization with coronary angiography in patients who are candidates for revascularization with chest pain who have not had evaluation of their coronary anatomy known of suspected CAD but without angina
• Noninvasive assessment of ischemia and viability in patients with known CAD without angina
• Maximal exercise testing with measurement of respiratory gas exchange to determine cause of exercise limitation candidacy for cardiac transplantation
• Echo cardiography in asymptomatic first-degree relatives of patients with IDCM
• Repeat measures of ejection fraction in patients with change in clinical status
• Screening for hemochromatosis
• Measurement of ANA, RF, urinary VMA and metanephrines in selected patients
Class IIb
• Noninvasive imaging to define likelihood of CAD
• Maximal exercise testing to prescribe exercise program
• Endomyocardial biopsy in patients with known or suspected inflammatory or infiltrative disorder HIV testing
Class III Endomyocardial biopsy in routine evaluation
• Routine Holter-monitoring or signal-averaged electrocardiography
• Repeat coronary angiography or noninvasive testing in patients in whom CAD has been excluded previously as the cause of left ventricular dysfunction
• Routine measurement of norepinephrine

CAD=coronary artery disease; IDCM=idiopathic dilated cardiomyopathy; ANA=antinuclear antibody; RF=rheumatoid factor; VMA= vanellylmandelic acid; HIV=human im munodeficiency virus.



Fig. 8.17: Chest radiograph in PA view shows an enlarged cardiac silhouette and edema at the lung bases, signs of acute heart failure

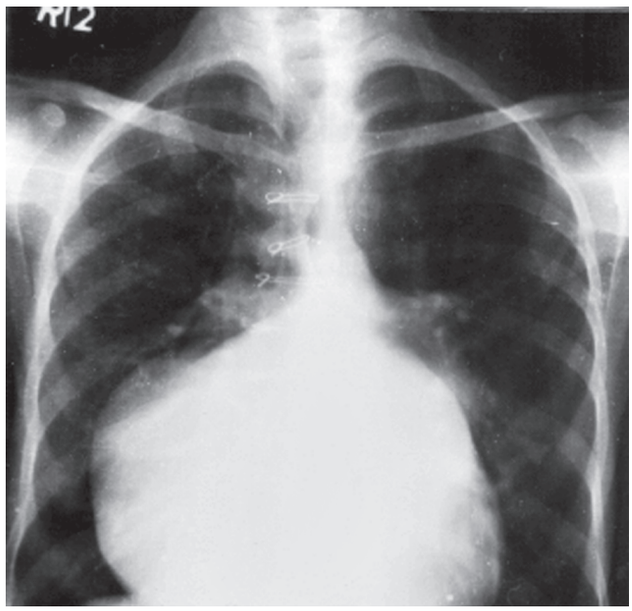

Fig. 8.18: Chest X-ray PA view showing globular heart in in patient with biventricular failure

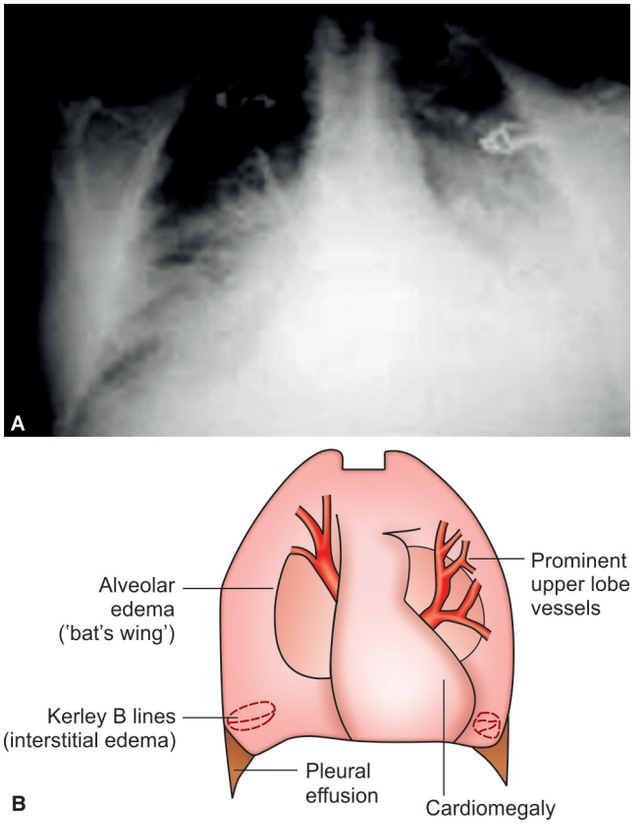

Fig. 8.19: (A) Classic signs of acute heart failure that can be seen on a chest X-ray of left ventricular failure. (B) Pleural effusion on a chest X-ray

following two principal features of chest radiographs are useful in the evaluation of patients with heart failure: (1) the size and shape of the cardiac silhouette and (2) edema at the lung bases.

Electrocardiography

A screening electrocardiogram (ECG) is reasonable in patients with symptoms suggestive of heart failure. The presence of left atrial enlargement and LVH is sensitive (although nonspecific) for chronic LV dysfunction. It is unlikely that an ECG would be completely normal in the presence of heart failure; therefore, an alternative diagnosis should be sought in such cases. Electrocardiography may suggest an acute tachyarrhythmia or bradyarrhythmia as the cause of heart failure. It may also aid in the diagnosis of acute myocardial ischemia or infarction as the cause of heart failure or may suggest the likelihood of prior MI or the presence of coronary artery disease as the cause of heart failure (Figs 8.20–8.28).

Echocardiography

Two-dimensional (2-D) echocardiography is recommended in the initial evaluation of patients with known or suspected heart failure. Ventricular function may be evaluated, and primary and secondary valvular abnormalities may be accurately assessed (Figs 8.29–8.31).

Doppler echocardiography, along with 2-D echocardiography, may play a valuable role in determining diastolic function and in establishing the diagnosis of diastolic heart failure. Approximately 30–40% of patients presenting with

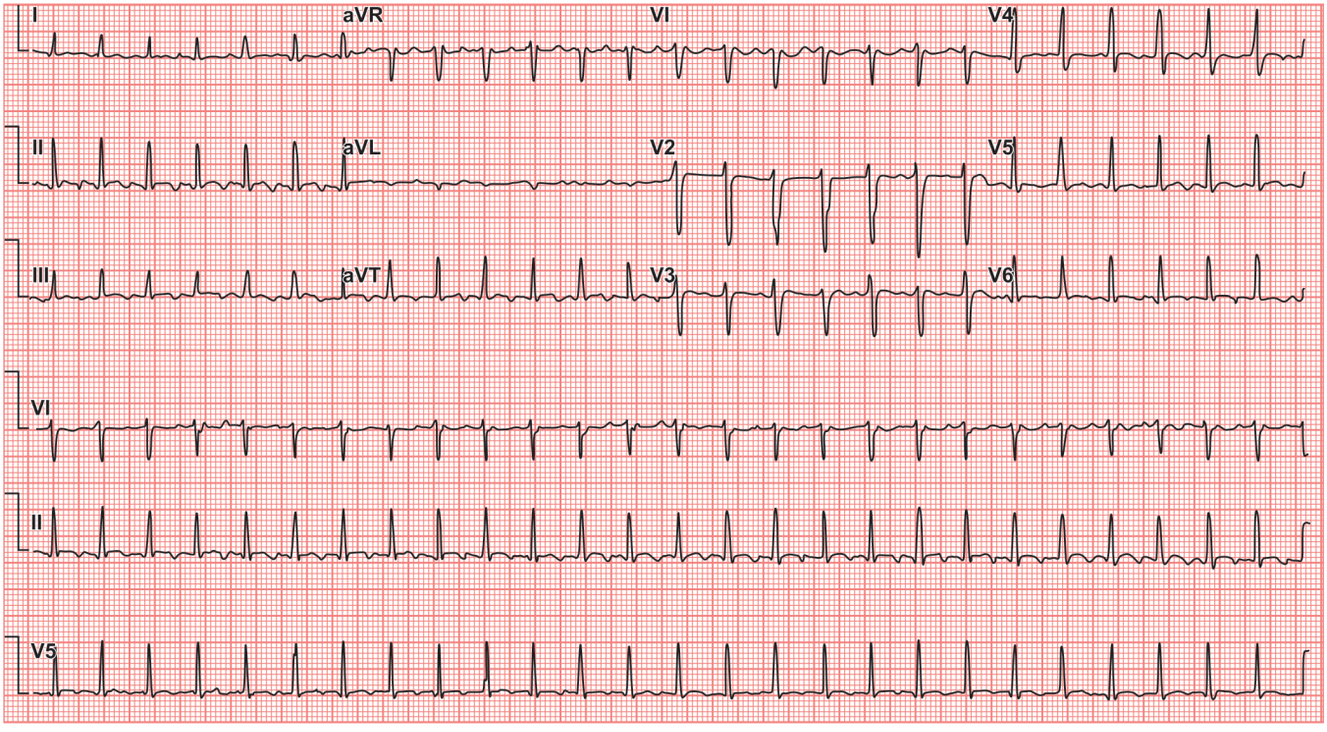

Fig. 8.20: ECG record of a patient with history of coronary artery disease, congestive heart failure with ejection fraction of 35%, presents to the emergency room with worsening shortness of breath and palpitations. ECG shows T-wave inversion in leads II, III, aVF, V4–V6

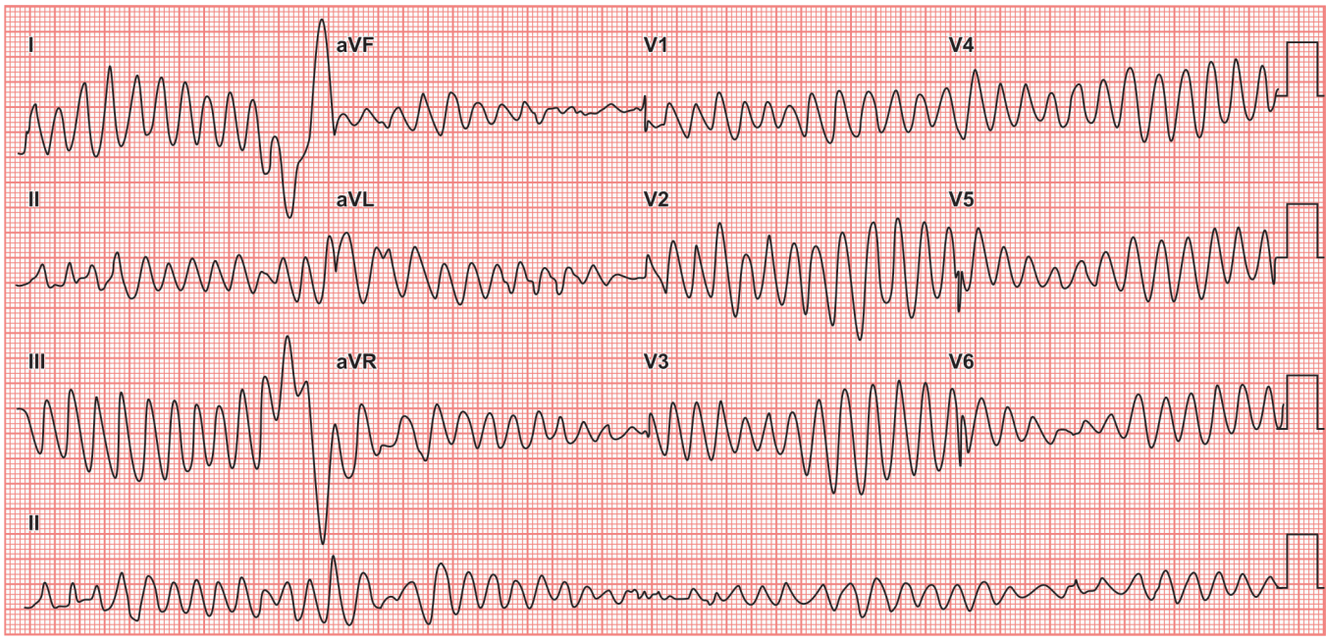

Fig. 8.21: ECG showing ventricular tachycardia in a case of heart failure

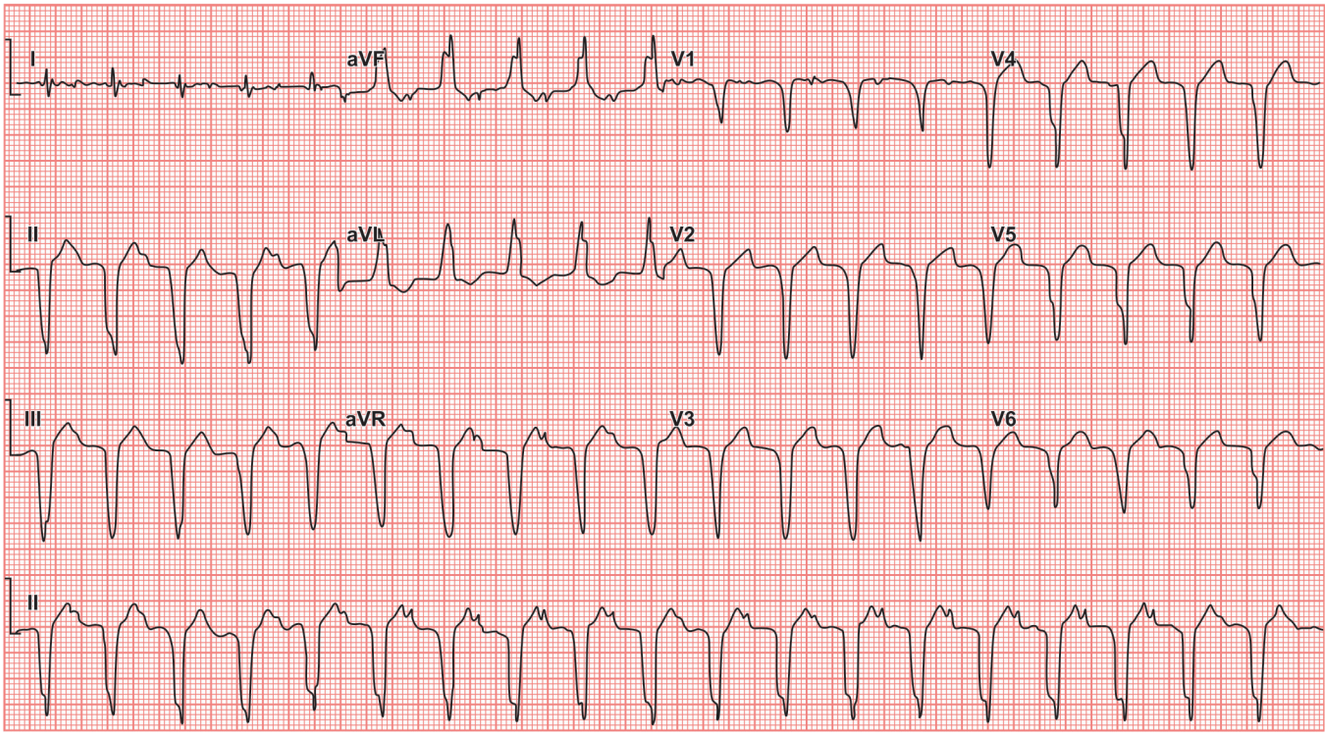

Fig. 8.22: Electrocardiogram (ECG) demonstrates a tachycardia with a 1:1 atrial-ventricular relationship in a 52-year-old male with recent-onset congestive heart failure and syncope

heart failure have normal systolic function but abnormal diastolic relaxation. The primary finding to differentiate diastolic heart failure is the presence of a normal ejection fraction; however, note that findings of diastolic dysfunction are common in the elderly and may not be associated with clinical heart failure. Because the therapy for this condition is distinctly different from that for systolic dysfunction, establishing the appropriate aetiology and diagnosis is essential.

Doppler and 2-D echocardiography may also be used to determine both systolic and diastolic LV performance, cardiac output (ejection fraction), and pulmonary artery and ventricular filling pressures. In addition, echocardiography may be used to identify clinically important valvular disease.

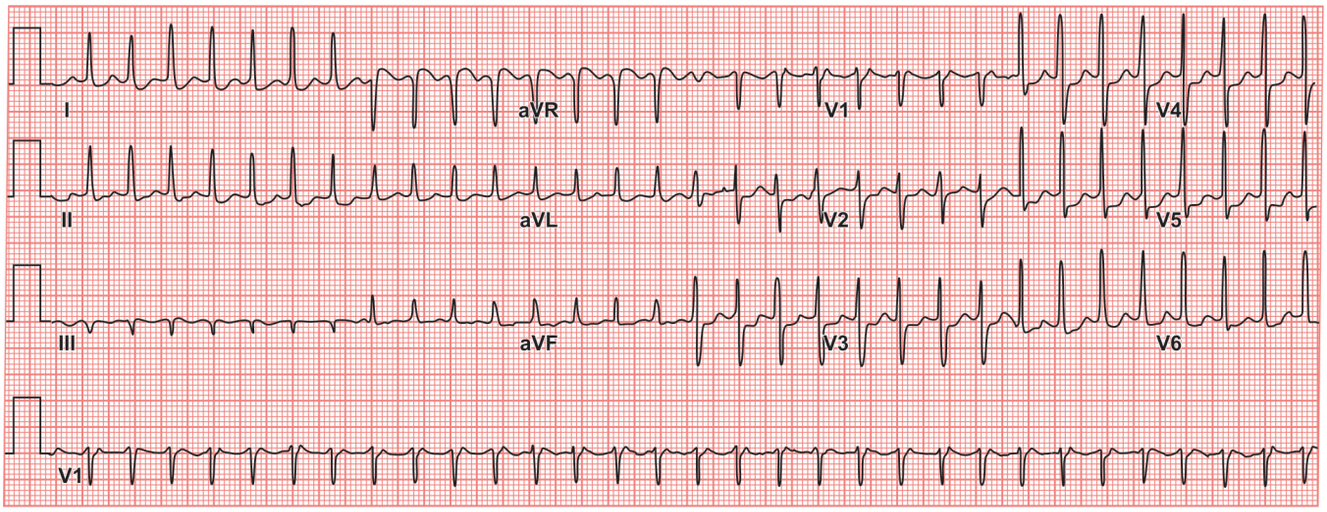

Fig. 8.23: ECG showing hemodynamically stable supraventricular tachycardia in a patient with heart failure

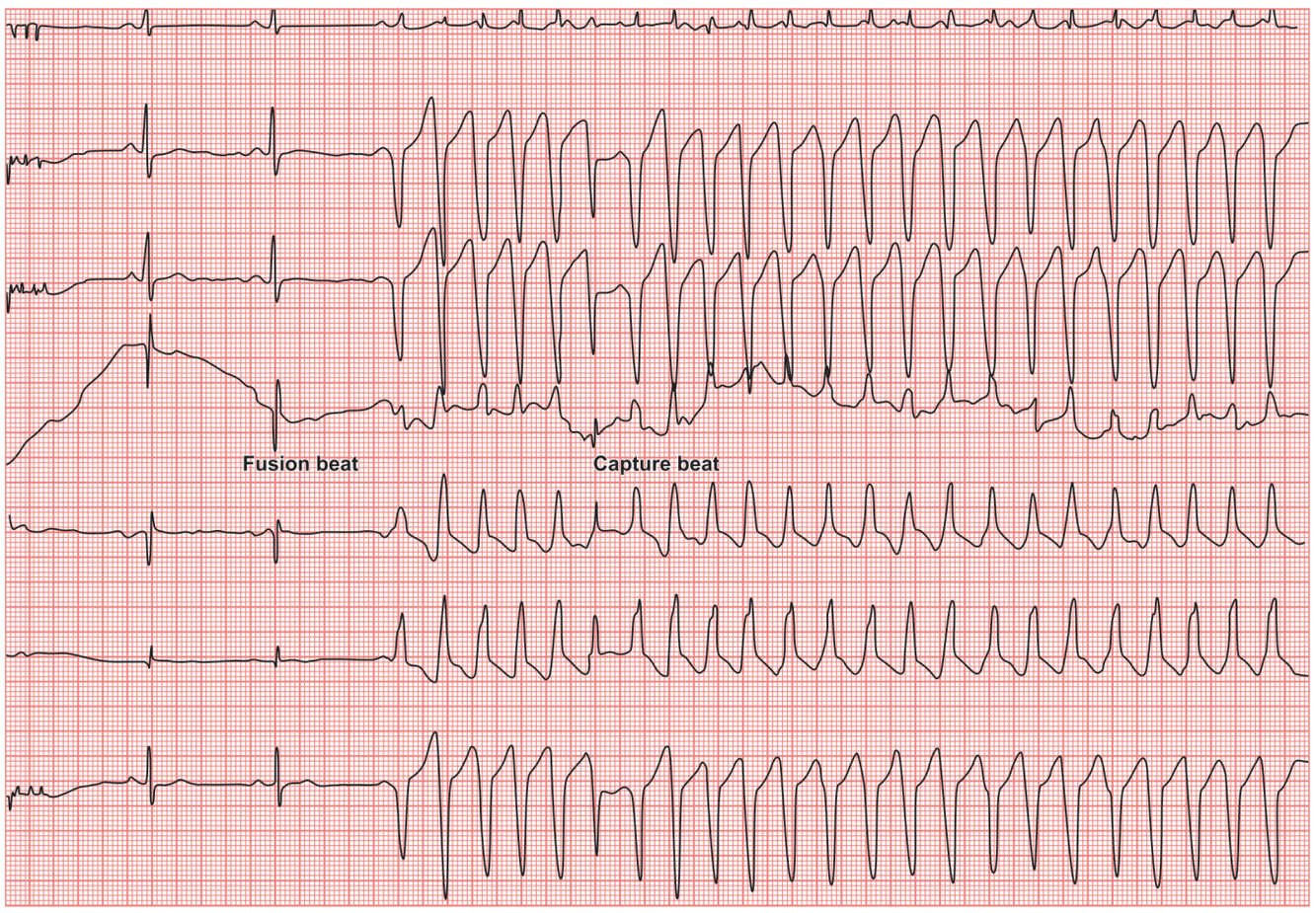

Fig. 8.24: ECG showing morphology of ventricular tachycardia (VT) in a patient with heart failure

Transesophageal Echocardiography

Transesophageal echocardiography is particularly useful in patients who are on mechanical ventilation or are morbidly obese and in patients whose transthoracic echocardiogram is suboptimal in its imaging. It is an easy and safe alternative to conventional transthoracic echocardiography and provides better imaging quality (Fig. 8.32).

Stress Echocardiography

Stress echocardiography, also known as dobutamine or exercise echocardiography, has several uses; however, in

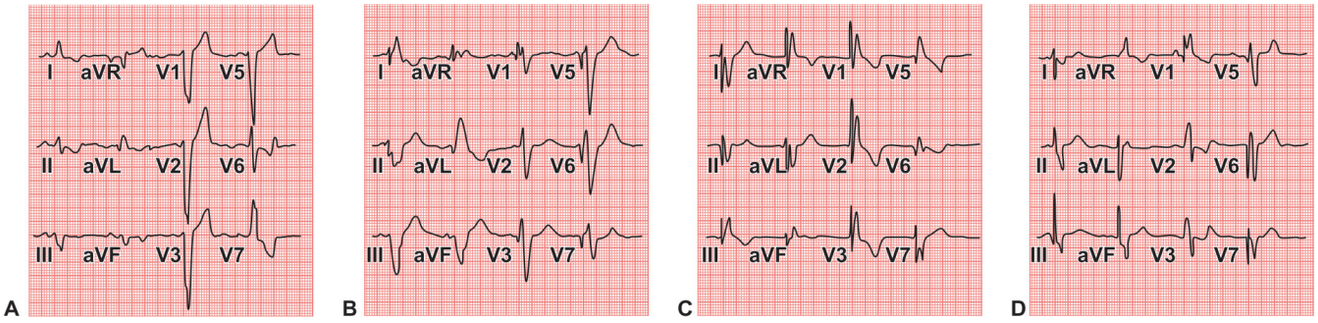

Fig. 8.25: Sample ECGs (average beat) during sinus rhythm, right ventricular pacing, left ventricular pacing, and biventricular pacing. (A) Subject in sinus rhythm. (B) Subject during right ventricular pacing. (C) Subject during left ventricular pacing. (D) Subject during biventricular pacing

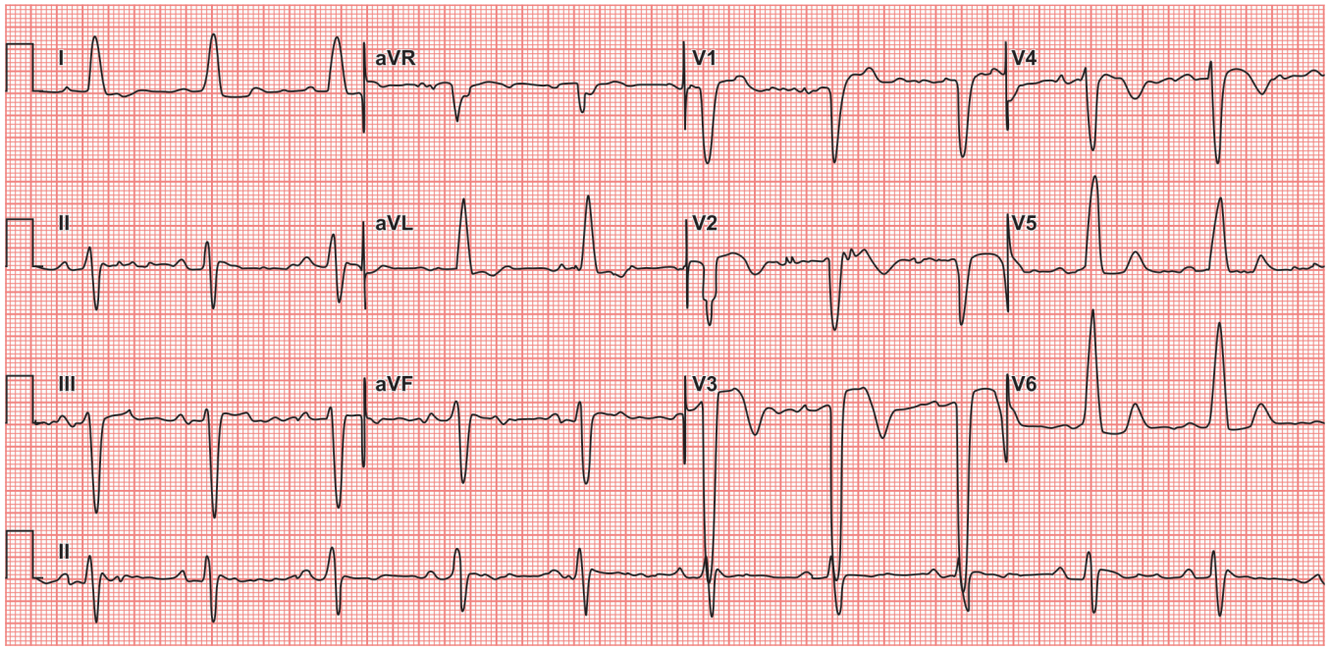

Fig. 8.26: The rhythm on this electrocardiogram (ECG) is sinus with borderline PR prolongation. There is evidence of an acute/evolving anterior ischemia/myocardial infarction (MI) superimposed on the left bundle branch block-like (LBBB) pattern in 75 years old man with heart failure

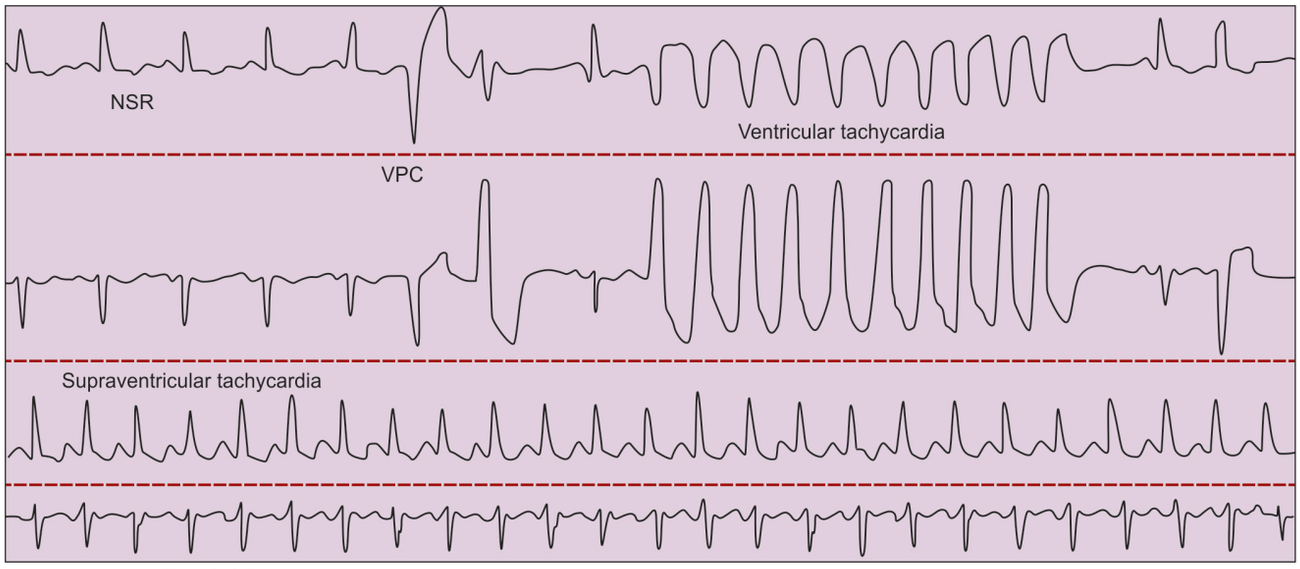

Fig. 8.27: Holter graph showing ventricular tachycardia in patient with ischemic heart failure

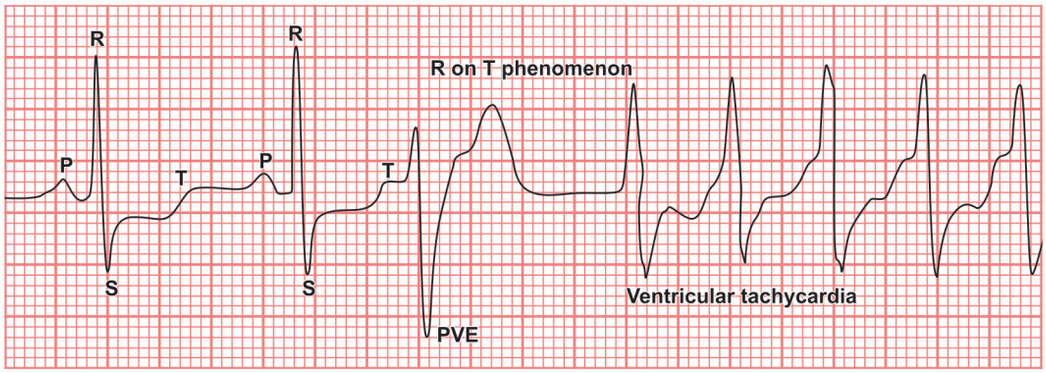

Fig. 8.28: ECG recorded by telemetry on a patient. The major time lines are 0.2 of a second. Note that the tachycardia is initiated with a premature ventricular beat with the retrograde P-wave sitting on the up sloping section of the T-wave. There is a long P-R interval to the next QRS with is the beginning of the tachycardia at a rate of about 160/min. With this tachycardia the patient had chest pain and a blood pressure of 70 mm systolic. A coronary angiogram found severe triple vessel coronary disease

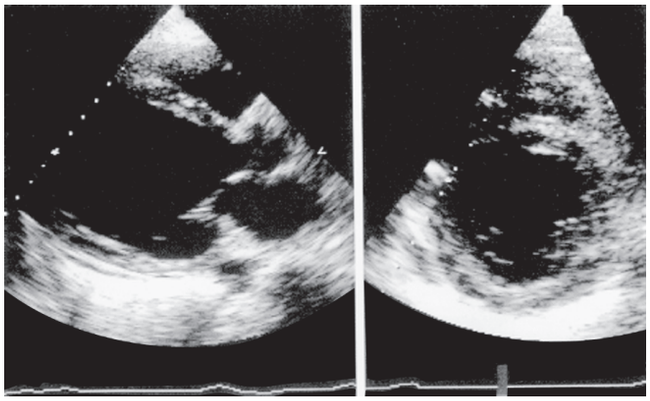

Fig. 8.29: Long axis and short axis 2D views of LV showing posterior wall infarction and hypokinetic anterior wall with cavity dilatation and poor LVEF =<15% in patient with breathlessness and effort angia

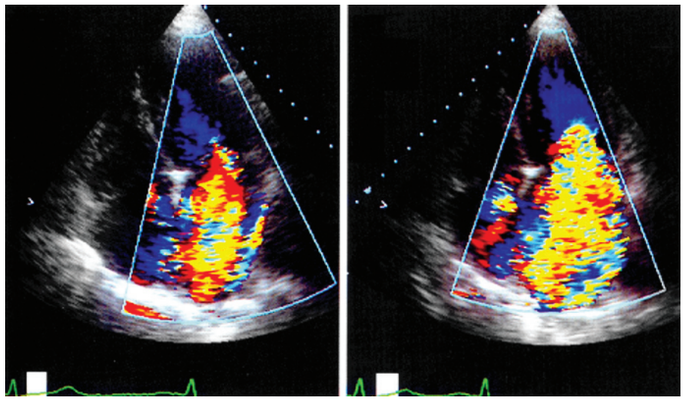

Fig. 8.30: Apical 4C view from a patient with ischemic cardiomyopathy and significant functional mitral regurgitation at rest (left). Note the increase in MR severity with stress, indicating development of severe ischemic dysfunction with stress

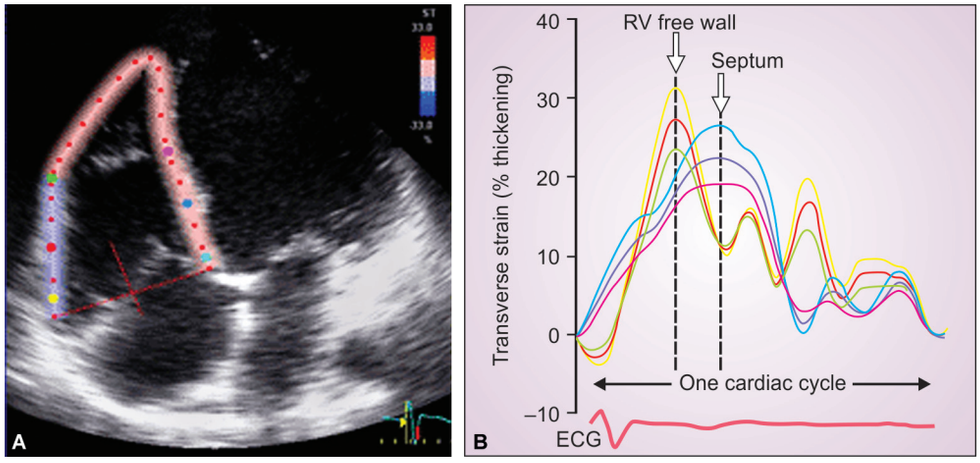

Fig. 8.31: RV failure. (A) Speckle tracking of 2D-echocardgraphic image of the right ventricle. (B) Strain vs time plotted for various regions of the RV. It shows delay in time to peak strain in the septum compared to the RV free wall

heart failure, this technique is used mainly to assess coronary artery disease (CAD). This imaging modality may be used to detect ventricular dysfunction caused by ischemia, evaluate myocardial viability in the presence of marked hypokinesis or akinesis, identify myocardial stunning and hibernation, and relate heart failure

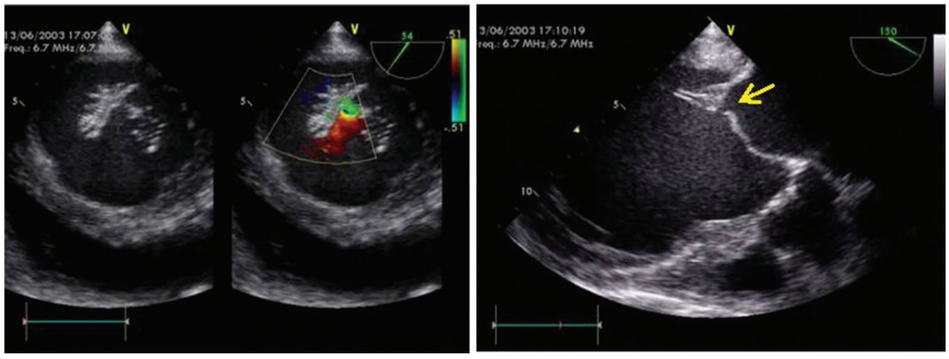

Fig. 8.32: Ischemic dilated cardiomyopathy with chronic mitral regurgitation due to important dilatation of the LV cavity, annular dilatation and loss of leaflet coaptation (arrow). TEE transgastric short and long axis views. Notice also the systolic restriction of the posterior leaflet (right picture)

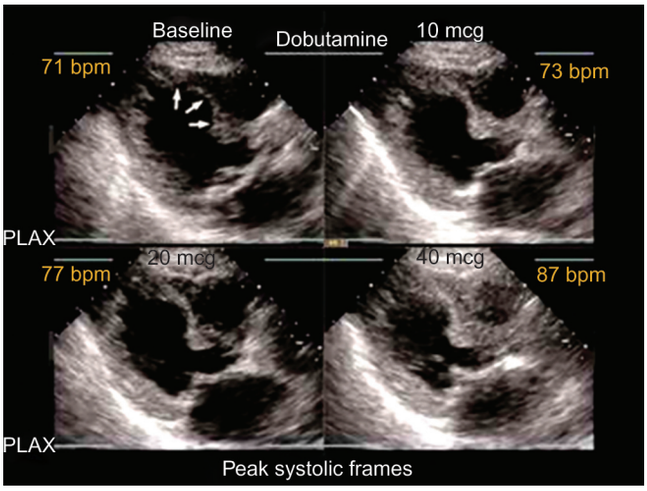

Fig. 8.33: A 64-years-old female with coronary artery disease and aortic valve disease underwent dobutamine stress echocardiography. Graded doses of dobutamine were infused in 3 minutes stages to a peak dose of 40 g/kg/min. Atropine (0.4 mg × 3) was given to achieve heart rate targets. Maximal heart rate achieved was 118 bpm (74% of predicted heart rate) and blood pressure was 110/82 mmHg. Patient had no symptoms. Baseline electrocardiogram showed normal sinus rhythm with ST abnormalities suggestive of a digitalis effect. Baseline echocardiogram showed dialated ventricular cavity size with estimated ejection fraction (EF) of 40–45% with akinesis and thinning of the basal-to-midanteroseptal and anterior wall. Images at peak infusion showed no increase in global systolic function (estimated EF 40%). The akinetic anteroseptal and anterior segments became progressively dyskinetic during the infusion consistent with a transmural infarct/scarring. In addition, the inferior wall, mildly hypokinetic at baseline, becomes akinetic at the high dose of dobutamine. Overall study was consistent with a large anterior and anteroseptal infarct with no significant peri-infarct ischemia. Sensitivity was limited because target heart rate was not achieved

symptoms to valvular abnormalities. However, stress echocardiography may have a lower sensitivity and specificity in heart failure patients because of LV dilatation or because of the presence of bundle branch block (Fig. 8.33).

Conventional Doppler Assessment of LV Diastolic Dysfunction

Mitral inflow measurements which included peak early (E) and peak late (A) flow velocities, the E/A ratio, the deceleration time of early mitral flow velocity (DT), the isovolumetric relaxation time (IVRT) at rest and during the Valsalva maneuver and the pulmonary venous flow measurements, characterized by peak systolic (S), diastolic (D), and atrial reversal (Ard) velocities; the systolic filling fraction (S/D); and the time difference between A and the duration of atrial reverse flow (Ard-Ad) were originally considered to be indicative of diastolic LV dysfunction if they exceeded specific cut-off values indexed for age group. Because of the absence of pseudonormalization on tissue Doppler imaging (TDI) lengthening velocity measurements, the use of blood flow Doppler measures of diastolic LV function is no longer recommended as a first-line diagnostic approach to diastolic LV dysfunction. Only when TDI lengthening velocities are suggestive but nondiagnostic or when plasma levels of natriuretic peptides are elevated does the simultaneous presence of a low E/A ratio and a prolonged DT or a prolonged Ard-Ad index provide diagnostic evidence of diastolic LV dysfunction (Figs 8.34–8.36).

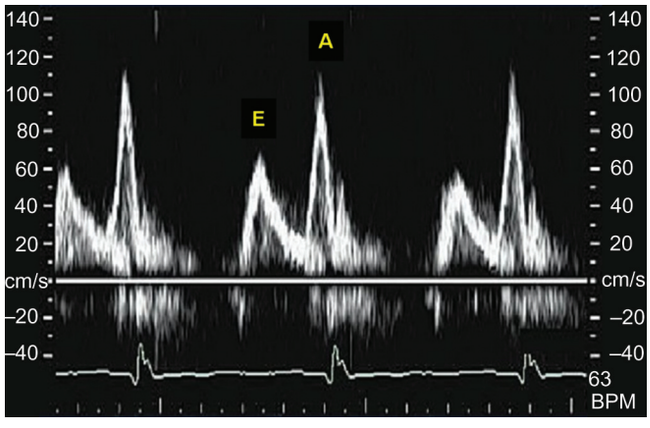

Fig. 8.34: Trans-mitral valve Doppler flow tracing in a patient with mild diastolic dysfunction (abnormal relaxation). The E- to A-wave ratio is <1.0

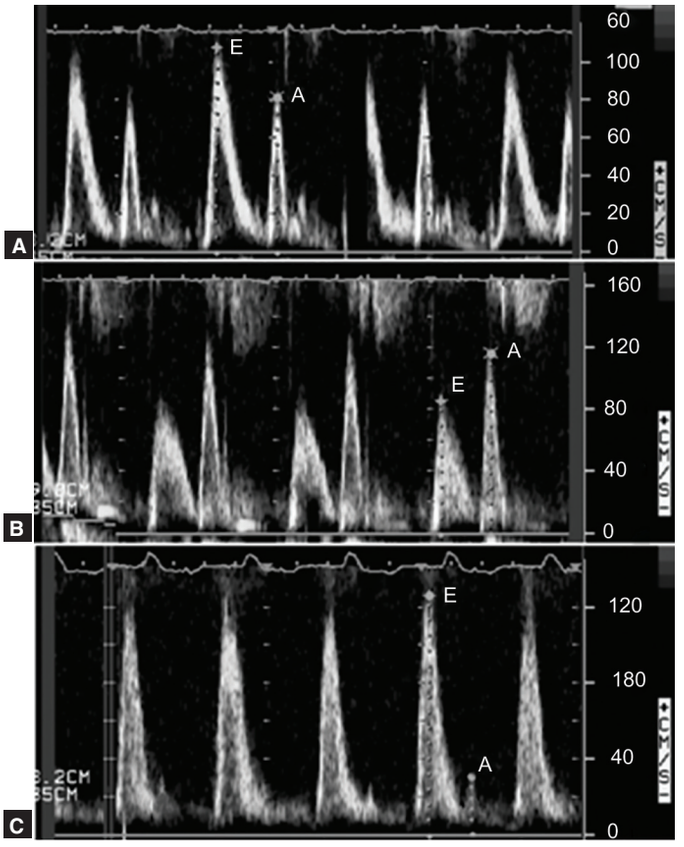

Fig. 8.35: Trans-mitral valve spectral Doppler flow pattern in a normal subject (A), in a patient with mild diastolic dysfunction (abnormal relaxation; B), and in a patient with severe (restrictive) diastolic dysfunction (C). In (A) the E/A wave ratio is approx. 1.5–1.0, and in (B) the E/A wave ratio is <1.0. In (C) the E/A wave ratio is abnormally high and A wave velocity is very low

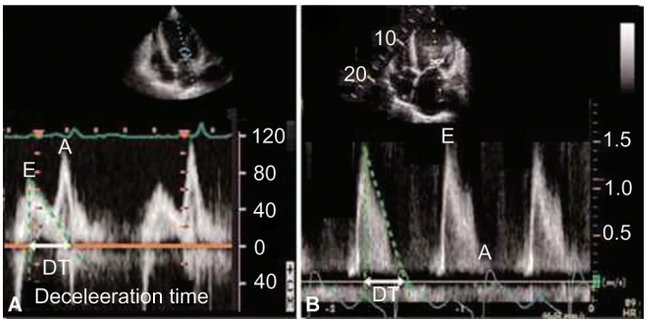

Fig. 8.36: Mitral inflow profiles showing evidence of diastolic dysfunction in dilated cardiomyopathy. The mitral inflow pulse Doppler profile in dilated cardiomyopathy often shows an impaired relaxation pattern (A) with prolonged deceleration time (DT >200 ms) and reversal of the normal E—a ratio during the early stages. Later worsening of diastolic dysfunction is accompanied by a compensatory increase in left atrial filling pressures (driving pressure) results in early rapid filling of the left ventricle (a tall, thin E-wave) in the setting of a dilated left atrium. The marked fall in the A-wave velocity reflects atrial systolic dysfunction owing to a poorly compliant left ventricle (B)

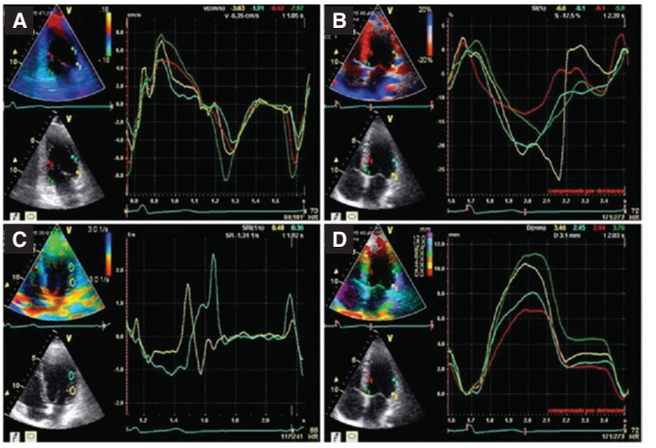

Fig. 8.37: Examples of tissue Doppler imaging measurements: (A) myocardial longitudinal segmental velocity in four regions of the anterior and inferior LV walls; (B) myocardial longitudinal segmental strain in lateral and septal LV walls; (C) myocardial longitudinal segmental strain rate in two regions in the lateral wall demonstrating some decrease in the velocity of deformation in the region represented by the yellow line; (D) myocardial longitudinal tissue displacement

Tissue Doppler Assessment of LV Diastolic Dysfunctions

Tissue Doppler (TD) echocardiography helps to accurately quantify LV diastolic function (Figs 8.37–8.39). TD may be used to quantify myocardial velocities in multiple segments of the myocardium from different echocardiographic acoustic windows. The most frequently used modality of TD is measurement of LV basal (annular), longitudinal myocardial shortening, or lengthening velocity. Measurements can be obtained either at the septal or at the lateral side of the mitral annulus. The peak systolic (S) shortening velocity and the early diastolic (E2) lengthening velocities are considered to be sensitive measures of LV systolic or diastolic function. Especially, the ratio of early mitral valve flow velocity (E) divided by E2 correlates closely with LV filling pressures. E depends on left atrial driving pressure, LV relaxation kinetics, and age but E′ depends mostly on LV relaxation kinetics and age. Hence, in the ratio E/E2, effects of LV relaxation kinetics and age are eliminated and the ratio becomes a measure of left atrial driving pressure or LV filling pressure. E2 can also be conceptualized as the amount of blood entering the LV during early filling, whereas E represents the gradient necessary to make this blood enter the LV. A high E/E2 thus represents a high gradient for a low shift in volume. Information on LV filling pressures can also be derived from the time interval between the onset of E and the onset of E2 (TE-E2).

When the ratio E/E2 exceeds 15, LV filling pressures are elevated and when the ratio is lower than 8, LV filling pressures are low. E/E2 is a powerful predictor of survival after myocardial infarction and E/E2 >15 is superior as predictor of prognosis than clinical or other echocardiographic variables. The close correlation between E/E2 and LV filling pressures has been confirmed in heart failure patients with depressed (<50%) or preserved LV

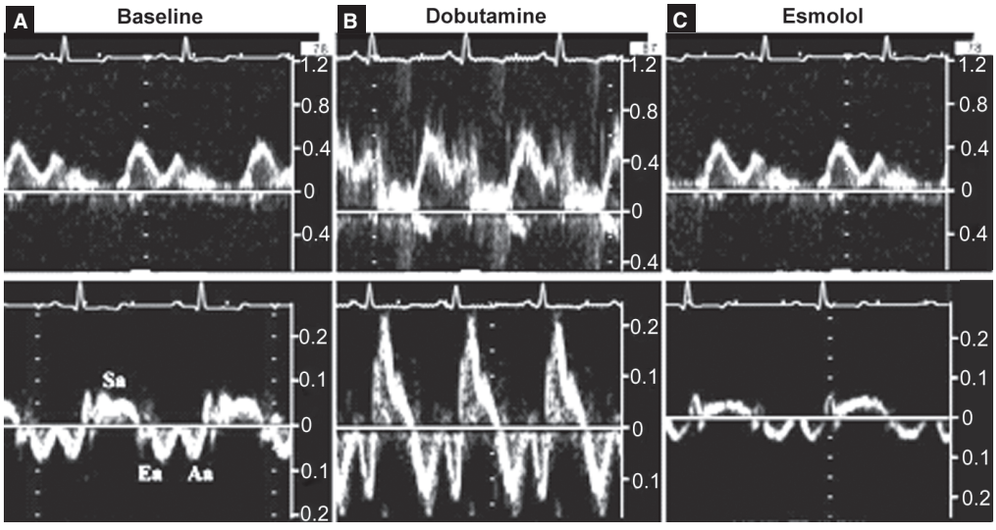

Fig. 8.38: Representative recordings of the lateral tricuspid annular motion velocity using tissue Doppler imaging (TDI) at baseline (A), with dobutamine (B), and with esmolol (C). Ea, ventricular early diastolic velocity; Aa, ventricular late diastolic velocity

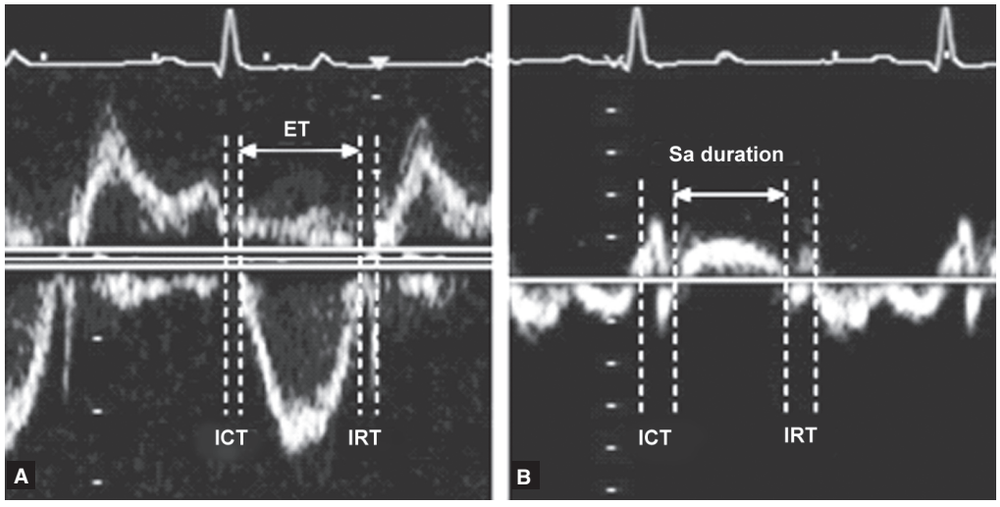

Fig. 8.39: Pulsed Doppler (PD)-derived myocardial performance index (MPI—A) and tissue Doppler-derived modified MPI (B). ET=ejection time; ICT=isovolumic contraction time; IRT=isovolumic relaxation time; Sa=ventricular systolic velocity

ejection fraction and in patients with slow relaxation or pseudonormal early mitral valve flow velocity filling patterns. The ratio E/E2 is considered diagnostic evidence of presence of diastolic LV dysfunction if E/E2 >15, and diagnostic evidence of absence of HFNLVEF if E/E2 <8. An E/E2 ratio ranging from 8–15 is considered suggestive but nondiagnostic evidence of diastolic LV dysfunction and needs to be implemented with other noninvasive investigations.

Invasive Method of Assessment of LV Diastolic Dysfunction

Definite evidence of abnormal LV relaxation, filling, diastolic distensibility or diastolic stiffness can be acquired invasively during cardiac catheterization. Such evidence consists of a time constant of LV relaxation (τ) > 48 ms, an LV enddiastolic pressure >16 mmHg or a mean pulmonary capillary wedge pressure >12 mmHg. A diastolic LV stiffness modulus >0.27 also provides diagnostic evidence of diastolic LV dysfunction. It has been pointed out that mitral flow Doppler alone, with its 40–70% specificity, cannot reliably detect diastolic dysfunction in HFNLVEF TDI including the transmitral flow velocity to annular velocity ratio (E/E2 index), which measures myocardial velocities during the cardiac cycle, is considered more reliable for diagnosing diastolic dysfunction. Oh et al. proposed comprehensive Doppler echocardiography with color flow or TDI as the most practical and reproducible method for either confirming or excluding diastolic dysfunction in HFNLVEF. In contrast, Maurer et al. recently argued that Doppler-derived diastolic parameters do not provide specific information on intrinsic passive diastolic properties and thus that diastolic dysfunction cannot be diagnosed by Doppler echocardiography. Invasive measurement of pressure–volume (PV) relationships with a conductance catheter system is generally considered most accurate for

characterizing diastolic cardiac function. It allows direct detection of LV relaxation abnormalities and passive LV stiffness characterized by a change in diastolic LV pressure relative to diastolic LV volume. A recent study Mario Kasner et al. was the first to investigate the accuracy of several echocardiographic Doppler techniques in detecting diastolic dysfunction in HFNLVEF by direct comparison with invasive PV loop data. It was found that no diastolic index of conventional Doppler echocardiography alone was sufficient to make the correct diagnosis. These indices correlated only weakly with diastolic relaxation anomalies and not at all with the degree of LV stiffness. On the other hand, TDI investigations and the LV filling index E/E2 lat were well suited for detecting invasively proven diastolic dysfunction in HFNLVEF patients.

Newer Techniques for Assessment of LV Dastolic Dysfunctions

Many studies have shown that atrial function is particularly important when ventricular dysfunction exists. Kurt et al. has shown that evaluation of LA systolic and diastolic function using strain Doppler echocardiography has reasonably high accuracy. This study showed that patients with DHF have a significantly reduced LA strain and strain rate during LV systole and increased LA stiffness index. Increased LA stiffness as assessed invasively and noninvasively readily identify patients with DHF from those with LV diastolic dysfunction. On the other hand, LV mass, volumes, and systolic function, LA volumes and atrial pump function were not significantly different in the patients of DHF and LVDD.

LA Strain and Strain Rate

These are new emerging real time ultrasound techniques that provide a measure of wall motion or a measure of deformation. Radial and longitudinal atrial or ventricular function can be assessed by the analysis of wall deformation using the rate of deformation of a myocardial segment (strain rate) and its deformation over time (strain).

A negative strain rate corresponds to myocardial shortening or thickening, whereas a positive strain rate corresponds to myocardial lengthening or thinning. Atrial strain and strain rate measurements are usually obtained during ventricular and atrial systole using sample volumes placed in the atrial myocardium near but clearly superior to the mitral annulus. For LA 'diastolic' strain variables (during LV systole) the source of the strain is the ventricle doing external work on the atrium as the LV ejects blood into the aorta. Deformation in the atria is reciprocally related to the deformation of the ventricles, as both apex and the atrial roof are relatively immobile, the ventricle shortens while atria elongates during systole, ventricle elongates and atria shortens during the diastolic phases. In diastasis, there is no deformation. And so the amount and rate of strain measured is determined primarily by ventricular and LV afterload attributes, although it follows that passive atrial tissue properties on which the LV is also doing work. In addition, because of its thin wall, strain rate imaging in the atria is extra prone to artefacts due to low

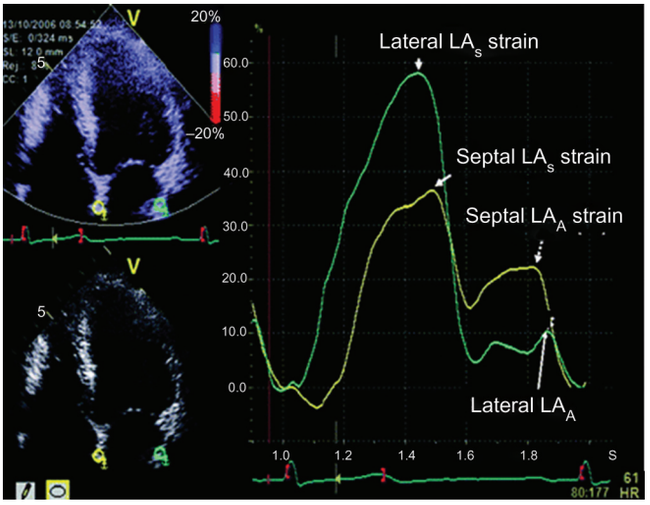

Fig. 8.40: Example of LA strain curves. Septal LA strain is shown in yellow, and lateral strain is shown in blue. LAS strain refers to LA strain during the systolic phase of the cardiac cycle, and LAA strain refers to LA strain during atrial contraction

lateral resolution. Kurt et al. has shown that patients with DHF had significantly a lower LA systolic strain and SR as compared to patients with LVDD alone. However, late diastolic strain and SR were similar in patients with DHF and LV diastolic dysfunction (Fig. 8.40).

LA Stiffness Index (Fig. 8.41)

Stiffness is conventionally defined as the force required to displace a passive spring a unit length. Physiologically it is the change in pressure required to increase the volume of a passive container a unit amount. LA stiffness can be estimated invasively, i.e. by ratio of pulmonary wedge pressure to LA systolic strain and noninvasive LA stiffness can be calculated by ratio of E/E2 and LA strain. LA systolic strain is determined by averaging values from four sites in the

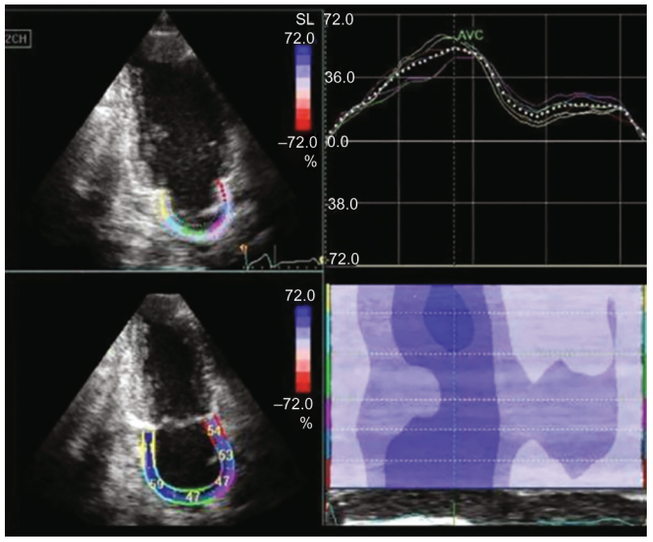

Fig. 8.41: Speckle echocardiographic left atrial strain and stiffness index as predictors of maintenance of sinus rhythm after cardioversion

LA myocardium. The units of LA stiffness are mmHg. Importantly, the denominator in this expression, although measured in the LA wall, is determined primarily by longitudinal apically directed displacement of the mitral annulus by the contracting ventricle, whereas the posterior aspect of the LA remains fixed. Hence this index, usually attributed to the LA as a stiffness measure, is very strongly influenced by LV properties. LA stiffness as assessed invasively and noninvasively readily identified patients with DHF from those with LV diastolic dysfunction. Kurt et al. has shown that a LA stiffness index of >1.1 mmHg had a sensitivity of 84%, and a specificity of 100% in distinguishing patients with DHF from those with LV diastolic dysfunction. Using E/E2 ratio in lieu of PCWP was also accurate in identifying DHF patients and an index of 0.99 had a sensitivity of 85% and a specificity of 78% in distinguishing patients with DHF from those with LV diastolic dysfunction.

Left atrial volume measurements: A left atrial volume indexed to body surface area (left atrial volume index) >32 ml/m^2 was first recognized in the elderly as a strong predictor (p=0.003) of a cardiovascular event with a higher predictive value than other echocardiographically derived indices such as LV mass index (p=0.014) or LV diastolic dysfunction (p=0.029). In a population-based study, left atrial volume index was also strongly associated with the severity and duration of diastolic LV dysfunction; the left atrial volume index progressively increased from a value of 23+6 ml/m^2 in normals to 25+8 ml/m^2 in mild diastolic LV dysfunction, to 31+8 ml/m^2 in moderate diastolic LV dysfunction, and finally to 48+12 ml/m^2 in severe diastolic LV dysfunction. Left atrial volume index was therefore proposed as a biomarker of both diastolic LV dysfunction and cardiovascular risk. Left atrial volume index (LAVi) is a more robust marker than left atrial area or left atrial diameter (Fig 8.42).

For these reasons, a left atrial volume index >40 ml/m^2 has been taken to provide sufficient evidence of diastolic LV dysfunction when the E/E2 ratio is nonconclusive

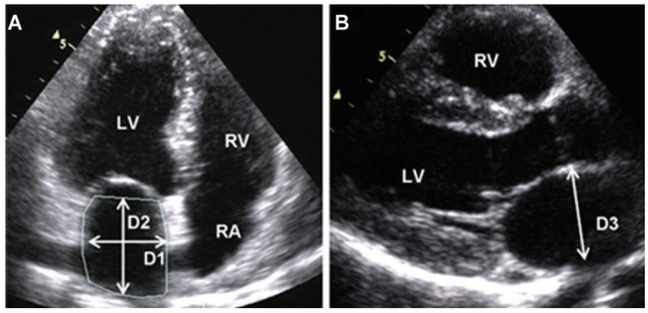

Figs 8.42A and B: Measurement of left atrial (LA) volume from the prolate ellipse method using apical four-chamber and parasternal long-axis views at ventricular end systole (maximum LA size). D2 is measured from the mitral annular plane to the back wall. D1 is the orthogonal short-axis dimension to D2. D3 is measured from the blood-tissue interface of the anterior and posterior walls. LA volume is (D1×D2×D3)×(0.523). LV=left ventricle; RA=right atrium; RV=right ventricle

(i.e. 15 >E/E2 >8) or when plasma levels of natriuretic peptides are elevated. Similarly, a left atrial volume index <29 ml/m^2 is proposed as a prerequisite to exclude HFNLVEF. Left atrial volume index values of 29 and 40 ml/m^2 correspond, respectively, to the lower cut-off values of mildly abnormal and severely abnormal LA size in the recent recommendations for cardiac chamber quantification of the American Society of Echocardiography and the European Association of Echocardiography.

LV Torsion with 2D Speckle Tracking Echocardiography

Left ventricular torsion (LVtor) and subsequent untwisting play an important role in diastolic filling. Sung-Ji et al. has shown that systolic torsion and diastolic untwisting are significantly increased in patients with mild diastolic dysfunction. However, analysis of LVtor with speckle tracking echocardiography needs to be further explored to elucidate the role of torsion in patients with LV diastolic dysfunction (Figs 8.43–8.50).

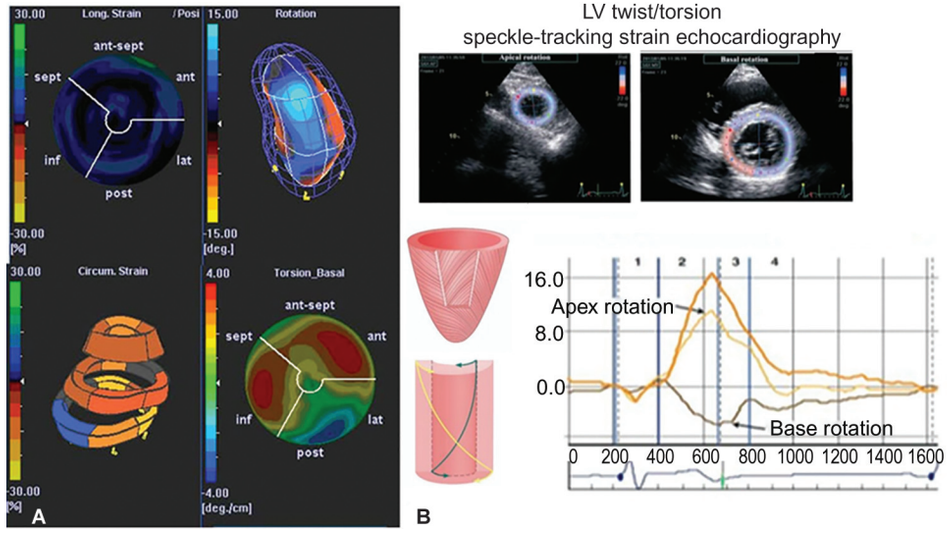

Figs 8.43A and B: Different parameters (longitudinal strain, rotation, circumferential strain and torsion-basal) displayed in different formats

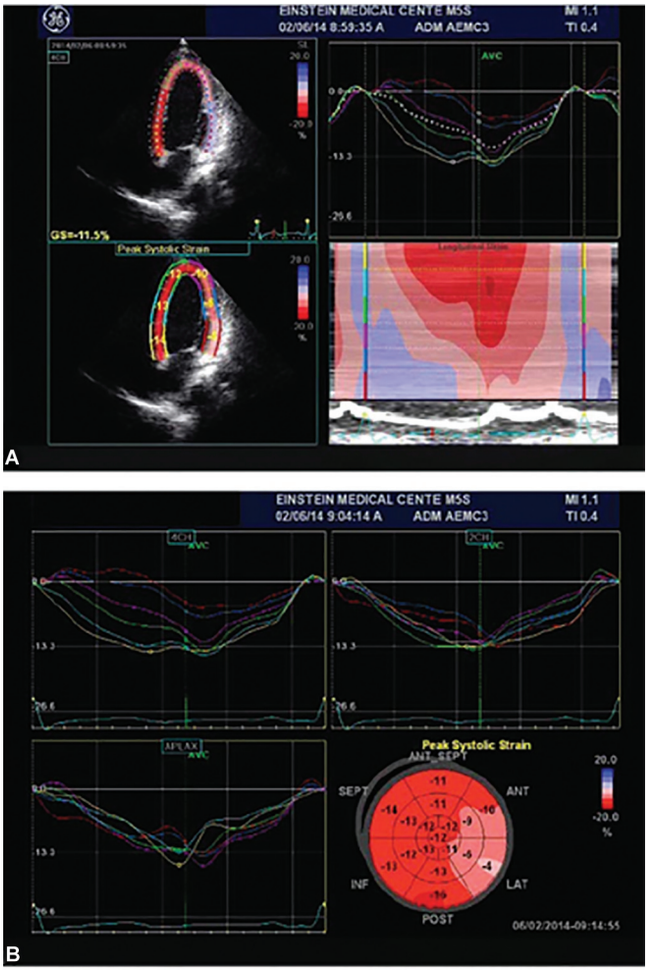

Fig. 8.44: Speckle-tracking echocardiography-derived longitudinal strain in a patient with cardiomyopathy with a left ventricular ejection fraction of 40%. (A, top left) Peak longitudinal strain in a apical four-chamber view. (A, top right) Wave form display. (A, bottom left) Quantitative parametric overlay. (A, bottom right) Color M-mode display. (B) Bull's eye presentation of strain

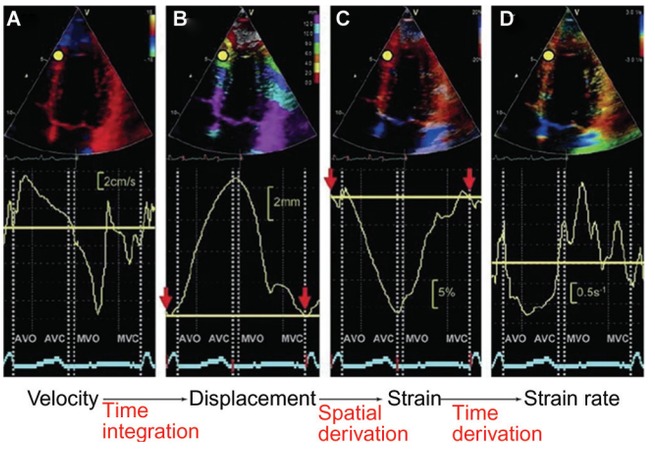

Fig. 8.45: Parameters of myocardial deformation derived from one region of interest (yellow dot) using tissue Doppler imaging. (A) Velocity, (B) displacement, (C) strain, (D) strain rate

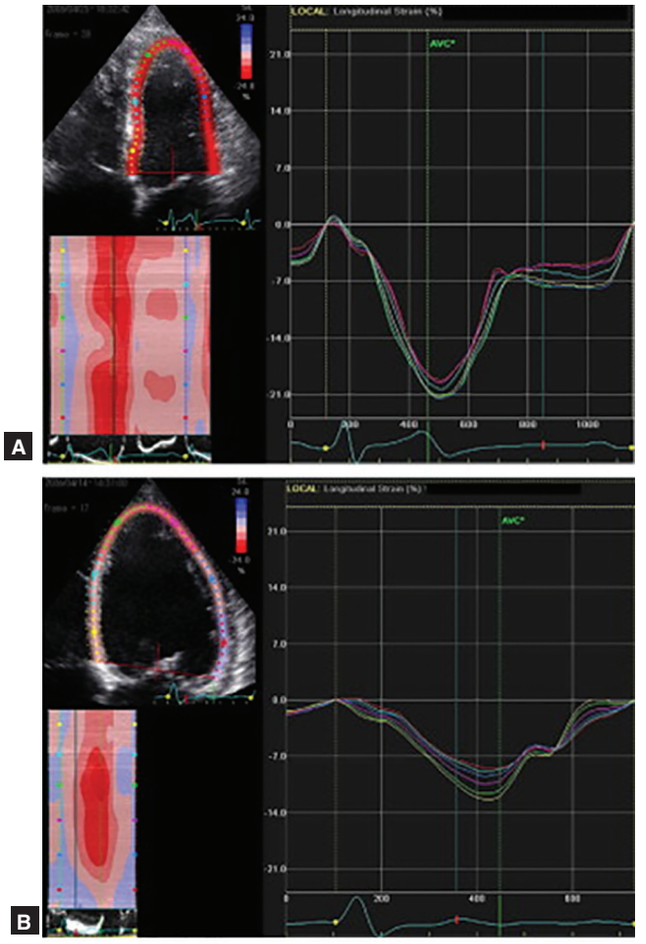

Fig. 8.46: Longitudinal strain by speckle tracking imaging in a normal subject and a heart failure patient. (A) An example of speckle tracking imaging of longitudinal strain using the apical four-chamber view in a normal subject demonstrating peak longitudinal strain of –16.5% and –21.5%, respectively. (B) An example of speckle tracking imaging of longitudinal strain using the apical four-chamber view in a heart failure patient with depressed ejection fraction demonstrating smaller peak longitudinal strain of –8.0% and –12.5%, respectively. AVC = aortic valve closure

Role of BNP in DHF

Measurements of the levels of B-natreuretic peptide (BNP) have been used to confirm the diagnosis of heart failure. Large population-based studies using BNP to screen for heart failure demonstrate a sensitivity of 40–50% and a specificity of 95% in detecting ejection fraction of less than 40%. The diagnostic accuracy of BNP increases tremendously if we include diastolic heart-failure patients. Therefore, the same authors found that when including diastolic dysfunction on echo, BNP had a sensitivity of 91% and a specificity of 82%. Doust et al. reviewed 20 studies looking at the accuracy of BNP in the diagnosis of heart failure and found that BNP had an area under the receiver operator curve of 0.83. Using the pooled diagnostic odds ratio (DOR) [sensitivity/(1-sensitivity)]/[(1-specificity)/specificity] they demonstrated a DOR of 11.6 for studies

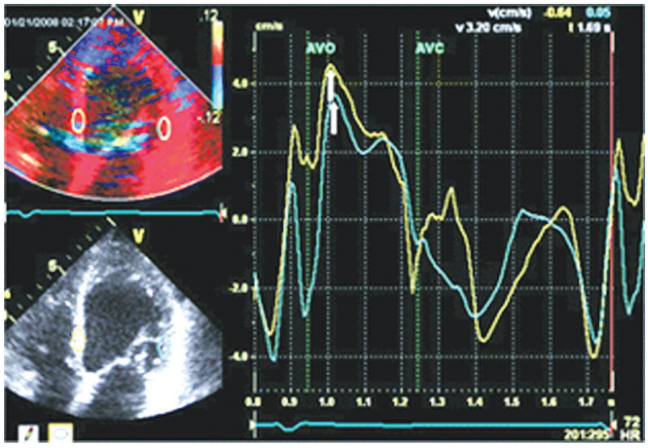

Fig. 8.47: Color-coded tissue Doppler image using the apical four-chamber view from a heart failure patient with widened QRS, but no significant mechanical dyssynchrony before cardiac resynchronization therapy. There was similar timing in peak velocities (arrows) from septal to lateral wall, determined between aortic valve opening (AVO) and aortic valve closure (AVC). This patient did not have a favourable clinical nor ventricular function response to resynchronization therapy

that compared BNP with impaired ejection fraction and a DOR of around 30 for studies that compared BNP with clinical heart failure including patients with diastolic heart failure. Therefore, BNP's diagnostic accuracy was increased when diastolic heart failure patients were included in the disease group. Moreover, in normal individuals, the concentration of BNP rises with age and is higher in women than in men. BNP levels can be influenced by comorbidities such as sepsis, liver failure, or kidney failure, pulmonary hypertension as a result of chronic obstructive pulmonary disease, pulmonary embolism, or mechanical ventilation and obesity. BNP levels are therefore recommended mainly for exclusion of HFNLVEF and not for diagnosis of HFNLVEF. Furthermore, when used for diagnostic purposes, BNP levels alone does not provide diagnostic standard evidence of HFNLVEF and always need to be complemented with other echocardiographic variables.

CT Scanning and MRI

Computed tomography (CT) scanning or magnetic resonance imaging (MRI) may be useful in evaluating chamber size and ventricular mass, cardiac function, and wall motion; delineating congenital and valvular abnormalities; and demonstrating the presence of pericardial disease. However, cardiac CT scanning is usually not required in the routine diagnosis and management of heart failure, and echocardiography and MRI may provide similar information without exposing the patient to ionizing radiation (Fig. 8.51).

The benefits of cardiac MRI (cMRI) include the ability to obtain a great deal of information with a noninvasive test. This modality provides detailed functional and morphologic information; can be used to assess ischemic versus nonischemic disease, infiltrative disease, and hypertrophic disease; and can be employed to determine viability. It is used principally for the delineation of con-

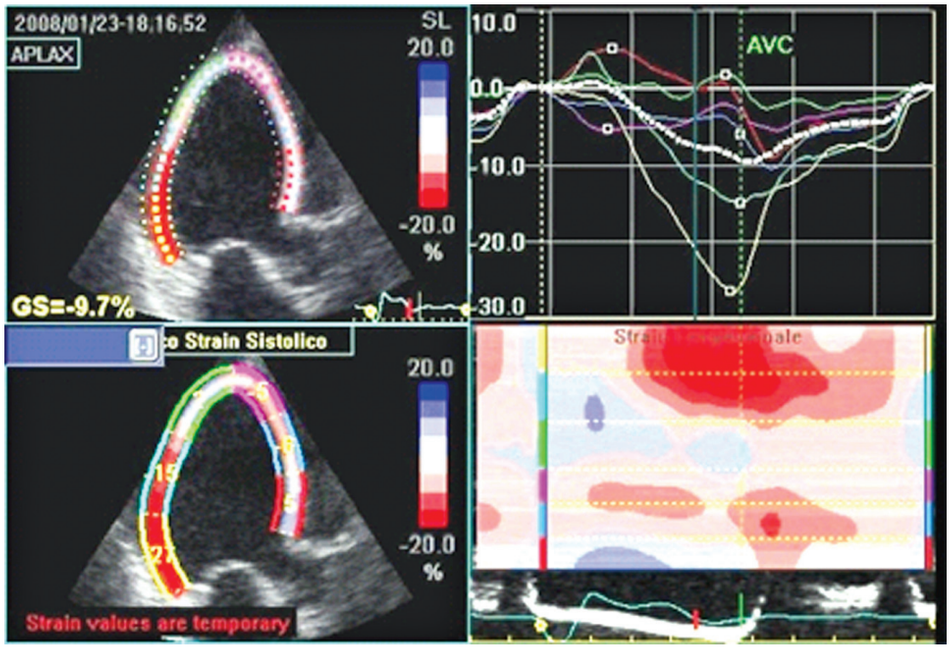

Fig. 8.48: Representation of 2D-strain (speckle tracking) of the left ventricle in the apical long axis view in a patient with systolic heart failure. The upper right panel depicts the strain curves sampled in each of the analyzed myocardial segments. It is also possible to calculate a global strain index (GS), which in this case is clearly diminished (GS=9,7%; see upper left panel). The lower left panel shows peak systolic strain for each segment while the lower right panel shows longitudinal strain processed according to a color map of curvilinear anatomical M-mode. From top to bottom: the basal, mid, and apical posterolateral wall, followed by the apical, mid, and basal interventricular anterior septum wall; in red the segments with higher contractility

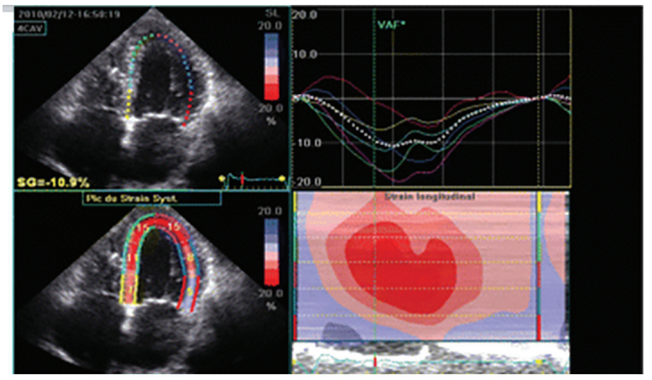

A. Patient

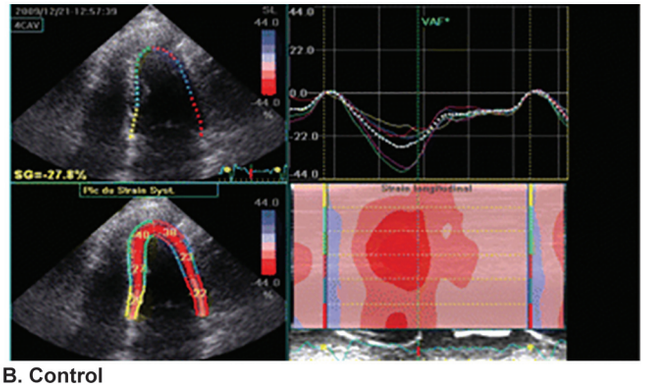

B. Control

Fig. 8.49: (A) Two-dimensional strain in an apical four-chamber view in a patient with heart failure and preserved ejection fraction and (B) in a control patient



Fig. 8.51: Magnetic resonance image shows a scar in the anterior cardiac wall in a patient indicative of a previous myocardial infarction precipitating heart failure

genital cardiac abnormalities and for the assessment of valvular heart disease, and it is the gold standard for evaluating RV function MRI has become particularly useful for evaluating abnormalities in wall motion and viable myocardium, and MRI results can help predict the success of revascularization in patients with low ejection fractions. However, the detailed information obtained by MRI must

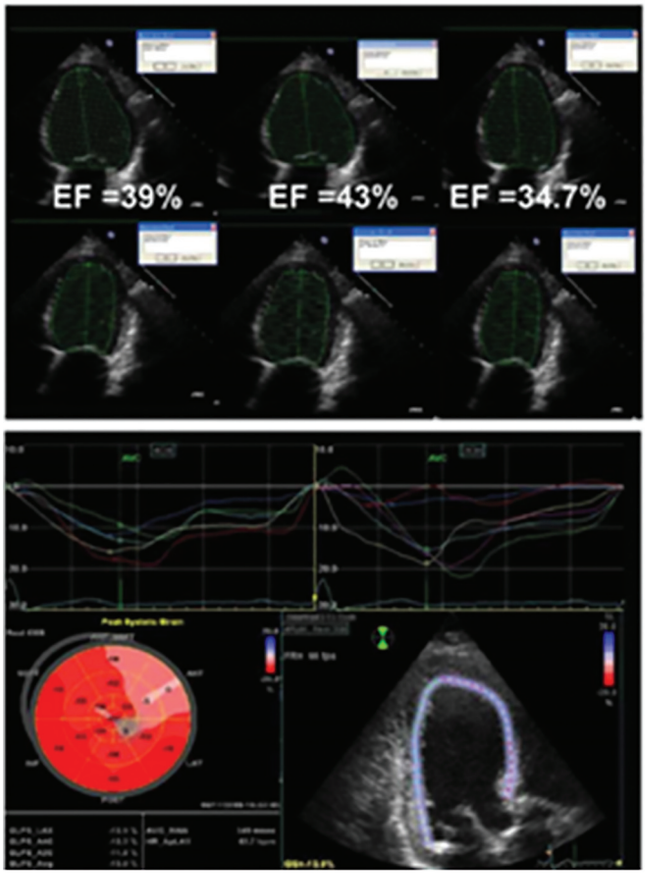

Fig. 8.50: (A) Left ventricular evaluation in heart failure (HF). Successive tracings may place this patient's EF above or below the threshold for device insertion, (B) Benefit of an automated approach to EF-based decision-making. Repeat measurements of global strain are highly likely to be reproducible

be balanced by its high costs and the fact that this imaging modality cannot be performed in patients with implantable defibrillators.

Nuclear Imaging

The incidence of heart failure (HF) is increasing and it remains the only area in cardiovascular disease wherein hospitalization rates and mortalities have worsened in the past 25 years. This review is provided to assess the role of radionuclide imaging in HF. The focus is on three aspects—the value of nuclear imaging to distinguish ischemic from nonischemic etiologies; risk stratification of patients with HF with evaluation of candidates for specific treatment strategies; and the role of cardiac neuronal imaging in patients with HF. Distinguishing ischemic from non-ischemic cardiomyopathy is important because patients with ischemic cardiomyopathy can potentially have dramatic improvement with revascularization. Single photon emission computed tomography (SPECT) has excellent reported sensitivity and negative predictive value in the detection of coronary artery disease in HF patients. SPECT imaging is also useful in establishing treatment strategies in patients with HF, including those with new onset CHF. Cardiac neuronal imaging of mIBG is parti-

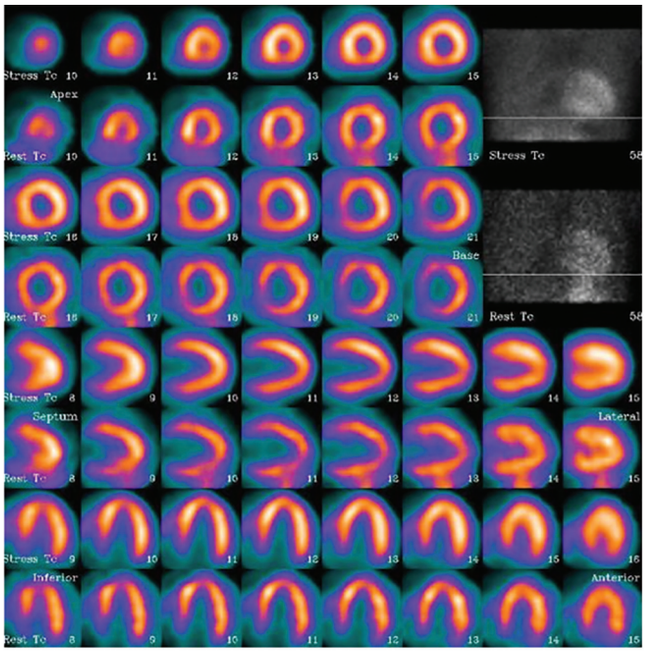

Fig. 8.52: Myocardial perfusion imaging was performed with dipyridamole stress test using one day Tc-99m-tetrofosmin rest-stress protocol. There were no symptoms or ECG changes to suggest dipyridamole induced myocardial ischemia. The images do not show any reversible perfusion defects to suggest presence of dipyridamole induced myocardial ischemia. Left ventricle is dilated (EDV 176 ccs) and hypertrophied. Gated images show global hypokinesis with an ejection fraction of 34%. These findings suggest nonischemic cardiomyopathy. Echocardiography showed left ventricular hypertrophy and dilatation with a globally reduced ejection fraction of 30–40%

cularly helpful in risk stratification of patients with HF. The modality can be used to monitor the response to therapy as dysfunctional mIBG uptake may show improvement with pharmacological treatment (Figs 8.52 and 8.53).

Radionuclide Multiple-gated Acquisition Scanning

Radionuclide multiple-gated acquisition (MUGA) scan is a reliable imaging technique for evaluation of LV and RV function and wall motion abnormalities. Because of its reliability, LV ejection fraction (LVEF), as determined by MUGA scanning, is often used for serial assessment of postchemotherapy LV function (Fig. 8.54).

Electrocardiogram-gated Myocardial Perfusion Imaging

The high photon flux of compounds labeled with technetium-99m (99m TC) makes it feasible to acquire myocardial perfusion images in an ECG-gated mode. ECG-gated single-photon emission CT (SPECT) images allow for assessment of global LVEF, regional wall motion, and regional wall thickening at rest in patients with documented stress-induced wall motion and perfusion abnormalities (Fig. 8.55).

In general, LVEF from gated SPECT agrees well with resting LVEF determined by other modalities. Quality assurance is important, however, because determinations of LVEF with gated SPECT may be less accurate, even invalidated, in the presence of an irregular heart rate, low count density, intense extracardiac radiotracer uptake adjacent to the LV, or a small LV.

Combined interpretation of perfusion and function on ECG-gated images substantially increases the confidence of interpretation. Taillefer and associates reported that the interpretation of stress and rest end-diastolic section, rather than summed ungated sections, may enhance the overall sensitivity for the detection of mild coronary artery disease.

ECG-gated images are useful for recognizing artifactual defects caused by attenuation (breast and diaphragm) and thus are useful in the quality control of SPECT imaging. ECG-gated SPECT imaging is currently considered the state of the art of radionuclide myocardial perfusion imaging.

There are three important practical issues that need to be addressed in the evaluation of patients with presumed ischemic dysfunction, as follows:

- Assessment of the relative regional myocardial uptake of thallium-201 (201 Tl; often after rest reinjection), 99m Tc-sestamibi, or 99m Tc-tetrofosmin (often after rest administration of nitroglycerin); when the resting uptake of radiotracer is greater than 50% of normal, expect recovery of function after revascularization.
- Assessment of the presence of demonstrable ischemia (e.g. partially reversible defect) in a myocardial segment with decreased uptake, even if the resting uptake is less than 50%.

Data reported in 2011 from a STICH viability substudy failed to demonstrate a significant impact on survival based on the extent of viable myocardium in patients with CAD and LV dysfunction treated surgically or medically.

Equilibrium Radionuclide Angiocardiography

Equilibrium radionuclide angiocardiography (ERNA) uses ECG events to define the temporal relationship between the acquisition of nuclear data and the volumetric components of the cardiac cycle. Sampling is performed repetitively over several hundred heartbeats, with physiologic segregation of nuclear data in accordance with their occurrence within the cardiac cycle (Fig. 8.56).

Data are quantified and displayed in an endless-loop, cinegraphic format for additional qualitative visual interpretation and analysis. Equilibrium blood-pool labeling is achieved by use of 99m-Tc. Data are analyzed by use of a computer, generally with some operator interaction.

Analysis may be obtained in either the frame or list mode. Radionuclide data are collected and segregated temporally. The process generally requires 3–10 minutes for completion of each view. Following data acquisition, data from the several hundred individual beats are summed, processed, and displayed as a single representative cardiac cycle. Data from the left anterior oblique (LAO) view are also used for qualitative analysis of global LV function. On this view, overlap of the two ventricles is

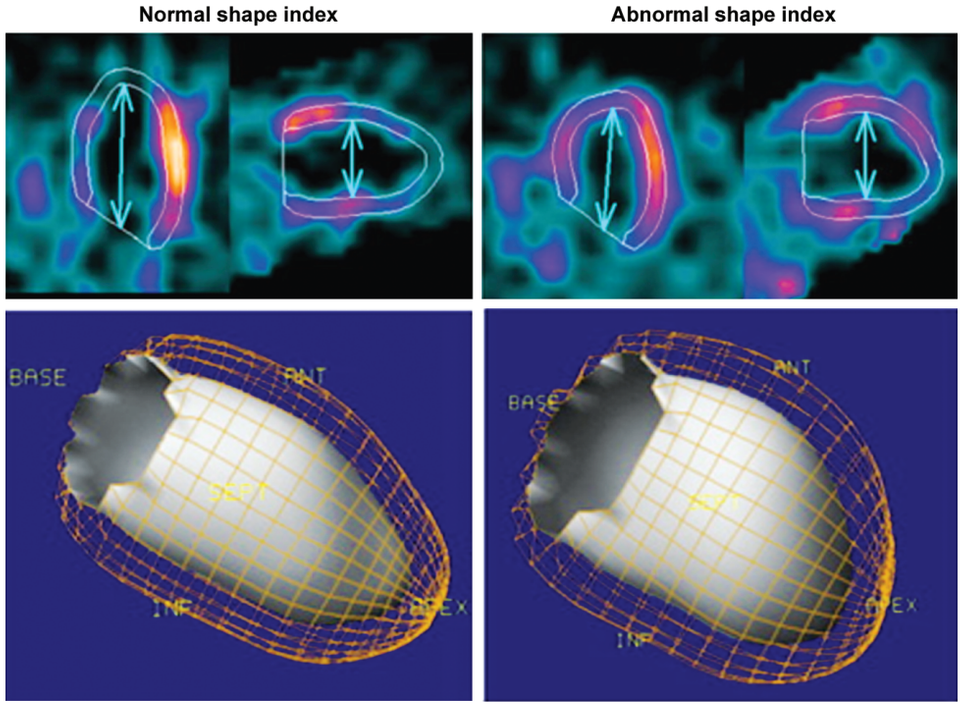

Fig. 8.53: Illustration of two cases with similar low LVEF but differing LV shape index. (A) The patient with no signs of congestive heart failure (CHF) has a more severe perfusion defect than the other patient but has a normal LV shape index and an elongated LV cavity. (B) The other patient, who has severe congestive heart failure, has an abnormal LV shape index and a more spherical left ventricle. ANT=Anterior; SEPT=septal; INF=inferior; LVSIs=systolic LV shape index (*reproduced with permission*)

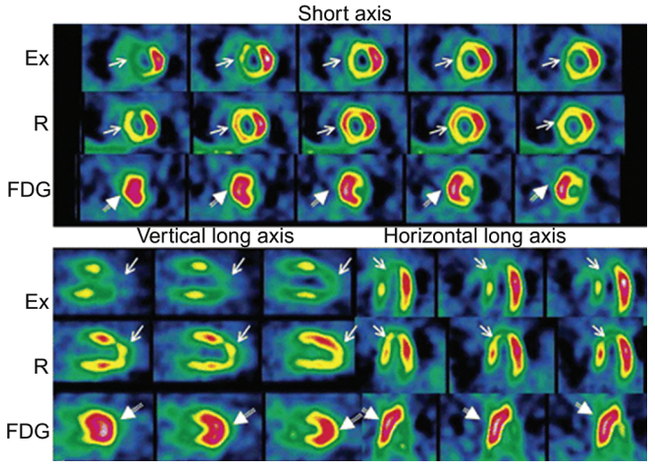

Fig. 8.54: Simultaneous myocardial perfusion and metabolism imaging after dual intravenous injection of 99mTc-sestamibi and 18F-FDG at peak exercise (Ex). Dual-isotope simultaneous acquisition was performed 40–60 min after exercise study was completed. Rest 99mTc-sestamibi imaging (R) was performed separately. In this patient with angina and no prior myocardial infarction, note evidence of extensive reversible perfusion defect in anterior, septal, and apical regions. Coronary angiogram showed 90% stenosis of left anterior descending and 60% of left circumflex coronary arteries. Corresponding 18F-FDG image shows intense uptake in regions with reversible sestamibi defects reflecting metabolic correlate of exercise-induced myocardial ischemia

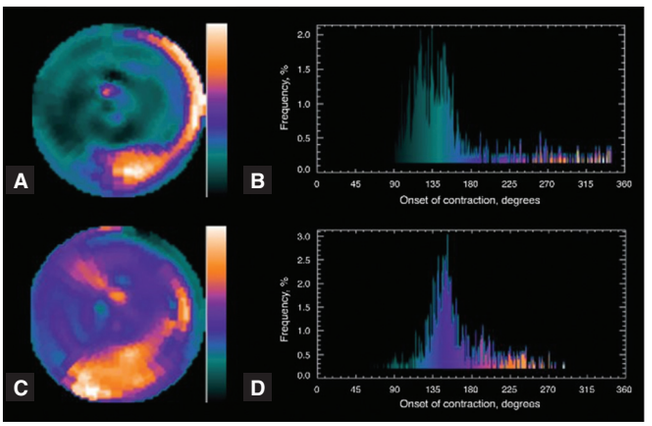

Fig. 8.55: Fourier analysis of a gated myocardial perfusion single-photon emission computed tomography. Before resynchronization (A), the phase histogram amplitude increases abnormally. The polar map (B) shows that the greatest delay occurs in the inferior-lateral region of the left ventricle. After cardiac resynchronization therapy (C), the histogram amplitude (D) improves significantly. The patient improved clinically and left ventricular ejection fraction improved from 18–32% lower (images courtesy of Dr. Santiago Aguadé-Bruix, Hospital Universitari Vall d'Hebron, Barcelona)

minimal. In a count-based approach, LVEF and other indices of filling and ejection are calculated from the LV radioactivity preset at various points throughout the cardiac cycle.

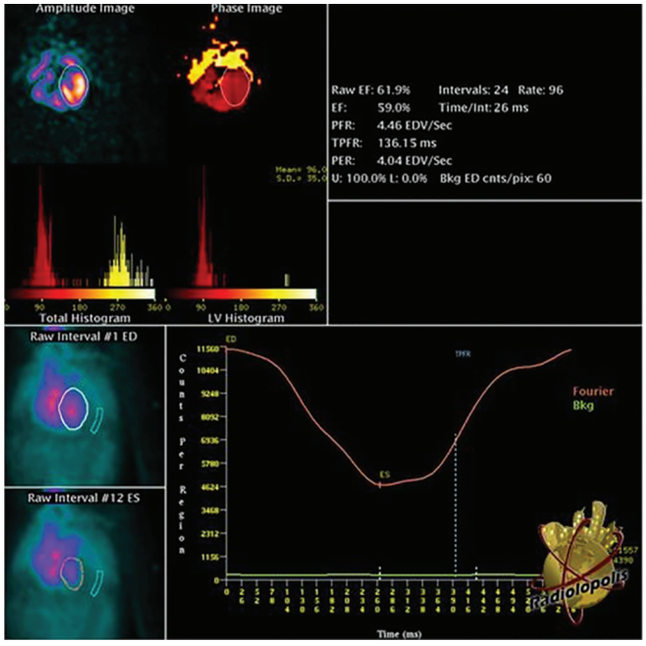

Fig. 8.56: Normal LV MUGA scan (equilibrium radionuclide angiography)

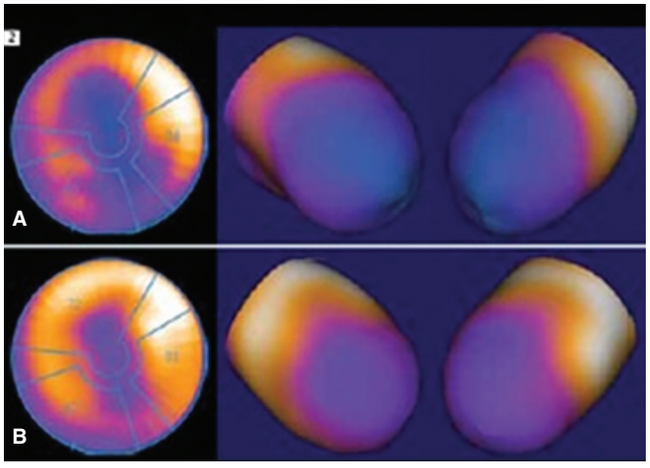

Fig. 8.57: Polar plots and volume rendering of stress (A) and rest (B) IQ•SPECT images show gross, but reversible, ischemia in the apical, anterior and anteroseptal walls and inferior and inferolateral walls. The apex and adjacent anterior wall show significant resting hypoperfusion, which may reflect hibernating myocardium. The posterolateral wall was relatively well perfused. Stress LVEF is significantly low at 39% with normal resting LVEF (56%), indicating severe stress induced LV dysfunction

RV function is best evaluated by first-pass techniques. The LAO view provides qualitative information concerning contraction of the septal, inferoapical, and lateral walls. The anterior view provides data concerning regional motion of the anterior and apical segments. The left lateral or left posterior oblique view provides optimal qualitative information concerning contraction of the inferior wall and posterobasal segment.

ERNA may easily be combined with additional physiologic stress testing or provocation, which may be in the form of either physiologic stress, such as exercise; pharmacologic stress, with the use of positive inotropic agents, such as dobutamine or isoproterenol; or psychological stress. The degree of confidence with ERNA is moderately high. False-positive and false-negative findings are infrequent.

Radionuclide Ventriculography

Radionuclide ventriculography is most often performed as part of a myocardial perfusion scan to obtain accurate measurements of LV function and right ventricular EF, but it is unable to directly assess valvular abnormalities or cardiac hypertrophy and has limited value for assessing volumes or more subtle indices of systolic or diastolic function (Fig. 8.57).

Catheterization and Angiography

In patients with a nonischemic cardiomyopathy, perfusion deficits and segmental wall-motion abnormalities suggestive of coronary artery disease are commonly present on noninvasive imaging. Only coronary angiography, however, can reliably demonstrate or exclude the presence of obstructed coronary vessels (Fig. 8.58).

According to the American College of Cardiology/American Heart Association (ACC/AHA), Heart Failure

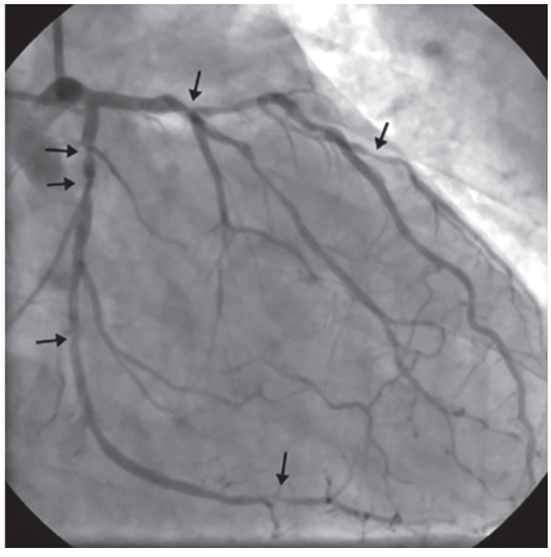

Fig. 8.58: Extensive coronary artery disease. Multiple stenoses are present; they involve the left anterior descending coronary artery and the circumflex coronary artery and their branches. in an elderly patient with heart failure

Society of America (HFSA) and European Society of Cardiology (ESC), cardiac catheterization and coronary angiography should be considered for patients with heart failure in the following situations; when symptoms worsen without a clear cause in patients with heart failure, no angina, and known coronary artery disease. In heart failure caused by systolic dysfunction in association with angina or regional wall-motion abnormalities and/or scintigraphic evidence of reversible myocardial ischemia when revascularization is being considered When pretest probability of underlying ischemic cardiomyopathy is high and surgical

coronary procedures are being considered. Before cardiac transplantation or left ventricular assist device placement. In cases of heart failure secondary to postinfarction ventricular aneurysm or other mechanical complications of myocardial infarction For these patients, the procedures are frequently indicated when systolic dysfunction of unexplained cause is present on noninvasive testing or when normal systolic function with episodic heart failure suggests ischemically mediated LV dysfunction. However, although coronary angiography may be indicated in young patients to exclude the presence of congenital coronary anomalies, this procedure may not be as useful in older patients, because revascularization has not been shown to improve clinical outcomes in patients without angina. Despite this, because revascularization may improve LV function, some experts suggest that coronary artery disease should be excluded whenever possible, especially in patients with diabetes mellitus or other states associated with silent myocardial ischemia. The degree of confidence is moderately high.

Right-sided Heart Catheterization

Right heart catheterization is useful in providing important hemodynamic information about filling pressures, vascular resistance, and cardiac output when there is doubt about the patient's fluid status; in heart failure refractory to initial therapy; in the presence of significant hypotension (systolic blood pressure typically < 90 mmHg or symptomatic low systolic blood pressure) and/or worsening renal function during initial treatment; and when heart transplantation or placement of a mechanical circulatory support device is being considered. However, it plays a limited role in the diagnosis of heart failure, as studies evaluating right heart catheterization and overall improved outcomes have been essentially neutral. Normal right-sided hemodynamics include right atrial pressure < 7 mmHg, RV pressure < 30/7 mmHg, pulmonary pressure < 30/18, pulmonary capillary wedge pressure (PCWP) < 18 mmHg, and cardiac index (CI) > 2.2 L/min/m^2.

PCWP can be measured by using a pulmonary arterial catheter (Swan-Ganz catheter). This helps differentiate cardiogenic causes of decompensated heart failure from noncardiogenic causes, such as acute respiratory distress syndrome (ARDS), which occurs secondary to injury to the alveolar-capillary membrane rather than to alteration in Starling forces. A PCWP exceeding 18 mmHg in a patient not known to have chronically elevated left atrial pressure is indicative of cardiogenic decompensated heart failure. In patients with chronic pulmonary capillary hypertension, capillary wedge pressures exceeding 25 mmHg are generally required to overcome the pumping capacity of the lymphatics and produce pulmonary edema.

Large V waves may be observed in the PCWP tracing in patients with significant mitral regurgitation because large volumes of blood regurgitate into a poorly compliant left atrium. This raises pulmonary venous pressure and may cause pulmonary edema.

Left-sided Heart Catheterization

Left-sided heart catheterization and coronary angiography should be undertaken when the aetiology of heart failure cannot be determined by clinical or noninvasive imaging methods or when the aetiology is likely to be due to acute myocardial ischemia or infarction. Coronary angiography is particularly helpful in patients with LV systolic dysfunction and known or suspected coronary artery disease in whom myocardial ischemia is thought to play a dominant role in the reduction of LV systolic function and the worsening of heart failure.

Endomyocardial Biopsy

Endomyocardial biopsy is indicated only when a specific diagnosis is suspected that would influence therapy in

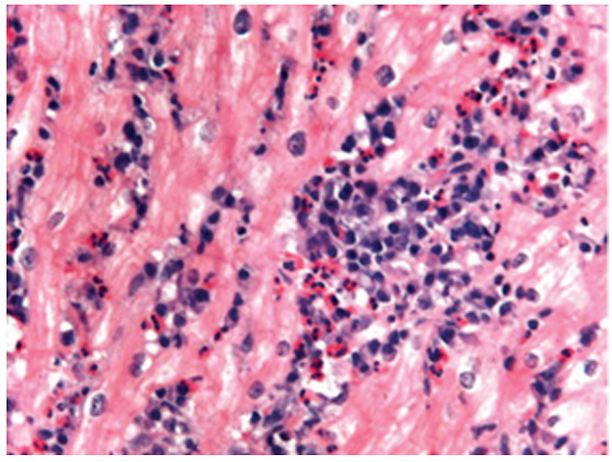

Fig. 8.59: Eosinophilic myocarditis. The patient had severe heart failure and peripheral eosinophilia. Immunosuppression improved her heart failure and probably primary hyper-eosinophilic syndrome (H and E; original magnification X 400)

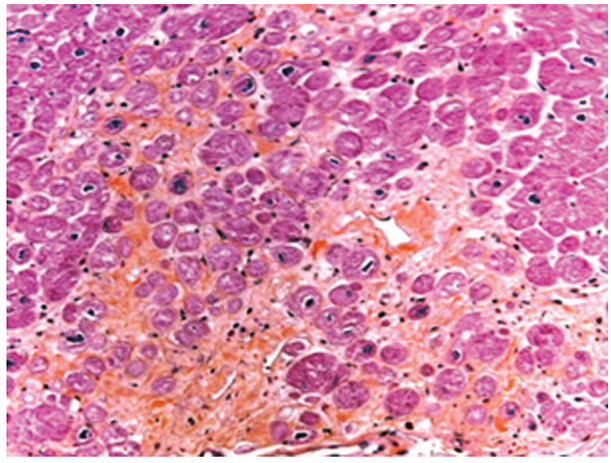

Fig. 8.60: Dilated cardiomyopathy. Middle-aged man with congestive heart failure. The photomicrograph shows cardiomyocytes with nuclear hypertrophy, myocytolysis and interstitial fibrosis. This is a nonspecific histological appearance that can be seen with many cardiomyopathies. Clinical information is always required (HPS; original magnification X 200)

patients presenting with heart failure (see the image below). The Heart Failure Society of America (HFSA) suggests that endomyocardial biopsy be considered in patients with rapidly progressive clinical heart failure or ventricular dysfunction, despite appropriate medical therapy, as well as in patients suspected of having myocardial infiltrative processes (e.g. sarcoidosis, amyloidosis) or in patients with malignant arrhythmias out of proportion to their LV dysfunction (e.g. sarcoidosis, giant cell myocarditis) (Figs 8.59 and 8.60).

Assessment of Functional Capacity

The European Society of Cardiology (ESC) indicates the 6-minute walk test is a good indicator of functional status and prognosis in patients with heart failure. It evaluates distance walked, dyspnea index on a Borg scale from 0–10, oxygen saturation, and heart rate response to exercise. A normal value is walking more than 1500 feet. Patients who walk less than 600 feet have severe cardiac dysfunction and a worse short- and long-term prognosis.

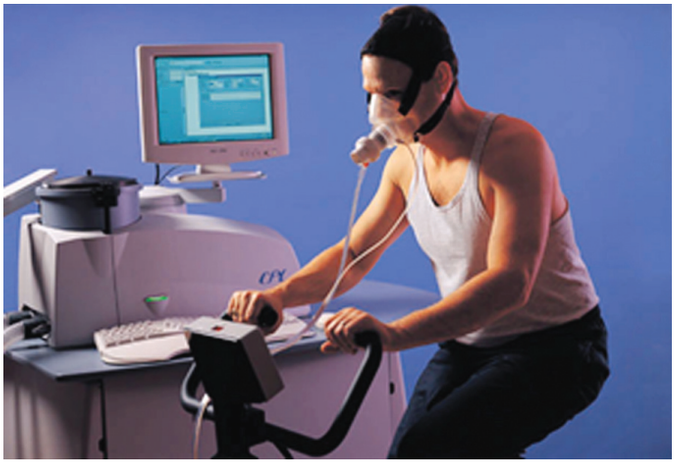

Fig. 8.61: Cardiopulmonary stress test. It is simply 'stress-testing' with some additional complementary measurements. Stress tests use a bicycle or treadmill to look at heart function at rest and during exercise stress

Cardiopulmonary stress testing (Fig 8. 61) (maximal exercise stress testing with measurement of respiratory gas exchange) can help assess a patient's chance of survival within the next year, as well as determine the need for referral for either cardiac transplantation or implantation of mechanical circulatory support. The ACC/AHA and HFSA do not recommend routine maximal exercise stress testing. It may be useful in situations such as the following with measurement of gas exchange:

- To assess the disparity between symptomatic limitation and objective indicators of disease severity
- To distinguish non HF-related causes of functional limitation, specifically cardiac versus pulmonary
- To consider whether patients are candidates for cardiac transplantation or mechanical circulatory support
- To determine the prescription for cardiac rehabilitation
- Values of peak oxygen consumption of less than 50% of predicted or less than 14 cc/kg/min reflect poor cardiac performance and a likelihood of 1-year survival less than 50%, facilitating referral for cardiac transplantation or mechanical circulatory device placement.

Medical Care Approach Considerations

Medical care for heart failure (HF) includes a number of nonpharmacologic, pharmacologic, and invasive strategies to limit and reverse the manifestations of heart failure. Depending on the severity of illness, nonpharmacologic therapies include dietary sodium and fluid restriction; physical activity as appropriate; and attention to weight gain. Pharmacologic therapies include the use of diuretics, vasodilators, inotropic agents, anticoagulants, beta-blockers, and digoxin (Table 8.11).

Table 8.11: Initial management for AHFS

1. Treat immediate life-threatening conditions/stabilize patient	Life-saving measures may precede or parallel diagnostic evaluation (i.e. unstable arrhythmia, flash pulmonary edema, STEMI)
2. Establish the diagnosis	Based on medical history, signs (JVP, S3, edema), symptoms (dyspnea), biomarkers (e.g. BNP) and CXR
3. Determine clinical profile and begin initial treatment	Key components include HR, BP, JVP, presence of pulmonary congestion, ECG, CXR, renal function, troponin, BNP, pulse oximetry, history of CAD
4. Determine and manage the cause or precipitant	Such as ischemia, hypertension, arrhythmias, acute valvular pathologies, worsening renal function, uncontrolled diabetes, and/or infectious etiologies is critical to ensure maximal benefits from HF management
5. Alleviate symptoms (e.g. dyspnea)	Usually a diuretic with or without other vasoactive agents. Morphine may also be used for pulmonary edema
6. Protect/preserve myocardium and renal function	Avoid hypotension or increase in HR, particularly in patients with CAD. Use of inotropes should be restricted to those with low-output state (low BP with organ hypoperfusion)
7. Make disposition	Majority are admitted to telemetry, with a small number discharged home. Robust evidence to support risk stratification and disposition identifying the low-risk patient for safe discharge with close outpatient follow-up is lacking

CXR=chest X-ray; ECG=electrocardiogram; HR=heart rate; JVP=jugular venous pressure; STEMI=ST-segment elevation myocardial infarction

Invasive therapies for heart failure include electrophysiologic intervention such as cardiac resynchronization therapy (CRT), pacemakers, and implantable cardioverter-defibrillators (ICDs); revascularization procedures such as coronary artery bypass grafting (CABG) and percutaneous coronary intervention (PCI); valve replacement or repair; and ventricular restoration. When progressive end-stage heart failure occurs despite maximal medical therapy, when the prognosis is poor, and when there is no viable therapeutic alternative, the criterion standard for therapy has been heart transplantation. However, mechanical circulatory devices such as ventricular assist devices (VADs) and total artificial hearts (TAHs) can bridge the patient to transplantation; in addition, VADs are increasingly being used as permanent therapy.

Consideration of Comorbidities

Coronary Artery Disease

Patients with heart failure should be evaluated for coronary artery disease, which can lead to heart failure (*see* aetiology). Not only may this condition be the underlying cause in up to two thirds of heart failure patients with low ejection fraction, but coronary artery disease may also play a role in the progression of heart failure through mechanisms such as endothelial dysfunction, ischemia, and infarction, among others.

Patients with coronary artery disease with modestly reduced ejection fraction and angina demonstrate symptomatic and survival improvement with coronary artery bypass grafting (CABG) in studies; however, the studies did not include individuals with heart failure or those with severely reduced ejection fractions. In patients with angina and ventricular dysfunction, evaluation with coronary angiography should not be delayed (see catheterization and angiography). Noninvasive cardiac testing is not recommended in patients with significant ischemic chest pain, as revascularization is advised in these patients independent of their degree of ischemia/viability.

Although there are no reports of controlled trials evaluating heart failure without angina and their outcomes with coronary revascularization, surgical revascularization is recommended in those with significant left main stenosis and in those with extensive noninfarcted but hypoperfused and hypocontractile myocardium on noninvasive testing. In patients with heart failure and reduced left ventricular ejection fraction but without angina, it has not yet been determined whether routine evaluation of possible myocardial ischemia/viability and coronary artery disease should be performed.

For patients with heart failure from LV dysfunction without chest pain and without a history of coronary artery disease, coronary angiography may be useful in young patients to exclude congenital coronary anomalies. However, because clinical outcomes have not been shown to improve in patients without angina, coronary angiography may not be as useful in older patients for evaluating the presence of coronary artery disease. Some experts nonetheless suggest excluding coronary artery disease whenever possible, particularly in the presence of diabetes or other states associated with silent myocardial ischemia, because LV function may show improvement with revascularization.

In general, if coronary artery disease has already been excluded as the cause of abnormalities in LV function, it is not necessary to perform repeated evaluations for ischemia (invasive or noninvasive) provided the patient's clinical status has not changed to suggest the development of ischemic disease.

For more information, *see the Medscape Reference articles Primary and Secondary Prevention of Coronary Artery Disease, Risk Factors for Coronary Artery Disease, and Risk Factors for Coronary Artery Disease*.

Valvular heart disease may be the underlying aetiology or an important aggravating factor in heart failure. For more information, *see the Medscape reference article valvular surgery*.

Sleep Apnea

Sleep apnea has an increased prevalence in patients with heart failure and is associated with increased mortality due to further neurohormonal activation, although randomized, controlled data are lacking. Sleep apnea should be treated aggressively in heart failure patients.

A long-term study involving 283 heart failure patients who had an implanted cardiac resynchronization device with cardioverter-defibrillator concluded that obstructive sleep apnea (OSA) and/or central sleep apnea (CSA) are independently associated with an increased risk for ventricular arrhythmias requiring cardioverter-defibrillator therapies.

Anemia

Anemia is also common in chronic heart failure. Whether anemia is a reflection of the severity of heart failure or contributes to worsening heart failure is not clear. Potential etiologies of anemia in heart failure involve poor nutrition, ACEIs, the RAAS, inflammatory cytokines, hemodilution, and renal dysfunction. Anemia in heart failure is associated with increased mortality.

The ACC/AHA, HFSA, and ESC make no recommendations regarding the administration of iron to patients with heart failure, although the ACC/AHA noted that several small studies suggested a benefit in mild anemia and heart failure. More and larger studies are needed.

Cardiorenal Syndrome

Cardiorenal syndrome reflects advanced cardiorenal dysregulation manifested by acute heart failure, worsening renal function, and diuretic resistance. It is equally prevalent in patients with heart failure with normal ejection fraction (HFNEF) and those with LV systolic dysfunction. Worsening renal function is one of the three predictors of increased mortality in hospitalized patients with heart failure regardless of the LVEF.

Cardiorenal syndrome can be classified into the following five types:

- **CR1:** Rapid worsening of cardiac function leading to acute kidney injury (HFNEF, acute heart failure, cardiogenic shock, and RV failure)
- **CR2:** Worsening renal function due to progression of chronic heart failure
- **CR3:** Abrupt and primary worsening of kidney function leading to acute cardiac dysfunction (heart failure, arrhythmia, and ischemia)
- **CR4:** Chronic kidney disease leading to progressive cardiac dysfunction, LVH, and diastolic dysfunction
- **CR5:** Combination of cardiac and renal dysfunction due to acute and chronic systemic conditions

The pathophysiology of CR1 and CR2 is complex and multifactorial, involving neurohormonal activation (RAAS, sympathetic nervous system, arginine vasopressin, natriuretic peptides, adenosine receptor activation), low arterial pressure, and high central venous pressure, leading to lower transglomerular perfusion pressure and decreased availability of diuretics to the proximal nephron. This results in an increased reabsorption of sodium and water and poor diuretic response—hence, diuretic resistance despite escalating doses of oral or intravenous diuretics.

Treatment of cardiorenal syndrome in patients with heart failure is largely empirical, but it typically involves the use of combination diuretics, vasodilators, and inotropes as indicated ultrafiltration is recommended for symptomatic relief by the ACC/AHA guidelines for patients with heart failure that is refractory to diuretic therapy.

A sudden increase in creatinine can be seen after initiation of diuretic therapy and is often mistakenly considered evidence of overdiuresis or intravascular depletion (even in the presence of fluid overload). A common error in this situation is to decrease the dose of ACEI/ARB and/or diuretics or to even withdraw one of these agents. In fact, when diuresis or ultrafiltration is continued, patients demonstrate improved renal function, decreased total body fluid, and increased response to diuretics, as central venous pressure falls.

Low-dose dopamine has been used in combination with diuretic therapy, on the supposition that it can increase kidney perfusion. Data have been contradictory, however. In a randomized controlled study, Giamouzis et al. found that the combination of low-dose furosemide and low-dose dopamine was equally as effective as high-dose furosemide for kidney function in patients with acute decompensated heart failure. In addition, patients who received dopamine and furosemide were less likely to have worsened renal function or hypokalemia at 24 hours.

Use of nesiritide, a synthetic natriuretic peptide, to increase diuresis in these cases has not been studied. A meta-analysis of several trials using nesiritide suggests the potential of worsening renal function, although this has not been demonstrated in prospective trials. Results of the acute study of clinical effectiveness of nesiritide in decompensated heart failure (ASCEND-HF) trial suggest that, although nesiritide is safe, it does not provide additional efficacy when added to standard therapy.

The efficacy of vasopressin antagonism in heart failure outcome study with tolvaptan (EVEREST) trial showed that the addition of the vasopressin antagonist tolvaptan to diuretic therapy facilitates diuresis in acute heart failure. However, tolvaptan had no impact on mortality or hospitalizations in this setting.

Adenosine receptor antagonists have been proposed for protecting renal function in acute heart failure. However, in a double-blind, placebo-controlled trial, the adenosine A1-receptor antagonist rolofylline demonstrated no benefit for patients hospitalized for acute heart failure with impaired renal function

A meta-analysis performed by Badve et al. suggests that treatment with beta-blockers was found to reduce all-cause mortality in patients with chronic kidney disease and systolic heart failure (risk ratio, 0.72).

Atrial Fibrillation

Many patients with heart failure also have atrial fibrillation, and the two conditions can adversely affect each other. However in the AFFIRM trial, there was no difference in stroke, heart failure exacerbation, or CV mortality in patients treated with rhythm control (amiodarone) and patients treated with rate control. All of these patients require anticoagulation for stroke prevention. This can be achieved by using warfarin or a direct thrombin inhibitor (no need to follow protime).

In a prospective controlled study by Hsu et al. catheter ablation for atrial fibrillation in patients with heart failure and an LVEF of less than 45% resulted in a 21% increase in LVEF and improvement in LV dimensions, exercise capacity, symptoms, and quality of life. At a mean of 12 months, 78% of patients remained in sinus rhythm without antiarrhythmic drugs.

A meta-analysis found that patients with LV systolic dysfunction who underwent catheter ablation for atrial fibrillation demonstrated significant improvements in LVEF, and their risk for recurrent atrial fibrillation or atrial tachycardia after catheter ablation was similar to that in patients with normal LV function after ablation. However, patients with LV systolic dysfunction were more likely to require repeat procedures.

In contrast, MacDonald et al. reported that in patients with advanced heart failure and severe LV systolic dysfunction, radiofrequency ablation for persistent atrial fibrillation resulted in long-term restoration of sinus rhythm in only 50% of cases. Radiofrequency ablation also failed to improve such secondary outcomes as walking distance or quality of life, and the rate of related serious complications was 15%.

Nonpharmacologic Therapy

Patients with heart failure can benefit from attention to exercise, diet, and nutrition. Restriction of activity promotes

physical deconditioning, so physical activity should be encouraged. However, limitation of activity is appropriate during acute heart failure exacerbations and in patients with suspected myocarditis. Most patients should not participate in heavy labor or exhaustive sports (Fig. 8.62).

Dietary sodium restriction to 2–3 g/day is recommended. Fluid restriction to 2 L/day is recommended for patients with evidence of hyponatremia (Na <130 mEq/dL) and for those whose fluid status is difficult to control despite sodium restriction and the use of high-dose diuretics. Caloric supplementation is recommended for patients with evidence of cardiac cachexia.

Ultrafiltration and Refractory Heart Failure

In ultrafiltration, blood is removed from the body and run through a device that applies hydrostatic pressure across a semipermeable membrane to separate isotonic plasma water. Solutes cross the semipermeable membrane freely, so fluid can be removed without causing significant changes in the concentration of electrolytes and other solutes in serum (Fig. 8.63).

Ultrafiltration was shown to be an effective alternative to intravenous diuretics in the ultrafiltration versus intravenous (IV) diuretics for patients hospitalized for acute decompensated heart failure (UNLOAD) trial. The ACC/AHA and ESC recommend the use of ultrafiltration for fluid reduction for patients with refractory heart failure that is not responsive to medical therapy.

Indications for Hospitalization

A patient whose condition is refractory to standard therapy will often require hospitalization to receive IV diuretics, vasodilators, and inotropic agents. The 2010 Heart Failure Society of America (HFSA) guidelines recommend hospitalization for acute heart failure in the presence of the following:

- Severe acute decompensated heart failure (low blood pressure, worsening renal dysfunction, altered mentation)
- Dyspnea at rest
- Hemodynamically significant arrhythmia



Fig. 8.62: Finger photoplethsmography can measure beat to beat blood pressure, pulse, stroke volume, cardiac output and left ventricular end diastolic pressure



Fig. 8.63: Venovenous ultrafiltration technique, in patients with acute decompensated heart failure with worsening of kidney function, a condition referred to as acute cardiorenal syndrome (type 1). Diuretics are commonly used to treat persistent congestion in these patients, but these drugs might worsen kidney function. An alternative therapeutic approach is venovenous ultrafiltration, which can improve control over the rate and volume of fluid removal, increase net loss of sodium, and reduce neurohormonal activation

- Acute coronary syndrome

Hospitalization should also be considered in the presence of the following:

- Worsening congestion with or without dyspnea
- Worsening signs and symptoms of systemic or pulmonary congestion, even in the absence of weight gain
- Major electrolyte abnormalities
- Associated comorbid conditions (e.g. pneumonia, pulmonary embolism, diabetic ketoacidosis, stroke/strokelike symptoms)
- Repeat ICD firings
- New diagnosis of heart failure with signs of active systemic/pulmonary congestion.
- Most patients requiring hospitalization should be admitted to a telemetry bed or intensive care unit; a small percentage can be admitted to the floor or observation unit. The goal is to continue the diagnostic and therapeutic processes started in the office or emergency department. Treatment includes the following:
  - Volume and hemodynamic status are optimized using careful clinical monitoring, and the heart failure medical regimen is optimized.
  - Surgical intervention with a ventricular device has been considered.
  - Heart failure education, behavior modification, and exercise and diet recommendation are made.
  - Enrollment in heart failure disease management programs for patients with advanced and difficult-to-control heart failure.

Invasive hemodynamic monitoring: Invasive hemodynamic monitoring is not indicated for stable patients with heart failure responding appropriately to medical therapy. The evaluation study of congestive heart failure and

pulmonary artery catheterization effectiveness [ESCAPE] trial showed no mortality or hospitalization benefit in such cases. In patients with acute decompensated heart failure, the following are indications for invasive hemodynamic monitoring:

- Respiratory distress
- Signs of impaired perfusion
- Inability to determine intracardiac pressures on the basis of clinical examination
- No improvement in clinical status despite maximal heart failure therapy

Clinical situations in which invasive hemodynamic monitoring is recommended to guide therapy include the following:

1. Persistent symptomatic hypotension despite initial therapy
2. Worsening renal function despite initial therapy or despite adjustment of recommended therapies
3. Need for parenteral vasoactive agents after initial clinical improvement
4. Presumed cardiogenic shock requiring escalating inotrope and/or pressor therapy and consideration of mechanical support
5. Consideration of advanced device therapy or transplantation

Discharge

The patient must be on a stable oral regimen for at least 24 hours before discharge. Patients are ready for discharge when they meet the following criteria:

Exacerbating factors have been addressed:

- Volume status has been optimized
- Diuretic therapy has been successfully transitioned to oral medication, with discontinuation of IV vasodilator and inotropic therapy for at least 24 hours
- Oral chronic heart failure therapy has been achieved with stable clinical status
- Before discharge, patient and family education should be completed, and extensive postdischarge instructions and follow-up in 3–7 days should be arranged. Refractory end-stage heart failure (ACC/AHA stage D, NYHA class IV) is often difficult to manage on an outpatient basis. Therefore, these patients may be referred to a heart failure program with expertise in management of refractory heart failure
- To ensure compliance and understanding of a complex medical regimen, a follow-up phone call can be made 3 days after discharge by a nurse with training in heart failure. Ideally, the patient should be seen in clinic 7–10 days after discharge.

Different monitoring methods have been implemented by physicians in an attempt to reduce hospitalization for heart failure. The results have been equivocal, regardless of the severity of heart failure. No differences in death or hospitalization for heart failure have been found with either standard outpatient monitoring or intense telemonitoring for heart failure.



Fig. 8.64: Continuous left atrial pessure monitoring in CHF patients recently published study that analyzed the clinical benefits of frequent and regular left atrial pressure (LAP) monitoring in patients with heart failure, patients wore a special device, called Heart POD, that monitored their LAP and routed the data wirelessly to their cardiologist

An investigational approach to monitoring is the use of a wireless implanted pulmonary artery pressure sensor. This device permits ambulatory monitoring and is designed to detect early-stage elevations in pulmonary artery pressure, so that appropriate medical intervention can be provided before worsening elevation leads to congestion. In a 6-month study in patients with NYHA class III heart failure, heart failure–related hospitalizations were approximately 30% lower with use of the device (Fig. 8.64).

Treatment of Heart Failure with Normal LVEF

Treatment of heart failure with normal left ventricular ejection fraction (HFNEF) is directed toward alleviating symptoms and addressing the underlying condition triggering HFNEF. Evaluation of cardiac ischemia or sleep apnea as potential precipitating factors should also be considered (Table 8.12).

There is a paucity of randomized, controlled studies addressing HFNEF. Control of blood pressure, volume, or other risk factors is the mainstay of therapy. Lifestyle modification in important and may include the following:

- Low-sodium diet
- Restricted fluid intake
- Daily measurement of weight
- Exercise
- Weight loss
- Diuretic therapy is recommended to reduce fluid retention. However, patients must be monitored carefully to avoid hypotension.
- ACEI/ARBs are used as indicated for patients with atherosclerotic disease, prior MI, diabetes mellitus, or hypertension. Use of candesartan, irbesartan, or perindopril has not been shown to decrease mortality but has

Table 8.12: Stepwise approach: evaluation and therapy of decompensated heart failure

Stablize acute stiuation
• Brief assessment/examination • Oxygenation – assess, treat with O_2 • Blood pressure/peripheral perfusion
Assess volume status/Diagnosis
• History and physical exam • noninvasive testing - (+ Review records) • Invasive testing - (+ Review Records)
Therapy
• Correct/reverse precipitating cause • Oxygen • Diuretics • Morphine sulphate (low dose) for central effect • Vasodilators • Inotropic agents • Mechanical assist devices complete diagnostic evaluation if new onset heart failure

produced a trend toward improved morbidity and decreased hospitalizations. Some evidence shows that losartan and valsartan may promote LV reverse remodeling, with improvement in diastolic function and regression of left ventricular hypertrophy (LVH).

- Beta-blockers are indicated for patients with prior MI or hypertension and for control of ventricular rate in those with atrial fibrillation. In the ADHERE registry, the subset of patients with HFNEF not treated with a beta-blocker had a higher mortality, potentially because of the higher incidence of coronary artery disease (CAD) in this population.
- Aldosterone receptor blockers are indicated for hypertension and to reduce myocardial fibrosis, although no randomized, controlled studies have been performed to evaluate their role in HFNEF. Calcium channel blockers may improve exercise tolerance via their vasodilatory properties, and nondihydropyridine calcium channel blockers are also used for ventricular rate control in patients with atrial fibrillation. Amlodipine has antianginal properties and is also indicated in hypertension.
- Restoration of sinus rhythm should be considered if the patient remains symptomatic despite the above efforts. Use of digitalis or inotropes in patients with HFNEF is not indicated.

Electrophysiologic Intervention

Devices for electrophysiologic intervention in heart failure include pacemakers, cardiac resynchronization therapy (CRT) devices, and implantable cardioverter-defibrillators (ICDs) (Tables 8.13 and 8.14).

The 2010 Heart Failure Society of America (HFSA) guidelines indicate that device therapy is an integral part of the treatment of heart failure and that considerations such as the nature and severity of the condition and any patient comorbidities are essential in optimizing the use of this

Table 8.13: Use of implantable defibrillators in patients with heart failure

Class I
• Cardiac arrest due to ventricular fibrillation (VF) or ventricular tachycardia (VT) not due to transient or reversible cause • Sportaneous sustained VT in association with structural heart disease • Syncope of undetermined origin with clinically relevant sustained VT or VF induced at electrophysiological study • Nonsustained VT with coronary artery disease, prior myocardial infraction and inducible • Nonsuppressible VT
Class IIa
• Left ventricular ejection fraction less than or equal to 30%, at least 1 month following myocardial infraction and 3 months after surgical revascularization NB
Class IIb
• Cardiac arrest presumed to be due to VF when electrophysiologic testing is precluded by other medical conditions. Severe symptoms, such as syncope, in patients awaiting cardiac transplantation. Nonsustained VT with sustained VT at electrophysiologic study in patients with ischemic heart disease • Recurrent syncope of undetermined aetiology in the presence of ventricular dysfunction.
Class III-contraindicated
• Increscent VT or VF (ICD may be indicated after arrhythmia control) • VT or VF due to a transient or reversible condition • Projected life expectancy less than 6 months • Significant psychiatric illness that may be aggravated by device implantation or that may preclude device follow-up • NYHA class IV heart failure in patinets who are not candidates for cardiac transplantation

therapy. The Committee for Practice Guidelines (CPG) of the European Society of Cardiology (ESC) and the ACC/AHA/Heart Rhythm Society (HRS) emphasized the importance of medical devices in heart failure in their respective 2010 and 2012 focused updates on these interventions.

In addition, the AHA has published guidelines on heart device strategies, patient selection, and postoperative care. The guidance focuses on risk stratification and early referral of high-risk patients with heart failure to centers that can implant mechanical circulatory support devices (MCS).

Pacemakers

Maintaining a normal chronotropic response and AV synchrony may be particularly significant for patients with heart failure. Because RV pacing may worsen heart failure due to an increase in ventricular dysynchrony, the current 2010 HFSA practice guidelines recommend against placement of a dual-chamber pacemaker in heart failure patients in the absence of symptomatic bradycardia or high-degree AV block.

Table 8.14: Interventional therapies for heart failure—established and investigational

- Revascularization-percutaneous/surgical
- Correction of structural pathology
- Ablation-therapeutic
- Cardiac re-synchronization (± ICD)
- Cardiac contractility modulation through non-excitatory electrical signal*
- Ventricular wall stress reduction therapy
  - Batista (partial ventriculectomy)
  - Dor (infarct exclusion, surgical ventricular restoration)
  - Device (myosplint*, Cardioclasp*)
- Cardiomyoplasty
  - Dynamic-tissue/device *
  - Static-device (Cor Cap, Acorn)*
- Ultrafiltration-Hemofiltration
- Descending aortic flow augmentation (Orqis Cancion System)*
- Immuno-modulatory therapy (Vasogen, Inc).
- Ventricular Assist Devices
  - Balloon counterpulsation
  - Pulsatile
  - Axial flow
- Total artificial heart
- Transplantation (Allograft, Cellular*)

The ACC/AHA heart failure guidelines recommend consideration of cardiac resynchronization therapy (CRT) for patients with heart failure who have indications for permanent pacing (e.g. first implant, upgrading of a conventional pacemaker) and NYHA class III-IV symptoms or those who have an LVEF less than 35% despite being on optimal heart failure therapy and who may have a dependence on RV pacing. These recommendations now also include patients with NYHA class II symptoms and the presence of left-bundle-branch block with a QRS duration that is greater than or equal to 150 ms.

Implantable cardioverter-defibrillators (Fig. 8.65)

- The role of the ICD has rapidly expanded. Sudden death is 5–10 times more common in patients with heart failure than in the general population. ICD placement results in remarkable reductions in sudden death from ischemic and nonischemic sustained ventricular tachyarrhythmias in heart failure patients. Consequently, current AHA/ACC guidelines recommend an ICD in virtually all patients with an LVEF of less than 35%.
- The AHA/ACC and ESC recommend ICD placement for the following categories of heart failure patients.
- Patients with LV dysfunction (LVEF=35%) from a previous MI who are at least 40 days post-MI.
- Patients with nonischemic cardiomyopathy; with an LVEF of 35% or less; in NYHA class II or III; receiving optimal medical therapy; and expected to survive longer than 1 year with good functional status.
- Patients with ischemic cardiomyopathy who are at least 40 days post-MI; have an LVEF of 30% or less; are in NYHA functional class I; are on chronic optimal medical therapy; and are expected to survive longer than 1 year with good functional status.
- Patients who have had ventricular fibrillation (VF).
- Patients with documented hemodynamically unstable ventricular tachycardia (VT) and/or VT with syncope; with an LVEF less than 40%; on optimal medical therapy; and expected to survive longer than 1 year with good functional status.
- In moderately symptomatic heart failure patients with an LVEF of 35% or less, primary prevention with an ICD provides no benefit in some cases but substantial benefit in others. A model based on routinely collected clinical variables can be used to predict the benefit of ICD treatment, according to a study by Levy et al. Using data from the placebo arm of the sudden cardiac death in heart failure trial (SCD-HeFT) with their risk prediction model, Levy et al. showed that patients could be classified into 5 groups on the basis of predicted 4-year mortality. In the treatment arm, ICD implantation decreased relative risk of sudden cardiac death by 88% in patients with the lowest baseline mortality risk but only by 24% in the highest-risk group. ICD treatment decreased relative risk of total mortality by 54% in the lowest-risk group but only by 2% in the highest-risk group.
- It is important to note that use of the SCD-HeFT model has not been prospectively validated for risk stratification in the decision for ICD implantation. More trials are needed.

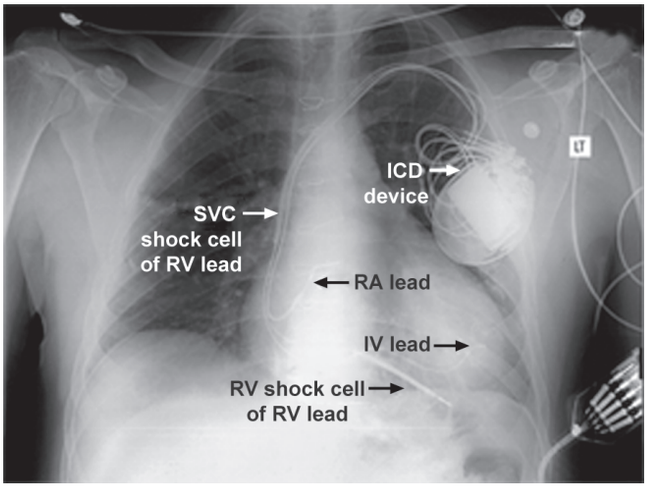

Fig. 8.65: X-ray chest showing ICD device fitted in a patient with cardiac arrhythmias and heart failure

Cardiac resynchronization therapy/biventricular pacing: Patients with heart failure and interventricular conduction abnormalities (roughly defined as those with a QRS interval >120 ms) are potential candidates for CRT by means of an inserted biventricular pacemaker. CRT aims to improve cardiac performance by restoring the heart's interventricular septal electrical and mechanical synchrony. Thus, it reduces presystolic mitral regurgitation and optimizes diastolic function by reducing the mismatch between cardiac contractility and energy expenditure (Fig 8.66).

The ACC/AHA guidelines recommend resynchronization therapy for patients in sinus rhythm or atrial

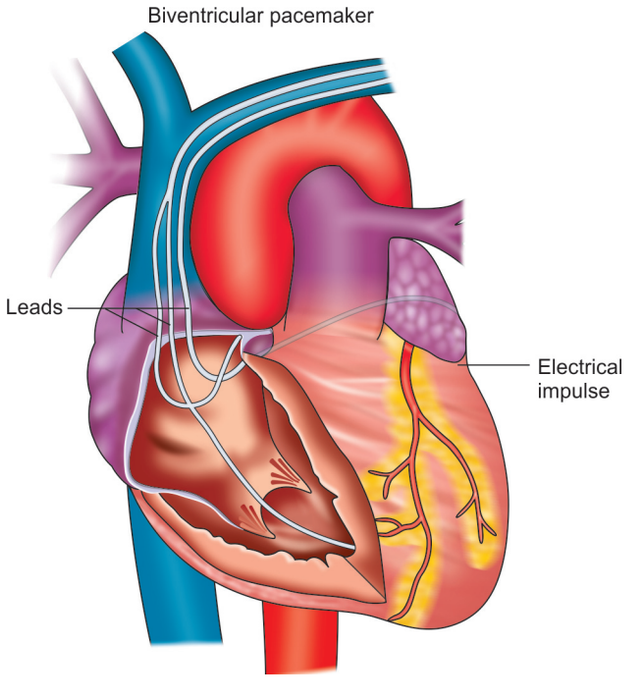

Fig. 8.66: Cardiac resynchronization therapy (CRT), also called biventricular pacing, uses a special kind of pacemaker, called a biventricular pacemaker, designed to help the ventricles contract more normally. It keeps the right and left ventricles pumping together by sending small electrical impulses through the leads. This therapy has been shown to improve the symptoms of heart failure and overall quality of life in certain patients with severe symptoms that are not controlled with medication

fibrillation with a QRS duration of 120 ms or longer (the greatest benefit is in patients with a QRS >150 ms) and an LVEF of 35% or less with persistent, moderate-to-severe heart failure (NYHA class III and functional NYHA class IV) despite optimal medical therapy. A 2012 update of ACC/AHA/HRS guidelines on CRT expanded Class I indications to patients with NYHA class II symptoms and left-bundle-branch block of =150 ms.

Biventricular pacing may also be considered in the following patients (Figs 8.68–8.70)

- Patients with reduced LVEF and a 2QRS of 150 ms or longer who have NYHA I or II symptoms.
- Patients with reduced LVEF who require chronic pacing and in whom frequent ventricular pacing is expected.

  The combination of biventricular pacing with ICD implantation (CRT-ICD) may be beneficial for patients with class II heart failure, an LVEF of 30% or less, and QRS duration of more than 150 ms. The MADIT-CRT and resynchronization/defibrillation for ambulatory heart failure trial (RAFT) investigators reported significant improvement in mortality and morbidity with CRT-ICD treatment versus ICD alone in this group of patients.
- Patients with unfavorable coronary sinus anatomy often cannot have a CRT properly placed adjacent to the posterolateral wall of the LV. A study by Giraldi et al. suggests that in such patients, a mini-thoracotomy allows for proper lead placement. These patients, when compared with patients who had typical transvenous placement (thus not allowing for preferred posterolateral

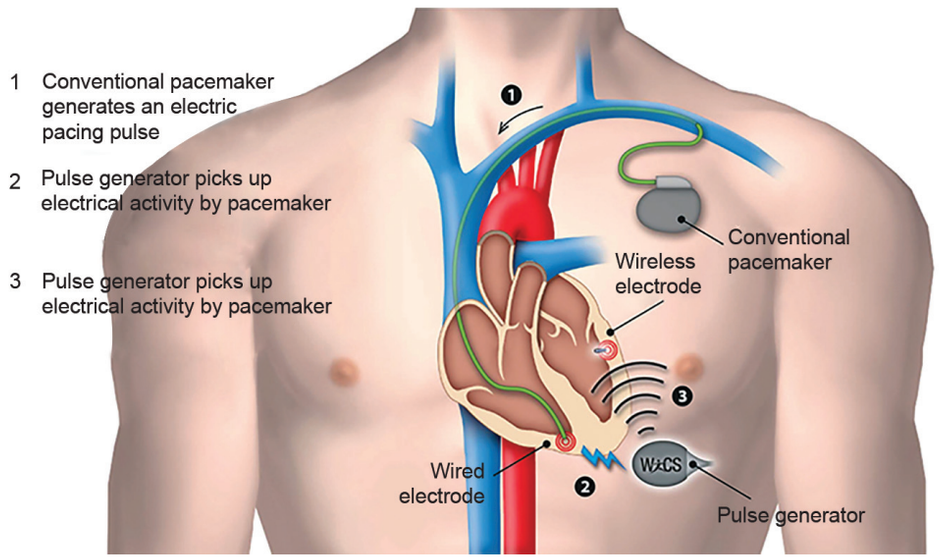

Fig. 8.67: Leadless pacemaker. The wireless cardiac stimulation system (WiCS) comprises two units, an implantable electrode and an external control unit. The electrode incorporates an ultrasonic, wireless receiver and delivers an electrical stimulus to the heart based on triggering signals from the external control unit. In its current iteration the WiCS system is designed to work with conventional pacemakers/defibrillators pacing the right ventricle of patients requiring biventricular pacing. The WiCS external control unit senses the pacing stimulus delivered to the right ventricle and initiates a burst of stimulus from the electrode implanted in the left ventricle. According to the company, the wireless left ventricular pacing approach removes the need for complex surgery and the complications often associated with the coronary sinus leads used to pace the left ventricle

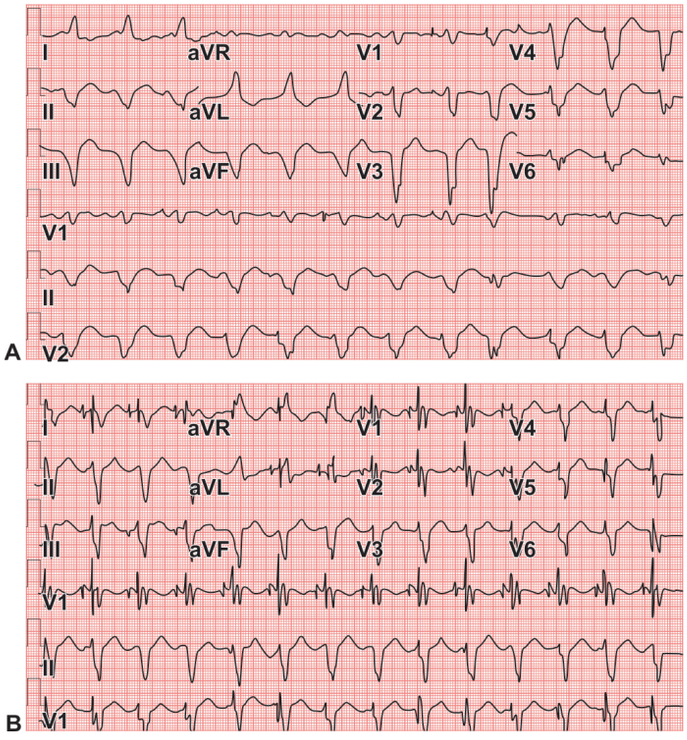

Fig. 8.68: Electrocardiogram (ECG) changes with (A) right ventricular (RV) and biventricular pacing 12-lead ECG from a patient with cardiomyopathy during RV apical pacing, and (B) biventricular (BiV) pacing cardiac resynchronization therapy (CRT) with alteration in the QRS duration and axis. Typically, a left bundle branch block pattern is observed in the presence of RV pacing, whereas a right bundle branch block pattern dominates when the left ventricular (LV) is also paced. Pacing from the RV apex is further identified by a superior axis in inferior leads (negative QRS in II, III, aVF)

wall lead placement), had improved outcomes in terms of improved EF and decreased end-systolic volume.

Regarding technique, three cardiac leads are placed transvenously: an atrial lead; an RV lead; and an LV lead, which is threaded through the coronary sinus and out one of its lateral wall tributaries. Surgeons have assisted difficult transvenous LV placements by epicardially inserting LV leads using a number of techniques (e.g. mini-thoracotomy, thoracoscopy, robotically assisted methods).

Studies of medical versus surgical therapy for CAD have historically focused on patients with normal LV function.

However, a significantly increased survival rate after coronary artery bypass surgery in a subset of patients with an LVEF of less than 50%, in comparison with the survival rate in patients who were randomly selected to receive medical therapy, was demonstrated in the veterans affairs cooperative study of surgery. This survival benefit was particularly evident at the 11-year follow-up point (50% vs 38%). Surgical revascularization prolonged survival to a greater degree than did medical therapy in most clinical and angiographic subgroups in the coronary artery surgery study (CASS) of patients with left main equivalent disease. Of importance, this study demonstrated that surgical therapy markedly improved the 5-year cumulative survival rate in patients with an EF of less than 50% (80% *vs* 47%) These early randomized trials were limited by their inclusion of patients who had what is currently considered a good EF. That is, many patients referred for coronary revascularization live with EFs of less than 35%.

Coronary Artery Bypass Grafting

The role of CABG in patients with CAD and heart failure has been unclear. Clinical trials from the 1970s that established the benefit of CABG for patients with CAD excluded patients with an EF of less than 35%. In addition, major advances in medical therapy and cardiac surgery have taken place since these trials (Fig. 8.70).

Investigators from Yale and the University of Virginia, among many others, have published their results of CABG in patients with extremely poor LV function who were on the transplant waiting list. Elefteriades et al. reported that in patients with EFs of less than 30% who had CABG, the survival rate was 80% at 4.5 years. This figure approaches that of cardiac transplantation. Kron et al. reported a similar 3-year survival rate, of 83%, in patients who underwent coronary artery bypass with an EF of less than 20%.

STICH Trial

The surgical treatment for ischemic heart failure (STICH) study found no significant difference between medical therapy alone and medical therapy plus CABG with respect to death from any cause (the primary study outcome). STICH included 1212 patients with an EF of 35% or less and CAD amenable to CABG. Patients were randomized to either CABG with intensive medical therapy or medical therapy alone and followed up for a median of 56 months.

There was no difference between the treatment groups for all-cause mortality. Owing to the lack of significant difference in the primary endpoint, the secondary endpoints should be viewed cautiously. Except for 30-day mortality, secondary study results favored CABG; compared with study patients assigned to medical therapy alone, patients assigned to CABG had lower rates of death from cardiovascular causes and of death from any cause or hospitalization for cardiovascular causes. Surprisingly, the presence of viable, hibernating myocardium was not predictive of improved outcomes from CABG.

Taken together, these findings suggest that in the absence of severe angina or left main disease, medical therapy alone remains a reasonable option for patients with an EF of 35% or less and CAD. Furthermore, current methods of assessing myocardial viability/hibernating myocardium may not accurately predict benefit from revascularization, although cardiac magnetic resonance imaging offers a promise of accuracy in identifying viable myocardium and predicting the success of revascularization in patients with low EFs.

The adoption of techniques on and off cardiopulmonary bypass, as well as beating-heart techniques for revascularization, highlight the aim of treating high-risk patients. The surgery in the STICH trial was performed with these

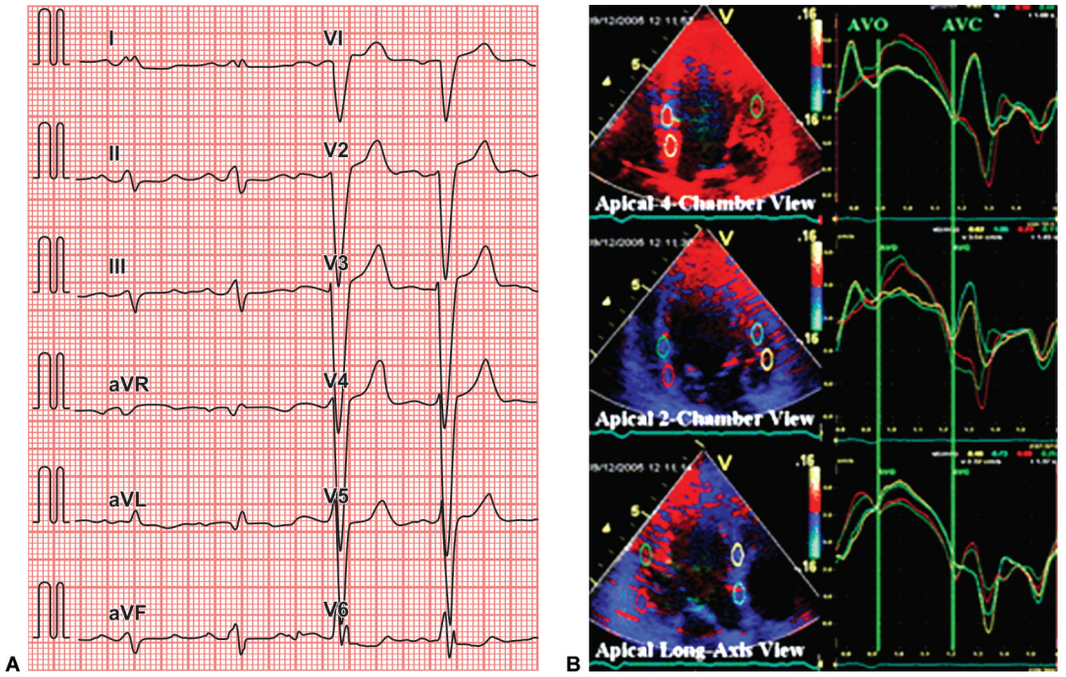

Fig. 8.69: (A) A 12-lead electrocardiogram before cardiac resynchronization therapy (CRT), demonstrating a QRS width of 160 ms with a left bundle branch block. (B) Longitudinal dyssynchrony by myocardial velocity before cardiac resynchronization therapy was as follows: 23 ms in Yu index and 35 ms in opposing wall delay, indicating no longitudinal dyssynchrony. AVO=aortic valve opening; AVC=aortic valve closure. Apical four-chamber view: yellow, basal-interior septum; blue, mid-inferior septum; red, basal-lateral; green, mid-lateral. Apical two-chamber view: yellow, basal-anterior; blue, mid-anterior; red, basal-inferior; green, mid-inferior. Apical long-axis view: yellow, basal-anterior septum; blue, mid-anterior septum; red, basal-posterior; green, mid-posterior

modern surgical advantages. Preventive strategies include the increased use of bilateral mammary and arterial grafting.

Valvular Surgery

Valvular heart disease may be the underlying aetiology or an important aggravating factor in heart failure.The ACC/AHA recommends that valve repair or replacement in patients with hemodynamically significant valvular stenosis or regurgitation and asymptomatic heart failure should be based on contemporary guidelines. In addition, the ACC/AHA indicates that such surgery should be considered for patients with severe aortic or mitral valve stenosis or regurgitation, even when ventricular function is impaired (Figs 8.71 and 8.72).

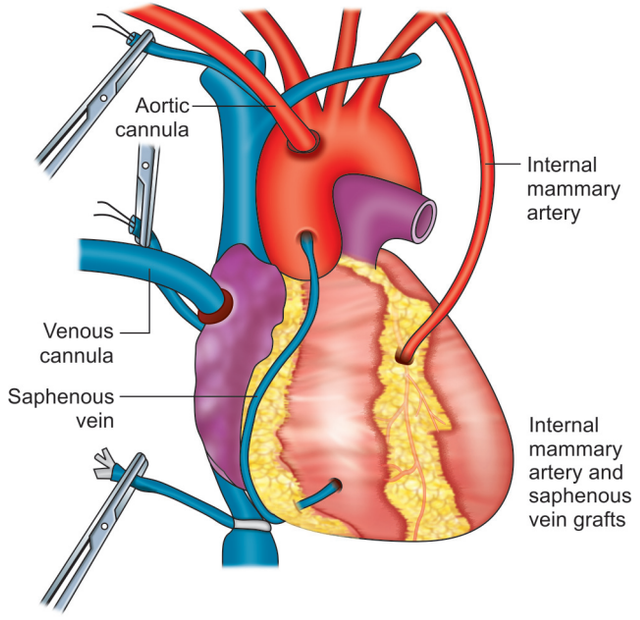

Fig. 8.70: Coronary artery bypass grafting in an elderly patient with severe triple vessels coronary artery disease with heart failure



Fig. 8.71: A 7-year-old child who had juvenile rheumatic mitral stenosis (MVA <2.0 cm^2) with severe MR (grade III–IV) enlarged LA with PAH and exertional dyspnea and showed early signs of heart failure. He is advised minimal invasive surgery

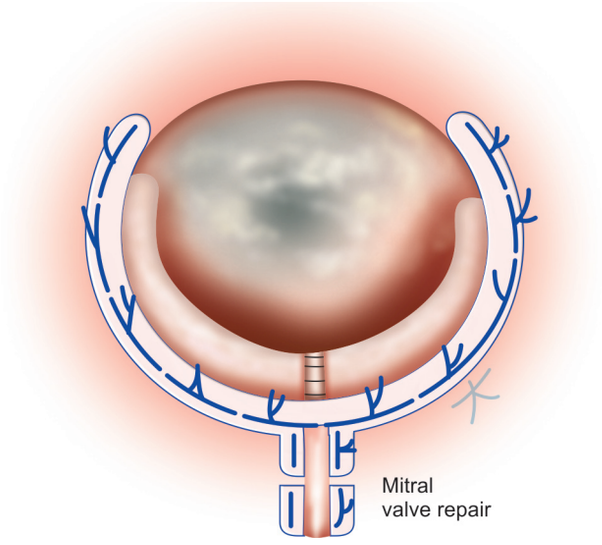

Fig. 8.72: Annuloplasty—complete repair of the damaged valve in the mitral valve apparatus

The ESC notes that although impaired LVEF is an important risk factor for higher perioperative and postoperative mortality, surgery may be considered in symptomatic patients with poor LV function. However, it is essential that optimal conservative management of the patient's heart failure and any comorbidities be undertaken before surgery, with a thorough clinical and echocardiographic assessment that focuses on cardiovascular and noncardiovascular comorbidities.

Aortic Valve Replacement

Diseases of the aortic valve can frequently lead to the onset and progression of heart failure. Although the natural histories of aortic stenosis and aortic regurgitation are well known, patients are often followed up conservatively after they present with clinically significant heart failure.

Heart failure is a common indication for aortic valve replacement (AVR), but one must be cautious in patients with a low LVEF and possible aortic stenosis (Figs 8.73 and 8.74).

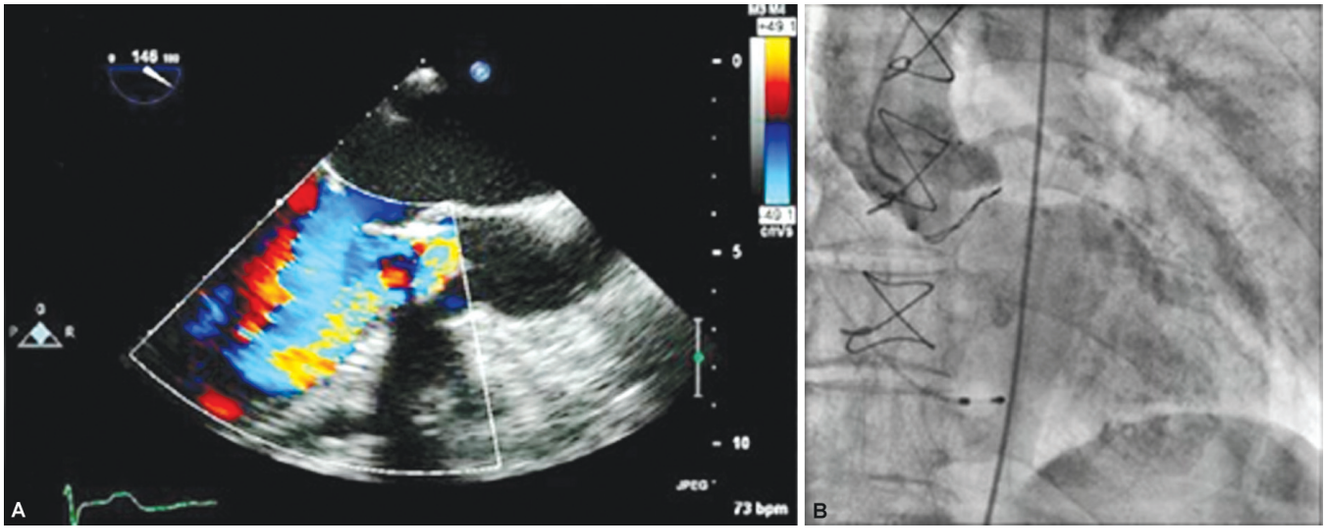

Fig. 8.73: (A) Aortic regurgitation documented by transesophageal echocardiography, and (B) aortography. The patient was referred for aortic valve replacement surgery for worsening of LV functions

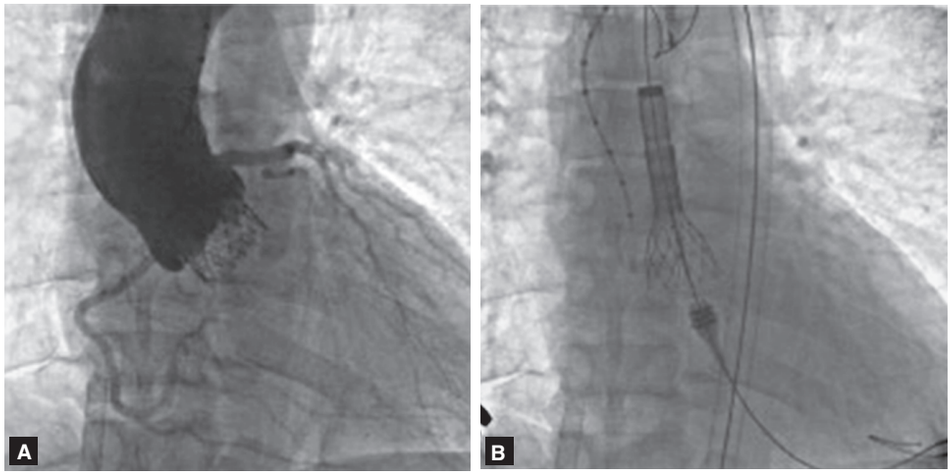

Fig. 8.74: (A) Controlled expansion of the aortic prosthesis. (B) Angiogram after successful implantation of aortic valve in an elderly patient with severe aortic stenosis and AR with heart failure

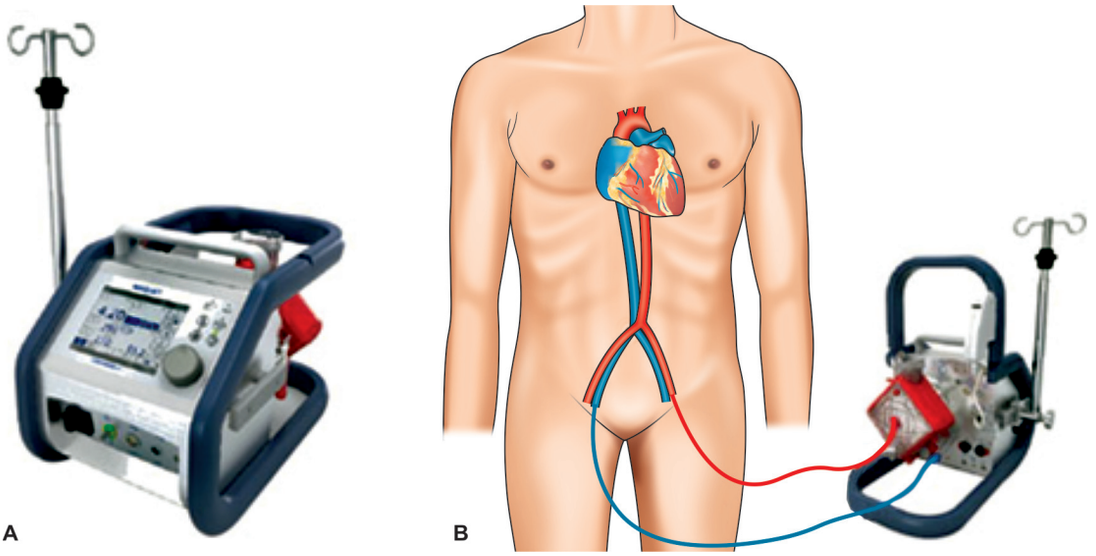

Fig. 8.75: (A) The device is compact and easily portable, with a total weight of only 9 kg. (B) Veno-arterial extracorporeal membrane oxygenation (ECMO) is established by cannulation of a femoral vein and artery using the Seldinger technique. To expedite interhospital transfer these vessels can be located with guidewires before arrival of the outreach team. The cannulas can then be inserted rapidly to begin ECMO before transport by air or ground ambulance. Images of the Cardiohelp® device courtesy of Maquet Cardiopulmonary AG©

Extracorporeal Membrane Oxygenation

In some cases of extreme cardiopulmonary failure (i.e. ACC/AHA stage D), the only recourse is complete support with extracorporeal membrane oxygenation (ECMO) (Fig. 8.75). ECMO provides both oxygenation and circulation of blood, allowing the lungs and heart time to recover. Unlike cardiopulmonary bypass, whose duration of use is measured in hours, ECMO can be used for 3–10 days.

For ECMO, one cannula is placed percutaneously via the right jugular vein or femoral vein into the right atrium, or it is placed surgically into the right atrial appendage, and another cannula is placed arterially either in the femoral artery or in the aortic arch. The drained venous blood is pumped through the ECMO device, where it is oxygenated, warmed, and anticoagulated. It is then returned to the arterial circulation.

ECMO devices can be used for short-term circulatory support in patients who are expected to recover from a major cardiac insult. Despite encouraging results with ECMO for the management of cardiogenic shock, most patients requiring circulatory assistance can be helped with ventricular support alone.

Ventricular Assist Devices

Ventricular assist devices (VADs) are invaluable tools in the treatment of heart failure. A number of these devices are available to support the acutely or chronically decompensated heart (i.e. ACC/AHA stage D). Depending on the particular device used, the right ventricle and left ventricle can be assisted with a left ventricular assist device (LVAD), a right VAD (RVAD), or a biventricular assist device (BiVAD). An alternative term for a VAD is a ventricular assist system (VAS) (Figs 8.76 and 8.77).



Fig. 8.76: Excor pediatric heart pump for treating shock conitions in children

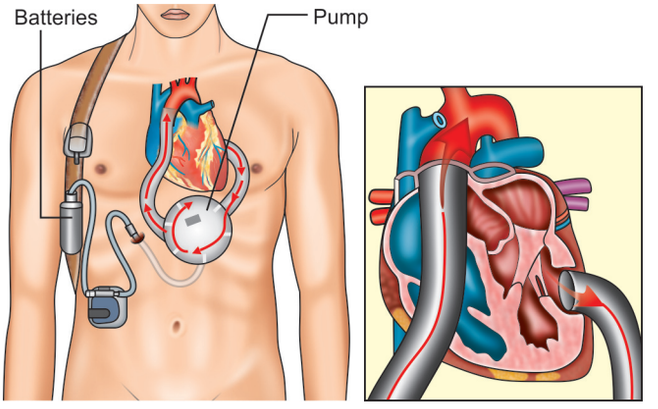

Fig. 8.77: VADs which are used for people with end-stage refractory congestive heart failure that has not responded to medicine. In the heart, the left ventricle does most of the work. It is usually the chamber that fails first. VADs can be used to support the left ventricle, right ventricle, or both. Getting a VAD is a way to improve the heart's ability to pump without having a heart transplant

In concept, LVADs, RVADs, and BiVADs are similar. Blood is removed from the failing ventricle and diverted into a pump that delivers blood to either the aorta (in the case of an LVAD) or the pulmonary artery (in the case of an RVAD). An exception is the Impella (Abiomed, Inc). This device is inserted percutaneously into the left ventricle; it draws blood from the left ventricle and expels it into the ascending aorta.

LVADs can often be placed temporarily. In patients with acute, severe myocarditis or those who have undergone cardiotomy, this approach can serve as a bridge to recovery, unloading the dysfunctional heart and perhaps allowing reverse remodeling; in patients with end-stage heart failure, it can serve as a bridge to heart transplantation, allowing them to undergo rehabilitation and possibly go home before transplantation.

Long-term use (i.e. destination therapy rather than bridge therapy) may be a consideration when no definitive procedure is planned. Patients with severe heart failure who are not transplant candidates and who otherwise would die without treatment are candidates for lifetime use of VADs. Destination therapy with LVADs is superior to medical therapy in terms of quantity and quality of life, according to the randomized evaluation of mechanical assistance for the treatment of congestive heart failure (REMATCH) trial and several later studies. In the United States, several Food and Drug Administration (FDA) approved options are available for bridging the patient to recovery and transplantation. These options continue to change and evolve. Some examples include are as follows.

Recommendations for clinical management of continuous-flow LVAD were published in 2010, assisting providers with standardized care for this patient population. Bleeding, infection, and stroke are postimplant complications, and death may occur due to right heart failure, sepsis, or stroke. A multidisciplinary approach to LVAD implantation is needed, as destination therapy identifies patients at high risk for complications and the need to optimize these patients medically before surgery. In a recent report from INTERMACS, 1-year survival for destination-therapy patients was 61% for pulsatile devices and 74% for continuous-flow devices.

Heart Transplantation

Selected patients with severe heart failure, debilitating refractory angina, ventricular arrhythmia, or congenital heart disease that cannot be controlled despite pharmacologic, medical device, or alternative surgical therapy should be evaluated for heart transplantation. The patient must be well informed, motivated, and emotionally stable; have a good social support network; and be capable of complying with intensive medical treatment (Figs 8.78 and 8.79).

Since Christiaan Barnard performed the first orthotopic heart transplantation in 1967, the world has seen tremendous advancement in the field of cardiac transplantation. For patients with progressive end-stage heart failure despite maximal medical therapy who have a poor prognosis and no viable alternative form of treatment, heart transplantation has become the criterion standard for therapy.

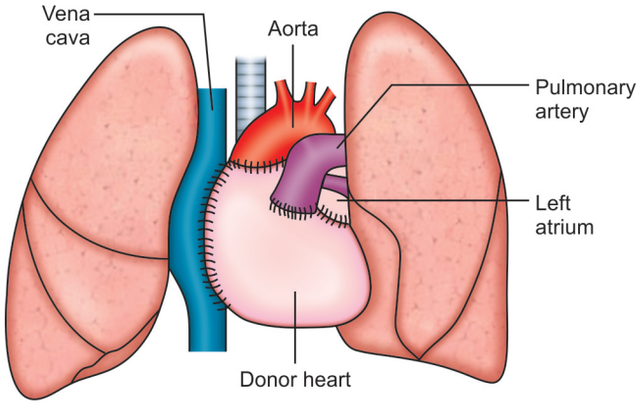

Fig. 8.78: Diagram illustrating the placement of a donor heart in an orthotopic procedure. Notice how the back of the patient's left atrium and great vessels are left in place

Compared with patients who receive only medical therapy, transplant recipients have fewer rehospitalizations; marked functional improvements; enhanced quality of life; more gainful employment; and longer survival, with 50% surviving 10 years postoperatively (heart transplantation is associated with a 1 year survival rate of 83%; subsequently, survival decreases in a linear manner by approximately 3.4% per year).

Careful selection of donors and recipients is critical for ensuring good outcomes. In addition, transplant teams must strive to minimize potential perioperative dangers, including ischemic times, pulmonary hypertension, mechanical support, and cardiogenic shock.

Indications

According to the ACC/AHA, absolute indications for heart transplantation include hemodynamic compromise following heart failure, including the following scenarios:

- Refractory cardiogenic shock
- Dependence on IV inotropic support for adequacy of organ perfusion
- Peak oxygen consumption per unit time (VO_2) less than 10 ml/kg/min
- Severe ischemic symptoms with consistent limitations of routine activity that are not amenable to revascularization procedures (CABG, percutaneous coronary intervention)
- Recurrent symptomatic ventricular arrhythmias despite all therapeutic interventions
- Relative indications for heart transplantation include the following:
  - Peak VO_2 between 11 and 14 ml/kg/min (or 55% of predicted) with major limitation of routine activities
  - Recurrent unstable ischemia that is not amenable to other treatment
  - Recurrent instability of fluid balance/renal function despite patient compliance with medical therapy

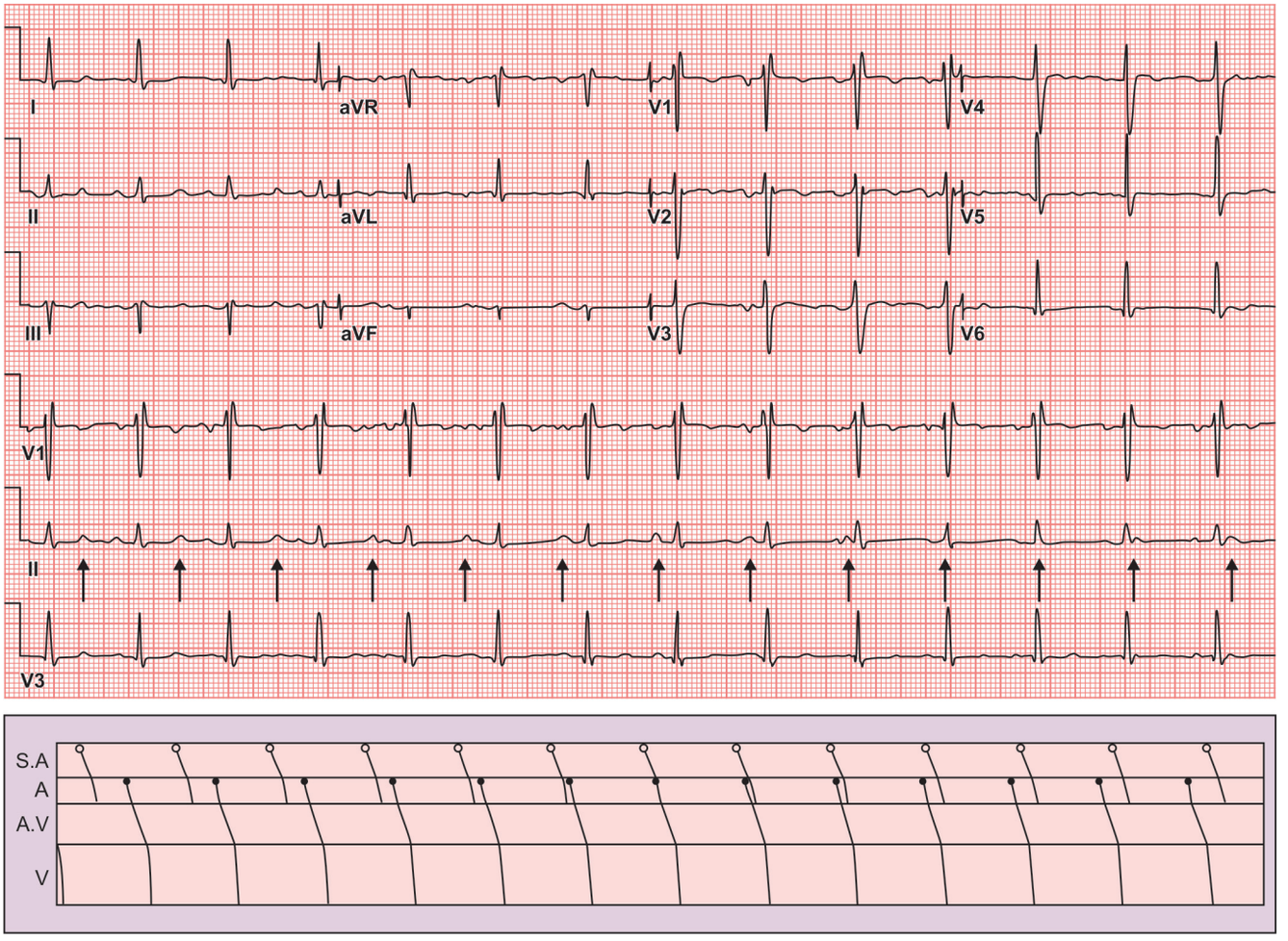

Fig. 8.79: ECG of orthotopic heart transplant. Recipient P-waves (arrows)

- In the absence of other indications, however, the following are not sufficient indications for heart transplantation:
  - Low LVEF
  - History of NYHA class III/IV heart failure symptoms
  - Peak VO_2 >15 ml/kg/min (and >55% predicted)

Contraindications

The ESC indicates that heart transplantation is contraindicated in patients with the following conditions.

- Current alcohol and/or drug abuse
- Lack of compliance
- Uncontrolled or mental health disease
- Active malignancy
- Multiorgan systemic disease
- Active infection except for LVAD infection
- Significant renal failure (creatinine clearance <50 ml/min), significant hepatic dysfunction, or pulmonary disease (FEV1 <50% of predicted or <1 L)
- Irreversible high pulmonary vascular resistance (6–8 wood units and mean transpulmonary gradient >15 mmHg)
- Recent thromboembolic complications
- Unhealed peptic ulcer
- Other serious comorbidity with a poor prognosis
- Note that the HFSA and ESC indicate that cardiomyoplasty and partial left ventriculectomy (Batista operation) is not recommended to treat heart failure, nor should it be used as an alternative to heart transplantation.

Coronary Graft Atherosclerosis

The Achilles heel of the long-term success of heart transplantation is the development of coronary graft atherosclerosis, the cardiac version of chronic rejection. Coronary graft atherosclerosis is uniquely different from typical coronary artery disease in that it is diffuse and is usually not amenable to revascularization.

Shortage of Donor Hearts

In the United States, fewer than 2500 heart transplantation procedures are performed annually. Each year, an estimated 10–20% of patients die while awaiting a heart transplant. Of the 5 million people with heart failure, approximately 30,000–100,000 have such advanced disease that they would benefit from transplantation or

mechanical circulatory support. This disparity between the number of patients needing transplants and the availability of heart donors has refocused efforts to find other ways to support severely failing hearts.

Cell Replacement Strategy

Cell replacement strategy is a new era in therapy for patients with myocardial dysfunction (Fig. 8.80). It has been postulated that therapies directly targeted at replacing or regenerating damaged myocardial tissue could prevent progression to heart failure and therefore would be an important contribution to the treatment of ischemic damage to the myocardium. Many cell types have been successfully transplanted into damaged myocardium, including fetal cardiomyocytes, skeletal myoblasts, embryonic stem cells, and bone marrow-derived stem cells. The best characterized of these is skeletal myoblast, an immature muscle cell that retains the ability to proliferate. Several studies have used human autologous skeletal myoblasts transplantation to determine if engraftment of these cells leads to long-term improvements in left ventricle function. However, these exciting progresses have many unanswered questions including potential arrhythmic and oncogenic potential of these cells, which can only be resolved by larger clinical trials with long-term follow-up.

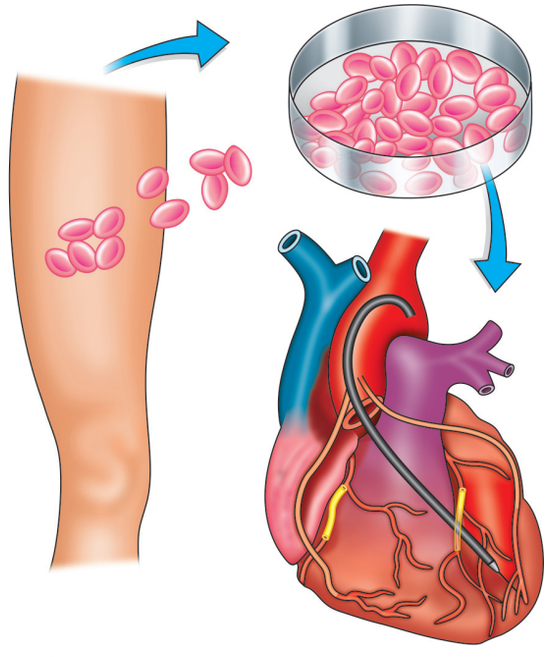

Fig. 8.80: Diagrammatic depiction of myogenesis in the heart muscle. Myoblasts are super powerhouse cells that originate from human body's muscle stem cells. These cells have the ability to take on the properties of the other cells such as cardiac muscle cells that make up the heart. Unlike cardiac muscle myoblasts can regenerate and repair themselves. The myoblasts can be transplanted from the skeletal muscles into heart and can stimulate myogenesis. A biopsy of muscle cells from patient thigh is taken and isolated and expanded in culture in a special cell laboratory for 3 weeks. These multiple cells are injected directly into the areas of heart where the muscle is damaged

Other Modes of Management

Maintain infant's temperature in euthermic range

Posture: A patient in CHF has cardiomegaly and congested lungs. Both diminish the volume available for air exchange. In addition hepatomegaly will limit diaphragmatic excursion in recumbent posture so keep the patient in a suitable chair in inclined posture.

Oxygen administration: If there is respiratory distress, pulmonary venous desaturation is pronounced, so increase inspired oxygen concentration will benefit the patient.

Sedation: Restlessness is very common in patients with CHF which raises oxygen demands. Sedation with chloral hydrate is useful in infants and children. Morphine is the sedative of choice in acutely ill patient and in postoperative period when pain is an additional factor.

In the second 24 hours: If the patient has good diuresis, respiratory distress has lessened and heart rate has slowed down, maintenance digoxin and diuretics are switched over to the oral route. But if inotropics and preload reducers do not produce the desired effect, search for additional problem is made because digoxin has got dynamic action depending upon the pH of blood, electrolyte normality, abnormal blood sugar level and hemoglobin concentration. If child is very anemic, packed blood cells are given which increase oxygen carrying capacity. Attempt is made to maintain electrolyte balance, normal blood sugar and proper blood pH. If child has got pulmonary infection adequate antibiotic treatment is given. If inspite of above variables being normal, after load reducers are considered. Two more therapeutic principles that can be followed both in the hospital as well as at home are:

- Salt restriction should not interfere with patient's eating.
- Restriction of physical activity is not the issue in pediatrics. It may be counter productive because it increases oxygen consumption. When the baby improves, can tolerate room air and develops an appetite sufficient to gain weight-maintenance of inotropics and diuretics should be decided and further investigation for proper surgical management should be carried out.

Vasopeptidase Inhibitors

Neutral peptidase is an enzyme that inactivates several of the peptides like atrial natriuretic peptide, brain type natriuretic peptide, bradykinin and adrenomedullin. These peptides have vasodilator, natriuretic and antiproliferative properties. Simultaneous inhibition of neutral peptidase and angiotensin converting enzyme markedly reduces vasoconstriction, improves sodium and water balance, decrease peripheral vascular resistance and blood pressure and improves local blood flow when compared with angiotensin converting enzyme inhibition alone.

The only available vasopeptidase inhibitor that has been evaluated in adults with heart failure is omapatrilat, which

is not yet recommended for use at this time. Candoxatril and ecadotril are oral forms of neutral peptidase inhibitors which increase levels of natriuretic peptides and are currently in trials in adult patients with heart failure.

Endothelin Receptor Antagonists

Endothelin-1 levels are increased in patients with heart failure and progressively higher plasma concentrations are found in patients with heart failure as their functional class deteriorates. Endothelin-1 plasma level also correlates with pulmonary artery pressure and pulmonary vascular resistance. Although the expression of endothelin-1 within the myocardium may initially represent an adaptive response to stress, over expression of endothelin-1 may eventually be maladaptive by producing focal vasospasm, myocyte necrosis and increased myocardial fibrosis. Nonselective endothelin receptor antagonists such as bosentan, tezosentran and enrasentran are now being evaluated in clinical trials in adults but have yet to demonstrate their clinical utility. Sitaxsentan is a selective endothelin-1A receptor antagonist and a selective pulmonary vasodilator.

Total Artificial Heart

- The creation of a suitable total artificial heart (TAH) for orthotopic implantation has been the subject of intense investigation for decades (in 1969, Dr Denton Cooley implanted the Liotta TAH, which is no longer made) into a high-risk patient after failing to wean the patient off cardiopulmonary bypass after LV aneurysm repair. The patient was sustained until, after 3 days, a donor heart became available, but the patient subsequently died of pneumonia and multiple organ failure.
- Compared with LVADs, the TAH has several potential advantages, including the ability to assist patients with severe biventricular failure; a lack of device pocket and thus a lessened risk of infection; and the opportunity to treat patients with systemic diseases (e.g. amyloidosis, malignancy) who are not otherwise candidates for transplantation.
- At present, 2 TAHs are receiving the most attention: SynCardia (formerly CardioWest) TAH (SynCardia Systems, Inc) AbioCor TAH (Abiomed, Inc)
- The SynCardia TAH is a structural cousin of the original Jarvik-7 TAH (Jarvik Heart, Inc) that was implanted into patient Barney Clark with great publicity in 1982. In 2004, investigators reported data that allowed this device to receive FDA approval for use as a bridge to transplantation.
- The AbioCor TAH involves a novel method of transcutaneous transmission of energy, freeing the patient from external drivelines. The patient exchanges the external battery packs, which can last as long as 4 hours. This TAH is unique in that it is the first TAH to use coils to transmit power across the skin; therefore, no transcutaneous conduits are needed. This feature allows for the advantages of a closed system, which potentially reduces sources of infection, a known complication of earlier devices.
- The first clinical implantation of this TAH was performed in July 2001. Before the end of 2004, 14 patients had received this device as part of a trial in patients whose expected survival was less than 30 days. Although all subsequently died, 4 patients were ambulatory after surgery, and 2 were discharged from the hospital to a transitional-care setting. One of the discharged patients was discharged on postoperative day 209. A limitation of the AbioCor TAH is its large size, which permits its implantation in only 50% of men and 20% of women. In 2006, the FDA approved the Abiocor TAH as a permanent TAH for humanitarian uses.
- The SynCardia and AbioCor TAHs require recipient cardiectomy before implantation. The devices are similar in that they are sewn to atrial cuffs and to the great vessels after the native heart is explanted.
- Despite more than 40 years of effort, the clinical application of artificial-heart technology is still immature. However, with the approval of the SynCardia device and with new efforts to create small pumps, TAHs will ultimately be routine components of heart failure surgery for very sick patients with heart failure and biventricular failure.

Drug Therapy

The goals of pharmacotherapy for heart failure are to reduce morbidity and to prevent complications (Table 8.15). Along with oxygen, medications assisting with symptom relief include:

- Diuretics, which reduce edema by reduction of blood volume and venous pressures,
- Vasodilators, for preload and afterload reduction,
- Digoxin, which can cause a small increase in cardiac output,
- Inotropic agents, which help to restore organ perfusion and reduce congestion,
- Anticoagulants, to decrease the risk of thromboembolism,
- Beta-blockers, for neurohormonal modification, left ventricular ejection fraction (LVEF) improvement, arrhythmia prevention, and ventricular rate control,

Table 8.15: Drug therapy and dosage schelule for treatment of CHF

- Initial oral digitalization dose
  (IV or IM dose is two-thirds of oral dose)
- Maintenance digoxin:
  - Premature
    - <1500 gm 0.02 mg/kg 0.005 mg/kg
    - >1500 gm 0.04 mg/kg 0.01 mg/kg
  - Newborns and upto six months 0.04 mg/kg 0.01 mg/kg
  - 6 months–2 years 0.06 mg/kg 0.015 mg/kg
  - 2 years–10 years 0.04 mg/kg 0.01 mg/kg
  - >10 years 0.04 mg/kg 0.01 mg/kg
- Dopamine 5–10 mcg/kg/min in 5% glucose
  - Morphine 0.1 mg/kg/dose
  - Chloral hydrate 20 mg/kg/dose

- Angiotensin-converting enzyme inhibitors (ACEIs), for neurohormonal modification, vasodilatation, and LVEF improvement,
- Angiotensin II receptor blockers (ARBs), also for neurohormonal modification, vasodilatation, and LVEF improvement, and
- Analgesics, for pain management.

Drugs that can exacerbate heart failure should be avoided, such as nonsteroidal anti-inflammatory drugs (NSAIDs), calcium channel blockers (CCBs), and most antiarrhythmic drugs (except class III). NSAIDs can cause sodium retention and peripheral vasoconstriction, and they can attenuate the efficacy and enhance the toxicity of diuretics and ACEIs. CCBs can worsen heart failure and may increase the risk of cardiovascular events; only the vasoselective CCBs have been shown not to adversely affect survival. Antiarrhythmic agents can have cardiodepressant effects and may promote arrhythmia; only amiodarone and dofetilide have been shown not to adversely affect survival.

Beta-blockers, Alpha Activity

Beta-blockers inhibit the sympathomimetic nervous system and block alpha1-adrenergic vasoconstrictor activity. These agents have moderate afterload reduction properties and cause slight preload reduction. In addition to decreasing mortality rates, beta-blockers also reduce hospitalizations and the risk of sudden death; improve LV function and exercise tolerance; and reduce heart failure functional class. Although other beta-blockers with similar pharmacologic properties might hypothetically be beneficial in heart failure, the target doses have not been identified in clinical trials.

Carvedilol (Cor, e.g. Coreg CR)

Carvedilol is a nonselective beta-and alpha1-adrenergic blocker. It does not appear to have intrinsic sympathomimetic activity. Carvedilol at the target dose of 25 mg twice daily has been shown to reduce mortality in clinical trials of heart failure patients with reduced ejection fraction.

Beta-blockers, Beta-1 Selective

Certain beta-1 blockers are selective in blocking beta-1 adrenoreceptors. These agents are used in heart failure to reduce heart rate and blood pressure.

Metoprolol (Lopressor, Toprol XL)

Metoprolol is a selective beta1-adrenergic blocker at lower doses. It inhibits beta2-receptors at higher doses. It does not have intrinsic sympathomimetic activity. The long-acting formulation (metoprolol succinate) at a target dose of 200 mg daily has been shown to reduce mortality in a clinical trial of patients with heart failure and low ejection fraction.

Bisoprolol (Zebeta)

Bisoprolol is a highly selective beta1-adrenergic receptor blocker that decreases the automaticity of contractions. Bisoprolol at the target dose of 10 mg daily has been shown to reduce mortality in a clinical trial of patients with heart failure and reduced ejection fraction, but is not approved for heart failure use in the United States.

ACE Inhibitors

Angiotensin-converting enzyme inhibitors (ACEIs) prevent conversion of angiotensin I to angiotensin II, which results in lower aldosterone secretion. Use of ACEIs increases survival, improves symptoms, and decreases repeat hospitalizations.

Captopril

Captopril prevents conversion of angiotensin I to angiotensin II, a potent vasoconstrictor, resulting in lower aldosterone secretion. Captopril at a target dose of 25 mg three times daily has been shown to improve survival in patients with low ejection fraction after myocardial infarction.

Enalapril (Vasotec)

Enalapril prevents conversion of angiotensin I to angiotensin II, a potent vasoconstrictor, resulting in increased levels of plasma renin and a reduction in aldosterone secretion. It helps control blood pressure and proteinuria. Enalapril decreases the pulmonary-to-systemic flow ratio in the catheterization laboratory and increases systemic blood flow in patients with relatively low pulmonary vascular resistance. It has a favorable clinical effect when administered over a long period. It helps prevent potassium loss in distal tubules. The body conserves potassium; thus, less oral potassium supplementation is needed. Enalapril at a target dose of 10 mg twice daily has been shown to improve survival in patients with heart failure and reduced ejection fraction.

Lisinopril (Prinivil, Zestril)

Lisinopril prevents conversion of angiotensin I to angiotensin II, a potent vasoconstrictor, resulting in increased levels of plasma renin and a reduction in aldosterone secretion. Lisinopril at a target dose of 10 mg daily has been shown to reduce mortality after myocardial infarction.

Ramipril (Altace)

Ramipril prevents conversion of angiotensin I to angiotensin II, a potent vasoconstrictor, resulting in increased levels of plasma renin and a reduction in aldosterone secretion. Ramipril at a target dose of 5 mg twice daily has been shown to reduce mortality in patients with heart failure after myocardial infarction.

Quinapril (Accupril)

Quinapril prevents conversion of angiotensin I to angiotensin II, a potent vasoconstrictor, resulting in increased

levels of plasma renin and a reduction in aldosterone secretion.

ARBs

Angiotensin receptor blockers (ARBs) are reasonable first-line therapy for patients with mild to moderate heart failure symptoms and left ventricular (LV) dysfunction when patients are already taking these agents for other indications. ARBs block the renin-angiotensin-aldosterone system (RAAS) by competitive inhibition of the AT1 receptor, thereby decreasing afterload and preventing LV remodeling. The use of ARBs increases survival and decreases hospitalization rates, but these agents are not superior to angiotensin-converting enzyme inhibitors (ACEIs). ARBs can also be used as add-on therapy for patients who have refractory heart failure symptoms despite optimal heart failure therapy.

Losartan (Cozaar)

Losartan blocks the vasoconstrictor and aldosterone-secreting effects of angiotensin II at tissue receptor sites. It may induce more complete inhibition of the renin-angiotensin system than ACE inhibitors, and it does not affect the response to bradykinin (less likely to be associated with cough and angioedema). These agents are used in patients unable to tolerate ACE inhibitors. Losartan has not been demonstrated to improve survival in heart failure.

Valsartan (Diovan)

Valsartan is a prodrug that produces direct antagonism of angiotensin II receptors. It displaces angiotensin II from the AT1 receptor and may lower blood pressure by antagonizing AT1-induced vasoconstriction, aldosterone release, catecholamine release, arginine vasopressin release, water intake, and hypertrophic responses. It may induce more complete inhibition of the renin-angiotensin system than ACE inhibitors, does not affect the response to bradykinin, and is less likely to be associated with cough and angioedema. It is used in patients unable to tolerate ACE inhibitors. Valsartan at a target dose of 160 mg twice daily has been shown to improve survival in patients with heart failure and reduced ejection fraction.

Candesartan (Atacand)

Candesartan blocks the vasoconstriction and aldosterone-secreting effects of angiotensin II. It may induce more complete inhibition of the renin-angiotensin system than ACE inhibitors, does not affect the response to bradykinin, and is less likely to be associated with cough and angioedema. Use candesartan in patients unable to tolerate ACE inhibitors. Candesartan at a target dose of 32 mg daily has been shown to improve survival in patients with heart failure and reduced ejection fraction.

Irbesartan (Avapro)

Irbesartan blocks the vasoconstrictor and aldosterone-secreting effects of angiotensin II at tissue receptor sites. It may induce more complete inhibition of the renin-angiotensin system than ACE inhibitors, and it does not affect the response to bradykinin (less likely to be associated with cough and angioedema). Irbesartan has not been shown to improve survival in heart failure

Azilsartan (Edarbi)

Azilsartan blocks the vasoconstrictor and aldosterone-secreting effects of angiotensin II at tissue receptor sites. It may induce more complete inhibition of the renin-angiotensin system than ACE inhibitors, and it does not affect the response to bradykinin (less likely to be associated with cough and angioedema).

Inotropic Agents

Inotropic agents such as milrinone, digoxin, dopamine, and dobutamine are used to increase the force of cardiac contractions. Intravenous positive inotropic agents should only be used in inpatient settings—and then only in patients who manifest signs and symptoms of low cardiac output syndrome (volume overload with evidence of organ hypoperfusion).

Milrinone

Milrinone is a type 3 phosphodiesterase inhibitor that increases inotropy, chronotropy, and lusitropy, acting via cyclic guanosine monophosphate (cGMP) to increase the intramyocardial adenosine triphosphate (ATP). It is a potent vasodilator agent, being a venous and arterial vasodilator, and it is used in patients with pulmonary hypertension. Milrinone can be used in the presence of a beta-blocker. Milrinone is thought to create less tachycardia, because it does not directly stimulate beta-receptors.

Digoxin (Lanoxin)

Digoxin is a cardiac glycoside with direct inotropic effects, in addition to indirect effects, on the cardiovascular system. It acts directly on cardiac muscle, increasing myocardial systolic contractions. Indirect actions result in increased carotid sinus nerve activity and enhanced sympathetic withdrawal for any given increase in mean arterial pressure. It is used to improve symptoms associated with HF by enhancing cardiac contractility. Although digoxin does not confer a survival benefit, it has reduced the number of hospitalizations that occur as a result of worsening heart failure.

Dopamine

Dopamine is a naturally occurring catecholamine that acts as a precursor to norepinephrine. It stimulates both adrenergic and dopaminergic receptors. The hemodynamic effect is dose dependent. Low-dose use is associated with dilation within renal and splanchnic vasculature, resulting in enhanced diuresis. Moderate doses enhance cardiac contractility and the heart rate. Higher doses cause increased afterload through peripheral vasoconstriction. Administer by continuous intravenous infusion. It is usually used in severe heart failure and is reserved for

patients with moderate hypotension (e.g. systolic blood pressure 70–90 mmHg). Typically, moderate or higher doses are used.

Dobutamine

Dobutamine, a beta-receptor agonist, increases inotropy and chronotropy and decreases afterload, thereby improving end-organ perfusion. It produces vasodilation and increases the inotropic state. At higher dosages, it may cause increased heart rate, exacerbating myocardial ischemia. Careful hemodynamic and patient monitoring is required.

Vasodilators

In addition to diuretic therapy, vasodilators are recommended as first-line therapy for patients with acute heart failure in the absence of hypotension, for relief of symptoms. Vasodilators decrease preload and/or afterload as well as reduce systemic vascular resistance (SVR).

Nitroprusside Sodium (Nitropress)

Nitroprusside sodium is a potent balanced arterial and venous vasodilator, resulting in a very efficient decrease of intracardiac filling pressures. It requires careful hemodynamic monitoring using indwelling catheters and monitoring for cyanide toxicity, especially in the presence of renal dysfunction. It is particularly helpful for patients who present with severe pulmonary congestion in the presence of hypertension and severe mitral regurgitation. The drug should be titrated down to cessation rather than abruptly stopped, owing to the rebound potential.

Hydralazine

Hydralazine decreases systemic resistance through direct vasodilation of arterioles. A hydralazine and nitrate combination reduces preload and afterload. Combinations of hydralazine and nitrates are recommended to improve outcomes for African Americans with moderate-to-severe symptoms of heart failure on optimal medical therapy with ACEIs/ARBs, beta-blockers, and diuretics.

Nitrates

Nitrates improve hemodynamic effects in heart failure by decreasing left ventricular filling pressure and systemic vascular resistance. These agents also result in a slight improvement on cardiac output.

Nitroglycerin (Nitrostat, Nitro-Dur, Nitrolingual, Nitro-Time, NitroMist, Minitran)

Nitroglycerin is first-line therapy for patients who are not hypotensive. It provides excellent and reliable preload reduction. Higher doses provide mild afterload reduction. It has rapid onset and offset (both within minutes), allowing rapid clinical effects and rapid discontinuation of effects in adverse clinical situations. It produces vasodilation and increases inotropic activity of the heart. At higher dosages, it may exacerbate myocardial ischemia by increasing the heart rate.

Isosorbide Dinitrate (Dilatrate-SR, Isordil Titradose)

Isosorbide dinitrate relaxes vascular smooth muscle by stimulating intracellular cyclic GMP. It decreases left ventricular pressure (preload) and arterial resistance (afterload). By decreasing left ventricular pressure and dilating arteries, it reduces cardiac oxygen demand. Chronic use of isosorbide dinitrate as a sole vasodilating agent is not recommended.

Isosorbide Dinitrate and Hydralazine

This is a fixed-dose combination of isosorbide dinitrate (20 mg/tab), a vasodilator with effects on both arteries and veins, and hydralazine (37.5 mg/tab), a predominantly arterial vasodilator. It is indicated for heart failure in black patients, based in part on results from the African American heart failure trial. Two previous trials in the general population of patients with severe heart failure found no benefit but suggested a benefit in black patients. Black patients showed a 43% reduction in mortality rate, a 39% decrease in hospitalization rate, and a decrease in symptoms from heart failure.

Isosorbide Mononitrate (Monoket)

Isosorbide mononitrate causes relaxation of vascular smooth muscle and consequent dilatation of peripheral arteries and veins. Dilation of the veins promotes peripheral pooling of blood and decreases venous return to the heart, thereby reducing left ventricular end-diastolic pressure and pulmonary capillary wedge pressure (preload). Arteriolar relaxation reduces systemic vascular resistance, systolic arterial pressure, and mean arterial pressure (afterload).

Other Cardiovascular Agents

Human B-type natriuretic peptides (hBNPs) such as nesiritide are used in patients with acutely decompensated heart failure. These agents reduce pulmonary capillary wedge pressure and improve dyspnea.

Nesiritide (Natrecor)

Nesiritide is a recombinant DNA form of hBNP that dilates veins and arteries. hBNP binds to the particulate guanylate cyclase receptor of vascular smooth muscle and endothelial cells. Binding to the receptor causes an increase in cGMP, which serves as a second messenger to dilate veins and arteries. It reduces PCWP and improves dyspnea in patients with acutely decompensated HF.

Diuretics, Loop

Diuretics remain the mainstay of therapy and the current standard of care for acute heart failure. First-line diuretic therapy is a loop diuretic (furosemide, bumetanide, torsemide) in the lowest effective dose, either once or twice a day, although it can be used up to 3–4 times a day, depending on the individual response and renal function. Response to diuretic therapy often depends on bioavail-

ability of the drug (better on an empty stomach) and nutritional level (loop diuretics are bound to proteins for renal delivery).

Furosemide (Lasix)

Furosemide increases the excretion of water by interfering with the chloride-binding cotransport system, which, in turn, inhibits sodium and chloride reabsorption in the ascending loop of Henle and distal renal tubule. The dose must be individualized to the patient. Depending on the response, administer furosemide at small dose increments (20–200 mg) until desired diuresis occurs.

Torsemide (Demadex)

Torsemide acts from within the lumen of the thick ascending portion of the loop of Henle, where it inhibits the sodium, potassium, and chloride carrier system. It increases urinary excretion of sodium, chloride, and water, but does not significantly alter the glomerular filtration rate, renal plasma flow, or acid-base balance. Torsemide is roughly twice as potent as furosemide on a milligram basis. Depending on the response, administer furosemide at small dose increments (10–100 mg) until desired diuresis occurs.

Bumetanide

Bumetanide increases the excretion of water by interfering with the chloride-binding cotransport system, which, in turn, inhibits sodium, potassium, and chloride reabsorption in the ascending loop of Henle. These effects increase urinary excretion of sodium, chloride, and water, resulting in profound diuresis. Renal vasodilation occurs following administration, renal vascular resistance decreases, and renal blood flow is enhanced. Bumetanide is roughly four times as potent as furosemide on a milligram basis. Depending on the response, administer bumetanide at small dose increments (0.5–5 mg) until desired diuresis occurs.

Other Diuretics

Metolazone is a diuretic of the quinazoline class and has thiazide-like properties. This agent interferes with the renal tubular mechanism of electrolyte reabsorption.

Metolazone (Zaroxolyn)

Metolazone increases excretion of sodium, water, potassium, and hydrogen ions by inhibiting reabsorption of sodium in the distal tubules. Metolazone may be more effective in patients with impaired renal function.

Diuretics, Potassium-Sparing

The potassium-sparing diuretics interfere with sodium reabsorption at the distal tubules, resulting in decreased potassium secretion. These agents have a weak diuretic and antihypertensive effect when used alone. The potassium-sparing diuretics spironolactone or triamterene are usually used in addition to the loop diuretics. Note that careful monitoring of renal function and potassium is necessary for all diuretics.

Spironolactone (Aldactone)

Spironolactone is used for the management of edema resulting from excessive aldosterone excretion. It competes with aldosterone for receptor sites in the distal renal tubules, increasing water excretion while retaining potassium and hydrogen ions. Spironolactone at a target dose of 25 mg has been shown to improve survival in patients with heart failure and reduced ejection fraction.

Amiloride (Midamor)

Amiloride is unrelated chemically to other known antikaliuretic or diuretic agents. It is a potassium-conserving (antikaliuretic) drug that, compared with thiazide diuretics, possesses weak natriuretic, diuretic, and antihypertensive activity.

Triamterene (Dyrenium)

Triamterene is a potassium-sparing diuretic with relatively weak natriuretic properties. It exerts its diuretic effect on the distal renal tubules by inhibiting the reabsorption of sodium in exchange for potassium and hydrogen. It increases sodium excretion and reduces excessive loss of potassium and hydrogen associated with hydrochlorothiazide.

Alpha/Beta-adrenergic Agonists

In the presence of significant hypotension, adrenergic agonists are used to improve cardiac output and organ perfusion.

Epinephrine (Adrenaclick, Adrenalin, EpiPen, EpiPen Jr.)

Epinephrine is an alpha-agonist and its effects include increased peripheral vascular resistance, reversed peripheral vasodilatation, systemic hypotension, and vascular permeability. Beta2-agonist effects include bronchodilatation, chronotropic cardiac activity, and positive inotropic effects.

Norepinephrine (Levophed)

Norepinephrine is a naturally occurring catecholamine with potent alpha-receptor and mild beta-receptor activity. It stimulates beta1-and alpha-adrenergic receptors, resulting in increased cardiac muscle contractility, heart rate, and vasoconstriction. It increases blood pressure and afterload. Increased afterload may result in decreased cardiac output, increased myocardial oxygen demand, and cardiac ischemia. It is generally reserved for use in patients with severe hypotension (e.g. systolic blood pressure <70 mmHg) or hypotension that is unresponsive to other medications.

Aldosterone Antagonists, Selective

Aldosterone antagonists are weak diuretics that reduce mortality and the risk of sudden death by blocking the effects of aldosterone, thereby decreasing myocardial and

vascular inflammation and collagen production. This, in turn, prevents apoptosis, decreases stimulation of the renin-angiotensin-aldosterone system (RAAS) and sympathetic nervous system (SNS), and acts as a membrane stabilizer, thus preventing arrhythmia. Aldosterone antagonists are recommended for patients who have moderately severe and severe heart failure and reduced left ventricular (LV) systolic function [randomized aldactone evaluation study (RALES)] who can be carefully monitored for preserved renal function and normal potassium concentration.

Eplerenone (Inspra)

Eplerenone selectively blocks aldosterone at the mineralocorticoid receptors in epithelial (e.g. kidney) and non-epithelial (e.g. heart, blood vessels, and brain) tissues; thus, it decreases blood pressure and sodium reabsorption. It is indicated to improve survival for heart failure or left LV dysfunction following acute MI. Compared with placebo, a significant risk reduction (15%) has been observed. The EMPHASIS-HF trial has shown that patients with systolic heart failure with mild symptoms treated with eplerenone have a significant reduction in cardiovascular death or heart failure hospitalization when compared with placebo.

Anticoagulants, Cardiovascular

Patients with heart failure and depressed left ventricular (LV) ejection fraction are thought to have an increased risk of thrombus formation due to low cardiac output. Hospitalized patients with heart failure are at a high risk for venous thromboembolism and should receive prophylaxis. Anticoagulation with an international normalized ratio (INR) goal of 2–3 is indicated in the presence of: (1) an LV thrombus, (2) a thromboembolic event with or without evidence of an LV thrombus, and (3) paroxysmal or chronic atrial arrhythmias.

Warfarin (Coumadin, Jantoven)

Warfarin interferes with hepatic vitamin K-dependent carboxylation. It is used for the prophylaxis and treatment of thromboembolic disorders.

Dabigatran (Pradaxa)

Competitive, direct thrombin inhibitor. Thrombin enables fibrinogen conversion to fibrin during the coagulation cascade, thereby preventing thrombus development. Inhibits both free and clot-bound thrombin and thrombin-induced platelet aggregation.

Calcium Channel Blockers

Generally, calcium channel blockers (CCBs) should be avoided. CCBs do not play a direct role in the management of heart failure; however, these agents may be used to treat other conditions, such as hypertension or angina in heart failure patients.

CCBs may be used in heart failure with normal left ventricular ejection fraction. These drugs may also improve exercise tolerance via their vasodilatory properties.

Amlodipine (Norvasc)

Amlodipine has antianginal and antihypertensive effects. It blocks the postexcitation release of calcium ions into cardiac and vascular smooth muscle, thereby inhibiting the activation of ATPase on myofibril contraction. The overall effect is reduced intracellular calcium levels in cardiac and smooth muscle cells of the coronary and peripheral vasculature, resulting in dilatation of the coronary and peripheral arteries. It also increases myocardial oxygen delivery in patients with vasospastic angina.

Nifedipine (Adalat CC, Afeditab CR, Nifediac CC, Nifedical XL, Procardia, Procardia XL)

Nifedipine relaxes coronary smooth muscle and produces coronary vasodilation, which in turn, improves myocardial oxygen delivery. Sublingual administration is generally safe, despite theoretical concerns.

Felodipine

Felodipine is a dihydropyridine calcium channel blocker. It inhibits the influx of extracellular calcium across the myocardial and vascular smooth muscle cell membranes. The resultant decrease in intracellular calcium inhibits the contractile processes of the smooth muscle cells, resulting in dilation of coronary and systemic arteries.

Opioid Analgesics

Opioid analgesics such as morphine sulfate may help to relieve patients' anxiety, distress, and dyspnea.

Morphine Sulfate

Morphine is the drug of choice for narcotic analgesia because of its reliable and predictable effects, safety profile, and ease of reversibility with naloxone. Morphine sulfate administered intravenously may be dosed in a number of ways and commonly is titrated until the desired effect is obtained. Morphine sulfate also decreases preload in heart failure and relieves dyspnea.

Cytokine Antagonists

The current interest in understanding the role tissue necrotizing factor alpha in heart failure, relates to the observation that many aspects of the syndrome of heart failure can be explained by the known biologic effects of this cytokine. When expressed at sufficiently high concentration, tumor necrosis factor alpha mimics some aspects of the so called heart failure phenotype, including (but not limited to) progressive left ventricular dysfunction, pulmonary edema, left ventricle remodeling, fetal gene expression, and cardiomyopathy. Elevated levels of tumor necrosis factor alpha and other inflammatory cytokines have been associated with heart failure in children with congenital heart disease. Trials with etanercept, a soluble recombinantly produced chimeric tumor necrosis factor alpha antagonist and infliximab, a monoclonal antibody against tumor necrosis factor alpha are underway for treatment of heart failure in adults.

Coenzyme Q 10

Although coenzyme Q 10 (2, 3-dimethoxy-5-methyl-6-decaprenyl-1, 4-benzoquinone) has theoretical benefits to improve the energetics in failing myocardium by helping as an electron carrier in production of adenosine triphosphate, an antioxidant and free radical scavenger with membrane stabilizing properties, no beneficial effects of Coenzyme Q 10 supplementation on the left ventricular ejection fraction, peak oxygen consumption, or exercise duration are found by Khatta and co-workers. Therefore, Coenzyme Q 10 is not recommended at this time until large scale clinical trials have been performed.

Metabolic Therapy

The heart is able to utilize a variety of substrates for energy generation, including carbohydrates (glucose and lactate), lipids (free fatty acids and triglycerides), and ketones. This allows a normal heart to maintain its functional performance in a wide range of physiological conditions without experiencing an energy debt. However, an energy deficit has been observed during the develop an energy deficit has been observed during the development of heart failure that directly relates to patient prognosis. Long-term follow-up studies in patients with idiopathic dilated cardiomyopathy demonstrate that decreased phosphocreatinine (which is the source of instant adenosine triphosphate) is an independent predictor of mortality, suggesting that impaired myocardial energetics play an active role in the progression of heart failure. This notion is further supported by consistent observations in clinical trials revealing that energy-costly treatment, such as positive inotropic agents (beta-receptor mimetic drugs, phosphodiesterase inhibitors) increase mortality, while energy-sparing treatments (e.g. angiotensin converting enzyme inhibitors, angiotensin II blockers, or beta-blockers) reduce mortality.

Carbohydrates are the primary substrates for fetal hearts, while fatty acids become the predominant fuel in adult hearts, supporting more than two-thirds of the total adenosine tri-phosphate synthesized. An important change in energy metabolism is observed in hypertrophied and failing heart; increasing reliance on carbohydrates while decreasing fatty acid utilization, an apparent reoccurrence of the fetal metabolic profile. Studies using animal model of heart failure reveal that this shift of substrate preference is associated with the down regulation of peroxisome proliferator-activated receptor alpha, a transcriptor factor controlling the expres.

Prognosis in Heart Failure

Prognosis is poor on the whole, with approximately 50% of people with heart failure dying within four years of diagnosis. The mortality rate in the UK appears to be improving. A UK study found that the 6-month mortality rate for people with heart failure had improved from 26% in 1995 to 14% in 2005. The prognosis for people with heart failure and preserved left ventricular ejection fraction is a little better than the prognosis for people with heart failure and reduced ejection fraction (Table 8.16).

MANAGEMENT OF RIGHT VENTRICULAR FAILURE

Right ventricular (RV) failure occurs when the RV fails to maintain enough blood flow through the pulmonary circulation to achieve adequate left ventricular filling (Figs 8.81–8.87). This can occur suddenly in a previously healthy heart due to massive pulmonary embolism or right-sided myocardial infarction, but many cases encountered in the intensive care unit involve worsening of compensated RV failure in the setting of chronic heart and lung disease. Management of RV failure is directed at optimizing right-sided filling pressures and reducing afterload. Due to a lower level of vascular tone, vasoactive medications have

Table 8.16: Prognostic indicators and potential targets of therapy in AHFS

SBP	Admission and early postdischarge SBP inversely correlates with postdischarge mortality. The higher the BP, the lower both in-hospital and postdischarge mortality. However, the readmission rate of approximately 30% is independent of the SBP at time of admission
CAD	Extent and severity of CAD appears to be a predictor of poor prognosis
Troponin release	Results in a 3-fold increase in in-hospital mortality, a 2-fold increase in postdischarge mortality, and a 3-fold increase in the rehospitalization rate
Ventricular dyssynchrony	Increase in QRS duration occurs in approximately 40% of patients with reduced systolic function and is a strong predictor of early and late postdischarge mortality and rehospitalization
Renal impairment	Associated with a 2- to 3-fold increase in post-discharge mortality. Worsening renal function during hospitalization or soon after discharge is also associated with an increase in in-hospital and postdischarge mortality
Hyponatremia	Defined as serum sodium <135 mmol/L, occurs in approximately 25% of patients, and is associated with a 2- to 3-fold increase in postdischarge mortality
Clinical congestion at time of discharge	An important predictor of postdischarge mortality and morbidity. EF Similar early postdischarge event rates and mortality between reduced and preserved EF
BNP/NT-proBNP	Elevated natriuretic peptides associated with increased resource utilization and mortality
Functional capacity at time of discharge	Predischarge functional capacity, defined by the 6-min walk test, is emerging as an important predictor of postdischarge outcomes.

Adapted and modified, with permission, from Gheorghiade et al. CAD=coronary artery disease.

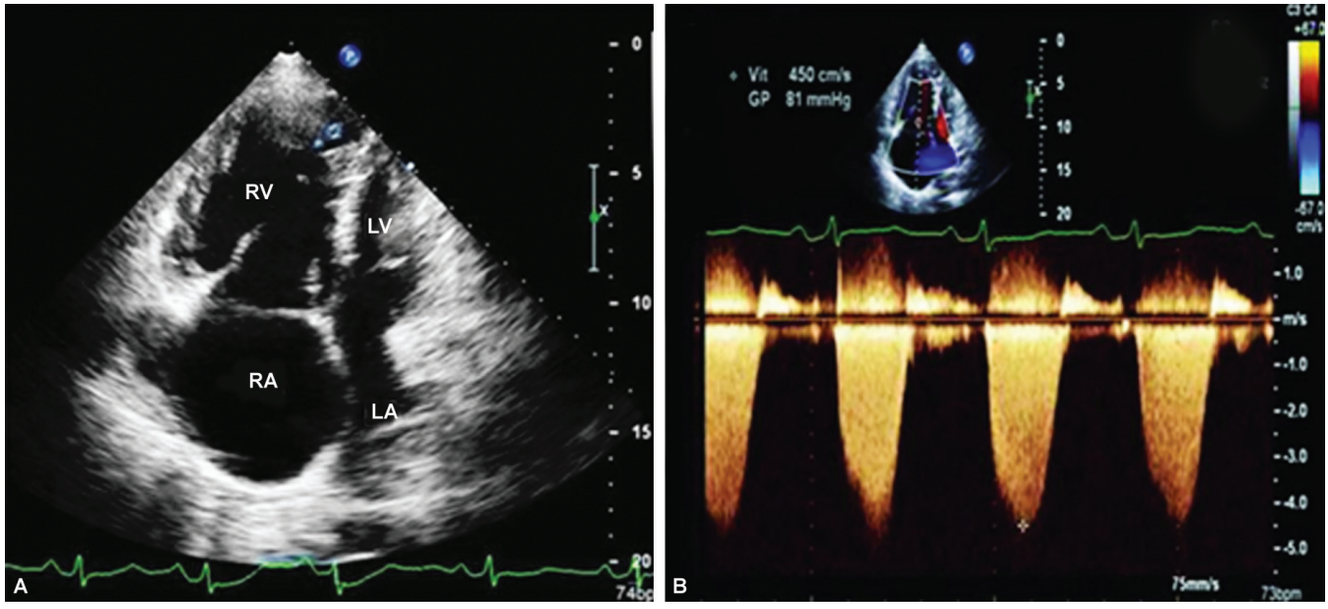

Fig. 8.81: Right ventricular failure. (A) Apical 4-chamber view showing gross dilatation of RA and RV. (B) Color Doppler view at tricuspid valve showing gross tricuspid regurgitation with gradient of more than 100 mmHg in a patient with primary pulmonary hypertension with CCR

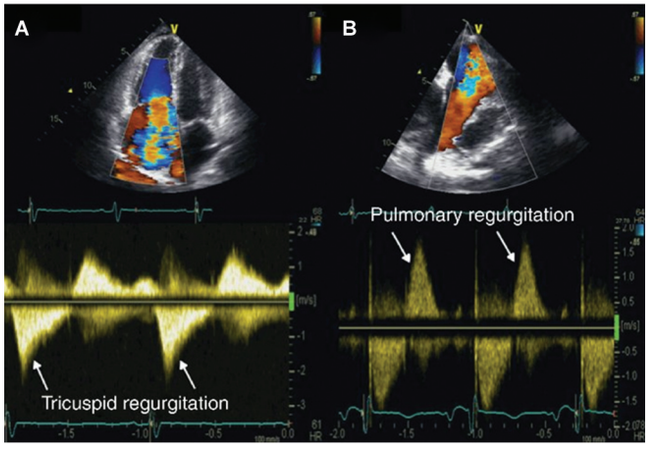

Fig. 8.82: Transthoracic echocardiography: Severe tricuspid (A) and pulmonary (B) regurgitation, shown by Color Doppler (top) and continuous wave Doppler (bottom)

less salient effects on reducing vascular resistance in the pulmonary than in the systemic circulation. Successful management requires reversal of any conditions that heighten pulmonary vascular tone and the use of selective pulmonary vasodilators at doses that do not induce systemic hypotension or worsening of oxygenation. Systemic systolic arterial pressure should be kept close to RV systolic pressure to maintain RV perfusion. When these efforts fail, the judicious use of inotropic agents may help improve RV contractility enough to maintain cardiac output. Extracorporeal life support is increasingly being used to support patients with acute RV failure who fail to respond to medical management while the underlying cause of their RV failure is addressed.

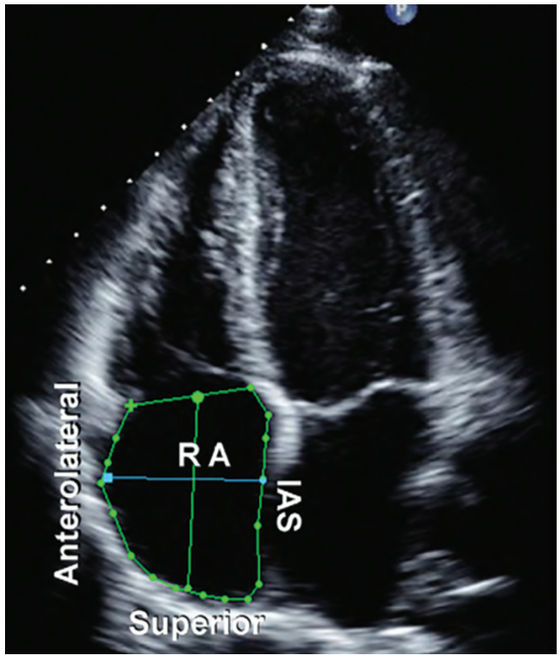

Fig. 8.83: Tracing of the right atrium (RA) is performed from the plane of the tricuspid annulus (TA), along the interatrial septum (IAS), superior and anterolateral walls of the RA. The right atrial major dimension is represented by the green line from the TA center to the superior right atrial wall, and the right atrial minor dimension is represented by the blue line from the anterolateral wall to the IAS

Current therapies directed toward pulmonary vasoconstriction, cellular proliferation, and thrombotic factors have improved the quality of life and survival in many patients with severe pulmonary arterial hypertension.

Likewise, therapies with afterload-reducing agents, β-receptor antagonists, inotropes, and diuretics have improved the functional status and prognosis of patients with left ventricular failure. Moreover, acute responsiveness to pulmonary vasodilators is associated with a better prognosis and survival in patients with advanced heart failure. Afterload reduction, however, cannot be achieved in many cases, but the increased right ventricular wall thickness and reversal of a fetal gene expression program have not yet been investigated as potential targeted treatments. Chronic intravenous epoprostenol infusion therapy in patients with pulmonary arterial hypertension appears to improve right ventricular function (although dilation and hypertrophy may not reverse over a 1-year period of observation, and the effects of the endothelin receptor antagonist bosentan on echocardiographic right ventricular parameters have also suggested a similar improvement in right ventricular function. However, the specific myocardial effects of these or other therapies for pulmonary arterial hypertension remain incompletely understood. In addition, right ventricular function, right ventricular–left ventricular interaction, and right ventricular–pulmonary arterial coupling have largely been overlooked as potential targets for investigation or therapy.

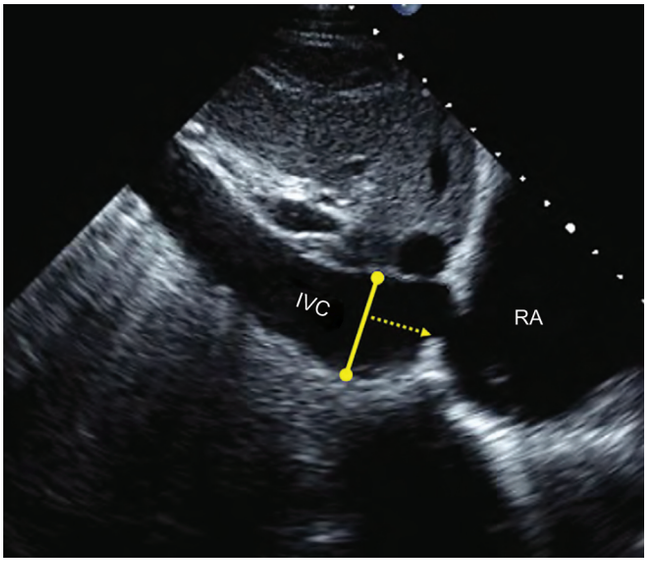

Fig. 8.84: Inferior vena cava (IVC) view. Measurement of the IVC. The diameter (solid line) is measured perpendicular to the long axis of the IVC at end-expiration, just proximal to the junction of the hepatic veins that lie approximately 0.5–3.0 cm proximal to the ostium of the right atrium (RA)

Continuous intravenous prostacyclin (epoprostenol) infusion therapy improves survival in idiopathic pulmonary arterial hypertension patients more than in patients with the limited variant of scleroderma-associated pulmonary arterial hypertension. Although the reasons for this discrepancy in treatment outcome are not clear, one possible explanation is the presence of a myocardial global microangiopathy in scleroderma patients.

Diagnosis and Treatment of Right Ventricular Heart Failure

Management of right ventricular (RV) failure includes treatment of the underlying cause; optimization of preload, afterload, and RV contractility; maintenance of sinus rhythm; and atrioventricular synchrony. Hypotension should be avoided, as it can potentially lead to further RV ischemia.

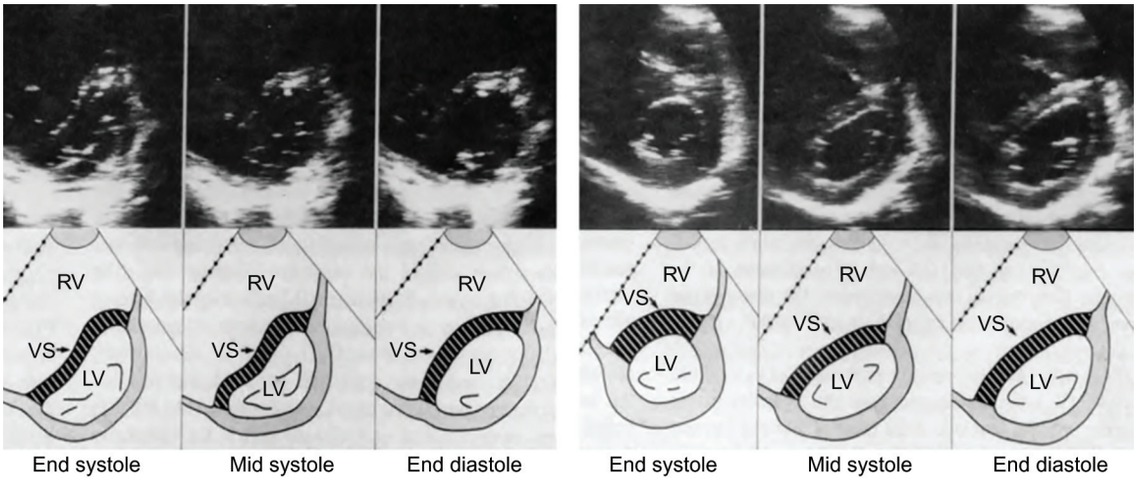

Fig. 8.85: Serial stop-frame short-axis two-dimensional echocardiographic images of the left ventricle at the mitral chordal level with diagrams from a patient with isolated right ventricular (RV) pressure overload due to primary pulmonary hypertension (left) and from a patient with isolated RV volume overload due to tricuspid valve resection (right). Whereas the left ventricular (LV) cavity maintains a circular profile throughout the cardiac cycle in normal subjects, in RV pressure overload there is leftward ventricular septal (VS) shift and reversal of septal curvature present throughout the cardiac cycle with most marked distortion of the left ventricle at end-systole. In the patient with RV volume overload, the septal shift and flattening of VS curvature occurs predominantly in mid to late diastole with relative sparing of LV deformation at end-systole *(reproduced with permission from J Am Coll Cardiol)*

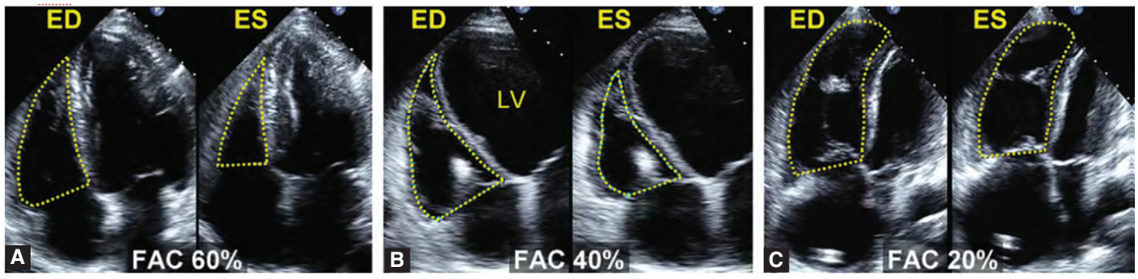

Fig. 8.86: Examples of right ventricular fractional area change (FAC). Percentage FAC = 100 end-diastolic area (area ED) endsystolic area (area ES)/end-diastolic area. The endocardial border is traced in apical four-chamber (A4C) views from the tricuspid annulus along the free wall to the apex, then back to the annulus, along the interventricular septum at end-diastole (ED) and end-systole (ES). Trabeculation, tricuspid leaflets, and chords are included in the chamber. (A) Normal subject, FAC 60%. (B) Moderately dilated right ventricle (RV), FAC 40%, and a markedly dilated left ventricle (LV). (C) Dilated RV, FAC 20%, and the LV is foreshortened as a result of optimizing the view for the right ventricular chamber

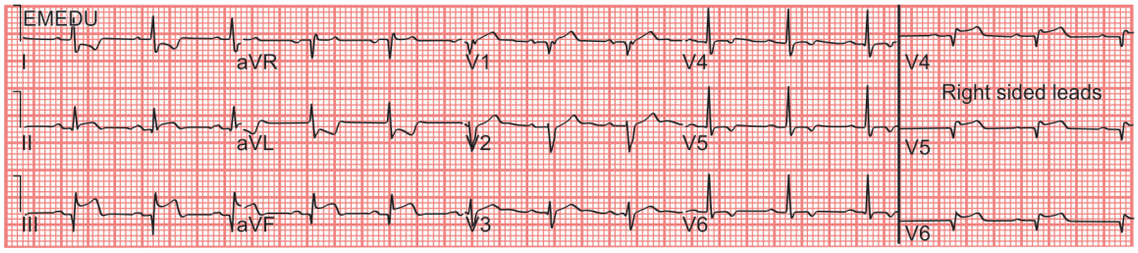

Fig. 8.87: ECG trace showing ST-elevation in leads II, III, AVF and V4–V6 in right sided precordial leads in acute right ventricular infarction

Assessment of Right Ventricular Functions

Although a fair amount of study has been devoted to assessment of right ventricular function, there remains a need to understand how to better define normal parameters of right ventricular function. Critical information is required to determine the most sensitive and specific variables to describe abnormal right ventricular function. It is likely that the definition of function will include parameters of geometry, ejection volume, hypertrophy, dilation, contraction, and oxygen supply to the ventricular wall. A clear picture of these parameters would help in determining which measurements are the best predictors of early right ventricular failure (such as right ventricular wall thickness, muscle perfusion, or metabolic activity). Ideally, a combination of approaches would be used to evaluate right heart function, including imaging techniques (Doppler echocardiography, computed tomography, magnetic resonance imaging, positron emission tomography), implanted continuous monitoring devices, and electrophysiology. Collaboration with the National Institute of Biomedical Imaging and Bioengineering to promote the development of imaging methods to study right ventricular function and dysfunction should be encouraged.

Distinguishing Characteristics of Right Heart Compared with Left Heart

Preliminary inquiry suggests that there are distinctions between the ventricles that need to be further evaluated and clarified to understand the differences, similarities, and interplay between the left and right heart. This issue can be addressed with chamber-specific studies in animal models that examine changes in gene expression, protein synthesis, histology, and geometry during development, injury, and stress (exercise and disease).

Investigation of Mechanism and Role of Hypertrophy

Although initial right ventricular hypertrophy in response to pressure overload may be adaptive, it is also the seemingly initial step in a remodeling process that is ultimately damaging, perhaps irreversibly so. Attention should be devoted to determining whether right ventricular hypertrophy is good or bad. Research is needed to compare hypertrophy seen in athletes with that seen in patients with diseases such as pulmonary arterial hypertension. Mechanisms of right ventricular hypertrophy and remodeling need to be determined.

Effect of Pulmonary Disease on Right Ventricular Function

Few studies address the interaction of right ventricular and pulmonary function. Research is needed to study the complex interaction of the heart and lungs and how changes in one affect the other. Examples of changes include inflammation, stress due to hypoxia or exercise, autoimmune reactions, infarction, and hypertension.

Models of Right Ventricular Failure

Researchers must develop reliable, reproducible, and relevant animal models of right ventricular failure. Animal

models would be particularly useful in determining factors that initiate right ventricular dysfunction. Models would also help to identify biomarkers and changes in gene expression and protein synthesis associated with right ventricular failure. Valuable information could be obtained from animal models through side-by-side comparisons of changes in the left and right ventricles. Parameters on which to focus would include tissue analysis; gene and protein expression; and markers of oxidative stress, apoptosis, and cell growth. When possible, such analyses should compare tissue from patients with animal models of right heart failure and pulmonary hypertension to address the question of whether data obtained from manipulated animal right ventricles can be extrapolated to right ventricular or interventricular septal biopsy material from the hearts of patients with severe pulmonary hypertension. Animal models will be a necessary component to determine whether right ventricle failure is associated with myocyte apoptosis or cytokine expression. In addition, data from animal studies suggest that significant differences exist between sexes in the development of right heart failure. Studies that further examine gender differences will be important for developing potential new therapeutics and determining whether treatment should be determined by sex.

General measures of treatment should be applied, as follows:

- Sodium and fluid restriction
- Moderate physical activity, with avoidance of isometric exercises
- Avoidance of pregnancy
- Compliance with medications

Avoidance, or rapid treatment of precipitating factors such as:

- Sleep apnea
- Pulmonary embolism
- Sepsis
- Arrhythmia
- Ischemia
- High altitude
- Anemia
- Hypoxemia
- Use of an ACEI/ARB is beneficial if RV failure is secondary to LV failure; the efficacy of these agents in isolated RV failure is not known. The same recommendation applies for use of beta-blockers. The role of nesiritide in RV failure is not well defined. Use of digoxin in RV failure associated with chronic obstructive pulmonary disease (COPD) not associated with LV dysfunction appears not to improve exercise tolerance or RV ejection fraction. Treatment of pulmonary-induced RV failure is to address the correction of a primary pulmonary aetiology and a decrease in RV afterload via specific pulmonary artery vasodilatory therapies.
- In patients with severe, hemodynamically compromising RV failure, inotropic therapy is administered, using dobutamine (2–5 mcg/kg/min), dobutamine and inhaled nitric oxide, or dopamine alone. Milrinone is preferred if the patient is tachycardic or on beta-blockers.
- Anticoagulation indications are standard for evidence of intracardiac thrombus, thromboembolic events, pulmonary arterial hypertension, paroxysmal or persistent atrial fibrillation/flutter, and mechanical right-sided valves. Hypoxemia should be corrected, and positive pressure should be avoided when mechanical ventilation is needed.
- Atrial septostomy can be considered as a palliative measure in patients with severe symptoms in whom standard therapy has failed. RV mechanical assist device is indicated only for RV failure secondary to LV failure or postcardiac transplantation.
- The prognosis in patients with RV failure depends on the aetiology. Volume overload, pulmonary stenosis, and Eisenmenger syndrome are associated with a better prognosis. Decreased exercise tolerance predicts poor survival.

Translational Research

An emphasis on translational research, particularly studies of human myocardial tissue, is required to determine the important markers of right ventricular function and dysfunction. Studies to identify markers in plasma as well as those in tissue might facilitate prediction of early diagnosis of ventricular dysfunction and may prevent failure. Robust parameters that predict outcome for patients with right heart failure are needed.

Right Ventricular Morphogenesis

The developmental aspects of right heart formation need to be studied to identify mechanisms involved in congenital heart disease and related pulmonary vascular disease.

Targeted Therapy

The development of new therapeutic strategies for right heart failure should be promoted. These new strategies might include cell-based or gene therapy, new drugs, or new combinations of existing drugs.

Awareness

Awareness should be promoted in the pulmonary and cardiology research communities about the lack of knowledge of the right ventricle with well-publicized requests for research proposals. New and established investigators should be encouraged to enter this fruitful area of research. The consensus of the working group is that the role of the right ventricle in a spectrum of cardiovascular diseases has been relatively neglected proportionate to its central importance. Advancing knowledge through research about the unique genetic, molecular, cellular, and functional characteristics of the right ventricle and their vulnerability to disease will lead to progress in the treatment of cardiomyopathy, pulmonary arterial hypertension, right ventricular ischemic syndromes, and

valvular heart disease. The success in such effort requires collaborations between and among clinical and basic investigators from various disciplines, including those in respiratory/pulmonary and cardiovascular fields as well from neuroscientists, immunologists, endocrinologists, and biomedical engineers. Joint meetings of the American Heart Association and the American Thoracic Society would be appropriate venues to promote the importance of understanding the right ventricle and would help to accelerate the gathering of information leading to better treatment and preventative means to reduce morbidity and mortality associated with right heart failure and left heart failure.

Future Directions

Given the pivotal involvement of the right ventricle in both common and rare cardiovascular diseases and the paucity of basic knowledge at all levels about its normal and pathological functions, support for further research should be a high priority for investigators and National Institutes of Health Funding. Areas of deficient understanding worthy of further exploration include the following issues.

KEY POINTS IN HEART FAILURE

- Patients with severe acute decompensated HF (ADHF) are best managed in hospital; those with mild decompensation or chronic compensated HF are often managed as outpatients by their GPs.
- Heart failure (HF) should be considered in all older patients presenting with a new wheeze.
- Understand the importance of new onset or exacerbation of HF as a risk factor for perioperative complications, especially in the elderly.
- Use the history and physical exam to stratify the patient's risk for cardiac complications of surgery, employing one of the available risk indices. Recognize that most patients with HF will be at high risk.
- Determine if the patient has 'decompensated' HF, which is present if the patient has NYHA Class III or IV symptoms or evidence of HF on physical exam or chest X-ray. If decompensated HF is present, postpone elective surgery in order to optimize management.
- Recognize the importance of the risk associated with the surgery itself, and with various forms of anesthesia.
- Obtain the following laboratory studies:
  - ECG
  - BUN and creatinine levels
  - Results of previous cardiovascular studies (echocardiogram, stress test, catheterization data)
  - Obtain an echocardiogram for patients with a history of HF and changes in symptoms to assess ventricular function/ejection fraction and structural/valvular abnormalities.

Contd...

Contd...

- Optimize the patient's medical regimen for HF and other cardiac disease before surgery.
- Consider preoperative transfusion if the patient's baseline hematocrit level is <8 mg/dl and extensive surgery or major blood loss is anticipated.
- Consider reducing or holding ACE inhibitors and/or diuretics on the day of elective surgery depending on the patient's clinical status and proposed surgery.
- Continue beta-blockers perioperatively in patients receiving them chronically.
- Use adequate pain management to reduce the risk for postoperative cardiac complications.
- Resume the patient's usual medications as soon as possible after surgery.

BIBLIOGRAPHY

1. American Heart Association. Classes of heart failure. Hunt SA, Abraham WT, Chin MH, et al. and the American College of Cardiology Foundation; American Heart Association. 2009 Focused update incorporated into the ACC/AHA 2005 guidelines for the diagnosis and management of heart failure in adults: a report of the American College of Cardiology Foundation/American Heart Association Task Force on practice guidelines developed in collaboration with the International Society for Heart and Lung Transplantation. J Am Coll Cardiol 2009;53(15).
2. Anversa P, Nadal-Ginard B. Myocyte renewal and ventri-cular remodelling. Nature 2002;415(6868):240–3.
3. Braunwald E, Ross J Jr, Sonnenblick EH (2nd edn). Mechanisms of Contraction of the Normal and Failing Heart. Boston: Little Brown & Co; 1976:417.
4. Braunwald E. The pathogenesis of heart failure: Then and now. Medicine 1991;70:68.
5. Bursi F, McNallan SM, Redfield MM, et al. Pulmonary pressures and death in heart failure a community study. J Am Coll Cardiol 2012;59(3):222–31.
6. Cardiovascular Diseases. Dean T. Jamison, Richard G. Feachem, Eduard R. Bos, Malegapuru W. Makgoba, Florence K. Baingana, Karen J. Hofman, Kahma O. Rogo. Disease and mortality in Sub-Saharan Africa. 2. Washington D.C: World Bank Publications. 2006:21.
7. Chen J, Normand SL, Wang Y, Krumholz HM. National and regional trends in heart failure hospitalization and mortality rates for Medicare beneficiaries, 1998–2008. JAMA 2011; 306(15):1669–78.
8. Clifford R Greyson, MD. Pathophysiology of right ventri-cular failure. Crit Care Med 2008;36(Suppl):S57–65.
9. Cody RJ. Hormonal alterations in heart failure. In: Hosenpud JB, Greenberg BH (Eds). Congestive Heart Failure: Pathophysiology, Diagnosis and Comprehensive Approach to Management. Philadelphia: Lippincott Williams & Wilkins; 2000:199–212.
10. Cohn JN. Structural basis for heart failure. Ventricular remodeling and its pharmacological inhibition. Circulation 1995;91(10):2504–7.

11. Damasceno A, Cotter G, Dzudie A, Sliwa K, Mayosi BM. Heart failure in sub-saharan Africa: time for action. J Am Coll Cardiol 2007;50(17):1688–93 [Medline].
12. Dewalt DA, Schillinger D, Ruo B, Bibbins-Domingo K, Baker DW, Holmes GM, et al. A Multisite Randomized Trial of a Single-versus Multi-Session Literacy Sensitive Self-Care Intervention for Patients with Heart Failure. Circulation 2012;[Medline].
13. Dickstein K, Cohen-Solal A, Filippatos G, et al. For the Task Force for the Diagnosis and Treatment of Acute and Chronic Heart Failure 2008 of the European Society of Cardiology. ESC Guidelines for the diagnosis and treatment of acute and chronic heart failure 2008: the Task Force for the Diagnosis and Treatment of Acute and Chronic Heart Failure 2008 of the European Society of Cardiology. Developed in collabo-ration with the Heart Failure Association of the ESC (HFA) and endorsed by the European Society of Intensive Care Medicine (ESICM). Eur Heart J 2008;29(19):2388–442.
14. Dries DL, Exner DV, Domanski MJ, Greenberg B, Stevenson LW. The prognostic implications of renal insufficiency in asymptomatic and symptomatic patients with left ventricular systolic dysfunction. J Am Coll Cardiol 2000;35(3):681–9.
15. Dunlay SM, Eveleth JM, Shah ND, McNallan SM, Roger VL. Medication adherence among community-dwelling patients with heart failure. Mayo Clin Proc 2011;86(4):273–81. [Medline] [Full Text].
16. Feldman AM, Combes A, Wagner D, et al. The role of tumor necrosis factor in the patho-physiology of heart failure. J Am Coll Cardiol 2000; 35(3):537–44.
17. Fonarow GC, Adams KF Jr, Abraham WT, Yancy CW, Boscardin WJ. Risk stratification for in-hospital mortality in acutely decompensated heart failure: classification and regression tree analysis. JAMA 2005;293(5):572–80.
18. Fonarow GC. Epidemiology and risk stratification in acute heart failure. Am Heart J 2008;155(2):200–7.
19. Gheorghiade M, Pang PS. Acute heart failure syndromes. J Am Coll Cardiol 2009;53(7):557–73.
20. Gottlieb SS, Khatta M, Friedmann E, Einbinder L, Katzen S, Baker B, et al. The influence of age, gender, and race on the prevalence of depression in heart failure patients. J Am Coll Cardiol 2004;43(9):1542–9.
21. Haddad F, Doyle R, Murphy DJ, Hunt SA. Right ventricular function in cardiovascular disease, part II: pathophysiology, clinical importance, and management of right ventricular failure. Circulation 2008;117(13):1717–31.
22. Halley CM, Houghtaling PL, et al. Mortality rate in patients with diastolic dysfunction and normal systolic function. Arch Intern Med 2011; 171(12):1082–7 [Medline].
23. He J, Ogden LG, Bazzano LA, et al. Risk factors for congestive heart failure in US men and women: NHANES I epidemio-logic follow-up study. Arch Intern Med 2001;161(7):996–1002 [Medline].
24. Ho JE, Liu C, Lyass A, Courchesne P, Pencina MJ, Vasan RS, et al. Galectin-3, a marker of cardiac fibrosis, predicts incident heart failure in the community. J Am Coll Cardiol 2012; 60(14):1249–56 [Medline].
25. Ho KK, Anderson KM, Kannel WB, Grossman W, Levy D. Survival after the onset of congestive heart failure in Framingham Heart Study subjects. Circulation 1993;88(1): 107–15 [Medline].
26. Hunt SA. For the Task Force on Practice Guidelines (Writing Committee to Update the 2001 Guidelines for the Evaluation and Management of Heart Failure). ACC/AHA 2005 guide-line update for the diagnosis and management of chronic heart failure in the adult: a report of the American College of Cardiology/American Heart Association Task Force on Practice Guidelines. J Am Coll Cardiol 20 2005; 46(6):e1–82.
27. Jencks SF, Williams MV, Coleman EA. Rehospitalizations among patients in the Medicare fee-for-service program. N Engl J Med 2009;360(14):1418–28.
28. Kajstura J, Leri A, Castaldo C, Nadal-Ginard B, Anversa P. Myocyte growth in the failing heart. Surg Clin North Am 2004;84(1):161–77
29. Kajstura J, Leri A, Finato N, Di Loreto C, Beltrami CA, Anversa P. Myocyte proliferation in end-stage cardiac failure in humans. Proc Natl Acad Sci USA 1998;95(15):8801–5.
30. Ketchum ES, Levy WC. Establishing prognosis in heart failure: a multimarker approach. Prog Cardiovasc Dis 2011; 54(2):86–96.
31. Lam CS, Lyass A, Kraigher-Krainer E, et al. Cardiac dysfunc-tion and noncardiac dysfunction as precursors of heart failure with reduced and preserved ejection fraction in the community. Circulation 2011;124(1):24–30.
32. Leri A, Claudio PP, Li Q, Wang X, Reiss K, Wang S, et al. Stretch-mediated release of angiotensin II induces myocyte apoptosis by activating p53 that enhances the local renin-angiotensin system and decreases the Bcl-2-to-Bax protein ratio in the cell. J Clin Invest 1998;101(7):1326–42.
33. Levy D, Kenchaiah S, Larson MG, et al. Long-term trends in the incidence of and sur-vival with heart failure. N Engl J Med 2002;347(18): 1397–402.
34. Lindenfeld J, Albert NM, Boehmer JP, et al. for the Heart Failure Society of America. Executive summary: HFSA 2010 comprehensive heart failure practice guideline. J Card Fail 2010;16(6):e1–194
35. Lindenfeld J, Albert NM, Boehmer JP, et al. HFSA 2010 Comprehensive Heart Failure Practice Guideline. J Card Fail 2010;16(6):e1–194. [Medline].
36. Lloyd-Jones D, Adams RJ, Brown TM, et al. Executive summary: heart disease and stroke statistics—2010 update: a report from the American Heart Association. Circulation 2010;121(7):948–54.
37. Lucas C, Johnson W, Hamilton MA, et al. Freedom from congestion predicts good survival despite previous class IV symptoms of heart failure. Am Heart J 2000;140(6):840–7.
38. MacIntyre K, Capewell S, Stewart S, et al. Evidence of improving prognosis in heart failure: trends in case fatality in 66 547 patients hospitalized between 1986 and 1995. Circulation 2000;102(10):1126–31.
39. Masoudi FA, Havranek EP, Smith G, et al. Gender, age, and heart failure with preserved left ventricular systolic function. J Am Coll Cardiol 2003; 41(2):217–23.
40. Morris DA, Gailani M, Vaz Perez A, et al. Right ventricular myocardial systolic and diastolic dysfunction in heart failure with normal left ventricular ejection fraction. J Am Soc Echocardiogr 2011;24(8):886–97.
41. Murphy RT, Starling RC. Genetics and cardiomyopathy: where are we now? Cleve Clin J Med 2005;72(6):465–6, 469–70, 472–3.

42. Onwuanyi A, Taylor M. Acute decompensated heart failure: pathophysiology and treatment. Am J Cardiol 2007; 99(6B): 25D–30D.
43. Rebecca Gary, RN, PhD, Leslie Davis, MSN, RN, et al. Diastolic heart failure. Heart & Lung 2007;37(6):405–16.
44. Roger VL, Go AS, Lloyd-Jones DM, et al. for the American Heart Association Statistics Committee and Stroke Statistics Subcommittee. Heart disease and stroke statistics—2011 update: a report from the American Heart Association. Circulation 2011;123(4):e18–e209.
45. Ross J Jr, Braunwald E. Studies on Starling's law of the heart. The effects of impeding venous return on performance of the normal and failing human left ventricle. Circulation 1954;30:719.
46. Stewart S, Wilkinson D, Hansen C, Vaghela V, Mvungi R, McMurray J, et al. Predominance of heart failure in the Heart of Soweto Study cohort: emerging challenges for urban African communities. Circulation 2008;118(23):2360–7.
47. Stiles S. FDA Approves Heart Sympathetic Activity Imaging Agent for HF Evaluation. Framingham Classification: Ho KK, Pinsky JL, Kannel WB, Levy D. The epidemiology of heart failure: the Framingham Study. J Am Coll Cardiol 1993; 22(4 Suppl A):6A–13A.
48. van Diepen S, Bakal JA, McAlister FA, Ezekowitz JA. Mortality and readmission of patients with heart failure, atrial fibrillation, or coronary artery disease undergoing non-cardiac surgery: an analysis of 38 047 patients. Circulation 2011;124(3):289–96.

9 Management of Heart Failure with Implantation of Newer Devices

Several new devices for the treatment of heart failure (HF) patients have been introduced and are increasingly used in clinical practice or are under clinical evaluation in either observational and/or randomized clinical trials. These devices include cardiac contractility modulation, spinal cord stimulation, carotid sinus nerve stimulation, cervical vagal stimulation, intracardiac atrioventricular nodal vagal stimulation, and implantable hemodynamic monitoring devices. This task force believes that an overview on these technologies is important. Special focus is given to patients with HF New York Heart Association Classes III and IV and narrow QRS complex, who represent the largest group in HF compared with patients with wide QRS complex. An overview on potential device options in addition to optimal medical therapy will be helpful for all physicians treating HF patients.

The Committee for Scientific Documents of the European Heart Rhythm Association felt, that several new devices for the treatment of heart failure (HF) patients have been introduced and are increasingly used in clinical practice or are under clinical evaluation in either observational and/or randomized clinical trials. So far, most of these technologies, if not all, have not been addressed in guidelines or position papers. Recently, several expert consensus documents and guidelines on device therapy in HF have been published followed by the publication of the 2012 EHRA/HRS consensus statement and new 2013 ESC guidelines on cardiac pacing and cardiac resynchronization therapy in 2013. Therefore, this position paper does not include any recommendation on cardiac resynchronization therapy (CRT) in heart failure.

Recommendations should represent evidence-based medicine. However, except for cardiac contractility modulation (CCM), no data based on randomized trials are available, and for none of the new devices clinical outcome data, in particular mortality data, are available.

Nevertheless, this task force believes that an overview on these new technologies is important and necessary. Special focus is given to patients with HF. New York Heart Association (NYHA) Classes III and IV and narrow QRS complex, who represent the largest group in HF compared with patients with wide QRS complex. Therefore, the task force believes that an overview on potential device options in addition to optimal medical therapy (OMT) would be helpful for all physicians treating HF patients (Figs 9.1–9.3, Tables 9.1 and 9.2).



Fig. 9.1: Rough, dry hair, skin, facial puffiness, edema of whole body and cardiomegaly in a middle-aged lady with hypothyroidism and heart failure



Fig. 9.2: Pitting edema. Bilateral, dependent pitting edema occurs with heart failure



Fig. 9.3: Low cost wireless ECG cardiac monitor can save lives and cut healthcare costs. Developed by British Medical Services startup Isansys and based on the class-leading performance of Nordic nRF24AP2 ANT chips—the LifeTouch HRV011 cardiac monitor supports low cost yet continuous, clinical-grade ECG monitoring for the first time and can thus be used to detect post-cardiac arrest and other problems when they are usually straightforward to treat, avoiding life-threatening and costly emergency room readmissions

Table 9.1: New therapeutic devices in heart failure

	Characteristics	Effects and status of trials
Cardiac contractility modulation (CCM)	Proteins and genes involved in Ca handling • CCM signals are nonexcitatory signals delivered to the LV ~30 ms after QRS onset • Effects are independent of QRS duration and additive to those of CRT • CCM signals acutely affect calcium handling but also expression	• Enhances the strength of LV contraction • Decreases LV volumes and increases EF • Improves exercise tolerance and quality of life • RCTs: FIX-HF-4, FIX-HF-5
Spinal cord stimulation	• Stimulation of afferent spinal nerve fibres • Increase of central vagal tone and decrease of sympathetic tone via central reflex activation • Reduces risk of ischemic ventricular	• Improves cardiac output, reduces peripheral resistance • Increases cardiac work efficiency, decreases myocardial oxygen demand arrhythmia • SCS-HEART (ongoing non-RCT) • DEFEAT-HF (ongoing RCT)
Carotid sinus nerve stimulation	• Stimulation of afferent fibres coupled to arterial baroreceptors • Increase of central vagal tone and decrease of sympathetic tone via central reflex activation	• Improves systolic and diastolic LV function • Slight decrease of heart rate and blood pressure • XR-1 heart failure study; HOPE4HF study (ongoing RCTs)
Cervical vagal nerve stimulation	• Stimulation of cervical preganglionic para-sympathetic fibres • Direct activation of overall cardiac vagal tone	• Antiarrhythmic, rate slowing, antifibrotic, anti-inflammatory, and reverse remodelling effects • Decreases LV volumes and increases EF • Improves exercise tolerance and quality of life • CardioFit study (non-RCT) • INNOVATE-HF (ongoing RCT)
Intracardiac AV-nodal vagal stimulation	• Stimulation of postganglionic cardiac para-sympathetic nerves selectively innervating AV node	• Dynamic ventricular rate control during AF • AV nodal selective • May avoid inappropriate shock delivery in patients with AF and ICD/CRT-D • AVNS study (ongoing non-RCT)

Table 9.2: Implantable hemodynamic monitoring devices

Device	Characteristics (*Monitors*)	Clinical outcome
RV-pressure monitoring	• Systolic and diastolic RV pressure • RV d*P*/d*t* • Pulmonary artery diastolic pressure • Heart rate • Patient activity • Core body temperature	• Nonsignificant reduction of all CHF-related events (COMPASS-HF)
LA-pressure monitoring (Heart-POD)	• LA pressure • Intracardiac electrogram • Body temperature	• Reduces death and CHF events • Adequate adjustment of drug-therapy results in improvement of NYHA class and LVEF (HOMEOSTASIS study)
Pulmonary artery pressure (CardioMEMS)	• PAP	• Reduces significantly rate and duration of CHF-related hospitalization (CHAMPION study)

CARDIAC CONTRACTILITY MODULATION

Resynchronization Therapy Device

Cardiac contractility modulation signals are nonexcitatory signals which, when applied during the absolute refractory period, enhance the strength of left ventricular (LV) contraction and improve exercise tolerance as well as QoL in patients with heart failure. As the signals influence cell function without any affecting activation sequence, the effects are independent of QRS duration and should be additive to those of CRT.

Concept of Cardiac Contractility Modulation

Cardiac contractility modulation signals are electrical impulses delivered during the absolute refractory period. Cardiac contractility modulation signals used in clinical practice are delivered ≥30 ms after detection of the QRS complex onset and consist of two biphasic ±7 V pulses spanning a total duration of >20 ms. These signals do not elicit a new action potential or contraction, as is the case with extra-or postextrasystolic contractions. Moreover, they do not affect the sequence of electrical or mechanical activation, nor do they recruit additional contractile elements. On this basis, CCM signals are referred to as 'nonexcitatory'.

If your heart is not beating efficiently and you meet the eligibility criteria, you may be eligible for a cardiac resynchronization therapy (CRT) heart device (Figs 9.4 and 9.5).

A CRT device sends small, undetectable electrical impulses to both lower chambers of the heart to help them beat together in a more synchronized pattern. This improves the heart's ability to pump blood and oxygen to the body.

The heart device itself is actually a tiny computer, plus a battery, contained in a small titanium metal case that is about the size of a pocket watch. It weighs about 3 ounces.

In addition to the heart device, insulated wires called leads are implanted for two purposes—to carry information signals from your heart to the heart device, and to carry electrical impulses to your heart.

The third part of your implantable device system is a programmer, an external computer located in your doctor's

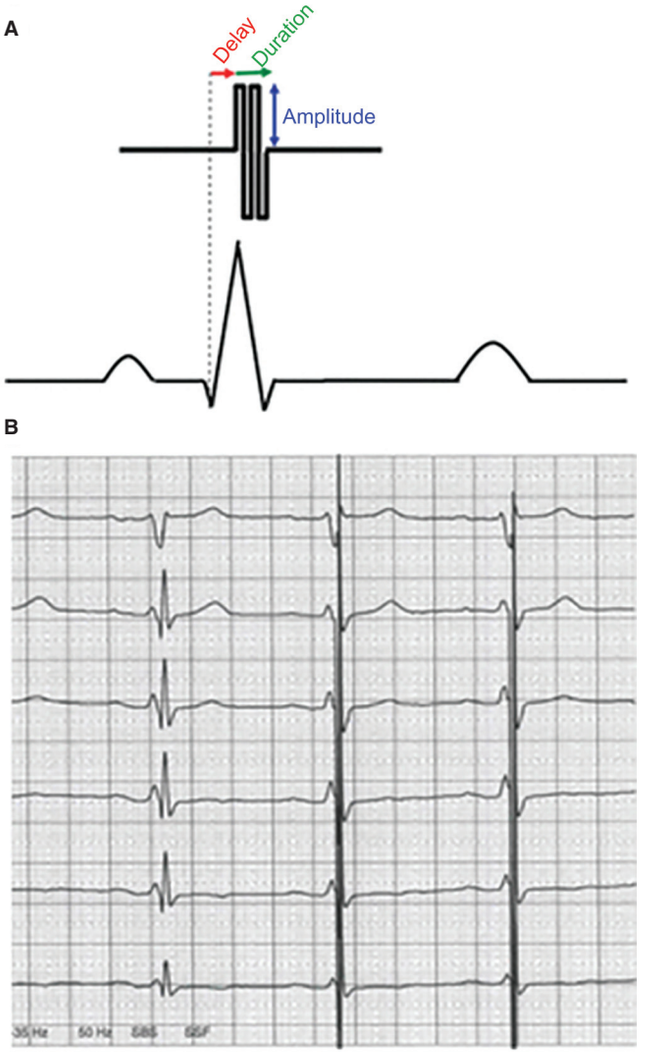

Fig. 9.4: (A) Top and middle—cardiac contractility modulation (CCM) signals are biphasic pulses, delivered after a defined delay from detection of local electrical activation. (B) Body surface electrocardiogram (leads V1–V6) showing one beat prior to initiating CCM signals and the first two beats of CCM signal application. Please note the stimulation artefact in beats 2 and 3 reflect CCM signals

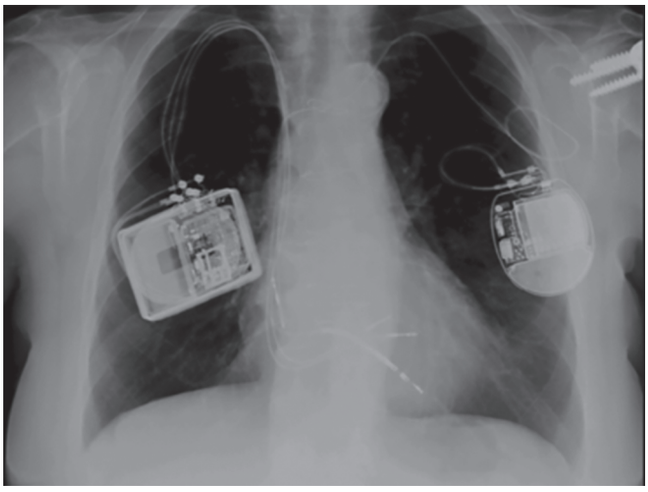

Fig. 9.5: Chest X-ray showing an implanted CCM system (CCM, right side) and one-chamber ICD device (left side). The CCM system consists of a can and three pace-sense electrodes. Two of them are fixed to the midseptum and the third one to the right atrium

office or clinic that is used to program the heart device and retrieve information from your heart device that will assist your doctor in your heart failure treatment.

There are two types of implantable heart failure heart devices—a CRT pacemaker and a combination CRT pacemaker with defibrillation therapy. Both of these devices help to coordinate the heart's pumping action and improve blood flow. They can also speed up a heart that is beating too slowly.

The CRT pacemaker with defibrillation therapy (CRT-D) also offers the ability to detect and treat dangerously fast heart rhythms, which some individuals with a damaged heart muscle may be at risk for developing. Your doctor will determine which CRT device is appropriate for your medical condition.

Cardiac resynchronization therapy improves symptoms, quality of life (QoL), exercise tolerance, and reduces hospitalizations in patients with advanced HF and prolonged electrical activation (i.e. increased QRS duration). The results of a recent study showed that patients with mechanical dyssynchrony detected by tissue Doppler imaging but a normal QRS duration did not benefit from CRT. While the results of outcome trials of CRT in patients with a normal QRS duration are negative including Echo-CRT, a QRS ≥120 ms remains as one of the criterion for selecting patients for CRT. Patients with a QRS duration >120 ms represent 31% of HF patients in a recent trial. The indications for CRT have been summarized in a recent update of ESC guidelines on devices in heart failure.

Although CRT is indicated in patients with a prolonged QRS duration, up to 60% of patients with HF have a normal QRS duration. According to European registries published recently, even in the broad QRS population, those cared in hospital cardiology setting and meeting the current indications to CRT therapy were 6%, and among them approximately one-third only were actually implanted with a CRT device. Therefore, although the last ESC guidelines on HF extended the indications to CRT in chronic heart failure, a substantial proportion of patients remain either not eligible for CRT or simply do not respond. At a time when pharmacological therapy for HF has made only little advances, it is appropriate to explore whether new device-based therapies have anything else to offer to patients with heart failure.

The CCM system consists of a can and three pace-sense electrodes. Two of them are fixed to the mid-septum and the third one to the right atrium. The impact of a HF therapy on myocardial energetics is an important factor to consider in long-term safety and efficacy. Therefore, the acute effects of CCM on myocardial energetics were investigated in a clinical study in which myocardial oxygen uptake (MVO_2) and LV dP/dt_{max} were measured in 9 patients exposed to acute CCM signals. In this study, acute CCM was associated with an increase in dP/dt_{max} from ~630 to ~800 mmHg/s (an ~20% increase). Despite an acute increase in contractility, there was no detectible increase in myocardial oxygen consumption. These data were compared with those of Nelson et al., who had also measured MVO_2 and dP/dt_{max} during temporary RV and biventricular pacing (BIV) pacing. In this study, contractility was increased first by applying CRT and then dobutamine to achieve a comparable increase in dP/dt_{max}. As expected from its effects on calcium cycling, dobutamine increased both dP/dt_{max} and MVO_2. In contrast, CCM increased dP/dt_{max} but not MVO_2. Thus, like CRT, the acute, modest increase in contractility achieved by CCM does not increase energy demands. In addition to acute hemodynamic effects noted above, improvement in global ventricular function has also been reported during chronic CCM signal application. In one study, 30 patients with ejection fraction (EF) <35% and NYHA III symptoms despite OMT underwent three-dimensional echocardiography at baseline and 3 months after CCM treatment. Left ventricular ejection fraction (LVEF) increased by 4.8 ± 3.6% and LV end-systolic volumes decreased by 11.5 ± 10.5%, respectively. These findings indicate that LV reverse remodelling could be achieved by CCM in the background of optimum medical therapy.

Combining Cardiac Contractility Modulation with Cardiac Resynchronization Therapy

As discussed above, CCM signals applied in the acute setting to HF patients simultaneously receiving CRT provide additive effects on LV contractility indexed by dP/dt_{max}. In view of the fact that symptoms persist in more ≥30% of patients with prolonged QRS duration receiving CRT, it can be postulated that addition of CCM treatment may provide an option for these patients. The initial experience of combining CCM in a CRT non-responders has been published.

It was demonstrated that the implantation procedure is technically feasible, that the OPTIMIZER and CRT defibrillator (CRT-D) devices can coexist without interference and

that acute hemodynamic and clinical improvements can be observed. These preliminary results, however, have to be confirmed in a prospective study that is underway to systematically investigate the effects of CCM in CRT non-responders.

Clinical Perspectives

Two large-scale studies have validated the safety and suggested the effectiveness of CCM therapy. Results of these trials show that CCM improves exercise tolerance as indexed by peak VO_2. Other indices of exercise tolerance (e.g. 6 min hall walk) and QoL (NYHA class and MLWHFQ) have also been shown to improve. Data from both clinical trials suggest that mortality rates are unaffected by CCM therapy. However, the aim of these studies was to demonstrate an absence of increase in mortality as a safety end-point and was not powered to show a mortality benefit. The level of recommendation would be substantially higher if a gain in mortality can be demonstrated. In this respect, a specific subgroup of HF patients (EF ≥25%) is more likely to respond favourably. Moreover, more research is probably required to determine the optimal pacing configuration (single or biphasic stimuli, optimal delay from the pacing spike, optimal duration of each phase, and optimal amplitude of the signal), the optimal daily duration of application, the optimal localization of the pacing sites, and the optimal number of pacing sites to gain the maximal benefit from this therapy. The potential interest of CCM in early stages of HF has not been investigated.

Required Technical Improvement

Some technical limitations should be solved in the future—(i) with the last version of the device, CCM cannot be delivered in patients with AF or frequent ectopy, as it is designed to inhibit CCM delivery on arrhythmias and relies on detection of a P-wave. A future device is supposed to incorporate an algorithm that does not rely on P-wave detection and therefore could be used in patients with AF. (ii) The development of a device combining CCM with implantable cardioverter defibrillator (ICD) functions would be desirable in this population of HF patients. Future studies will be required to define whether CCM is additive to CRT pacemaker or CRT-D in patients with wide QRS. This would be facilitated by the development of a single device that incorporates pacing, antitachycardia therapies, and CCM. (iii) A simple peri-implantation method to guide lead positioning would be desirable, beyond the invasive LV dP/dt_{max} measurement.

Neuromodulation

Heart failure is associated with significant perturbances of the autonomic balance with predominant sympathetic activation over the parasympathetic system. Several indirect markers of cardiac vagal tone like heart rate variability, heart rate turbulence, baroreflex sensitivity are suppressed in CHF which in turn is predictive for a worse outcome of CHF. Likewise, an increase of cardiac vagal tone by pharmacological β-receptor blockade has substantially improved functional status and survival of HF patients. Cardiac vagal tone is controlled by preganglionic parasympathetic cardiac neurons mainly residing in the nucleus ambiguus and the dorsal motor nucleus of the brainstem. Of note, parasympathetic cardiac efferent neurons in the nucleus ambiguus are intrinsically electrically silent, thus needing presynaptic input to generate and modulate parasympathetic efferent activity and tone. Such input is likely provided by sensory afferent fibres from arterial baroreceptors or respiratory sensory neurons, but spinal cord afferent fibres may also connect to the brainstem and modulate cardiac vagal tone Thus, attempts to therapeutically increase the cardiac parasympathetic tone by electrical neural stimulation may operate at any part of this integrative circuit. This has led to four neurostimulation approaches, two of which are focusing on reflex activation of the parasympathetic tone and sympathetic inhibition via afferent fibre stimulation [spinal cord stimulation (SCS), carotid sinus nerve stimulation], while two are concentrating on efferent parasympathetic stimulation (cervical vagal and intracardiac vagal stimulation).

Spinal Cord Stimulation

Preliminary work suggests some benefits from neuromodulation with SCS in HF patients. Spinal cord stimulation has been used for over 40 years in the management of chronic intractable pain. According to the American Association of Neurosurgical Surgeons, as many as 50,000 neurostimulators are implanted worldwide every year. Among multiple indications, the benefits have been confirmed in patients with refractory angina associated with end-stage CAD and in the absence of CAD (syndrome X) Positive effects have also been demonstrated in the peripheral vascular beds—patients with severe pain due to distal atherosclerosis, in Raynaud's disease, and at the level of cerebral vasculature.

Mechanisms of Action

Spinal cord stimulation compared positively with surgical and laser endomyocardial revascularization in patients with severe refractory angina associated with severe CAD without any increase in adverse ischemic events. This suggests that the improvement in symptoms and the clinical condition of these patients was mediated only partially through the 'gate-control' mechanisms described by Melzack and Wall in 1965. The involved mechanisms remain incompletely understood and appear to be far more complex than just the suppression of the nociceptive influx associated with myocardial ischemia: SCS seems to affect the balance between oxygen demand and supply. Since there is little evidence that SCS improves the coronary blood flow in ischemic patients, other factors acting in the balance between oxygen requirements and supplies have to play an important role. Spinal cord stimulation applied at the low cervical (C7–C8) and/or high thoracic (T1–T6) level exerts effects through reflex activation of the vagus nerve and sympathetic.

Overall, the cumulated effects on both the sympathetic and the parasympathetic system seems to be a re-equilibrium of the balance in favour of the latter. Other positive effects via the cytokines and the NO/NOS system have been identified and there may even be some direct protective mechanisms on the myocardium during ischemia (Figs 9.6–9.9 and Table 9.3).

Clinical Perspectives

Spinal cord stimulation, via complex mechanisms, appears promising in preclinical experiments to improve the systolic function of the LV and to decrease the ventricular arrhythmias associated with this condition. According to Clinicaltrials.org, there are at the present time two ongoing clinical studies that are directly addressing the role—and possible benefits—of SCS in severely afflicted HF patients. SCS-HEART is a nonrandomized feasibility study that aims to determine the safety of SCS in 20 patients with a LVEF between 20 and 35%, in NYHA functional class III, and who already have an ICD implanted. Results should be available in the second part of 2014. On the other hand, DEFEAT-HF (sponsored by Medtronic) is a single blind randomized study involving similar patients but that will compare SCS 'ON' *vs* 'OFF' in 250 recipients. Results are also expected for the end of 2014. Until these studies are completed, it remains impossible to recommend this therapy in HF patients outside of the current recognized indications.

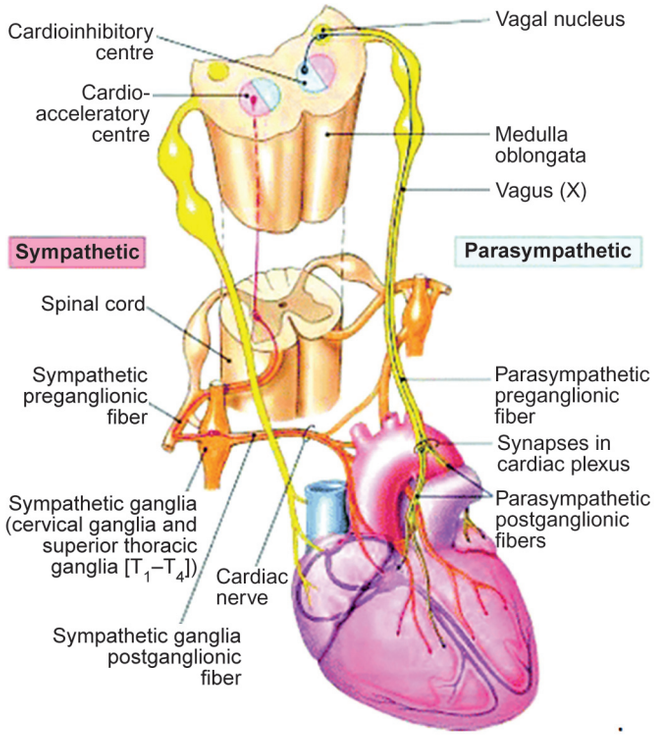

Fig. 9.6: Parasympathetic and sympathetic innervations of the heart. Functional anatomy—efferent preganglionic vagal nerve (parasympathetic) fibres course from the brainstem towards the heart and connect with postganglionic cells in circumscript epicardial ganglionic plexus. Sympathetic preganglionic fibres (orange color) switch to postganglionic fibres inside the stellate ganglion. Major afferent inputs to the central autonomic centres are the carotid sinus nerves and spinal cord afferents

Carotid Sinus Nerve Stimulation

Baroreceptors are embedded into the wall of arterial vessels and can be preferentially found in the aortic arch at the



Fig. 9.7: CardioFit is an implantable electrical stimulation device designed to restore balance in the autonomic nervous system and improve heart function in patients with HF

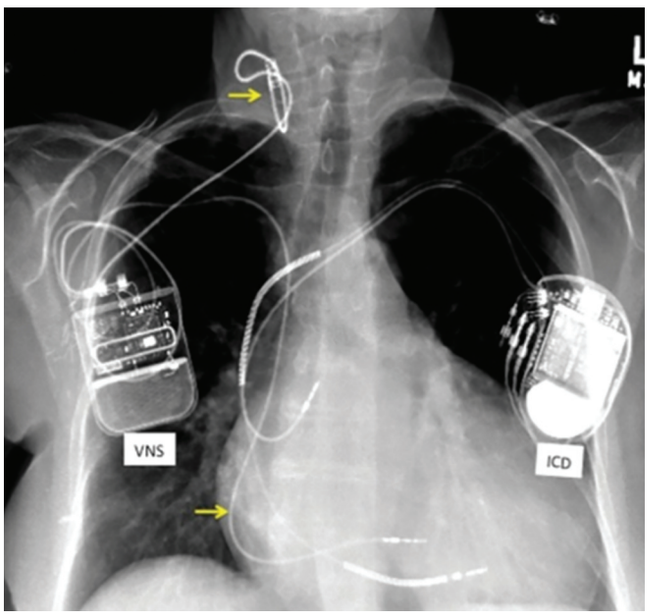

Fig. 9.8: X-ray of a patient with a vagal nerve stimulator with a previously implanted implantable cardioverter defibrillator. The arrows show a lead attached to the vagus nerve on the right side and an additional right ventricular sensing lead connected to the vagal nerve stimulator device

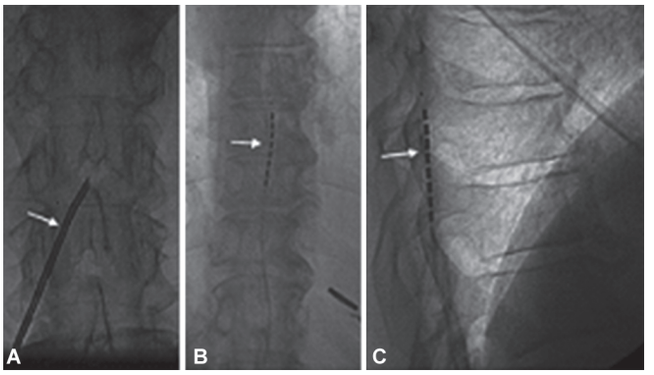

Fig. 9.9: Spinal cord stimulation—single-lead placement. (A) Introducer (arrow) is directed into the epidural space. (B and C) anteroposterior and lateral views demonstrate the lead in the posterior epidural space in the midthoracic region at approximately T1 (arrows)

Table 9.3: Major findings reported with SCS

Spinal cord stimulation has been shown to have positive impact on cardiac ischemia due to CAD
1. The mechanisms involved go beyond suppression of the nociceptive stimuli. 2. SCS has limited impact on coronary blood flow, therefore the mechanisms must lie somewhere else. 3. SCS has a profound positive impact on the cardiac sympathetic/parasymapathetic balance. 4. SCS also affects positively the NO/NOS and cytokines system at the myorcardial level.
Spinal cord stimulation has shown some effects on LV function and ventricular arrhythmias
1. One preliminary report on four HF patients who improved clinically with SCS. 2. SCS was associated with smaller deterioration of LVEF due to adenosine administration in patients with multivessel CAD. 3. SCS was associated with better invasive hemodynamic evaluation in patients with normal LV function. 4. SCS was associated with reduced risk of ventricular arrhythmias and LV function improvement in animal models of HF.

origins of the brachiocephalic or left subclavian artery, in the brachiocephalic artery at its bifurcation into the right subclavian and right common carotid artery, in the carotid sinuses, along both common carotid arteries, and in both common carotid arteries at the origin of the superior thyroid artery. They respond to changes in arterial pressure and mediate their signals via afferent rapid conducting (2.5–60 m/s) myelinated A fibres and slow conducting (<2.5 m/s) nonmyelinated C fibres to the brainstem where they connect to efferent vagal neurons. A-type receptors respond to normal arterial pressures and are regularly discharging at high frequency (>100 Hz) synchronously to the pulsatile pressure wave. By contrast, C-type baroreceptor respond to higher threshold values of the mean arterial pressure with irregular firing at lower frequency of 20–30 Hz. Increases of arterial blood pressure elicit a reflectory activation of efferent vagal fibres resulting in a decrease of the sinus heart rate. The baroreflex activation is considered as powerful contributor to the baseline parasympathetic tone.

Mechanisms of Action

Electrical stimulation of the baroreceptor fibres (carotid sinus nerve fibres) elicits a graded response decrease of heart rate and arterial pressure via parasympathetic efferent activation and sympathetic withdrawal and has recently been clinically introduced for treatment of resistant arterial hypertension. The potential of electrical carotid sinus nerve stimulation to shift the autonomic balance towards a higher parasympathetic tone has also been investigated in HF models. In fact, chronic low-intensity carotid sinus stimulation, which lowers blood pressure by only 10–15 mmHg and which does not critically decrease heart rate was able to improve survival in dogs with pacing-induced HF In addition, LV systolic and diastolic function improved due to reverse LV geometric and interstitial remodeling. In parallel, the downregulation of α1 receptor density in CHF was almost normalized to control levels and serum catecholamine levels declined which may be taken as evidence for a direct or reflectory decrease of the systemic sympathetic tone in these models (Fig. 9.10).

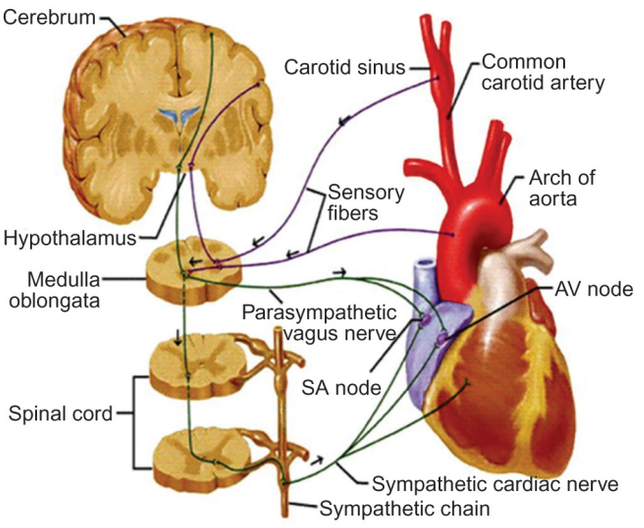

Fig. 9.10: Baroreceptor reflexes. Congestive heart failure is a syndrome that is usually initiated by a reduction in pump function of the heart, i.e. a decrease in cardiac output. Initially, a reduction in cardiac output leads to unloading of baroreceptor reflex that, in turn, increases heart rate through vago-sympathetic mechanisms and total peripheral resistance via an increase in sympathetic outflow to vascular beds. During human HF, this baroreflex is profoundly suppressed and worsens with deterioration of CHF. Thus, electrical stimulation of afferent carotid sinus nerves, which connect baroreceptors to the brainstem may evolve as tool for increasing cardiac vagal tone during HF

Clinical Data

The Rheos system was the first baroreceptor stimulation system by CVRx implanted in hypertensive patients. The Rheos system was so far evaluated in three multicentre clinical studies in patients with resistant hypertension—the DEBuT-HT/DEBuT-HET in Europe and the Rheos Feasibility Trial and Rheos Pivotal Trial which mostly included patients in the USA. The Rheos Pivotal trial is in long-term follow-up by now. The randomized part of the trial with a 12-month blinded follow-up was published in 2011: 265 patients with resistant hypertension received the device and were either randomized to immediate BAT or delayed BAT following the 6-month visit. Three of the five prespecified coprimary endpoints were met—long-term sustained response to baroreceptor activation therapy, with 88% responders after 12 months of follow-up, incidence of short-term AEs (6-month follow-up), and long-term AEs (12-month follow-up). The study did not meet the endpoints for acute responders (54 *vs* 46% responders after 6-month follow-up) and procedural safety (event-free rate 74.8%). A majority of these events were related to the carotid sinus lead placement and involved transient or permanent nerve injury that occurred during the implant. The majority (76%) of procedure-related AEs resolved completely (Figs 9.10 and 9.11).

To date, there exist no randomized clinical data evaluating the effectiveness of BAT in patients with systolic HF. In addition to experimental data, several sub-studies and single-centre data indicated beneficial physiological effects of BAT beyond just blood pressure reduction.

Cervical Vagal Nerve Stimulation

The efferent cardiac parasympathetic signalling chain comprises preganglionic parasympathetic neurons originating in the brainstem, which course inside the vagal nerve and connect via nicotinergic acetylcholine receptors to postganglionic neurons, which are aggregated in circumscript cardiac ganglionic plexus inside the heart. Postganglionic fibres then innervate the cardiac target cells via muscarinergic acetylcholine receptors. During CHF, the density of cardiac muscarinergic receptors is increased, which is most probably due to an adaptive upregulation secondary to a decreased efferent vagal input. However, the postganglionic vagal nerve transmission seems to be intact in HF; selective electrical stimulation of post-ganglionic vagal nerve fibres to the sinus node leads to a larger decrease of the sinus rate in HF dogs than in controls, which would be in line with an increased number of muscarinergic receptors in HF. By contrast, electrical stimulation of presynaptic cervical vagal fibres led to a smaller decrease of the sinus rate in CHF animals as compared with control animals. Thus, pre-to-post ganglionic parasympathetic efferent neurotransmission via nicotinergic acetylcholine receptors seems to be impaired during CHF. Importantly, these nicotinergic receptors are agonist dependent and chronic exposure to a nicotinic agonist during HF has been shown to re-establish efferent parasympathetic neural control of the sinus node. These experiments form a pathophysiological rationale to apply electrical preganglionic cervical vagal nerve stimulation to re-establish the diminished cardiac vagal tone in CHF (Figs 9.12 and 9.13).

Mechanisms of Action

Several studies in various chronic HF animal models have shown a reduction of the progression of HF and a survival benefit with cervical vagal nerve stimulation. Major contributing mechanisms are detailed as follows:

Antiarrhythmic effects: Vagal nerve stimulation increases the ventricular refractory period in humans, leads to a prolongation of the epicardial action potential duration, and decreases ventricular vulnerability to ventricular fibrillation. These electrophysiological effects may contribute to its potent antifibrillatory effects as demonstrated during cervical vagal nerve stimulation experiments in postinfarction animal models. In addition, vagal nerve stimulation in HF reduces the loss of Cx43, which may prevent proarrhythmic conduction delays and dispersion of action potential duration.

Rate slowing effects: Vagal nerve stimulation exerts profound negative chronotropic and dromotropic effects. Since an increased heart rate is associated with adverse prognosis in CHF, a reduction of heart rate both in SR and AF might contribute beneficial therapeutic effects in CHF.

Antifibrotic effects: In a coronary microembolization-induced HF model, chronic cervical vagal nerve stimulation



Fig. 9.11: (A) The principle of carotid sinus nerve stimulation. The device is implanted via the right side and is connected to a patch electrode fixed on the right-sided carotid sinus. (B) An example of a carotid sinus nerve stimulator. The device carries one electrode connected to the patch electrode. (C) Demonstrates a patch electrode which will be fixed to the carotid sinus nerve

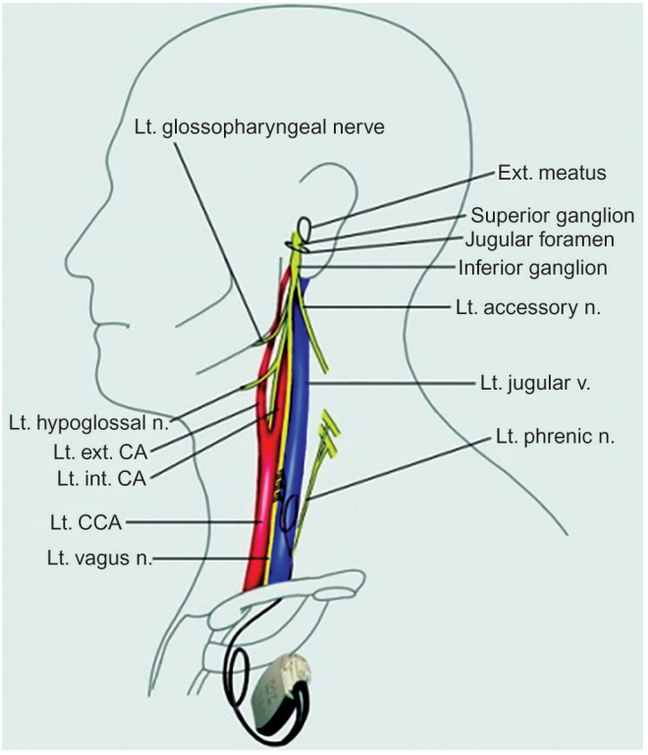

Fig. 9.12: Anatomical relationship between vagus nerve and surrounding structures and location of VNS

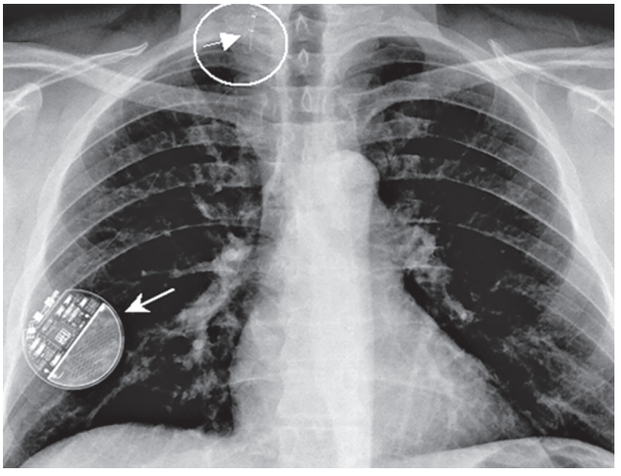

Fig. 9.13: Plain thoracic X-rays displaying the vagus nerve stimulator (VNS) implanted on the right side in a patient. Encircled upper arrow points to the VNS around the right vagus nerve trunk. VNS generator is positioned at the right paraaxillary region (arrow)

has been shown to decrease ventricular replacement fibrosis and to blunt the development of CHF-associated cellular hypertrophy of remaining myocytes.

Anti-inflammatory effects: Vagal nerve stimulation has potent anti-inflammatory effects. Recently, vagal nerve stimulation was shown to blunt HF-associated increases of tumor necrosis factor-α, interleukin-6, and C-reactive protein in two animal models of HF.

Reverse remodelling: Vagal nerve stimulation decreases ventricular end-systolic and end-diastolic diameters and improves LVEF. Chronic vagal stimulation has also been shown to reduce NT-proBNP levels in a dog HF model and biventricular weight in a rat HF model.

Clinical Data

The first multicentre, open-label phase II, two-staged study (8-patient feasibility phase plus 24-patient safety and tolerability phase) enroled 32 NYHA Class II–IV patients (age 56 + 11 years, LVEF 23 + 8%). Right cervical vagal nerve stimulation (VNS) with an implantable system started 2–4 weeks after implant, slowly raising intensity; patients were followed 3 and 6 months thereafter with optional 1-year follow-up. Overall, 26 serious AEs occurred in 13 of 32 patients (40.6%), including three deaths and two clearly device-related AEs (postoperative pulmonary edema, need of surgical revision). Expected nonserious device-related AEs (cough, dysphonia, and stimulation-related pain) occurred early but were reduced and disappeared after stimulation intensity adjustment. There were significant improvements ($P = 0.001$) in NYHA Class QoL, 6 min walk test (from 411 + 76 to 471 + 111 m), LVEF (from 22 + 7 to 29 + 8%), and LV systolic volumes ($P = 0.02$). These improvements were maintained at 1 year.

Several scientific articles have summarized the use of cervical vagal nerve stimulator (CVS) in patients with CHF. Naturally, the data provided in those articles are limited, due to the small patient cohort and the nonrandomized nature of first in man and safety and feasibility studies; however important considerations can be drawn from them:

- Patients with mild-to-moderate HF can tolerate the higher current amplitudes and other parameters used in chronic vagal stimulation vs the parameters used for treatment of epilepsy.
- Vagal stimulation may generate side effects like hoarseness, voice alteration, and increased cough. The majority of side effects are related to the underlying disease or a multitude of comorbidities.
- In patients with both CVS and ICD, no interferences from vagal stimulation were recognized by the ICD nor were detectable on the intracardiac electrogram of the device.
- CVS increased parasympathetic tone of subjects with HF (as measured by heart rate variability on 24-hour Holter recordings; and as inferred by reduction of resting heart rate).
- Vagal stimulation improved subjective, as well as objective clinically relevant parameters of functional class, quality of life, submaximal exercise capacity, and cardiac structure and function in a first clinical study.

Unresolved Issues

Atrial Proarrhythmia

At the atrial level, an increased vagal tone substantially shortens the atrial refractory period and increases the heterogeneity of refractory periods in the atria. Whether

this might promote the occurrence of AF especially in HF patients with a diseased atrial substrate is unknown. Experimental evidence in healthy dogs, however, suggests that the occurrence of AF during cervical vagal nerve stimulation depends on the intensity of vagal stimulation with no AF occurrence at lower level stimulation. Data on the occurrence of AF during vagal stimulation in HF patients need to be gathered prospectively (Fig. 9.14).

Selectivity of Neural Stimulation

The cervical vagal nerve contains efferent and afferent fibres coursing not only to the thoracic but also to or from the abdominal viscera. So far, the issue of concomitant stimulation of efferent parasympathetic fibres to the gastrointestinal tract has not yet been thoroughly investigated. Such inadvertent stimulation might increase gastric acid secretion or increase intestinal motility. Likewise, afferent electrical stimulation or block of the vagal nerve below the diaphragm has been shown to decrease food intake and to reduce weight gain. Since these fibres potentially course through the cervical vagal nerve inadvertent stimulation or block of these fibres may occur during vagal nerve stimulation for HF possibly inducing weight loss masking as cardiac cachexia.

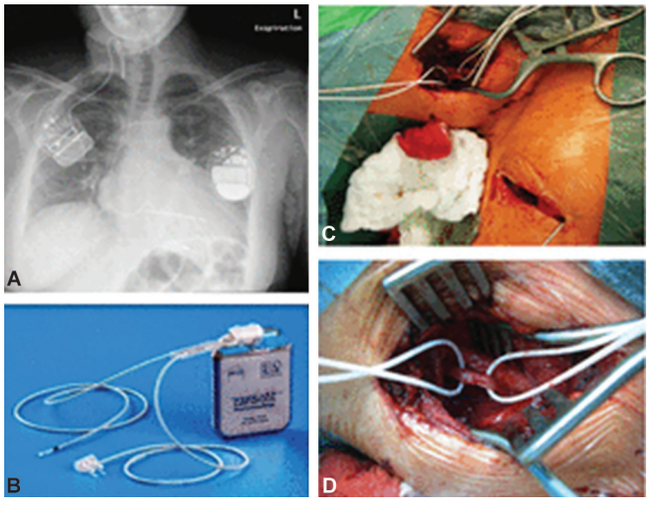

Fig. 9.14: (A) Chest X-ray of an implanted cervical vagal nerve stimulator in a patient with severely reduced LV systolic function. The device has been implanted via the right side and consists of a ventricular sensing lead and a cervical vagal nerve electrode. On the left side an ICD had been previously implanted. (B) Example of a cervical vagal stimulator. The device carries two electrodes—one conventional RV screw-in pace/sense electrode monitors the heart rate during vagal nerve stimulation, while the other cuff electrode is wrapped around the cervical vagal nerve. (C) Local implantation site of the CVS; there are two incisions, one for exposure of the cervical vagal nerve and a second one for implanting the RV electrode. The vagal electrode is tunnelled subcutaneously to the impulse generator, which is implanted below the collarbone. (D) Exposed cervical vagal nerve

Intracardiac Atrioventricular Nodal Vagal Stimulation

Thirty to forty percent of patients with CHF eventually will develop AF. Rapid ventricular rates during AF may further deteriorate HF or decrease the degree of LV resynchronization in patients with cardiac resynchronization devices and may ultimately lead to inappropriate shock delivery in up to 5% of ICD recipients. Long-term selective atrioventricular (AV) nodal vagal stimulation for ventricular rate control has been developed as potential adjunctive treatment modality for these patients (Figs 9.15–9.18).

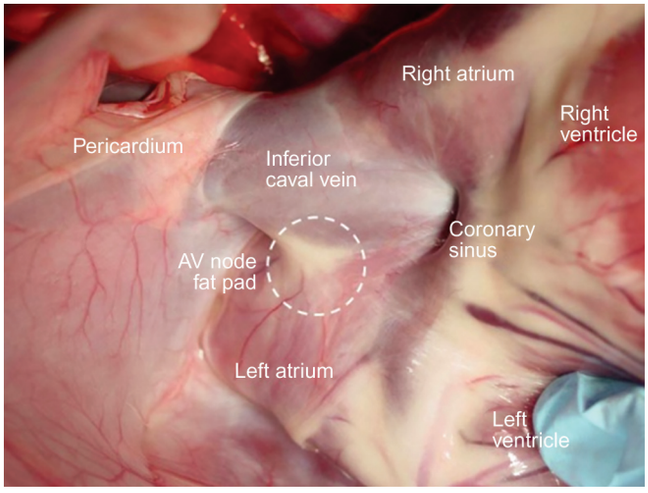

Fig. 9.15: Anatomical location of the atrioventricular node fat pad. The diagram uses as a background a real anatomical epicardial image of heart. The heart has been lifted up towards the head to show the anatomical position of the epicardial AV node fat pad (dashed circle)

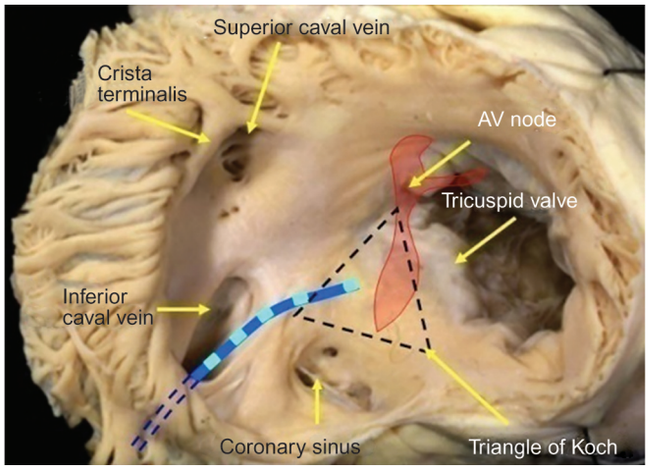

Fig. 9.16: Vagal stimulation site for endocardial approach in the human heart. A schematic diagram showing the site at the posterior right atrium at which optimal AV conduction delay could be achieved by electrical postganglionic vagal stimulation delivered with an endocardial catheter inserted through the inferior caval vein. Anatomical image of endocardial view of human right atrium provided by *Prof. RH Anderson*)

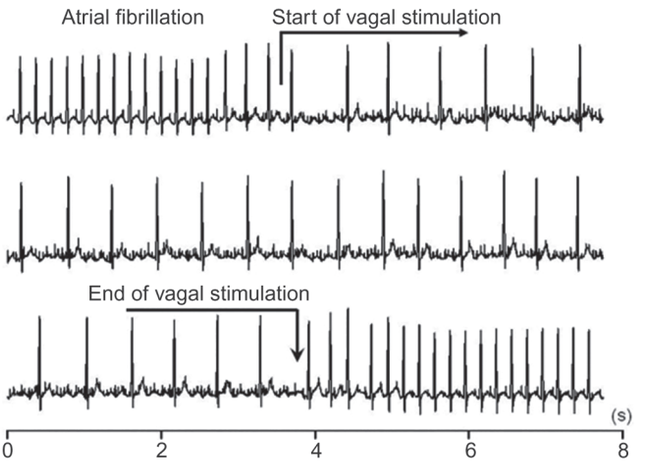

Fig. 9.17: Surface ECG recordings from a chronic dog implanted with an AV node vagal stimulation device. The top trace shows at the beginning a rapid ventricular rate (>240 bpm) during AF without vagal stimulation. The arrow indicates the start of vagal stimulation and the immediate resultant slowing of the ventricular rate. The middle trace shows the maintenance of slow ventricular rate (105 bpm) during continuous vagal stimulation. The bottom trace shows the prompt restoration of the initial (fast) ventricular rate after vagal stimulation was terminated (arrow)

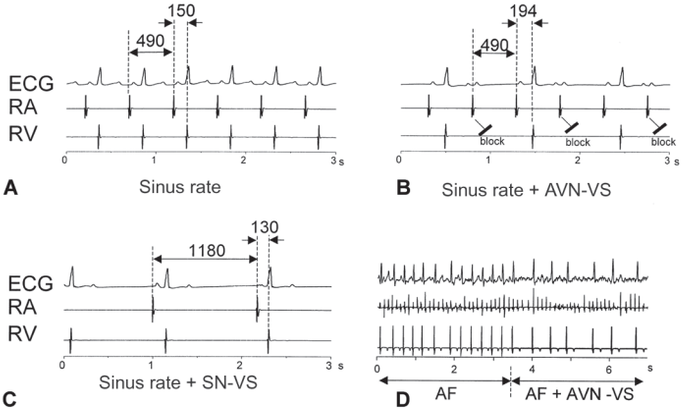

Fig. 9.18: Effects of subthreshold epicardial stimulation of the fat pads. (A) Control sinus rate. Numbers refer to the sinus cycle length and the AV conduction time, respectively. (B) Stimulation of the SN fat pad. Note the strong chronotropic effect and the associated shortening of the control AV conduction time. (C) Stimulation of the AVN fat pad. There was no change in the control sinus cycle length, whereas AV conduction was strongly depressed and 2:1 Wenckebach periodicity was observed. (D) Atrial fibrillation (AF) alone (left), followed by AF in combination with AVN fat-pad stimulation (right). Note the slowing of the ventricular rate during vagal stimulation. ECG=electrocardiogram; RA=right atrium; VS=vagal stimulation

Mechanisms and Experimental Models

Postganglionic cardiac vagal fibres, which preferentially supply the AV node reside in an inferior right ganglionated plexus (IRGP) at the postero-inferior interatrial septum.This makes them amenable to stimulation from the endocardial surface, thus resulting in a graded response negative dromotropic effect. Chronic stimulation of the IRGP in animal models provides reliable and well-tolerated ventricular rate control in dogs and has been shown to be hemodynamically superior to His bundle ablation and RV pacing probably because ventricular conduction over the His–Purkinje system is maintained.

Technology and Implant Technique

The IRGP is located at the epicardial surface of the heart between the ostium of the coronary sinus and the entrance of the inferior vena cava. For chronic electrostimulation of this plexus, atrial pacing leads of current technology can be screwed into the IRGP from the right atrial endocardial site at the posteroinferior interatrial septum either by using specifically shaped guiding catheters or manually shaped conventional mandrins.

Clinical Data

Recently, the feasibility of such an approach was shown in a series of chronic human implants in HF patients with AF. A prospective multicentre study (AVNS: AV node stimulation study, which investigates whether short-term probatory AV nodal vagal stimulation may avoid inappropriate shock delivery in patients with resynchronization defibrillators is ongoing.

Electrical Determinants of Neurostimulation

Electrical stimulation of parasympathetic pre- or postganglionic efferent fibres obeys the same fundamental laws as myocardial electrostimulation with the exception that the chronaxie time of 180 ms is shorter. In contrast to the myocardial action potential, the action potential of neurons is very short lasting only 10–20 ms. Thus, transmitter release and physiological effects may be elicited by electrical stimulation at higher frequencies, which typically is set to 20–50 Hz during cervical vagal stimulation for seizures or depression, 100 Hz for carotid sinus stimulation, or 4–20 Hz for cervical vagal stimulation in HF. For postganglionic efferent parasympathetic stimulation the frequency-response curve is bell-shaped with an optimum at 40 Hz. Since most stimulated nerve structures contain afferent and efferent autonomic fibres with varying fibre diameter and conduction velocities, efforts have been undertaken to preferentially stimulate efferent fibres. For example, cervical vagal nerve stimulation for treatment of HF aims to stimulate efferent parasympathetic B fibres coursing towards the heart but tries to avoid afferent A and C fibre excitation. This can be achieved by hyperpolarizing the nerve fibres at the anode thus preventing excitation and simultaneously depolarizing fibres at the cathode. Since larger afferent A fibres (diameter 520 µm) are more sensitive to hyperpolarization than smaller efferent B fibres (13 µm) inside the vagal nerve preferential efferent stimulation can be accomplished. Besides electrode configuration, the applied stimulus strength also affects differential recruitment of A–C fibres and changes the frequency dependence of afferent neural stimulation. Finally, the application of biphasic impulses may bare the

benefit of decharging the membrane with the second phase of the impulse thus preventing damage to the neurocytes.

Implantable Hemodynamic Monitoring Devices

Clinical management to prevent acute decompensated heart failure (ADHF) and/or hospitalization in ambulatory HF patients remains challenging. There is an urgent need to develop strategies to reduce hospitalizations and re-admission rates for HF. Frequent monitoring of physiological data is imperative in the management of HF. The development of wireless and remote technology makes it possible to frequently monitor and transfer data via telemonitoring. The concept of telemonitoring involves patient-activated automatic devices which provide physiological parameters such as weight, blood pressure, heart rate, rhythm, and activity logs. Results of studies using telemonitoring have been contradictory. A meta-analysis demonstrated that telemonitoring may provide better outcomes compared with usual care, with a reduction in mortality and HF hospitalizations. Recently, the value of telemonitoring has been challenged by two randomized clinical trials. The results of the Telemedical Interventional Monitoring in Heart Failure (TIM-HF) trial showed no significant difference in all-cause mortality (primary endpoint) or in the composite of cardiovascular death or HF hospitalization. The study of Chaudhry et al. demonstrated that telemonitoring failed to reduce HF hospital admissions, duration of hospital stay, or the frequency of admissions. One explanation might be the insensitivity of daily weight monitoring to predict HF hospitalization, which is >20%. Another strategy is the use of cardiac implantable devices (defibrillators and CRT) to stratify the risk of ADHF based on a single parameter as thoracic impedance or heart rate variability, or a combination of parameters. These parameters, single or combined, have a sensitivity of 60–70%, a positive predictive value up to 7.8%, and false-positive alarms ranging from 1.8 to 2.7 per patient-year of monitoring. Although these parameters enable physicians to identify patients at increased risk of ADHF, they do not impact patient outcomes and are not sufficiently accurate to adjust treatment. A new approach to monitor the status of ambulatory HF patients and preventing potential hospitalizations may involve implantable devices providing real-time hemodynamic data to the clinician. Device companies began to develop new implantable devices designed to collect hemodynamic data. These investigational devices include RV, left atrial pressure (LAP), and pulmonary artery pressure (PAP) sensors (Figs 9.19 and 9.20).

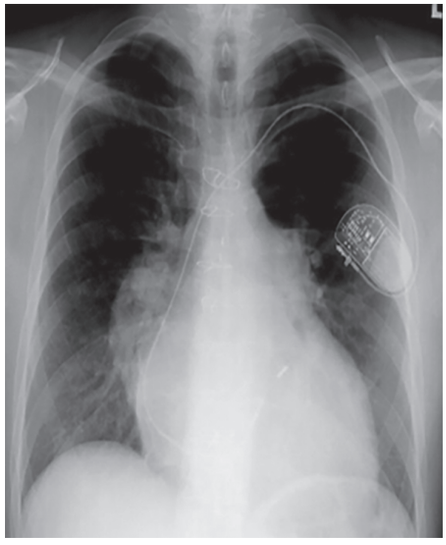

Fig. 9.19: The implant procedure of the Chronicle implantable hemodynamic monitoring is similar to that of a cardiac pacemaker, whereby the device is positioned subcutaneously in the pectoral area with the lead positioned transvenously in the right ventricular outflow tract. Average implant time is >1 hour

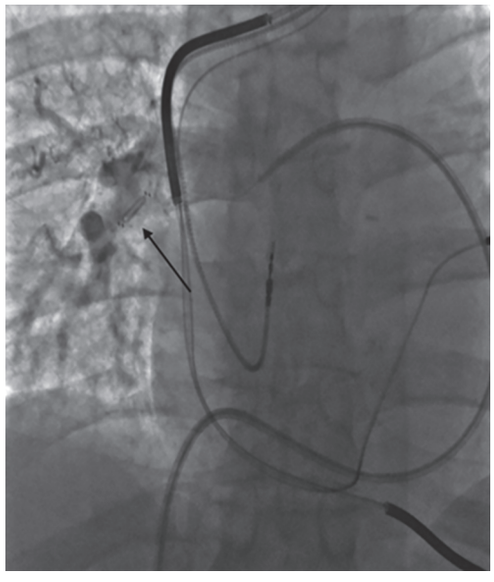

Fig. 9.20: Heart failure sensor implanted through right heart catheterization in the right pulmonary artery (arrow), although left is the preferred location. Flow is noted around the sensor on venogram

Right Ventricular Pressure Monitoring

The Device, Implantation, and Monitored Data

The Chronicle (model 9520, Medtronic Inc.) is an implantable hemodynamic monitor. The system consists of a specialized transvenous lead that has a sensor incorporated near the tip to measure intracardiac pressure and a programmable device similar in size and shape to a pacemaker. Details of the components have been previously described. The device is able to monitor and telemeter systolic and diastolic RV pressure, RV dP/dt (positive and negative), to estimate pulmonary artery diastolic pressure, to monitor heart rate and patient's activity, and to measure core body temperature. In addition, continuous remote monitoring of data is available. The implantation procedure is similar to that of a single-lead pacemaker. The device is positioned subcutaneously in the pectoral area and the lead is placed transvenously in the RV outflow tract or septum. The patient is furnished with a small external device, which aids in correcting for barometric pressure.

The monitor capabilities includes pressure sensing circuitry and a memory to store continuous pressure trends, as well as specific triggered events such as bradyarrhythmias, tachyarrhythmias, or patient-activated episodes. The device continuously measures and stores RV systolic, diastolic, and pulse pressure, estimated pulmonary arterial diastolic pressure (ePAD), RV dP/dt, pre-ejection interval, and systolic time interval. The ePAD is defined as the RV pressure at the time of pulmonary valve opening or maximal RV dP/dt and has been shown to correlate with PA diastolic pressures (r = 0.87 at baseline and 1 year), thus reflecting LV filling pressure. In addition, heart rate, patient activity levels, and central venous temperature are also monitored and stored.

Clinical Perspectives

In March 2007, FDA's circulatory system devices panel voted against the approval of Chronicle implantable hemodynamic monitor because its use was not proved to significantly improve clinical outcomes in the COMPASS-HF randomized, controlled trial. The following step has been the planning of a trial designed to test the potential usefulness of combining the hemodynamic monitoring capabilities of an implantable monitoring device with an ICD in patients at risk of sudden cardiac death. Indeed, a new trial, REDUCEhf, was designed to enrol 850 patients (then increased to 1300) with indication for an ICD (NYHA functional class II or III with reduced LVEF) to test the hypothesis that the use of RV pressure-guided patient management would reduce HF-related events (hospitalization and emergency department or urgent clinic visit requiring parenteral therapy) Because of technical complications, REDUCEhf was prematurely ended after enrolment of 400 patients. Data analysis showed no benefit from haemodynamic monitoring and a lower than expected event rate. Demonstrating the efficacy of HF disease management programmes using RV pressure monitoring was particularly difficult and many issues appear to condition the ability to demonstrate a substantial clinical benefit. These factors include the degree of HF severity in the tested population, the quality of comparative usual care (with a potential low-external validity if the trial is managed by highly specialized centres), the choice of the primary endpoint (the need for medical visits may actually increase during continuous monitoring in view of earlier detection of worsening HF, but this may imply avoidance of subsequent hospitalizations), as well as the specific characteristics of the disease management programme adopted. Moreover, it is possible that a substantial improvement in patient care will require to couple the information provided by an implantable hemodynamic sensor to an effect or capable of promptly instituting an appropriate therapy, thus 'closing the loop' and limiting the need for interventions of healthcare providers.

Left Atrial Pressure Monitoring

Patients admitted for decompensated HF usually have elevated LAP causing pulmonary congestion and edema. The rise in LAP is usually gradual and precedes the onset of symptoms. Therefore, monitoring of LAP has the potential to forecast and abort HF decompensation by adjusting drug therapy (Figs 9.21 and 9.22).

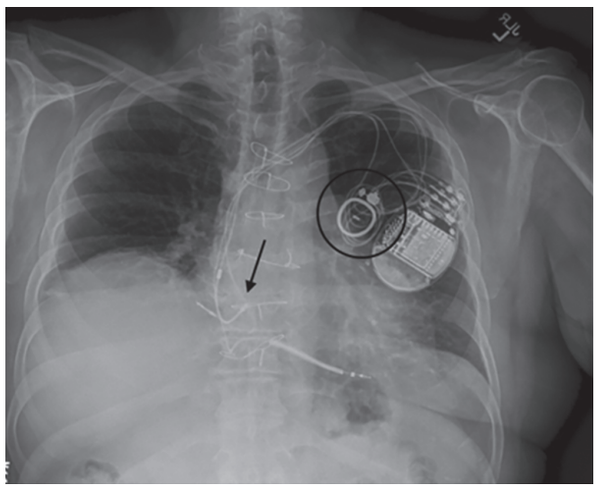

Fig. 9.21: Heartpod (left atrial pressure sensor, arrow) in the transseptal location attached to the coil antenna (circle) implanted in the subpectoral area. This patient also has a dual-chamber defibrillator for primary prevention with right atrial and right ventricular leads

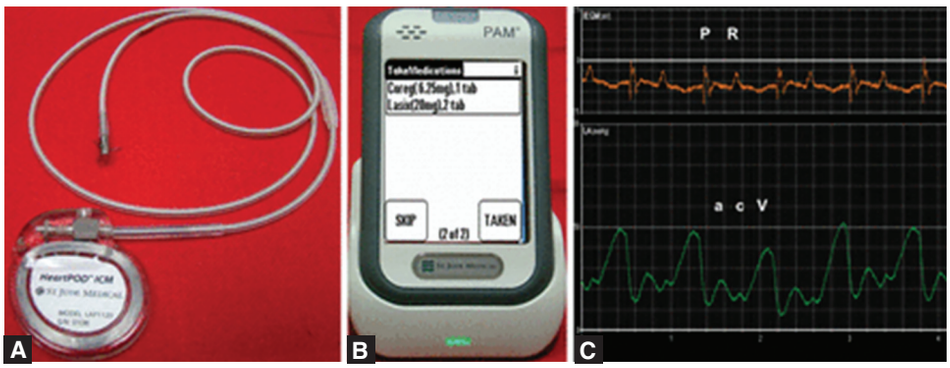

Fig. 9.22: (A) A standalone HeartPOD device with the communicator module connected to the sensor lead. (B) The PAM that powers the HeartPOD by telemetry, records data, and provides therapeutic advice to the patient. (C) Electrograms and LAP waveforms recorded by the HeartPOD (reproduced with kind permission by St Jude Medical)

The Device

The HeartPOD (St Jude Medical) comprises an implantable sensor lead that measures pressure, intracardiac electrograms, and temperature, coupled to a coil antenna positioned in the subcutaneous tissue. Folding proximal and distal nitinol anchors fix the sensor lead onto the interatrial septum. The device is either standalone or coupled to a CRT-D unit. A handheld patient advisory module (PAM) powers the implanted device (which has no battery) by radiofrequency wireless transmission. The PAM also measures the atmospheric pressure, that is then subtracted from the pressure measured in the implant to obtain LAP. During interrogation, physiological waveforms of LAP and intracardiac electrograms are captured in the memory of the PAM for periods of up to 20 s. The PAM has the capacity to store ~3 months of data with six daily interrogations.

Clinical Perspectives

Self-titration of HF therapy by patients based upon LAP readings (similar to diabetics adjusting insulin levels with glycemia) is a paradigm shift in HF management. This strategy of course requires patient participation and compliance, and may not be suitable for many individuals. Patients with diastolic HF are a therapeutic challenge, in whom volume overload may rapidly cause pulmonary congestion. Analysis of the LAPTOP-HF data in this subset of patient will clarify whether titration of diuretics based upon LAP readings improves outcome. LAP data may be of use to optimize AV delays in CRT-HeartPOD devices (as the left atrial A-wave is recorded), but has not as yet been tested.

In conclusion, preliminary data relating to the HeartPOD show good mid-term device function and hold promise for improving patient self-management in HF. These data however need to be confirmed by the ongoing randomized LAPTOP-HF trial. Device implantation requires special training, and techniques are still evolving. The presence of a lead allows extraction (contrary to PAP monitor), but further experience is required to better evaluate procedural complications (Figs 9.23 and 9.24).

Pulmonary Artery Pressure Monitoring

The Device

The CardioMEMS heart failure sensor (Cardio MEMS Inc.) consists of a coil and a pressure-sensitive capacitor housed in a hermetically sealed silica capsule covered in medical-grade silicone. Two wired nitinol loops at the ends of the capsule serve as anchors to prevent distal migration of the sensor. The coil and capacitor form an electrical circuit that resonates at a specific frequency. The coil allows for electromagnetic coupling to the sensor by an external antenna, which is held against the patient's body. The antenna powers the implanted device, continuously measures its resonant frequency, which is then converted to a pressure waveform. The interrogating device measures the atmospheric pressure, which is subtracted from the pressure measured by the implanted sensor. The CardioMEMS sensor is designed to measure PAP.

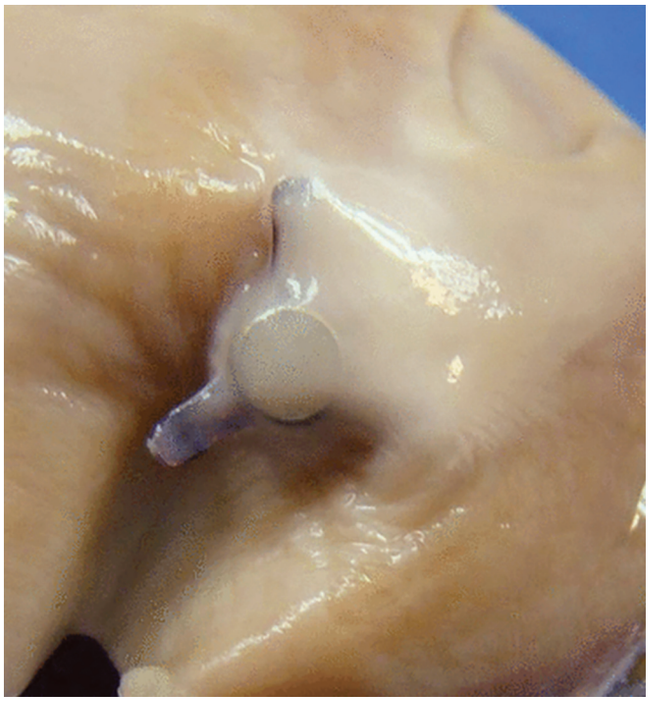

Fig. 9.23: Autopsy in a patient after 37 months of implantation of a HeartPOD showing endothelialisation of the pressure sensor (reproduced with kind permission by St Jude Medical)

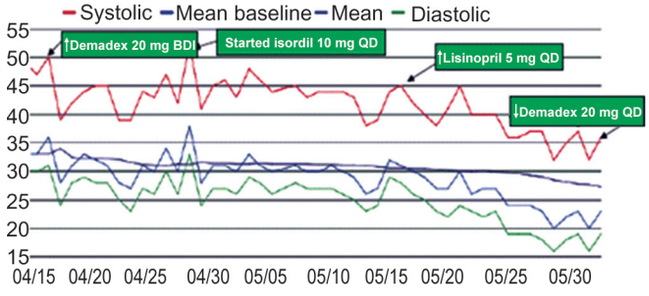

Fig. 9.24: Pressure-guided sensor has been used in a patient with heart failure. The patient had a history of NYHA Class III ischemic cardiomyopathy, cardiac resynchronization therapy combined with a defibrillator, atrial fibrillation, and renal insufficiency. At device implantation, the patient was on low-dose angiotensin-converting enzyme inhibitor, diuretic, and β-blocker. Vasodilating therapy and diuretic doses were titrated to maintain prespecified target pressures

Sensor Delivery System and Implantation

The CardioMEMS sensor is supplied preloaded and attached to a tether wire at the end of the delivery catheter. The sensor is implanted by using a venous femoral approach. First, a Swan–Ganz catheter is advanced into the deployment site in the pulmonary artery. After identification of the target artery, a guidewire (0.018–0.025 inch) is placed through the Swan–Ganz catheter to allow the sensor delivery catheter system to be advanced. The delivery catheter is advanced over the wire and released

in the target vessel. After removal of the delivery catheter, the Swan–Ganz catheter is replaced into the pulmonary artery proximal to the sensor. Subsequently, the implanted sensor is calibrated using PAPs acquired from the Swan–Ganz catheter (Figs 9.25 and 9.26).

Clinical Perspectives

In November 2011, FDA's circulatory system devices panel voted against the approval of the CardioMEMS implantable haemodynamic monitor because its use was not proved to significantly improve clinical outcomes in the randomized, single-blind CHAMPION trial. The greatest concern is the trial's design, which made it impossible to distinguish any treatment effect from the device itself in the single-blind trial. Physicians knew which patients had the device and specific treatment recommendations were made in the treatment group and not in the control group. Ambulatory HF patients are at high risk for hospital admission. There is an urgent need to develop strategies to reduce hospitalizations and readmission rates for HF. New technologies for invasive hemodynamic monitoring have been developed as an adjunct to clinical follow-up. The results of studies with implantable hemodynamic monitoring devices show great promise as adjunctive tools in the management of HF patients. The technology of haemodynamic monitoring is not incorporated in current defibrillators or devices with CRT. Future studies have to evaluate whether a role exists for combining impedance measurements by current cardiac devices with hemodynamic sensors.



Fig. 9.25: The CardioMEMS sensor consists of a coil and a pressure-sensitive capacitor housed in a hermetically sealed silica capsule covered in medical-grade silicone. Two wired nitinol loops at the ends of the capsule serve as anchors to prevent distal migration of the sensor

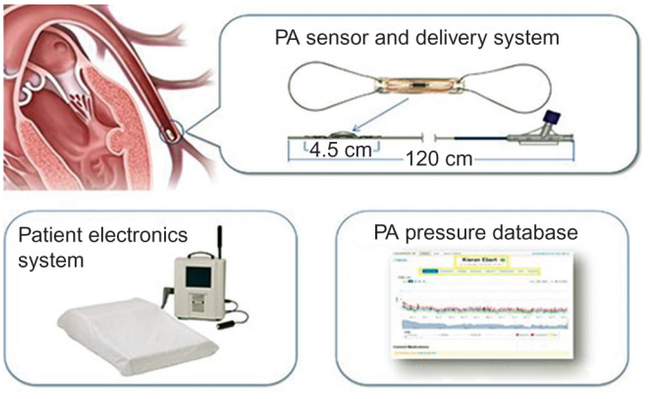

Fig. 9.26: FDA approves first implantable wireless device with remote monitoring to measure pulmonary artery pressure in certain heart failure patients

BIBLIOGRAPHY

1. Abraham WT, et al Wireless pulmonary artery haemodynamic monitoring in chronic heart failure: a randomised controlled trial. Lancet 2011;377:658–66.
2. Abraham WT, et al. Cardiac resynchronization in chronic heart failure. N Engl J Med 2002;346:1845–53.
3. Abraham WT, et al. Subgroup analysis of a randomized controlled trial evaluating the safety and efficacy of cardiac contractility modulation in advanced heart failure. J Card Fail 2011;17:710–7.
4. Adamson PB, et al. Continuous hemodynamic monitoring in patients with mild to moderate heart failure: results of The Reducing Decompensation Events Utilizing Intracardiac Pressures in Patients with Chronic Heart Failure (REDUCEhf) trial. Congest Heart Fail 2011;17:248–54.
5. Andresen MC, et al. Nucleus tractussolitarius—gateway to neural circulatory control. Annu Rev Physiol 1994;56: 93–116.
6. Ardell JL, et al. Dorsal spinal cord stimulation obtunds the capacity of intrathoracic extracardiac neurons to transduce myocardial ischemia. Am J Physiol Regul Integr Comp Physiol 2009;297:R470–77.
7. Armour JA, et al. Long-term modulation of the intrinsic cardiac nervous system by spinal cord neurons in normal and ischaemic hearts. Auton Neurosci 2002;95:71–9.
8. Bedder MD, et al. Spinal cord stimulation surgical technique for the nonsurgically trained. Neuromodulation 2009; 12:1–19.
9. Beshai JF, et al. Cardiac-resynchronization therapy in heart failure with narrow QRS complexes. N Engl J Med 2007.
10. Bibevski S, et al. Ganglionic mechanisms contribute to diminished vagal control in heart failure. Circulation 1999; 99:2958–63.
11. Bibevski S, et al. Prevention of diminished parasympathetic control of the heart in experimental heart failure. Am J Physiol Heart Circ Physiol 2004;287:H1780–5.
12. Binkley PF, et al. A polymorphism of the endothelial nitric oxide synthase promoter is associated with an increase in autonomic imbalance in patients with congestive heart failure. Am Heart J 2005;149:342–8.
13. Binkley PF, et al. Parasympathetic withdrawal is an integral component of autonomic imbalance in congestive heart failure: demonstration in human subjects and verification in a paced canine model of ventricular failure. J Am Coll Cardiol 1991;18:464–72.

14. Bisognano JD, et al. Baroreflex activation therapy lowers blood pressure in patients with resistant hypertension: results from the double-blind, randomized, placebo-controlled Rheos pivotal trial. J Am Coll Cardiol 2011; 58: 765–73.
15. Blank M, et al. Initial interactions in electromagnetic field-induced biosynthesis. J Cell Physiol 2004;199:359–63.
16. Borggrefe MM, et al. Randomized, double blind study of non-excitatory, cardiac contractility modulation electrical impulses for symptomatic heart failure. Eur Heart J 2008;29: 1019–28.
17. Bourge RC, et al. Randomized controlled trial of an implantable continuous hemodynamic monitor in patients with advanced heart failure: the COMPASS-HF study. J Am Coll Cardiol 2008;51:1073–9.
18. Brandt MC, et al. Baroreflex activation as a novel thera-peutic strategy for diastolic heart failure. Clin Res Cardiol 2011;100: 249–51.
19. Brignole M, et al. ESC guidelines on cardiac pacing and cardiac resynchronization therapy: the task force on cardiac pacing and resynchronization therapy of the European Society of Cardiology (ESC). Developed in collaboration with the European Heart Rhythm Association (EHRA). Europace 2013;15:1070–118.
20. Bristow MR, et al. Cardiac-resynchronization therapy with or without an implantable defibrillator in advanced chronic heart failure. N Engl J Med 2004;350:2140–50.
21. Bristow MR, et al. Decreased catecholamine sensitivity and beta-adrenergic-receptor density in failing human hearts. N Engl J Med 1982;307:205–11.
22. Brodison A, et al. Spinal-cord stimulation in management of angina. Lancet 1999;354:1748–9.
23. Brook AL, et al. Spinal cord stimulation: a basic approach. Tech Vasc Interv Radiol 2009;12:64–70.
24. Brunner-La Rocca HP, et al. Effect of cardiac sympathetic nervous activity on mode of death in congestive heart failure. Eur Heart J 2001;22:1136–43.
25. Burkhoff D, et al. 'Responder analysis' for assessing effectiveness of heart failure therapies based on measures of exercise tolerance. J Card Fail 2009;15:108–15.
26. Burkhoff D, et al. Nonexcitatory electrical signals for en-hancing ventricular contractility: rationale and initial investigations of an experimental treatment for heart failure. Am J Physiol Heart Circ Physiol 2005;288:H2550–6.
27. Butter C, et al. Cardiac contractility modulation electrical signals improve myocardial gene expression in patients with heart failure. J Am Coll Cardiol 2008;51:1784–9.
28. Butter C, et al. Enhanced inotropic state of the failing left ventricle by cardiac contractility modulation electrical signals is not associated with increased myocardial oxygen consumption. J Card Fail 2007;13:137–42.
29. Cameron T. Safety and efficacy of spinal cord stimulation for the treatment of chronic pain: a 20-year literature review. J Neurosurg 2004;100:254–67.
30. Cardinal R, et al. Spinal cord activation differentially modulates ischaemic electrical responses to different stressors in canine ventricles. Auton Neurosci 2004;111:37–47.
31. Cardinal R, et al. Spinal cord stimulation suppresses bradycardias and atrial tachyarrhythmias induced by mediastinal nerve stimulation in dogs. Am J Physiol Regul Integr Comp Physiol 2006;291:R1369–75.
32. Castro PF, et al. A wireless pressure sensor for monitoring pulmonary artery pressure in advanced heart failure: initial experience. J Heart Lung Transplant 2007;26:85–8.
33. Chandler MJ, et al. A mechanism of cardiac pain suppres-sion by spinal cord stimulation: implications for patients with angina pectoris. Eur Heart J 1993;14:96–105.
34. Creager MA, et al. Arterial baroreflex regulation of blood pressure in patients with congestive heart failure. J Am Coll Cardiol 1994;23:401–5.
35. Cygankiewicz I, et al. MuerteSubita en Insuficiencia Cardiaca Investigators. Heart rate turbulence predicts all-cause mortality and sudden death in congestive heart failure patients. Heart Rhythm 2008;5:1095–102.
36. Czachurski J, et al. Localization of neurons with baroreceptor input in the medial solitary nucleus by means of intracellular application of horseradish peroxidase in the cat. Neurosci Lett 1982;28:133–7.
37. Daubert JC, et al. EHRA/HRS expert consensus statement on cardiac resynchronization therapy in heart failure: implant and follow-up recommendations and management. Europace 2012;14:1236–86.
38. de Jongste MJ, et al. Stimulation characteristics, complications, and efficacy of spinal cord stimulation systems in patients with refractory angina: a prospective feasibility study. Pacing Clin Electrophysiol 1994;17:1751–60.
39. de Vries J, et al. An open label, single-centre, randomized trial of spinal cord stimulation vs. percutaneous myocardial laser revascularization in patients with refractory angina pectoris: the spirit trial. Eur Heart J 2006;27:1631–2. [Author reply 1632].
40. Dickstein K, et al; ESC Committee for Practice Guidelines. 2010 Focused Update of ESC Guidelines on device therapy in heart failure: an update of the 2008 ESC Guidelines for the diagnosis and treatment of acute and chronic heart failure and the 2007 ESC Guidelines for cardiac and resynchronization therapy. Developed with the special contribution of the Heart Failure Association and the European Heart Rhythm Association. Europace 2010;12: 1526–36.
41. Diedrichs H, et al. [Increased myocardial blood flow after spinal cord stimulation in patients with refractory angina pectoris]. Med Klin (Munich) 2003;98:146–50.
42. Diedrichs H, et al. Symptomatic relief precedes improvement of myocardial blood flow in patients under spinal cord stimulation. Curr Control Trials Cardiovasc Med 2005;6:7.
43. Eckberg DL, et al. Defective cardiac parasympathetic control in patients with heart failure. N Engl J Med 1971; 285:877–83.
44. Ekre O, et al. Feasibility of spinal cord stimulation in angina pectoris in patients with chronic pacemaker treatment for cardiac arrhythmias. Pacing Clin Electrophysiol 2003;26: 2134–41.
45. Eliasson T, et al. Myocardial turnover of endogenous opioids and calcitonin-gene-related peptide in the human heart and the effects of spinal cord stimulation on pacing-induced angina pectoris. Cardiology 1998;89:170–7.
46. Eliasson T, et al. Spinal cord stimulation in angina pectoris with normal coronary arteriograms. Coron Artery Dis 1993;4:819–27.

47. Enggaard TP, et al. Spinal cord stimulation for refractory angina in patients implanted with cardioverter defibrillators: five case reports. Europace 2010;12:1336–7.
48. Fan W, et al. Graded and dynamic reflex summation of myelinated and unmyelinated rat aortic baroreceptors. Am J Physiol 1999;277:R748–56.
49. Ferrero P, et al. Spinal cord stimulation affects T-wave alternans in patients with ischaemic cardiomyopathy: a pilot study. Europace 2008;10:506–8.
50. Foody JM, et al. Beta-blocker therapy in heart failure: scientific review. JAMA 2002;287:883–9.
51. Foreman RD, et al. Modulation of intrinsic cardiac neurons by spinal cord stimulation: Implications for its therapeutic use in angina pectoris. Cardiovasc Res 2000;47:367–75.
52. Georgakopoulos D, et al. Chronic baroreflex activation: a potential therapeutic approach to heart failure with preserved ejection fraction. J Card Fail 2011;17:167–78.
53. Gersbach PA, et al. Spinal cord stimulation treatment for angina pectoris: more than a placebo? Ann Thorac Surg 2001; 72:S1100–04.
54. Gibbons DD, et al. Neuromodulation targets intrinsic cardiac neurons to attenuate neuronally mediated atrial arrhythmias. Am J Physiol Regul Integr Comp Physiol 2012;302:R357–64.
55. Hautvast RW, et al. Effect of spinal cord stimulation on heart rate variability and myocardial ischemia in patients with chronic intractable angina pectoris—a prospective ambulatory electrocardiographic study. Clin Cardiol 1998; 21:33–8.
56. Hautvast RW, et al. Spinal cord stimulation in chronic intractable angina pectoris: a randomized, controlled efficacy study. Am Heart J 1998;136:1114–20.
57. Hegarty D. Spinal cord stimulation: the clinical application of new technology. Anesthesiol Res Pract 2012;2012: 375–691.
58. Henderson JM, et al. Nans training requirements for spinal cord stimulation devices: selection, implantation, and follow-up. Neuromodulation 2009;12:171–4.
59. Heusser K, et al. Chronic baroreflex activation: a potential therapeutic approach to heart failure with preserved ejection fraction carotid baroreceptor stimulation, sympathetic activity, baroreflex function, and blood pressure in hypertensive patients. Hypertension 2010; 55:619–26.
60. Hosobuchi Y. Electrical stimulation of the cervical spinal cord increases cerebral blood flow in humans. Appl Neurophysiol 1985;48:372–6.
61. Illig KA, et al. An implantable carotid sinus stimulator for drug-resistant hypertension: surgical technique and short-term outcome from the multicenter phase II Rheos feasibility trial. J Vasc Surg 2006;44:1213–8.
62. Imai M, et al. Therapy with cardiac contractility modulation electrical signals improves left ventricular function and remodeling in dogs with chronic heart failure. J Am Coll Cardiol 2007;49:2120–8.
63. Issa ZF, et al. Thoracic spinal cord stimulation reduces the risk of ischemic ventricular arrhythmias in a postinfarction heart failure canine model. Circulation 2005;111:3217–20.
64. Jacques F, et al. Spinal cord stimulation causes potentiation of right vagus nerve effects on atrial chronotropic function and repolarization in canines. J Cardiovasc Electrophysiol 2011;22:440–7.
65. Jesus S, et al. Initial experience with spinal cord stimulation (SCS) for the treatment of advanced heart failure. J Card Fail 2010;16:S67.
66. Kadish A, et al. A randomized controlled trial evaluating the safety and efficacy of cardiac contractility modulation in advanced heart failure. Am Heart J 2011;161:329–37.
67. Kirchheim HR. Systemic arterial baroreceptor reflexes. Physiol Rev 1976;56:100–77.
68. Klomp HM, et al. Systematic review and meta-analysis of controlled trials assessing spinal cord stimulation for inoperable critical leg ischaemia (Br J Surg 2004;91:948–55). Br J Surg 2005;92:120. author reply 120–1.
69. Kollai M, et al. Relation between baroreflex sensitivity and cardiac vagal tone in humans. Am J Phy 1994;266:H21–7.
70. Kosharskyy B, et al. Feasibility of spinal cord stimulation in a patient with a cardiac pacemaker. Pain Physician 2006; 9:249–51.
71. Kujacic V, et al. Assessment of the influence of spinal cord stimulation on left ventricular function in patients with severe angina pectoris: an echocardiographic study. Eur Heart J 1993;14:1238–44.
72. La Rovere MT, et al. ATRAMI (Autonomic Tone and Reflexes After Myocardial Infarction) Investigators. Baroreflex sensitivity and heart-rate variability in predic-tion of total cardiac mortality after myocardial infarction. Lancet 1998;351:478-84.
73. Lanza GA, et al. Effect of spinal cord stimulation on sponta-neous and stress-induced angina and 'ischemia-like' ST-segment depression in patients with cardiac syndrome X. Eur Heart J 2005;26:983–9.
74. Latif OA, et al. Spinal cord stimulation for chronic intract-able angina pectoris: a unified theory on its mechanism. Clin Cardiol 2001;24:533–41.
75. Lawo T, et al. Electrical signals applied during the absolute refractory period: an investigational treatment for advanced heart failure in patients with normal QRS duration. J Am Coll Cardiol 2005;46:2229–36.
76. Li W, et al. Inflammatory cytokines and nitric oxide in heart failure and potential modulation by vagus nerve stimu-lation. Heart Fail Rev 2011;16:137–45.
77. Liu Y, et al. Thoracic spinal cord stimulation improves cardiac contractile function and myocardial oxygen consumption in a porcine model of ischemic heart failure. J Cardiovasc Electrophysiol 2011.
78. Long DM, et al. Electrical stimulation of the spinal cord and peripheral nerves for pain control. A 10-year experience. Appl Neurophysiol 1981;44:207–17.
79. Lopshire JC, et al. Spinal cord stimulation improves ventricular function and reduces ventricular arrhythmias in a canine postinfarction heart failure model. Circulation 2009;120:286–94.
80. Lund LH, et al. Prevalence, correlates, and prognostic significance of QRS prolongation in heart failure with reduced and preserved ejection fraction. Eur Heart J 2013;34:529–39.
81. Maggioni AP, et al. EURObservational Research Programme: the Heart Failure Pilot Survey (ESC-HF Pilot). Eur J Heart Fail 2010;12:1076–84.
82. Mannheimer C, et al. The problem of chronic refractory angina; report from the esc joint study group on the treatment of refractory angina. Eur Heart J 2002;23:355–70.

83. Marin-Neto JA, et al. Abnormal baroreflex control of heart rate in decompensated congestive heart failure and reversal after compensation. Am J Cardiol 1991;67:604–10.
84. Markos F, et al. Nitric oxide facilitates vagal control of heart rate via actions in the cardiac parasympathetic ganglia of the anaesthetised dog. Exp Physiol 2002;87:49–52.
85. McMurray JJ, et al. ESC guidelines for the diagnosis and treatment of acute and chronic heart failure 2012: The Task Force for the Diagnosis and Treatment of Acute and Chronic Heart Failure 2010 of the European Society of Cardiology. Developed in collaboration with the Heart Failure Association (HFA) of the ESC. Eur Heart J 2012;33:1787–847.
86. McNab D, et al. An open label, single-centre, randomized trial of spinal cord stimulation vs. percutaneous myocardial laser revascularization in patients with refractory angina pectoris: the spirit trial. Eur Heart J 2006;27:1048–53.
87. Mekhail NA, et al. Retrospective review of 707 cases of spinal cord stimulation: indications and complications.Pain Pract 2011;11:148–53.
88. Melzack R, et al. Pain mechanisms: a new theory. Science 1965;150:971–9.
89. Mendelowitz D. Firing properties of identified parasympathetic cardiac neurons in the nucleus ambiguus. Am J Physiol 1996;271:H2609–14.
90. Merchant FM, et al. Implantable sensors for heart failure. Circ Arrhythm Electrophysiol 2010;3:657–67.
91. Mohri S, et al. Cardiac contractility modulation by electric currents applied during the refractory period. Am J Physiol Heart Circ Physiol 2002;282:H1642–7.
92. Molon G, et al. ICD and neuromodulation devices: is peaceful coexistence possible? Pacing Clin Electrophysiol 2011; 34:690–3.
93. Morita H, et al. Cardiac contractility modulation with nonexcitatory electric signals improves left ventricular function in dogs with chronic heart failure. J Card Fail 2003; 9:69–75.
94. Nägele H, et al. Cardiac contractility modulation in nonresponders to cardiac resynchronization therapy. Europace 2008;10:1375–80.
95. Neelagaru SB, et al. Nonexcitatory, cardiac contractility modu-lation electrical impulses: feasibility study for advanced heart failure in patients with normal QRS duration. Heart Rhythm 2006;3:1140–7.
96. Nelson GS, et al. Left ventricular or biventricular pacing improves cardiac function at diminished energy cost in patients with dilated cardiomyopathy and left bundle-branch block [In Process Citation]. Circulation (Online) 2000;102: 3053–9.
97. Olgin JE, et al. Effects of thoracic spinal cord stimulation on cardiac autonomic regulation of the sinus and atrioventricular nodes. J Cardiovasc Electrophysiol 2002;13:475–81.
98. Olshansky B, et al. Parasympathetic nervous system and heart failure: pathophysiology and potential implications for therapy. Circulation 2008;118:863–71.
99. Ooi YC, et al. Simultaneous use of neurostimulators in patients with a preexisting cardiovascular implantable electronic device. Neuromodulation 2011;14:20–5. discussion 25–26.
100. Pappone C, et al. Cardiac contractility modulation by electric currents applied during the refractory period in patients with heart failure secondary to ischemic or idio-pathic dilated cardiomyopathy. Am J Cardiol 2002;90:1307–13.
101. Pappone C, et al. Electrical modulation of cardiac contractility: clinical aspects in congestive heart failure. Heart Fail Rev 2001;6:55–60.
102. Pappone C, et al. First human chronic experience with cardiac contractility modulation by nonexcitatory electrical currents for treating systolic heart failure: mid-term safety and efficacy results from a multicenter study. J Cardiovasc Electrophysiol 2004;15:418–27.
103. Reig E, et al. Spinal cord stimulation: a 20-year retrospective analysis in 260 patients. Neuromodulation 2009;12:232–9.
104. Ritzema J, et al. Direct left atrial pressure monitoring in ambulatory heart failure patients: initial experience with a new permanent implantable device. Circulation 2007; 116:2952–9.
105. Ritzema J, et al. Physician-directed patient self-management of left atrial pressure in advanced chronic heart failure. Circulation 2010;121:1086–95.
106. Romano M, et al. Efficacy and safety of permanent cardiac DDD pacing with contemporaneous double spinal cord stimulation. Pacing Clin Electrophysiol 1998;21:465–7.
107. Rydlewska A, et al. Changes in autonomic balance in patients with decompensated chronic heart failure. Clin Auton Res 2011;21:47–54.
108. Sabbah HN, et al. Cardiac contractilty modulation with the impulse dynamics signal: studies in dogs with chronic heart failure. Heart Fail Rev 2001;6:45–53.
109. Sabbah HN, et al. Chronic electrical stimulation of the carotid sinus baroreflex improves left ventricular function and promotes reversal of ventricular remodeling in dogs with advanced heart failure. Circ Heart Fail 2011;4:65–70.
110. Schau T, et al. Long-term outcome of cardiac contractility modulation in patients with severe congestive heart failure. Europace 2011;13:1436–44.
111. Scheffers IJM, et al. Novel baroreflex activation therapy in resistant hypertension: results of a European multi-center feasibility study. J Am Coll Cardiol 2010;56:1254–8.
112. Schimpf R, et al. Potential device interaction of a dual chamber implantable cardioverter defibrillator in a patient with continuous spinal cord stimulation. Europace 2003; 5:397–402.
113. Schwartz PJ, et al. Sympathetic-parasympathetic interaction in health and disease: abnormalities and relevance in heart failure. Heart Fail Rev 2011;16:101–7.
114. Shenkman HJ, et al. Congestive heart failure and QRS duration: establishing prognosis study. Chest 2002;122:528–34.
115. Sibell DM, et al. Successful use of spinal cord stimulation in the treatment of severe Raynaud's disease of the hands. Anesthesiology 2005;102:225–7.
116. Southerland EM, et al. Preemptive, but not reactive, spinal cord stimulation mitigates transient ischemia-induced myocardial infarction via cardiac adrenergic neurons. Am J Physiol Heart Circ Physiol 2007;292:H311–7.
117. Stix G, et al. Chronic electrical stimulation during the absolute refractory period of the myocardium improves severe heart failure. Eur Heart J 2004;25:650–5.
118. Tordoir JH, et al. An implantable carotid sinus baroreflex activating system: surgical technique and short-term

outcome from a multi-center feasibility trial for the treatment of resistant hypertension. Eur J Vasc Endovasc Surg 2007;33: 414–21.
119. Troughton RW, et al. Direct left atrial pressure monitoring in severe heart failure: long-term sensor performance. J Cardiovasc Transplant Res 2011;4:3–13.
120. Ubbink DT, et al. Spinal cord stimulation for non-reconstructable chronic critical leg ischaemia. Cochrane Database Syst Rev 2005:CD004001.
121. Vanoli E, et al. Vagal stimulation and prevention of sudden death in conscious dogs with a healed myocardial infarction. Circ Res 1991;68:1471–81.
122. Vatner DE, et al. Physiological and biochemical evidence for coordinate increases in muscarinic receptors and Gi during pacing-induced heart failure. Circulation 1996; 94:102–7.
123. Verdejo HE, et al. Comparison of a radiofrequency-based wireless pressure sensor to swan-ganz catheter and echo-cardiography for ambulatory assessment of pulmonary artery pressure in heart failure. J Am Coll Cardiol 2007; 50:2375–82.
124. Visocchi M, et al. Spinal cord stimulation and cerebral hemo-dynamics: updated mechanism and therapeutic implications. Stereotact Funct Neurosurg 2011;89:263–74.
125. Wang J, et al. Synaptic and neurotransmitter activation of cardiac vagal neurons in the nucleus ambiguus. Ann N Y Acad Sci 2001;940:237–46.
126. Wang M, et al. Long-term baroreflex activation therapy increases the threshold for the induction of lethal ventricular arrhythmias in dogs with chronic advanced heart failure. Circulation 2008;118:S721.
127. Whellan DJ, et al. Review of advanced heart failure device diagnostics examined in clinical trials and the potential benefit from monitoring capabilities. Prog Cardiovasc Dis 2011;54:107–14.
128. Wu M, et al. Putative mechanisms behind effects of spinal cord stimulation on vascular diseases: a review of experimental studies. Auton Neurosci 2008;138:9–23.
129. Wustmann K, et al. Effects of chronic baroreceptor stimulation on the autonomic cardiovascular regulation in patients with drug-resistant arterial hypertension. Hypertension 2009;54:530–6.
130. Yu CM, et al. Impact of cardiac contractility modulation on left ventricular global and regional function and remodeling. JACC Cardiovasc Imaging 2009;2:1341–9.
131. Yu CM, et al. Intrathoracic impedance monitoring in patients with heart failure: correlation with fluid status and feasibility of early warning preceding hospitalization. Circulation 2005;112:841–8.
132. Zucker IH, et al. Chronic baroreceptor activation enhances survival in dogs with pacing-induced heart failure. Hypertension 2007;50:904–10.

10 Recognition and Management of Syncopal Attacks

Syncope is defined as a partial or complete loss of consciousness with interruption of awareness of oneself and ones surroundings. When the loss of consciousness is temporary and there is spontaneous recovery, it is referred to as syncope or, in nonmedical quarters, fainting. Syncope accounts for one in every 30 visits to an emergency room. It is pronounced sin-ko-pea.

Syncope is due to a temporary reduction in blood flow and therefore a shortage of oxygen to the brain. This leads to lightheadedness or a 'black out' episode, a loss of consciousness. Temporary impairment of the blood supply to the brain can be caused by heart conditions and by conditions that do not directly involve the heart.

Careful and thorough evaluation of the cause of syncope is warranted in all patients. Determining that certain individuals are at 'low mortality risk' is inadequate; syncope, although often benign from a mortality perspective, tends to recur, is associated with risk of physical injury, diminishes quality-of-life, and might lead to restriction from employment or avocation. However, the diagnostic evaluation and treatment of syncope is challenging for many reasons. First, syncope is only 1 of many causes of transient loss of consciousness. Second, the patient's symptoms are fleeting, and the patient is generally fully recovered when seen in the clinic; only infrequently are there helpful physical findings. Third, spontaneous events are often unwitnessed by medical professionals; consequently, the medical history of symptom events is usually a 'second-hand' or 'third-hand' story. Finally, there is often an excessive sense of diagnostic 'urgency' that tends to result in a rush to undertake multiple poorly considered 'diagnostic' testing procedures; a deliberate approach based on initial risk stratification is more likely to reap the dual rewards of a correct diagnosis and initiation of effective treatment in a cost-effective manner (Figs 10.1–10.3).

How common is syncope?

Syncope is a common condition. It affects 3% of men and 3.5% of women at some point in life. Syncope is more common as you get older and affects up to 6% of people



Fig. 10.1: (A) Person's tendency to fall from a chair with a syncopal spell. (B) A young lady is lying on the ground with syncopy and her mother is calling for medical help

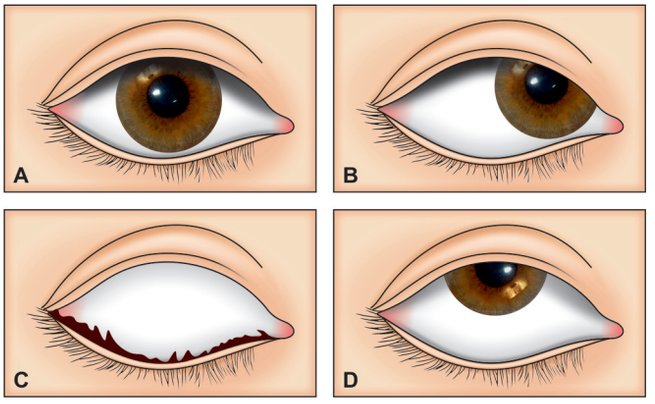

Fig. 10.2: Eye closure and gaze in various epileptic and non-epileptic seizures. (A) Staring during a temporal lobe seizure. (B) Lateral gaze during an extratemporal lobe seizure. (C) Closed eyes during a psychogenic; non-epileptic attack. (D) Upward gaze during a syncope

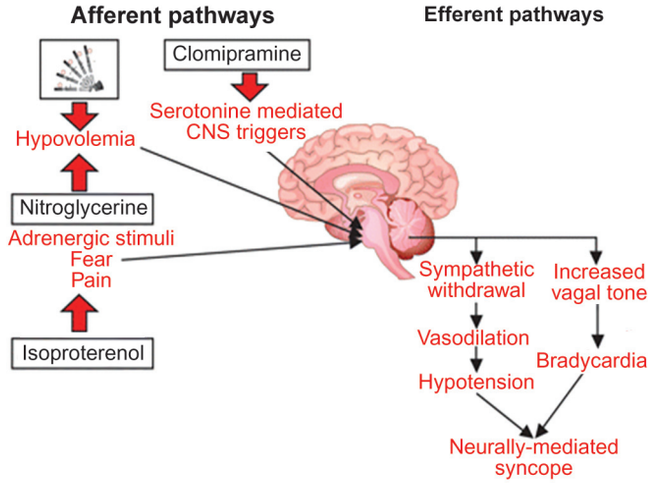

Fig. 10.3: This figure shows very schematically the different possible afferent pathways of neurally-mediated syncope and how tilt testing and the different drugs can act on these different triggers. Tilt testing and nitroglycerin provoke central hypovolemia by increasing venous pooling; isoproterenol, increases the adrenergic nerve tone, as happens in those cases triggered by fear or pain; clomipramine enhances central serotonergic activity as probably happens in some syncopal centrally-induced syncopal episodes

over age 75. The condition can occur at any age and happens in people with and without other medical problems.

What are the symptoms of syncope?

The most common symptoms of syncope include:

- Blacking out
- Feeling lightheaded
- Falling for no reason
- Feeling dizzy
- Feeling drowsy or groggy
- Fainting, especially after eating or exercising
- Feeling unsteady or weak when standing
- Changes in vision, such as seeing spots or having tunnel vision
- Headaches
- Many times, patients feel an episode of syncope coming on. They have what are called 'premonitory symptoms,' such as feeling lightheaded, nauseous, and heart palpitations (irregular heartbeats that feel like 'fluttering' in the chest). If you have syncope, you will likely be able to keep from fainting if you sit or lie down and put your legs up if you feel these symptoms.
- Syncope can be a sign of a more serious condition. So, it is important to get treatment right away after you have an episode of syncope. Most patients can prevent problems with syncope once they get an accurate diagnosis and proper treatment

The following questions should be answered:

- Was loss of consciousness complete?
- Was loss of consciousness with rapid onset and short duration?
- Was recovery spontaneous, complete, and without sequelae?
- Was postural tone lost?

If the answers to these questions are positive, the episode has a high likelihood of being syncope. If one or more answers are negative, consider other forms of loss of consciousness prior to proceeding with syncope evaluation. The clinician should attempt to gather all information with respect to symptoms preceding the syncope.

Prior faintness, dizziness, or light-headedness occurs in 70% of patients experiencing true syncope. Other symptoms, such as vertigo, weakness, diaphoresis, epigastric discomfort, nausea, blurred or faded vision, pallor, or paresthesias, may also occur in the presyncopal period.

Symptoms of nausea or diaphoresis prior to the event may suggest syncope rather than seizure when the episode was not witnessed, whereas an aura may suggest seizure.

Patients with true syncope do not remember actually falling to the ground. Presyncope involves the same symptoms and pathophysiology but terminates prior to loss of consciousness and can occasionally include loss of postural tone.

The duration of symptoms preceding a syncopal episode has been reported to be an average of 2.5 minutes in vasovagal syncope and an average of only 3 seconds in arrhythmia-related cardiac syncope.

Clinicians should specifically inquire as to red flag symptoms, such as exertional onset, chest pain, dyspnea, low back pain, palpitations, severe headache, focal neurologic deficits, diplopia, ataxia, or dysarthria prior to the syncopal event.

Patients should be asked to estimate the duration of their loss of consciousness. Syncope is associated with patient estimates ranging from seconds up to 1 minute in most cases. To discriminate from seizures, patients should also be asked if they remember being confused about their surroundings after the event or whether they have oral trauma, incontinence, or myalgias.

A detailed account of the event must also be obtained from any available witnesses. Witnesses can aid the clinician in differentiating among syncope, altered mental status, and seizure.

Convulsive activity, automatisms, or attempts to elicit focality can indicate seizure. Witnesses may be able to estimate the duration of unconsciousness and to assist in ascertaining whether the patient experienced postevent confusion.

Postevent confusion is the most powerful tool for discriminating between syncope and seizure. A postictal phase suggests that a seizure has occurred. Postevent confusion has been described with syncope, but the confusion should not last more than 30 seconds. Seizure-like activity can occur with syncope if the patient is held in an upright posture.

A medication history must be obtained in all patients with syncope with special emphasis placed on cardiac and antihypertensive medications. Drugs commonly implicated in syncope include the following:

- Agents that reduce blood pressure (e.g. antihypertensive drugs, diuretics, and nitrates)
- Agents that affect cardiac output (e.g. beta-blockers, digitalis, and antiarrhythmics)
- Agents that prolong the cardiac output (QT) interval (e.g. tricyclic antidepressants, phenothiazines, quinidine, and amiodarone)
- Agents that alter sensorium (including alcohol, cocaine, analgesics with sedative properties)
- Agents that alter serum electrolytes (especially diuretics)

Inquiry must be made into any personal or familial past medical history of cardiac disease. Patients with a history of myocardial infarction (MI), arrhythmia, structural cardiac defects, cardiomyopathies, or CHF have a uniformly worse prognosis than other patient groups.

Remember to consider the broad differential diagnosis of syncope. Assess whether the patient has a history of seizure disorder, diabetes, stroke (CVA), deep venous thrombosis (DVT), or abdominal aortic aneurysm or if pregnancy is a possibility.

Table 10.1: Causes of nonsyncopal attacks (commonly misdiagnosed as syncope

Disorders without any impairment of consciousness
• Falls • Cataplexy • Drop attacks • Psychogenic pseudosyncope • Transient ischaemic attacks (TIA) of carotid origin
Disorders with partial or complete loss of consciousness
• Metabolic disorders, including hypoglycemia, hypoxia, hyperventilatio with hypocapnia • Epilepsy • Intoxications • Vertebro-basilar TIA

Causes

Cardiac (cardiopulmonary) syncope may be due to vascular disease, cardiomyopathy, arrhythmia, or valvular dysfunction and predicts a worse short-term and long-term prognosis. Obtaining an initial ECG is mandatory if any of these causes are possible for the differential diagnosis. Low flow states, such as those associated with advanced cardiomyopathy, CHF, and valvular insufficiency, may result in hypotension and cause transient global cerebral hypoperfusion. Often, these patients are on medications that reduce afterload, which may contribute to the cause of syncope (Tables 10.1–10.3 and Fig. 10.4).

Diagnosis of syncope: Dizzy spells or syncopal attacks can be diagnosed with different approaches because it is considered as multifactorial entity (Table 10.4).

Ventricular arrhythmias (Fig. 10.5), such as ventricular tachycardia and torsade de pointes, tend to occur in older patients with known cardiac disease. These patients tend to have fewer recurrences and have a more sudden onset with few, if any, presyncopal symptoms. Associated chest pain or dyspnea may be present. This type of syncope is generally unrelated to posture and can occur during lying, sitting, or standing. Often, these arrhythmias are not

Table 10.2: Clinical features suggestive of specific causes of syncope

Neurally-mediated syncope
• Absence of cardiac disease • Long history of syncope • After sudden unexpected unpleasant sight, sound, smell or pain • Prolonged standing or crowded, hot places • Nausea, vomiting associated with syncope • During or in the absorptive state after a meal • With head rotation, pressure on carotid sinus (as in tumors, shaving, tight collars) • After exertion
Syncope caused by orthostatic hypotension
• After standing up • Temporal relationship with start of medication leading to hypotension or changes of dosage • Prolonged standing especially in crowded, hot places • Presence of autonomic neuropathy or Parkinsonism • After exertion
Cardiac syncope
• Presence of severe structural heart disease • During exertion, or supine • Preceded by palpitation or accompanied by chest pain • Family history of sudden death
Cerebrovascular syncope
• With arm exercise • Differences in blood pressure or pulse in the two arms

Table 10.3: Causes of syncope

Neurally-mediated (reflex)

- Vasovagal syncope (common faint)
  - Classical
  - Nonclassical
- Carotid sinus syncope
- Situational syncope
  - Acute hemorrhage
  - Cough, sneeze
  - Gastrointestinal stimulation (swallo, defaecation, visceral pain)
  - Micturition (post-micturition)
  - Postexercise
  - Postparandial
  - Others (e.g. brass instrument playing, weightlifting)
- Glossopharyngeal neuralgia

Orthostatic hypotension

- Automomic failure
  - Primary autonomic failure syndromes (e.g. pure autonomic failure, multiple system atrophy, Parkinson's disease with autonomic failure)
  - Secondary autonomic failure syndromes (e.g. diabetic neuropathy, amyloid neuropathy)
  - Drugs and alcohol
  - Postexercise
  - Postparadial
- Volume depletion
  - Hemorrhage, diarrhoea, and Addison's disease

Cardiac arrhythmias as primary cause

- Sinus node dysfunction (including bradycardia/tachycardia syndrome)
- Atrioventricular conduction system disease
- Paroxysmal supraventricular and ventricular tachycardias
- Inherited syndromes (e.g. long QT syndrome, Brugada syndrome)
- Implanted device (pacemaker, implantable cardioverter-defibrillator) malfunction
- Drug-induced arrhythmias

Structural cardiac or cardiopulmonary disease

- Obstructive cardiac valvular disease
- Acute myocardial infarction/ischemia
- Obstructive cardiomyopathy
- Atrial myxoma
- Acute aortic dissection

revealed on the initial ECG but may be captured with prolonged monitoring.

Supraventricular tachyarrhythmias include supraventricular tachycardia and atrial fibrillation with rapid response. These may be associated with palpitations, chest pain, or dyspnea. Patients typically have prodromal symptoms and may have syncope while attempting to stand or walk because of resultant hypotension. These symptoms may spontaneously resolve prior to evaluation but are often noted during initial triage and assessment. Be sure to scrutinize ECG findings for evidence of Wolff-Parkinson-White syndrome, Brugada syndrome, and long QT syndrome (Fig. 10.6).

Bradyarrhythmias (Figs 10.7) include sick sinus syndrome, sinus bradycardia, high-grade atrioventricular blocks, pacemaker malfunction, and adverse medication reactions. Generally, these patients have a history of cardiac problems and are symptomatic. Chest pain, dyspnea, decreased exercise tolerance, and fatigue may all be present. Consider cardiac ischemia and medication side-effects as additional causes.

Cardiac outflow obstruction may also result in sudden-onset syncope with little or no prodrome. One critical clue is the exertional nature, and the other is the presence of a cardiac murmur. Young athletes may present with this aetiology for syncope. Specific pathology includes aortic stenosis, hypertrophic obstructive cardiomyopathy, mitral stenosis, pulmonary stenosis, pulmonary embolus, left atrial myxoma, and pericardial tamponade.

Syncope can also result from an acute MI, acute aortic dissection, and pulmonary embolus. These conditions can have associated chest pain, neck pain, shoulder pain, dyspnea, epigastric pain, hypotension, alteration of mental status and can result in sudden death.

Reflex (neurally mediated) syncope may be due to vasovagal syncope, which is mediated by emotional distress such as fear or physical pain. Situational syncope describes syncope that occurs with a fixed event such as micturition, deglutition, exercise induced, and carotid sinus syncope. These causes tend to be more benign and do not predict poor outcomes (Table 10.5).

Vasovagal syncope is the most common type in young adults but can occur at any age. It usually occurs in a standing position and is precipitated by fear, emotional stress, or pain (e.g. after a needlestick). Autonomic symptoms are predominant. Classically, nausea, diaphoresis, fading or 'graying out' of vision, epigastric discomfort, and light-headedness precede syncope by a few minutes. Syncope is thought to occur secondary to efferent vasodepressor reflexes by a number of mechanisms, resulting in decreased peripheral vascular resistance. It is not life threatening and occurs sporadically.

Situational syncope is essentially a reproducible vasovagal syncope with a known precipitant. Micturition, defecation, deglutition, tussive, and carotid sinus syncope are types of situational syncope. These stimuli result in autonomic reflexes with a vasodepressor response, ultimately leading to transient cerebral hypotension. These are not life-threatening but can cause morbidity. The treatment involves avoidance of the precipitant when possible and the initiation of counter manoeuvres when anticipated.

Syncope due to orthostatic hypotension can occur through several mechanisms. Pure autonomic failure can be associated with Parkinson's disease or dementia. Secondary

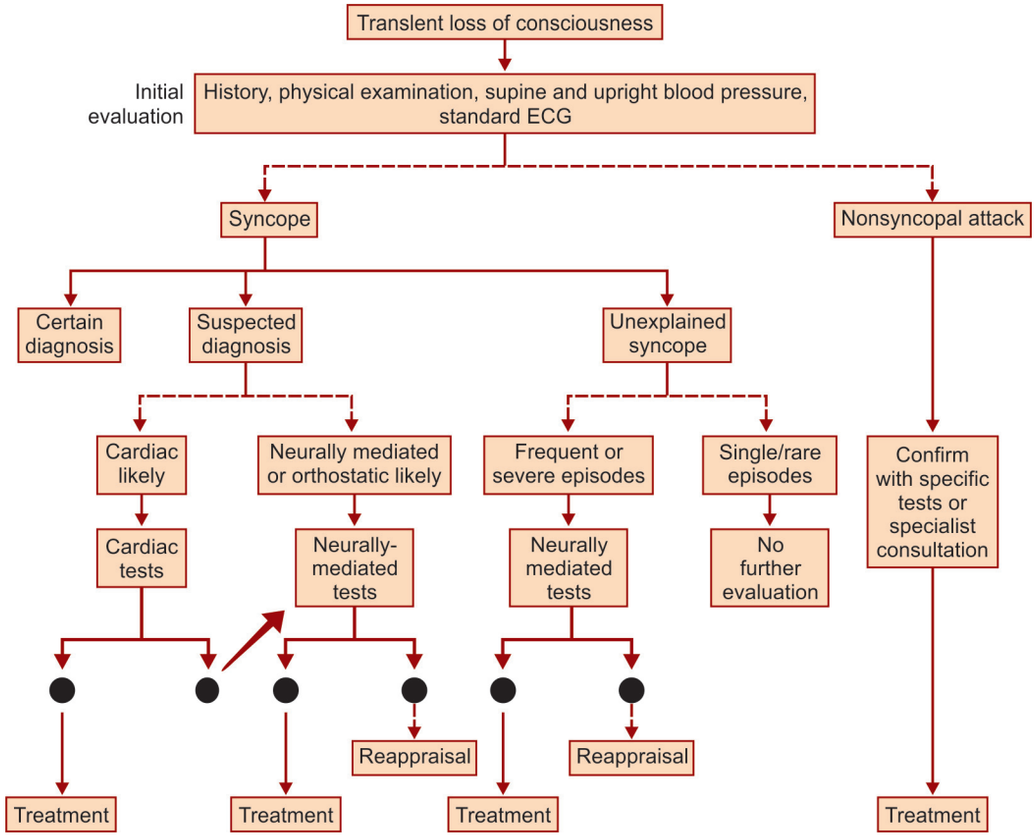

Fig. 10.4: Flow diagram outlining an approach to the evaluation of loss of consciousness on the basis of the initial evaluation. Differentiating true syncope from other 'nonsyncopal' spells is the first diagnostic step and affects the subsequent diagnostic strategy. Among cardiac investigations, echocardiography, prolonged electrocardiographic (ECG) monitoring, stress testing, electrophysiological study, and implantable loop recorder (ILR) are most useful. Among neurally-mediated investigations, tilt test, carotid sinus massage, and ILR are most useful. From Europace,1 with permission from the European Society of Cardiology

Table 10.4: Recommendations—diagnostic criteria with initial evaluation

Recommendations	Class[a]	Class[b]
• VVS is diagnosed if syncope is precipitated by emotional distress or orthostatic stress and is associated with typical prodrome	I	C
• Situational syncope is diagnosed if syncope occurs during or immediately after specific triggers listed in Table 10.5	I	C
• Orthostatic syncope is diagnosed when it occurs after standing up and there is documentation of OH	I	C
• Arrhythmia-related syncope is diagnosed by ECG when there is: » Persistent sinus bradycardia <40 bpm is awake or repetitivesinoatrial block or sinus pauses ≥3s » Mobitz II second or third degree AV block » Alternating left and right BBB » VT or rapid paroxysmal SVT » Non-sustained episodes of polymorphic VT and long or short QT interval » Pacemaker or ICD malfunction with cardiac pauses		
• Cardiac ischemia-related syncope is diagnosed when syncope presents with ECG evidence of acute ischemia with or without myocardial infarction	I	C
• Cardiovascular syncope is diagnosed when syncope presents in patients with prolapsing atrial myxoma, severe aortic stenosis, pulmonary hypertension, pulmonary embolus, or acute aortic dissection	I	C

[a]Class of recommendation. [b]Level of evidence. AV=atrioventricular; BBB=bundle branch block; ECG=electrocardiogram; ICD=implantable cardioverter defibrillator; OH=orthostatic hypotension; SVT=supraventricular tachycardia; VVS=vasovagal syncope; VT=ventricular tachycardia.

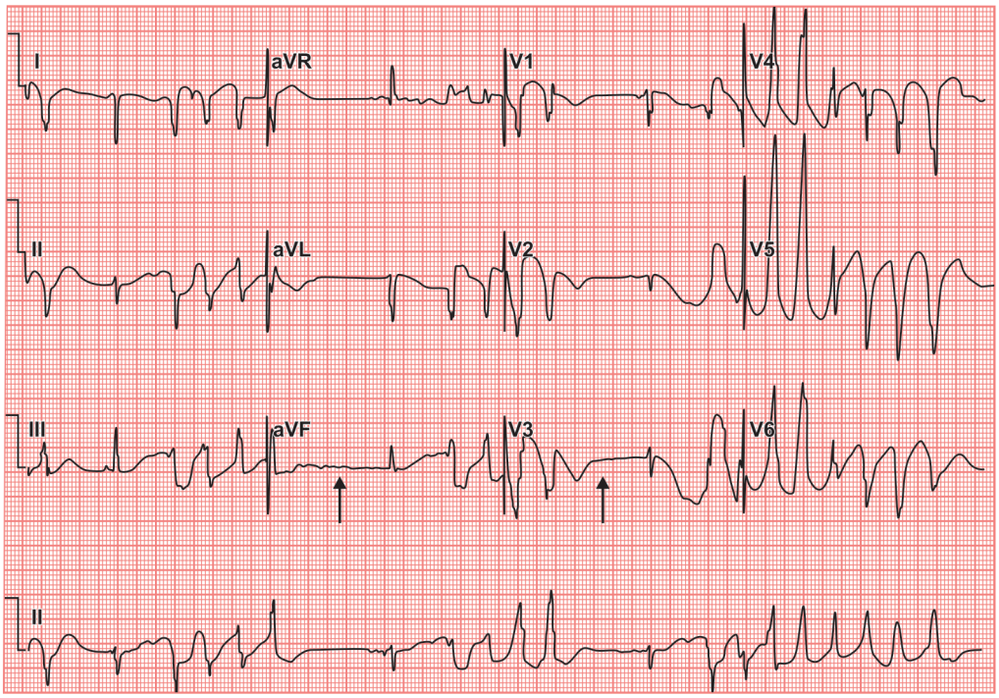

Fig. 10.5: 38 years of patient presented with syncope showed defects in ion channels predispose patients to episodes of torsade de pointes (TdP), which can cause cardiac arrest. TdP is a form of polymorphic ventricular tachycardia that results in a characteristic twisting of the QRS complex around the isoelectric baseline. This arrhythmia is associated with LQTS and can degenerate into more unstable rhythms. In the case of acquired LQTS, a pause usually precedes the onset of TdP. This form of TdP is said to be 'pause dependent' (arrows). Image courtesy of ECG Wave-Maven

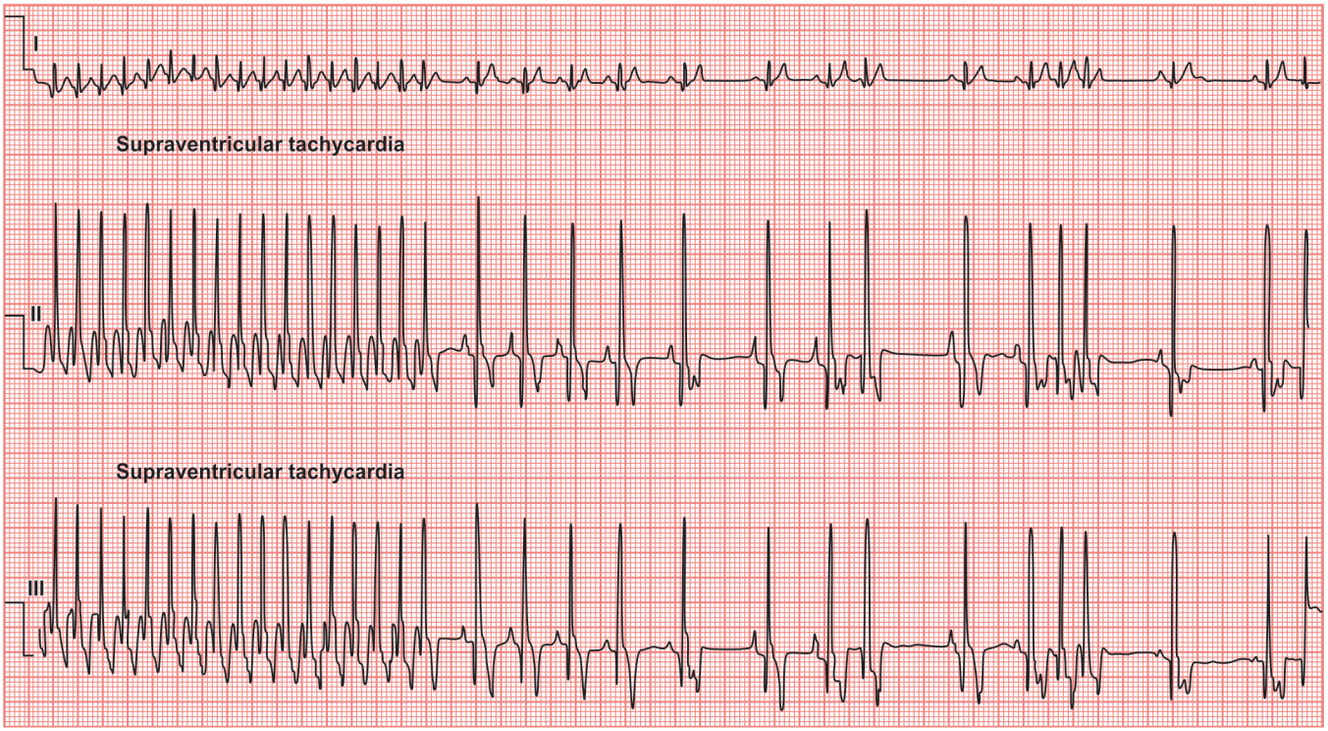

Fig. 10.6: 48-years-patient presented with syncope showed episodes of supraventricular tachycardia

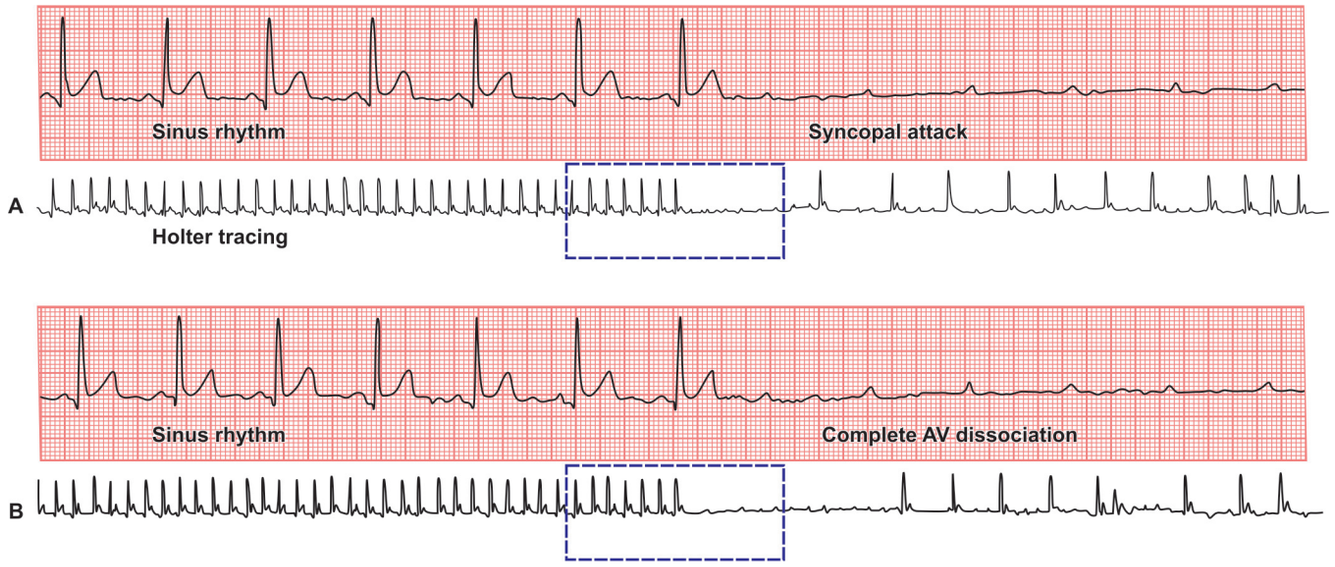

Fig. 10.7: Holter EC graph showing narrow QRS complex in a patient suffering from congenital complete heart block respectively presening as syncopal attacks

Table 10.5: Recommendations: treatment of reflex syncope

Recommendations	Class[a]	Class[b]
• Explanation of the diagnosis, provision of reassurance, and explanation of risk of recurrence are indicated in all patients	I	C
• Isometric PCMs are indicated in patients with prodrome	I	B
• Cardiac pacing should be considered in patients with dominant cardioinhibitory CSS	IIa	B
• Cardiac pacing should be considered in patients with frequent recurrent reflex syncope, age >40 years, and documented spontaneous	IIb	B
• Midodrine may be indicated in patients with VVS refractory to lifestyle measures	IIb	B
• Tilt training may be useful for education of patients but long-term benefit depends on compliance	IIb	B
• Cardiac pacing may be indicated in patients with recurrent frequent unpredictable syncope and age >40 after alternative therapy has failed	IIb	C
• Cardiac pacing is not indicated in the absence of a documented cardioinhibitory reflex	III	C
• β-adrenergic blocking drugs are not indicated	III	A

[a]Class of recommendation. [b]Level of evidence. CSS=carotid sinus syndrome; PCM=physical isometric counterpressure manouuvre; VVS=vasovagal syncope.

autonomic insufficiency can be due to diabetes, uremia, or spinal injury. Drugs such as alcohol cause orthostatic intolerance and medications such as vasodilators and antidepressants block orthostatic reflexes. Volume depletion due to blood loss, vomiting, diarrhea, poor oral intake, and diuretics also cause orthostatic syncope.

Dehydration and decreased intravascular volume contribute to orthostasis (Table 10.6).

Orthostatic syncope describes a causative relationship between orthostatic hypotension and syncope. Orthostatic hypotension increases in prevalence with age as a blunted baroreceptor response results in failure of compensatory cardioacceleration. In elderly patients, 45% of these cases are related to medications. Limited evidence suggests that polydipsia may reduce recurrences.

Orthostasis is a common cause of syncope and tends to be recurrent. Bedside orthostatics cannot exclude this as an aetiology; if suspected, patients should be referred to a primary care provider for outpatient tilt-table testing.

Dehydration and decreased intravascular volume contribute to orthostasis. Orthostatic syncope describes a

Table 10.6: Recommendations: treatment of orthostatic hypotension

Recommendations	Class[a]	Class[b]
• Adequate hydration and salt intake must be maintained	I	C
• Midodrine should be administered as adjunctive therapy if needed	IIa	B
• Fludrocortisone should be administered as adjunctive therapy if needed	IIa	C
• PCMs may be indicated	IIb	C
• Abdominal binders and/or support stockings to reduce venous pooling may be indicated	IIb	C
• Head-up tilt sleeping (>10°) to increase fluid volume may be indicated	IIb	C

[a]Class of recommendation. [b]Level of evidence. PCM=physical counter pressure manoeuvre.

causative relationship between orthostatic hypotension and syncope. Orthostatic hypotension increases in prevalence with age as a blunted baroreceptor response results in failure of compensatory cardioacceleration. In elderly patients, 45% of these cases are related to medications. Limited evidence suggests that polydipsia may reduce recurrences. Orthostasis is a common cause of syncope and tends to be recurrent. Bedside orthostatics cannot exclude this as an aetiology; if suspected, patients should be referred to a primary care provider for outpatient tilt-table testing.

LABORATORY STUDIES

Currently, no specific testing has sufficient power to be absolutely indicated for evaluation of syncope. Research-based and consensus guideline recommendations are listed below.

Serum glucose level: In one study, 2 of 170 patients with syncope tested for serum glucose were found to be hypoglycemic. Despite this low yield, rapid blood glucose assessment is easy, fast, and may be diagnostic, leading to efficient intervention.

CBC count: If performed empirically, a CBC count has an exceedingly low yield in syncope. Some risk stratification protocols use a low hematocrit level as a poor prognostic indicator.

A prospective evaluation of syncope found that 4 of 170 patients had signs and symptoms of GI hemorrhage with a confirmatory CBC count. No occult bleeding was diagnosed based on an empiric CBC count in this study. Anemia has been shown in several studies to suggest poor short-term outcomes.

Serum Electrolyte Levels with Renal Function

These tests if performed empirically have an exceedingly low yield in syncope. Some risk stratification protocols use electrolyte level abnormalities and renal insufficiency as poor prognostic indicators. In the study by Martin et al. 134 patients with syncope had electrolytes drawn as part of the routine workup. One patient was unexpectedly found to be hyponatremic secondary to diuretic use.

Serum electrolyte tests are indicated in patients with altered mental status or in patients in whom seizure is being considered. If arrhythmia is noted, evaluation of electrolytes may be useful.

Cardiac Enzymes

These tests are indicated in patients who give a history of chest pain with syncope, dyspnea with syncope, or exertional syncope; those with multiple cardiac risk factors; and those in whom a cardiac origin is highly suspected.

Total Creatine Kinase

A rise in creatine kinase (CK) levels may be associated with prolonged seizure activity or muscle damage secondary to a prolonged period of loss of consciousness.

BNP level >300 pg/ml is a predictor of serious outcomes at 30 days.

Urinalysis/Dipstick

In elderly and debilitated patients, UTI is common, easily diagnosed, and treatable and may precipitate syncope. UTIs may occur in the absence of fever, leukocytosis, and symptoms in this population.

IMAGING STUDIES

Chest Radiography

In elderly patients and in patients who are debilitated, pneumonia is common, easily diagnosed, and treatable and may precipitate syncope. Pneumonia may occur in the absence of fever, leukocytosis, and symptoms in this population. Evaluation of a select number of etiologies of syncope may be aided by chest radiography. Pneumonia, CHF, lung mass, effusion, and widened mediastinum can all be seen if present and may guide therapy (Figs 10.8 and 10.9).

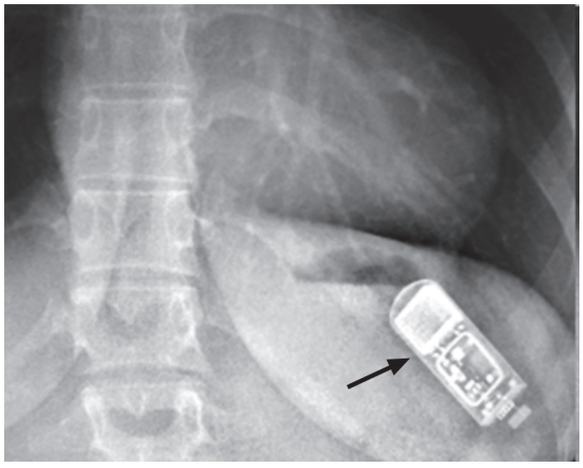

Fig. 10.8: Collimated frontal view of the chest shows an implantable loop recorder (arrow) in the left breast of a 25-year-old woman with syncope

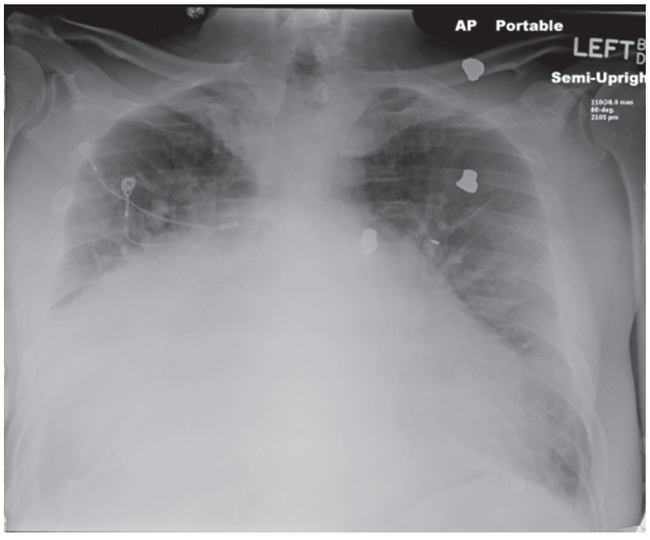

Fig. 10.9: Chest X-ray showing massive cardiomegaly due to CHF in elderly person with syncopal attacks

Head CT Scanning (Noncontrast)

Head CT scanning is not indicated in a nonfocal patient after a syncopal event. This test has a low diagnostic yield in syncope.

Of 134 patients prospectively evaluated for syncope using CT scanning, 39 patients had abnormal findings on scans. Only 1 head CT scan was diagnostic in a patient not expected to have intracranial pathology. Of the remaining scans, 5 showed subdural hematomas thought to be secondary to syncope.

Head CT scanning may be clinically indicated in patients with new neurologic deficits or in patients with head trauma secondary to syncope.

Chest/abdominal CT scanning (Fig. 10.10): This imaging study is indicated only in select cases, such as cases in which aortic dissection, ruptured abdominal aortic aneurysm, or pulmonary embolus is suspected.

Brain MRI/magnetic resonance arteriography (MRA) (Fig. 10.11): These tests may be required in select cases to evaluate vertebrobasilar vasculature and are more appropriately performed on an inpatient basis in consultation with a neurologist or a neurosurgeon.

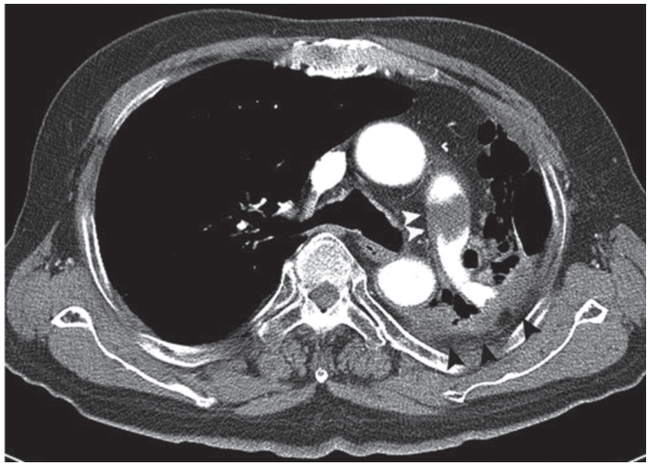

Fig. 10.10: Rarity of isolated pulmonary embolism and acute aortic syndrome occurring outside of the field of view of dedicated coronary CT angiography in patient with syncope

Ventilation-perfusion (V/Q) scanning: This test is appropriate for patients in whom pulmonary embolus is suspected.

Echocardiography (Figs 10.12 and 10.13): In patients with known heart disease, left ventricular function and ejection fraction have been shown to have an accurate predictive correlation with death. Echocardiography is the test of choice for evaluating suspected mechanical cardiac causes of syncope

Electrocardiography (Figs 10.14–10.20 and Tables 10.7–10.9): Obtain a standard 12-lead ECG in syncope. This is a level A recommendation by 2007 ACEP consensus

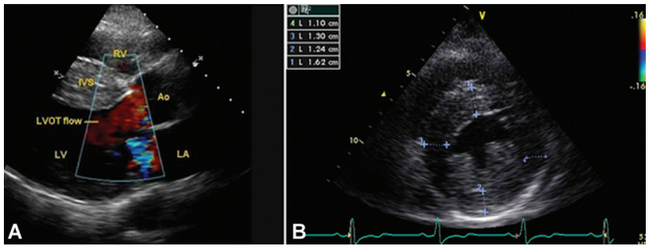

Fig. 10.12: Color Doppler 2-D echocardiogram in long (A) and short axis (B) views showing marked hypertrophy of interventricular septum and posterior left ventricular wall, almost approximating anterior mitral valve leaflet with hypertrophied interventricular septum producing severe left ventricular outflow tract obstruction in patient with hypertrophic cardiomyopathy presenting as syncopal attack

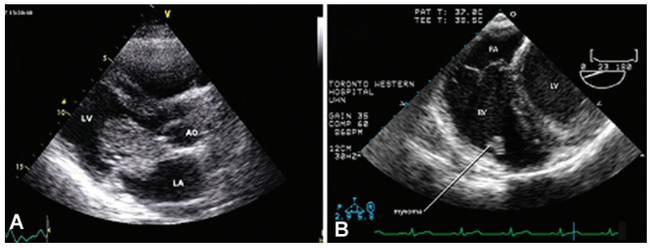

Fig. 10.13: (A) 2-D LAX view showing mass prolapsing across the mitral valve during diastole. (B) TEE showing myxoma in the right ventricular cavity in two different patients presenting with syncopal attacks

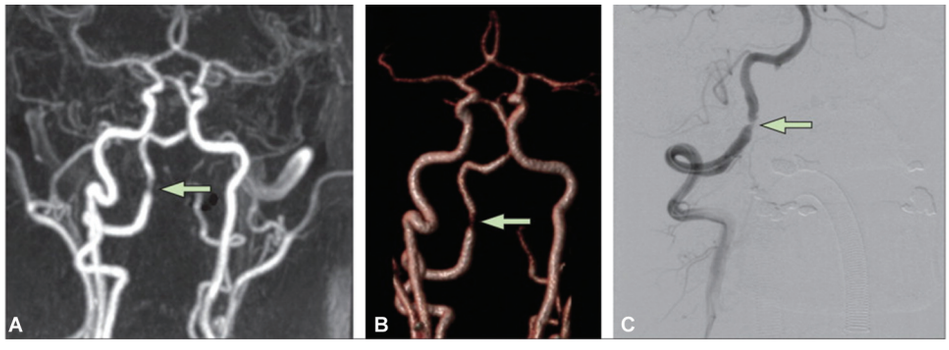

Fig. 10.11: MRI (A) CT angiography (B) and conventional angiography (C) of posterior circulation in an elderly patient with ischemic stroke and transient syncopal attack

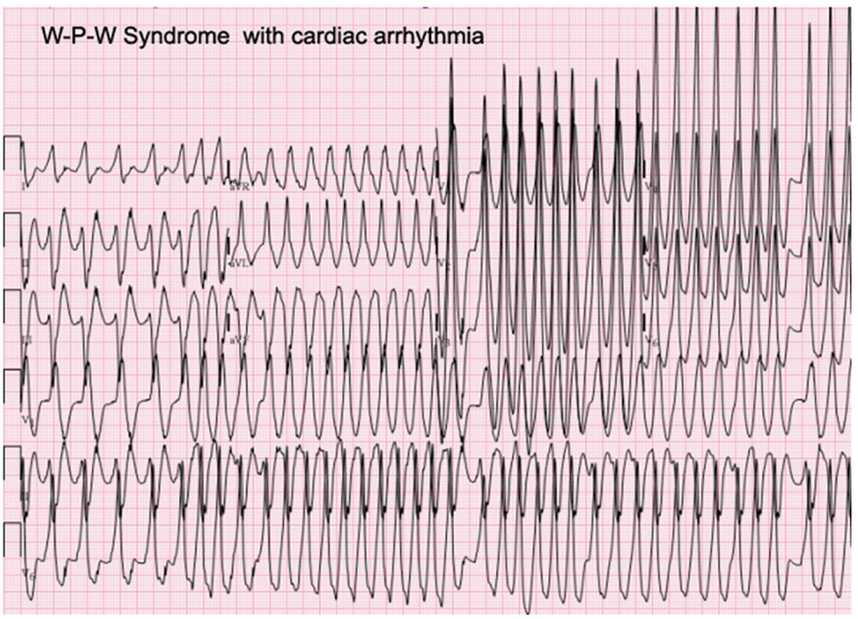

Fig. 10.14: ECG—supraventricular arrhythmia in W-P-W syndrome in patient with syncopal attacks

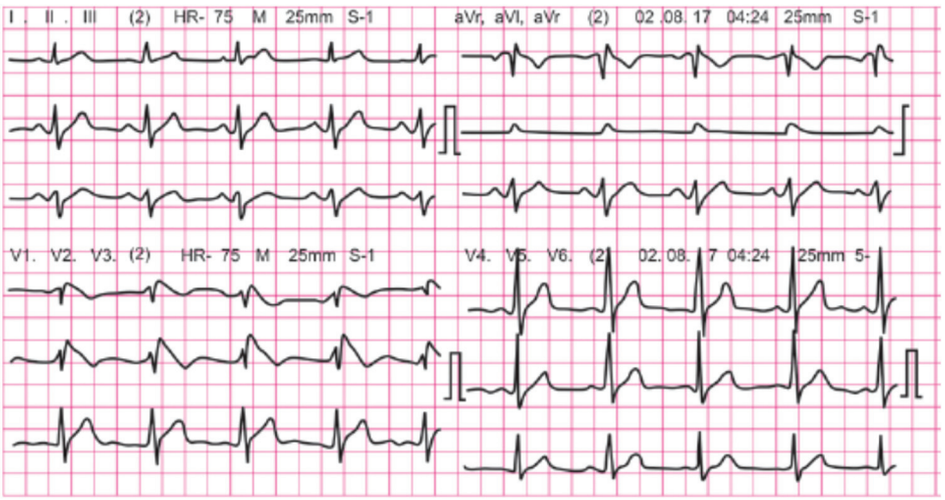

Fig. 10.15: Holter diagnosis of Brugada syndrome in a young male who presented with syncopal episode

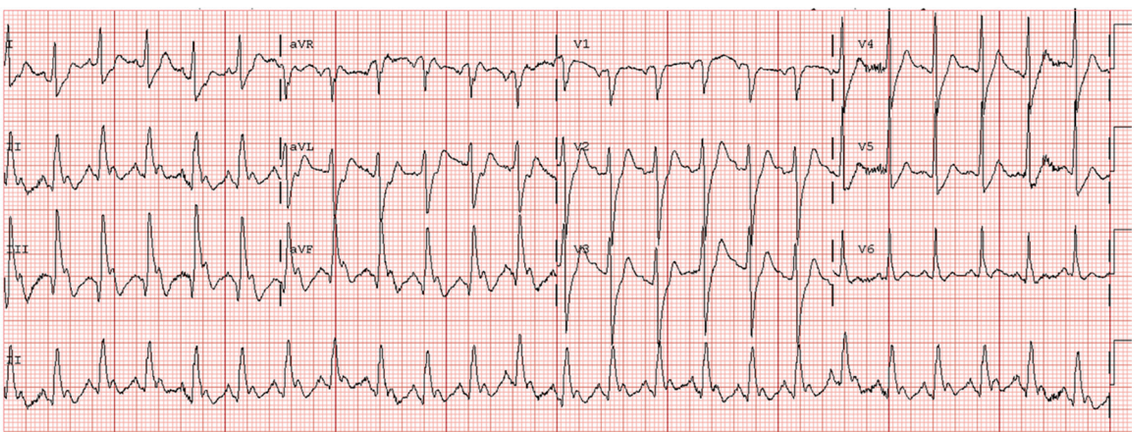

Fig. 10.16: ECG—atrial flutter in patient with syncopal attacks

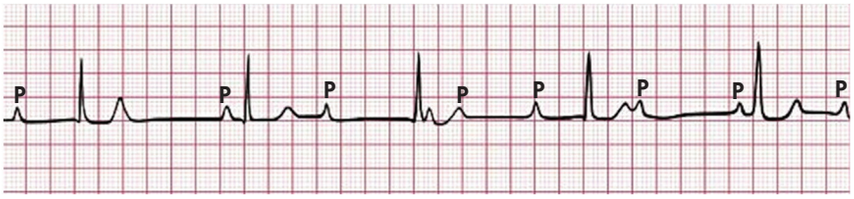

Fig. 10.17: ECG—complete AV dissociation in patient with syncopal attacks

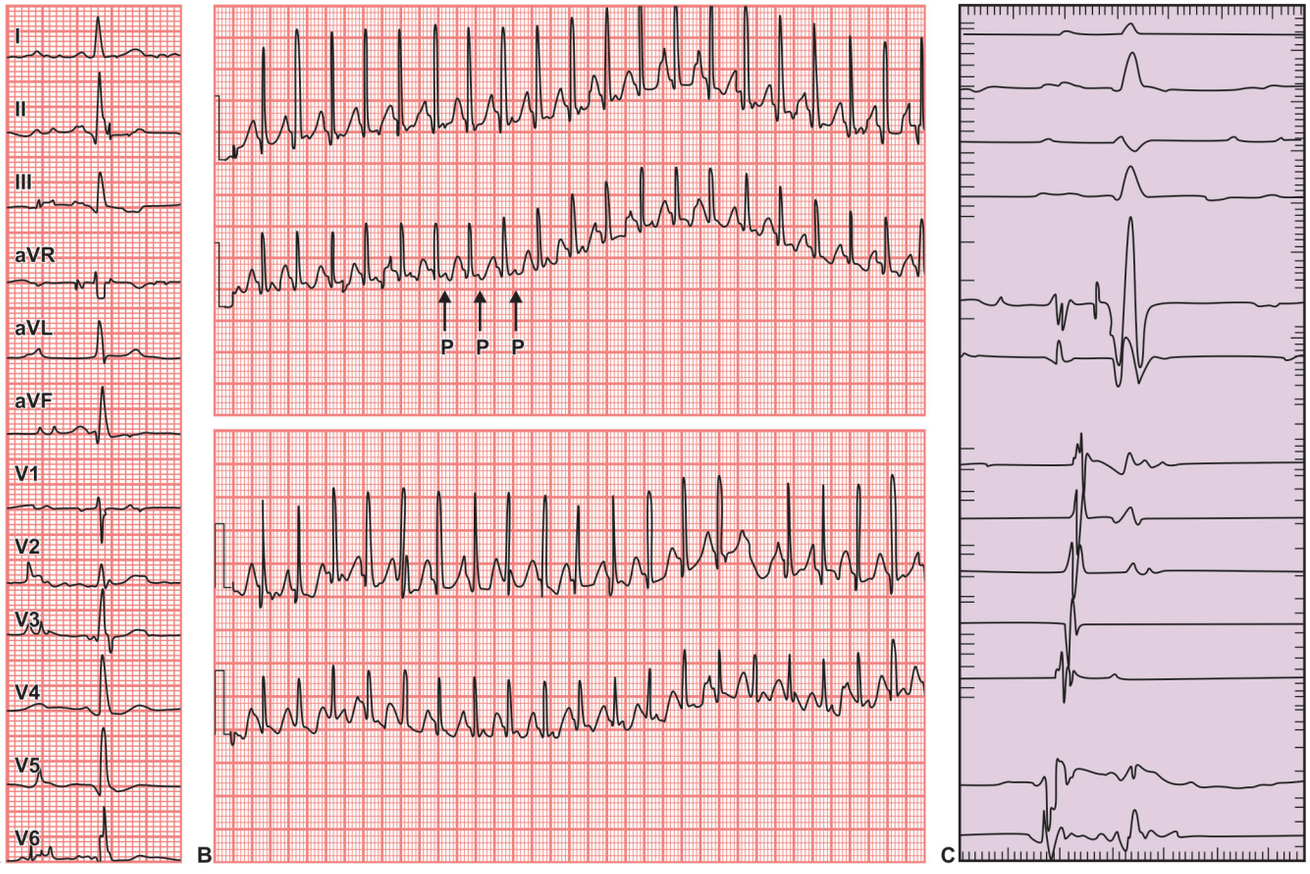

Fig. 10.18: (A) Rest 12-lead ECG. (B) ECG Holter tracing showing two episodes of long PR–short RP, narrow complex symptomatic tachycardia. (C) Intracardiac recordings. Rest AH and HV intervals are, respectively, 110 and 35 ms, are displayed I, II, V1, and V6 surface ECG channels, recordings from distal and proximal His bundle (His 1–2 and His 3–4), distal to proximal decapolar CS (CS 1–2, 3–4, 5–6, 7–8, and 9–10), and distal and proximal right atrium (OD 1–2 and OD 3–4). Sweep speed is 100 mm/s

guidelines for syncope. ECG is used in most every clinical decision rule for risk stratification. Normal ECG findings are a good prognostic sign. ECG can be diagnostic for acute MI or myocardial ischemia and can provide objective evidence of preexisting cardiac disease or dysrhythmia such as **Wolff-Parkinson-White syndrome, Brugada syndrome, atrial flutter, or AV blocks.**

Bradycardia, sinus pauses, nonsustained ventricular tachycardia and sustained ventricular tachycardia, and atrioventricular conduction defects occur with increasing frequency with age and are truly diagnostic only when they coincide with symptoms.

Holter monitor/loop event recorder (Figs 10.21–10.25): This is an outpatient test. In the past, all patients with syncope were monitored for 24 hours in a hospital. Later, loop recorders and signal-averaged event recorders allowed for monitoring over longer time periods, which increased the yield of detecting an arrhythmia.

Recent studies show that age-matched asymptomatic populations have an equivalent number of arrhythmic events recorded by ambulatory monitoring. Loop recorders have a higher diagnostic yield than Holter monitor evaluation with a marginal cost savings. A study completed through an ECG outpatient registry in Vermont by Gibson and Heitzman involving 1512 patients referred for syncope, showed that symptomatic arrhythmias were found in just 0.5% of patients. In fact, patients had symptoms without arrhythmias more often than symptoms with arrhythmias, advancing the notion that ambulatory monitoring has a higher negative than positive diagnostic yield.

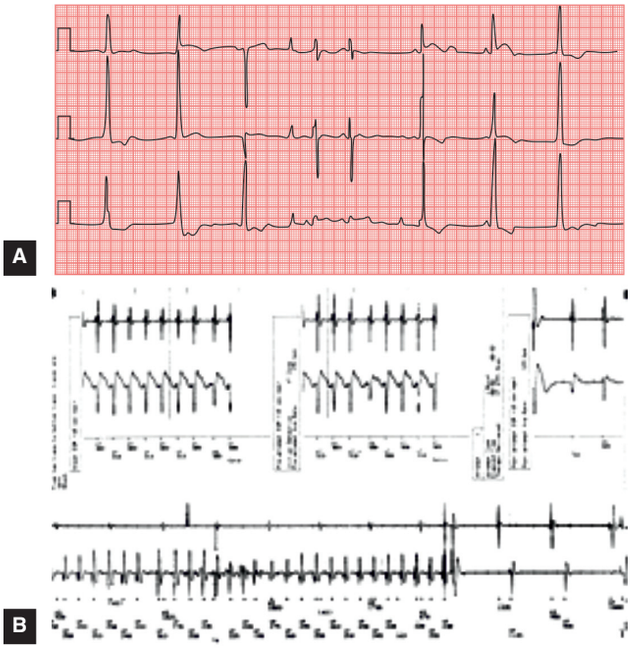

Fig. 10.19: HCM. (A) This ECG from a patient with HCM who presented with recurrent syncopal spells shows severe left ventricular hypertrophy and Wolff-Parkinson-White pattern. (B) ICD intracardiac electrogram with successful conversion using antitachycardia pacing for VT (top) and an appropriate shock-converting VF (bottom)

Head-up tilt-table test (Figs 10.26 and 10.27, Tables 10.10 and 10.11): This test is useful for confirming autonomic dysfunction and can generally be safely arranged on an outpatient basis. The test involves using a tilt table to stand a patient at 70 degrees for 45 minutes. Various modified protocols with concomitant medications, fasting, and maneuvers exist. Normally norepinephrine (NE) levels rise initially and are maintained to hold BP constant. A positive result occurs when NE levels fatigue with time and a falling BP and pulse rate produce symptoms. The head-up tilt-table test is less sensitive than electrophysiologic stress testing, and a negative result does not exclude the diagnosis of neurogenic syncope.

Electrophysiological studies: It may be useful in those cases where Holter ECG and other noninvasive studies are found noncontributory (Figs 10.28–10.30 and Table 10.12).

Electroencephalography: Electroencephalography (EEG) can be performed at the discretion of a neurologist if seizure is considered a likely alternative diagnosis.

Stress test: Stress test/electrophysiologic studies (EPS) have a higher diagnostic yield than the Holter monitor and should be obtained for any patient with a suspected arrhythmia as a cause of syncope.

A cardiac stress test is appropriate for patients in whom cardiac syncope is suspected and in whom have risk factors

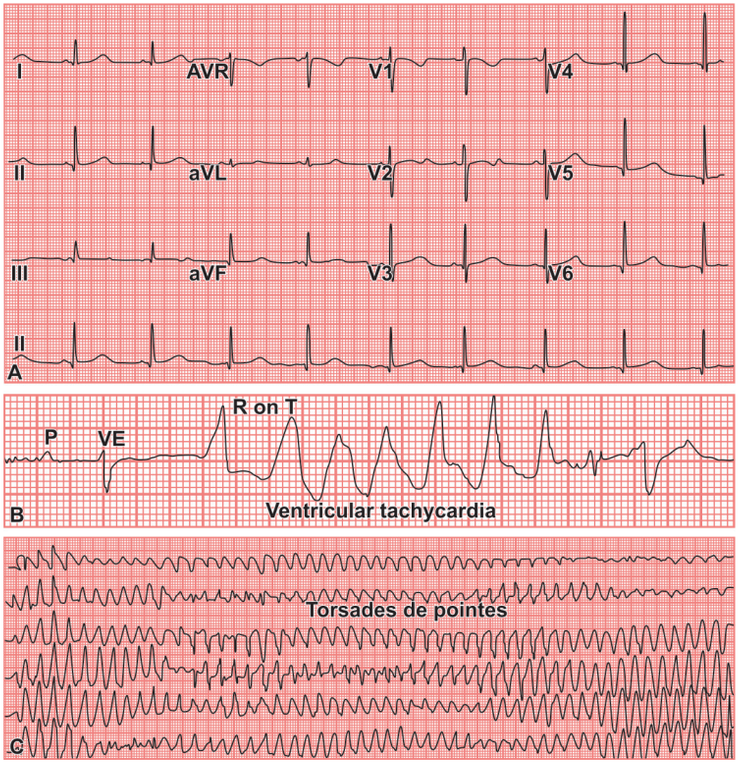

Fig. 10.20: ECG findings in patient with long QT syndrome type 2. (A) ECG of an 80-year-old woman with recurrent syncope. As is typical in LQTS, the QTc interval is prolonged at 500 ms. The subtype of LQTS can be predicted from a detailed examination of the T-wave (Zhang et al. 2004). In this case, the biphasic T-waves in V2 and lead III were consistent with a hERG mutation. (B) Cardiac telemetry recording showed the onset of TdP, with an 'R on T' initiation. (C) Subsequent ECG, during syncope, illustrates the characteristic appearance of TdP

Table 10.7: Recommendations—electrophysiological monitoring

Recommendations	Class[a]	Class[b]
Indications		
ECG monitoring is indicated in patients who have clinical or ECG features suggesting arrhythmic syncope (listed in Table 10.10). The duration (and technology) of monitoring should be selecated according the risk and the predicted recurrence rate of syncope.	I	B
• Immediate in-hospital monitoring (in bed or telemetric) is indicated in high risk patients defined in Table 10.11	I	C
• Holter monitoring is indicated in patients who have very frequent syncope or pre-syncope (≥1 per week)	I	B
• ILR is indicated in:		
» An early phase of evaluation in patients with recurrent syncope of uncertain orgin, abscence of high risk criteria listed in Table 10.11 and a high likehood of recurrence within battery longevity of the device	I	B
» High risk patients in whom a comprehensive evaluation did not demonstrate a cause of syncope or lead to a specific treatment	I	B
• ILR should be considered to assess the contribution of bradycardia before embarking cardiac pacing in patients with suspected or certain reflex syncope presenting with frequent or traumatic syncopal episodes	IIa	B
• External loop recorders should be considered in patients who have an intersymptom interval ≤4 weeks	IIa	B
Diagnostic criteria		
• ECG monitoring is diagnostic when a correlation between syncope and an arrhythmia (brady- or tachyarrhythmia) is detected	I	B
• In the absence of such correlation, ECG monitoring is diagnostic when periods of Mobiz II or III degree AV block or a ventricular pause >3s (with the possible exception of young trained persons, during sleep, medicated patients, or rate-controlled atrial fibrilation), or rapid prolonged paroxysmal SVT or Vt are detected. The absence of arrhychmia during syncope excludes arrhythmic syncope	I	C
• The ECG documentation of pre-syncope without any relevant arrhythmia is not an accurate surrogate for syncope	III	C
• Aysmptomatic arrhythmias (other than those listed above) are not an accurate surrogate for syncope	III	C
• Sinus bradycardia (in the absence of syncope) is not an accurate surrogate for syncope	III	C

[a]Class of recommendation. [b]Level of evidence. AV=atrioventricular; ECG=electrocardiogram; ILR=implantable loopr recorder; SVT=supra-ventriculartachyradia; VT=ventricular tachycardia.

Table 10.8: ECG abnormalities suggesting arrhythmic syncope

- Bifascicular block (defined as either left bundle branch block or right bundle branch block combined with left anterior or left posterior fascicular block)
- Other intraventricular conduction abnormalities (QRS duration ≥0.12 s)
- Mobitz I second degree atrioventricular block
- Asymptomatic sinus bradycardia (<50 beats/min) or sino-atrial block
- Pre-excited QRS complexes
- Prolonged QT interval
- Right bundle branch block pattern with ST-elevation in leads V1–V3 (Brugada syndrome)
- Negative T-waves in right precordial leads, epsilon waves and ventricular late potentials suggestive of arrhythmogenic right ventricular dysplasia
- Q-waves suggesting myocardial infarction

for coronary atherosclerosis. This test can assist with cardiac risk stratification and can guide future therapy.

PROCEDURES

Carotid sinus massage (Figs 10.31 and Table 10.13) has been used with some success to diagnose carotid sinus syncope. Patients are placed on a cardiac monitor and beat-to-beat BP monitoring device. Atropine is kept at the bedside.

Longitudinal massage lasting 5 seconds is initiated at the point of greatest carotid pulse intensity at the level of the thyroid cartilage on one side at a time. The maximal response occurs after approximately 18 seconds, and a positive result is one that produces 3 seconds of asystole or syncope. If the result is negative, the process is repeated on the other carotid sinus. Carotid sinus massage may theoretically precipitate an embolic stroke in persons with preexisting carotid artery disease.

Table 10.9: Most useful and less useful tests

	Test	Suspected diagnosis
Most useful	Carotid sinus massage	Neurally-mediated
	Tilt testing	Neurally-mediated
	Echocardiogram	Cardiac
	Holter/external loop monitoring	Cardiac
	Electrophysiological test	Cardiac
	Exercise stress testing	Cardiac
	Implantable loop recorder	Neurally-mediated and cardiac
Less useful (indicated only in selected cases)	Electroencephalography	Epilepsy and TIA
	Brain computed tomography	Epilepsy and TIA
	Brain magnetic resonance imaging	Epilepsy and TIA
	Carotid Doppler sonography	Epilepsy and TIA
	Coronary angiography	Cardiac
	Pulmonary computed tomography/scintigraphy	Cardiac
	Chest X-ray	Cardiac
	Abdominal ultrasound examination	Comorbidities

TIA=transient ischemic attack

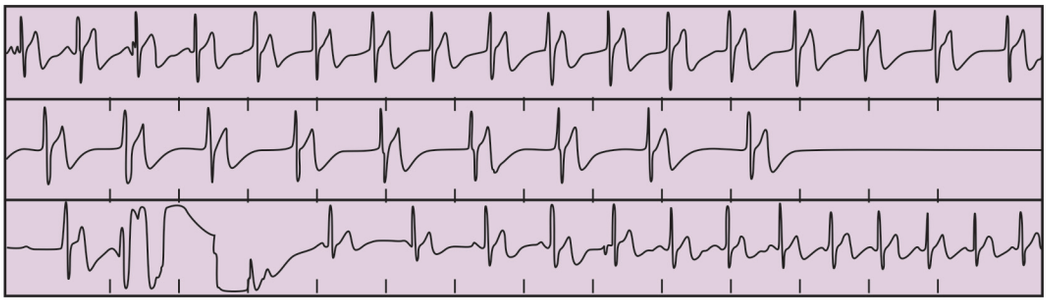

Fig. 10.21: Utility of implantable loop recorder in the diagnosis of unexplained syncope. Event recorder tracing showing a 4.8s asystole period in a 31-year-old subject. Time is indicated on the right scale. After a few sinus beats, there is a progressive slowing of a junctional rhythm ending into asystole. Recovery of sinus rhythm is evident in the bottom panel

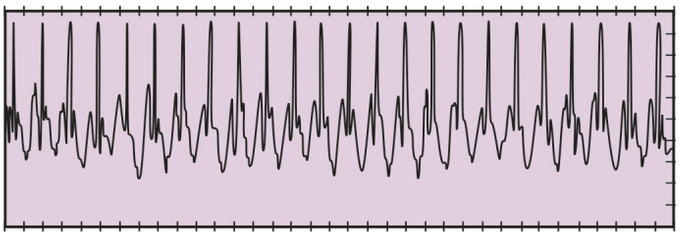

Fig. 10.22: The single-lead ECG tracing from ILR in patient 13 showing SVT at 214 beats per minute

EMERGENCY DEPARTMENT CARE

In patients brought to the ED with a presumptive diagnosis of syncope, appropriate initial interventions include intravenous access, oxygen administration, and cardiac monitoring. ECG and rapid blood glucose evaluation should be promptly performed. A study to determine the sensitivity and specificity of the San Francisco Syncope Rule (SFSR) ECG criteria for determining cardiac outcomes found that when used correctly, the criteria can help predict which syncope patients are at risk of cardiac outcomes. ECG

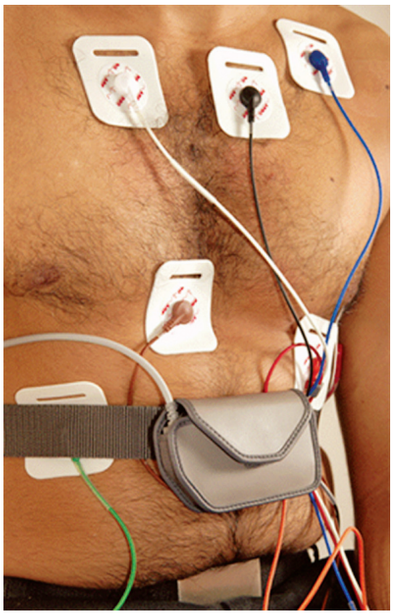

Fig. 10.23: Holter fitting on the chest of 30-year-old man with frequent syncopal attacks

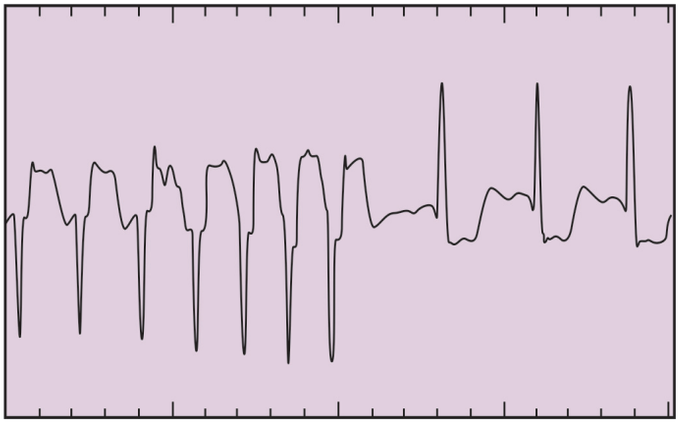

Fig. 10.24: The single-lead ECG tracing from ILR in patient 20 shows nonsustained VT with abrupt termination, followed by normal sinus rhythm

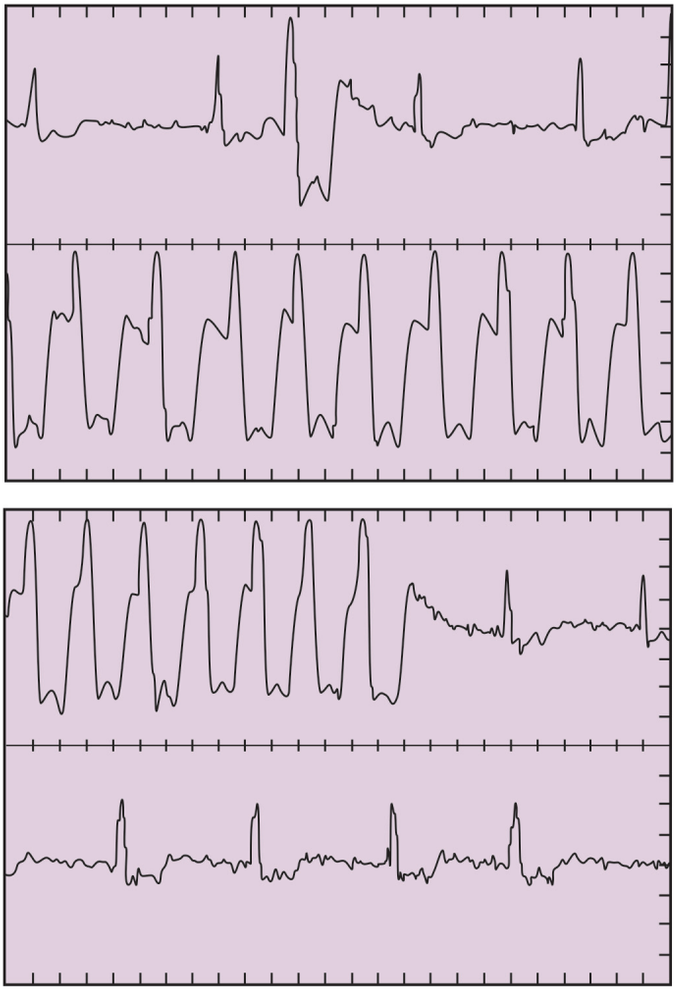

Fig. 10.25: Utility of implantable loop recorder in the diagnosis of unexplained syncope event recorder tracing showing a bout of wide QRS tachycardia during a syncopal episode

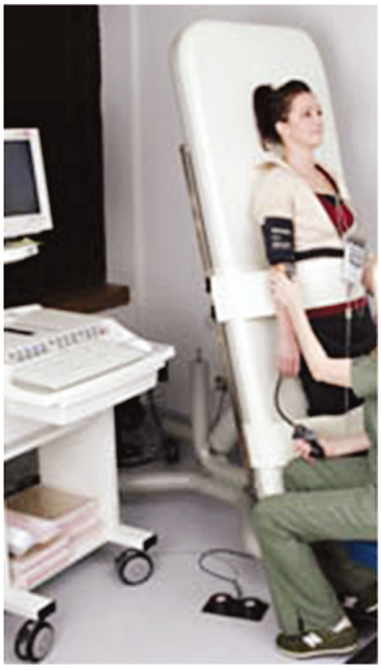

Fig. 10.26: Performance of HUTT Test a patient with syncopal attack

criteria predicted 36 of 42 patients with cardiac outcomes, with a sensitivity of 86%, a specificity of 70%, and a negative predictive value of 99% (Table 10.14).

Syncope may be the manifestation of an acute life-threatening process but is generally not emergent. Clinically ruling out certain processes is important. The treatment choice for syncope depends on the cause or precipitant of the syncope. Patients in whom a cause cannot be ascertained in the ED, especially if they have experienced significant trauma, warrant supportive care and monitoring.

Situational syncope treatment focuses on educating patients about the condition. For example, in carotid sinus syncope, patients should be instructed not to wear tight collars, to use a razor rather than electric shaver, and to maintain good hydration status; they should also be informed of the possibility of pacemaker placement in the future.

Orthostatic syncope treatment also focuses on educating the patient. Inform patients about avoiding postprandial dips in BP, teach them to elevate the head of their bed to prevent rapid BP fluctuations on arising from bed, and emphasize the importance of assuming an upright posture slowly. Additional therapy may include thromboembolic disease (TED) stockings, mineralocorticoids (e.g. fludrocortisone for volume expansion), and other drugs such as midodrine (an alpha1-agonist with vasopressor activity). Patients' medications must be reviewed carefully to eliminate drugs associated with hypotension. Intentional oral fluid consumption is useful in decreasing frequency and severity of symptoms in these patients.

Table 10.10: Recommendations—tilt testing

Recommendations	Class[a]	Class[b]
Methodology		
• Supine pre-tilt phase of at least 5 min. when no venous cannulation, and of at least 20 min. when cannulation is undertaken, is recommended	I	C
• Tilt angle between 60° and 70° is recommended	I	B
• Passive phase of a minimum of 20 min and a maximum of 45 min is recommended	I	B
• For nitroglycerine, a fixed dose of 300–400 µg sublingually administered in the upright position is recommended	I	B
• For isoproterenol, an incremental infusion rate from 1 mg/min up to 3 mg/min in order to increase average heart rate by ~20–25% over baseline is recommended	I	B
Indications		
• Tilt testing is indicated in the case of an unexplained single syncopal episode in high risk setting (e.g. occurrence of, or potential risk of physical injury or with occupational implications) or recurrent episodes in the absence of organic heart disease, or in the presence of organic heart disease, after cardiac causes of syncope have been excluded	I	B
• Tilt testing is indicated when it is of clinical value to demonstrate susceptibility to reflex syncope to the patient	I	C
• Tilt testing should be considered to discriminate between reflex and OH syncope	IIa	C
• Tilt testing may be considered for differentiating syncope with jerking movements from epilepsy	IIb	C
• Tilt testing may be indicated for evaluating patients with frequent syncope and psychiatric disease	IIb	C
• Tilt testing is not recommended for assesment of treatment	IIb	C
• Tilt testing is not recommended for assessment of treatment	III	B
• Isoproterenol tilt testing is contraindicated in patients with ischemic heart disease	III	C
Diagnostic criteria		
• In patients without structural heart disease the induction of reflex hypotension/bradycardia with reproduction of syncope or progessive OH (with or without symptoms) are diagnostic of reflex syncope and OH, respectively	I	B
• In patients without structural heart disease the induction of reflex hypotension/bradycardia without reproduction of syncope may be diagnostic of reflex syncope	IIa	B
• In patients with structural heart disease, arrhythmia or other cardiovascular cause of syncope should be excluded prior to considering positive tilt test results as diagnostic	IIa	C
• Induction of LOC in absence of hypotension and/or bradycardia should be considered diagnostic of psychogenic pseudosyncope.	IIa	C

[a]Class of recommendation. [b]Level of evidence. BP=blood pressure; CSM=carotid sinus massage; HR=heart rate; LOC=loss of consciousness; OH=orthostatic hypotension; TIA=transient ischaemic attack; mg=micrograms.

Table 10.11: Classification of vasovagal syncope induced by head-up tilt table testing

Type	Classification
Type 1 mixed	Ventricular rate during syncope 40 bpm or falls to <40 bpm for <10 sec asystole for <3 sec. BP falls prior to heart rate
Type 2A cardioinhibitory	Ventricular rate during syncope <40 bpm for >10 sec or asystole for >3s. BP falls prior to heart rate
Type 2B cardioinhibitory	Ventricular rate at syncope <40 bpm for >10s or asystole for >3s. BP falls to <80 mmHg systolic at or after rapid fall in heart rate (as above)
Type 3 pure vasodepressor	Heart rate does not fall more than 10% from its peak at syncope. Fall in BP precipitates syncope.

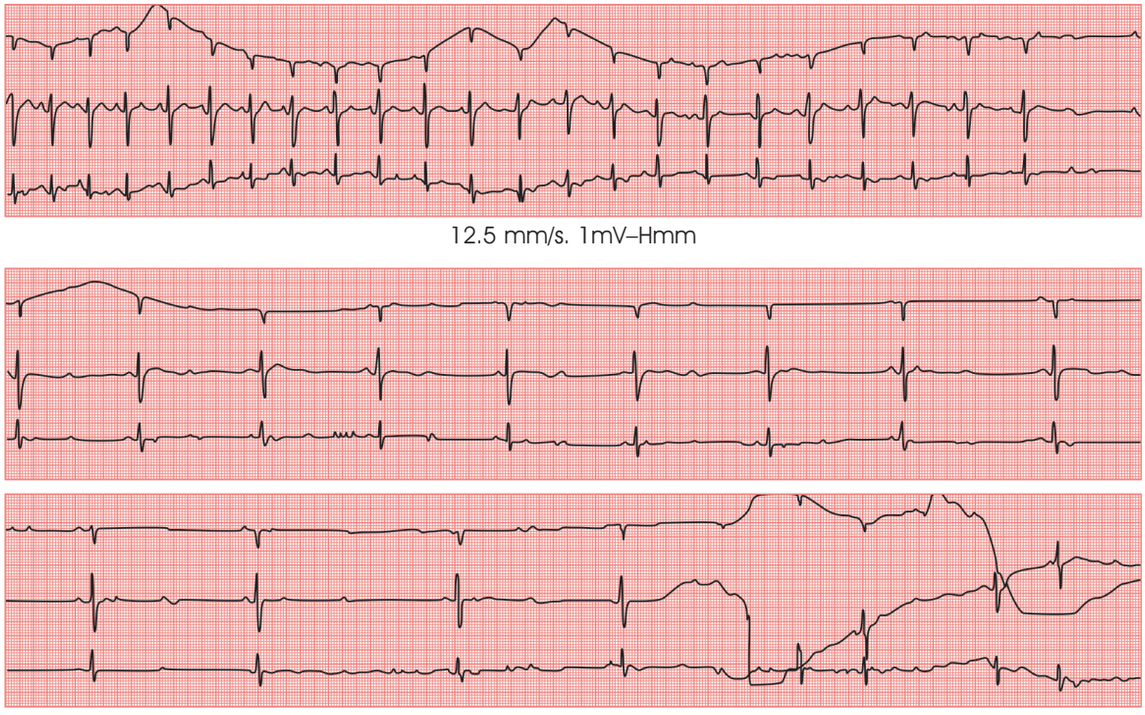

Fig. 10.27: Electrocardiographic characteristics of atrioventricular block induced by tilt testing. Electrocardiographic Holter recordings at 12.5 mm/s, 3 consecutive strips. The electrocardiographic tracing begins with sinus rhythm slowing, PR prolongation and then 2:1 (48.4% of patients) atrioventricular block occurs, ending with Mobitz I (35.5% of patients) second-degree atrioventricular block

Table 10.12: Recommendations—electrophysiological study

Recommendations	Class[a]	Class[b]
Indications		
• In patients with ischemic heart disease EPS is indicated when initial evaluation suggests an arrhythmic cause of syncope (listed in Table 10.10) unless there is already an established indication for ICD	I	B
• In patients with BBB, EPS should be considered when noninvasive tests have failed to make the diagnosis	IIa	B
• In patients with syncope proceded by sudden and brief palpitations, EPS may be performed when other non-invasive tests have failed to make the diagnosis	IIb	B
• In patients with Brugada syndrome, ARVC and hypertrophic cardiomyopathy an EPS may be performed in selected cases	IIb	C
• In patients with high-risk occupations, in whom every effort to exdude a cardiovascular cause of syncope is warranted, an EPS may be performed in selected cases	IIb	C
• EPS is not recommended in patients with normal ECG, no heart disease, and no palpitations	III	B
Diagnostic criteria		
• EPS is diagnostic, and no additional tests are required, in the following causes:		
» Sinus bradycardia and prolonged CSNRT (>525 ms)	I	B
» BBB and either a baseline HV interval of ≥100 ms, or second or third degree His-Purkinje block is demonstrated during incremental airtal packing or with pharmacological challenge	I	B
» Induction of sustained monomorphic VT in patients with previous myocardial infarction	I	B
» Induction of rapid SVT which reproduces hypotensive or spontanous systems	I	B
• An HV interval between 7 ms and 100 ms should be considered diagnostic	IIa	B
• The induction of polymorphic VT or ventricular fibrilation in patients with Brugada syndrome, ARVC and paitnets resuscitated from cardiac arrest may be considered diagnostic	IIb	B
• The induction of polymorphic VT or ventricular fibrillation in patients with ischemic cardiomyopathy or DCM cannot be considered a diagnostic finding	III	B

[a]Class of recommendation. [b]Level of evidence. ARVC=arrhythmogenic right ventricular cardiomyopathy; BBB=bundle branch block; CSNRT=corrected sinus node recovery time; DCM=dilated cardiomyopathy; EPS=electrophysiological study; ICD=implantable cardioverter defibrillator; HV=His-ventricle; SVT=supraventricular tachycardia; VT=ventricular tachycardia.

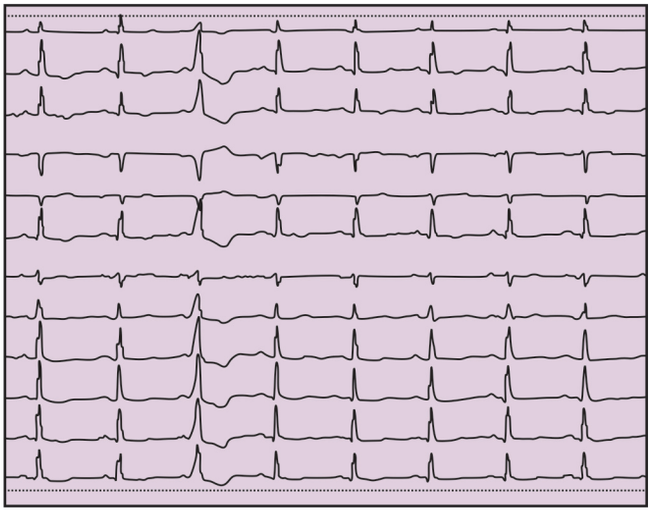

Fig. 10.28: Intermittent fasciculoventricular pathway: ECG and electrophysiologic findings, clinical implications 12-lead ECG unregistered during electrophysiologic study after resumption of sinus rate acceleration induced by isoproterenol infusion. Intermittent ventricular pre-excitation visualized (third complex from the left to the right). Sweep speed is 50 mm/s

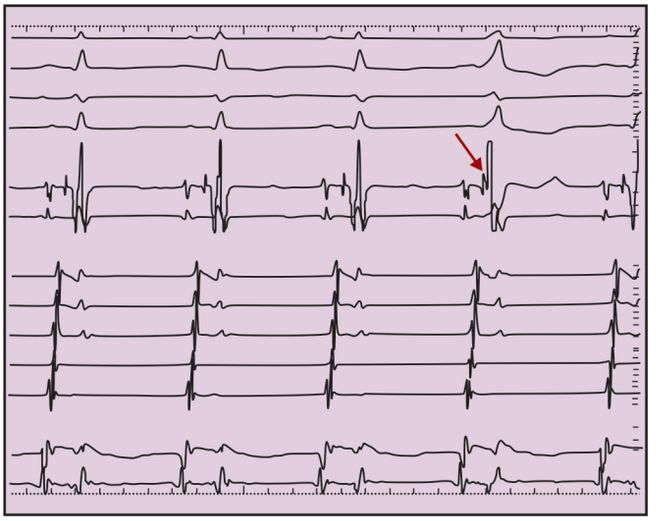

Fig. 10.29: Intracardiac recordings of an intermittent pre-excited ventricular complex (fourth complex—black arrow—from the left to the right). H and V potentials are merged. There is no change among the CS ventricular activation pattern. Sweep speed is 100 mm/s

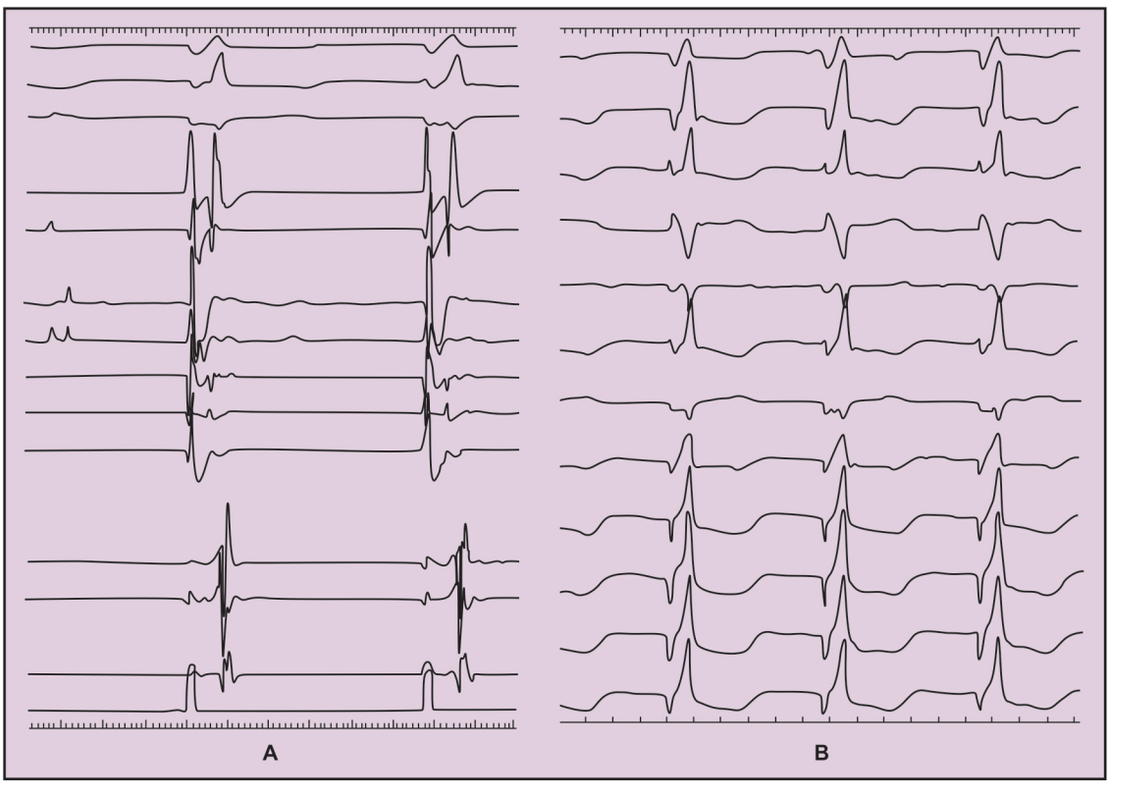

Fig. 10.30: (A) Intracardiac recordings during pacing from the para-Hisian region. Capture of the FV accessory pathway. The QRS morphology induced by pacing reproduces exactly the intermittent ventricular pre-excitation pattern visualized previously (Figs 2 and 3), are displayed leads I, aVF, and V1 surface ECG channels, recordings from the distal and proximal para-Hisian catheter (ABL d and ABL p), distal to proximal decapolar His bundle (His 1–2, 3–4, 5–6, 7–8, and 9–10), distal to proximal CS (CS 1–2 and CS 3–4), and bipolar right atrium (RA d). Sweep speed is 150 mm/s. (B) 12-lead ECG recordings during pacing from the para-Hisian region with capture of the FV accessory pathway. The QRS morphology is identical to that of the intermittent ventricular pre-excitation pattern. Sweep speed is 100 mm/s

Table 10.13: Recommendations—carotid sinus massage

Recommendations	Class[a]	Class[b]
Indications		
• CSM is indicated in patients >40 years with syncope of unknown aetiology after initial evaluation	I	B
• CSM should be avoded in patients with TIA or stroke within the past 2 months and in patients with carotid bruits (except if carotid Doppler studies)	III	C
Diagnostic criteria		
• CSM is diagnostic if syncope is reproduced in the presence of asystole longer than 3s and/or a fall in systolic BP >50 mmHg	I	B

[a]Class of recommendation. [b]Level of evidence. BP=blood pressure; CSM=carotid sinus massage; TIA=transient ischemic attack.

Table 10.14: Recommendations—indications for ICD in patients with unexplained syncope and a high risk of SCD

Recommendations	Class[a]	Level[b]	Comments
• In patients with ischemic cardiomyopathy with severely depressed LVEF or HF. ICD–cardiac resynchronization therapy implantation	I	A	
• In patients with nonischemic cardiomyopathy with severely depressed LVEF or HF. ICD therapy is indicated according to current guidelines for ICD–cardiac resynchronization therapy implantation	I	A	
• In hypertrophic cardiomyopathy ICD therapy should be condisered in patients at high risk (see text)	IIa	C	In non-high risk, consider ILR
• In right ventricular cardiomyopathy ICD thrapy should be condisered in patients at high risk (see text)	IIa	C	In non-high risk, consider ILR
• In Brugada syndrome ICD therapy should be considered in patients with spontaneous type I ECG	IIa	B	In the absence of spontaneous type I pattern, consider ILR
• In long QT syndrome, ICD therapy, in conjunction with beta-blockers, should be consider in patients at risk	IIa	B	In non-high risk, consider ILR
• In patients with ischemic cardiomyopathy without severely depressed LVEF or HF and negative programmed electrical stimulation ICD therapy may be considered	IIb	C	Consider ILR to help define the nature of unexplained syncope
• In patients with nonischemic cardiomyopathy without severely depressed LVEF or HF ICD therapy may be considered	IIb	C	Consider ILR to help define the nature of unexplained syncope

[a]Class of recommendation. [b]Level of evidence. HF=heart failure; ECG=electrocardiogram; ICD=implantable cardioverter defibrillator; ILR=implantable loop recorder; LVEF=left ventricular ejection fraction; SCD=sudden cardiac death

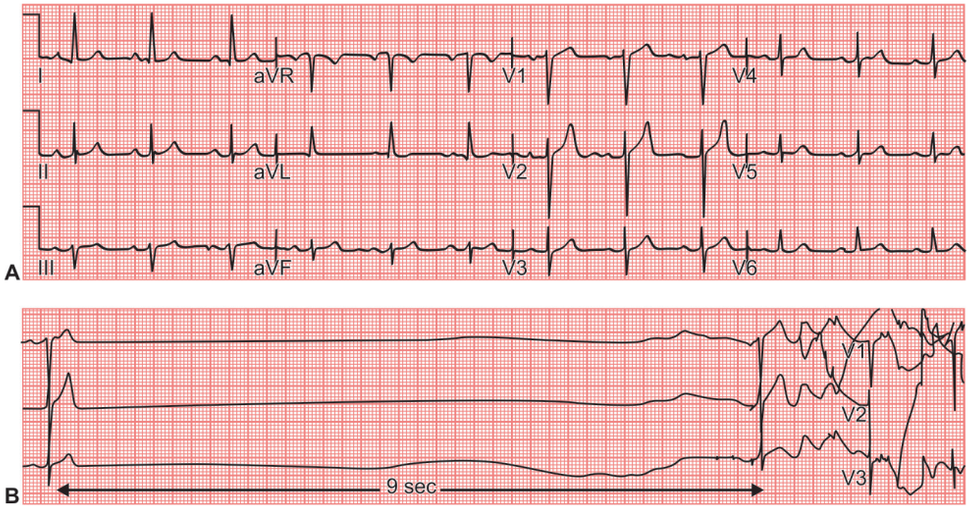

Fig. 10.31: Carotid sinus hypersensitivity revealed during massage manoeuvre. (A) Electrocardiographic at rest. Heart rate=72 bpm, PR interval=174 ms. (B) Electrocardiographic during carotid sinus massage resulting in syncopal attack

Table 10.15: Recommendations—treatment of syncope due to cardiac arrhythmias

Recommendations	Class[a]	Level[b]
• Syncope due to cardiac arrhythmias must receive treatment appropriate to the cause	I	C
Cardiac pacing		
• Pacing is indicated in patients with sinus node disease in whom syncope is demonstrated to be due to sinus arrest (symptom ECG correlation) without a correctable cause	I	C
• Pacing is indicated in sinus node disease patients with syncope and abnormal CSNRT	I	C
• Pacing is indicated in sinus node disease patients with syncope and asymptomatic pauses ≥3s (with the possible eaxceptions of yound trained persons, during sleep and in medicated patients)	I	C
• Pacing is indicated in patients with syncope and second degree Mobilz II, advanced or complete AV block	I	B
• Pacing is indicated in patients with syncope, BBB, and positive EPS	I	B
• Pacing should be considered in patients with unexplained syncope and BBB	IIa	C
• Pacind may be indicated in patients with unexplained syncope and sinus node disease with persistent sinus bradycardia itself asymptomatic	IIb	C
• Pacing is not indicated in patients with unexplained syncope without evidence of any conduction disturbance	III	C
Catheter ablation		
• Catheter ablation is indicated in patients with symptom–arrhythmia ECG correlation in both SVT and VT in the absence of structural heart disease (with the exception of atrial fibrillation	I	C
• Catheter ablation may be indicated in patients with syncope due to the onset of rapid atrial fibrillation	IIb	C
Antiarrhythmic drug therapy		
• Antiarrhythmic drug therapy, including rate control drugs, is indicated in patients with syncope due to onset of rapid atrial fibrillation	I	C
• Drug therapy should be considered in patients with symptom–arrhythmia ECG correlation in both SVT and VT when catheter ablation cannot be undertaken or has failed	IIb	C
Implantable cardioverter defibrillator		
• ICD is indicated in patients with documented VT and structural heart disease	I	B
• ICD is indicated when sustained monomorphic VT is induced at EPS in patients with previous myocardial infarction	I	B
• ICD should be considered in patients with documented VT and inherited cardiomyopathies or channelopathies.	IIa	B

[a]Class of recommendation. [b]Level of evidence. AV=atrioventricular; BBB=bundle branch block; CSNRT=corrected sinus node recovery time; ECG=electrocardiogram; EPS=electrophysiological study; ICD=implantable cardioverter defibrillator; SVT=supraventricular tachycardia; VT=ventricular tachycardia.

Cardiac arrhythmic syncope is treated with antiarrhythmic drugs or pacemaker placement. Consider cardiologist evaluation or inpatient management since this is more commonly associated with poor outcomes. Trials assessing beta-blockade to prevent syncope have conflicting results, but no clear effect has been demonstrated (Table 8.15).

Cardiac mechanical syncope may be treated with beta-blockade to decrease outflow obstruction and myocardial workload. Valvular disease may require surgical correction. This, too, is associated with increased future morbidity and mortality.

KEY POINTS

- The starting point for evaluation of syncope is the 'initial evaluation' that consists of history taking and physical examination, including orthostatic blood pressure measurements and standard electrocardiogram.
- The initial evaluation may lead to certain diagnosis, or suspected diagnosis that needs to be confirmed by appropriate diagnostic tests, or no diagnosis.
- The strategy of evaluation varies according to the severity and frequency of the episodes and the presence or absence of heart disease.

Contd...

Contd...

- In general, the absence of suspected or certain heart disease excludes a cardiac cause of syncope.
- Conversely, the presence of heart disease is a strong predictor of a cardiac cause of syncope and virtually includes all cardiac syncopes, but its specificity is low as about half of patients with heart disease have a noncardiac cause of syncope.
- Determining the mechanism of syncope is a prerequisite for advising patients with regard to prognosis, and to developing an effective mechanism-specific treatment.
- Most patients with syncope require only reassurance and education regarding the nature of the disease and the avoidance of triggering events.

BIBLIOGRAPHY

1. Andrea U, Attilio DR, Franco G, et al. Early and late outcome of treated patients referred for syncope to emergency department: the EGSYS 2 follow-up study. Eur Heart J 18;2010.
2. Birnbaum A, Esses D, Bijur P, Wollowitz A, Gallagher EJ. Failure to validate the San Francisco Syncope Rule in an independent emergency department population. Ann Emerg Med 2008;52(2):151–9.
3. Calkins H, Shyr Y, Frumin H, Schork A, Morady F. The value of the clinical history in the differentiation of syncope due to ventricular tachycardia, atrioventricular block, and neurocardiogenic syncope. Am J Med 1995;98(4):365–73.
4. Chen L, Chen MH, Larson MG, Evans J, Benjamin EJ, Levy D. Risk factors for syncope in a community-based sample (the Framingham Heart Study). Am J Cardiol 2000;85(10): 1189–93.
5. Costantino G, Perego F, Dipaola F, et al. Short- and long-term prognosis of syncope, risk factors, and role of hospital admission: results from the STePS (Short-Term Prognosis of Syncope) study. J Am Coll Cardiol 2008;51(3):276–83.
6. Dipaola F, Costantino G, Perego F, Borella M, Galli A, Cantoni G. San Francisco Syncope Rule, Osservatorio Epidemiologico sulla Sincope nel Lazio risk score, and clinical judgment in the assessment of short-term outcome of syncope. Am J Emerg Med 2010;28(4):432–9.
7. Gibson TC, Heitzman MR. Diagnostic efficacy of 24-hour electrocardiographic monitoring for syncope. Am J Cardiol 1984;53(8):1013–7.
8. Huff JS, Decker WW, Quinn JV, et al. Clinical policy: critical issues in the evaluation and management of adult patients presenting to the emergency department with syncope. [Guideline] Ann Emerg Med 2007;49(4):431–44.
9. Martin GJ, Adams SL, Martin HG, et al. Prospective evaluation of syncope. Ann Emerg Med 1984;13(7):499–504.
10. Martin TP, Hanusa BH, Kapoor WN. Risk stratification of patients with syncope. Ann Emerg Med 1997;29(4):459–66.
11. Middlekauff HR, Stevenson WG, Stevenson LW, Saxon LA. Syncope in advanced heart failure: high risk of sudden death regardless of origin of syncope. J Am Coll Cardiol 1993; 21(1):110–6.
12. Moya A, Sutton R, Ammirati F, et al. Guidelines for the diagnosis and management of syncope (version 2009): the Task Force for the Diagnosis and Management of Syncope of the European Society of Cardiology (ESC). Eur Heart J 2009;30(21):2631–71.
13. Pratt JL, Fleisher GR. Syncope in children and adolescents. Pediatr Emerg Care 1989;5(2):80–2.
14. Quinn J, McDermott D. Electrocardiogram findings in emergency department patients with syncope. Acad Emerg Med 2011;18(7):714–8.
15. Quinn JV, Stiell IG, McDermott DA, et al. Derivation of the San Francisco Syncope Rule to predict patients with short-term serious outcomes. Ann Emerg Med 2004;43(2):224–32.
16. Reed MJ, Newby DE, Coull AJ, Prescott RJ, Jacques KG, Gray AJ. The ROSE (risk stratification of syncope in the emergency department) study. [Best Evidence] J Am Coll Cardiol 2010; 55(8):713–21.
17. Rockx MA, Hoch JS, Klein GJ, et al. Is ambulatory monitoring for "community-acquired" syncope economically attractive? A cost-effectiveness analysis of a randomized trial of external loop recorders versus Holter monitoring. Am Heart J 2005;150(5):1065.
18. Sarasin FP, Hanusa BH, Perneger T, Louis-Simonet M, Rajeswaran A, Kapoor WN. A risk score to predict arrhythmias in patients with unexplained syncope. Acad Emerg Med 2003;10(12):1312–7.
19. Savage DD, Corwin L, McGee DL, Kannel WB, Wolf PA. Epidemiologic features of isolated syncope: the Framingham Study. Stroke 1985;16(4):626–9.
20. Serrano LA, Hess EP, Bellolio MF, et al. Accuracy and quality of clinical decision rules for syncope in the emergency department: a systematic review and meta-analysis. Ann Emerg Med 2010;56(4):362–73.e1.
21. Shen WK, Decker WW, Smars PA, et al. Syncope Evaluation in the Emergency Department Study (SEEDS): a multidisciplinary approach to syncope management. Circulation 2004;110(24):3636–45.
22. Soteriades ES, Evans JC, Larson MG, et al. Incidence and prognosis of syncope. N Engl J Med 2002;347(12):878–85.
23. Suzuki M, Hori S, Nakamura I, Soejima K, Aikawa N. Long-term survival of Japanese patients transported to an emergency department because of syncope. Ann Emerg Med 2004;44(3):215–21.
24. Thiruganasambandamoorthy V, Hess EP, Alreesi A, et al. External validation of the San Francisco Syncope Rule in the Canadian setting. Ann Emerg Med 2010; 55(5):464–72.

11 Electrophysiological Study and Catheter Management of Cardiac Arrhythmia

Historical aspects of electrophysiology (EP) study: Clinical cardiac electrophysiologic testing has evolved rapidly since 1968, when the technique was first described. In an electrophysiologic study, electrode catheters are positioned within the heart to record electrical activity from the atrium, atrioventricular conduction tissue, and ventricle. Programmed stimulation is then performed, which involves pacing of the atrium or ventricle and introducing critically timed premature stimuli during sinus rhythm or paced rhythm. The use of programmed stimulation in conjunction with intracardiac recordings in electrophysiologic studies has facilitated the diagnosis of mechanisms of arrhythmias and the assessment of therapy.

Electrophysiologic testing (Fig. 11.1) is useful in selected patients with sinus node dysfunction, conduction system disorders, supraventricular tachycardia, ventricular tachycardia, or ventricular fibrillation and in survivors of out-of-hospital cardiac arrest and patients with symptomatic but unsubstantiated rhythm disturbances. Therapeutic approaches that can be assessed by electrophysiologic testing include serial drug testing to determine the effectiveness of antiarrhythmic agents, antitachycardia pacing, the implantable defibrillator, transcatheter ablation, and electrophysiologically guided surgical procedures. In this review, we discuss the methods of electrophysiologic testing, its clinical applications in diagnosing the various cardiac rhythm disturbances, and its use in assessing various therapeutic modalities.



Fig. 11.1: The electrophysiology lab for carrying out EP studies and catheter ablation of various types in drug-resistant cardiac arrhythmias

An Overview of the Procedure

While ECGs are noninvasive, an EP study is somewhat invasive. The study is performed after giving local anesthesia and conscious sedation (twilight sleep) to keep the patient as comfortable as possible. The procedure involves inserting a catheter—a narrow, flexible tube-attached to electricity monitoring electrodes, into a blood vessel, often through a site in the groin or neck, and winding the catheter wire up into the heart. The journey from entry point to heart muscle is navigated by images created by a fluoroscope, an X-ray-like machine that provides continuous, 'live' images of the catheter and heart muscle. Once the catheter reaches the heart, electrodes at its tip gather data and a variety of electrical measurements are made. These data pinpoint the location of the faulty electrical site. During this "electrical mapping," the cardiac arrhythmia specialist, an electrophysiologist, may instigate, through pacing (the use of tiny electrical impulses), some of the very arrhythmias that are the crux of the problem. The events are safe, given the range of experts and resources close at hand and are necessary to ensure the precise location of the problematic tissue.

Once the damaged site or sites are confirmed, the specialist may administer different medications or electrical impulses to determine their ability to halt the arrhythmia and restore normal heart rhythm. Based on this data, as well as information garnered before the study, sometimes the specialist will proceed to place an implantable cardioverter device (ICD) or a pacemaker or will perform radiofrequency ablation. In any case, the information proves useful for diagnosis and treatment.

Throughout the procedure, the patient is sedated but awake and remains still. Patients rarely report pain, more often describing what they feel as discomfort. Some watch the procedure on monitors and occasionally ask questions. The procedure usually takes about 2 hours. The patient remains still for 4–6 hours afterward to ensure the entry point incision begins to heal properly. Once mobile again, patients may feel stiff and achy from lying still for hours.

The Importance of the Flow of Electricity

Each heart has it own normal rhythm brought about by the seamless flow of electrical impulses throughout the organ. This electrical flow begins in the heart's natural 'pacemaker' (also know as the sinoatrial node or sinus node) in the upper right heart chamber, the right atrium. The electricity flows through the upper chambers (atria), crosses the bridge between upper and lower chambers (atrioventricular node) and travels to the lower chambers (ventricles). The passage of electricity culminates in a carefully coordinated contraction of heart muscle that pushes blood through the human body. Problems in the precise flow of electricity are the cause of arrhythmias (Fig. 11.2).

Clinical Application of EP Study

An electrophysiologic, or EP, study provides information that is key to diagnosing and treating arrhythmias. Although it is more invasive than an electrocardiogram (ECG) or echocardiogram, and involves provoking arrhythmias, the test produces data that makes it possible to:

1. Diagnose the source of arrhythmia symptoms
2. Evaluate the effectiveness of certain medications or procedures in controlling the heart rhythm disorder
3. Predict the risk of a future cardiac event, such as sudden cardiac death
4. Assess the need for an implantable device (a pacemaker or ICD) or treatment procedure (radiofrequency catheter ablation)

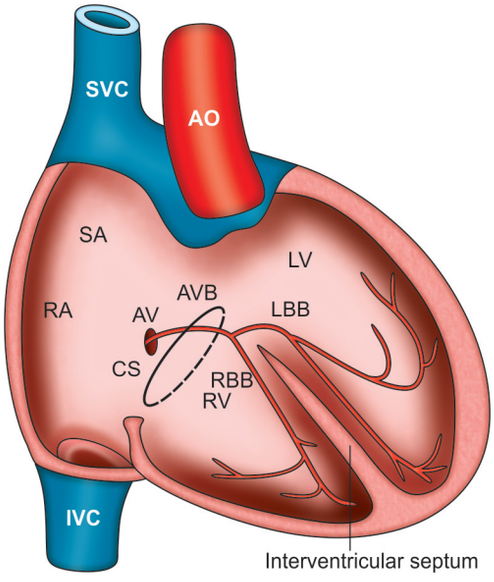

Fig. 11.2: Anatomical features of bundle of His as a conduction system of the heart close to tricuspid valve

Who performs the test and where?

Since potentially dangerous arrhythmias are provoked during an EP study, it is crucial that specialized staff are present to handle all situations. A physician electrophysiologist, with advanced training in the diagnosis and treatment of heart rhythm problems, performs the EP study. The electrophysiologist leads a team of specially trained health care professionals, technicians and nurses, who assist during the procedure. The team performs the EP study in an electrophysiology laboratory, or EP lab, a well-equipped, controlled clinical environment usually located within a hospital or clinic. As a result, the test is quite safe and complications are rare.

Complications in EP study

The procedure is generally very safe. Possible risks include:

- Arrhythmias
- Bleeding
- Blood clots that lead to embolism
- Cardiac tamponade
- Heart attack
- Infection
- Injury to the vein
- Low blood pressure

TECHNICAL CONSIDERATIONS IN PERFORMANCE OF ELECTROPHYSIOLOGICAL STUDY

I. Before the Procedure

- Your physician will explain the procedure to you and offer you the opportunity to ask any questions that you might have about the procedure.
- You will be asked to sign a consent form that gives your permission to do the test. Read the form carefully and ask questions if something is not clear.
- Notify your physician if you are sensitive to or are allergic to any medications, iodine, latex, tape, or anesthetic agents (local and general).
- You will need to fast for a certain period of time prior to the procedure. Your physician will notify you how long to fast, usually overnight.
- If you are pregnant or suspect that you may be pregnant, you should notify your physician.
- Notify your physician if you have any body piercing on your chest and/or abdomen.
- Notify your physician of all medications (prescription and over-the-counter) and herbal supplements that you are taking.
- Notify your physician if you have heart valve disease, as you may need to receive and antibiotic prior to the procedure.

- Notify your physician if you have a history of bleeding disorders or if you are taking any anticoagulant (blood-thinning) medications, aspirin, or other medications that affect blood clotting. It may be necessary for you to stop some of these medications prior to the procedure.
- Your physician may request a blood test prior to the procedure to determine how long it takes your blood to clot. Other blood tests may be done as well.
- Notify your physician if you have a pacemaker.
- If a sedative is given before the procedure, you may need someone to drive your home afterwards.
- The area around the catheter insertion (groin area) may be shaved.
- Based upon your medical condition, your physician may request other specific preparation.

II. During the Procedure (Figs 11.3–11.6)

An EP study may be performed on an outpatient basis or as part of your stay in a hospital. Procedures may vary depending on your condition and your physician's practices.

Generally, an EP study follows this process:

- You will be asked to remove any jewelry or other objects that may interfere with the procedure.
- You will be asked to remove clothing and will be given a gown to wear.
- You will be asked to empty your bladder prior to the procedure.
- An intravenous (IV) line will be started in your hand or arm prior to the procedure for injection of medication and to administer IV fluids, if needed.
- You will be placed in a supine (on your back) position on the procedure table.
- You will be connected to an ECG monitor that records the electrical activity of the heart and monitors the heart during the procedure using small, adhesive electrodes. Your vital signs (heart rate, blood pressure, breathing rate, and oxygenation level) will be monitored during the procedure.
- There may be several monitor screens, showing your vital signs and the images of the catheter being moved through the body into the heart.
- You will receive a sedative medication in your IV before the procedure to help you relax. However, you will likely remain awake during the procedure.
- Your pulses below the IV site may be checked and marked with a marker so that the circulation to the limb below the site can be checked after the procedure.
- A local anesthetic will be injected into the skin at the insertion site. You may feel some stinging at the site for a few seconds after the local anesthetic is injected.



Fig. 11.3: Cardiac catheterization laboratory. Electrophysiologist is busy in performing electrophysiological study for diagnosis of cardiac arrhythmia

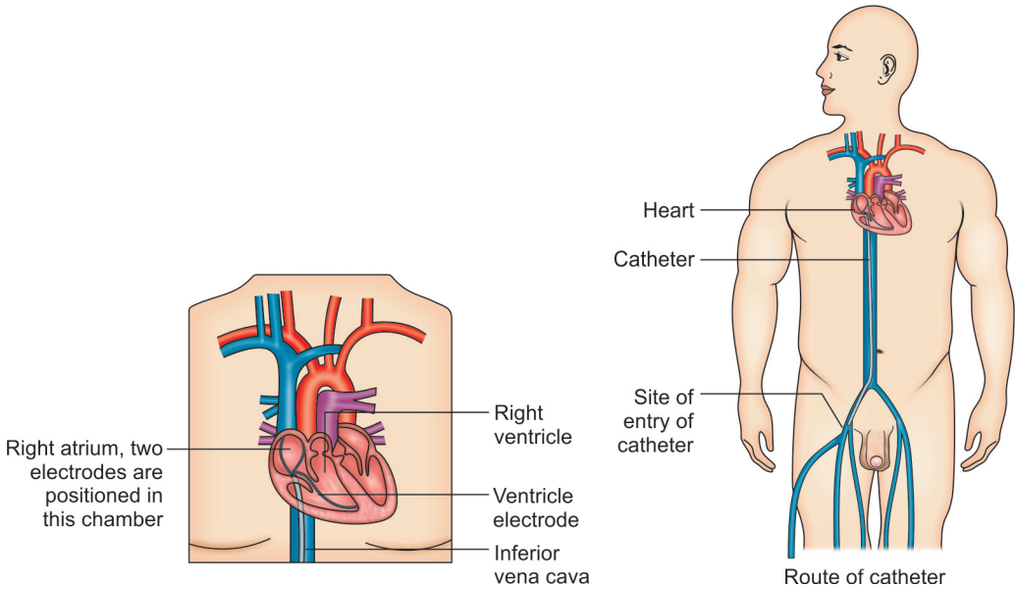

Fig. 11.4: Routes inserting catheter in intracardiac electrocardiographic study

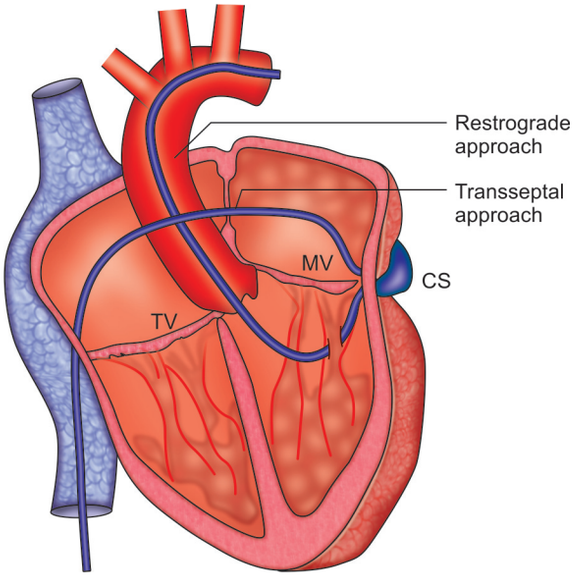

Fig. 11.5: Illustration showing transseptal and retrograde approaches in EP study

- Once the local anesthetic has taken effect, a sheath, or introducer, will be inserted into the blood vessel. This is a plastic tube through which the catheter will be inserted into the blood vessel and advanced into the heart.
- One or more catheters will be inserted through the sheath into the blood vessel. The physician will advance the catheter through the blood vessel into the right side of the heart. Fluoroscopy (a special type of X-ray that is displayed on a TV monitor), may be used to assist in advancing the catheter to the heart.
- Once the physician has the catheter(s) placed properly, the electrical testing will begin by sending very small electrical impulses to certain areas within the heart. If a dysrhythmia occurs, you may begin to feel lightheaded or dizzy.

Medication will be given to you IV to treat the dysrhythmia. Alternatively, a shock will be delivered to stop the dysrhythmia. You will be sedated before this type of shock is given.

- If a certain area of tissue is found to be causing a dysrhythmia, the physician may perform an ablation to eliminate the tissue. This is done with radio waves (radiofrequency ablation). The radio waves are delivered through the catheter to the tissue.
- If you notice any discomfort or pain, such as chest pain, neck or jaw pain, back pain, arm pain, shortness of breath, or breathing difficulty, let the physician know.
- Once the procedure has been completed, the catheter(s) will be removed from the insertion site. The physician or an assistant will hold pressure on the insertion site so that the blood can begin to form a clot at the site and stop the bleeding.
- Once the bleeding has stopped, a bandage will be placed on the site.
- You will be assisted to slide from the table onto a stretcher so that you can be taken to the recovery area.

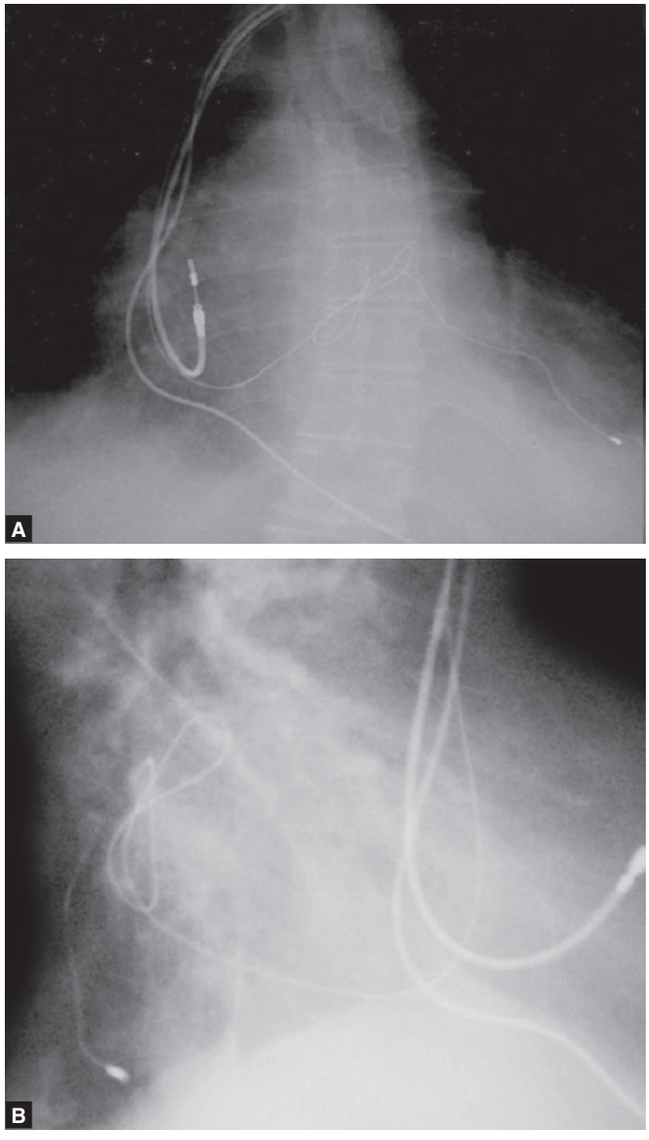

Fig. 11.6: (A) X-ray chest AP view showing 'granny knot' of left ventricular lead in coronary sinus (B) X-ray chest lateral view showing 'granny knot' of left ventricular lead in coronary sinus

Note: If the insertion was in the groin, you will not be allowed to bend your leg for a few hours.

- To help you remember to keep your leg straight, the knee of the affected leg may be covered with a sheet and the ends will be tucked under the mattress on both sides of the bed to form a type of loose restraint.

Transseptal Approach Technique in EP Study

Throughout the diagnostic electrophysiological study and transseptal procedure the patients were kept well hydrated with a continuous infusion of normal saline, receiving at least 500 ml before the transseptal procedure. The transseptal procedures were performed using a standard Brockenborough needle and either a Mullins sheath (Bard Inc, Billerica, Massachusetts, USA) or a Swartz sheath and dilator (Daig Corporation, Minnetonka, Minnesota, USA). The needle was connected to a standard catheterisation

manifold by a short length of flexible tubing, so that contrast could be injected and pressure could be displayed and recorded. Biplane fluoroscopic projections used were (right anterior oblique 45° and left anterior oblique 40°) in all cases, providing en face and longitudinal views of the interatrial septum respectively. The transseptal sheath/dilator was placed in the superior vena cava and then the dilator/sheath/needle combination was withdrawn inferiorly in the left anterior oblique projection until the tip of the dilator 'popped' into the fossa ovalis. Positioning was always checked in the right anterior oblique projection to ensure that the tip of the needle/sheath assembly was pointing directly away from the plane of vision and slightly anterior. A test injection of contrast was delivered through the dilator in the left anterior oblique projection to check for 'tenting' of the fossa at the intended puncture site. This was typically just below the level of the His recording catheter in the left anterior oblique 40° projection, and well behind the His catheter electrodes in the right anterior oblique 45°. The needle was then advanced and a second test injection was made following needle advancement to check that the needle had entered the left atrium; left atrial pressure was then recorded. The sheath/dilator were advanced over the needle into the left atrium. Once the dilator was well into the left atrium, the sheath was advanced over the dilator, but the needle remained just inside the dilator to give support for advancement of the long sheath. Once the needle is withdrawn, the tip of the dilator tends to flex. This makes it hazardous to redeploy the needle, since this may result in penetration of the wall of the dilator.

Patients then received 5000 units of heparin, with a further 2500 units being given if left sided deployment lasted more than one hour. If deployment exceeded 90 minutes, activated partial thromboplastin time was estimated. Ablations were performed using 4 mm tipped 'Steerocath' or 'Blazer-T' thermistor tipped electrodes (EP Technologies, Sunnyvale, California, USA). The ablation catheter was passed through the sheath into the left atrium and positioned on the mitral annulus. Care was always taken to flush the sheath during catheter advancement to avoid entrainment of air. Suitable ablation sites were obtained using conventional criteria. Patients remained in the laboratory with transseptal sheath in place for 30 minutes after the procedure (particularly after accessory pathway ablation) for confirmation of success. After successful ablation, transseptal sheaths were withdrawn across the interatrial septum with the ablation catheter tip protruding slightly. This technique was employed to avoid inadvertent displacement of adherent coagulum from the catheter at the sheath tip.

III. After the Procedure

In the Hospital

- After the procedure, you may be taken to the recovery room for observation or returned to your hospital room. You will remain flat in bed for a few hours after the procedure. The circulation and sensation of the limb where the catheter was inserted will be monitored. A nurse will monitor your vital signs, the insertion site, and circulation/sensation in the affected leg or arm.
- You should immediately inform your nurse if you feel any chest pain or tightness, or any other pain, as well as any feelings of warmth, bleeding, or pain at the insertion site in your leg or arm.
- Bed-rest may vary from 2–6 hours depending on your specific condition.
- In some cases, the sheath or introducer may be left in the insertion site. If so, the period of bed-rest will be prolonged until the sheath is removed. After the sheath is removed, you may be given a light meal.
- You may be given pain medication for pain or discomfort related to the insertion site or having to lie flat and still for a prolonged period.
- You may resume your usual diet after the procedure, unless your physician decides otherwise.
- After the specified period of bed-rest has been completed, you may get out of bed. The nurse will assist you the first time you get up, and will check your blood pressure while you are lying in bed, sitting, and standing. You should move slowly when getting up from the bed to avoid any dizziness from the long period of bed-rest.
- When you have completed the recovery period, you may be discharged to your home unless your physician decides otherwise. If this procedure was performed on an outpatient basis, you must have another person drive you home.

IV. Discharge Instructions and Care

- Your heart rhythm specialist will discuss specific individualized recommendations in regard to your discharge care. The following are general recommendations:
- Limit heavy lifting or strenuous exertion for 4–5 days after your study
- You may shower after your return home the day of the procedure
- You may remove any dressing or bandages placed at the catheter site after you return home
- You may typically return to work in 1–2 day, as long as it does not involve heavy lifting or strenuous exertion
- Call your physician if your incision site (typically in the groin) appears to swell or become more painful
- It is normal to develop some bruising at the catheter site with a transition to a 'black-and-blue appearance' however, this should not become more painful or lead to increased swelling
- Follow-up with your physician in approximately 1 month for a clinic visit.

At Home

Once at home, you should monitor the insertion site for bleeding, unusual pain, swelling, and abnormal discoloration or temperature change at or near the injection site.

A small bruise is normal. If you notice a constant or large amount of blood at the site that cannot be contained with a small dressing, notify your physician. It will be important to keep the insertion site clean and dry. Your physician will give you specific bathing instructions. You may be advised not to participate in any strenuous activities. Your physician will instruct you about when you can return to work and resume normal activities.

Postprocedural Information to your physician about your physical problems such as:

- Fever and/or chills
- Increased pain, redness, swelling, or bleeding or other drainage from the insertion site
- Coolness, numbness and/or tingling, or other changes in the affected extremity
- Chest pain/pressure, nausea and/or vomiting, profuse sweating, dizziness, and/or fainting

Your physician may give you additional or alternate instructions after the procedure, depending on your particular situation.

Management of Cardiac Arrhythmias with Catheter Ablation

Radiofrequency catheter ablation (RFCA) has revolutionized treatment for tachyarrhythmias and has become first-line therapy for some tachycardias. Although developed in the 1980s and widely applied in the 1990s, formalized guidelines for its use in clinical practice were not developed until recently.

Different Types of Catheters Employed in Ablation

The design and functionality of catheters is constantly evolving. Most atrial fibrillation ablations today use single point radiofrequency energy catheters, which have a success rate-freedom from atrial fibrillation-of about 70%. It's believed that different types of catheters could have higher success rates or fewer complications. Here are the different types of catheters available today for atrial fibrillation catheter ablations (Figs 11.7–11.10).



Fig. 11.7: A typical ablation catheter with a distal tip consisting of electrodes that can measure the electrical activity in the heart as well as deliver radiofrequency, or heat, energy to ablate cardiac arrhythmias

Single point radiofrequency catheters emit radiofrequency energy from a single point at the catheter tip. To make lesions, electrophysiologists ablate one spot after another,



Fig. 11.8: Flexible electronics with multisensing cardiac ablation catheter. As an early example that was just announced, an international team of researchers built and tested a balloon ablation catheter capable of measuring intracardiac pressure, EKG, and local temperature around the device tip. All this data can be monitored in real time by the physician during ablation without having to switch devices catheters. Finally, these catheters enable the use of bipolar radiofrequency energy, which may reduce certain complications that are seen with unipolar radiofrequency energy. However, there is limited clinical data on multielectrode catheters, which means that complications arising from these procedures may not be fully known or understood



Fig. 11.9: An Estech Cobra ablation system



Fig. 11.10: Hansen Medical's robotic catheter control system for EP study

similar to drawing a line by making dots one after the other. If all the dots are not connected, afib could re-enter the heart in the unablated space (gap).

Multielectrode radiofrequency catheters have several electrodes, each of which can transmit radiofrequency energy. These catheters can ablate a larger area of tissue than single point radiofrequency energy catheters, which could decrease procedure times. In addition, multielectrode catheters may be better at making contiguous lesions (lesion lines without any gaps) than single point.

Contact force sensing radiofrequency catheters: Contact force is one of the variables that affects transmurality. If there is not enough pressure, the lesion may not fully penetrate the tissue, which would allow afib to re-enter the heart. If there is too much pressure, complications, such as steam pops, can occur. These catheters tell the electrophysiologist how much pressure is being applied to the catheter and tissue.

Balloon catheters: After the balloon catheter is inserted into the left atrium, the electrophysiologist inflates the balloon at the tip of the catheter. Balloon catheters can ablate a larger area of tissue than single point radiofrequency catheters, which enhances the prospects that lesions will be contiguous (without gaps) and could shorten procedure times. There are balloon catheters using cryothermy, laser energy, and even radiofrequency energy. In general, balloon catheters have difficulty reaching the right pulmonary veins.

Robotic Catheter Navigation for Ablation

Robotic catheter ablation is performed at some centers. Robotic systems could improve navigation of the catheter, keep the catheter in a stable position, and shorten procedure times. In general, robotic catheter ablations have had similar outcomes as traditional (manual) catheter ablation, meaning that the success and complications rates aren't significantly better or worse. Robotic systems are expensive, so not all centers have them. Performing catheter ablation with a single point radiofrequency catheter can be technically challenging, particularly for doctors who have not performed many ablations. In theory, using a robot will simplify the procedure and decrease the expertise needed. However, studies that test this theory have not been performed. A robotic ablation starts the same way as a traditional catheter ablation. The doctor inserts a catheter into the groin and guides the catheter to the right side of the heart. After making a puncture in the septum, the wall that separates the right and left sides of the heart, the doctor leaves the patient's side and goes to the control system for the robotic system, which is usually located in an adjacent room.

Leading Robotic Systems Used in Catheter Ablations

Niobe (Stereotaxis): Niobe is a magnetic system that only works with the CARTO electroanatomic mapping system and Biosense Webster mapping and ablation catheters. It does not look like a robot, but is considered a robotic system. The patient's bed lies between two large magnets, which track the movement in the catheter and send the information to the system. The doctor uses a joystick like those used in video games to change the position of the magnets, which then makes the catheters move. People who have a pacemaker or ICD cannot have a Niobe procedure because these devices would be affected by the magnets.

Sensei (Hansen Medical): Sensei has a robotic arm that is attached to the patient's bed. It works with both Ensite NaVx and CARTO as well as standard mapping and ablation catheters. Similar to the Niobe system, the doctor uses a joystick to change the catheter's location. When the doctor moves the joystick in the Sensei system, the robotic arm moves the catheter. Robotic technology is changing the paradigm for catheter ablation treatment of atrial fibrillation to read about the largest study to date comparing Sensei to traditional catheter ablations, which was presented at Boston Atrial Fibrillation Symposium 2010.

Amigo (Catheter Robotics): Amigo is a less expensive system than Niobe and Sensei and works with a variety of mapping and ablation catheters. It is in a clinical trial in the United States.

Artis zeego (Siemens): Artis zeego uses computed tomography (CT) imaging technology to guide navigation, and is also in clinical studies.

Catheter Ablation Technology

The goal of any catheter or energy source is to create a transmural lesion while minimizing complications (Figs 11.11–11.17). A transmural lesion-scar tissue that completely

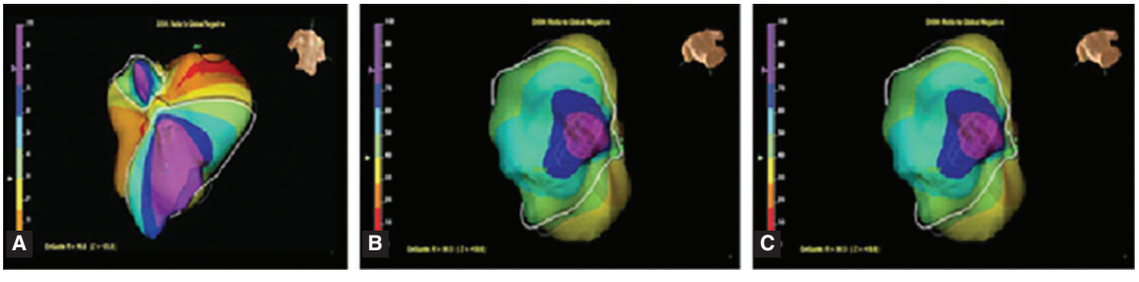

Fig. 11.11A to C: Three-dimensional views showing large anteroapical scars

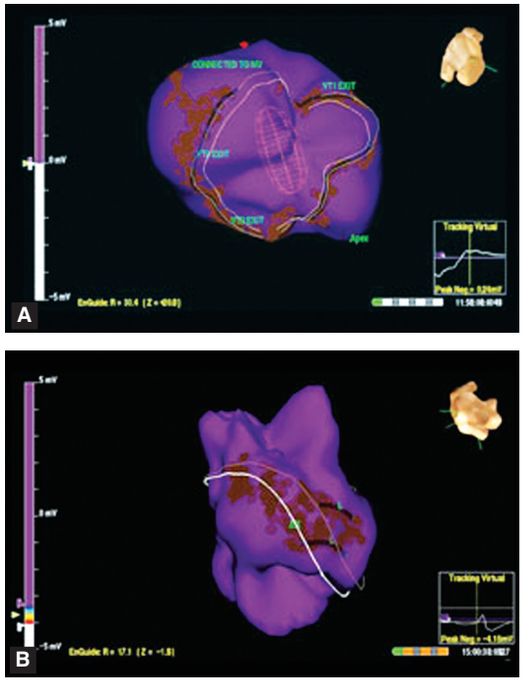

Fig. 11.12: (A) Three-dimensional view of multiple radiofrequency ablations in a line along the border of large anterior scar connecting it to mitral annulus, (B) three-dimensional view of multiple radiofrequency ablations in a line along the border of large posterior scar at the site of VT exit

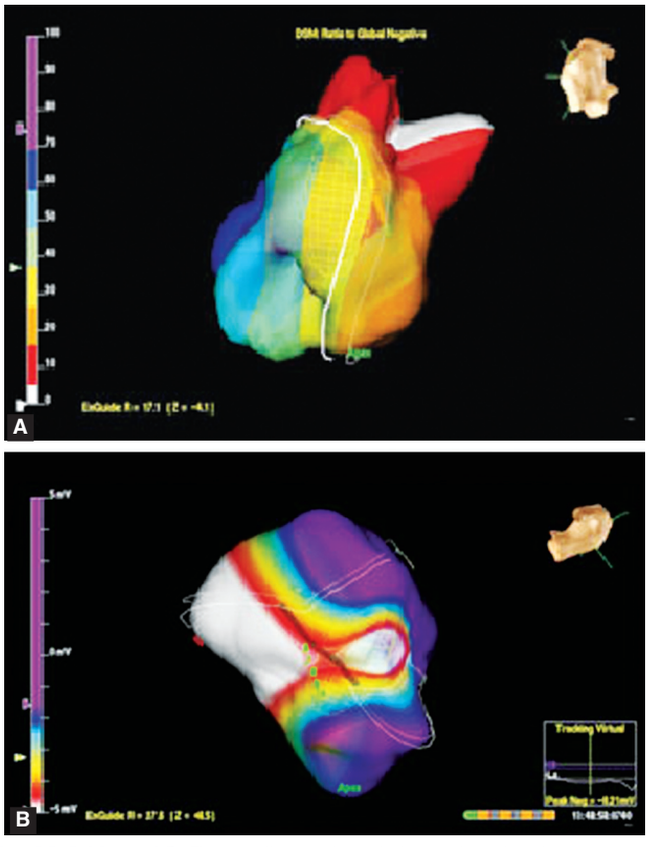

Fig. 11.14A and B: Three-dimensional views showing large areas of posterior scar

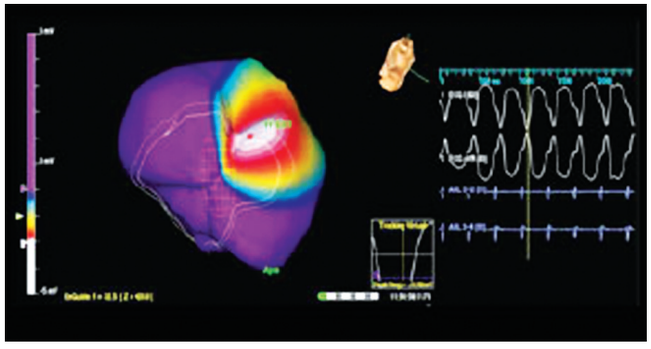

Fig. 11.13: Three-dimensional view showing the exit of ventricular tachycardia from the scar area

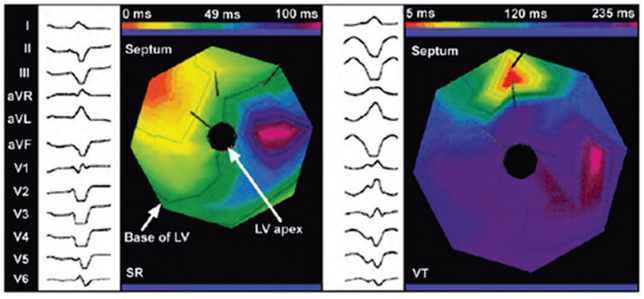

Fig. 11.15: 32-site bipolar mapping of ventricular tachycardia. The outer circle is located near the base of the left ventricle (LV) while the inner circle is positioned within the LV apex. Left panel—mapping during sinus rhythm (SR) shows that the earliest endocardial activation (red) is in the region near the basal septum; activation then spreads rapidly in a radial pattern over the endocarium. The area in purple/pink is activated last. Right panel—during ventricular tachycardia (VT), there is a change in the activation sequence and an increase in the activation time, indicated by the blue/purple color over the majority of the LV endocardium (reprinted by permission from Schalij MJ, van Rugge P, Siezenga M, et al. Circulation. 1998;98:2168)

penetrates the heart tissue is key to a successful ablation because it keeps errant electrical signals from being transmitted. Making a transmural lesion is as much of an art as it is a science. It depends on the temperature generated by the energy source, how much pressure is applied to the catheter (contact force), and how long the catheter remains in contact with tissue. There are different energy sources that can be used in various types of catheters, and each has advantages and disadvantages, so it's important for patients to understand the different options.

Energy Sources

Here are the energy sources being used today in atrial fibrillation catheter ablations.

Radiofrequency (RF) energy is radio waves that are converted to heat to ablate and create scar tissue. It reliably achieves transmurality and is the most widely used energy source in catheter ablations. In general, high temperatures are needed to make sure that all layers of tissue are ablated. Traditional catheters use unipolar radiofrequency energy,

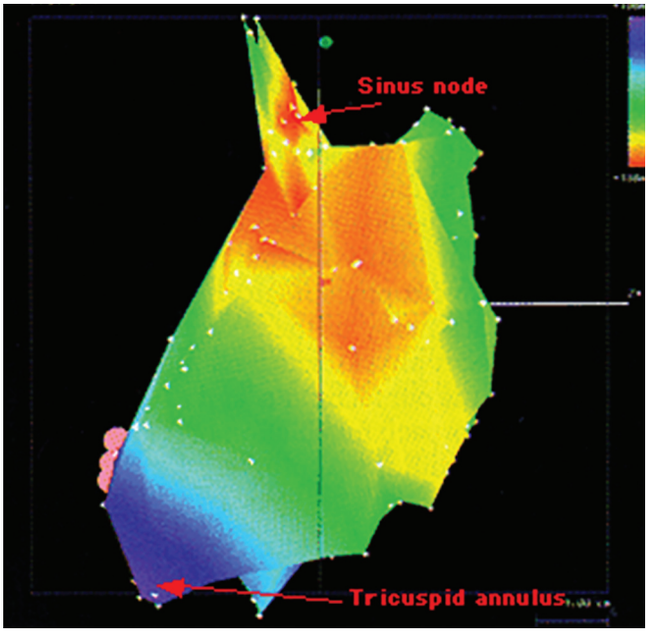

Fig. 11.16: Activation sequence during sinus rhythm. Electroanatomic mapping of the right atrium with the CARTO system during sinus rhythm shows the earliest activation in the region of the sinus node (red), spreading throughout the atrium. The last part to be activated is the region of the tricuspid annulus and coronary sinus as (dark blue/purple). (Reprinted with permission from Cooke PA, Wilber DJ. Pacing Clin electrophysiol. 1998; 21:1802)

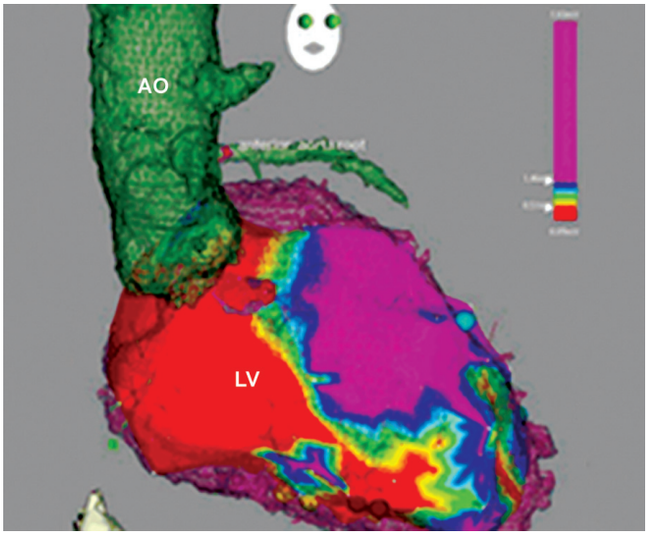

Fig. 11.17: The 3-D composed tomographic reconstruction of the left ventricle (LV) displayed as purple wireframe aligned with the 3-D LV endocardial voltage map (solid color map). Red areas represent dense scar and purple areas represent normal myocardium; dark brown points indicate ablation sites. AO=aorta.

which simply means that the radiofrequency energy is transmitted from a single point at the catheter's tip.

Cryothermy, or cryo energy, is intense cold that is used to form ice crystals within the tissue, causing the cells to die and creating scar tissue. It may be easier to make lesions using cryothermy since the cold temperatures cause tissue to stick to the catheter. In addition, cryo energy may have fewer major complications. Animal studies have shown cryo energy to have a much lower incidence of thrombus (clot) formation than radiofrequency energy, which suggests that cryothermy could lower the risk of a stroke. Cryo energy can be used in single point catheters or balloon catheters. Laser energy is light waves that are converted to heat to ablate and create scar tissue. It may be a safer heat-based energy than unipolar radiofrequency energy. With laser energy, the catheter doesn't need to be in direct contact with tissue, which could mean it will have fewer complications than radiofrequency energy. Unlike other energy sources, contact force is not a factor in whether a laser lesion is transmural. In addition, laser energy can be adjusted when ablating tissues of varying thickness, with higher energy applied to thicker tissue and lower energy applied to thinner structures in the heart.

Other energy sources, such as microwave and high intensity focused ultrasound (HIFU), have been studied but these energy sources aren't widely used in catheter ablation. The tools used to assist with catheter ablation are constantly evolving. Here are some of the tools that are commonly used for atrial fibrillation catheter ablations.

Mapping and Navigation Tools for Ablation

The tools used to assist with catheter ablation are constantly evolving. Here are some of the tools that are commonly used for atrial fibrillation catheter ablations

1. ***CT and MR imaging of the atrium and pulmonary veins*** provides pre-ablation imaging to help doctors locate anatomic features and identify variations in anatomy of the individual heart
2. ***Fluoroscopy X-ray*** helps doctors guide mapping and ablation catheters in the body by generating 2D (flat) black and white images, but can't show contours in anatomy, such as the 'curve' of a pulmonary vein, and also exposes the patient and doctor to radiation
3. ***Pulmonary vein venography*** helps determine the location of the pulmonary vein ostia, the base of the pulmonary veins, and guide the manipulation of the catheter
4. ***Intracardiac echocardiography (ICE)*** provides real time information about anatomy to facilitate the transseptal puncture (from the right atrium to the left atrium) and to guide catheter ablation
5. ***Electroanatomic mapping system*** reduces fluoroscopy exposure to doctors and patients and allows doctors to visualize structures in 3D and create appropriate lesions, particularly with the incorporation of previously-acquired MR or CT images
6. ***Robotic catheter navigation*** improves navigation precision and may shorten procedures, and includes the Stereotaxis' Niobe magnetic navigation system, Hansen Medical's Sensei robot, and Catheter Robotics' Amigo robot
7. ***Multielectrode circumferential mapping catheter*** verifies that the pulmonary veins are electrically isolated

Electroanatomic Mapping Systems for Ablation

Because of the shortcomings of fluoroscopy, some electrophysiologists use electroanatomic mapping systems like Ensite NaVx (St. Jude Medical) and CARTO (Biosense Webster), which provide colorful 3D images that show variations in a patient's anatomy. These systems may assist doctors in assuring that lesions are contiguous (no gaps) and in reducing complications, such as perforation of the heart or esophagus. In addition, the use of an electroanatomic mapping system may lessen the time that doctors and patients are exposed to radiation. However, the systems are expensive, so they are not available at all facilities.

Using these systems, electrophysiologists create a real time 3D view of the heart by positioning a mapping catheter in the heart. When the doctor moves the catheter in a sweeping motion, the systems track the catheter's location. CARTO and Ensite NaVx use different methods to do this. In a CARTO procedure, the table where the patient lies has an electromagnetic pad that tracks movement of the catheter, whereas in an EnSite NaVx procedure, patches on the patient's skin track the catheter. Both systems use algorithms to translate data on the catheter's location into a 3D image. It usually takes about 20 minutes to complete this process.

Electroanatomic mapping systems are sometimes called multimodality mapping or image integration systems because they can show pictures or data from other sources. For instance, patient CT or MRI scans taken a few days or weeks before the procedure may be loaded onto Ensite NaVx or CARTO and matched with the real time 3D image of the heart. The doctor does this by moving the catheter slightly, verifying its location in the heart, and taking note of large structures like the pulmonary veins. After several common areas on the two images are identified, the system merges the real time view and pre-procedure scan into one 3D picture. It usually takes about 15 minutes to complete this process, which is called registration. However, the positioning of anatomy can even change within just a week, so if the pre-procedure scan doesn't easily correspond with the real time view of the heart, it can take much longer. Electroanatomic mapping systems also provide real time data on electrical activity within the heart, which means that electrophysiologists can see whether conduction block has been achieved. The systems also provide other real time information, such as atrial pressure and volume, so doctors can easily monitor the patient during the procedure.

Catheter Ablation Techniques

Catheter ablation techniques are constantly evolving. Initial catheter ablations attempted to recreate the lesion set used in the open-chest Cox maze procedure by creating linear ablation lines that interrupted the atrial fibrillation wavelets (Figs 11.18–11.21). However, doctors had difficulty

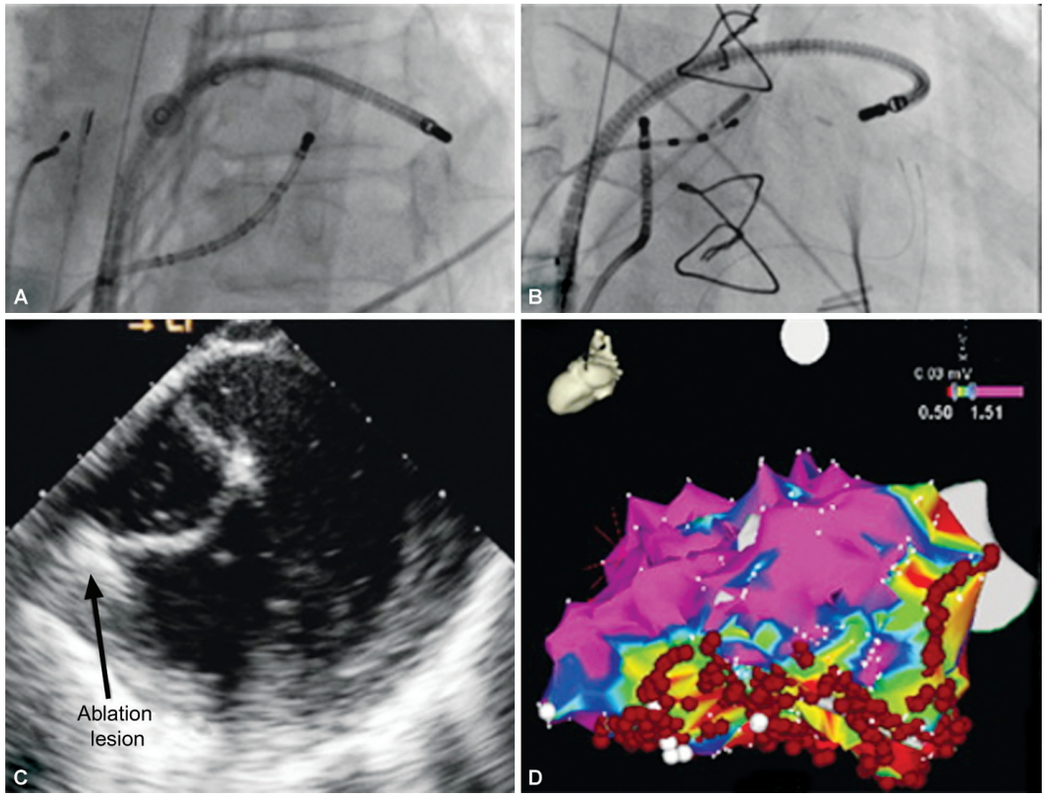

Fig. 11.18: Mapping and ablation of a basal lateral scar. (A, B) Robotic catheter position in left and right anterior oblique fluoroscopic views, respectively. The mid-lateral wall is being mapped, (C) intracardiac echocardiographic image showing catheter contact and lesion formation in the left ventricular lateral wall, (D) three-dimensional map of the lateral scar and the ablation lesions created

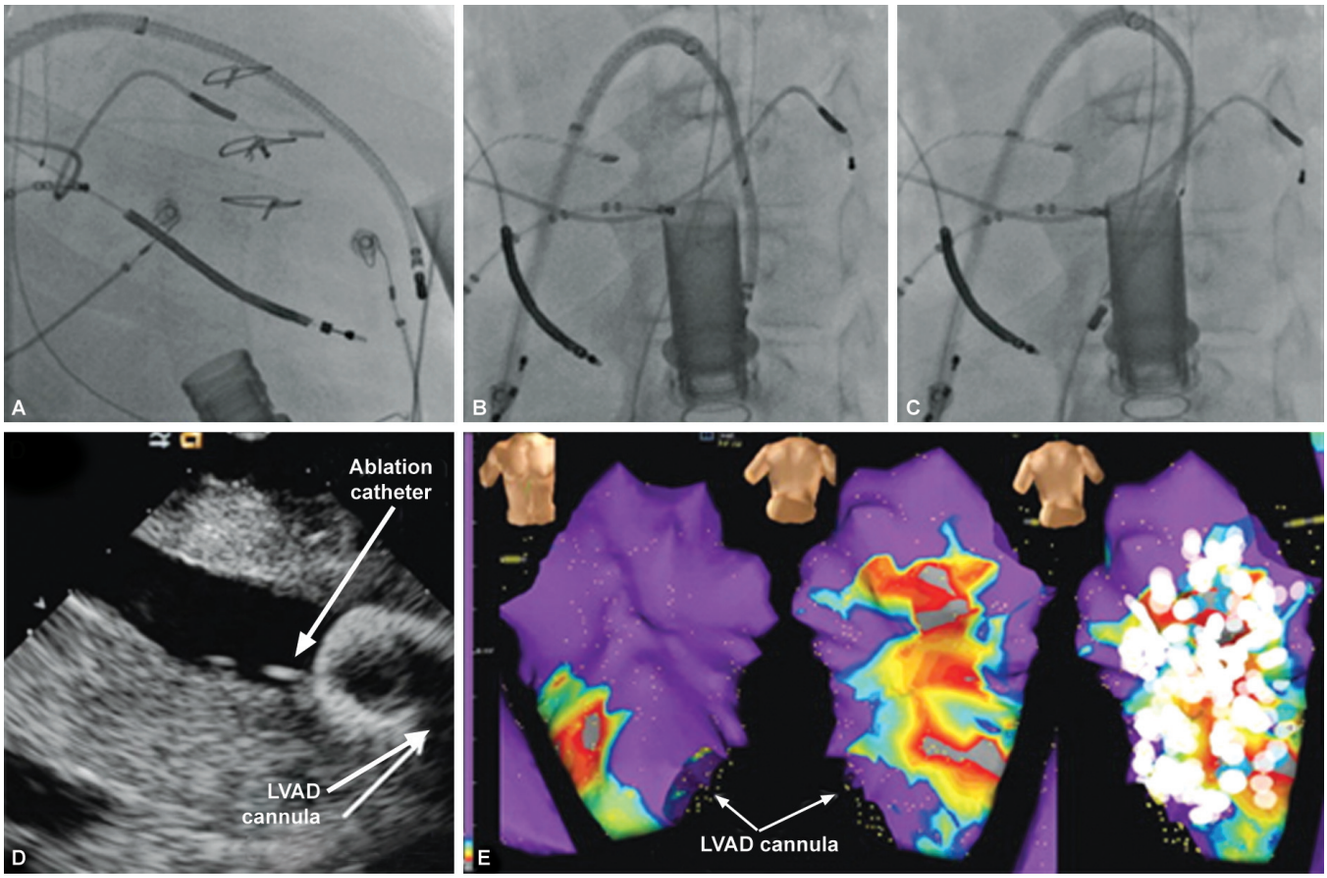

Fig. 11.19: Mapping and ablation of an inferior wall scar in the presence of a left ventricular assist device (LVAD). (A to C) Robotic catheter position in the right (A) and left (B, C) anterior oblique fluoroscopic views, with the catheter tip around the LVAD inflow cannula. (D) Intracardiac echocardiographic image of the LVAD cannula and the ablation catheter. (E) Three-dimensional scar maps and ablation lesions

duplicating the Cox maze lesion set during a closed-chest catheter ablation. The procedure had high complication rates and required long fluoroscopy times. Research in Bordeaux, France, by Michel Haïssaguerre, MD, and colleagues, suggested that electrophysiologists didn't need to duplicate the Cox maze lesion set. Dr. Haïssaguerre's group found that over 90% of atrial fibrillation is triggered (starts) in or near the pulmonary veins. As a result of these findings, a new type of catheter ablation technique, called segmental pulmonary vein isolation or ostial pulmonary vein isolation, was created. Dr. Haïssaguerre and his colleagues used radiofrequency energy to ablate the pulmonary vein ostium, the opening to the pulmonary veins. When 'isolated', pulmonary veins can no longer be a trigger point for atrial fibrillation. Dr. Haïssaguerre and his colleagues were able to terminate atrial fibrillation in, and stop prescribing antiarrhythmic drugs for, 62% of patients in the study.

This pulmonary vein isolation approach continues to be the cornerstone of catheter ablation strategies for the treatment of paroxysmal atrial fibrillation. However, pulmonary vein isolation can mean different things to different doctors. Indeed, it has become a catch-all term to describe any ablation of the pulmonary veins. This can lead to misunderstandings between doctors and patients, and can make a big difference in the rate of freedom from afib after ablation. Perhaps the most important difference among doctors relates to whether the pulmonary veins are isolated, or just ablated. In order for a procedure to be called a pulmonary vein isolation, the doctor must confirm that the pulmonary veins are 'blocked', in other words, that conduction block was achieved. This is done with a mapping catheter that can determine whether there is any electrical activity around the pulmonary veins. If conduction block isn't confirmed, then the procedure is an ablation, not an isolation. Thus, it is important to ask doctors what type of lesion set will be made and whether they will confirm that conduction is blocked.

There have been several updates to the segmental (ostial) pulmonary vein isolation developed by Dr. Haïssaguerre and his colleagues. First, it was found that ablating tissue in the ostia (opening) of the pulmonary veins could lead to pulmonary vein stenosis (narrowing), which is a serious complication that can obstruct oxygenated blood from flowing from the lungs into the heart. Second, it has been found that more extensive lesion sets are better at stopping afib. This is probably because the pulmonary veins aren't the only area in the heart that can trigger atrial fibrillation.

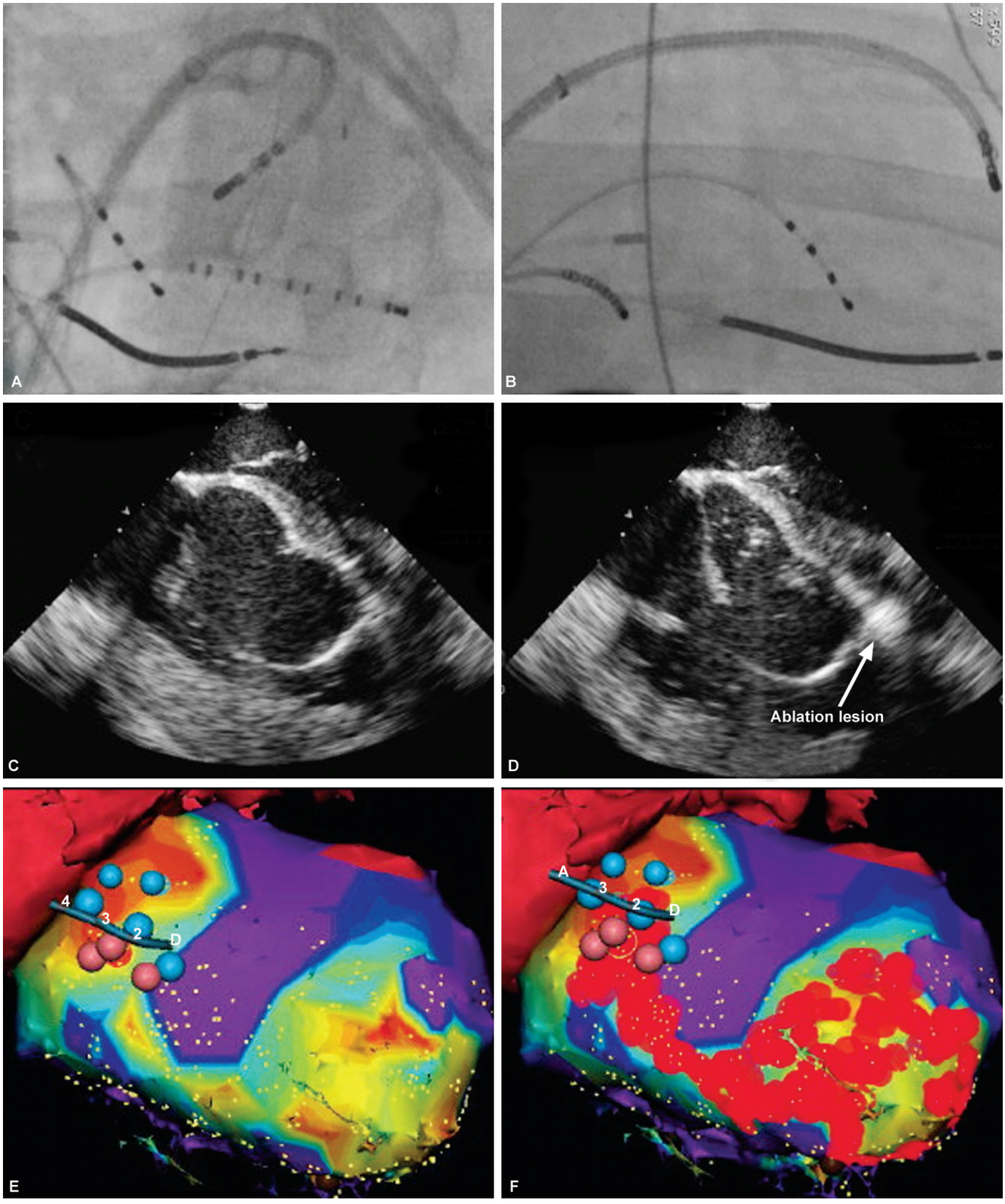

Fig. 11.20: Mapping and ablation of a septal scar. Stable catheter positioning allowed real-time monitoring of lesion creation on intracardiac echocardiography. (A, B) Robotic catheter position in left and right anterior oblique fluoroscopic views, respectively. The septal aspect of the apex was being mapped. (C, D) Intracardiac echocardiographic images before and 15 seconds after application of radiofrequency. The catheter tip is in the distal septum, where increased echogenicity is seen at the ablation site. (E, F) Three-dimensional maps of the large septal and apical scar and the ablation lesions, respectively

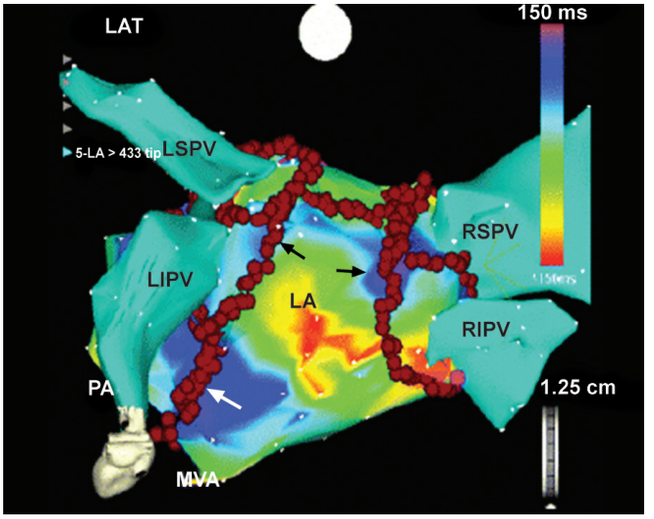

Fig. 11.21: Postablation electroanatomic map showing a wide area circumferential ablation in a patient with persistent atrial fibrillation. Shown are the left superior pulmonary vein (LSPV), left inferior pulmonary vein (LIPV), right superior pulmonary vein (RSPV), and right inferior pulmonary vein (RIPV). Ablative rings circumscribe the left and right pulmonary vein sets. The carinal lines between the veins, a line connecting the right to the left pulmonary vein rings, and an ablative line (white arrow) from the LIPV to the mitral valve annulus (MVA) are also shown. LA=left atrium. (With permission from Packer DL. Catheter ablation for atrial fibrillation: A promising alternative to drug therapy

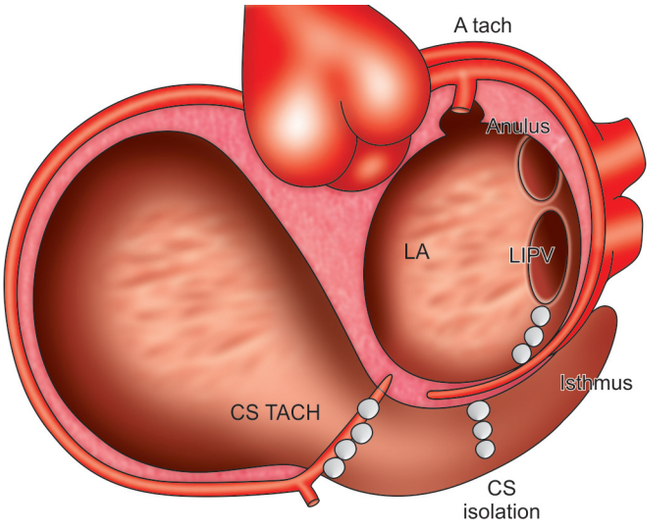

Fig. 11.22: Diagrammatic representation of ablation sites which may involve injury to the major coronary arterial system. Septal mitral annular tachycardias may result in injury to the proximal circumflex coronary artery, whereas the more distal portions of this artery can be injured during Ic or coronary sinus-based ablation

Over time, afib can create new pathways, called macro reentry sites, where it can 'cycle' in the heart. Macro reentry sites are different for each patient.

Ablation strategies and techniques continue to evolve, as does the terminology, as doctors learn more about areas of the heart that could act as a trigger or reentry site. Thus, the term 'segmental pulmonary vein isolation' is rarely used today, and instead we refer to the anatomic area that will be ablated or to the technical approach to ablation.

Basic Catheter Ablation Techniques

Here are the most frequently used basic catheter ablation techniques, shown in order of the fewest to the greatest number of ablation (lesion) lines.

Antrum pulmonary vein ablation: Because of the issues with the ostia, as mentioned above, the antrum (base) of the pulmonary veins became the site of catheter ablations. The antrum includes the posterior (back) wall of the left atrium and extends to the anterior (front) of the right pulmonary veins. In essence, it is a wide perimeter around the pulmonary veins. Antrum pulmonary vein ablation entails lesion lines in this area, but doctors do not confirm conduction block.

1. ***Pulmonary vein antrum isolation (PVAI or PVI)*** (Figs 11.22 and 11. 23): Lesion lines are made in the antrum of the pulmonary veins, and doctors confirm that conduction block has been achieved. Some electrophysiologists also make additional lesion lines. These may include the superior vena cava, roof of the atrium, or the septum, the wall that separates the two sides of the heart. You can see these structures in this diagram of the heart. However, the location of the additional lesions varies by doctor. That is, there is not a standard that requires that all pulmonary vein antrum isolations include a lesion line along the superior vena cava.
2. ***Circumferential ablation:*** Similar to pulmonary vein antrum isolation, circumferential ablation entails lesions encircling the pulmonary veins. Some electrophysiologists also make an ablation line that connects the pulmonary veins on the posterior (back) wall of the left atrium or ablate tissue from the pulmonary veins to the mitral valve. In addition, a mapping catheter is used to identify 'potentials', which are areas that could serve as a trigger or macro reentry site for atrial fibrillation. According to the HRS Consensus Statement, there is not a single endpoint, or goal, for circumferential ablation. Some doctors confirm that conduction block has been achieved, whereas others look for elimination of 'potentials' or a reduction in electrical activity in the ablated area.

Advanced Catheter Ablation Techniques

Atrial fibrillation leads to atrial remodeling over time, meaning that afib can change the deeper layers of heart tissue (substrate) or change the way electricity is conducted within the heart. This is also known as substrate modification. Advanced catheter ablation techniques, which are primarily used to treat persistent and long-standing persistent afib, target anomalies in the substrate or electrical conduction. However, clinical data is inconclusive, meaning that it is not clear whether these

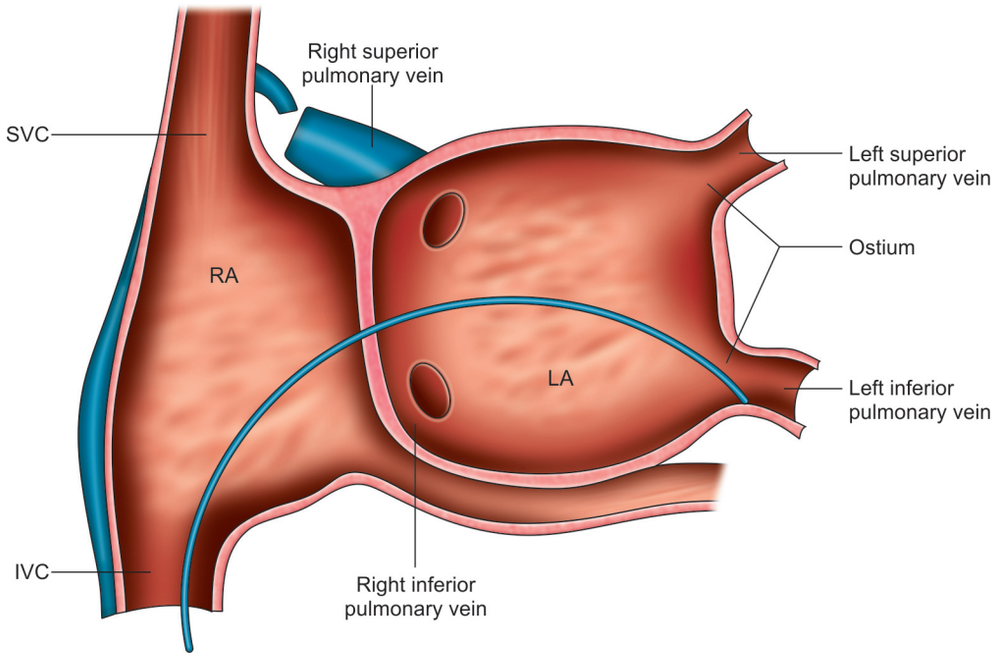

Fig. 11.23: Targeting the triggers in atrial fibrillation (AF) ablation

techniques can stop persistent or longstanding persistent afib for the majority of patients.

The most commonly used advanced catheter ablation techniques are:

1. ***Stepwise ablation:*** Stepwise ablation is the only ablation strategy with a stated goal of terminating afib. It involves isolation of the pulmonary veins and entails additional lesion lines, which differ by electrophysiologist. It is sometimes called sequential ablation because the additional ablation lines are performed in a specified order. That is, doctors may make a lesion line along the roof of the left atrium, and then pace or use a mapping catheter to determine whether conduction has been stopped. If there continues to be afib activity, the doctor will ablate the next area in the sequence. The lesion lines and sequences vary by doctor. Most electrophysiologists make a lesion on the roof of the left atrium after isolating the pulmonary veins. After this, some doctors will ablate the coronary sinus, the vessel between the left atrium and the left ventricle, whereas others might ablate the mitral isthmus, the area where the mitral valve and the left inferior pulmonary vein meet. There isn't one specific sequence that has proven to have the best results, largely because clinical trials haven't been performed on this.
2. ***Complex fractionated atrial electrograms:*** Ablation of complex fractionated atrial electrograms (CFAE, pronounced cafe) is performed by some electrophysiologists to treat persistent and longstanding persistent afib. A complex fractionated atrial electrogram is a site where there is an unusual electrical pattern, which could be due to the length of the electrical wave (long or short), the frequency of electrical activity (a lot or a little), or the speed of conduction (fast or slow). Complex fractionated atrial electrograms appear to represent macro reentry sites for atrial fibrillation, so ablation of these sites should stop afib, but that has not been proven by clinical data. In fact, CFAE ablation has been shown to be less effective in stopping afib than a pulmonary vein antral isolation with additional lesion lines at the roof of the left atrium and along the mitral isthmus. To learn more, *see* can catheter ablation successfully treat persistent atrial fibrillation, which discusses a session at the Heart Rhythm Society about ablating persistent afib.
3. ***Ganglionated plexi ablation:*** Another advanced strategy for stopping afib is to ablate the ganglionated plexi (GPs), which are 'fat pads' in the heart. Nerves that control automatic functions, such as breathing, are located in these ganglionated plexi. These nerves also initiate electrical activity at various places in the heart. It is thought that when one ganglionated plexus is activated, another ganglionated plexus located nearby will also be activated. Some doctors use mapping catheters with high frequency electrodes to identify ganglionated plexi, while others simply ablate the four primary ganglionated plexi in the left atrium. Ablation of the ganglionated plexi has not been widely adopted by electrophysiologists, which may be because there is little research data available.
4. ***Hybrid ablation:*** Hybrid ablation is an emerging treatment for patients with more severe forms of atrial fibrillation, typically persistent and longstanding persistent afib. Hybrid ablation is a dual approach in which an electrophysiologist ablates from inside the heart and a cardiac surgeon ablates on the outside of the heart. A hybrid ablation may enhance the prospects that ablation lines fully penetrate all layers of the cardiac tissue, which

is crucial to stopping afib. In addition, higher success rates and fewer complications could be possible because each specialty (electrophysiology and cardiac surgery) can ablate areas of the heart that are best suited to their different approaches. *See* hybrid procedure may offer better outcomes for persistent and longstanding persistent atrial fibrillation for Dr. James Edgerton's presentation on hybrid ablations at Boston Atrial Fibrillation Symposium in January 2011. Another dual approach, the convergent procedure, also has surgeons and electrophysiologists collaborate on ablation. The convergent procedure is different from hybrid procedures in that it uses a different entry point and a different device, in this case a unipolar radiofrequency device instead of a bipolar radiofrequency one.

Clinical Applications of Catheter Ablation

There are three classes of indications for catheter ablation:

1. The first is symptomatic supraventricular tachycardia (SVT) due to atrioventricular nodal re-entrant tachycardia (AVNRT), Wolff-Parkinson-White syndrome, unifocal atrial tachycardia, or atrial flutter (especially common right atrial forms). For these conditions, catheter ablation is first-line therapy if that is the patient's preference.
2. The second indication is atrial fibrillation with lifestyle-impairing symptoms and inefficacy or intolerance of at least 1 antiarrhythmic agent. Both left atrial ablation for restoration of sinus rhythm and AV junction ablation for rate control are class I indications, depending on the circumstance.
3. The third indication is symptomatic ventricular tachycardia (VT). Catheter ablation is first-line therapy in idiopathic VT, if that is the patient's preference. In structural heart disease, catheter ablation is generally performed for drug inefficacy or intolerance, or as adjunctive therapy in patients with an implantable cardioverter-defibrillator (ICD) who are experiencing frequent ICD discharges.

Uncommon indications for catheter ablation include the following:

1. Symptomatic drug-refractory (inefficacy or intolerance) idiopathic sinus tachycardia
2. Lifestyle-impairing ectopic beats
3. Symptomatic junctional ectopic tachycardia
4. RFCA has been applied to most clinical tachycardias, even to polymorphic ventricular tachycardia and ventricular fibrillation in preliminary studies. Success rates are highest in patients with common forms of SVT, namely AVNRT and orthodromic reciprocating tachycardia (ORT).

Contraindications to Radiofrequency Catheter Ablation

Few absolute contraindications to RFCA exist. Left atrial ablation and ablation for persistent atrial flutter should not be performed in the presence of known atrial thrombus. Similarly, mobile left ventricular thrombus would be a contraindication to left ventricular ablation. Mechanical prosthetic heart valves are generally not crossed with ablation catheters. Reproductive-aged women should not be exposed to fluoroscopy if any possibility exists that they are pregnant.

Table 11.1: Characteristics of catheter ablation for selected cardiac arrhythmias

Arrhythmia	Ablation location	Success rate (%)	Complication rate (%)	Potential complications	Indications
Atrial tachycardia	Variable, anywhere in right or left atrium	86–100	0–8	Atrioventricular or sinus node dysfunction; cardiac perforation with tamponade; phrenic nerve injury	Incessant tachycardia; symptomatic tachycardia-mediated cardiomyopathy
Atrioventricular reentrant tachycardia	Right atrium, perinodal	96	0.5–1	Atrioventricular nodal block, usually requiring pacemaker implantation	First-line therapy innodal patients willing and able to undergo catheter ablation
Atrioventricular reciprocating tachycardia	Variable, left or right atrioventricular	Approximately 95	2–4	Complete atrioventricular nodal block; cardiac perforation with tamponade	First-line therapy for symptoms, single or infrequent episodes, or with atrial fibrillation and rapid conduction
Atrial flutter	Right atrium, if common variety of atrial flutter	88–100	2.5–3.5	Cardiac perforation with tamponade; heart block; myocardial infarction; thromboembolic events	First-line therapy for poorly tolerated or recurrent episodes
Atrial fibrillation	Left atrium, pulmonary vein antra	60–80	6–10	Cardiac perforation with tamponade; phrenic nerve injury; pulmonary vein stenosis; thromboembolic events; vascular complications	Alternative to drug therapy for recurrent atrial in fibrillation in symptomatic patients with minimal or no left atrial enlargement

Preprocedural Considerations in Ablation Procedure

- Anesthesia for catheter ablation
- The procedure is typically performed under conscious sedation with intravenous tranquilizers and narcotics. General anesthesia is used in children and selected adults.
- Clinical examination of patient prior to ablation: The preprocedural evaluation always includes a thorough history and physical examination, as well as review of electrocardiograms (12-lead, if available) performed during the tachycardia and with the patient in sinus rhythm. At a minimum, preprocedure blood studies typically includes a complete blood cell count and an assessment of renal function and electrolyte levels.
- An echocardiogram is frequently obtained to exclude structural heart disease. Other tests that are indicated in specific situations include exercise testing with or without cardiac imaging (especially for exercise-induced tachyarrhythmias), and cardiac catheterization.
- The patient should fast overnight before the procedure. Cardiac medications with electrophysiologic effects, such as beta-blockers, calcium channel blockers, digoxin, and class I and III antiarrhythmic drugs, are often tapered and/or discontinued prior to the procedure. Warfarin is typically discontinued for at least a few doses prior to the procedure.

Technique Employed in Catheter Ablation in Different Clinical Situations

Typically, 2–5 electrode catheters are percutaneously inserted via the femoral or internal jugular veins and are positioned within the left heart, right heart, or both. Multiple catheters are needed to induce and map various tachyarrhythmias prior to radiofrequency catheter ablation (RFCA). Cannulation of the coronary sinus is helpful to exclude left-sided accessory pathways or other left-sided tachyarrhythmia substrates. For left heart catheterization, 1 of 2 approaches may be taken: transseptal catheterization via the interatrial septum or retrograde catheterization across the aortic valve. Anticoagulation with intravenous heparin is used to reduce the risk of periprocedural thromboembolism.

A. Ablation in Atrial Fibrillation

The simplest catheter ablation procedure performed in patients with atrial fibrillation is RFCA of the AV junction. AV nodal modification is less therapeutic than AV junction ablation and less commonly performed. Catheter ablation of atrial tissue to cure atrial fibrillation is still evolving. The procedure is technically demanding, more risky, and less successful than AV junction or AV nodal ablation. Nevertheless, the observation of Haissaguerre and others that pulmonary vein foci can trigger atrial fibrillation has stimulated much additional research, and there is considerable scientific excitement that this common tachyarrhythmia may be amenable to a curative catheter procedure. The complete surgical Maze procedure (incisions in both atria +/− transmural radiofrequency lesions) is still the most effective technique for potentially curing atrial fibrillation in all comers, regardless of chronicity or whether structural heart disease is present. The best success rates with left atrial catheter ablation are in patients with paroxysmal atrial fibrillation and hearts that are not too structurally abnormal. No consensus exists on the optimal left atrial ablation technique or what constitutes a clinically successful procedure. Nevertheless, evidence is accruing that catheter ablation for atrial fibrillation is more effective than antiarrhythmic drug therapy, especially in patients who have already failed an antiarrhythmic drug. The 2006 ACC/AHA/ESC guidelines for the management of atrial fibrillation now list catheter ablation as a reasonable strategy for patients with life-style impairing symptoms who have failed at least one antiarrhythmic agent (Figs 11.24–11.28).

RFCA of the atrioventricular (AV) junction is the simplest catheter ablation procedure performed in patients

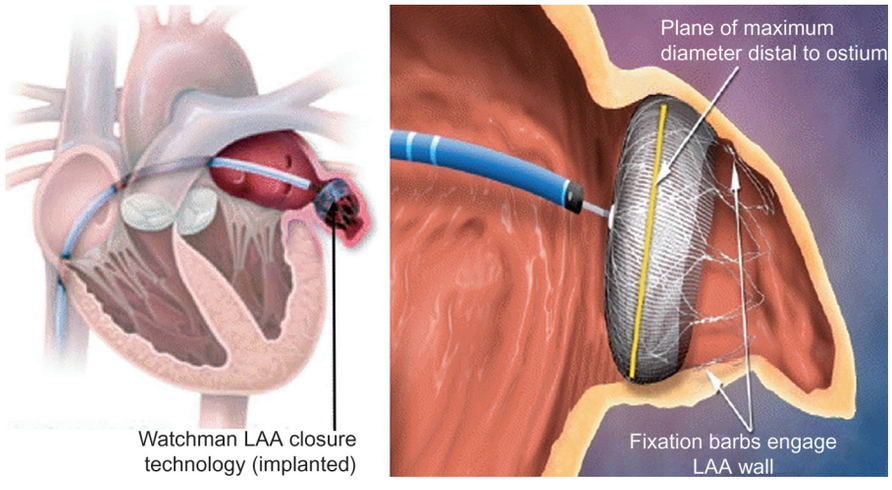

Fig. 11.24: A novel procedure using WATCHMAN left atrial appendage closure device implantation. Device is indicated to reduce the risk of thromboembolism from the left atrial appendage in patients with nonvalvular atrial fibrillation who are at increased risk for stroke and systemic embolism

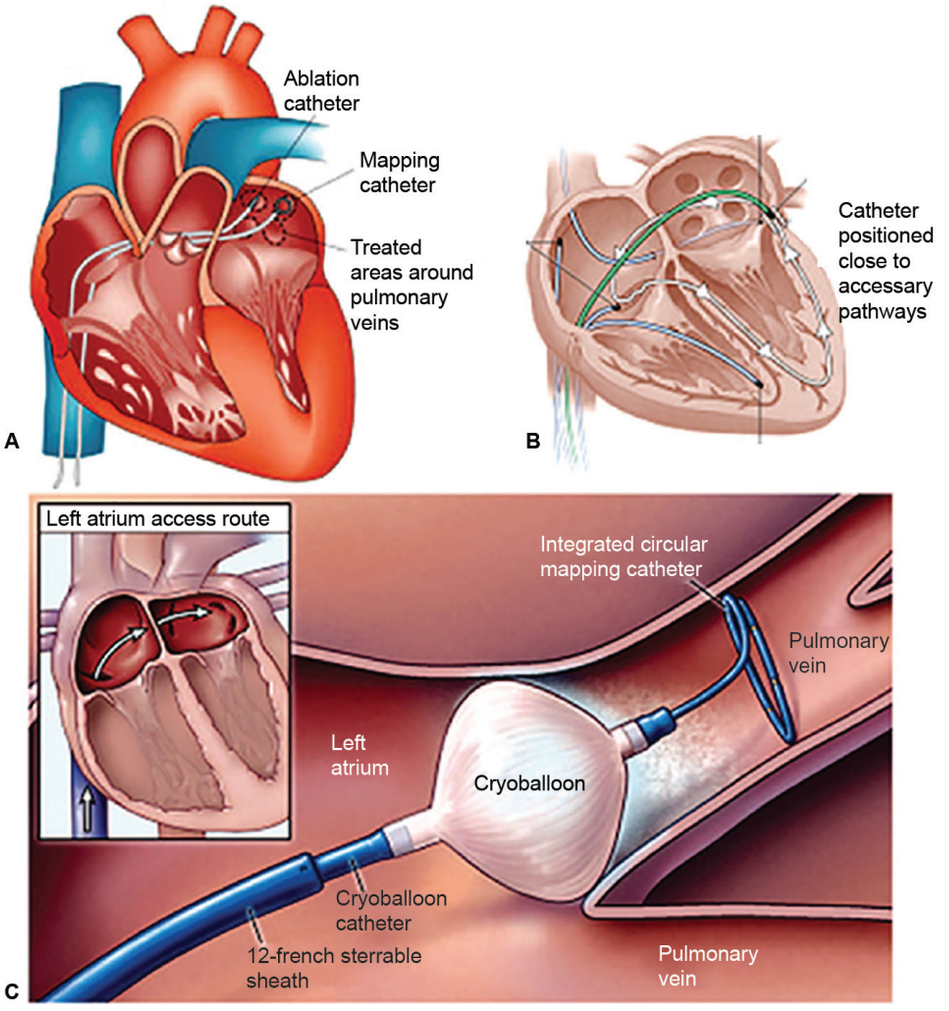

Fig. 11.25: (A) Shows treated area around pulmonary vein after introducing mapping and ablation catheters, (B) shows ablation catheter close to accessory pathway, (C) shows cryoablation catheter around the pulmonary vein



Fig. 11.26: Atrial fibrillation 12-lead ECG shows a rapid, irregularly irregular rhythm due to paroxysmal atrial fibrillation which was refractory to multiple medications



Fig. 11.27: Electrophysiologic mapping in Wolff-Parkinson-White syndrome. Shown are five surface ECG leads (I, aVF, V1, V3, V6) and intracardiac recordings from the high right atrium (HRA), lateral mitral annulus (HBE 1-2 and HBE 3-4), coronary sinus (proximal to distal, CS9-10, CS7-8, CS5-6, CS3-4, and CS1-2), and the right ventricular apex (RVA3-4). During the diagnostic electrophysiology study, orthodromic atrioventricular re-entrant tachycardia was induced recordings from the CS demonstrated that the earliest site of ventricular activation was at CS7-8, indicating a left lateral location of the accessory pathway (arrow). The mapping catheter (HBE1-2, 3-4) was advanced through a patient foramen ovale to the lateral mitral annulus. Activation mapping was used to select the ablation site; during sinus rhythem the ablation catheter was manoeuvreted to the site along the mitral annulus which recorded earliest ventricular activity (HBE1-2), i.e. the atrial (A) and ventricular (V) electrograms recorded from the ablation catheter tip were continuous and the local ventricular activity preceded the onset of the delta wave on the surface ECG

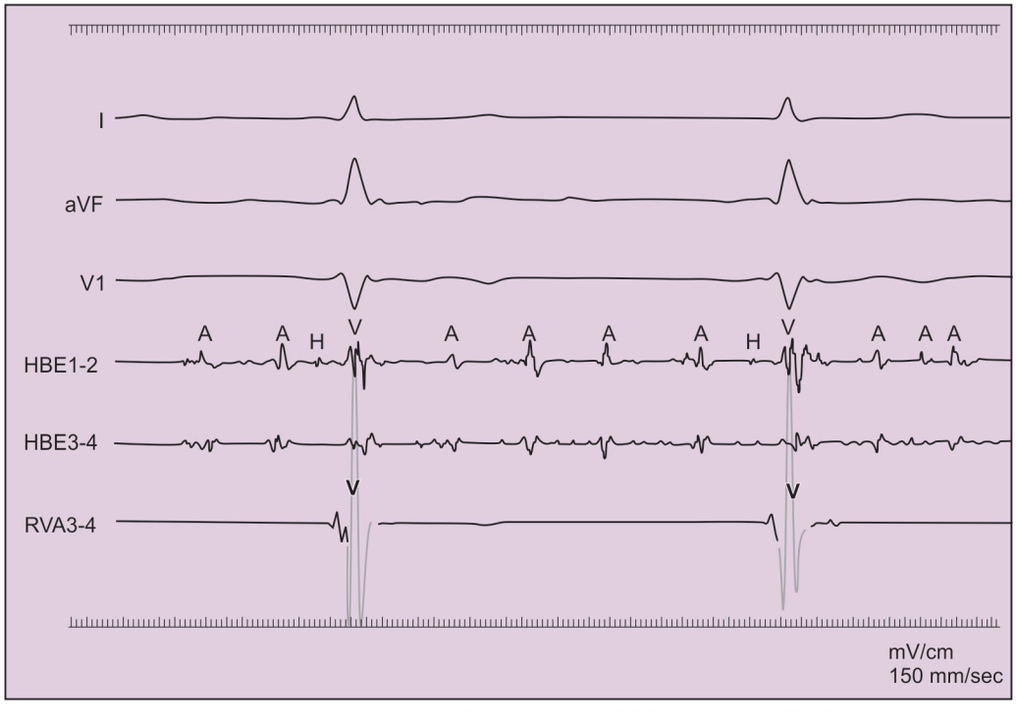

Fig. 11.28: Intracardiac electrograms during atrial fibrillation. Three surface ECG leads (I, aVF, V1) and intracardiac recordings from the atrioventricular (AV) junction region (HBE1–2, HBR3–4), and the right ventricular apex (RVA3–4) in a patient with atrial fibrillation. The patient has extremely symptomatic, medically refractory atrial fibrillation with rapid ventricular rates and recurrent congestive heart failure. The mapping catheter (HBE) has been manoeuvred from the area of maximal His bundle activity to a more proximal position, where a larger atrial (A) and smaller His electrogram (H) are recorded. V=ventricular electrogram

with atrial fibrillation. AV nodal modification is less often performed. For catheter ablation of atrial tissue for atrial fibrillation, the most commonly used techniques involve ablation of the muscular connections between the pulmonary veins and the left atrium (pulmonary vein isolation), or a wide circumferential ablation around the pulmonary veins (see image below). The goal is to electrically isolate foci arising from inside the veins, or adjacent to the pulmonary vein ostia, from the rest of the left atrium. Electroanatomic map of the posterior left atrium, illustrating the pulmonary veins: right superior pulmonary vein (RSPV), right inferior pulmonary vein (RIPV), left superior pulmonary vein (LSPV), and left inferior pulmonary vein (LIPV). The red circles represent actual discrete radiofrequency applications, predominantly delivered in a circumferential pattern around the pulmonary veins. This ablation strategy can isolate pulmonary vein foci that initiate atrial fibrillation, and/or alter the substrate of the left atrium to inhibit fibrillatory activity due to reentry. Image courtesy of American College of Cardiology Foundation.

B. Atrioventricular Nodal Reentrant Tachycardia
(Figs 11.29 and 11.30)

- In the common form of atrioventricular nodal reentrant tachycardia (AVNRT), the inferior atrionodal input to

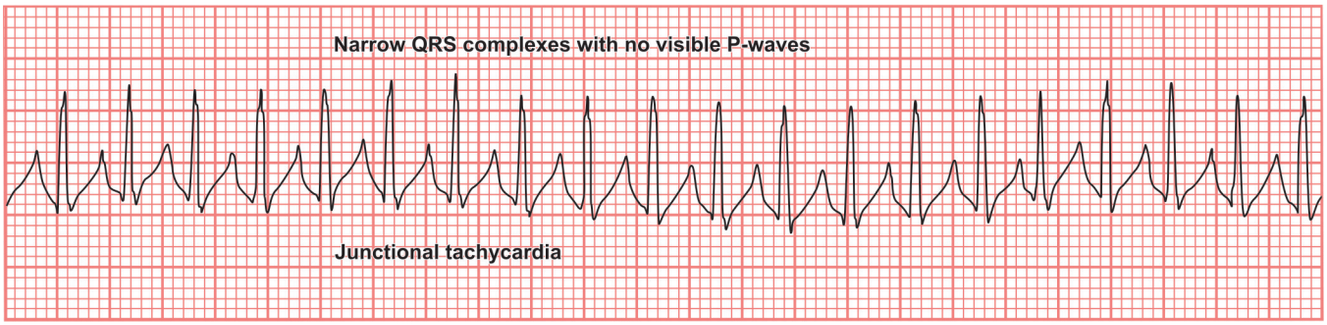

Fig. 11.29: Junctional tachycardia: Narrow QRS complexes with no visible P-waves



Fig. 11.30: Identification of slow pathway for ablation of AV nodal reentrant tachycardia recordings from the high right atrium (HRA3–4) and distal His bundle region (HBE1–2), proximal to distal coronary sinus (CS9–10, CS5–6, CS3–4, and CS1–2), and the right ventricular apex (RVA3–4). The patient had a history of medically refractory supraventricular arrhythmia and the diagnostic study revealed easily inducible, typical atrioventricular (AV) nodal reentrant tachycardia. The HBE catheter was manoeuvred from the His position to the slow pathway region, which is typically inferior and posterior to the His bundle and just anterior to the coronary sinus ostium. This is an ideal site for slow pathway ablation and has a small atrial electrogram (A) and large ventricular electrogram (V), with no evidence of His bundle activity. The tip of the HBE catheter (HBE1–2) records such a signal, and is used for ablation

the atrioventricular (AV) node serves as the anterograde limb (i.e. the slow pathway) of the reentry circuit, and the superior atrionodal input serves as the retrograde limb (i.e. the fast pathway). Typically, AVNRT can be cured by targeting the slow pathway near the inferior tricuspid valve annulus at the level of the coronary sinus os or somewhat higher.

- The risk of iatrogenic heart block with ablation in this region is quite low (1–2%). Targeting the slow pathway is safer than targeting the fast pathway, which is located closer to the compact AV node.

C. Orthodromic Reciprocating Tachycardia

In orthodromic reciprocating tachycardia (ORT) the AV node serves as the anterograde limb and an accessory AV connection (i.e. the accessory pathway) serves as the retrograde limb (see images below). Schema of orthodromic reciprocating tachycardia (ORT). The atrioventricular node serves as the antegrade limb, whereas an accessory pathway (atrioventricular connection) serves as the retrograde limb. For ECG features of ORT, see the image below. Supraventricular tachycardia (SVT) in a patient with orthodromic reciprocating tachycardia (ORT) due to a concealed pathway. Note the retrograde P-wave, seen best in lead V2, separated from the QRS complex by an isoelectric baseline. (Compare to the first ECG above, in which the P-wave is fused to the QRS.) This pattern of 'short R-P tachycardia' (in which the interval between the QRS complex and retrograde P-wave is shorter than the subsequent P-R interval and the P-wave is in the first half of the R-R interval) suggests an SVT incorporating an accessory pathway. Typically, ORT can be cured by targeting the accessory pathway as it crosses the mitral or tricuspid valve annulus (Figs 11.31 and 11.32).

D. Antidromic Reciprocating Tachycardia

An **antidromic tachycardia** refers to a fast heart rhythm that utilizes the *manifest accessory* pathway to preexcite the ventricles, irregardless of whether the normal *AV node* is used in a retrograde fashion. In other words, other *SVTs,* such as *atrial tachycardia* or *atrial flutter* and *fibrillation* can now conduct at fast heart rates to the ventricles in a 1 to 1 fashion (no protection to limit this conduction since the *AV node* is not in use). This is the theoretical danger of an *accessory* pathway that allows conduction to the *ventricles* in an uncontrolled, potentially fast rate, with repetitive stimulation of the *ventricles* potentially leading to *ventricular fibrillation* with hemodynamic collapse and sudden cardiac death. This situation is rare and it is estimated that this tragic event has less than a 0.1% chance (1 in a 1000) of occurring each year in patients with manifest WPW (Figs 11.33 and 11.34).

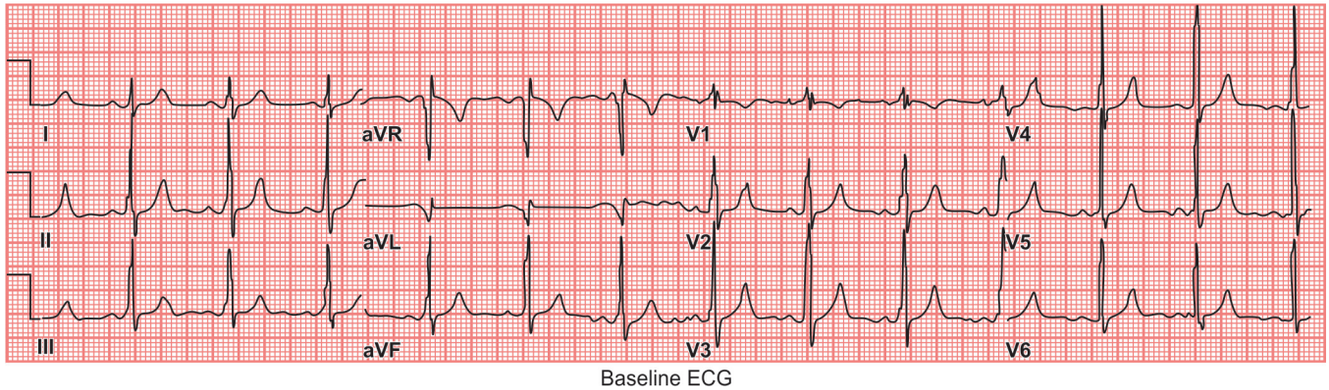

Baseline ECG

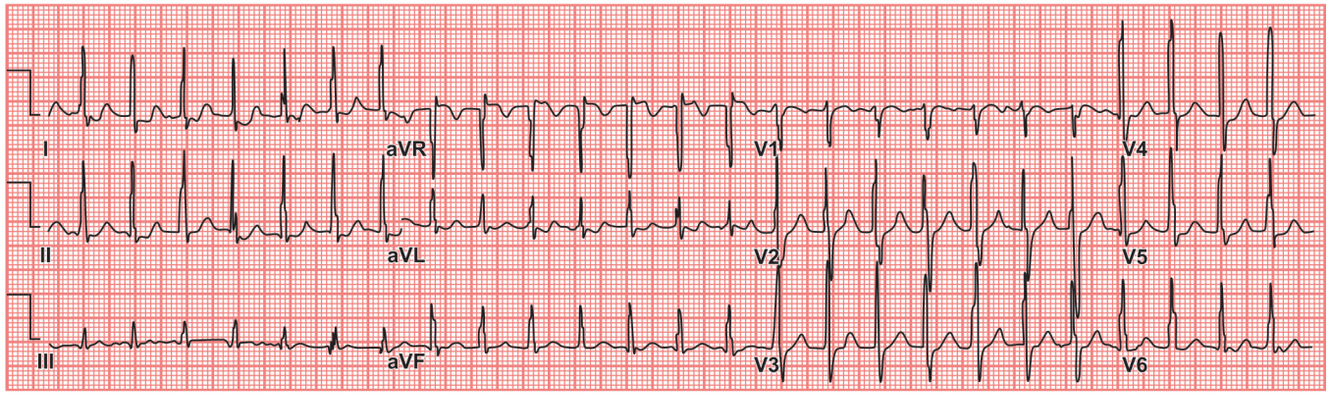

Orthodromic reciprocating tachycardia

Fig. 11.31: Left lateral accessory pathway (AP). It is prudent to recognise that the delta wave vector can only be determined with precision when the ECG shows maximum preexcitation. A right-sided AP with minimal preexcitation but with a posteroseptal location can not be determined with a high probability until ART occurs

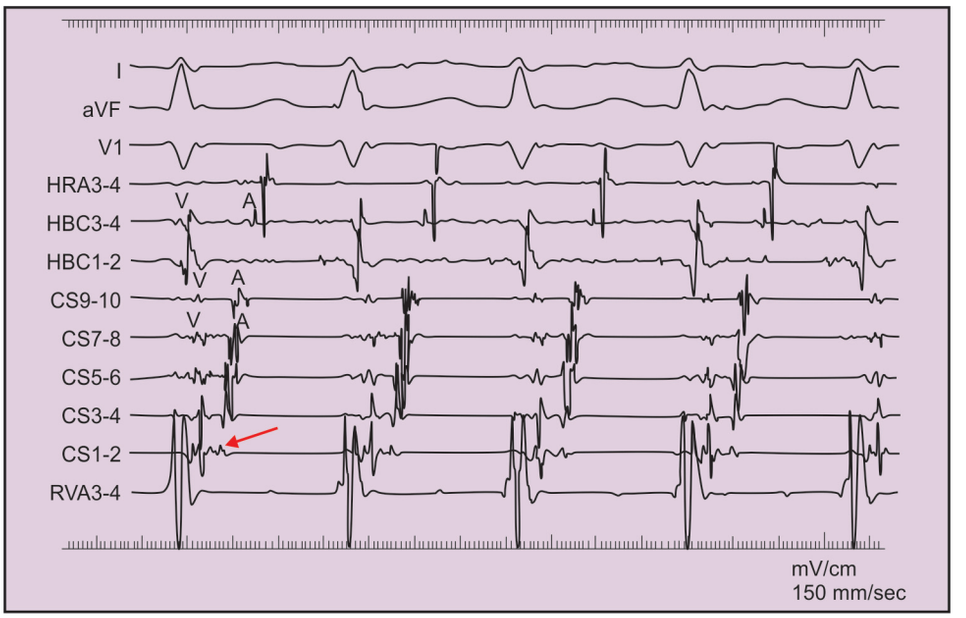

Fig. 11.32: Orthodromic AV reentrant tachycardia in concealed accessory pathway. Shown are three surface ECG leads (I, aVF, V1) and intracardiac recording from the high right atrium (HRA), proximal (HBE3–4) and distal His bundle region (HBE1–2), proximal to distal coronary sinus (CS9–10, CS7–8, CS5–6, CS3–4 and CS1–2), and right ventricular apex (RVA3–4) in a patient with atrioventricular reentrant tachycardia (AVRT). During an orthodromic AVRT, there is retrograde atrial (A) activation which occurs after ventricular activation (V); the earliest atrial activation (arrow) is seen in the lateral mitral annulus (CS1-2) due to a conceated left lateral accessory pathway

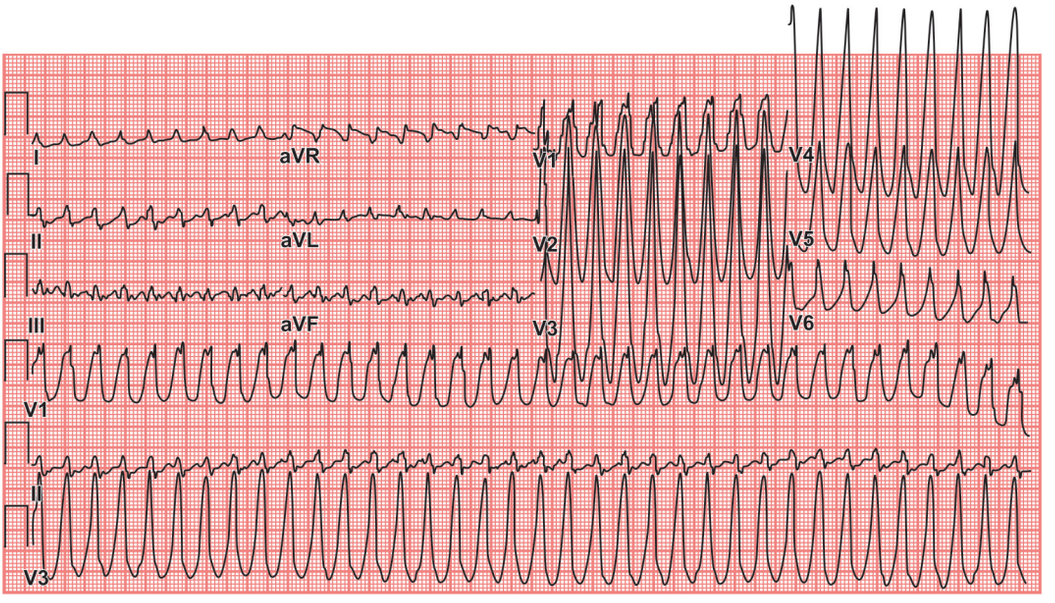

Fig. 11.33: Antidromic AV reciprocating tachycardia (ART)

Not all *accessory* pathways are manifest with a *delta* wave on the 12-lead EKG (no *WPW EKG pattern* seen). *Concealed* **WPW** is actually more common than *manifest WPW*. In these situations, the patient will have a normal baseline EKG but a clinical narrow-complex SVT of unclear origin. These accessory pathways are *concealed* may conduct only in the reverse, or retrograde fashion, leading to *orthodromic AVRT* as described above, but no clues to its existence with a normal baseline EKG. In addition, multiple accessory pathways are present in as many as 13% of patients referred to a heart rhythm specialist because of *WPW syndrome*.

E. Unifocal Atrial Tachycardia

Unifocal atrial tachycardia (Fig. 11.35), which can arise from either atrium, is somewhat more challenging to ablate than the more common forms of generic SVT. For those

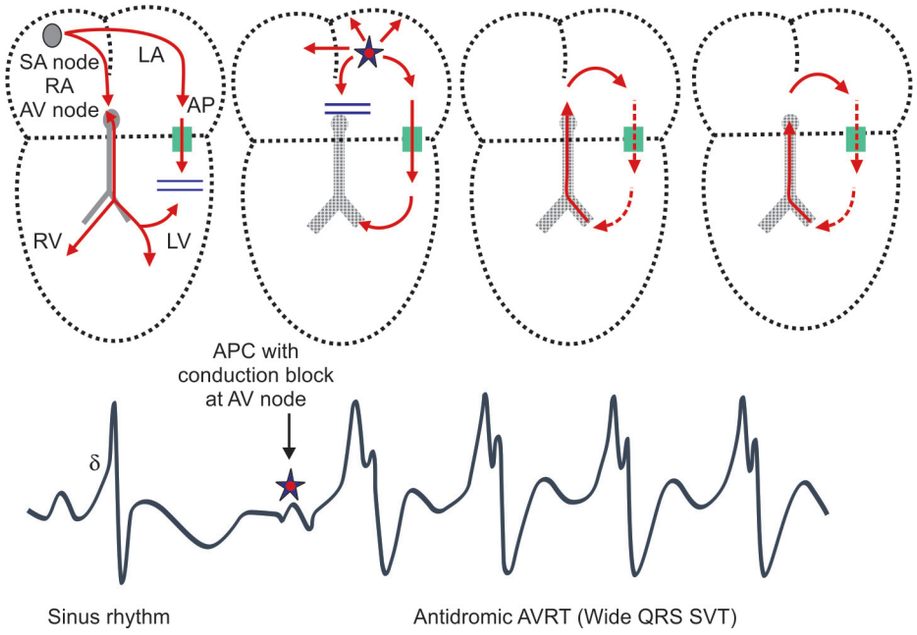

Fig. 11.34: Antidromic AV reciprocating tachycardia in a patient with left-sided AP

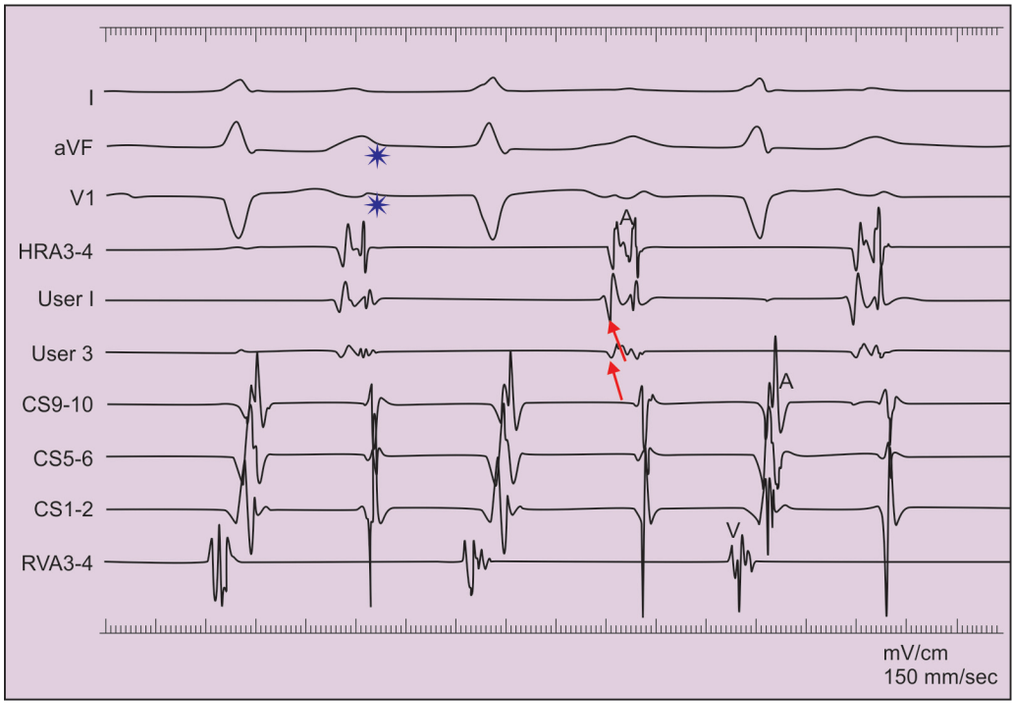

Fig. 11.35: Electrophysiologic mapping of atrial tachycardia. Three surface ECG leads (I, aVF, V1) and intracardiac recordings from the high posterior right atrium (HRA); posterior left atrium (USER 1 and USER 3); proximal, mid, and distal coronary sinus (CS9–10, CS5–6, CS1–2); and right ventricular apex (RVA). The patient had an incessant atrial tachycaria and dilated cardiomyopathy (left ventricular ejection fraction 9%) referred for cardiac transplant evaluation. The P-wave (*) falls at the end of the T-wave on the surface ECG; its onset is difficult to discern. However, the intracardiac electrograms demonstrate obvious atrial (A) and ventricular (V) activity. Activation mapping involves positioning the mapping catheters in the right (HRA) and left atrial (USER) to the record earliest electrical activity (arrow) than the right atrial catheter, but the timing with respect to the surface P-wave is obscured because of the T-wave of the preceding QRS complex

tachycardias originating from the left atrium, transseptal catheterization via a patent foramen ovale or transseptal puncture is usually required.

F. Wolff-Parkinson-White syndrome

Typically, a transition from ORT to atrial fibrillation can be the cause of rapid preexcited tachycardia in Wolff-

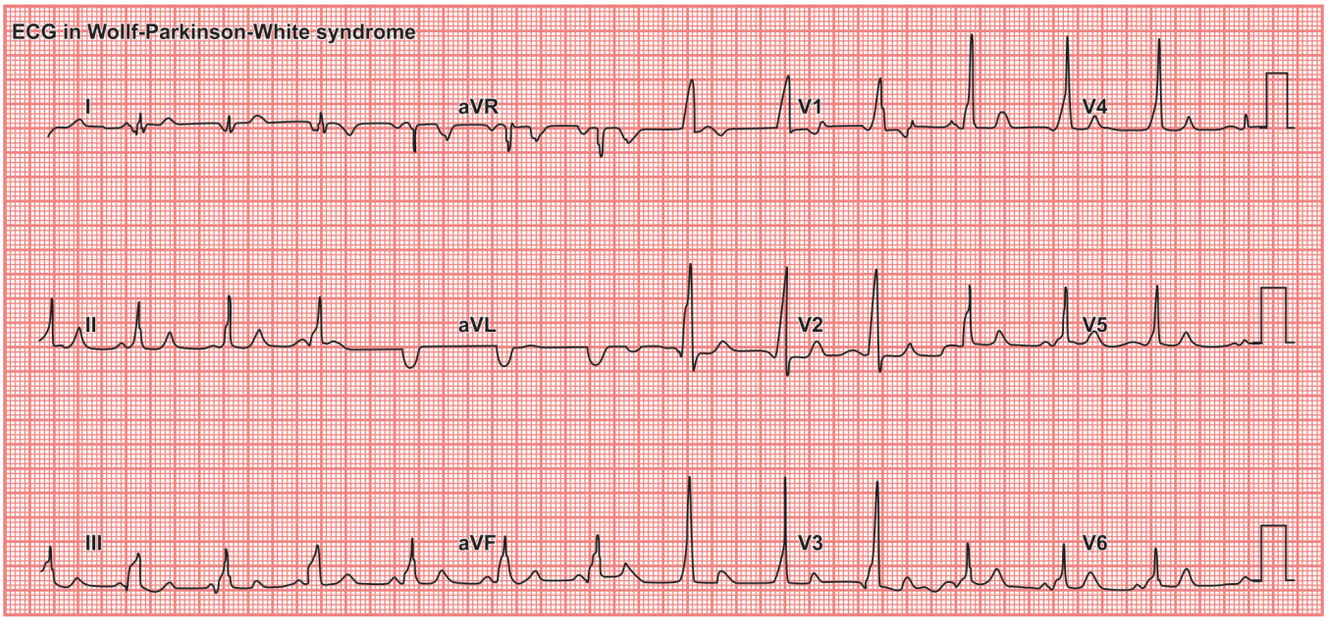

Fig. 11.36: ECG shows the short PR interval and slurred upstroke of the QRS (delta wave). The QRS is positive in V1 and in the inferior leads; thus, the pathway is left-sided and anterior (free wall)

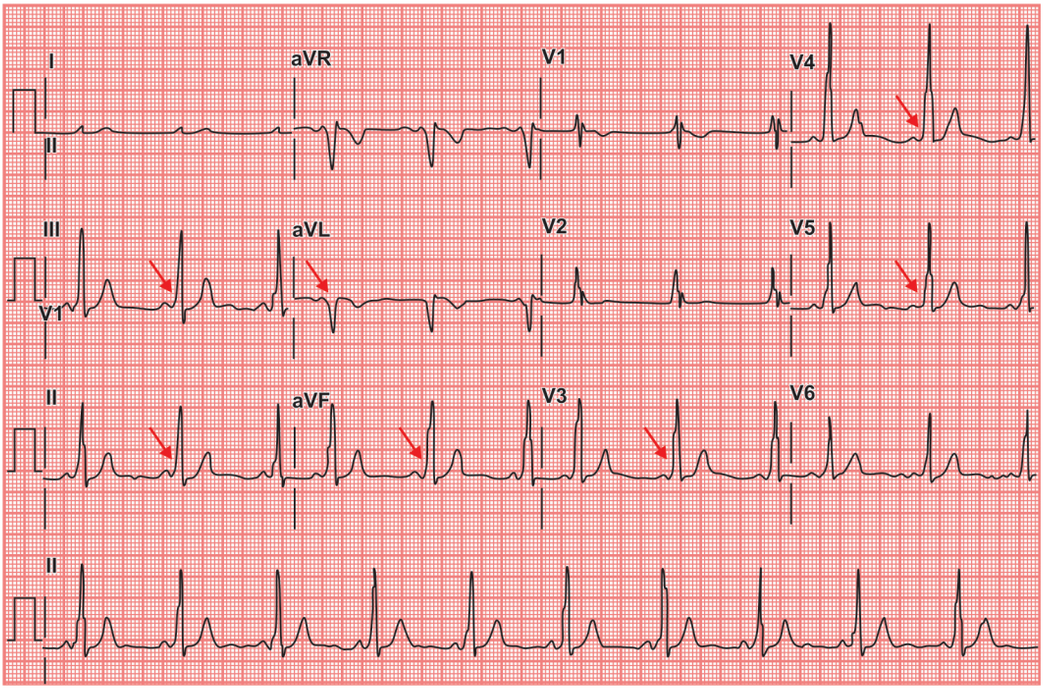

Fig. 11.37: Resting ECG shows delta waves (red arrows) in the inferior and lateral leads

Parkinson-White syndrome. Ablation of the accessory pathway cures the syndrome, eliminating ORT and atrial fibrillation in most instances (Figs 11.36–11.39).

G. Atrial Flutter

Atrial flutter is most commonly due to a large reentrant circuit in the right atrium, involving an isthmus of tissue between the tricuspid valve annulus and the inferior vena cava (Figs 11.40 and 11.41). Most commonly, reentry proceeds counterclockwise up the atrial septum and down the lateral wall of the right atrium, inscribing inverted (i.e. 'sawtooth') flutter waves in the inferior leads and upright P-waves in V1 schema of the common variety of atrial flutter. The reentry circuit is confined to the right atrium and circulates as a counterclockwise macroreentrant circuit proceeding superiorly over the atrial septum and inferiorly

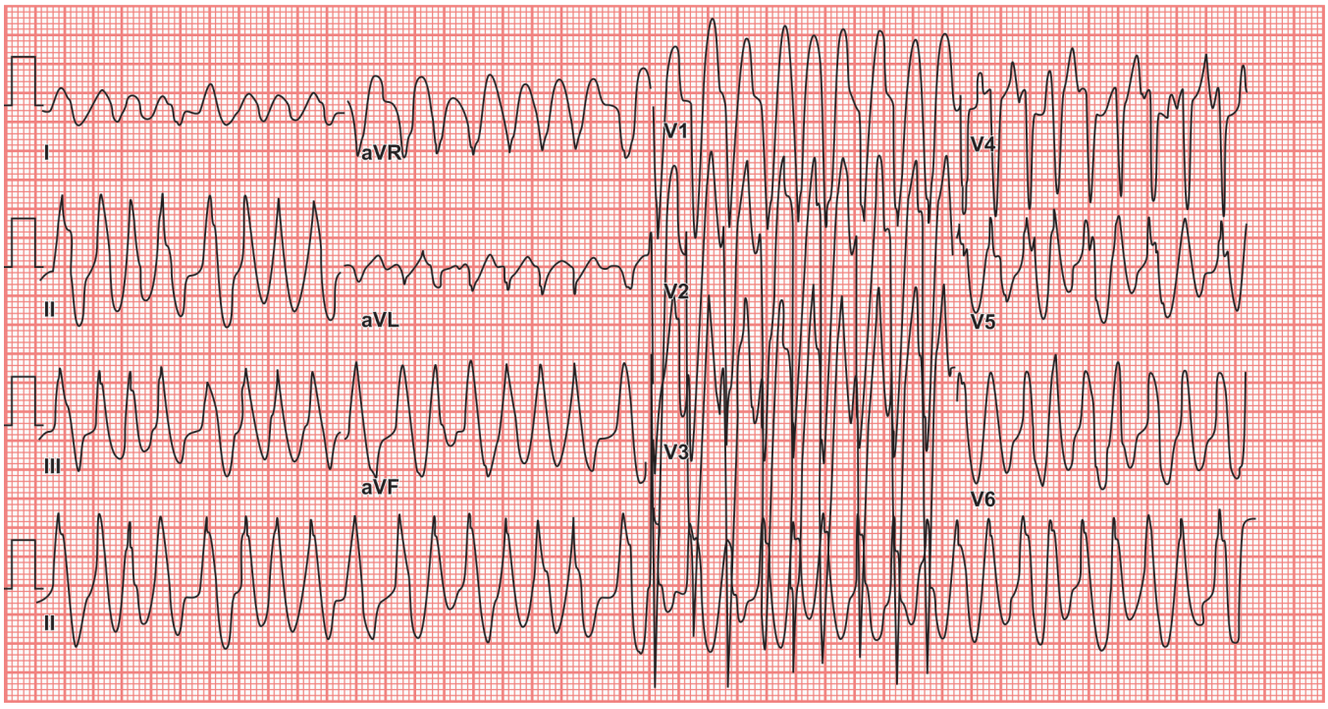

Fig. 11.38: ECG morphology showing preexcited atrial fibrillation

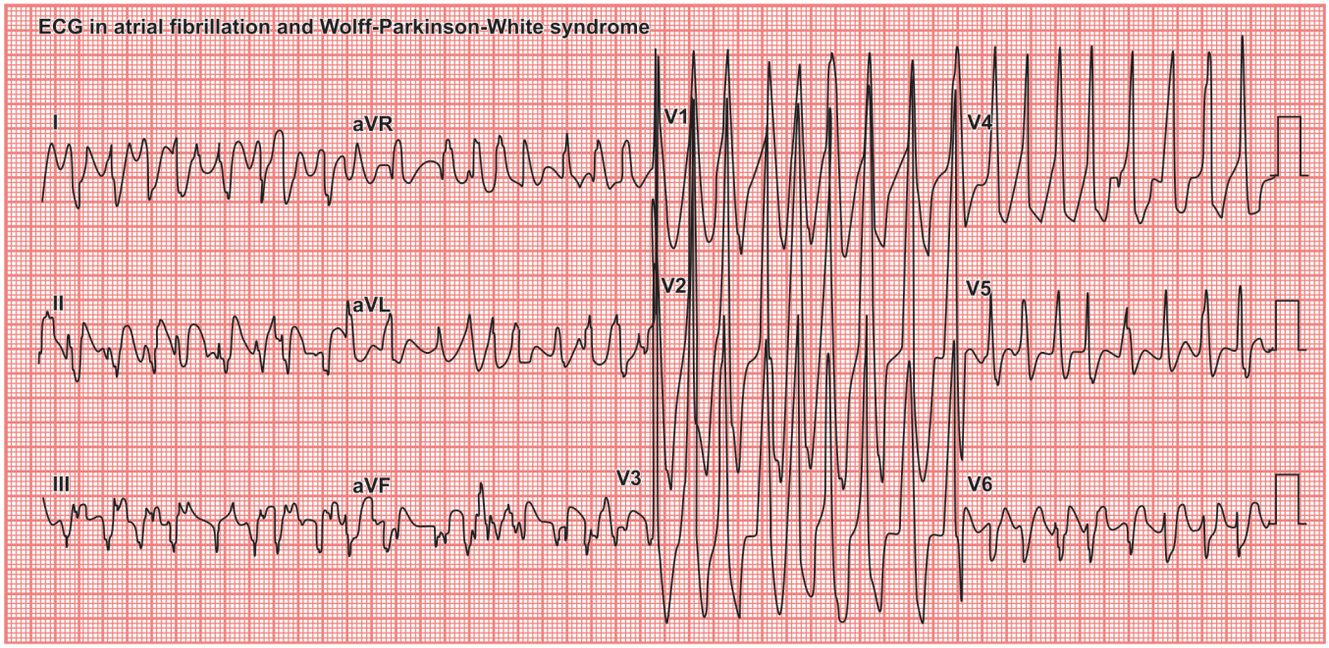

Fig. 11.39: ECG shows an irregular broad-complex tachycardia. Almost all irregular tachycardias are atrial fibrillation. QRS morphology varies because of the varying contributions of the atrioventricular node and the accessory pathway in atrial fibrillation to activation of the ventricle. This ECG shows preexcited atrial fibrillation. The shortest RR Interval is 200 milliseconds; intervals <260 milliseconds are associated with a risk of sudden death

over the lateral atrial wall. The wave front circulates through a narrow isthmus of tissue between the tricuspid valve annulus and the inferior vena cava. Linear ablation across this isthmus cures this common form of atrial flutter.

An example of a typical counterclockwise atrial flutter, the most common form of atrial flutter. The cardinal features are a perfectly regular atrial rhythm with inverted P-waves inferiorly that have a positive overshoot, upright P-waves in V1, and inverted P-waves in V6. Clockwise reentry using this same circuit can also occur, giving upright P-waves inferiorly and inverted P-waves in V1. Linear ablation of the cavotricuspid isthmus cures these

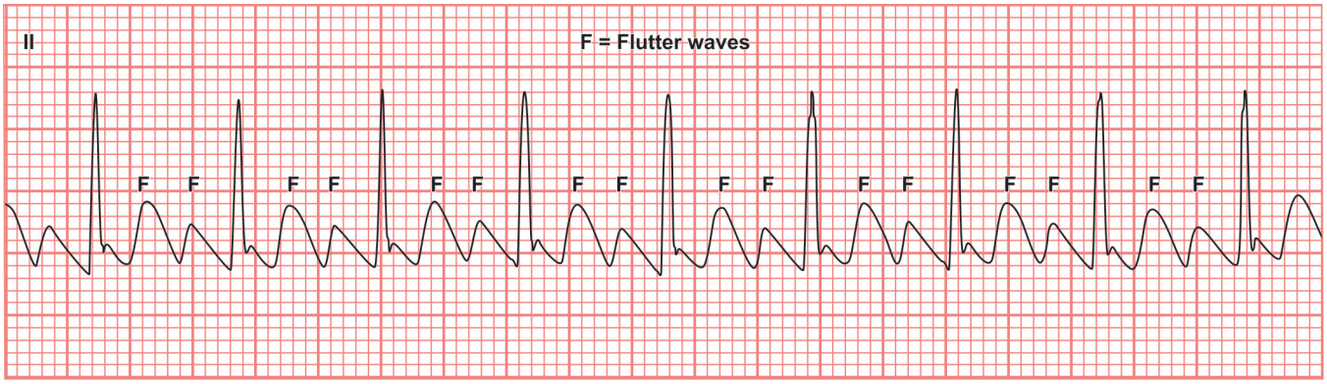

Fig. 11.40: Atrial flutter. Narrow QRS complexes are associated with regular flutter waves

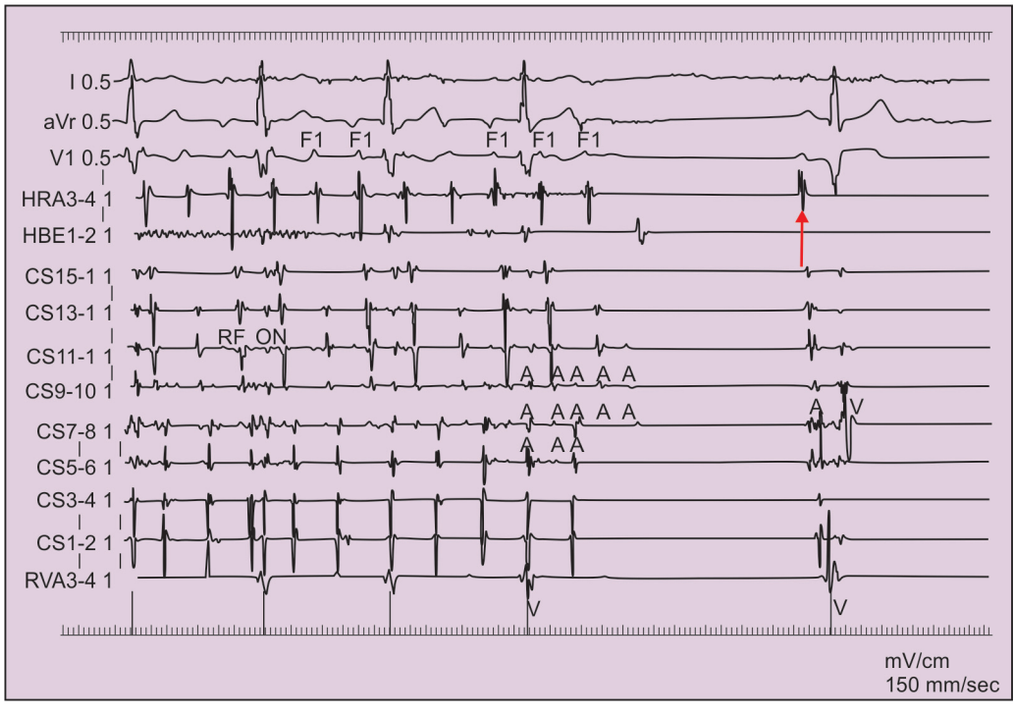

Fig. 11.41: Radiofrequency catheter ablation of typical atrial flutter. There surface ECG leads (I, aVF, V1) and intracardiac recordings from the high right atrium (HRA), a mapping catheter in the isthmus between the tricuspid valve and inferior vena cava (TV-IVC) (HBE1–2), eight recordings from a catheter extending from the lateral right atrial wall through the TV-IVC isthmus and into the ostium of the coronary sinus (CS15–1 to CS1–2), and right ventricular apex (RVA3–4) in a patient with typical atrial flutter. The tip of the mapping catheter was initially positioned on the tricuspid annulus, and then dragged through the TV-IVC isthmus to the ostium of the IVC during RF application; atrial flutter terminated. Note that the atrial activation (A) blocks between CS7–8 and CS5–6, which on fluoroscopy corresponded to the position of the mapping catheter. FI=flutter waves, V=ventricular electrogram

common forms of atrial flutter.Non-isthmus-dependent flutters can occur elsewhere in the right atrium as well as in the left atrium. Left atrial flutters are uncommon, may be difficult to ablate, and generally require a 3-dimensional mapping system to facilitate the procedure. A 3-dimensional electroanatomic map of cavotricuspid isthmus flutter. The colors progress from red to purple and represent relative conduction time in the right atrium (early to late). An ablation line (red dots) has been created from the tricuspid annulus to the inferior vena cava. This interrupts the flutter circuit.

H. Ablation in Accessory Pathways

Since first described in 1989, radiofrequency catheter ablation of accessory pathways has gained rapid and widespread acceptance as a safe and curative treatment for patients with the Wolff-Parkinson-White syndrome and/or paroxysmal supraventricular tachycardia involving a concealed accessory pathway. Catheter ablation of accessory pathways is now considered as first line therapy for the treatment of patients with the Wolff-Parkinson-White syndrome and is considered an alternative to

antiarrhythmic therapy for patients with paroxysmal supraventricular tachycardia (Figs 11.42–11.48).

I. Ablation in Ventricular Tachycardia (Figs11.49 to 11.51)

Idiopathic ventricular tachycardia (VT) most commonly arises from the right ventricular outflow tract and less commonly originates in the inferoseptal left ventricle near the apex. These forms of VT are amenable to catheter ablation, although success rates are somewhat lower than those for the common forms of SVT. For patients with stable VT, the potential benefit of catheter ablation before implantation of an ICD was demonstrated in the Ventricular Tachycardia Ablation in Coronary Heart Disease (VTACH) study. This prospective, randomized, controlled international trial in 104 patients found that time to recurrence of VT or ventricular fibrillation (VF) was longer in the ablation group (median, 18.6 mo) than in the control group (5.9 mo). At 2 years, estimates for survival free from VT or VF were 47% in the ablation group and 29% in the control group (Figs 11.49–11.51).

Measures to be Adopted After Ablation Procedure in the Following Clinical Situations

Atrial Fibrillation

Radiofrequency catheter ablation (RFCA) of the atrioventricular (AV) junction results in excellent rate control, relieves palpitations, and improves functional capacity; however, patients who undergo this procedure require permanent pacemaker implantation to manage the resulting AV block and require warfarin therapy to prevent stroke because the atrial fibrillation itself is not affected. AV nodal modification is less therapeutic than AV junction ablation and may result in late heart block.

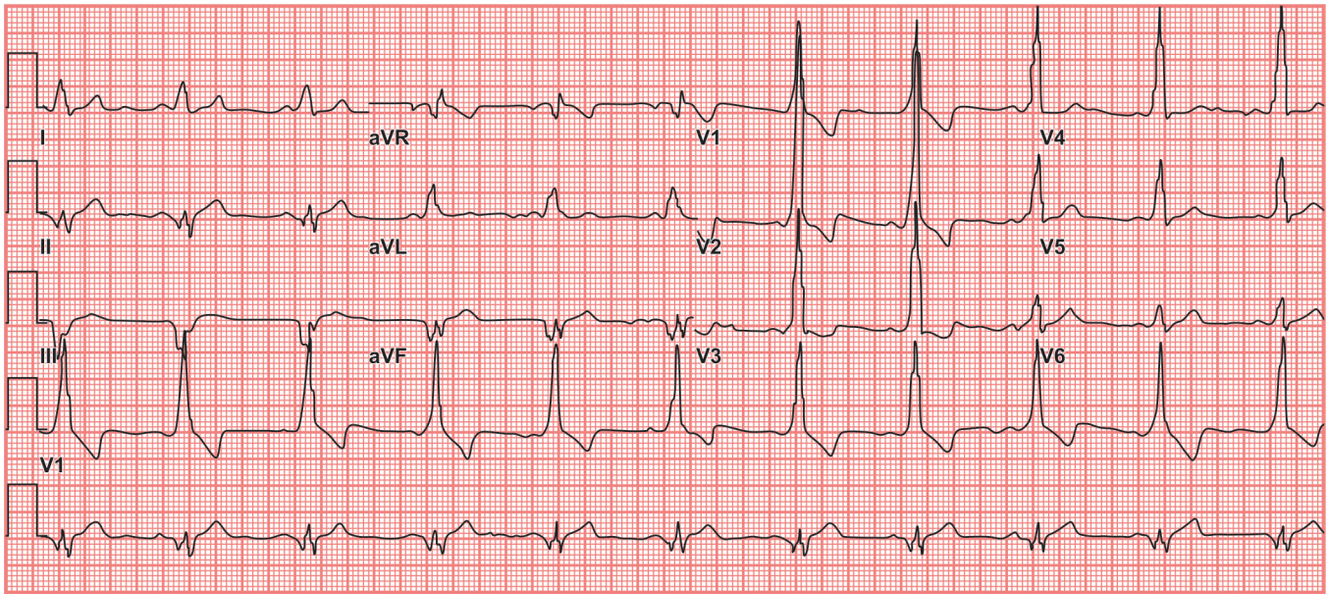

Fig. 11.42: Left posteroseptal accessory pathway (AP). A negative delta wave in lead I, aVL and V6 (rightward QRS axis) with a positive delta wave in lead V1 suggests a left lateral pathway

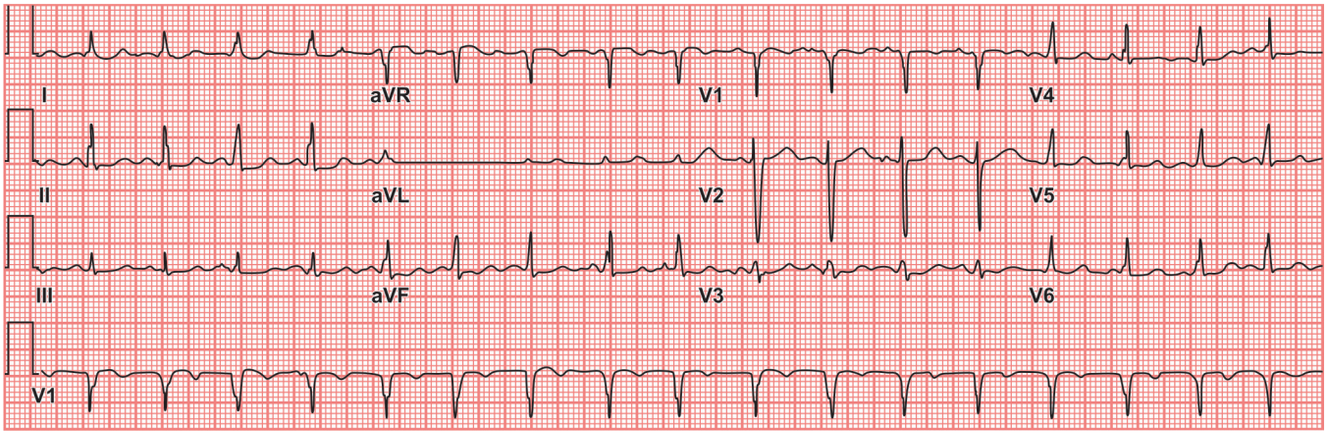

Fig. 11.43: Right anteroseptal accessory pathway (AP). A left axis (with a negative delta wave in lead V1) suggests a right lateral AP

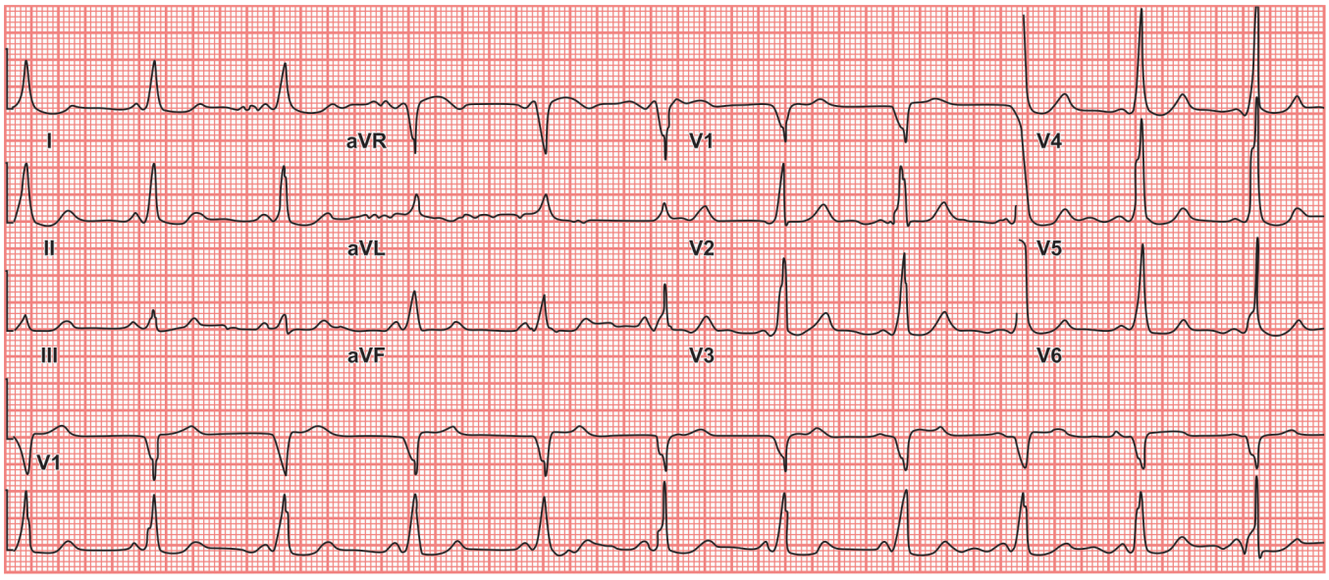

Fig. 11.44: Right lateral accessory pathway (AP). If the delta waves in the inferior leads are negative, then it denotes a posteroseptal AP right, or left, depending on the delta wave vector in lead V1 as described earlier

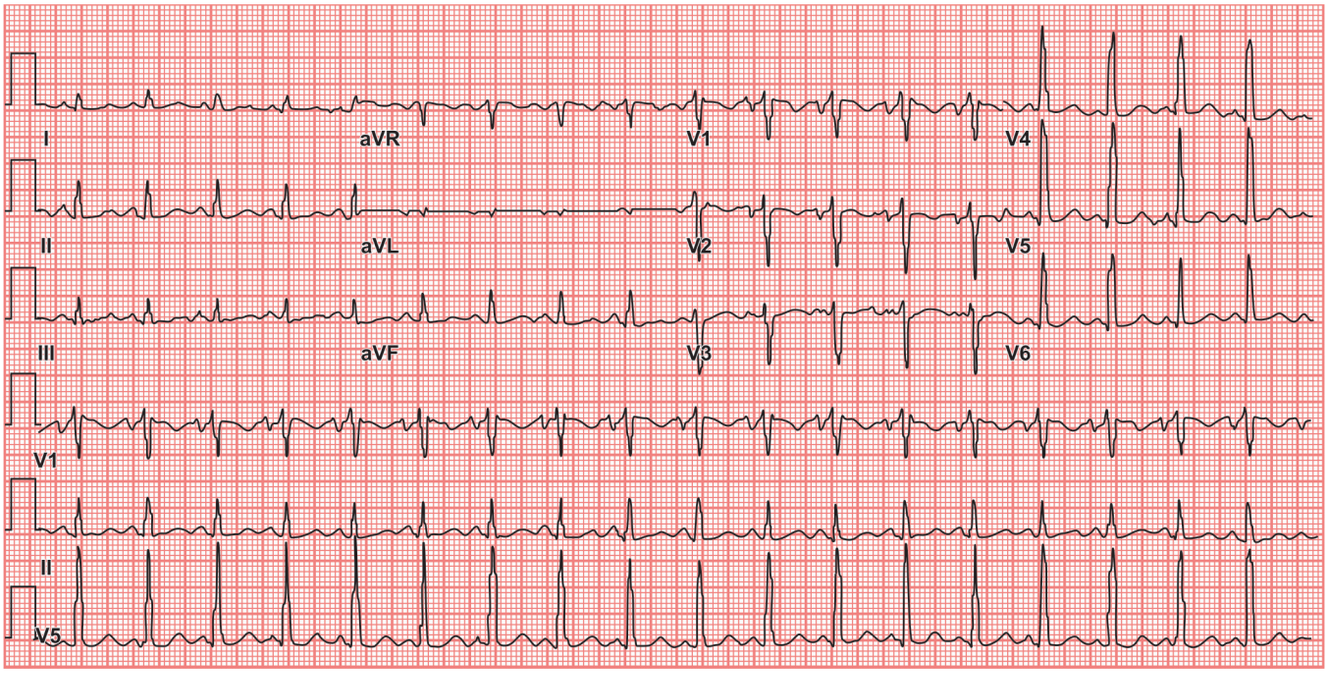

Fig. 11.45: Left lateral accessory pathway (AP) showing signs of minimal preexcitation in the inferior leads

Supraventricular Tachyarrhythmias

The common forms of supraventricular tachycardia (SVT) (e.g. atrioventricular nodal reentrant tachycardia [AVNRT], SVT associated with Wolff-Parkinson-White syndrome) are usually curable with a single procedure; the success rate is typically 90–95%. Cure rates for unifocal atrial tachycardia and common right atrial flutter are somewhat lower but still approach 90%. Recurrent tachyarrhythmias typically occur in the first few months after ablation and may be amenable to cure with a second procedure.

AVNRT is usually amenable to cure with a slow pathway ablation near the inferior atrial septum, where the risk of heart block is 1–2%. In the uncommon circumstances in which ablation near the compact AV node is required (e.g. fast pathway for AVNRT, or an accessory pathway in a para-Hisian location), the risk of heart block may approach 5% or a little higher.

In a number of centers, catheter-based cryoablation is used rather than radiofrequency catheter ablation (RFCA) near the compact AV node to minimize the risk of heart

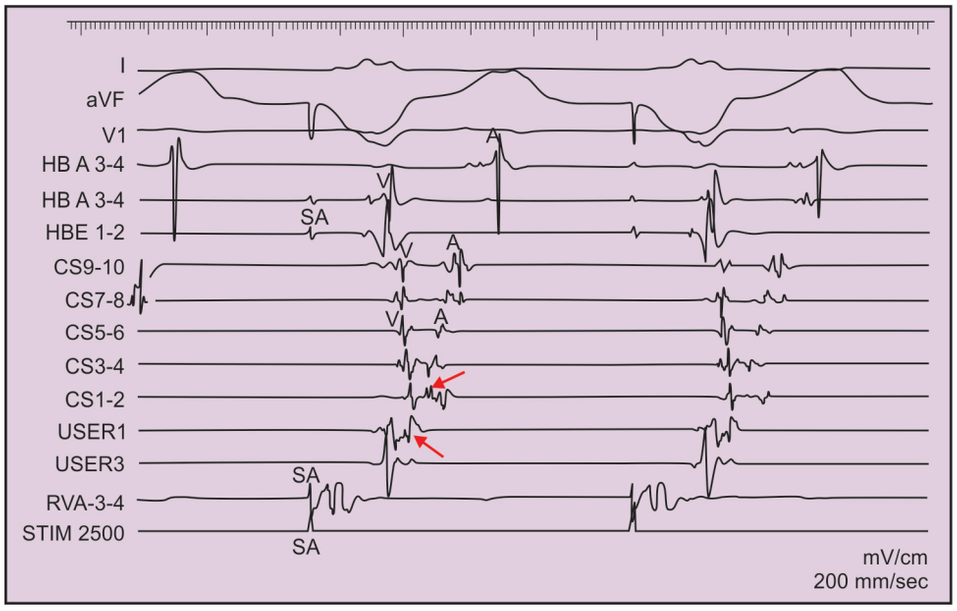

Fig. 11.46: Electrophysiologic mapping of concealed accessory pathway during ventricular pacing. Shown are three surface ECG leads (I, aVF, and V1) and intracardiac recording from the high right atrium (HRA), proximal (HBE 3–4) and distal His bundle region (HBE1–2), proximal to distal coaronary sinus (CS9–10, CS7–8, CS 5–6, CS3–4, and CS1–2), right ventricular apex (RVA3–4), from a mapping catheter's distal (USER 1) and proximal (USER 3) electrode pairs, and a stimulus artifact (SA) channel (STIM). The mapping catheter was advanced through the right femoral artery and retrograde across the aortic valve into the left ventricle. With each ventricular paced beat (V); there is retrograde conduction from the ventricle to atrium (A) via the left free wall accessory pathway. The mapping catheter has been manoeuvred to the site along the mitral annulus which records the earliest atrial activity (red arrow); the atrial activity recorded at the tip electrode of USER 1 precedes the earliest atrial activity (black arrow) noted in the coronary sinus (CS 1–2) by 25 msec

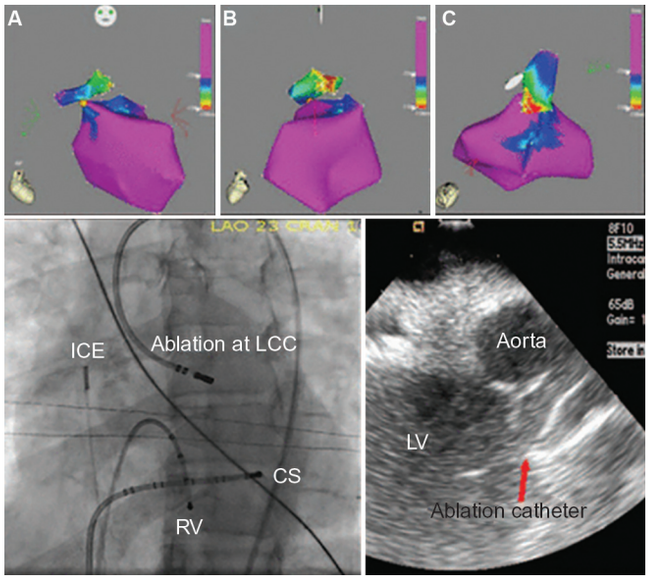

Fig. 11.47: Top, electroanatomic map (CARTO) showing the left ventricle relative to the site of earliest activation in the left coronary cusp (A) anterior-posterior view; (B) left lateral view; (C) superior view). Bottom left, fluoroscopic view of the successful ablation site. Bottom right, ICE image showing the ablation catheter at the site of successful ablation in the LCC. LV=left ventricle, ICE=intracardiac echocardiography catheter, RV=right ventricle, CS=coronary sinus catheter, and LCC=left coronary cusp

block. With cryoablation, heart block is generally reversible with prompt rewarming. However, cryoablation appears to be slightly less effective than radiofrequency as an energy source, especially for deep accessory pathways.

Success rates for curing atrial fibrillation with RFCA are highest (up to 87% in the 5 randomized trials reported through 2006) for paroxysmal atrial fibrillation in the absence of structural heart disease and lowest (50% or less) with persistent atrial fibrillation in the presence of structural heart disease and left atrial enlargement. Repeat procedures are typically needed in 25% or more of patients.

Success rates have historically been based on patient symptoms and periodic electrocardiographic monitoring. Success rates are lower if intensive ambulatory monitoring to detect asymptomatic atrial fibrillation recurrences is used, such as daily monitoring for a month with an auto-triggering event monitor. Some patients require the use of previously ineffective antiarrhythmic drugs to maintain success.

Ventricular Tachyarrhythmias

Idiopathic ventricular tachycardia (VT) is curable (success rate approximately 80%), assuming it is readily inducible during electrophysiology studies. The most common location for these VTs is the right ventricular outflow tract. Because these VTs are usually not reentrant in nature, a significant percentage are not inducible. Some cannot be

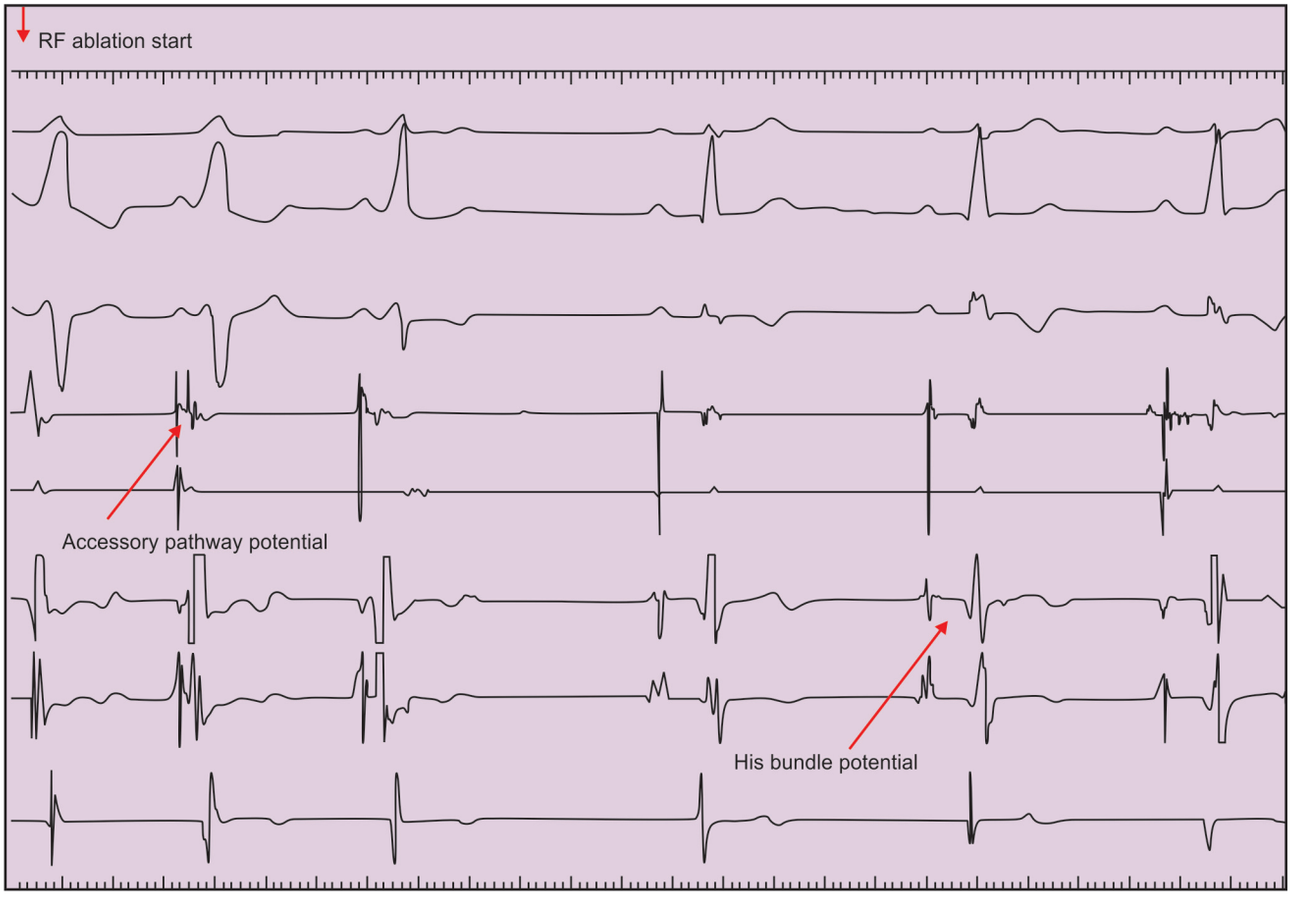

Fig. 11.48: Accessory pathway potential and local AV fusion at successful RF ablation site with loss of preexcitation and return of normal HV interval

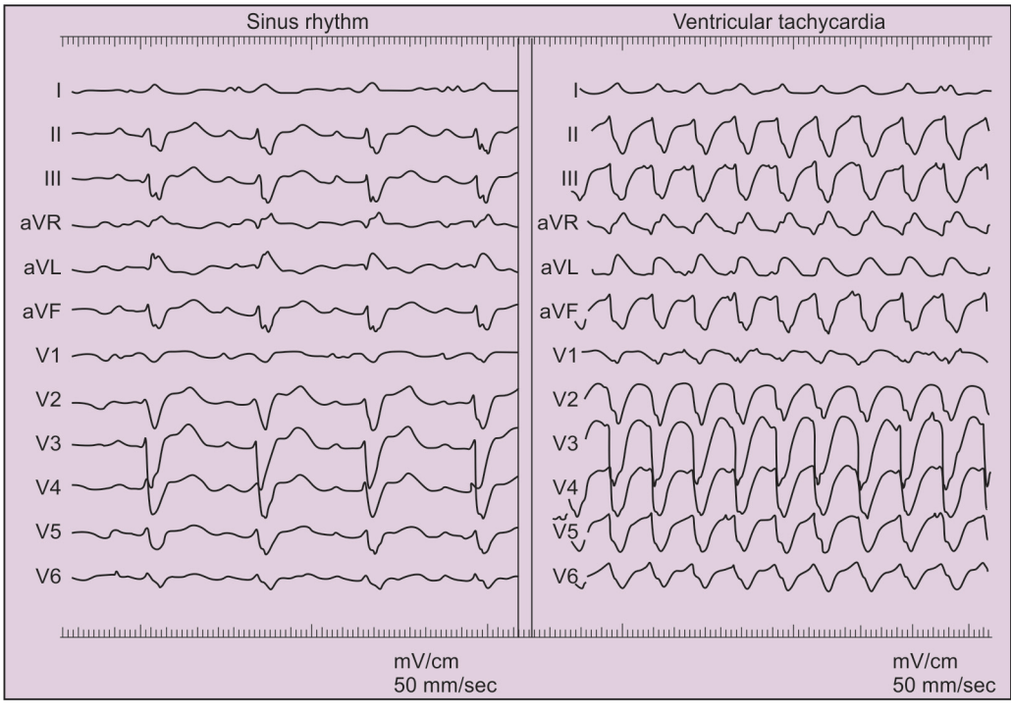

Fig. 11.49: Bundle branch reentrat tachcardia. Left panel—I2 lead ECG during sinus rhythm; there is a left bundle type intraventricular conduction delay. Right panel—I2 lead ECG during ventricular tachycardia; there is a remarkable similarity in QRS morphology during VT and sinus rhythm. The HV interval during sinus rhythm was 65 mse, suggesting underlying His-Purkinje conduction disease

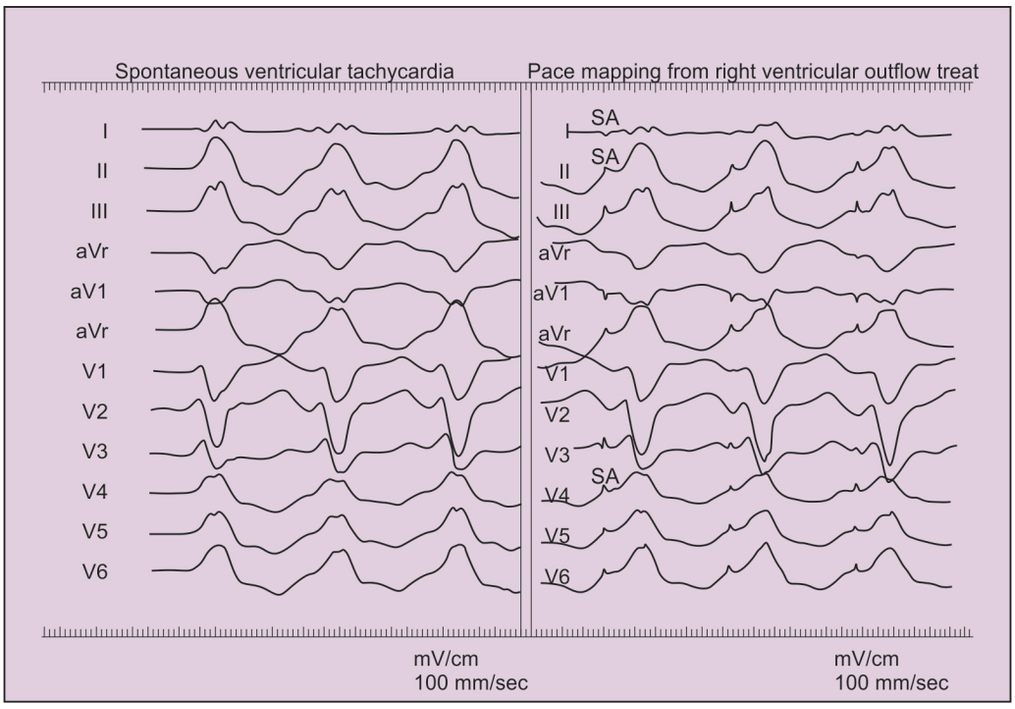

Fig. 11.50: Pace mapping of an idioipathic RVOT tachycardia. Left panel—I2 lead ECG of spontaneous ventricular tachycardia (VT) in a patient with a structurally normal heart. The VT has a left bundle branch block (LBBB) and an inferior axis morphology, suggesting that the origin is in the right ventricular outflow tract (RVOT). Right panel—A mapping catheter has been positioned in the RVOT and pacing is performed from its tip during sinus rhythm. The 'pace map' closely approximates the QRS morphology of the spontaneous VT in all I2 leads, suggesting that the mapping catheter is at or near the VT focus. SA=pacing stimulus artifact

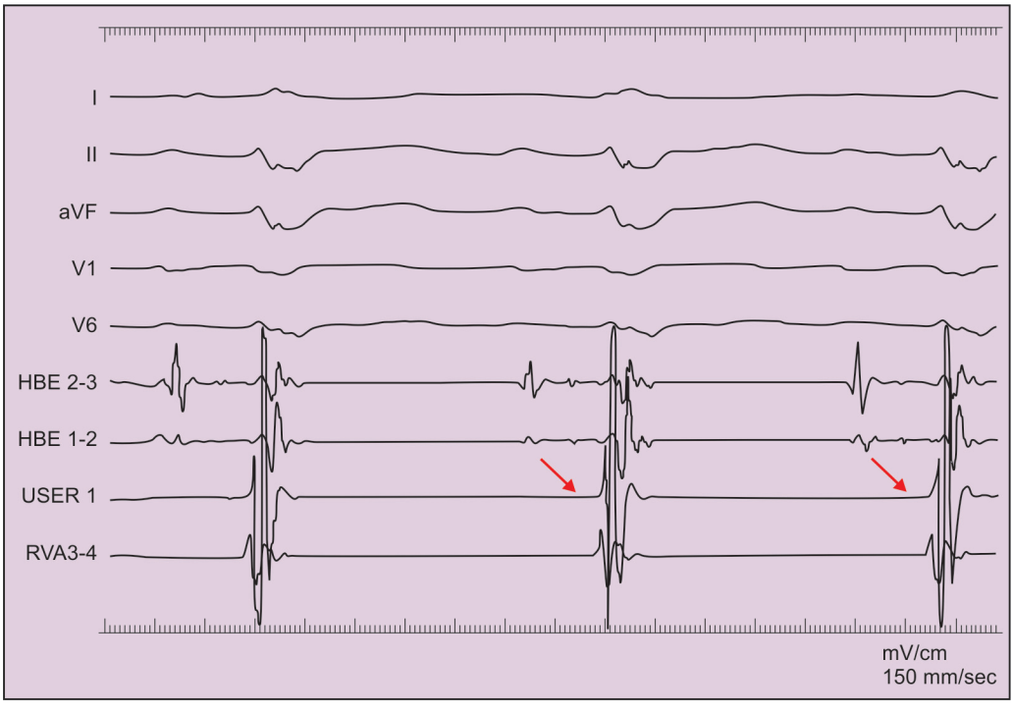

Fig. 11.51: Bundle branch reentrant ventricular tachcyardia. Five surface ECG leads (I, II, aVF, V1, V6) and intracardiac recordings from the His bundle region (HBE2–3, 1–2), the right ventricular apex (RVA3–4), and a mapping catheter (USER1) positioned distal to the His catheter along the RV septum to record a right bundle potential (arrow). The right bundle potential was recorded 30 ms after the His potential (HP). A=atrial electrogram, V=ventricular electrogram)

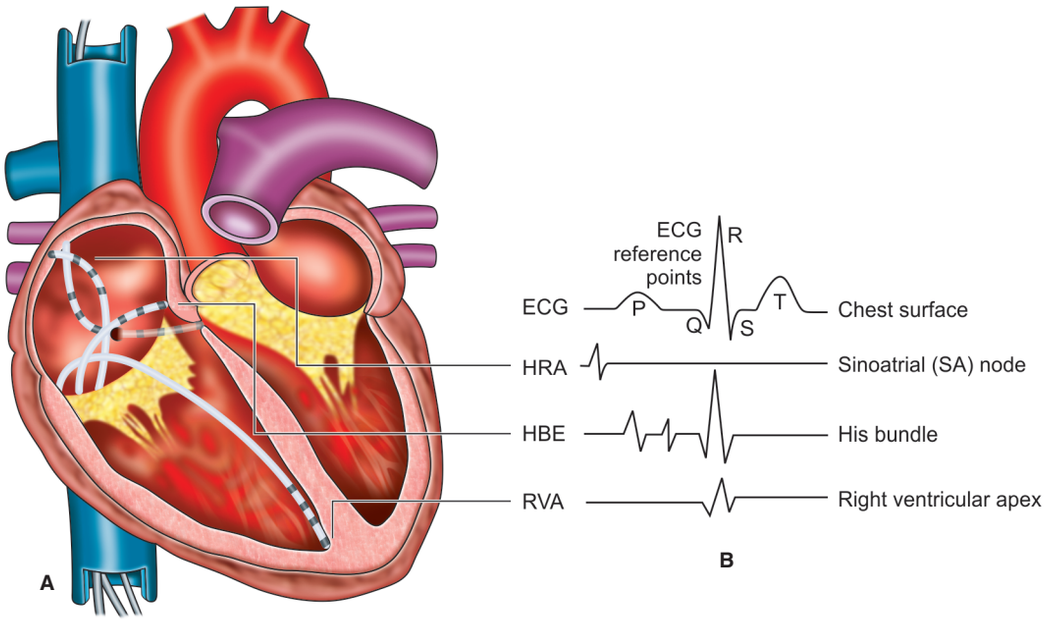

Fig. 11.52: (A) Different intracardiac conduction system from where electrograms are generated. (B) Schematic illustrations of several intracardiac electrograms contrasted with a conventional body-surface electrocardiogram (ECG)

ablated because of their deep septal or epicardial location. Some left ventricular VTs originate near a coronary cusp, which may preclude a successful ablation because of concern regarding coronary artery damage. Approximately half the cases of VTs associated with structural heart disease can be palliated by catheter ablation. Extensive scarring in these ventricles may limit the efficacy of the relatively small lesions made by RFCA, and multiple VT circuits may also contribute to this moderate success rate. Some form of 3-dimensional mapping is helpful for these complex ablations. In practice, many of these patients have ICDs, and catheter ablation is used as adjunctive therapy for frequent device activations.

Diagnostic Programmed Electrical Stimulation

Intracardiac electrogram recordings were measured first in the 1960s, and the methods of diagnostic programmed electrical cardiac stimulation were introduced in the 1970s. These procedures are safe when performed under the carefully controlled conditions of the electrophysiology (EP) laboratory. Typically, a number of catheters (wires) are placed in the heart under X-ray fluoroscopic guidance, and electrograms are recorded from various sites, most frequently the high right atrium, His bundle [i.e. atrioventricular (AV) junction], coronary sinus, and right ventricle (Figs 11.52. 11.53 and Table 11.2).

In addition to recording the electrograms from these sites, pacing the heart is also possible using an external stimulator. This setup provides the ability to assess the conduction properties of the heart, as well as the ability to induce and terminate cardiac arrhythmias using various pacing protocols. Analysis of the electrogram patterns and the patient's response to pacing interventions and drugs provides an accurate diagnosis of the mechanisms and

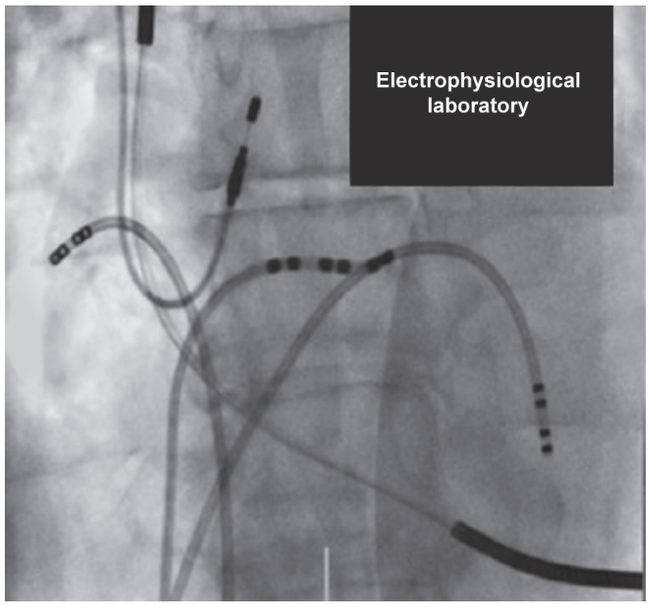

Fig. 11.53: An X-ray image showing three catheters introduced into the heart to record electrical signals and for circuit testing

Table 11.2: Diagnosis of different conduction abnormalities along the His bundle

Location	Character	Morphology
1. Supra-Hisian (above the HB)	1st° block 2nd° block 3rd° block	Normal QRS or narrow QRS
2. Intra-Hisian (inside)	–do–	Widening or Split His bundle potentials
3. Infra-Hisian (below HB)	–do–	Wide QRS

circuits for most arrhythmias. The introduction of radiofrequency catheter ablation in the 1980s provided the option for therapeutic interventions during the EP study. This has revolutionized the treatment of cardiac arrhythmias and has high success rates, particularly for reentrant supraventricular arrhythmias.

Indications for Programmed Electrical Stimulation

- Risk stratification (regarding ventricular arrhythmias) in patients with structural heart disease
- Risk assessment in patients with Wolff-Parkinson-White (WPW) syndrome
- Evaluation of patients with syncope
- Characterization of AV conduction
- Determining the mechanism of supraventricular tachycardia
- Assessment of efficacy of catheter ablation
- Determining the mechanism of a wide QRS complex tachycardia
- Determining the mechanism of ventricular tachycardia
- Determining the impact of pacing on initiation and termination of the tachycardia

Methods of Programmed Electrical Stimulation of the Heart

Types of pacing protocols are used during EP testing:

- Burst pacing or continuous pacing: The atrium or ventricle is paced at a faster fixed rate than the underlying sinus rate. For example, during measurement of sinus node function
- Decremental pacing is burst pacing but with a continuous increase in the pacing rate and hence a decrease in the cycle length (CL). For example, as in the measurement of the Wenckebach CL or the rate at which the AV node blocks a beat in conduction from the atrium to the ventricle
- *Extrastimuli:* Typically, 6–8 beats are delivered at a fixed rate (drive train), followed by 1–3 additional premature beats at a shorter CL or faster rate, for example, used particularly for induction of reentrant supraventricular or ventricular arrhythmias
- A standard electrophysiology protocol involves single premature atrial extrastimuli at two cycle lengths, and from 1 site, single, double, and triple ventricular premature extrastimuli from two right ventricular sites at two-cycle lengths. There are various ways to decrement atrial and ventricular premature extrastimuli during fixed rate pacing.
- Occasionally, isoproterenol or other drugs are given to help initiate a tachycardia.
- *Extrastimuli during tachycardias:* Premature atrial or ventricular beats may be introduced during tachycardia to help differentiate the circuit and mechanism of the arrhythmia. In addition, accelerating the rate of tachycardia by pacing at a faster rate with a catheter in or near the circuit is possible; this is called entrainment.
- *Pace termination:* Pacing at a faster rate (shorter CL) near the circuit can frequently terminate reentrant tachycardias

Note: A heart rate (HR) of 60 beats per minute (bpm) corresponds to a CL of 1000 milliseconds (1 second); thus, CL (in milliseconds) equals 60,000/HR.

Measurements during Electrophysiology Testing

Conduction Intervals

The AH interval is defined as the conduction time from the low right atrium through the AVN to the His bundle. It is measured on the His catheter electrogram. The normal range is 50–150 ms. The AH interval varies tremendously, depending on the patient's autonomic tone. The HV interval is defined as the time from the His bundle deflection to the earliest ventricular signal, measured in any intracardiac or surface recording. It represents the conduction time through the His-Purkinje system and is typically 35–55 milliseconds (Figs 11.54–11.62).

Sinus Node Assessment

The sinus node recovery time is measured by pacing the high right atrium at a rate faster than the sinus rate for up to 1 minute and then measuring the interval from the last

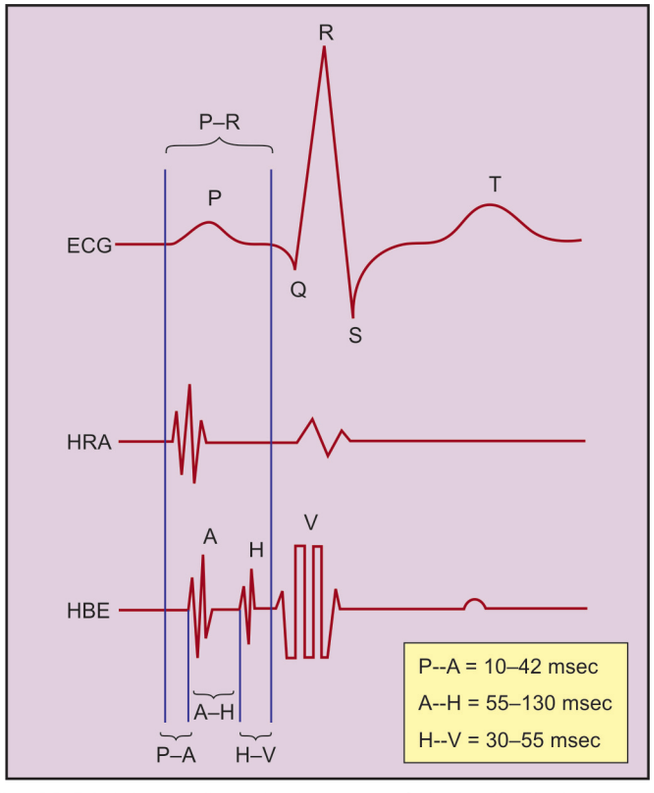

Fig. 11.54: Intracardiac electrograms. Schematic illustrations of several intracardiac electrograms contrasted with a conventional body-surface electrocardiogram (ECG). HRA=high right atrial electrogram; HBE=His bundle electrogram, in which A=low right atrial activity, H=His bundle activity, and V=ventricular septal activity; also shown are the P–R, P–A, A–H, and H–V intervals

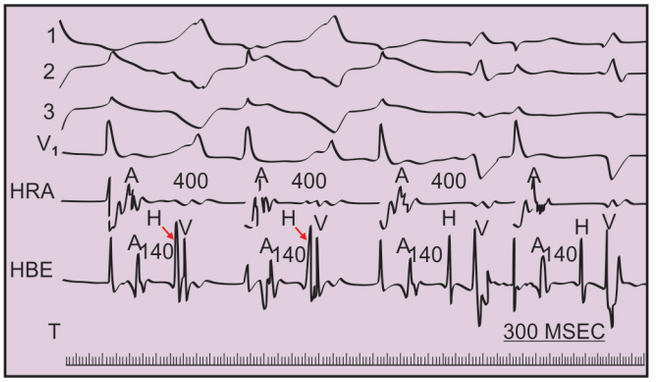

Fig. 11.55: Graph showing influence of atrial pacing on conduction over an AV bypass tract. In this electrophysiological study, the atrial are being paced at a cycle length of 400 msec. First two complexes show marked preexcitation with the antegrade His bundle potential (H) buried in the QRS complex. Constant AH intervals and normal QRS complex results when sudden block appears during pacing

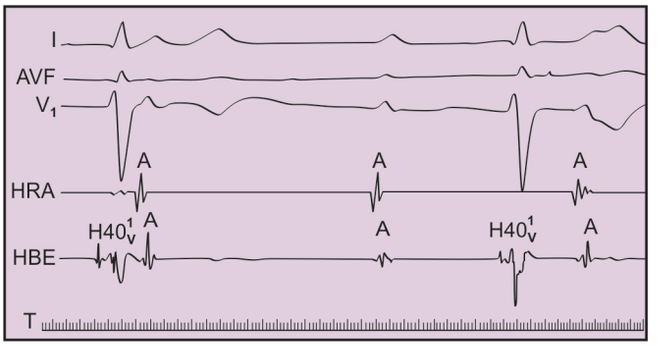

Fig. 11.56: Graph (upper panel) leads 1 aVF and V1 shows morphology of complete heart block in which there is no association of P-waves with QRS complex and all atrial impulses are unable to conduct due to block at AV junction. His bundle electrogram in this case reveals that each junctional escape QRS complex is preceded by a His bundle deflection (H) with a normal H–V interval (40 msec) in congenital complete heart block

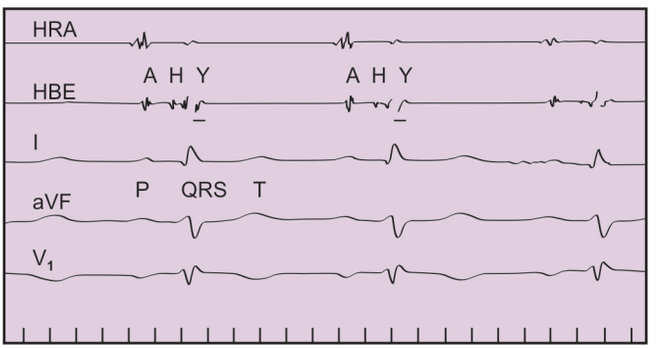

Fig. 11.57: Graph showing spontaneous rhythm with normal features of HBE with normal PA, AH and HV intervals. HRA=High right atrium, HBE=His bundle electrogram, 1, aVF and V1 are standard and precordial leads respectively

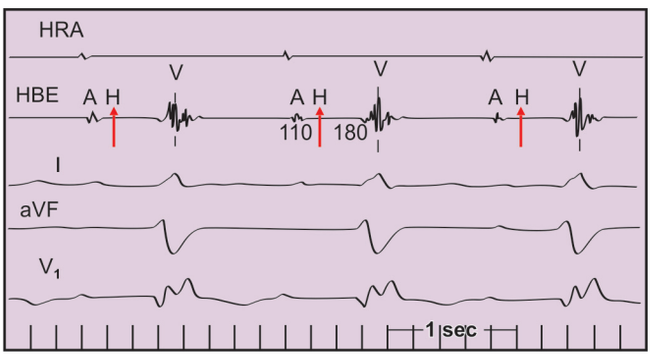

Fig. 11.58: Graph shows (HBE) marked prolongation of HV interval to 180 msec in a patient suffering from bifascicular block and prolonged P-R interval

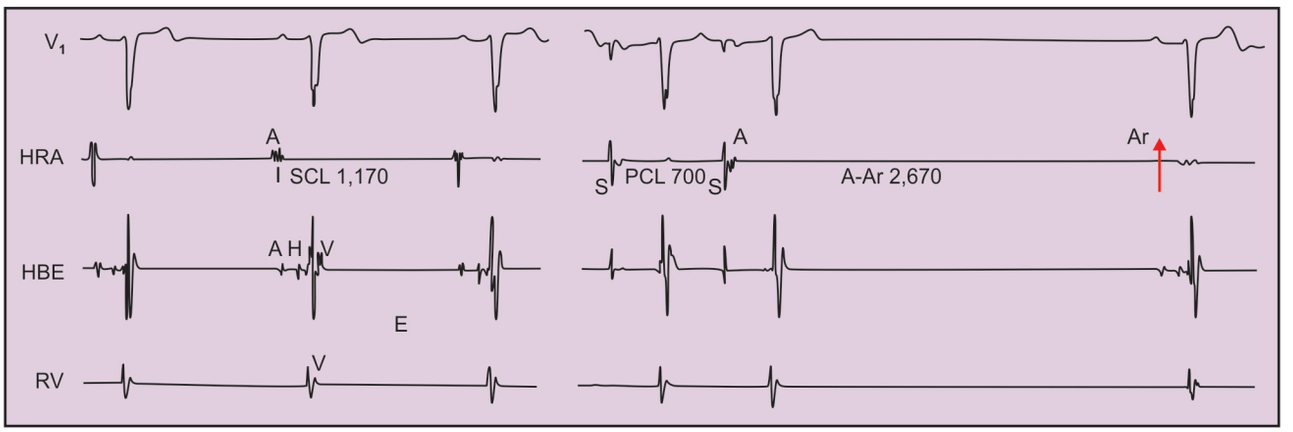

Fig. 11.59: Graph (upper panel) shows features of sinus bradycardia in sick sinus syndrome (V1), whereas, in HRA, there is marked delay in the sinoatrial conduction time (more than 2670 msc) with 700 pacing cycle length. His bundle electrogram shows normal HV

paced beat to the first sinus beat. The normal range is less than 1500 milliseconds. The corrected sinus node recovery time is the difference between the sinus node recovery time and the sinus cycle length; the normal value is < 550 ms. Patients with sick sinus syndrome have prolonged sinus node recovery times.

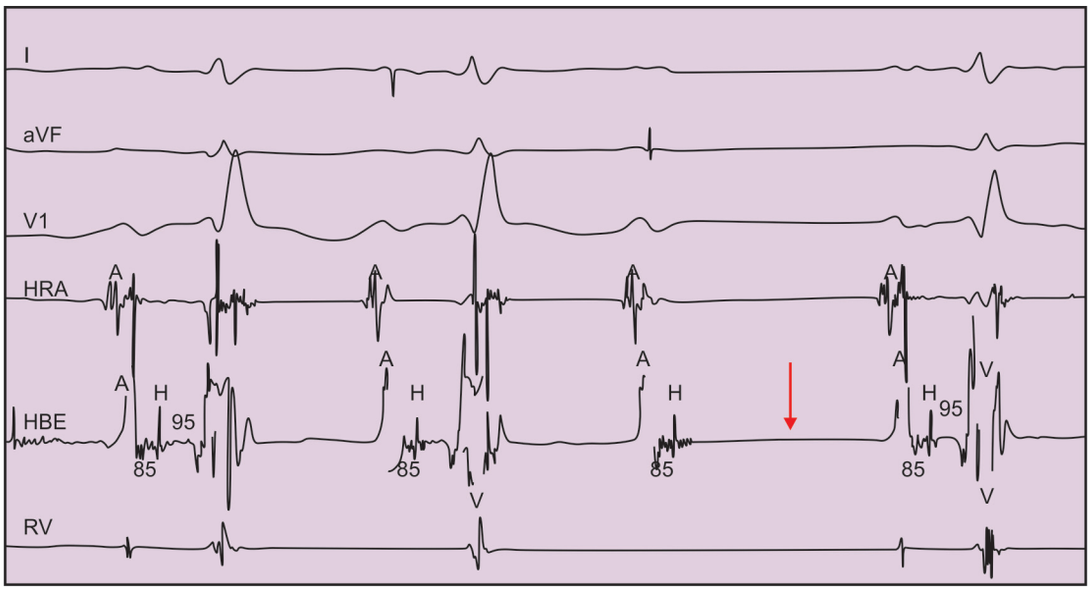

Fig. 11.60: Graph shows features of spontaneous type 11 second degree infra-Hisian block. Note that AH and HV intervals remain constant during conducted inpulses at 85 msec and 95 mec respectively. The third AH interval complex, however is suddenly and unexpectedly not followed by a ventricular depolarization. The complex followed by the blocked one revealed no change in the conduction intervals

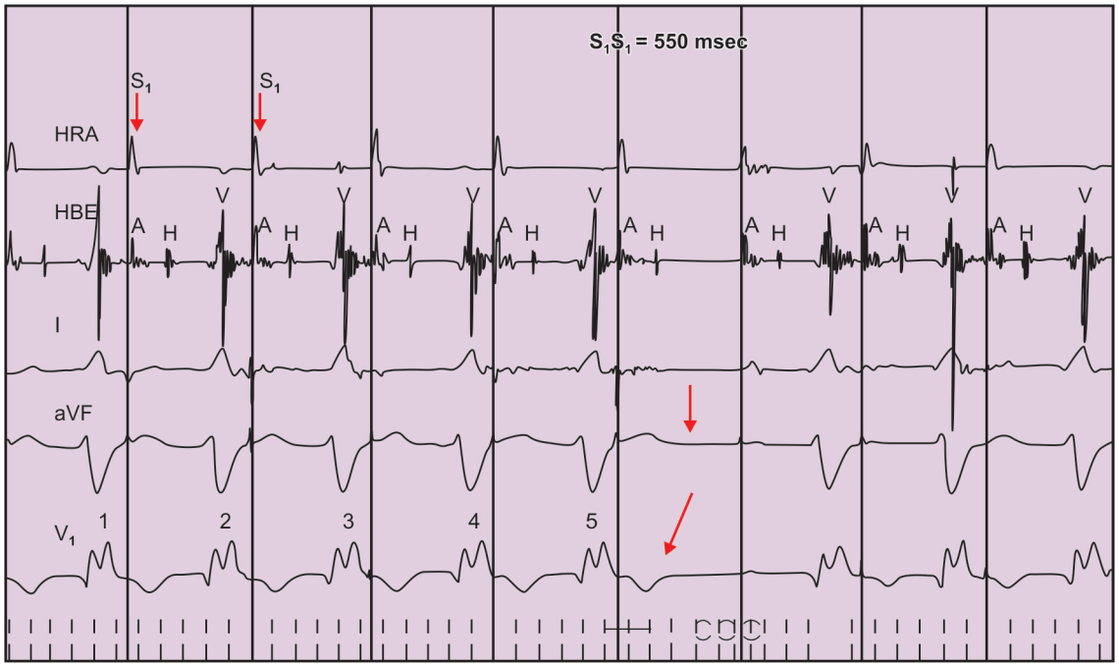

Fig. 11.61: Graph shows block distal to His bundle during atrial pacing Mobitz 11 second degree AV block is seen following 5th beat of atrial pacing at 550 msec (110 beats/min). There is absence of ventricular activity following His deflection in the 5th beat, clearly demonstrating Mobitz 11 AV block (second degree)

AV Node Assessment

The function of the AV node is to control the rate of impulse conduction from the atria to the ventricles. When the atrial rate increases above a certain rate (typically 150–200 bpm), the AV node initially causes AV block in a Wenckebach pattern and then generates higher degrees of block if the atrial rate increases further, thus controlling the ventricular rate and preserving cardiac output.

Two measurements of AV nodal function are as follows:

- Wenckebach CL uses decremental pacing to measure the lowest rate (longest CL) at which a dropped
- Ventricular beat occurs
- The AV nodal effective refractory period (ERP) is measured by introducing a single extrastimulus (S2)
- After a drive train of 8 stimuli at a fixed rate (all S1), at which time the S1–S2 interval is decreased until the S2

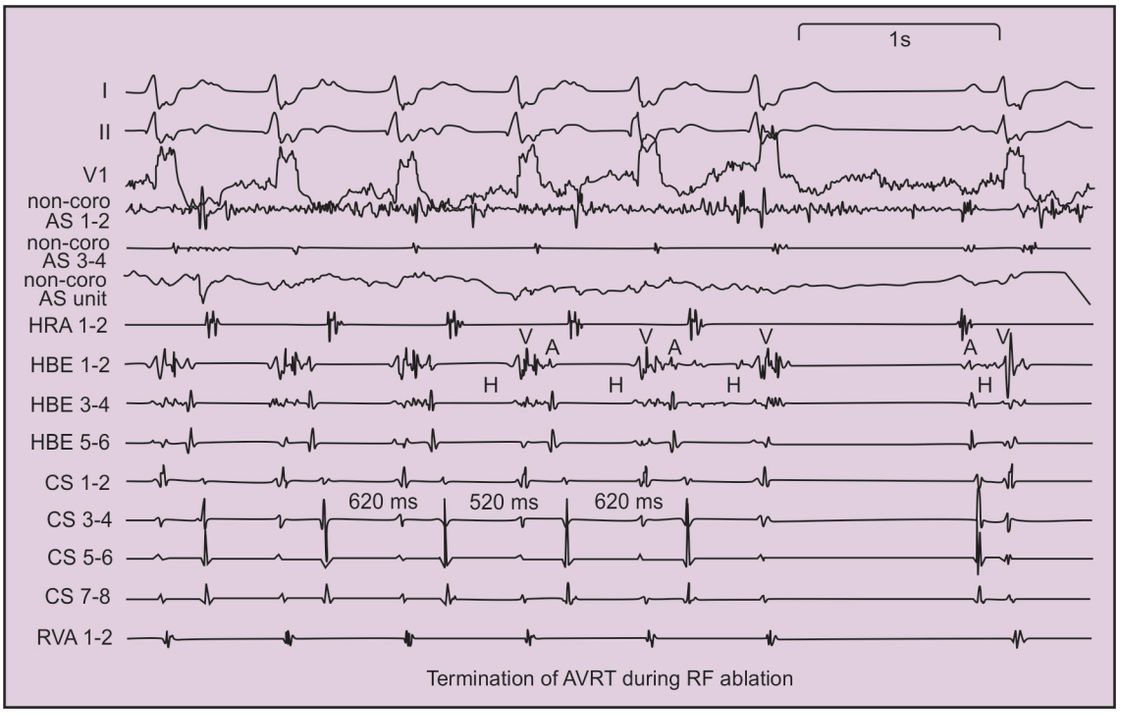

Fig. 11.62: Tracings are ECG leads I, II, V1, and intracardiac electrograms recorded from a mapping catheter in the noncoronary AS (non-coro AS1–2, non-coro AS3–4, and non-coro AS unit), a catheter in the HRA, a catheter at the region (HBE), a catheter within the CS, and a catheter at the RVA in a patient with an anteroseptal AP during RF ablation in the noncoronary AS. A single RF delivery at this site successfully resulted in tachycardia termination after 15s and ventriculoatrial dissociation

impulse does not conduct to the ventricle. This is noted on the electrogram where an atrial impulse does not result in a His bundle electrogram and subsequently no ventricular stimulation. This interval defines the AV nodal ERP

- Decremental pacing of the ventricle, as previously described for antegrade (A-V) conduction, assesses retrograde (V-A) conduction
- Extrastimulus pacing in the ventricle, in a method similar to that previously described for the AV node, measures ventricular refractory periods. The ventricular ERP is defined as the longest S1–S2 interval in which S2 fails to capture the ventricle.

His-Purkinje System Assessment

Conduction through the His-Purkinje system and determination of refractory period can provide important information regarding conduction system disease and a need for a permanent pacemaker. The latter is especially important if infra-Hisian block is observed.

Induction of Arrhythmias

Most arrhythmias encountered during EP testing are reentrant in nature and are therefore amenable to induction by the methods of extrastimuli. A reentrant arrhythmia requires a circuit with different limbs that have different refractory periods. When conduction blocks in one limb, the electrical impulse may travel down the other limb and then return (re-enter) via the limb that was blocked. For example, in typical AV nodal reentrant tachycardia (AVNRT), the impulse initially blocks in the fast pathway, conducts antegrade (A-V) over the slow pathway, and is then able to enter retrograde (V-A) over the fast pathway, which has recovered conduction. When the impulse continues to travel around this circuit, a reentrant arrhythmia is generated, yielding a supraventricular tachycardia. Other examples of reentrant tachycardias are:

1. AV reentrant tachycardia (AVRT), in which antegrade conduction over the AV node and retrograde conduction over a bypass tract occur.
2. Atrial flutter, which is a reentrant circuit, usually in the right atrium.
3. Scar-related ventricular tachycardia of coronary artery disease, in which the impulse travels through or around the area of scar tissue. A typical stimulation protocol for induction of reentrant arrhythmias uses a drive train of 8 paced beats (S1 beats) at a fixed CL (e.g. 500 milliseconds) with a premature beat (S2) added to the end of the drive train. The S2 stimulus is brought into atrial or ventricular refractoriness in intervals of 10 milliseconds. When S2 no longer captures, this defines the ERP of the tissue. A second extrastimulus, S3, is then added, with S2 set at a coupling interval 20 milliseconds above the ERP. The S2–S3 interval is also decremented until refractoriness is reached. If no arrhythmia is induced, the pacing sequences may be repeated using a third extrastimulus, i.e. S4. By convention, drive CLs (S1) of 500 and 400 milliseconds are used in ventricular pacing protocols. Arrhythmias with a reentrant mechanism are most often induced with this method. Another type of

pacing sequence is the continuous (or straight) burst pacing sequence, in which the atrium or ventricle is paced at a fixed rate (S1) for up to 10 seconds. In arrhythmias that have mechanisms other than reentry, this method is more likely to induce such triggered activityIn addition, burst pacing at a rate faster than the arrhythmia CL often terminates reentrant arrhythmias.

Termination of Arrhythmias

- Programmed stimulation can also be used to terminate reentrant cardiac arrhythmias. In ventricular tachycardia, pacing at a rate faster than the tachycardia rate (overdrive pacing) can capture part of the tissue in the circuit and render it refractory, thus terminating the tachycardia. This is used clinically in the methods of overdrive pacing or antitachycardia pacing used in implantable cardioverter-defibrillator (ICD) devices
- Overdrive pacing in the right atrium can terminate atrial flutter, and either atrial or ventricular pacing can terminate AVNRT and AVRT. Pacing methods are not successful in treatment of atrial or ventricular fibrillation because these arrhythmias comprise multiple small reentrant circuits or breakdown of spiral waves

Complications after Catheter Ablation

Radiation risk in catheter ablation is low, but it may exceed the risk from common radiologic procedures. The average risk for genetic defects has been computed at 1 case per million births. The average risk for fatal malignancies ranges from 0.3 to 2.3 deaths per 1000 cases for every 60 minutes of fluoroscopy. Many ablation procedures require less than 60 minutes of fluoroscopy. Major complications occur in approximately 3% of patients who have ablation procedures, including thromboembolism in less than 1% (higher in some atrial fibrillation ablation series) and death in 0.1–0.2% of all procedures. The incidence of cardiac complications varies, based on the site and type of ablation. Cardiac complications include the following:

- High-grade AV block
- Cardiac tamponade (highest in atrial fibrillation ablation, up to 6%)
- Coronary artery spasm/thrombosis
- Pericarditis
- Valve trauma
- Vascular complications, which occur in approximately 2–4% of procedures, include the following:
- Retroperitoneal bleeding
- Hematoma
- Vascular injury
- Transient ischemic attack/stroke
- Hypotension
- Thromboembolism or air embolism

Pulmonary complications include the following:

- Pulmonary hypertension with and without hemoptysis (secondary to pulmonary vein stenosis)
- Pneumothorax

Miscellaneous complications include the following:

1. Left atrial esophageal fistula
2. Acute pyloric spasm/gastric hypomotility
3. Phrenic nerve paralysis
4. Radiation or electrically induced skin damage
5. Infection at access site
6. Inappropriate sinus tachycardia
7. Proarrhythmia

LONG-TERM MONITORING

Some physicians empirically treat patients with 4–12 weeks of aspirin therapy to possibly reduce the risk of thromboembolic sequelae. Echocardiography is not routinely performed unless a complication may have occurred (e.g. pericardial effusion). Postprocedure electrophysiologic testing is not performed routinely unless recurrent tachyarrhythmias are suspected.

SURGICAL INTERVENTIONS IN THE MANAGEMENT OF CARDIAC ARRHYTHMIAS

Maze Procedure (Surgical Ablation)

The surgical ablation maze procedure, or Cox-Maze IV, evolved from the Cox-Maze III cut-and-sew procedure (Fig. 11.63). Instead of using incisions, a surgical ablation

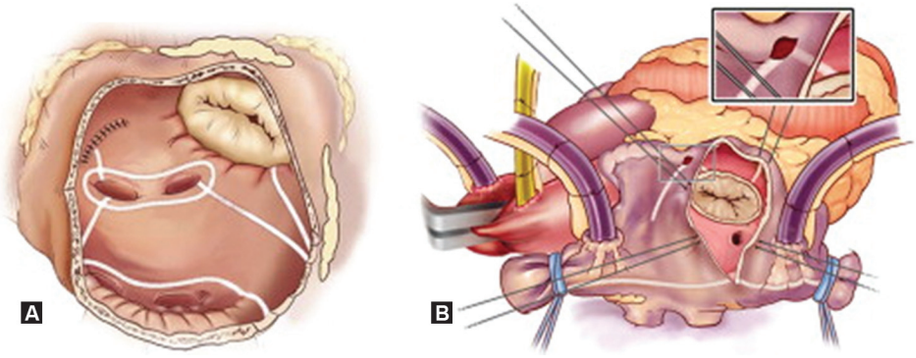

Fig. 11.63: Biatrial Cox-Maze IV lesion set. (A) Left atrial lesions. (B) Right atrial lesions. Irrigated radiofrequency ablation for treatment of AF during cardiac surgery was associated with a low complication rate. No device-related complications occurred. The Cox-Maze lesion set was effective at restoring sinus rhythm and had higher success rates in patients with smaller left atrial diameters and longer ablation times

energy source is used to create a conduction block of scar tissue to stop the errant electrical signals. The surgical ablation version of the maze procedure is much faster than Cox-Maze III and is considered very effective As an open-chest procedure, it is usually performed on patients needing open-heart surgery for other issues, such as valve replacement or repair or coronary artery bypass (CABG). This is called 'concomitant surgery,' meaning that it's done along with another procedure. It is performed on either a stopped or a beating heart.

Maze Surgical Ablation (Open Chest)

While this open-chest maze surgery is sometimes done as a standalone procedure on patients with atrial fibrillation only, more often these afib-only cases are handled by the closed chest mini maze procedure.

Maze Procedure Success Rates

The open-chest maze procedures done by surgical ablation have been found to have similar success rates to Cox-Maze III procedures, including those utilizing a variety of surgical ablation energy sources. Many centers doing this maze surgery also cite freedom from stroke in excess of 99%.

Mini Maze Procedure Risks

The blood clots and strokes that are occassional complications with catheter ablation are rarely found in the mini maze procedure as no catheters are involved. And since the surgeon uses a thoracoscope to see the heart directly, there may be less risk of obstructing the pulmonary veins (pulmonary vein stenosis).

However, any procedure dealing with the heart has risks. While we rarely see any of the following, the risks of a mini maze procedure do include:

- Collapsed lung from deflating the lung in surgery, which is correctable with a chest tube
- Vein inflammation (phlebitis)
- Heart tissue inflammation (pericarditis)
- Blood vessel or heart damage
- Death

In most studies reviewed, there are minimal complications, though in one study there was one death very early on due to tearing of the left atrial appendage. Research has also shown that there is some risk of blood clots and a stroke following surgery.

Abnormal Heart Rhythms and Implantable Cardioverter Defibrillators

Treatment for abnormal heart rhythms is possible with an implantable cardioverter defibrillators (ICD), or implantable cardioverter defibrillator. An ICD is an electronic device that constantly monitors your heart rate and rhythm. When it detects a very fast, abnormal heart rhythm, it delivers energy to the heart muscle. This causes the heart to beat in a normal rhythm again (Fig. 11.64).

The ICD has two parts—the lead(s) and a pulse generator. The lead(s) monitor the heart rhythm and deliver

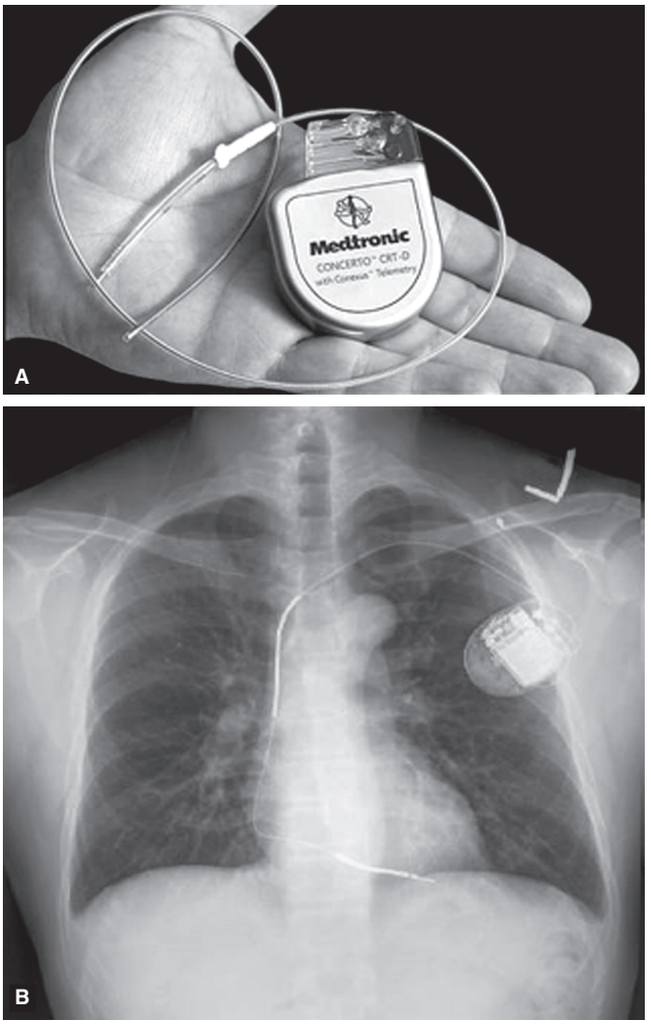

Fig. 11.64: (A) An implantable cardioverter-defibrillator (ICD). (B) Chest X-ray showing an implantable cardioverter-defibrillator (ICD), with its battery fixed at left subclavicular region and is connected with a wire placed in the trabecular part of the right ventricular apex

energy used for pacing and/or defibrillation (see below for definitions). The generator houses the battery and a tiny computer. Energy is stored in the battery until it is needed. The computer receives information from the leads to determine how well the heart is beating.

Types of ICDs, including:

- Single chamber ICD: A lead is attached in the right ventricle. If needed, energy is delivered to the ventricle to help it contract normally.
- Dual chamber ICD: Leads are attached in the right atrium and the right ventricle. Energy is delivered first to the right atrium and then to the right ventricle, helping your heart to beat in a normal sequence.
- Biventricular ICD: Leads are attached in the right atrium, the right ventricle and the left ventricle. This technique helps the heart beat in a more balanced way and is specifically used for patients with heart failure.

Your doctor will determine which type of ICD is best for you.

How does an ICD Work?

The ICD monitors the heart rhythm, identifies abnormal heart rhythms, and determines the appropriate therapy to return your heartbeat to a normal rhythm. Your doctor programs the ICD to include one or all of the following functions:

- Anti-tachycardia Pacing (ATP): When the heart beats too fast, a series of small electrical impulses are delivered to the heart muscle to restore a normal heart rate and rhythm.
- Cardioversion: A low energy shock is delivered at the same time as your heartbeat to restore a normal heart rhythm.
- Defibrillation: When the heart is beating dangerously fast, a high-energy shock is delivered to the heart muscle to restore a normal rhythm.
- Bradycardia pacing: When the heart beats too slow, small electrical impulses stimulate the heart muscle to maintain a suitable heart rate.

Who is a Candidate for an ICD?

- People who have had an episode of sudden cardiac arrest or ventricular fibrillation.
- People who have had a heart attack and are at high risk for sudden cardiac arrest.
- People who have hypertrophic cardiomyopathy and are at high risk for sudden arrest.
- People who have had at least one episode of ventricular tachycardia, an abnormal heart rhythm.

BIBLIOGRAPHY

1. Blomström-Lundqvist C, Scheinman MM, Aliot EM, et al. For the European Society of Cardiology Committee, NASPE-Heart Rhythm Society. ACC/AHA/ESC guidelines for the management of patients with supraventricular arrhythmias-executive summary. J Am Coll Cardiol 2003;42(8):1493–1531.
2. Calkins H, Canby R, Weiss R, et al. For the 100W Atakr II Investigator Group. Results of catheter ablation of typical atrial flutter. Am J Cardiol 2004;94(4):437–42.
3. Calkins H, Langberg J, Sousa J, et al. Radiofrequency catheter ablation of accessory atrioventricular connections in 250 patients. Abbreviated therapeutic approach to Wolff-Parkinson-White syndrome. Circulation 1992;85(4):1337–46.
4. Calkins H, Sousa J, el-Atassi R, et al. Diagnosis and cure of the Wolff-Parkinson-White syndrome or paroxysmal supraventricular tachycardias during a single electrophysiologic test. N Engl J Med 1991;324(23):1612–18.
5. Calkins H, Yong P, Miller JM, et al. For the Atakr Multicenter Investigators Group. Catheter ablation of accessory pathways, atrioventricular nodal reentrant tachycardia, and the atrioventricular junction: Final results of a prospective, multicenter clinical trial. Circulation 1999;99(2):262–70.
6. Chen SA, Chiang CE, Wu TJ, et al. Radiofrequency catheter ablation of common atrial flutter: comparison of electrophysio-logically guided focal ablation technique and linear ablation technique. J Am Coll Cardiol 1996;27(4):860–8.
7. Hindricks G. The multicentre European radiofrequency survey (MERFS): Complications of radiofrequency catheter ablation of arrhythmias. The Multicentre European Radiofrequency Survey (MERFS) Investigators of The Working Group on Arrhythmias of the European Society of Cardiology. Eur Heart J 1993;14(12):1644–53.
8. Jackman WM, Wang XZ, Friday KJ, et al. Catheter ablation of accessory atrioventricular pathways (Wolff-Parkinson-White syndrome) by radio-frequency current. N Engl J Med 1991;324(23):1605–11.
9. Kottkamp H, Hügl B, Krauss B, et al. Electromagnetic versus fluoroscopic mapping of the inferior isthmus for ablation of typical atrial flutter: A prospective randomized study. Circulation 2000;102(17):2082–6.
10. Kuck KH, Schlüter M, Geiger M, Siebels J, Duckeck W. Radio-frequency current catheter ablation of accessory atrioventri-cular pathways. Lancet 1991;337(8757):1557–61.
11. Langberg JJ, Leon A, Borganelli M, et al. A randomized, prospective comparison of anterior and posterior approaches to radiofrequency catheter ablation of atrioventricular nodal reentry tachycardia. Circulation 1993;87(5):1551–6.
12. Lesh MD, Van Hare GF, Scheinman MM, Ports TA, Epstein LA. Comparison of the retrograde and transseptal methods for ablation of left free wall accessory pathways. J Am Coll Cardiol 1993;22(2):542–9.
13. Man KC, Knight B, Tse HF, et al. Radiofrequency catheter ablation of inappropriate sinus tachycardia guided by activation mapping. J Am Coll Cardiol 2000;35(2):451–7.
14. Paydak H, Kall JG, Burke MC, et al. Atrial fibrillation after radiofrequency ablation of type I atrial flutter: time to onset, determinants, and clinical course. Circulation 1998;98(4): 315–22.
15. Pérez FJ, Schubert CM, Parvez B, Pathak V, Ellenbogen KA, Wood MA. Long-term outcomes after catheter ablation of cavotricuspid isthmus dependent atrial flutter: a meta-analysis. Circ Arrhythmia Electrophysiol 2009;2(4):393–401.
16. Scheinman M, Calkins H, Gillette P, et al. North American Society of Pacing and Electrophysiology. NASPE policy statement on catheter ablation: personnel, policy, procedures, and therapeutic recommendations. Pacing Clin Electrophysiol 2003;26(3):789–99.
17. Scheinman MM. NASPE survey on catheter ablation. Pacing Clin Electrophysiol 1995;18(8):1474–8.
18. Tsai CF, Tai CT, Yu WC, et al. Is 8-mm more effective than 4-mm tip electrode catheter for ablation of typical atrial flutter? Circulation 1999;100(7):768–71.
19. Walsh EP, Saul JP, Hulse JE, et al. Transcatheter ablation of ectopic atrial tachycardia in young patients using radiofrequency current. Circulation 1992;86(4):1138–46.
20. Willems S, Weiss C, Ventura R, et al. Catheter ablation of atrial flutter guided by electroanatomic mapping (CARTO): a randomized comparison to the conventional approach. J Cardiovasc Electrophysiol 2000;11(11):1223–30.

12 Recognition and Management of Infective Endocarditis

In the century and a quarter since William Osler delivered his famed lectures on endocarditis, substantial advancements have occurred in the understanding and treatment of this disease.

Streptococcus viridans is the most common microbial agent responsible for infective endocarditis in children and adults. However, currently, staphylococcal aureus endocarditis is emerging as one of the leading causes of acute infective endocarditis particularily among those patients who are found to be malnourished and have congenital or acquired type of hypogammaglobulinemia with or without associated heart ailment. Despite the decline in rheumatic heart disease world wide and the use of antibiotic prophylaxis, there is no evidence that the incidence of infective endocarditis is decreasing. In fact, some data suggest it may be increasing. Several factors explain this apparent paradox (Fig. 12.1).

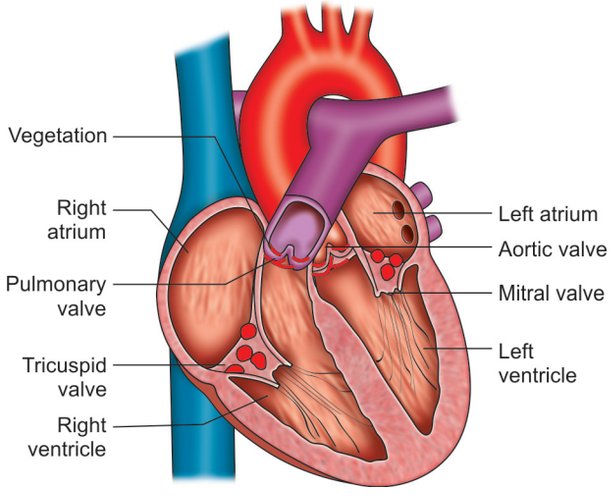

Fig. 12.1: This cross-sectional view shows vegetations (accumulations of bacteria and blood clots) on the four valves of the heart

- **First**, in industrialized nations, patients are living longer; this results in a higher prevalence of degenerative cardiac disease, which can serve as a nidus for endocardial infection.
- **Second** there is an increase in nosocomial infections. which are often caused by species of bacteria or yeasts associated with infective endocarditis.
- **Third** intravenous drug use has increased in industrialized societies.
- **Fourth** increasing application of cardiac surgery has provided new substrates for endocardial infection.
- **Fifth** the increased use of indwelling intravascular lines and implantable devices has resulted in many more catheter-related infections, bacteremias, and device-related infections.
- **Finally** the increased application of echocardiography has probably increased the rate at which infective endocarditis is diagnosed.

These factors have also increased the variety of ways infective endocarditis can present. The classical fever of unknown origin presentation represents a minority of infective endocarditis cases today. Thus, clinicians need to be vigilant about keeping infective endocarditis in mind with some of these more unusual presentations. Gram-negative and fungal endocarditis occur most often followig cardiac surgery or in debilitated patients. A wide variety of organisms have been implicated in the causation of infective endocarditis. Cardiac malformation is the major factor predisposing to infective endocarditis. With the better survival rate in congenital heart disease, the incidence in this group has shown rather on the increase; whereas with rheumatic heart disease it had shown upward trend in developing countries and concomitant decrease in developed countries of the world. Cardiac defects which are more prone to this infection are tetralogy of Fallot, VSD with aortic regurgitation or obstruction, MVP with MR and those with prosthetic valve. The patients who had under-

Table 12.1: The organisms responsible for IE

Staphylococcus aureus	The most common cause of IE overall (acute and subacute); most common with prosthetic valves, acute IE and IE related to intravenous drug abuse. High mortality rate. Coagulase-negative *S. aureus* causes subacute disease similar to *Streptococcus viridans*. Accounts for 30% of IE associated with prosthetic valves.
Streptococci	***S. viridans:*** 50–60% of subacute IE cases.
	Group D streptococci: Usually subacute and the third most common cause of IE.
Streptococcus intermedius	Acute and subacute infection. Causes 15% of all cases of IE.
Group A, C and G streptococci	Acute IE is similar to that with *S. aureus*. High mortality (up to 70%).
Group B streptococci	Acute disease, high mortality often requiring valve replacement. Occurs in pregnancy and the elderly particularly.
Pseudomonas aeruginosa	Usually acute IE and requires surgery for cure. **HACEK organisms (*H*aemophilus** spp., ***A**ggregatibacter actinomycetemcomitans*, ***C**ardiobacterium* spp., ***E**ikenella corrodens*, ***K**ingella kingae*) usually subacute disease and about 5% of all IE.
Fungi	Cause subacute disease.
Enterococci	

gone recent cardiac surgery are also more prone to infective endocarditis.

Pathogenesis

Infective endocarditis is a disease caused by microbial infection of the endothelial lining of the heart. The characteristic lesion is a vegetation,which usually develops on a heart valve. In the pathogenesis of infectious endocarditis, local turbulence is believed to promote a sterile network of fibrin and platelets on the endocardial surface, which is colonized later by microorganisms entering the bloodstream from a distant site (Tables 12.1 and 12.2).

The infecting microorganisms are protected by the microthrombus from normal host defense mechanisms and from antibiotic penetration, requiring high dose parenteral antimicrobial agents over a long period.Whether the result of colonization of previously damaged heart endothelium or de novo infection of healthy tissues, the lesion is a vegetation whose primary features are a heavy colonization of microorganisms, a stroma consisting primarily of fibrin and a relative paucity of leukocytes. Once established, the vegetations have a tendency to enlarge with further deposition of fibrin and multiplication of the infecting organisms. The fibrin acts as a barrier to leukocytes; yet it permitis diffusion of essential nutrients from the blood.

Table 12.2: Localization of organisms according to the condition and site of origin

Condition	Location of stream
Coarctation	Downstream wall
Patent ductus arterosus	Pulmonary artery
A-V fistula	Veins
Aortic insufficiency	Ventricular surface of valves
Mitral insufficiency	Atrial surface of mitral valve
Pulmonary insufficiency	Ventricular surface of pulmonary valve
Tricuspid insufficiency	Atrial surface of tricuspid valve

The high density of infecting organisms and the difficulty for leukocytes to penetrate the nidus of infection partially explains the necessity of prolonged antimicrobials of primarily nature.

Its cure usually requires surgical excision of the infected vegetations and valve replacement. Infective endocarditis represents an endothelial infection that usually occurs at sites of endothelial damage, with the superimposed thrombus serving as the nidus. For the nidus to become infected, bacteria must enter the blood stream in sufficient numbers from a break in the epidermal or mucosal surfaces of the body. As the vegetation grows, regurgitation of the affected valve almost always occurs due to destruction, scarring, and retraction of the leaflet Occasionally, chordal involvement results in rupture, causing sudden severe atrioventricular valve regurgitation. Very large vegetations rarely can obstruct the valve orifice. Embolization of vegetations can result in damage to other organs from ischemia or remote infection. Invasion of the valve annulus by the organisms can lead to abscesses and fistulas. Infection of arterial walls due to vegetation embolization would lead to aneurysm formation and rupture, which can be devastating in the central nervous system.

Incidence: Osler's portentous words are as relevant now as when originally published. Despite improved preventive strategies, rational antibiotic prescribing, advances in imaging, and increasing use of early life saving cardiac surgery, the incidence of infective endocarditis remains high at 1.7–6.2 per 100,000 person years in the USA and Europe, with a one year mortality approaching 40%. The classical patient with infective endocarditis described in textbooks no longer represents the majority of cases in practice. The emergence of staphylococcal infection, often associated with indwelling devices, co-existent medical conditions and resistant to conventional antibiotic regimes, a variety of other atypical organisms, and the persistent syndrome of culture negative endocarditis make diagnosis and treatment as great a challenge as ever.

Diagnostic criteria (Table 12.3) The original von Reyn diagnostic criteria for infective endocarditis, based upon clinical and microbiological features, have now been surpassed by the Duke criteria which emphasise the role of echocardiography, the key imaging tool for both diagnosis and assessment of prognosis. Many studies have now demonstrated the superiority of the Duke criteria and a recent scientific statement of the American Heart Association concluded that they should be adopted as the primary diagnostic schema in the clinical evaluation of patients in whom infective endocarditis is suspected. Nevertheless, clear deficiencies remain.

Major criteria: Two positive blood cultures with atypical microbe, new murmur or echocardiogram finding of oscillating mass, abscess, or prosthetic valve dehiscence.

Minor criteria: Predisposing cardiac condition or IV drug use, fever >38°C, vascular phenomena, such as Osler's nodes, Janeway lesions. Immunologic phenomena, such as splenomegaly, echocardiogram consistent with endocarditis, but not meeting major criteria.

Positive blood culture, but not meeting major criteria, or positive serology for a combatable microbe.

Definite diagnosis: Positive histology or positive culture from vegetation. Two major criteria, one major and three minor criteria—all six minor criteria.

Diagnosis rejected: Alternative diagnosis established, resolution of illness after 4–5 days of antibiotics.

Possible diagnosis neither definite nor rejected.

Clinical Presentation

Symptoms and signs: Malaise, weight loss, fatigue, night sweats, fever, chills, arthralgias, myalgias. Specific symptoms due to sites of damge, such as dyspnea with heart failure due to severe valvular regurgitation.

Physical Examination (Fig. 12.2)

- Osler's node, Janeway lesion, petechiae, and splinter
- Hemorrhages, Roth spots, and blue toe syndrome
- Fever
- Regurgitant heart murmurs, especially new or Worsemng
- Signs of heart failure
- Signs of stroke
- Splenomegaly



Fig. 12.2: Doctor is physically examining a patient with infective endocarditis

Table 12.3: Duke criteria for the diagnosis of infective endocarditis

Major criteria	1. Positive blood cultures (>2) with microbe typical for infective endocarditis, or persistently positive blood cultures with compatible microbe 2. Evidence of endocardial involvement: new regurgitant murmur or positive echocardiogram for oscillating mass, abscess, or prosthetic valve dehiscence
Minor criteria	1. Predisposing cardiac condition or intravenous drug use 2. Fever >38.0°C (100.4°F) 3. Vascular phenomena 4. Immunologic phenomena 5. Echocardiogram consistent with endocarditis, but not meeting major criteria 6. Positive blood culture, but not meeting major criteria, or positive serology or molecular test for compatible microbe
Diagnosis	
Definite endocarditis	1. Positive histology, or positive culture from vegetation, or 2. Two major criteria, or 3. One major and three minor criteria, or 4. Five minor criteria
Rejected	1. Firm alternative diagnosis established 2. Resolution after <4 days of antibiotic treatment
	Possible endocarditis (neither definite nor rejected)

Osler's or Austrian triad? Osler's or Austrian triad consists of endocarditis, pneumonia, and meningitis. The most common organism is *Streptococcus pneumoniae*, which is especially prevalent in alcoholic (40%), elderly, and diabetic patients. The course is fulminant, with rapid valve de struction and abscess formation. The aortic valve is most often, followed by the tricuspid valve. Infection is usually responsive to penicillin, but resistant strains that require vancomycin are becoming more common.

Four peripheral stigmata of IE (Figs 12.3–12.6)

1. Splinter hemorrhages (Fig. 12.3)
2. Janeway lesions (Figs 12.4 and 12.5)
3. Roth's spots
4. Osler's nodes

Differential Diagnosis

- Fever due to other causes
- Sepsis not due to infective endocarditis

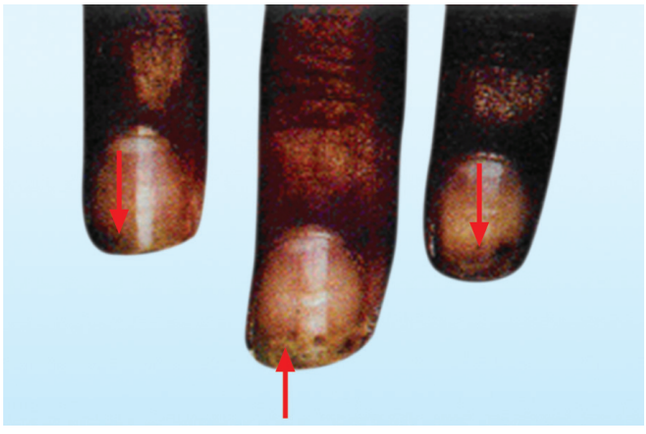

Fig. 12.3: Suhungual or splinter hemorrahage in patient with infective endocarditis

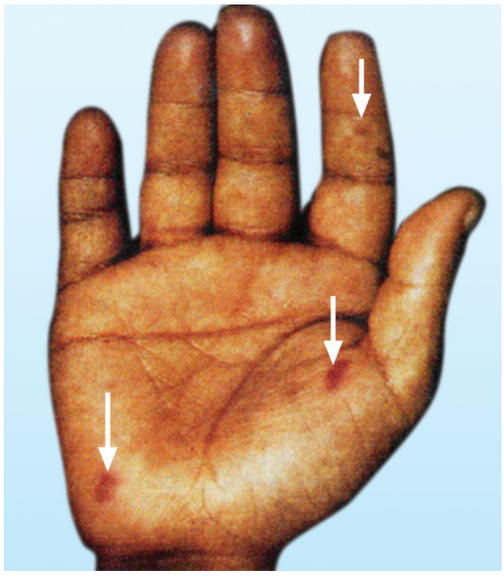

Fig. 12.4: Janeway lesions on the palm in the same patient

- Valvular lesions on echocardiography that resemble vegetations (e.g. myxomatous valves)

Laboratory Tests

- Blood cultures: Three from separate venipunctures over 24 hours
- Serologic testing for organisms such as Histoplasma, Q fever, Brucella
- Rheumatoid factor may be falsely positive
- Leukocytosis, elevated gamma globulins, elevated erythrocyte sedimentation rate, anemia

Laboratory Approach for Blood Sample Study

Optimal antiseptic skin preparation is important and at least 10 ml of blood (less in children) should be obtained for each culture. Bacteraemia is usually continuous and there is no rationale for timing blood cultures to coincide with peaks of pyrexia. If there is a history of prior antibiotic treatment, maximum diagnostic yield may be achieved by diluting the culture broth and considering the use of sodium polyanetholsulfonate or a dedicated adsorbent resin, both of which inactivate antimicrobial effects. Multiple separate blood cultures are required and most guidelines recommend at least two, and most usually three

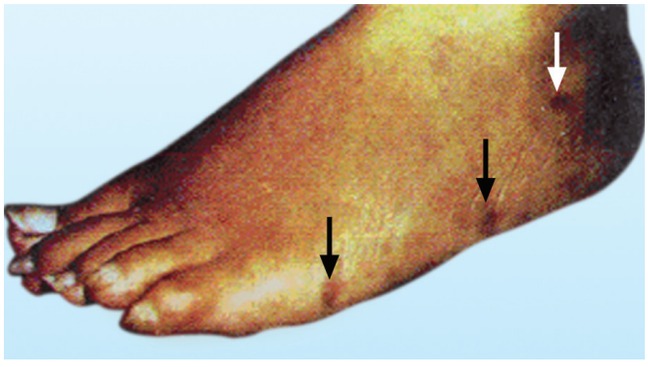

Fig. 12.5: Janeway lesions on the foot of the same patient



Fig. 12.6: Clubbing of fingers in infective endocarditis

sets. Although endocarditis caused by anaerobes is uncommon, blood cultures should be incubated in both aerobic and anaerobic atmospheres to detect organisms such as Bacteroides or Clostridium species. If all blood cultures remain negative at 5 days but infective endocarditis remains likely on clinical grounds, subculture onto chocolate agar plates may allow identification of an atypical organism, although prolonged culture for up to 2–3 weeks is associated with rising likelihood of contamination. At this stage, therefore, serum should be analysed for antibodies to organisms that cannot be cultured by routine methods, and, if available, antibodies to gram-positive bacterial cell walls. Excised valves, vegetations or other relevant material should undergo microscopy, culture, histopathology, and relevant molecular techniques (usually PCR) which can also be applied to newly acquired blood samples or the original growth negative blood culture substrate.

Electrocardiography

Aortic valve abscess formation can lead to first second-, or third-degree heart block. Increased QRS voltage in acute aortic or mitral regurgitation owing to left ventricular volume increase (Figs 12.7 and 12.8).

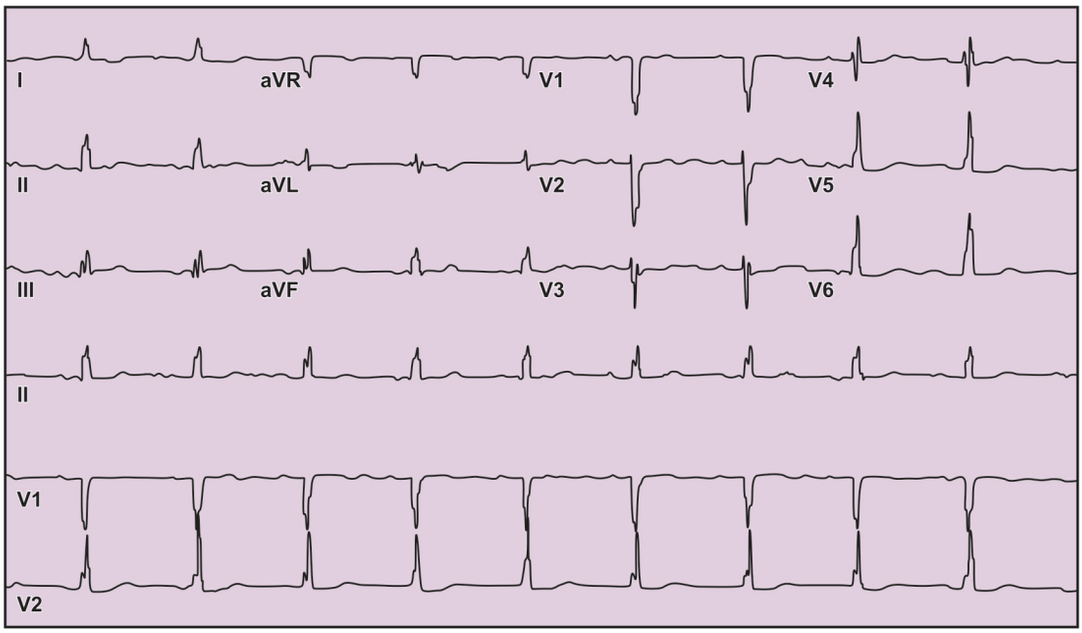

Fig. 12.7: ECG of a patient with infective endocarditis. Note the first-degree AV block, nonspecific intraventricular conduction delay, and nonspecific ST-T-wave abnormalities

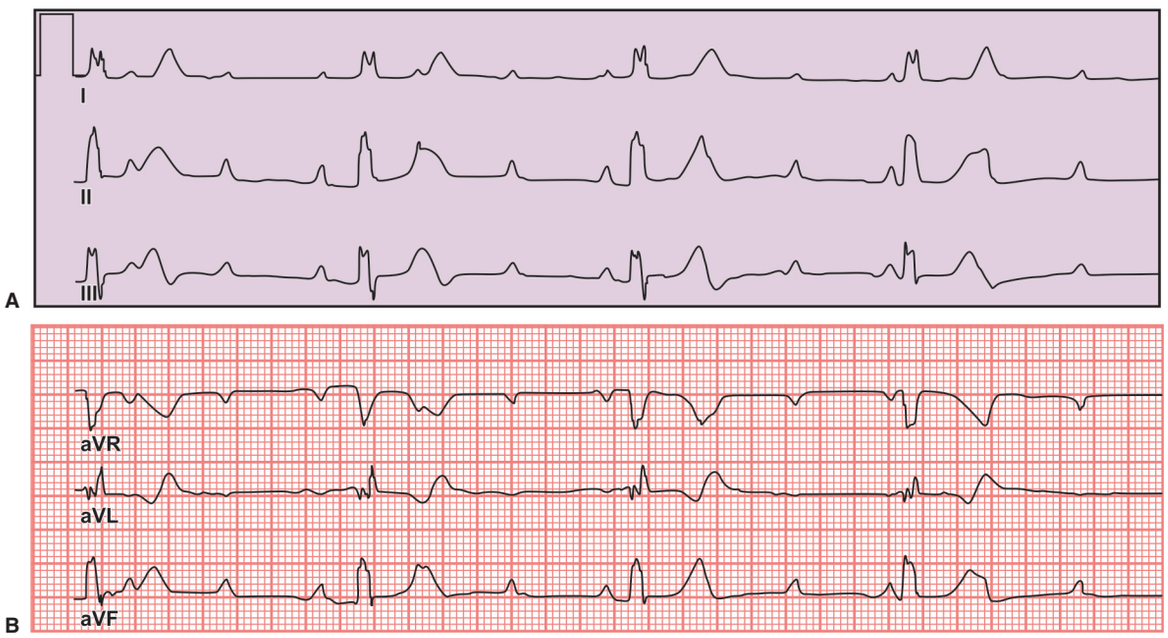

Fig. 12.8A and B: Electrocardiograms show complete heart block in infective endocarditis due to abcess along IVS

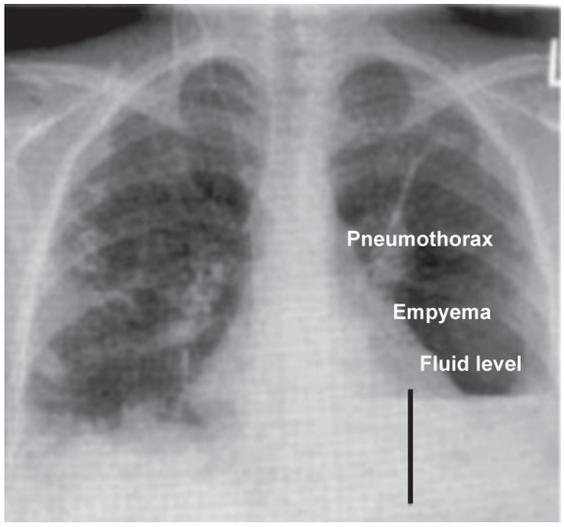

Fig. 12.9: X-ray chest PA view in the same patient showing multiple alveolar opacities in the right lung. Abscess formation in the left lung has caused a bronchopleural fistula, pneumothorax and emphysema,hence the air fluid level

Imaging Studies

Chest X-ray may show cardiomegaly pulmonary edema, or septic pulmonary emboli (right-sided endocarditis) (Fig. 12.9).

Echocardiography in Infective Endocarditis

Since Dillon and colleagues' in 1973 described valvar vegetations by M mode echocardiography, the technique has assumed an increasingly important role in the assessment and management of endocarditis. The development of two dimensional and later transesophageal echocardiography (TEE) has significantly improved the noninvasive detection of vegetations. Moreover, echo-Doppler studies provide clinically important information on the presence and degree of valvar destruction and their hemodynamic consequences, as well as on the existence of perivalvar infection. The diagnostic strategy proposed by Durack and colleagues (the Duke criteria) combined echocardiographic findings with clinical and microbiological data. Three echocardiographic findings were considered to be major criteria for the diagnosis of endocarditis. Transesophageal echocardiography is the preferred diagnostic technique because of its high sensitivity and specificity comparedwith transthoracic echocardiography (Tables 12.4, 12.5, and Box 12.1).

1. Findings that are almost certainly endocarditis include (major criteria) oscillating low-density masses, abscess, fistulas, and prosthetic valve dehiscence.
2. Probable endocarditis findings include localized leaflet thickening, nonmobile valve related masses, chordal rupture, aortic leaflet prolapse, and paraprosthetic valve regurgitation (minor criteria).
3. Possible endocarditis findings include valve lesions such as diffuse thickening, which could be a substrate for endocarditis, but specific findings are not seen.

BOX 12.1: Echocardiographic characteristics of infective endocarditis

Location	*Findings*
Aortic valve	Shaggy nonuniform thickening in systole or diastole with unrestricted leaflet motion Dense shaggy echoes moving across valve and into LVOT Flail or ruptured cusps Fine diastolic fluttering on anterior mitral leaflet secondary to aortic insufficiency
Mitral valve	Thick shaggy echoes attached to or moving behind leaflets demonstrat-ingunne stricted motion Systolic flutter of prolapsing segments of mitral valve Fuzzy leaflet echoes in left atrial cavity during systole (differentiate from myxoma)
TV and PV	Shaggy thickening of leaflets, demonstrating unrestrictive motion. Mass of echoes moving with leaflets (dependent motion) Rupture of tricuspid chordae tendinae
Prosthetic valve	Thick shaggy collection located behind site of attachment of prosthesis to valve ring. Evidence of severe regurgitation.

4. A negative echocardiographic study does not completely rule out endocarditis, but makes it less likely. If clinical suspicion remains high, a repeat study should be done in 5 days. Presence of vegetations defined as:
   - Mobile echodense masses implanted in a valve or mural endocardium in the trajectory of a regurgitant jet or implanted in prosthetic material with no alternative anatomical explanation;
   - Presence of abscess/s; or
   - Presence of a new dehiscence of a valvar prosthesis.

Abnormal echocardiographic findings not fulfilling those definitions were considered minor criteria. More recently the use of TEE has resulted in better imaging and therefore doubtful findings are not considered minor criteria any longer. Since the definite diagnosis of endocarditis requires the presence of two major criteria, or one major and three minor criteria, it is clear that echocardiography has assumed a crucial role in the diagnosis of the disease, particularly when blood cultures are negative. A negative TEE has an important clinical impact on the diagnosis of endocarditis with a high negative predictive value ranging from 86–97%. In patients with native heart valves a negative TEE virtually rules out the diagnosis of infective endocarditis. However, in the study of Sochowski and colleagues. 5 out of 65 patients (7.6%) with an initially negative TEE were finally diagnosed with endocarditis: in three of the patients a TEE performed 1–2 weeks after the initial examination showed the presence of vegetations. This study underlines the importance of recognising the

Table 12.4: Anatomic and echocardiographic definitions

	Surgery/necropsy	*Echocardiography*
Vegetation	Infected mass attached to an endocardial structure, or on implanted intracardiac material	Oscillating or nonoscillating intracardiac mass on valve or other endocardial structures, or on implanted intracardiac material
Abscess	Perivalvular cavity with necrosis and purulent material not communicating with the cardiovascular lumen	Thickened, nonhomogeneous perivalvular area with echodense or echolucent appearance
Pseudoaneurysm	Perivalvular cavity communicating with the cardiovascular lumen	Pulsatile perivalvular echo-free space, with colour-Doppler flow detected
Perforation	Interruption of endocardial tissue continuity	Interruption of endocardial tissue continuity traversed by colour-Doppler flow
Fistula	Communication between two neighbouring cavities through a perforation	Colour-Doppler communication between two neighboring cavities through a perforation
Valve aneurysm	Saccular outpouching of valvular tissue	Saccular bulging of valvular tissue
Dehiscence of a prosthetic valve	Dehiscence of the prosthesis	Paravalvular regurgitation identified by TTE/TEE, with or without rocking motion of the prosthesis

Anatomically, IE is characterized by a combination of vegetations and destructive lesions

phase of the disease in which the study is performed, since vegetations may not be large enough to be visualised when endocarditis is suspected very early on. In common with other diagnostic techniques, specificity of echocardiography is related to the clinical indication and the type of population studied. The technique does not permit differentiation between septic vegetations and other aseptic vegetations present in other situations such as Libman-Sacks endocarditis in systemic lupus erythematosus, and antiphospholipid syndrome or marantic endocarditis. Vegetations persisting after effective treatment must not be interpreted as a clinical recurrence of the disease unless supported by clinical features and bacteriologic evidence. Specificity is influenced mainly by the presence of valvar thickening or calcifications and also by rupture mitral chordae tendinae or Lambl's nodules which can be confused with vegetation images. The usefulness of TEE in patients with suspected endocarditis on a native valve is related to the results of the TTE. TEE is useful when TTE is negative or inconclusive.

Detection of Vegetations

There is no better technique for noninvasive visualisation of vegetations than echocardiography. Overall the detection rate for vegetations by transthoracic echocardiography (TTE) in patients with a clinical suspicion of endocarditis averages around 50%. The diagnostic yield of the technique in the detection of vegetations is influenced by several factors, i.e. image quality, echogenicity and vegetation size, vegetation location, presence of previous valvar disease or valvar prosthesis, experience and skill of the examiner, and pretest probability of endocarditis.

Native valve endocarditis

The use of harmonic imaging has improved study quality, but not the sensitivity in the visualisation of vegetations. 'Vegetation size also affects TTE sensitivity' since only 25%

Table 12.5: Risk of infective endocarditis associated with pre-existing cardiac disorders

Prophylaxis for endocarditis recommended

- *High-risk cardiac condition*
  - Prosthetic heart valves
  - Previous infective endocarditis
  - Cyanotic congenital heart disease (single ventricle states, transposition of the great arteries, tetralogy of Fallot)
  - Surgically constructed systemic—pulmonary shunts (e.g. Blalock shunt)
- *Intermediate-risk cardiac condition*
  - Mitral valve prolapse with regurgitation
  - Acquired valvular dysfunction (e.g. rheumatic heart disease)
  - Hypertrophic cardiomyopathy
  - Most congenital cardiac malformations (other than those listed above and below)

Prophylaxis for endocarditis not recommended

- *Low-risk cardiac condition (Risk no greater than general population)*
  - Mitral valve prolapse without regurgitation
  - Trivial valvular regurgitation on echocardiography without structural abnormality (except mitral valve prolapse)
  - Isolated atrial septal defect
  - Atherosclerotic plaque
  - Coronary disease or previous coronary artery bypass surgery
  - Cardiac pacemakers or defibrillators
  - Previous Kawasaki's disease or rheumatic fever without valvular dysfunction
  - Surgically repaired intracardiac lesions, with minimal or no hemodynamic abnormality more than 6 m after operation
  - Innocent heart murmur

Adapted from Dajani AS, Taubert KA, Wilson W, et al. Prevention of bacterial endocarditis: recommendations by the American Heart Association. Circulation. 1997;96:358–86.

of vegetations <5 mm and 70% of those between 6–10 mm are identified. Underlying valve disease may influence the diagnostic accuracy of TTE when a myxomatous mitral valve or sclerotic or calcified valves are present. These limitations have been overcome by TEE owing to its better resolution and multiple study planes. Many studies have compared the sensitivity and specificity of TTE and TEE in the diagnosis of vegetations. In the majority of these studies TTE sensitivity ranges between 40–63% and that of transesophgeal echocardiography (TEE) between 90–100% (Figs 12.10 –12.13).

A negative TEE has an important clinical impact on the diagnosis of endocarditis with a high negative predictive value ranging from 86–97%. In patients with native heart valves a negative TEE virtually rules out the diagnosis of infective endocarditis. However, in the study of Sochowski and colleagues, 5 out of 65 patients (7.6%) with an initially negative TEE were finally diagnosed with endocarditis.



Fig. 12.10: Echocardiography demonstrates a large vegetation on the aortic valve

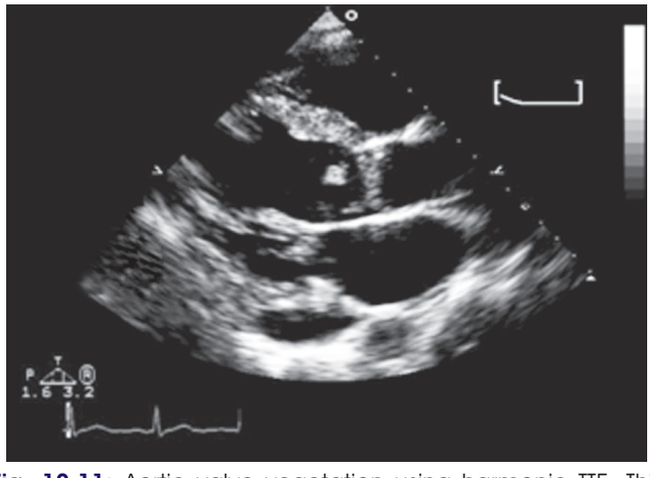

Fig. 12.11: Aortic valve vegetation using harmonic TTE. This demonstrates an echodense mass attached to the aortic valve leaflet consistent with a vegetation using harmonic TTE imaging

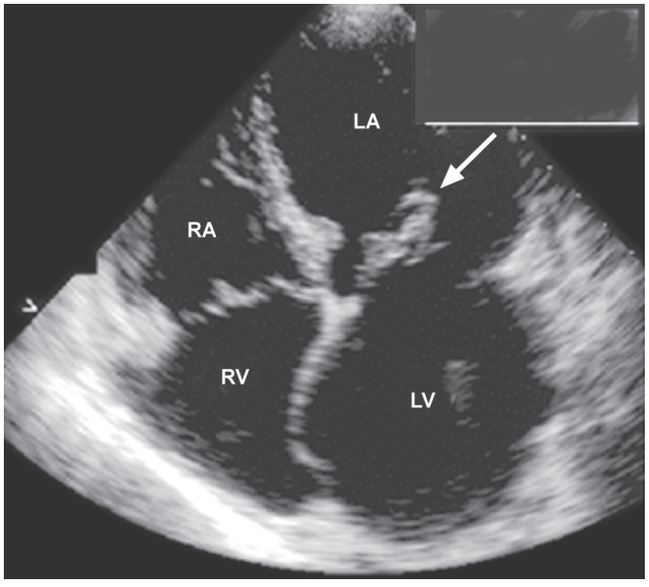

Fig. 12.12: Mitral valve vegetation shown (arrow) by echocardiogram. The vegetation is the mass seen in the dark space between the left atrium (LA) and left ventricle (LV). RA=indicates right atrium; RV=right ventricle

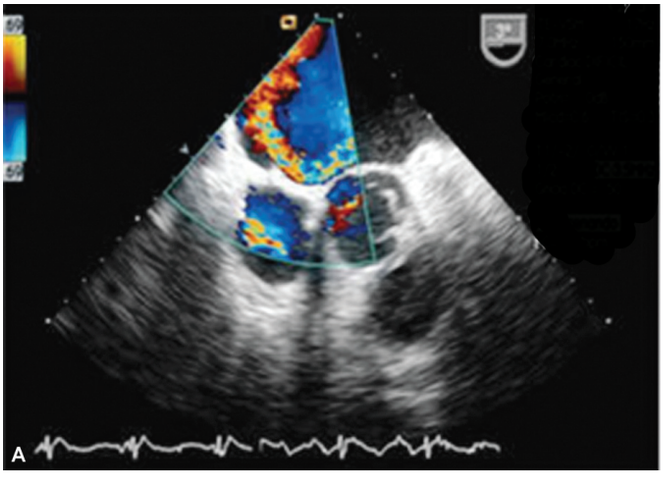

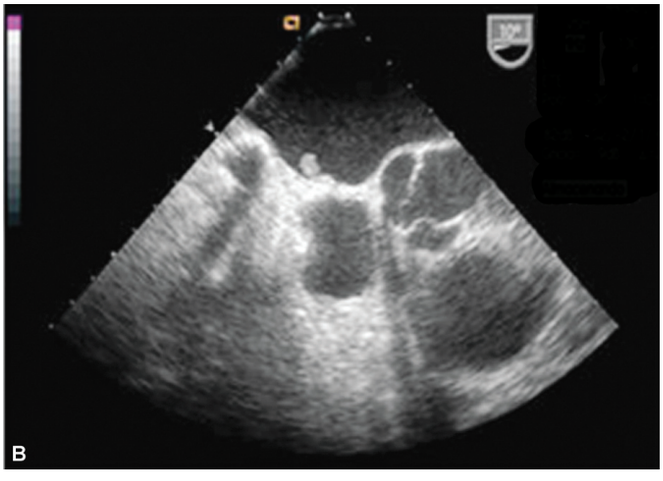

Fig. 12.13: (A and B) Mitral color jet on the interatrial septum and vegetation

In three of the patients a TEE performed 1–2 weeks after the initial examination showed the presence of vegetations. This study underlines the importance of recognising the phase of the disease in which the study is performed, since vegetations may not be large enough to be visualised when endocarditis is suspected very early on. In common with other diagnostic techniques, specificity of echocardiography is related to the clinical indication and the type of population studied. The technique does not permit differentiation between septic vegetations and other aseptic vegetations present in other situations such as Libman-Sacks endocarditis in systemic lupus erythematosus, and antiphospholipid syndrome or marantic endocarditis. Vegetations persisting after effective treatment must not be interpreted as a clinical recurrence of the disease unless supported by clinical features and bacteriologic evidence. Specificity is influenced mainly by the presence of valvar thickening or calcifications and also by rupture mitral chordae tendinae or Lambl's nodules which can be confused with vegetation images. The usefulness of TEE in patients with suspected endocarditis on a native valve is related to the results of the TTE. TEE is useful when TTE is negative or inconclusive.

Prosthetic valve endocarditis: Vegetations on prosthetic valves are more difficult to detect by TTE than those involving native valves, and therefore, TEE should always be used if the diagnosis of prosthetic endocarditis is suspected. The sewing ring and support structures of mechanical and bioprosthetic valves are strongly echogenic and may prevent vegetation detection within the valve apparatus or its shadow (Fig. 12.14).

The vegetative growth appears as thickening and irregularity of the normally smooth contour of the sewing ring. Both thrombus and pannus have a similar appearance and cannot be distinguished from vegetative material. It is also important to recognise strands to avoid false positive diagnoses. Strands are commonly observed by TEE on prosthetic valves, particularly in the early postoperative months, especially in mitral prostheses. In large series of prosthetic endocarditis TEE has shown an 86–94% sensitivity and 88–100% specificity for vegetation diagnosis, while TTE sensitivity was only 36–69%. Bioprosthetic valve leaflets may become infected with secondary destruction of leaflet tissue. The distinction between wear-and-tear degeneration of tissue valves and endocarditis is often difficult. TEE also led to an improved diagnostic accuracy in the diagnosis of endocarditis on bioprosthetic valves.

Right-sided endocarditis and pacemaker lead infections: Staphylococcal endocarditis in injection drug users is now the dominant form of the disease in many urban communities where there is a high incidence of injection drug use and homelessness. Right-sided endocarditis accounts for 10% of all IE in population based surveys' and a higher proportion of IE in injection drug users. Modern echocardiographic techniques have considerably augmented our ability to diagnose IE and to understand its natural history. Despite this, there are many areas in which our understanding of right-sided IE remains incomplete. Right-sided IE has a significant morbidity and mortality that adds a notable economic burden to stretched inner city health care facilities. The challenges of caring for this population of patients should not be underestimated and demands a logical and coordinated approach among care providers and physicians from a variety of specialties (Figs 12.15 and 12.16).

Epidemiology and Predisposing Factors

Although right-sided IE may occur in association with congenital heart disease and instrumentation of the right heart, it is overwhelmingly a disease of injection drug users, at least in western populations. Among injection drug users presenting with fever, 13% will have echocardiographic

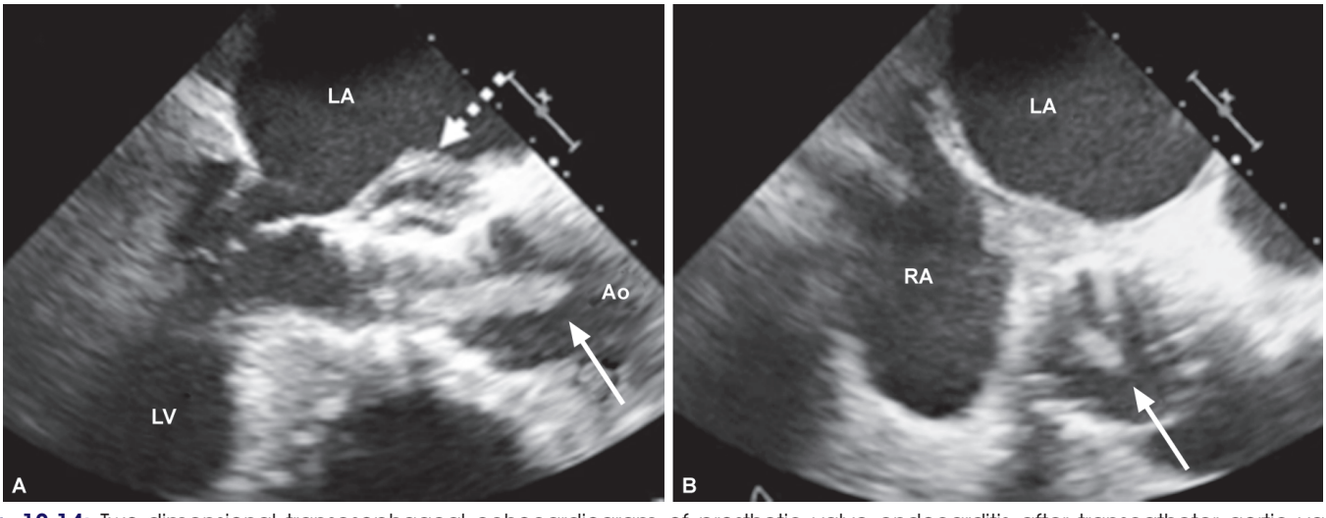

Fig. 12.14: Two-dimensional transesophageal echocardiogram of prosthetic valve endocarditis after transcatheter aortic valve replacement. Two-dimensional transesophageal echocardiography (A) long axis; (B) short axis) showing a 3 cm floating endocarditic lesion within the stent lumen of a prosthetic transcatheter aortic valve (solid arrow). Signs of a paravalvular abscess can be seen close to the noncoronary sinus Valsalva (dashed arrow). Transesophageal images were obtained with a Philips X7-2t transducer/iE33 ultrasound system on admission and a Siemens Acuson Sequoia ultrasound system 3 months before. Ao=aortic root; LA=left atrium; LV=left ventricle; and RA=right atrium

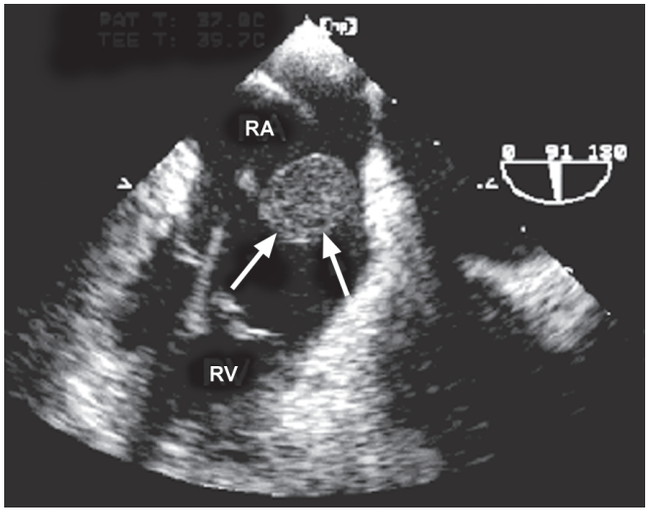

Fig. 12.15: Endocarditis on a pacemaker or defibrillator lead. Ball-like vegetation on pacemaker lead (vertical echoes seen in right atrium (RA). Horizontal echoes between RA and right ventricle (RV) represents the tricuspid valve (arrows)

evidence of IE.' If injection drug users with bacteraemia from an inner city demographic are considered, up to 41% will have evidence of IE.'The pathogenic mechanisms that explain the increased prevalence of right-sided IE in injection drug users are not fully elucidated. Damage to the right-sided valves from injected particulate matter in the setting of injected bacterial loads is thought to be important, while subtle abnormalities of immune function may also have a role in pathogenesis. In keeping with the demographic characteristics of injection drug use, this disease occurs most commonly in young males in their 20s and 30s. Before infection the tricuspid valve is usually structurally normal. Reinfection of a tricuspid valve that has been damaged by previous IE accounts for a significant proportion of cases and can add to the difficulty of echocardiographic interpretation. It seems logical that valves previously damaged by infection are more likely than normal valves to become infected. Earlier reports of IE in injection drug users emphasised the dominance of right-sided involvement. The tricuspid valve is most frequently involved followed by the mitral and then the aortic valve. Concurrent involvement of both left and right-sided valves is not infrequent. In right-sided IE it is almost always the tricuspid valve that is involved. One study of injection drug users found vegetations involving the tricuspid valve in 127 episodes, the pulmonary valve in four, and both valves in one instance. Involvement of other right-sided structures such as the Eustachian valve has been reported but is rare.

The dominant infective organism is *Staphylococcus aureus*, in most series accounting for around 70% of infections, with the remainder being caused mainly by streptococcal species or, less frequently, by Gram negative organisms, fungi or diphtheroids. Pseudomonal infections may have a predilection for multivalve involvement. Infections with unusual organisms and polymicrobial infections do occur, probably as the result of the injection of contaminated diluent, but are relatively unusual. Blood cultures are positive in a high proportion of cases of right-sided IE. When culture negative right-sided IE occurs, it is usually as a result of antibiotic use before the drawing of blood cultures. Bartonella infection has been described as a cause of culture negative IE in a homeless inner city population, and in right-sided IE. Although patterns of drug use in relation to IE have not been extensively studied, cocaine use may be a risk factor, presumably as a consequence of the much higher frequency of injections than in heroin users. The reported prevalence of HIV disease in patients with right-sided IE is variable. In a Spanish series of injection drug users with IE, 76% were HIV positive. In a

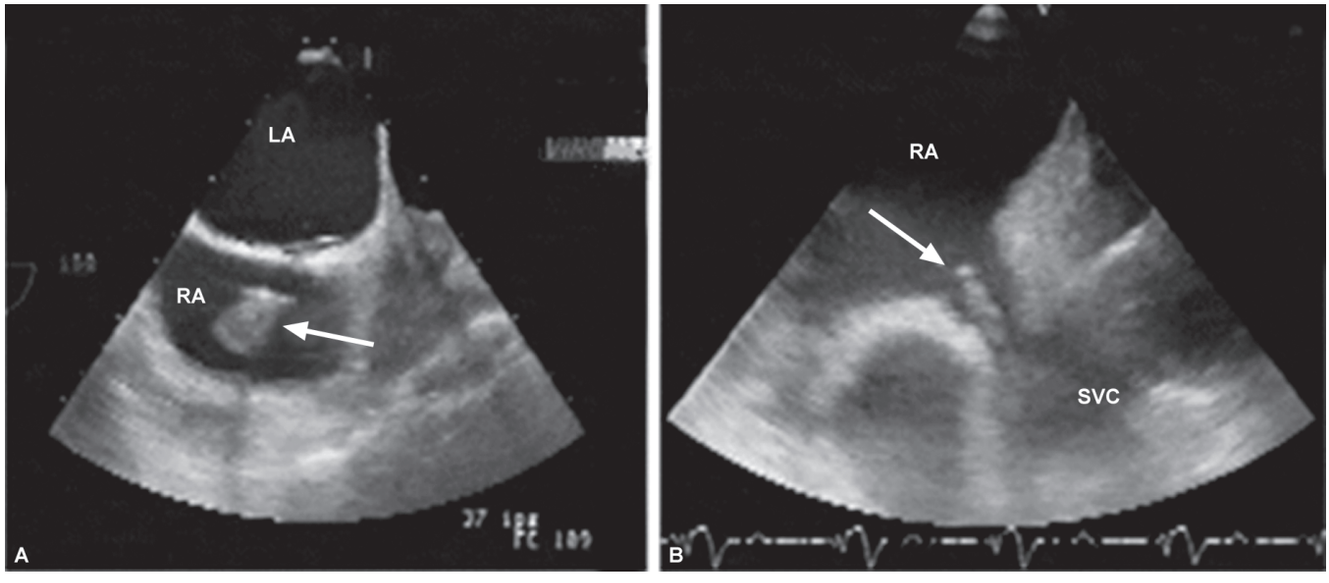

Fig. 12.16: Pacemaker lead infective endocarditis (transoesophageal echocardiography). (A) Typical vegetation on a pacemaker lead (arrow). (B) Thickening of the pacemaker lead with a sleeve-like appearance (arrow). RA=right atrium; LA=left atrium; SVC=superior vena cava

cohort of injection drug users with IE, those who were HIV positive were more likely to exhibit right-sided involvement. Advanced HIV infection is probably a risk factor for IE.

Diagnostic Procedures

Rarely, cardiac catheterization is done to draw blood cultures in proximity of the valve lesions.

Medications (Table 12.6): Appropriate antibiotic therapy.

Surgery

1. Cardiac surgery, usually to replace the infected valve(s) Absolute indications for valve surgery in endocarditis; Intracardiac abscess or fistula
2. Left heart failure
3. Endocarditis due to fungi or Gram-negative organisms, new prosthetic valve paravalve regurgitation, fistula, ascess, or dehiscence.

Monitoring

ECG and blood pressure monitoring as appropriate in the hospital. Repeat blood cultures to assess response to therapy.

Diet and Activity

Restricted activiry. Low-salt diet.

Hospital Discharge Criteria

1. Resolution of problem
2. Sufficient IV therapy to warrant oral antibiotics
3. Successful surgery

Follow up

After course of antibiotics, repeat blood cultures and echocardiogram in 2–4 weeks; then careful clinical follow-up at 3-, 6-, then 12-month intervals.

Complications

- Heart failure
- Pulmonary edema
- Pericarditis
- Myocarditis
- Myocardial infarction
- Heart block
- Stroke

Table 12.6: Circumstances where short course antibiotic treatment for infective endocarditis is not appropriate

- Confirmed or suspected left-sided endocarditis
- Metastatic sites of infection or empyema
- Cardiac or extracardiac complications
- Methicillin resistant *Staphylococcus aureus* (MRSA)
- Presence of any prosthetic valve
- Vegetation size >10 mm
- Incomplete response to treatment
- HIV positive and CD4 count <200/mm^2

- Brain abscess
- Renal failure
- Sudden death

Prognosis

Despite modern antibiotics and improved surgical techniques, mortaliry rate for patients with infective endocarditis is almost 40%.

Prevention

Antibiotic prophylaxis for invasive procedures/surgery in naturally colonized places such as the mouth, and gastrointestinal tract in patients with the substrate for endocarditis, such as rheumatic valvular disease, audible heart murmurs, or cyanotic congenital heart disease (Table 12.7).

Table 12.7: Recommendations for prophylaxis in dental or surgical procedures

Prophylaxis recommended for high- and medium-risk cardiac condition

- Oropharyngeal Procedures
  - Dental procedures known to induce gingival or mucosal bleeding
  - Tonsillectomy and/or adenoidectomy
  - Bronchoscopy with a rigid bronchoscope
- Gastrointestinal Procedures[a]
  - Surgical operations that involve intestinal mucosa
  - Sclerotherapy for esophageal varices
  - Esophageal stricture dilatation
  - Billary surgery
  - Endoscopic biliary cannulation with biliary obstruction
- Genitourinary Procedures
  - Cystoscopy
  - Urethral dilatation
  - Prostate surgery
- Miscellaneous
  - Incision and drainage of infected tissue

Prophylaxis not recommended

- Oropharyngeal
  - Dental procedures not likely to induce gingival bleeding
  - Injection of local intraoral anesthetic (except intraligamentary injections)
  - Shedding of primary teeth
  - Tympanostomy tube insertion
  - Endotracheal intubation
  - Bronchoscopy with a flexible bronchoscope with or without biopsy[b]
- Gastrointestinal Procedures[b]
  - Transesophageal echocardiography
  - Endoscopy with or without gastrointestinal biopsy
- Genitournary Procedures
  - Postoperative suture removal
  - Cesarean section

Contd...

Contd...

- Vaginal hysterectomy or uncomplicated vaginal delivery[b]
- Circumcision
- Specific procedures in the absence of infectio, including:
  - Urethral catheterization
  - Dilatation and curettage
  - Therapeutic abortion
  - Sterilization procedures
  - Insertion or removal of intrauterine device

- Cardiac Procedures
  - Cardiac catheterization or balloon angioplasty
  - Implanted stents, pacemakers, or defibrillators

[a]Prophylaxis is recommended for high-risk but is optional for medium-risk cardiac conditions. [b]Prophylaxis is optional for high-risk cardiac conditions. Adapted from Dajani AS, Taubert KA, Wilson W, et al. Prevention of bacterial endocarditis: recommendations by the American Heart Association. Circulation. 1997;96:358–66.

Culture Negative Infective Endocarditis and Atypical Organisms

Negative blood cultures occur in 2.5–31% of all cases of infective endocarditis, often delaying diagnosis and the onset of treatment with profound impact on clinical outcome. Moreover, the sensitivity of the Duke criteria, which rely heavily on microbiological indices, is diminished in this setting. Negative cultures arise most commonly as a consequence of prior antibiotic administration, but an increasingly common scenario is infection by fastidious organisms with limited proliferation under conventional culture conditions, or requiring specialised tools for identification. Such pathogens include Coxiella, Legionella, the HACEK group (Haemophilus species, *Actinobacillus actinomycetemcomitans, Cardiobacterium hominis, Eikenella corrodens, and Kingella kingae*), Chlamydia, Bartonella, *Tropheryma whippelii,* and fungi, including Candida, Histoplasma, and Aspergillus species, and *Torulopsis glabrata*. These organisms may be particularly common in cases of infective endocarditis affecting patients with prosthetic valves, indwelling venous lines, pacemakers, renal failure, and immuno-compromised states.

Modified Criteria and New Diagnostic Techniques

In 1997, Lamas and Eykyn proposed a number of clinical modifications to the Duke criteria to include newly diagnosed splenomegaly or clubbing, elevated inflammatory markers, haematuria, and the presence of central and peripheral venous lines ('the St Thomas modifications'). Simultaneously, recognition of the role of Q fever, a worldwide zoonosis caused by *Coxiella burnetti* and a particularly frequent cause of infective endocarditis in France, increasing prevalence of staphylococcal infection, and widespread use of transoesophageal echocardiography resulted in further modifications; these involved incorporating the acceptance of positive Q fever serology or bacteraemia caused by *Staphylococcus aureus* (regardless of its source) as major criteria and the elimination of minor echocardiographic criteria A recent study compared these modifications in pathologically proven yet culture negative cases. Only 21% were classified as definite by the original Duke criteria, while 32% were definite by the modified Duke criteria, and the St Thomas modifications classified 62% correctly. Interestingly, the four additional cases identified correctly by the modified Duke criteria were upgraded on account of positive Q fever serology. Furthermore, careful scrutiny led to identification of the causative organism in almost 50% of culture negative cases, achieved by serology (*C. burnetti*, Bartonella, *Chlamydia psittaci*) in 24%, culture of the excised valve in 14%, microscopy of the excised valve in 5%, and nonvalve culture in 6%.

Histological/immunological techniques: Histological findings are included in the Duke and von Reyn diagnostic criteria and pathological examination of resected valvar tissue or embolic fragments remains the gold standard for the diagnosis of infective endocarditis. Pathological examination may also guide antimicrobial treatment if the causative agent can be identified by means of special stains or immuno histological techniques, and allow distinction from conditions whose echocardiographic features mimic infective endocarditis (for example, myxomas, fibroelastomas, and rheumatoid nodules). It should be noted that specimens are potentially infectious to the examiner, particularly when Q fever is suspected. The pathological hallmark of endocarditis is the demonstration of inflammatory changes in valvar tissue and/or vegetations, characteristically at the site of attachment or base of a vegetation. This finding is not specific, however, and inflammation is also a feature of degenerative and other valve pathology. Electron microscopy has high sensitivity and may help to characterise new microorganisms. However, it is time consuming and expensive and therefore reserved for cases in which other techniques fail to detect an organism. Histological criteria for the diagnosis of endocarditis have been proposed and a variety of specialised stains and immunohistological techniques (immunoperoxidase staining, enzyme linked immunosorbent (ELISA) and immunofluorescent ELIFA) assays, and direct immunofluorescence using fluorescein conjugated monoclonal antibodies) are now available to allow the identification of elusive bacteria and fungi. *C. burnetti* and Bartonella species are the most common aetiological agents in culture negative endocarditis and may be easily detected by serological testing using indirect immunofluorescence or ELISA. Immunological analysis of urine may also allow detection of microorganism degradation products and ELISA detection of Legionella species has been described using this technique. However, the incorporation of these techniques into accepted diagnostic criteria awaits prospective validation.

Molecular Techniques

Several molecular approaches have been assessed for the detection and identification of pathogens in a wide variety of infectious diseases. The polymerase chain reaction (PCR) utilising nucleic acid target or signal amplification, alone or in combination with sequence analysis, is most widely

used and allows rapid and reliable detection of fastidious and nonculturable agents in blood and surgical material of patients with infective endocarditis. It may also be of value when phenotypic characterisation is essential following isolation of two or more organisms in separate cultures (most commonly caused by contamination with skin commensals during sampling or polymicrobial infection in intravenous drug abusers). Indeed, the incorporation of such techniques as a major Duke diagnostic criterion has been proposed with widespread support. Specific primers are now available for many bacterial agents including *T. whippelii, C. burnetti*, and species of Bartonella, Chlamydia, Brucella, Legionella, Mycobacteria, and Mycoplasma. Future improvements include the possibility of quantitation by real time PCR eliminating the need for gel electrophoresis with faster, more accurate results, and the possibility of investigating common antimicrobial resistance genes enabling a targeted approach to antibiotic treatment.

Indications and Optimal Timing for Surgery in Infective Endocarditis

More and more patients are operated on during theactive phase of infective endocarditis (IE) (Tables 12.8–12.10). The principal indications for cardiac surgery are:

- Heart failure,
- No control of infection,
- Embolisms,
- Large size of vegetations,

Table 12.8: Indications for Surgery in IE

Congestive heart failure*
- Congestive heart failure caused by severe aortic or mitral regurgitation or, more rarely, by valve obstruction caused by vegetations
- Severe acute aortic or mitral regurgitation with echocardiographic signs of elevated left ventricular end-diastolic pressure or significant pulmonary hypertension
- Congestive heart failure as a result of prosthetic dehiscence or obstruction

Periannular extension
- Most patients with abscess formation or fistulous tract formation

Systemic embolism†
- Recurrent emboli despite appropriate antibiotic therapy

Large vegetations (>10 mm) after 1 or more clinical or silent embolic events after initiation of antibiotic therapy
- Large vegetations and other predictors of a complicated course
- Very large vegetations (>15 mm) without embolic complications, especially if valve-sparing surgery is likely (remains controversial)
- Cerebrovascular complications‡
- Silent neurological complication or transient ischemic attack and other surgical indications
- Ischemic stroke and other surgical indications, provided that cerebral hemorrhage has been excluded and neurological complications are not severe (e.g. coma)

Persistent sepsis
- Fever or positive blood cultures persisting for >5 to 7 days despite an appropriate antibiotic regimen, assuming that vegetations or other lesions requiring surgery persist and that extracardiac sources of sepsis have been excluded
- Relapsing IE, especially when caused by organisms other than sensitive streptococci or in patients with prosthetic valves

Difficult organisms
- *S. aureus* IE involving a prosthetic valve and most cases involving a left-sided native valve
- IE caused by other aggressive organisms (Brucella, *Staphylococcus lugdunensis*)
- IE caused by multiresistant organisms (e.g. methicillin-resistant *S. aureus* or vancomycin-resistant enterococci) and rare infections caused by gram-negative bacteria

***Pseudomonas aeruginosa* IE**
- Fungal IE
- Q fever IE and other relative indications for intervention

Prosthetic valve endocarditis
- Virtually all cases of early prosthetic valve endocarditis
- Virtually all cases of prosthetic valve endocarditis caused by *S. aureus*
- Late prosthetic valve endocarditis with heart failure caused by prosthetic dehiscence or obstruction, or other indications for surgery

Surgery should be performed immediately, irrespective of antibiotic therapy, in patients with persistent pulmonary edema or cardiogenic shock. If congestive heart failure disappears with medical therapy and there are no other surgical indications, intervention can be postponed to allow a period of days or weeks antibiotic treatment under careful clinical and echocardiographic observation. In patients with well tolerated severe valvular regurgitation or prosthetic dehiscence and no other reasons for surgery, conservative therapy under careful clinical and echocardiographic observation is recommended with consideration of deferred surgery after resolution of the infection, depending upon tolerance of the valve lesion.

Table 12.9: Timing of surgery

- Emergency surgery (within 24 hours)
- Native (aortic or mitral) or prosthetic valve endocarditis and severe congestive heart failure or cardiogenic shock caused by:
- Acute valvular regurgitation
- Severe prosthetic dysfunction (dehiscence or obstruction)
- Fistula into a cardiac chamber or the pericardial space
- Urgent surgery (within days)
- Native valve endocarditis with persisting congestive heart failure, signs of poor hemodynamic tolerance, or abscess
- Prosthetic valve endocarditis with persisting congestive heart failure, signs of poor hemodynamic tolerance, or abscess
- Prosthetic valve endocarditis caused by staphylococci or Gram-negative organisms
- Large vegetation (>10 mm) with an embolic event
- Large vegetation (>10 mm) with other predictors of a complicated course
- Very large vegetation (>15 mm), especially if conservative surgery is available
- Large abscess and/or periannular involvement with uncontrolled infection
- Early elective surgery (during the in-hospital stay)
- Severe aortic or mitral regurgitation with congestive heart failure and good response to medical therapy
- Prosthetic valve endocarditis with valvular dehiscence or congestive heart failure and good response to medical therapy
- Presence of abscess or periannular extension
- Persisting infection when extracardiac focus has been excluded
- Fungal or other infections resistant to medical cure

Table 12.10: Indications and timing of surgery in native and prosthetic valve infective endocarditis

Indication for surgery	Timing	Class	Level of evidence
HEART FAILURE			
Aortic or mitral IE or PVE with severe acute regurgitation, obstruction or fistula causing refractory pulmonary edema or cardiogenic shock	Emergency	I	B
Aortic or mitral IE with severe acute regurgitation or obstruction and persisting heart failure or echocardiographic signs of poor hemodynamic tolerance (early mitral closure or pulmonary hypertension)	Urgent	I	B
Aortic or mitral IE or PVE with severe regurgitation and no HF	Elective	IIa	B
Right HF secondary to severe tricuspid regurgitation with poor response to diuretic therapy	Urgent/Elective	IIa	C
UNCONTROLLED INFECTION			
Locally uncontrolled infection (abscess, false aneurysm, fistula, and enlarging vegetation)	Urgent	I	B
Persisting fever and positive blood cultures >7–10 days	Urgent	I	B
Infection caused by fungi or multiresistant organisms	Urgent/Elective	I	B
PVE caused by staphylococci or gram negative bacteria	Urgent/Elective	IIa	C
PREVENTION OF EMBOLISM			
Aortic or mitral IE or PVE with large vegetations (>10 mm) following one or more embolic episodes despite appropriate antibiotic therapy	Urgent	I	B
Aortic or mitral IE or PVE with large vegetations (>10 mm) and other predictors of complicated course (heart failure, persistent infection, and abscess)	Urgent	I	C
Aortic or mitral IE or PVE with isolated very large vegetations (>15 mm)*	Urgent	IIb	C
Persistent tricuspid valve vegetations >20 mm after recurrent pulmonary emboli	Urgent/Elective	IIa	C

*IE=infective endocarditis; PVE=prosthetic valve endocarditis *Surgery may be preferred if procedure preserving the native valve is feasible.*

- Severe valvar and perivalvar lesions, and
- Infection caused by some atypical microorganisms

Indications for Cardiac Surgery

1. **Heart failure:** If heart failure is present, the mortality rate of native valve infective endocarditis is 55–85% in the case of medical treatment and 10–35% in operated patients. The first indication for cardiac surgery in infective endocarditis is heart failure: it represents more than half of the indications. Heart failure caused by aortic regurgitation is particularly poorly tolerated (heart failure is better tolerated in the case of mitral regurgitation because the left atrium and the pulmonary vascular bed adapt better than the left ventricle to the

regurgitant volume), and it progresses faster, thus needing rapid surgery. Not only does heart failure increase the mortality rate if there is no surgery, but it also increases the perioperative mortality rate from 5–10% in patients without heart failure to 15–35% in patients with heart failure. Moreover, delaying surgery increases the risk of perivalvar infection (Table 12.11).

2. **Resistance infection:** The first step is to make sure that there is no extracardiac infectious location. If there is no such extracardiac location, cardiac surgery should be performed if the course of fever and inflammatory syndrome is unfavourable after 1 week of appropriate antibiotic treatment.
3. **Vegetations and embolic risk:** The literature on this topic contrasts greatly. The embolism rate varies from 10–50% in different series. 'Three quarters of embolisms occur before the beginning of antibiotic treatment.' The embolic risk decreases greatly and regularly over time, from 15% after one week of treatment to 1% after 4 weeks of treatment. In mitral infective endocarditis, embolisms look to be more frequent if vegetations are located on the anterior leaflet than on the posterior leaflet. Embolisms are more frequent when vegetation size is more than 20 mm in some studies, but not in other studies. In a recent study, embolisms were more frequent when the size of the vegetations was more than 10 mm or when vegetations were very mobile.' Embolisms should always be looked for not only by clinical means but also by systematic scanners (for example, cerebral, thoracoabdominal), searching for clinically silent embolisms, especially in spleen and kidneys. Rapid surgery must be performed when there has been an embolic episode and when large and mobile vegetations remain. When there are large and/or mobile vegetations but no embolic event, the medical community is divided. The decision is easier in the case of mitral infective endocarditis when valve repair looks possible, or when there are other arguments for surgery (heart failure, no control of infection, severe valvar and perivalvar lesions, etc).
4. **Perivalvar infection:** Infective endocarditis on the aortic valve and prosthetic infective endocarditis are those most commonly associated with perivalvar infection, such as abscesses and intracardiac fistula. 10–40% of aortic valve infective endocarditis and 45–100% of prosthetic infective endocarditis. Occurrence and persistence of conduction disturbances are not very sensitive indicators of perivalvar infection, but they look very specific (85–90%). Rapid surgery is recommended in most cases since the perioperative risk increases with the delay to surgery. However, in large aortic abscesses, a large resection exposes the patient to the risk of postoperative complete atrioventricular block. Valvar obstruction—Valvar obstruction is an obvious indication for urgent surgery. Unstable prosthesis—dehiscence of an infected prosthesis means that there is perivalvar infection, and hemodynamic deterioration usually occurs quickly. Thus rapid surgery is recommended (Fig. 12.17).
5. **Prosthetic infective endocarditis:** In early prosthetic infective endocarditis >12 months after valve replacement), most often the microorganism is a Staphylococcus and lesions are severe (abscess, prosthesis dehiscence).

Table 12.11: Factors and complications that predispose to a poor outcome

- Congestive heart failure (leading adverse prognostic factor)
- Nonstreptococcal disease
- Aortic valve involvement
- Infection of a prosthetic valve
- Older age
- Abscess formation
- HIV with CD4 count <200
- Delayed diagnosis
- CNS or coronary embolization
- Recurrent infective endocarditis

CNS=Central nervous system; HIV=Human immunodeficiency virus

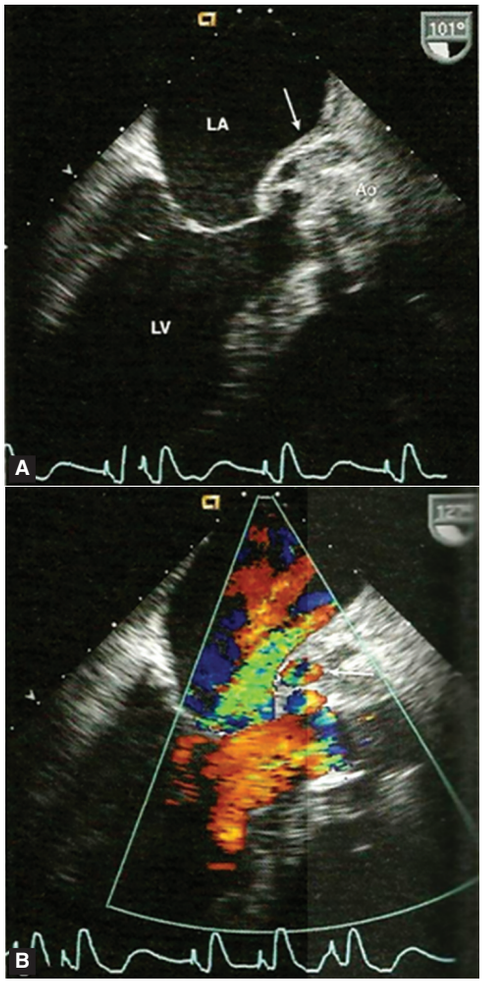

Fig. 12.17: Paravalvular abscess. (A) A TEE long-axis image in a patient with aortic valve endocarditis shows irregular areas of echoluency and echodensity odensity in the aortic annulus and sinuses (arrow), (B) Color-Doppler shows both mitral regurgitation and flow in the echolucent areas in the aortic annulus. At surgery, a paravalvular abscess was present

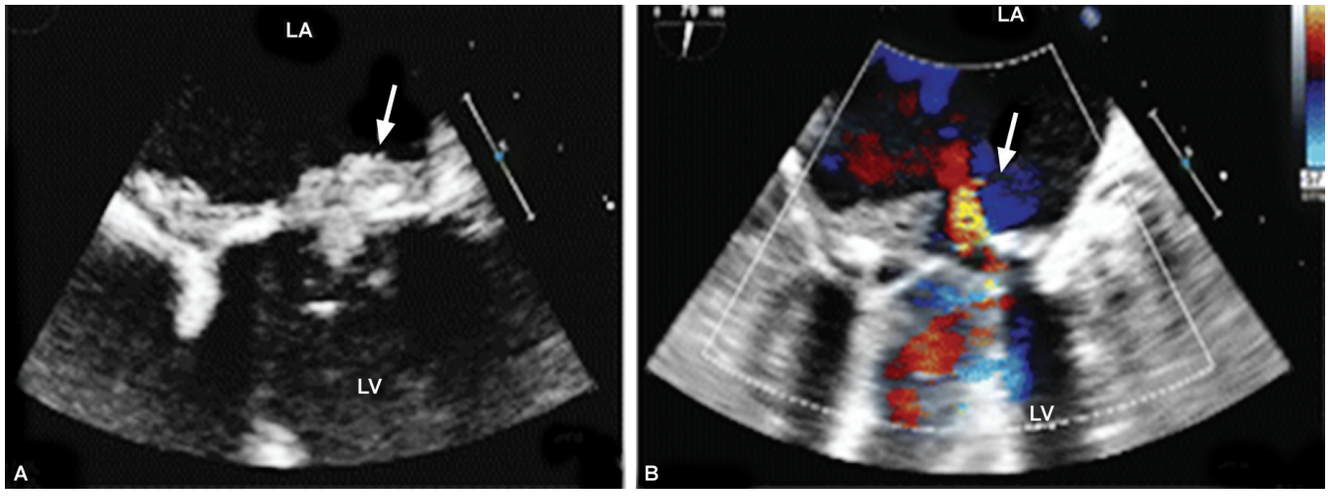

Fig. 12.18: Mitral prosthetic valve endocarditis with prosthetic obstruction (transoesophageal echocardiography). (A) Large vegetation prolapsing into the mitral mechanical prosthetic valve (arrow), (B) central regurgitation associated with the absence of the physiological regurgitant jets (arrow). LV=left ventricle; LA=left atrium; RV=right ventricle

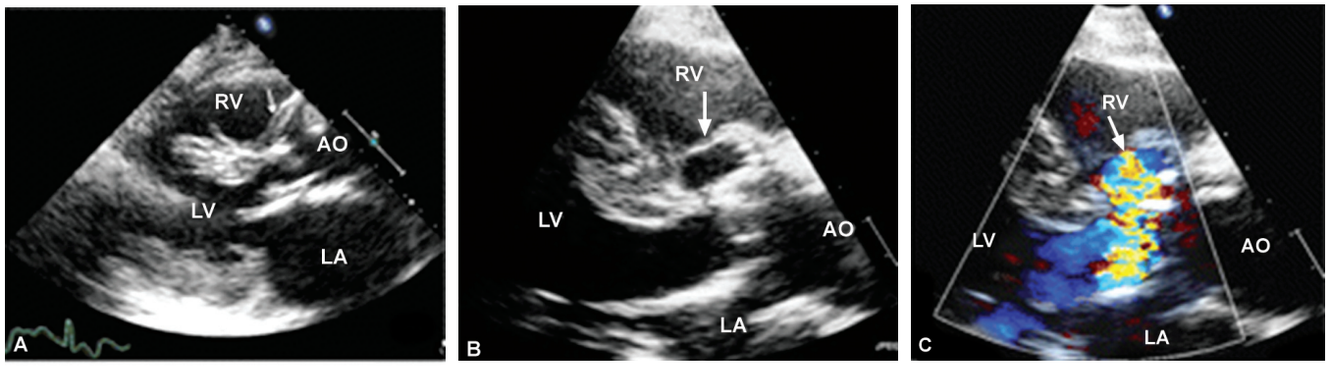

Fig. 12.19: Evolution of an anterior aortic bioprosthetic abscess (TTE). (A) Initial evaluation showing the absence of abscess formation, (B) second evaluation showing the presence of a new anterior free space corresponding to an abscess, (C) color-Doppler showing that the abscess communicates with the left ventricle (arrow) (pseudoaneurysm)

Redo surgery is associated with a lower mortality rate than medical treatment alone, and it is most often necessary, although it may be technically difficult. The mortality rate of prosthetic infective endocarditis caused by *Staphylococcus aureus* is about 75% in the case of medical treatment and 25% in the case of combined medical and surgical treatment. Surgery is thus recommended in prosthetic infective endocarditis caused by *S. aureus* when there is an intracardiac complication. Medical treatment only may be sufficient in cases of late infective endocarditis caused by some microorganisms (oral streptococci, organisms from the HACEK group—Haemophilus species, *Actinobacillus actinomycetemcomitans*, *Cardiobacterium hominis*, *Eikenella corrodens*, and *Kingella kingae*), if there are no signs of perivalvar infection (Figs 12.18 and 12.19).

6. **Fungal infective endocarditis**: Infective endocarditis caused by Candida or Aspergillus are often complicated with very large vegetations, infectious metastases, perivalvar infection, and embolisms. Amphotericin B poorly penetrates into vegetations. Rapid surgery is thus most often needed (Fig. 12.20).

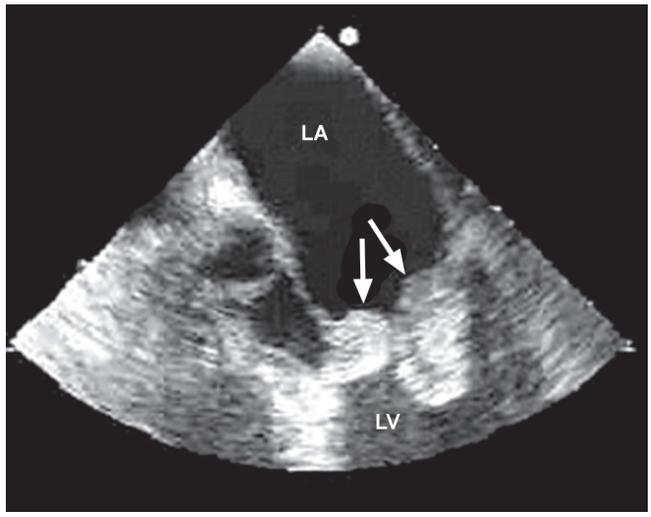

Fig.12.20: Large vegetations (arrows) in the mitral valve secondary to fungal endocarditis. LA=left atrium; LV=left ventricle

7. **Difficult-to-treat microorganisms**: Surgery is almost always needed in infective endocarditis caused by

certain gram-negative bacilli (for example, *Pseudomonas aeruginosa, Achromobacter xylosoxitans*), by Brucella, or by highly resistant enterococci.

8. **Neurological complications:** The rate of neurological complications varies from 15–45% in different series.' They mostly are ischemic cerebral vascular accidents, but also cerebral hemorrhages, ruptured mycotic aneurysms, meningitis, and encephalopathy. A cerebral scan must always be performed in infective endocarditis, to look for silent cerebral vascular accidents. In the case of cerebral hemorrhage, an arteriography or an angiomagnetic resonance image must be performed, to look for a mycotic aneurysm. There is a risk of cerebral hemorrhage associated with cardiac surgery because of anticoagulation during and after the procedure. The risk of cerebral hemorrhage is not increased in the case of a stroke without hemorrhage, but it is greatly increased if the stroke is hemorrhagic. In this case, cardiac surgery should be delayed 2–3 weeks.If there is a ruptured mycotic aneurysm, it must be resected, clipped or embolised before cardiac surgery.

Timing of Cardiac Surgery: Classically, early surgery was considered to be a greater risk than delayed surgery because of tissue inflammation and the surgery was technically more difficult. In fact,the duration of antibiotic treatment before surgery does not appear to influence the perioperative mortality, nor the rate of recurrent infective endocarditis. Surgery should be rapid in the case of hemodynamic deterioration, where there is no control of infection, or there are large and mobile vegetations. Decision as to the timing of surgery is particularly difficult when there is a neurological complication.

RIGHT-SIDED ENDOCARDITIS

Clinical Manifestations

The presenting clinical features of right and left-sided endocarditis are different. While most patients with right-sided endocarditis will have systolic murmurs, the murmur is clearly pathologic in a minority of cases.' Murmurs are, in fact, left-sided and nonspecific in most instances. The usual manifestations are persistent fever, bacteraemia, and multiple pulmonary emboli. Peripheral embolic manifestations are characteristically absent; rather, symptoms and complications arise from the involvement of the pulmonary vasculature by multiple septic pulmonary emboli, chest pain, dyspnea, cough, and hemoptysis may be presenting feature. When peripheral embolic or neurologic features occur, either left-sided endocarditis or paradoxical embolism should be considered. The conjunction of bacteraemia, fever, and multiple pulmonary infiltrates on chest radiography should always prompt a search for right-sided endocarditis.

Complications of Right-sided Endocarditis

It may be thought of as either cardiac or pulmonary. A variety of complications attributed to septic pulmonary emboli have been described including pulmonary infarction, pulmonary abscesses, bilateral pneumothoraces, pleural effusions, and empyema. Mycotic aneurysms of the pulmonary arteries may be complicated by potentially fatal pulmonary hemorrhage. Multiple pulmonary emboli may result in right-sided chamber dilatation, right heart failure, and a worsening of tricuspid regurgitation. The embolisation of vegetations large enough to result in obstruction of a significant portion of the pulmonary arterial circulation has been described but is unusual. Cardiac complications may arise as a consequence of tricuspid valve destruction and severe tricuspid regurgitation with right-sided volume overload, chamber dilatation, and right heart failure. Chronic right atrial dilatation may be a substrate for supraventricular arrhythmias, including atrial flutter and fibrillation. Paravalvar abscess formation occurs infrequently. Vasculitis may complicate right-sided IE, but is not a typical feature. Hypoxemia has been described in right-sided IE when right atrial pressure is raised sufficiently to cause right to left shunting through a patent foramen ovale. Paradoxical embolism resulting from the transit of an embolus across an acquired pulmonary arteriovenous malformation has been reported. It should be recalled that a variety of coexistent medical problems such as hepatitis or HIV disease might be present in this population as a result of complications of injection drug use and poor self care.

Diagnosis of Right-sided Endocarditis

Duke criteria: The Duke system defines a major echocardiographic criterion for IE as the finding of an oscillating intracardiac mass on the valve or supporting structures, in the path of a regurgitant jet. A paravalvar abscess or new dehiscence of a prosthetic valve. Although the sensitivity and specificity of tbe Duke criteria have not been 'specifically studied in the right-sided endocarditis with finding of anyone of these echocardiographic features involving right heart structures. In the presence of positive blood cultures with atypical organism should be regarded as diagnostic of right-sided endocarditis. There are nonetheless some conceptual difficulties in uncritically applying the Duke criteria to right-sided endocarditis. Right-sided murmurs are more difficult to detect. This is especially true of many patients who are injection drug users with their first episode of endocarditis, who will have normal or only slightly elevated right ventricular pressures and in whom a lower velocity, less turbulent tricuspid regurgitant jet might be anticipated. One should not allow the lack of a murmur, therefore, to preclude further investigation if the clinical suspicion is high. Immunologic and vascular phenomena, which feature as minor criteria in the Duke system, are also less common. Septic pulmonary emboli are listed as a minor criterion in the Duke scheme; it could be argued that this important diagnostic feature is somewhat underweighted in the present Duke criteria. On balance, however, it seems reasonable to continue to use the Duke criteria as a useful diagnostic framework.

Electrocardiography: It can help in diagnosing serious complications of right-sided endocarditis, such as pulmonary embolism (Fig 12.21).

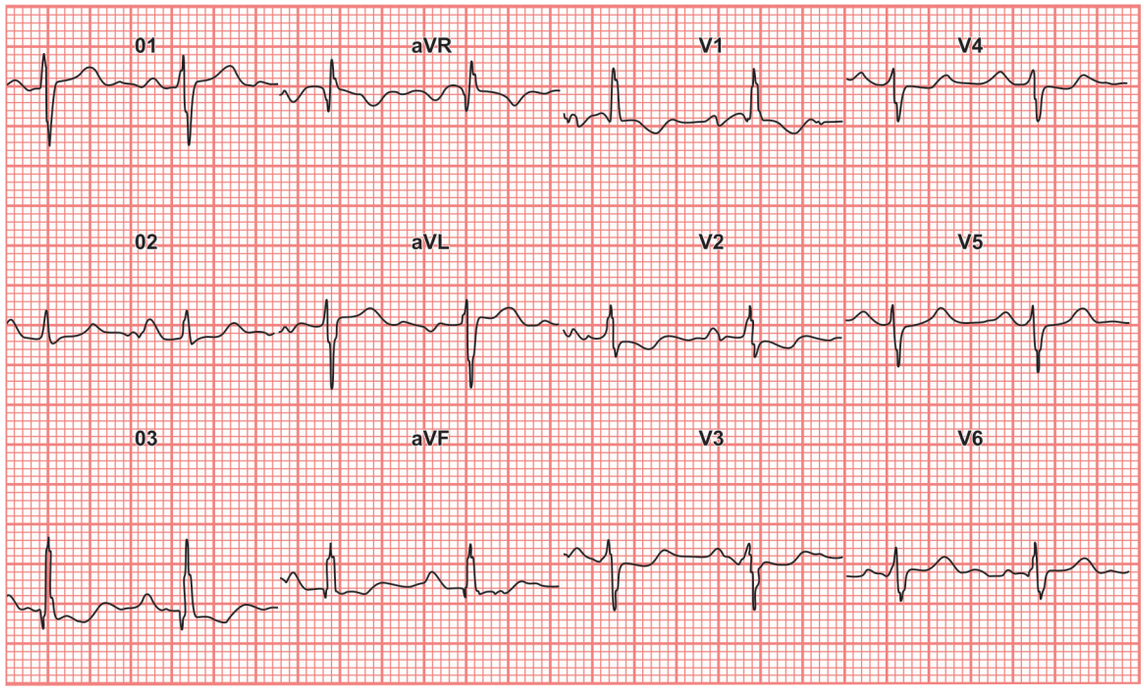

Fig. 12.21: Pulmonary embolism (S_1, Q_3 and T_3 signs) and signs of right frontal axis are shown in right-sided endocarditis

Chest radiography: The chest X-ray is a helpful laboratory aid in diagnosing right-sided endocarditis with 55% of radiographs at presentation showing evidence of pulmonary infiltrates compatible with pulmonary emboli (Fig. 12.22).

Transthoracic echocardiography (TTE): Modern echocardiographic techniques have significantly improved our ability to diagnose right-sided endocarditis and are now the cornerstone of the diagnosis in this disease (Figs 12.23–12.30). In febrile injection drug users, standard laboratory testing and physical examination without echocardiography were ineffective in detecting the patients with endocarditis.' The key echocardiographic finding in right-sided endocarditis is that of vegetation(s) in association with the tricuspid or rarely the pulmonary valve. As with vegetations on the left-sided valves, they tend to be localised to the atrial side of the valve in the path of the regurgitant jet. Tricuspid vegetations are often large and may be in excess of 2 cm, a finding that does not necessarily suggest the presence of fungal endocarditis. On rare occasions, vegetations may be sufficiently large so as to be confused with an intracardiac tumor. Entrapment of an embolised vegetation in the tricuspid chordal apparatus is sometimes

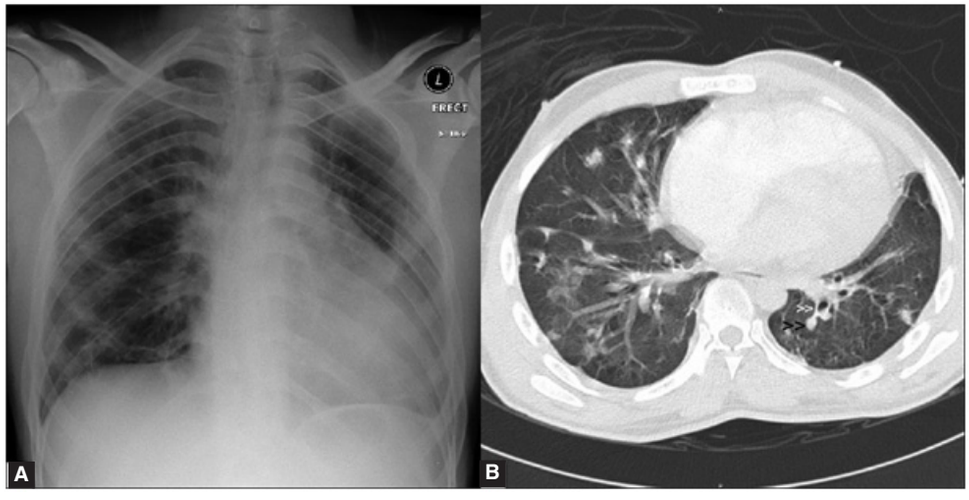

Fig. 12.22: (A) Chest X-ray showing cardiomegaly with bilateral lung infiltrates, and (B) CT scan of chest showing bilateral irregular pulmonary infiltrates with multiple nodules (black arrowheads) with distinct central feeding vessel (white arrowheads), consistent with septic pulmonary emboli in a patient with intravenous drug abuse and tricuspid valve endocarditis

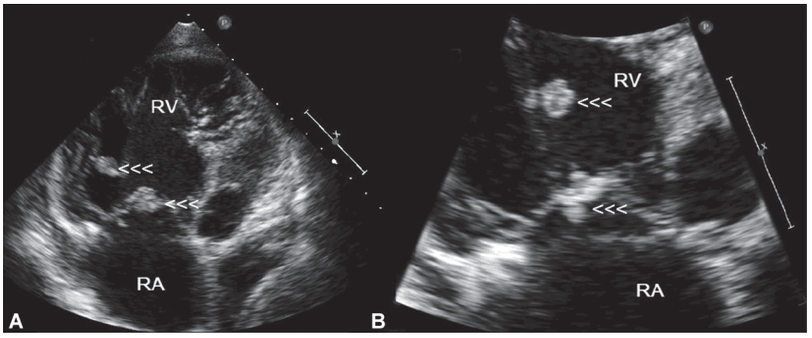

Fig. 12.23: Transthoracic echocardiography (A and B) showing multiple vegetations attached to tricuspid valve leaflets (arrowheads) and one large vegetation on the chordae of anterior tricuspid leaflet (upper arrowheads) in a patient with IV drug abuse and septic pulmonary emboli. RA=right atrium; RV=right ventricle

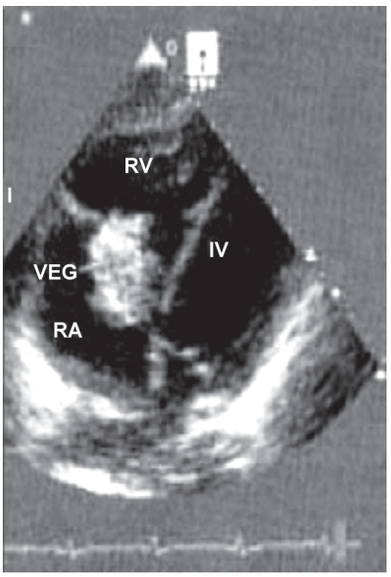

Fig. 12.24: An apical 4C view showing large vegetation attached to the tricuspid valve in patient with infective endocarditis on tricuspid valve who had been using intravenous narcotic drugs

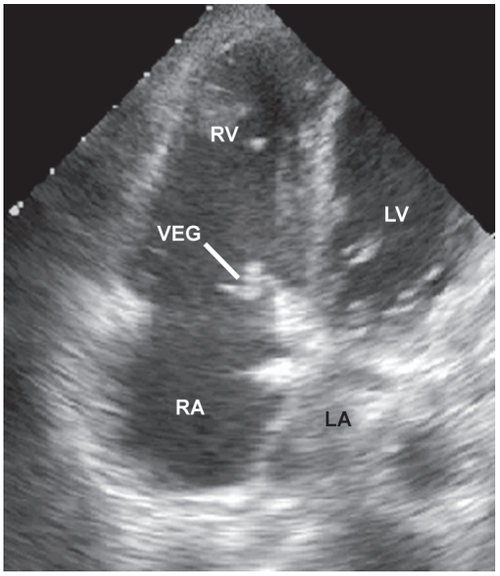

Fig. 12.25: An apical 4C view showing vegetation on tricuspid valve

seen. Similarly, embolised vegetations have been seen floating free in the right ventricle or pulmonary artery. Occasionally the presence of normal anatomic variants such as Chiari network or prominent Eustachian valve may cause diagnostic confusion, more particularly with transthoracic imaging; similarly venous catheters erroneously placed in the right atrium need to be identified and distinguished from vegetations. Right atrial thrombus may be distinguished from vegetation in that it is less likely to lie in the path of the jet and tends to layer on the right atrial wall. Past infection with damage to the tricuspid valve is commonly seen in this group, so the presence of vegetation does not in itself signify the presence of active infection. Extensive valve destruction with failure of leaflet cooptation and severe tricuspid regurgitation is a common sequel to tricuspid endocarditis. Although older or healed vegetations tend to be more echogenic and may even be calcified, this finding cannot reliably distinguish new from old infection. It should be clearly understood that echocardiographic findings need always to be taken in their clinical context. The finding of new or worsening tricuspid regurgitation, which is otherwise unexplained, should always prompt a diligent search for evidence of tricuspid endocarditis in the injection drug using patient.

Transesophageal echocardiography (TEE): Many injection drug users have good thoracic ultrasound windows meaning that high resolution images can be obtained with transthoracic echocardiographic examination in many patients (Figs 12.31–12.38). This, combined with the relative proximity of the tricuspid valve to the ultrasound transducer, means that this valve is often well imaged by the transthoracic technique. Careful attention to the adjustment of sector width, depth, and focus settings will help in accurate identification of vegetations. Under some circumstances higher frequency transducers, e.g. 4 MHz or broad-band transducers switched to a 'resolution setting' may be used to improve spatial resolution. Alternatively use of the 'zoom function' (on some machines) may assist with lesion identification. The need for routine transoesophageal echocardiography (TEE) in right-sided

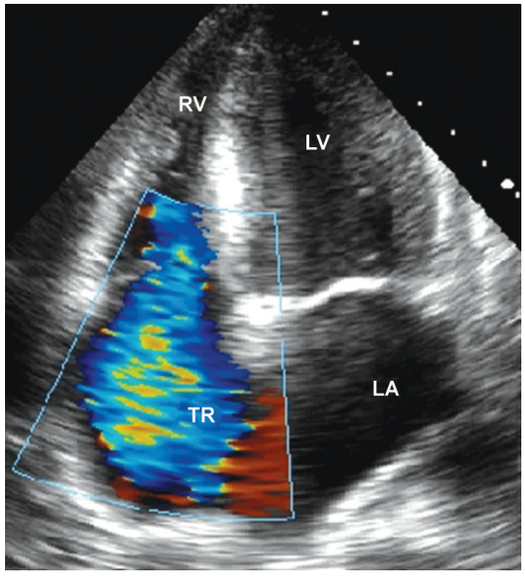

Fig. 12.26: Tricuspid regurgitation jet due to vegetation on the tricuspid valve

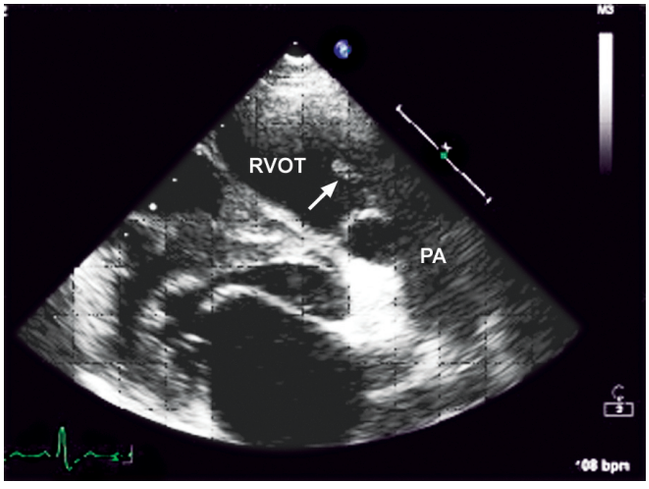

Fig. 12.27: Two-dimensional transthoracic echocardiography showing vegetations attached to the pulmonary valve cusps (arrow). RVOT=right ventricular outflow tract; PA=pulmonary artery

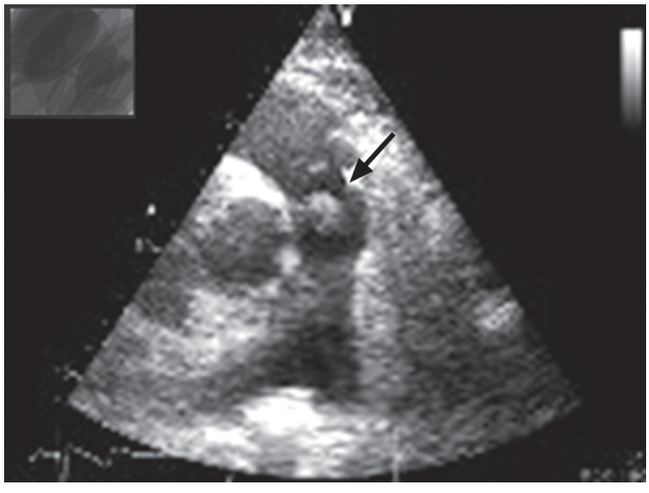

Fig. 12.28: Short-axis view of vegetation on pulmonary valve after 6 weeks of antibiotic therapy, indicated by the white arrow

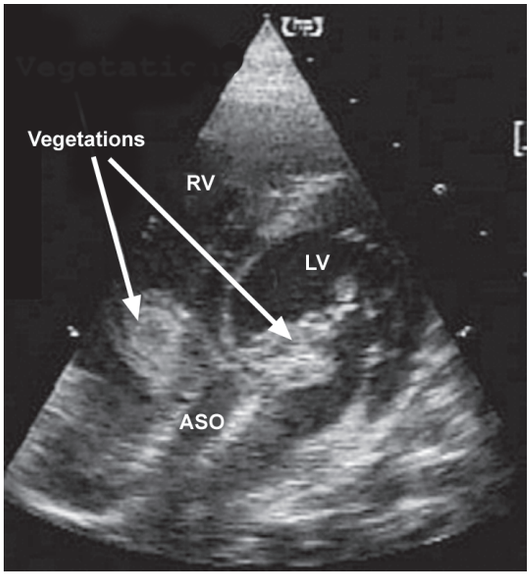

Fig. 12.29: Transthoracic echocardiographic image in a modified apical 4-chamber imaging plane showing a large vegetation located above the tricuspid valve. The ASO device is seen within the atrial septum, and the mitral valve vegetation is again visualized. RV=indicates right ventricle; LV=left ventricle

endocarditis is therefore questionable. TEE may be useful in detecting paravalvar abscess formation and for diagnosing unusual forms of right-sided endocarditis such as pulmonary valve involvement or infection on the Eustachian valve. The rationale for this approach is the simplicity and reduced cost of TTE and the importance of having the TTE information to direct and target a subsequent TEE examination appropriately. If there is a moderate or high suspicion of IE, and the initial TTE is negative, the TTE is repeated after an interval of about 1 week. TEE is then used in those patients in whom diagnostic quality images are not obtained with transthoracic imaging, and those who have negative TTE examinations where the suspicion of endocarditis is moderate or high (especially in the setting of staphylococcal bacteraemia). Occasionally pacing wires or right-sided prosthetic valves are encountered; where there is a suspicion of endocarditis TEE is usually indicated. Rotation of the crystal array and angulation of the probe tip in order to visualise the valves in a number of orientations is mandatory during TEE.

HIV and right-sided endocarditis: Significant immunosuppression (CD4 count <200/mm) is associated with a higher mortality rate in right-sided IE in HIV infected injection drug users, though it is not clear that this increased mortality is as a consequence of the IE. As in non-HIV infected patients with right-sided endocarditis, the

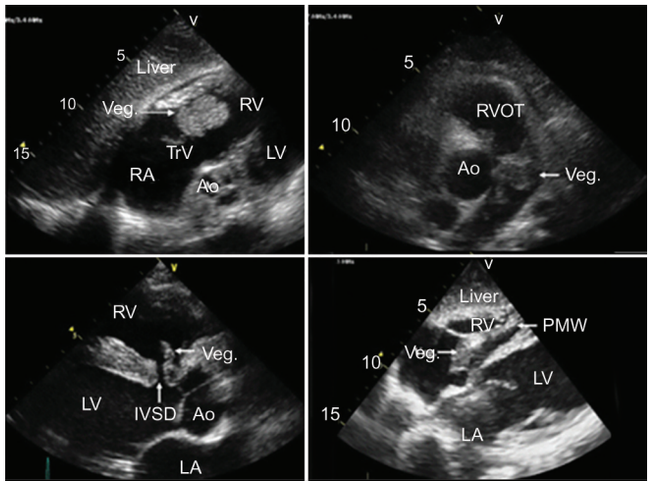

Fig. 12.30: Cases of right-sided infective endocarditis. AO=aorta; LV=left ventricle; LA=left atrium; RV=right ventricle; Veg=vegetation; PMW=pacemaker wire; IVSD=interventricular septal defect; TrV=tricuspid valve

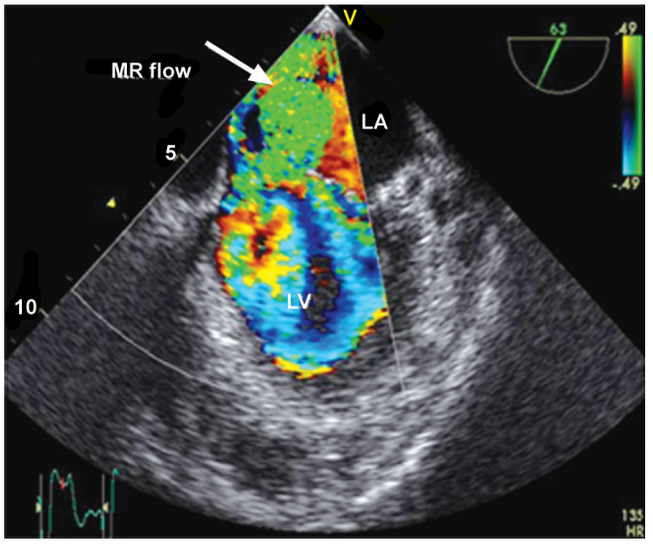

Fig. 12.32: Color-Doppler transesophageal study demonstrated aneurismal cavity with central perforation due to infective endocarditis in midpart of anterior mitral leaflet with severe mitral regurgitation

involvement of the left-sided valves is predictive of an increased risk of death.

Treatment of right-sided endocarditis: Short course antibiotic treatment for right-sided endocarditis and management of addiction. The successful management of a complicated case often requires the close cooperation of a cardiologist, an infectious disease physician, and occasionally a cardiac surgeon. The role of physicians in managing intercurrent drug withdrawal and maintaining the patient in hospital has been understated in the past methadone and/or other agents may be needed to control withdrawal symptoms. These patients may be difficult and disruptive and often engender negative attitudes in health

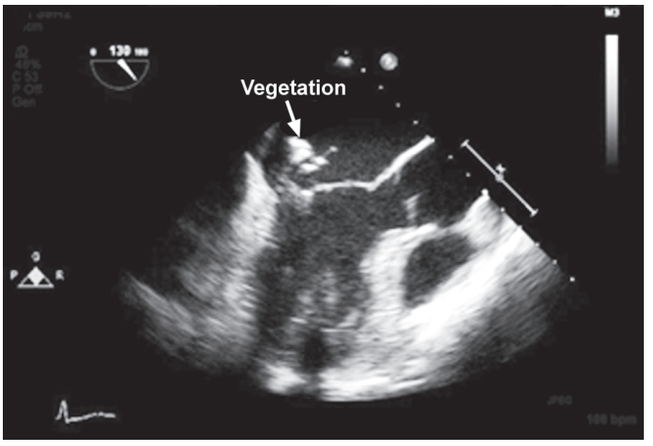

Fig. 12.31: Transoesophageal echocardiogram showing vegetation in the P2 scallop of the posterior mitral valve leaflet

care professionals. Their lack of adherence to in-hospital treatment is a major practical hurdle and has stimulated interest in developing shorter duration antibiotic regimens. There is reasonable evidence that short course antibiotic treatment for uncomplicated right-sided endocarditis is effective. The benefit of gentamicin in native valve endocarditis lies in earlier defervescence of fever and the sterilisation of blood cultures; there is no proven survival advantage. In the presence of a relative or absolute contraindication to gentamicin, therefore, a 2-week course of cloxacillin alone may be adequate. In the event that the patient cannot be persuaded to stay in hospital for the full two weeks, a 28-day course of oral treatment with ciprofloxacin and rifampin is prescribed, ideally with administration in a supervised setting such as a drug treatment facility. There are some situations in which short course antibiotic treatment is not appropriate In general nonstaphylococcal right-sided endocarditis is treated in a similar fashion to left-sided endocarditis (Table 12.12).

Prognosis and surgical treatment of right-sided endocarditis: Right-sided endocarditis is generally regarded as having a relatively benign prognosis and inhospital mortality is less than 10% (Table 12.13). Most will survive even if they leave hospital before the full course of treatment has been completed. As follow up in the injection drug using population is notoriously difficult, few data are available on their long term outlook. It is clear that there will be a significant late mortality from causes other than IE and right heart failure, such as noncardiac infections, drug overdose, and AIDS related complications. Mortality is higher where there is left-sided involvement. Fortunately most patients can be treated medically, with surgery being necessary in only a small minority of cases. Indications for surgical treatment are better defined for left than for right-sided endocarditis. Sepsis, which is uncontrolled despite adequate antibiotic treatment, and intractable right heart failure despite appropriate medical treatment, are the most important indications for surgical intervention. The finding of a paravalvar abscess or fungal endocarditis are usually indications for surgery. Recurrent pulmonary embolism

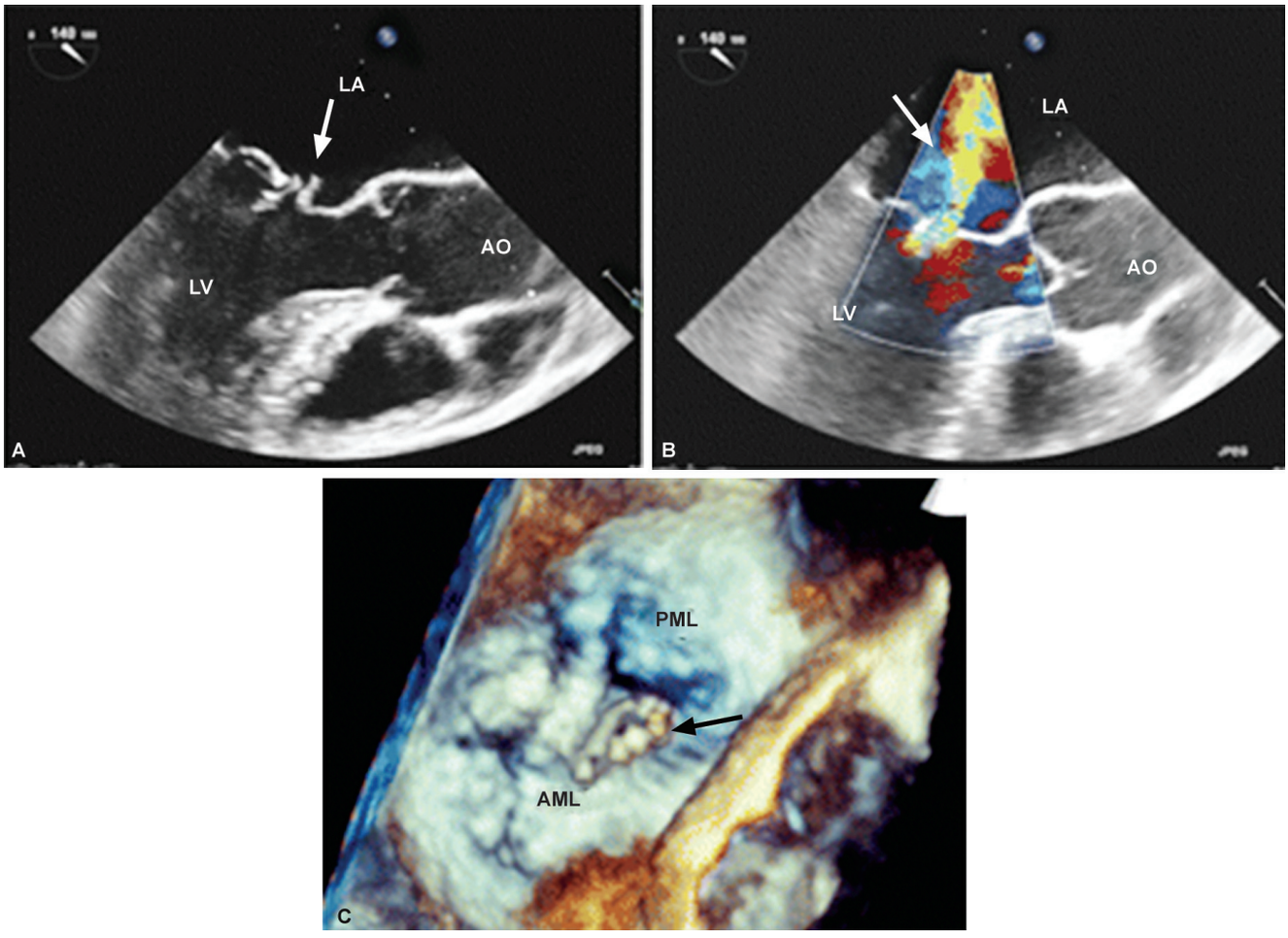

Fig. 12.33: Perforation of the anterior mitral leaflet (arrow). (A) TEE. (B) Color-Doppler. (C) Three-dimensional echocardiography. LA=left atrium; LV=left ventricle; AML=anterior mitral leaflet; PML=posterior mitral leaflet; Ao=aorta

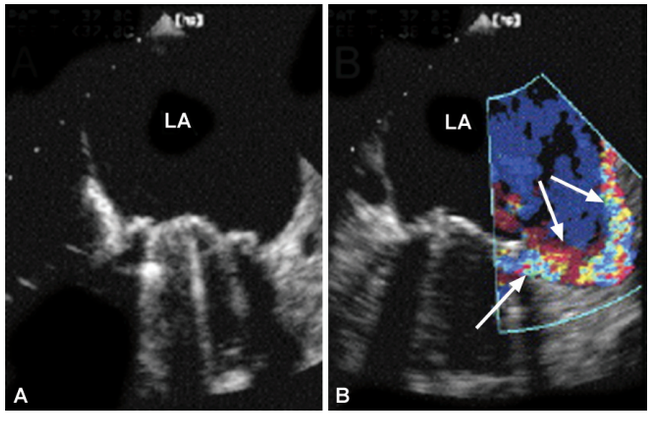

Fig. 12.34: TEE echocardiography showing vegetations on mitral valve prosthesis

following the initiation of antibiotic treatment may occur and does not in itself represent an indication for surgery. Some authors have felt that large vegetation size (diameter >10 mm) in the context of persisting fever identifies a set of patients who are likely to benefit from surgery. Others have felt that many of these patients will eventually recover with medical treatment. Very large vegetations (>20 mm), however, are associated with a poor outcome. Patients may

Table 12.12: Injection drug use and right-sided endocarditis—key points

- In inner city communities most cases of infective endocarditis (IE) occur in injection drug users; many of these will have right-sided IE caused by staphylococci
- If injection drug users with bacteraemia from an inner city demographic are considered, up to 41% will have evidence of endocarditis
- The conjunction of bacteraemia, fever, and multiple pulmonary infiltrates on chest radiography should always prompt a search for right-sided IE
- A transoesophageal echocardiographic examination is not necessary in many cases of right-sided IE
- Coexistent medical problems such as hepatitis or HIV disease may be present
- Successful treatment of right-sided IE in injection drug users requires a multidisciplinary approach
- Most patients will recover with medical treatment: short course or rarely oral antibiotic treatment may be useful in certain situations

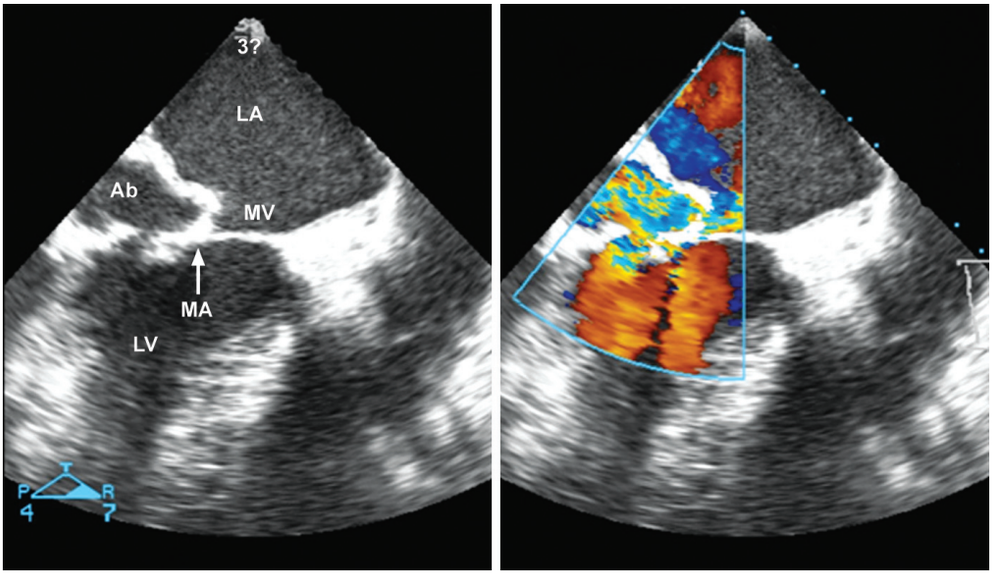

Fig. 12.35: Transesophageal echocardiogram showing mitral paravalvular abscess with ventriculo-atrial fistula. LA=indicates left atrium; MV=mitral valve; MA=mitral annulus; LV=left ventricle; and Ab=abscess

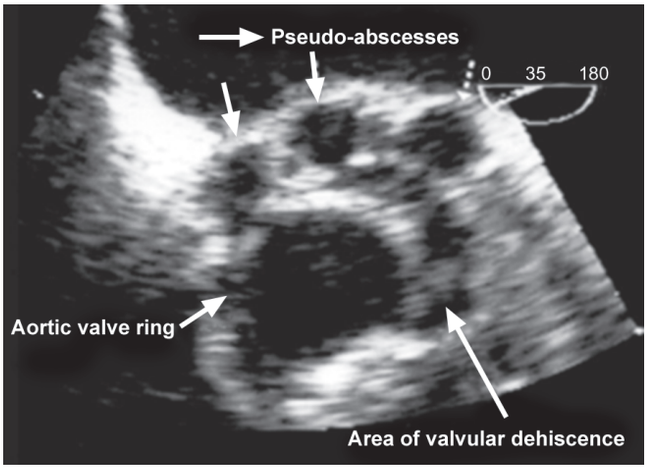

Fig. 12.36: Multiple pseudo-abscesses following aortic valve replacement Mid-oesophageal short-axis view magnified with zoom

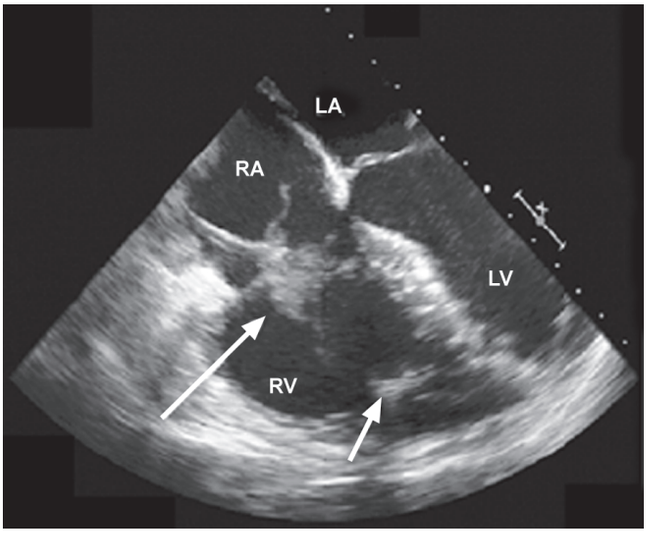

Fig. 12.37: Transesophageal echocardiography. Four chamber view shows multiple vegetations on the tricuspid valve (long arrow) and pacing leads (short arrow)

also require an operation to treat concomitant left-sided endocarditis. Enthusiasm for surgery is tempered by the knowledge that the majority of patients will resume injection drug use following hospital discharge. Surgical approaches vary, with valve removal or replacement being the historical, commonly recommended approaches. Both approaches are controversial and there is a lack of controlled trials in the literature upon which to base decision making. Valvectomy may result in permanent damage to the right ventricle and ultimately intractable right heart failure and death. Significant early mortality (11 %) was reported in one group where this approach was used. More recent attention has focused on tricuspid valve vegetectomy or repair. The repair has the advantage of avoiding or minimising the implantation of foreign material in the infected area while preserving the function of the valve. Several different techniques have been used, including cusp resection (rendering the valve bicuspid), commissural plication, the use of artificial chordae, and pericardial patch repair of the tricuspid leaflet (sometimes in conjunction with mobilisation of the secondary chordae and tricuspid annuloplasty). Where extensive valvar destruction has occurred, replacement of the tricuspid valve may be necessary. When valve replacement is unavoidable our current approach is to use cryopreserved mitral homografts in the tricuspid position, which usually requires the addition of a tricuspid ring to provide annular stability. Reinfection of the valve can be anticipated in some cases; when this occurs, antibiotic treatment may result in a cure of the prosthetic valve endocarditis.

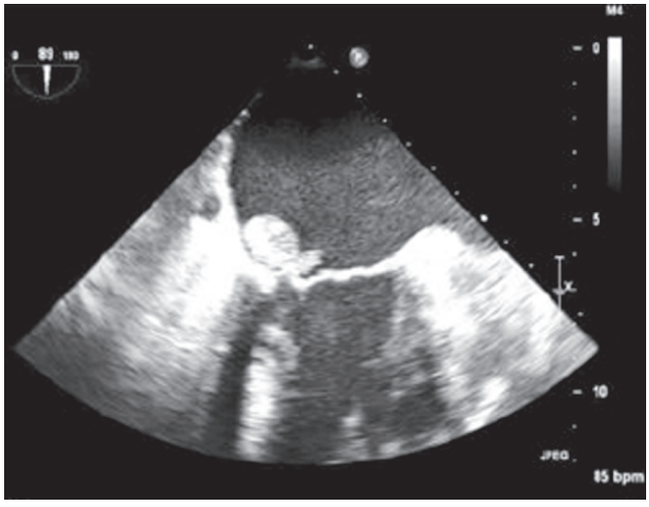

Fig. 12.38: Transesophageal echocardiogram showing a 2 cm mobile mass on the atrial surface of the posterior mitral valve leaflet consistent with a vegetation

Prevention

It is possible that harm reduction strategies aimed at reducing injection frequency (such as methadone availability) or clean injection strategies (clean injection education, injection rooms, needle exchange programmes or legal heroin) may have a beneficial effect. The clinical suspicion is low. If the clinical suspicion is high TEE should be performed. TEE should also be performed if the results of the TTE are equivocal owing to underlying structural abnormalities or poor acoustic windows. If the TEE is negative, observation or reevaluation of the clinical data are warranted. If the suspicion of endocarditis is high TEE should be repeated after 7–10 days to allow potential vegetations to become more apparent. A repeated negative study should virtually rule out the diagnosis unless TEE images are of poor quality.

Conclusion

To date, definitive studies of infective endocarditis have been difficult to perform because of its heterogenous nature. Launched in 1999, the international collaboration on endocarditis was conceived to develop a large global database of patients whose clinical, echocardiographic, and microbiological findings have been characterised using standard methodology. Modification of the original Duke criteria is now proposed to enhance diagnostic sensitivity, especially in culture negative cases. Increased emphasis on symptoms and signs coupled with improved likelihood of identification of a causative pathogen using serology, additional culture, or newer histological and molecular techniques will improve the sensitivity of the diagnosis and increase therapeutic specificity. These measures, combined with close collaboration and communication between the cardiologist, cardiac surgeon, and microbiologist, are essential to ensure optimal diagnosis and management and a favourable impact on patient outcome.

Table 12.13: Echocardiographic features suggesting potential need for surgical intervention

- Vegetation
- Persistent vegetation after systemic embolization
- Anterior mitral leaflet vegetation, particularly with size >10 mm^2
- One or more embolic events during first 2 weeks of antimicrobial therapy
- Two or more embolic events during or after antimicrobial therapy
- Increase in vegetation size after 4 weeks of antimicrobial therapy
- Valvular dysfunction
- Acute aortic or mitral insufficiency with signs of ventricular failure
- Heart failure unresponsive to medical therapy
- Valve perforation or rupture
- Perivalvular extension
- Valvular dehiscence, rupture, or fistula
- New heart block
- Large abscess, or extension of abscess despite appropriate antimicrobial therapy.

BIBLIOGRAPHY

1. A useful contemporary snapshot of IE epidemiology. Weisse AB, Heller DR, Schimenti RJ, et al. The febrile parenteral drug user: a prospective study in 121 patients. J Am Med 1993;94: 274–80.
2. Additional references appear on the Heart website-www. heartinl.com/supplemental
3. Alestig K, Hogevik H, Olaison l. Infective endocarditis: a diagnostic and therapeutic challenge for the new millennium. Scand) Infect Dis 2000;32:343–56.
4. Alexander RW, Schlent RC, Foster V, (Eds.). Hurst's The Heart 9/ed. New York: MGraw-Hill, 1998:2205–42.
5. Arbulu A, Holmes R, Asfaw I. Surgical treatment of intractable right-sided infective endocarditis in drug addicts: 25 yrs experience.) Heart Valve Dis 1993;2:129–37; discussion 138–9.
6. Bayer AS, Bolger AF, Taubert KA, et al. Diagnosis and management of infective endocarditis and its complications. Circulation 1998;98:2936–48.
7. Blumberg EA, Karalis DA, Chandrasekaran K, et al. Endocarditis-associated paravalvular abscesses. Do clinical parameters predict the presence of abscess? Chest 1995; 107:898–903.
8. Cabell CH, Abrutyn E. Progress toward a global understanding of infective endocarditis. Early lessons from the International Collaboration on Endocarditis investigation. Infect Dis Clin North Am 2002;16:255–72.
9. Cabell CH, Jollis JG, Peterson GE, et al. Changing patient characteristics and the effect on mortality in endocarditis. Arch Intern Med 2002;162:90–4.
10. Carozza A, Renzulli A, De FM, et al. Tricuspid repair for infective endocarditis: clinical and echocardiographic results. Texas Heart Inst J 2001;28:96–101. Contemporary insight into surgical approaches to tricuspidendocarditis.

11. Case control study of a cohort of injection drug users that compares those with and without HIV infection.
12. Chastre J, Trouillet JL. Early infective endocarditis on prosthetic valves. fur Heart) 1995;16(suppl B):32–8,217.
13. Chon Kl. Early clinical course and long-term outcome of patients with infective endocarditis complicated by perivalvular abscess. Can Moo Assoc 2002;167:19–24.
14. Choussat R, Thomas D, Isnard R, et al. Perivalvular abscesses associated with endocarditis: clinical features and prognostic factors of overall survival in a series of 233 cases. Perivalvular abscess French multicenter study. for Heart 1999;20:232–41.
15. Chua JD, Wilkoff B, et al. Diagnosis and management of infections involving implantable electrophysiologic cardiac devices. Ann Intern Med 2000;133:604–8.
16. Cicalini S, Forcina G, De Rosa FG. Infective endocarditis in patients with human immunodeficiency virus infection. Infect 2001;42:267-71.Retrospective study of IE in an HIV population.
17. Correspondence to: Professor Francois Delahaye, Hopital cardiovasculaire et pneumologique, BP Lyon Montchat, 69394-Lyon Cedex 03, France; francois.delahaye@chu-lyonJr.
18. Crane LR, Levine DP, Zervos MJ, et al. Bacteremia in narcotic addicts at the Detroit Medical Center. I. Microbiology, epidemiology, risk factors, and empiric therapy. Rev Infect Dis 1986;8:364–73.
19. D'Udekem Y, David TE, Feindel CM, et al. Long-term results of surgery for active infective endocarditis. fur) Cardiothorac Surg 1997;11:46–52.
20. Dajani AS, Taubert KA, Wilson W, et al. Prevention of bacterial endocarditis: recommendations by the American Heart Association. Circulation 1997;96:358–66.
21. Daniel WG, Mogge A, Martin RP, et al. Improvement in the diagnosis of abscesses associated with endocarditis by transesophageal echocardiography. N Eng J Med 1991;324: 795–800.
22. Delahaye F, Celard M, Roth O, de Gevigney G, Hopital cardiovasculaire et pneumologique, Lyon, France.
23. Di Salvo G, Habib G, Pergola V, et al. Echocardiography predicts embolic events in infective endocarditis. J Am Col Cordial 2001;37:1069–76.
24. Dillon JC, Feigenbaum H, Konecke LL, et al. Echocardiographic manifestations of volvular vegetations. Am Heart 1973;6:698–704.
25. DiNubile MJ. Short-course antibiotic therapy for right-sided endocarditis caused by Staphylococcus aureus in injection drug users. Ann Intern Med 1994;121:873–6.Review focusing on short course antibiotic treatment in right-sided IE.
26. Dressler FA, Roberts WE. Infective endocarditis in opiate addicts:analysis of 80 cases studied at necropsy. Am Cardiol 1989;63:1240–57.
27. Durack DT, Lukes AS, Bright DK, et al. New criteria for diagnosis of infective endocarditis: utilization of specific echocardiographic findings. Am J Med 1994;96:200–9.
28. Durack DT, Lukes AS, Bright DK. New criteria for diagnosis of infective endocarditis: utilization of specific echocardiogrophic findings. Duke endocarditis service. Am J Med 1994;96:200–9. Classic paper that underscores the key role of echocardiography in the diagnosis of IE; it has formed the basis for increased accuracy in the diagnosis of IE and provided a solid basis for defining entry criteria in clinical and epidemiological studies.
29. Durack DT, Lukes AS, Bright DK. New criteria lor diagnosis of infective endocarditis: utilization of specific echocardiographic Finding: Duke Endocarditis Service. Am Moo 1994; 96:200–9.
30. Durack DT. Prevention of infective endocarditis. N Engl J Med 1995;332:38–44. Durack DT, Lukes AS, Bright DK. New criteria for diagnosis of infective endocarditis: utilization of specific echocardiographic findings. Am J Med 1994;96: 200–209.
31. Erbel R, Rohmann S, Drexler M, et al. Improved diagnostic value of echocardiography in potients with infective endocarditis by transoesophageal approach. A prospective study. Eur Heart 1988;9:43–53.
32. Fournier PE, Casalta JP, Habib G, et al. Modification of the diagnostic criteria proposed by the Duke endocarditis service to permit improved diagnosis of Q fever endocarditis. Am J Med 1996;100:629–33.
33. Gillinov AM, Shah RV, Curtis WE, et al. Valve replacement in patients with endocarditis and acute neurologic deficit. Ann Thorac Surg 1996;61:1125–30.
34. Gordon SM, Serkey JM, Longworth DL, et al. Early onset prosthetic valveendocarditis: the Cleveland Clinic experience 1992–7. Ann Thorac Surg2000;69:1388–92.
35. Grijalva M, Horvath R, Dendis M, et al. Molecular diagnosis of culture negative infective endocarditis: clinical validation in a group of surgically treated patients. Heart 2003;89:263–8.
36. Habib G, Derumeaux G, Avierinos J-F, et al. Value and limitations of the Duke criteria for the diagnosis of infective endocarditis. J Am Coll Cardiol 1999;33:2023–9.
37. Hecht S, Berger M. Right-sided endocarditis in intravenous drug users. Prognostic features in 102 episodes. Ann Intern Med 1992;117:560–6. Definitive retrospective study of right-sided IE.
38. Heiro M, Nikoskelainen J, Engblom E, et al. Neurologic manifestations of infective endocarditis: a 17-year experience in a teaching hospital in Finland. Arch Intern Mad 2000;160: 2781–7.
39. Heldman AW, Hartert TV, Ray SC, et al. Oral antibiotic treatment of right-sided staphylococcal endocarditis in iniection drug users: prospective randomized comparison with parenteral therapy. Am J Med1996;101:68–76. Oral treatment compared prospectively with intravenous treatment in right-sided IE.
40. Hoen B, Alia F, Selton-Suty C, et al. Changing profile of infective endocarditis: results of a 1-year survey in France JAMA 2002;288:75–81.
41. Hoen B, Alia F, Selton-Suty C, et al. For the AEPEI group. Changing profile of infective endocarditis. Results of a 1-year survey in France. JAMA 2002;288:75–81.
42. Houpikian P, Raoult D. Diagnostic methods. Current best practices and guidelines for identification of difficult-to-culture pathogens in infective endocarditis. Infect Dis Clin N Am 2002;16:377–92.
43. John MD, Hibberd PL, Karchmer AW, et al. Staphylococcus aureus prosthetic valve endocarditis: optimal management and risk factors for death. Infect Dis 1998;26:1302–9.

44. Karalis OO, Bansal RC, Hauck AJ, et al. Transesophageal echocardiographic recognition of subaortic complications in aortic valve endocarditis. Circulation 1992;86:353–62.
45. Karchmer AW. Infecious Endocarditis. In: Braunwald E, (Ed.) Heart disease: a textbook of cardiovascular medicine, 6th ed. Philadelphia: WB Saunders, 2002:1723–48. Otto C. The practice of clinical echocardiography, 2/e. Philadelphia: WB Saunders, 2002:451–69.
46. Khanderia BK, Seward JB, Oh JK, et al. Value and limitations of transesophageal echocardiography in assessment of mitral valve prostheses. Circulation 1991;83:1956–68.
47. Knosalla C, et al. Surgical treatment of active infective aortic valve endocarditis with associated periannular abscesses with 11 year results. Eur Heart J 2000;21:490–7.
48. Knosalla C, Weng Y, Yankah AC, et al. Surgical treatment of active infective aortic valve endocarditis with associated periannular abscess. 11 year results. Eur Heart 2000;21:490–7.
49. Lamas C, Eykyn SJ. Suggested modifications to the Duke criteria for the clinical diagnosis of native valve and prosthetic valve endocarditis: analysis of 118 pathologically proven cases. Clin Infect Dis 1997;25:713–9.
50. Lamas CC, Eykyn SJ. Blood culture negative endocarditis endocarditis: analysis of 63 cases presenting over 25 years. Eur Heart 2003;89:258–62.
51. Lengyel M. The impact of transesophageal echocardiography on management of prosthetic valve endocarditis: experience of 31 cases and review of the literature. Heart Valve Dis 1997;6:204–11.
52. Lepidi H, Durack DT, Raoult D. Diagnostic methods. Current best practices and guidelines for histologic evaluation in infective endocarditis. Infect Dis Clin N Am 2002;16:339–61.
53. Li JS, Sexton DJ, Mick N, et al. Proposed modifications to the Duke criteria for the diagnosis of infective endocarditis. Clin Infect Dis 2000;30:633–8.
54. Li JS, Suton DJ, Mick N, et al. Proposed modifications to the Duke criteria lor the diagnosis of infective endocarditis C in Infect Dis 2000;30:633–8.
55. Lisby G, Gutschik E, Durack DT. Molecular methods for diagnosis of infective endocarditis. Infect Dis Clin North Am 2002;16:393–412.
56. Manolis AS, Melita H. Echocardiographic and clinical correlates in drug addicts with infective endocarditis. Implications 01 vegetation size. Arch Intern Med 1988;148:2461–5.
57. Mathew J, Addai T, Anand A et al. Clinical features, site of involvement, bacteriologic findings, and outcome of infective endocarditis in intravenous drug users. Arch Intern Med 1995;155:1641–8. Important retrospective cohort study of intravenous drug users with native valve endocarditis.
58. Mestres CA, Miro JM, Pare JC, et al. Six-year experience with cryopreserved mitral homogralts in the treatment of tricuspid valve endocarditis in HIV-infected drug addicts. J Heart Valve Dis 1999;8:575–7.
59. Millar BC, Moore JE, Mallon P, et al. Molecular diagnosis of infective endocarditis–a new Duke's criterion. Scand J Infect Dis 2001;33:673–80.
60. Miyagishima R, Brumwell M, Eric JW, et al. Tricuspid valve replacement using a cryopreserved mitral homogralt. Surgical technique and initial results. Heart Valve Dis 2000;9:805–8; discussion 808–9.
61. Moore JE, Millar BC, Yongmin X, et al. A rapid molecular assay for the detection of antibiotic resistance determinants in cause of infective endocarditis. J Appl Microbiol 2001;90: 719–26.
62. Moyer D, Edwards JE. Fungal endocarditis. In: Kaye D, (Ed.) Infective endocarditis. New York: Raven Press, 1992:299–312.
63. Mugge A, Daniel WG, Frank G, et al. Echocardiography in infective endocarditis: reassessment of prognostic implications of vegetation size determined by the transthoracic and the transesophageal approach. Am Coli Cardio 1989;14: 631–8.
64. Olaison L, Pettersson G. Current best practice and guidelines: indications for surgi-cal intervention in infective endocarditis. Infect Dis Clin North Am 2002;16: 453–75.
65. Olaison L, Pettersson G. Current best practices and guidelines indications for surgical intervention in infective endocarditis. Infect Dis Clin North Am 2002;16:453–75.
66. Palepu A, Cheung SS, Montessori V, et al. Factors other than the Duke criteria associated with infective endocarditis among injection drug users. Cl in Invest Med 2002;25: 118–25. This study examines the usefulness of the Duke criteria in an intravenous drug user population and non-Duke clinical variables that predict a diagnosis of IE.
67. Raoult D, et al. Cultivation of the bacillus of Whipple's disease. N Engl J Med 2000; 342:620–5.
68. Reynolds HR, Jagen MA, Tunick PA, et al. Sensitivity of transthoracic versus transesophageechocardiography lor the detection of native valve vegetations in the modern era. Am So Echocardiogr 2003;16:67-70.
69. Ribera E, Miro JM, Cortes E, et al. Influence of human immunodeficiency virus 1 infection and degree of immunosuppression in the clinical characteristics and outcome of infective endocarditis in intravenous drug users. Arch Intern Med 1998;158:2043–50.
70. Robbins M, Frater R, Soeiro R, et al. Influence of vegetation size on clinicol outcome of right-sided infective endocarditis. Am J Med 1986;80:165–71.
71. Rohmann S, Erbel R, Gorge G, et al. Clinical relevance of vegetation localization by transoesophageal echocardiography in infective endocarditis. Eur Heart. 1992;13:446–52.
72. Rozich JD, Edwards WD, Hanna RD, et al. Mechanical prosthetic valve associated strands: Pathologic correlates to transesophageal echocardiography. Am Soc Echocardiogr 2003;J6:97–100.
73. San Roman JA, Vilacosta I, Zamorano J, et al. Transesophageal echocardiography in right-sided endocarditis.) Am Coli Cordial 1993;21:1226–30. This paper questions the routine role of TOE in the diagnosis of right-sided endocarditis.
74. Sanders GP, Yeon SB, Grunes J, et al. Impact of a specific echocardiographic report comment regarding endocarditis prophylaxis on compliance with American Heart Association Recommendations. Circulation 2002;106:300-303.
75. Sexton DJ, Spelman D. Current best practice and guidelines: assessment and management of complications in infective endocarditis. Infect Dis Clin North Am 2002; 16:507–21.
76. Shapiro SM, Young E, De Guzman S, et al. Transesophageal echocardiography in diagnosis of infective endocarditis. Chest 1994;105:377–82.

77. Shively BK, Gurule FT, Roldan CA, et al. Diagnostic value of transesophogeal compored with transthoracic echocordiography in infective endocarditis. Am Coli Cardio 1991;18: 391–7.
78. Sochowski RA, Chan K-I. Implicotion of negative results on a monoplane transesophageal echocardiographic study in patients with suspected infective endocarditis. Am Coli Cardio 1993;21:216–21.
79. Son Roman JA, Vilacosta I, Zamorano JL, et al. Transesophageal echocardiography in right-sided endocarditis. Am Coli Cardio 1993;21:1226–30.
80. Truninger K, Attenhofer Jost CH, et al. Long term follow up of prosthetic valve endocarditis: what characteristics identify patients who weretreated successfully with antibiotics alone? Heart 1999;82:714–20.
81. von Reyn CF, Levy BS, Arbeit RD, et al. Infective endocarditis: an analysis based on strict case definitions. Ann Intern Med 1981;94:505–17.
82. Wallace SM, et al. Mortality from infective endocarditis: clinical predictors of out-come. Heart 2002;88:53–60.
83. Wilson LE, et al. Prospective study of infective endocarditis among injection drug users. J Infect Dis 2002;1 85:1761–66.
84. Wilson LE, Thomas DL, Astemborski J, et al. Prospective study of infective endocarditis among injection drug users. Infect Dis 2002;185: 1761–6.
85. Wilson WR, Karchmer AW, Dajani AS, et al. Antibiotic treatment of adults with infective endocarditis due to streptococci, enterococci, staphylococci, and HACEK microorganisms. JAMA 1995;274:1706–13.

13 Recognition and Management of Acute Myocarditis

Myocarditis is an acute or chronic inflammatory disease of the myocardium which can be viral, postinfectious immune or primarily organ-specific autoimmune. Clinical manifestations of acute and chronic myocarditis are extremely varied, ranging from mild to severe. Affected patients may recover or develop (dilated) cardiomyopathy (DCM) with life-threatening symptoms including heart failure, conduction disturbances, arrhythmias, cardiogenic shock or sudden cardiac death.

The diagnosis of myocarditis is a challenging process and not only because of a diverse presentation; other problems are limited sensitivity of endomyocardial biopsies (EMB) and overlapping symptoms. Furthermore, the diagnosis is not well defined. However, early diagnosis is mandatory to address specific etiology-directed therapeutic management in myocarditis that influences patient morbidity and mortality.

INCIDENCE AND PREVALENCE

Difficult to determine; the majority of patients are clinically silent and resolve spontaneously without treatment. Highly variable incidence owing to differences in methods used for diagnostic evaluation. One estimate has been 8–10 cases per 100,000 of the US population. The prevalence of myocarditis among unselected autopsy series is as high as 1–5%. The prevalence of viral myocarditis is variable and is related to the periodic cycle of viral epidemics. A recent study pointed out that myocarditis is a frequently underdiagnosed disorder. Viral RNA was detected in a large amount of biopsy samples obtained from patients that were initially diagnosed as idiopathic dilated cardiomyopathy (IDCM). These findings suggest that viral myocarditis is frequently the etiology of heart failure in patients who were initially identified as having IDCM using current standard diagnostic techniques.

ETIOLOGICAL FACTORS

The most common form of myocarditis, endemic in both rural Central and South America, is Chagas' disease, caused by the parasitic protozoan *Trypanosoma cruzi*. In North America, viral infections cause most cases of myocarditis. Enteroviruses, most importantly coxsackievirus B, are the most frequently reported cause of epidemics of viral myocarditis in children. However, more recent reports indicated that adenoviral infection is as common a cause as enteroviral infection is, if not more so. Rarely, bacteria, fungi, protozoa, parasites, and rickettsiae are causative agents. Myocarditis has also been associated with immune-mediated diseases, collagen vascular diseases, and toxins (Table 13.1).

EPIDEMIOLOGICAL FEATURES OF MYOCARDITIS

Occurrence of myocarditis can be affected by viral epidemics. An outbreak of coxsackievirus B in Europe in 1965 correlated with cardiac dysfunction in 5% of infected patients. Incidences were as high as 12% that same year in Scotland, Finland, and Austria. Seasonal viral distributions have been recognized for decades (influenza prevalent during winter months; poliovirus and coxsackievirus A and B typically isolated during summer and fall). Myocarditis has been a prominent finding during epidemics of influenza; thus, occurrence may be seasonal.

AGE AND GENDER

Age plays a marked role in prevalence. During the neonatal period, myocarditis is usually abrupt, severe, and often fatal, with mortality as high as 75%. Infants infected with coxsackievirus B during the first year of life have a high incidence of myocarditis. Myocarditis has been linked to sudden infant death syndrome, because inflammatory infiltrates have been found on autopsies of some victims.

Table 13.1: Aetiology of myocarditis

Viruses	**Immune-mediated diseases**	**Drugs**
Coxasackievirus A	Rheumatoid arthritis	Sulfonamides
Coxasackievirus B	Rheumatic fever	Cyclophosphamide
Echovirus	Ulcerative colitis	Acetazolamide
Adenovirus	Systemic lupus erythematosis	Amphotericin B
Rubella virus		Indomethacin
Measles virus	**Toxins**	Tetracycline
Varicella virus	Ethanol	Phenytoin
Polio virus	Heavy metals: iron, copper, lead	Penicilin
Mumps virus	Arsenic	
Herpesvirus	Bee and wasp sting	**Fungi and yeast**
Epstein-Barr virus	Carbon monoxide	Aspergilus
Cytomegalovirus	Scorpion bites	Candida
Human immunodeficiency virus	Spider bites	
	Snake bites	**Protozoa**
Bacteria	*Toxoplasma gondii*	*Trypanosoma cruzi*
Meningococci		
Borrelia burgdorferi (Lyme disease)	**Physical conditions or agents**	**Parasties**
Salmonellae	Hyperpyrexia	*Ascaris*
Mycobacteria	Electric shock	*Schistosoma*
Streptococci	Radiation	Trichinella spirals

Incidence increases again during late childhood and adolescence; the myocarditis usually has a delayed onset and patients recover.

Male predominance has been noted with coxsackievirus B heart disease, particularly in adolescents and adults. In these age groups, two-thirds to three-quarters of patients with myocarditis are male. Male predominance has also been reported with coxsackievirus A myocarditis and poliomyelitis. Whether or not differences between the sexes occur in other viral infections is unknown.

PATHOPHYSIOLOGY

Although viral infection is the most common initiator of acute myocarditis, the subsequent autoimmune response plays a lead role in myocyte injury. The principal mechanism of myocardial damage is not just viral replication; it includes cell-mediated immunological reactions.

The pathophysiology of myocarditis has been studied in mice infected with a cardiotropic virus, such as coxsackievirus B. After systemic infection, the virus enters the myocyte, where it replicates in the cytoplasm of the cell. Some replicated viruses then enter the interstitium and are phagocytized by activated macrophages. Macrophage activation is due to both viral particles in the interstitium and the release of interferon γ by natural killer (NK) cells. The release of interferon γ is followed by release of pro-inflammatory cytokines (interleukins 1β and 2 and tumor necrosis factor α). When activated by interleukin 2, NK-cells eliminate virally infected myocytes and inhibit virus replication. The significance of the action of NK-cells in the pathogenesis of the disease is well established; in animals depleted of NK-cells before infection, a more severe myocarditis develops. As noted earlier, myocarditis after infection with coxsackievirus B occurs more often in men. This propensity may be related to differences between the sexes in the activation of NK-cells. After infection, myocarditis that develops in female mice is less severe than that in male mice. In one study, after the same infection, male mice were markedly less efficient than female mice in activating NK-cells. This decrease in NK-cell activation presumably results in decreased viral clearance with a resultant increase in illness severity. This difference in NK-cell activation may explain the male predominance for the development of clinically significant myocarditis. Unlike NK-cells, T cells may contribute to damage in both infected and noninfected myocytes. Activation of T cells results in accumulation of macrophages within the myocyte and production of cell-mediated cytotoxic effects. Although T cells can lyse virus-infected myocytes, the accumulation of macrophages and the concomitant cytotoxic effects create a fine balance between viral clearance and myocyte damage. Adding to myocyte injury, lysis by T cells is indiscriminate; it occurs in both infected and noninfected cells. The result is necrosis of healthy as well as infected myocytes. Therefore, a percentage of myocardial damage comes from 'friendly fire,' specifically the patient's own immune response.

Permanent myocardial damage can be the end result of myocarditis. Such damage is thought to be due to an overaggressive immunological activation in which persistent T-cell infiltration leads to long-term tissue destruction and subsequent dilated cardiomyopathy. Infection with enteroviruses plays a major role in chronic forms of dilated cardiomyopathy.

Myocarditis is classified as fulminant, acute, or chronic. Fulminant myocarditis is preceded by a viral prodrome that

is followed by sudden onset of severe hemodynamic compromise. Acute myocarditis has a less distinct onset and, initially, less severe compromise but is followed by a worse outcome than fulminant myocarditis. McCarthy et al. found that adults with fulminant myocarditis had excellent long-term survival, whereas patients with acute myocarditis had progressive failure that led to death or the need for a heart transplant. Chronic myocarditis can be defined as persistent (lasting >3 months), recurrent, and latent.

Diagnosing myocarditis in children can be challenging. Not only can children have a wide range of nonspecific signs and symptoms, but depending on cognitive development, they may not be able to communicate their symptoms. Despite a variety of invasive and noninvasive studies, myocarditis is a presumptive diagnosis based on history and clinical features.

CLINICAL HISTORY

Clinical features of viral myocarditis are affected by age, sex, and the child's baseline health status. These variables affect the balance between pathogen clearance and degree of inflammation. Older children may have a history of upper respiratory infection; infants may have anorexia, vomiting, and lethargy. Often, signs and symptoms are nonspecific or may resemble the signs and symptoms of relatively common diagnoses in children, including bronchiolitis, pneumonia, failure to thrive, and gastroenteritis.

Both cases described earlier had the potentially insidious manifestations of viral myocarditis. In the first case, the signs and symptoms suggested benign gastroenteritis with slight dehydration, a situation that is not unusual in toddlers and preschool children. KM, who had a history of gastroenteritis, also had syncope, wheezing, and increased work of breathing. His history of asthma confounded his clinical features. Consequently, he initially received treatment for an exacerbation of asthma.

Older children may have **chest pain** (the sole symptom in some patients). Some have abdominal pain. Atypical manifestations such as syncope (KM), seizures, and sudden death also have been reported. A more focused cardiac examination when no signs of congestive heart failure occur may be prompted by patients' reports of chest pain, dyspnea, exercise intolerance, or fatigue. Tachycardia of unknown origin in an otherwise healthy child may be an ominous sign. Newborns and infants, unlike older children, are more likely to have circulatory shock.

When myocarditis is suspected, a thorough history is imperative for identifying possible causes. Parents should be asked about exposures to potential infectious agents, pharmacological agents that can cause myocardial inflammation, and toxins, including illicit drugs (e.g. cocaine). Immunization status should be obtained because several infectious diseases of childhood (diphtheria, poliomyelitis) are potential causes.

PHYSICAL SIGNS AND SYMPTOMS

During episodes of cardiac compromise, neurohormonal responses activate the sympathetic nervous system and the renin-angiotensin-aldosterone system, resulting in improved contractility, increase in heart rate, vasoconstriction, and fluid and sodium retention. Tachycardia out of proportion for age is common in children with myocardial compromise as the heart attempts to compensate for inadequate oxygen delivery to the tissues. Vasoconstriction occurs to improve preload and maintain blood pressure. This decrease in peripheral perfusion is manifested as cool extremities, described by level of coolness (e.g. cool to midcalf, cool to knee), quality of pulses, capillary refill time (compromise considered at >3 seconds with the extremity at the level of the heart), decreased urine output (<1 ml/kg per hour), and changes in mental status. Pulse quality is characterized by using the 0–4 pulse intensity scale (0=no pulses detected, 4=bounding). Extremities may appear mottled or pale. Despite these alterations in perfusion, it must be emphasized that vasoconstriction in children will maintain a blood pressure within a normal range for age even when tissue perfusion is inadequate. Hypotension is considered not only a late finding of cardiac failure but also an ominous one (Table 13.2).

Often, an **S_3 (ventricular gallop)** occurs because of rapid filling of a noncompliant, poorly contracting left ventricle. Murmurs are less common, although a soft systolic murmur may be heard if mitral or tricuspid insufficiency is present. Heart sounds may be muffled if concomitant pericarditis is present. Rhythm irregularities may be detected, especially supraventricular tachycardia or ventricular ectopic beats as with KM.

Table 13.2: Signs and symptoms of myocarditis in children

Subjective	Chest pain
	Abdominal pain
	Dyspnea/orthopnea
	Exercise intolerance
	Fatigue
Objective	Tachycardia
	Tachypnea
	Wheezing, cough, increased work of breathing
	Alternation in peripheral perfusion
	• Prolonged capillary refill
	• Decrease in pulse quality
	• Extremity coolness
	• Painless, mottling
	• Decreased urine output
	Murmur
	Gallop
	Rhythm irregularities
	• Ventricular ectopy
	• Atrioventricular block
	• Sinus tachycardia or supraventricular tachycardia
	Hepatomegaly[a]
	Rales[b]
	Hypotension[b]

[a]May or may not be present
[b]Late findings

Tachypnea is a common sign of myocardial failure in children. Tachypnea is the result of pulmonary edema due to left ventricular failure. Clinical findings can include wheezing, a cough, grunting, nasal flaring, and intercostal retraction. Older children may report orthopnea or inability to catch their breath. Cyanosis is rare. Rales are typically a late sign of pulmonary congestion and may not occur at all in infants.

Hepatomegaly, an indication of venous congestion, may or may not occur. Liver tenderness or absence of a firm edge on palpation below the right costal margin may indicate liver engorgement.

NONINVASIVE DIAGNOSTIC STUDIES

The diagnostic approach for a child with suspected myocarditis includes strategies to both aid in establishing the diagnosis and rule out disease processes that may mimic myocarditis (e.g. a structural cardiac defect or pericardial effusion). In addition, many of these interventions provide an estimate of myocardial function and can help in establishing clinical interventions (Table 13.3).

X-ray Chest

Evidence of cardiomegaly on a chest radiograph is an important clinical finding in myocarditis; however, the degree of heart enlargement depends on the stage of the disease. Subacute or chronic myocarditis is characterized by cardiomegaly; cardiomegaly may or may not occur in children with fulminant myocarditis.In fact, the possibility of myocarditis is often not considered until late, when cardiomegaly is evident on chest radiographs. Myocarditis should not be ruled out in infants or children with marked cardiovascular compromise or collapse of unknown cause who do not have evidence of heart enlargement on radiographs (Fig. 13.1).

Electrocardiography

Although not diagnostic, findings on an electrocardiogram are rarely normal in patients with myocarditis (Fig. 13.2). Some children have such mild illness that a conduction disturbance on an electrocardiogram is the only abnormal finding. Sinus tachycardia is a common finding with

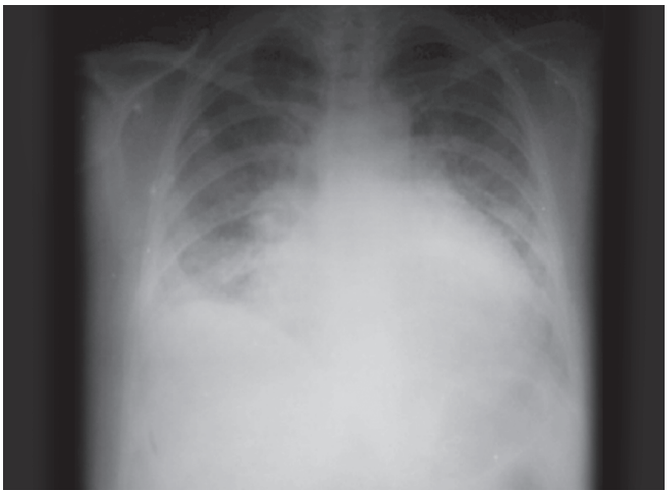

Fig.13.1: X-ray chest frontal view showing pulmonary edema in a patient with cardiogenic shock as a result of acute myocarditis in a 12 years old child

Table 13.3: Diagnosis of myocarditis

Assessment	Findings
Chest radiography	Cardiomegaly
Electrocardiography	Tachycardia—sinus or supraventricular
	Atrioventricular block
	Low-voltage ORS complexes
	ST-T-wave abnormalities (elevation or depression)
	Prolonged QT interval
	Ventricular ectopy
Echocardiography	Impared ventricular function (left > right)
	Ventricular dilation
	Atrioventricular valve regurgitation
	Left ventricular thrombi
Laboratory studies	
Serological tests	Increased levels of creatine kinase and its MB isoenzyme
	Increased level of cardiac troponin C
	Elevated sedimentation rate
	Increased level of C reactive protein
	Increased level of white blood cells, with lymphocytes predominating
	viral titers
	Increased level of immunoglobulin G
Cultures: Blood, stool, cerebro, spinal fluid, nasopharyngeal, secretions	Presence of virus
Myocardiat biopsy	Myocyte destruction, fibrosis, inflammatory cells, and lymphocytic infiltrates

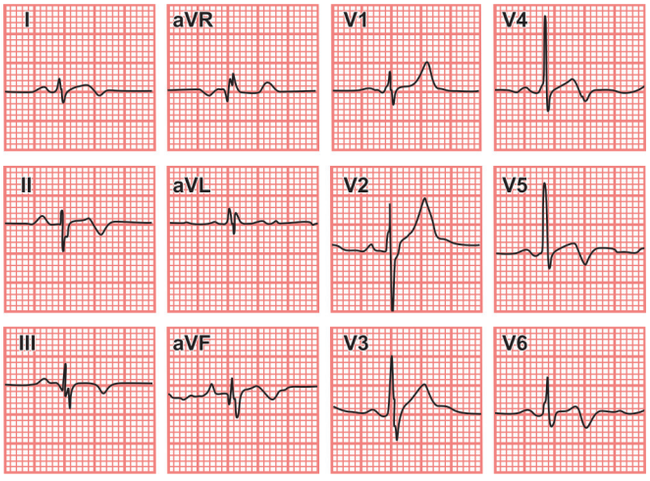

Fig. 13.2: The T-waves are deeply and symmetrically inverted in I, II, III, and V4–6, suggesting a diffuse myocardial process in a young patient with acute viral myocarditis

myocarditis. Low-voltage QRS complexes, ST-T-wave abnormalities, or prolonged QT interval may be apparent. Left ventricular hypertrophy with repolarization changes (strain) is typical. Complete atrioventricular block has also been described. Occasionally, evidence of myocardial infarction is seen.

Echocardiography

Findings on echocardiograms are rarely normal in patients with myocarditis. As with KM, impaired left ventricular function with dilatation of 1 or more chambers is typical. KM's echocardiogram showed poor left ventricular systolic function, with dilatation and slightly diminished right ventricular function. In the absence of any structural abnormalities, these findings help establish the diagnosis. Generally, right ventricular function is less compromised than is left ventricular function; atrioventricular valve

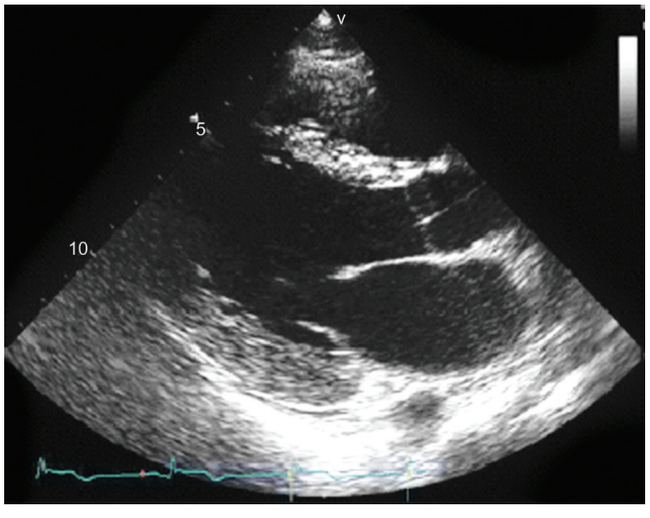

Fig. 13.3: Two-dimensional parasternal long-axis view depicting disproportionate thickening, increased echogenicity, and dyskinesis of the inferolateral wall relative to the septum; findings are consistent with tissue edema

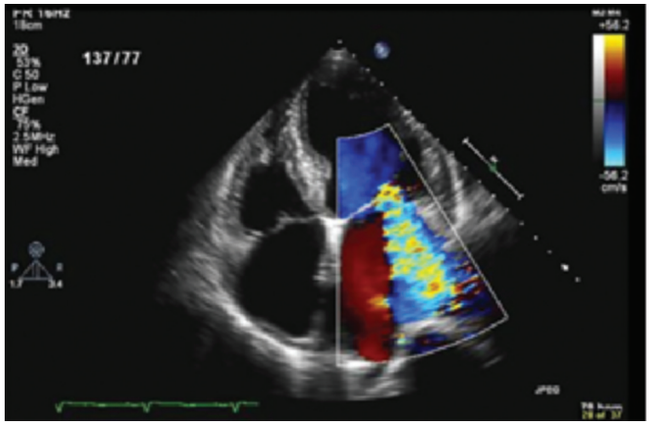

Fig. 13.4: Color-Doppler echocardiography shows MR appears as a systolic regurgitation from the left ventricle to the left atriumin a young patient with acute myocarditis

regurgitation may occur. Occasionally, left ventricular thrombi are found (Figs 13.3 amd 13.4).

CMR imaging: Recent studies have demonstrated that CMR has shown promising results in the early diagnosis and the follow-up of AM and its subsequent stages. CMR includes several techniques that can be used in various combinations to assess left ventricular (LV) functional parameters, morphology, myocardial perfusion, and myocardial disorders within one examination (Fig.13.5).

LABORATORY TESTS

Endomyocardial Biopsy

Historically, despite its limited sensitivity and specificity and its inherent risks, endomyocardial biopsy has been the reference standard for diagnosing viral myocarditis (Fig. 13.6).

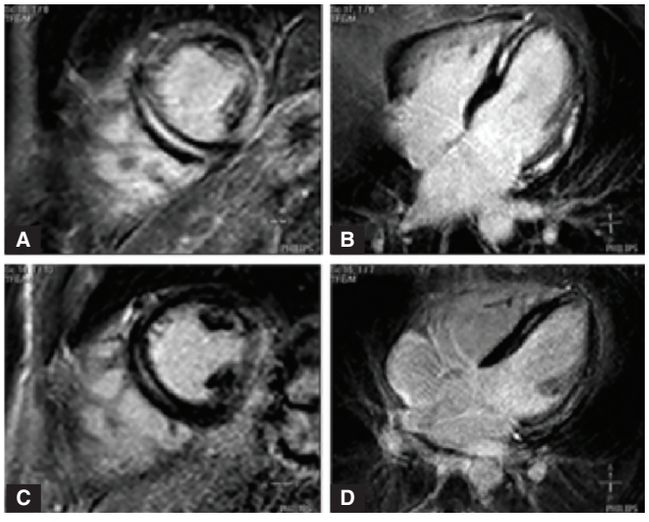

Fig. 13.5: Acute and chronic phase of myocarditis in a patient. (A, B) Acute myocarditis—short-axis view and 4-chamber view showing an extensive pattern of midwall contrast enhancement. Only the basal septal wall and distal anterolateral wall are spared. (C, D) Chronic myocarditis—short-axis and 4-chamber view showing the same pattern of midwall delayed contrast enhancement with lower signal intensity

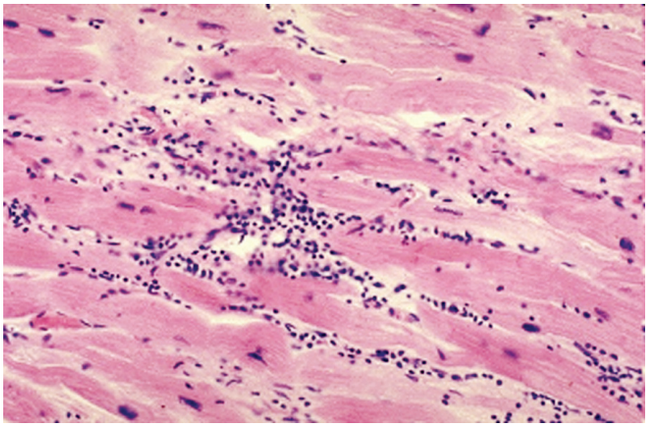

Fig.13.6: Histo-photograph H/E stain showing interstitial inflammatory infiltrates mostly lymphocytes in acute viral myocarditis

Nevertheless, for several reasons, endomyocardial biopsy is used less often in children than in adults. First, biopsy can be associated with significant sampling error. Several tissue specimens (5 or more) are needed because of the focal nature of the disease; many clinicians think that biopsy leads to underestimation of the presence of the disease. Second, borderline myocarditis can result in little to no evidence of myocyte destruction. Third, expert interpretation can vary, including variance with other markers of viral infection. Because of the possibility of false-negative results, lack of an endomyocardial biopsy positive for myocarditis does not rule out this disease. For KM, findings on endomyocardial biopsy on hospital day 8 confirmed the diagnosis. Tissue specimens from the right ventricle had intact myocytes with small foci of lymphocytic infiltrates and extensive areas of myocyte destruction with organizing fibrosis and infiltrates of inflammatory cells most consistent with myocarditis.

Polymerase Chain Reaction

Recently, use of less invasive means of diagnosing myocarditis in children has been emphasized.Use of polymerase chain reaction (PCR) and in situ hybridization has increased the sensitivity for diagnosing viral myocarditis. Tracheal aspirates for PCR analysis in intubated children are useful for detecting viral genomes in children with or without myocarditis. Akhtar et al. reported that PCR of tracheal aspirates had a sensitivity of 100% for predicting the results of PCR of endomyocardial biopsy specimens, albeit for a small (n=10) sample size. Although a tracheal aspirate positive for virus is not diagnostic for myocarditis itself, PCR of tracheal aspirates may provide a safer means of identifying a viral cause for illness in children with cardiac decompensation of unknown origin.

Serological studies may reveal an elevation in myocardial enzyme levels (creatine kinase, normal value 25–190 IU/L [to convert to microkatals, multiply by 0.0167]; MB isoenzyme of creatine kinase, normal value <12% of creatine kinase). In children, the level of cardiac troponin T is a more sensitive indicator of myocardial damage than are myocardial enzyme levels. In healthy children, cardiac troponin levels are typically less than the detection level (<0.02 ng/ml). Lauer et al. reported that 35% of patients with suspected myocarditis also had elevated levels of cardiac troponin; among those, 98% had viral myocarditis confirmed histologically.

Nonspecific laboratory studies may aid in the diagnosis of viral myocarditis. Elevations in sedimentation rate (>20 mm/h) and level of C-reactive protein (>0.05 mg/dl; to convert to nanomoles per liter, multiply by 9.524) may occur. A normal sedimentation rate, however, does not rule out myocarditis. Viral studies may reveal enteroviral or adenoviral antibodies, Esptein-Barr virus, cytomegalovirus, or a 4-fold increase in the level of immunoglobulin G but do not definitively establish causation. Levels of immunoglobulin G antibodies to Epstein-Barr virus nuclear antigen were elevated in KM. PCR may also be used to detect viral genomes.

Elevation in white blood cell count with predominance of lymphocytes may suggest viral causes of myocarditis. Cultures of blood, stool, cerebrospinal fluid, or nasopharyngeal secretions are less specific than cultures of tracheal aspirates; Martin et al. found that cultures showed growth in only 27% of children with viral myocarditis.

MANAGEMENT IN MYOCARDITIS (Tables 13.4 and 13.5)

Critical Care

Care of children with clinical features consistent with myocarditis depends on the severity of myocardial dysfunction. Management is designed around supportive measures rather than being aimed at a causative agent. Maintenance of cardiac output with aggressive support of cardiac function is essential. Such support includes initiation and monitoring of inotropic therapy, afterload reduction, arrhythmia management, and adequate tissue oxygenation. Respiratory support may require intubation and mechanical ventilation. Fluid management may include both administration of fluid boluses and diuretic therapy. Monitoring of and interventions to prevent complications should be ongoing.

Inotropic Support

When cardiac output is inadequate, a rapid acting inotropic agent is administered. Inotropic agents are administered cautiously because the myocardium is irritable and use of inotropic agents can instigate and/or worsen arrhythmias. One inotropic agent or a combination of such agents, including dopamine, dobutamine, and milrinone, can be administered .

Dobutamine is often used when the primary cause of inadequate tissue perfusion is cardiac in origin. Dobutamine improves contractility and decreases systemic vascular resistance, providing afterload reduction in addition to improving cardiac output. A mild increase in heart rate can occur, although significant tachycardia is unusual. Although dobutamine increases myocardial oxygen demand in adults with congestive heart failure, in

Table 13.4: Contiouns infusion inotropic support

Drug	Classification	Dose, µg/kg per minute	Action	Adverse effect
Dopamine	Sympathomimetic	0.5–2	Dopaminergic—renal vasodilatation Promotion of sodium excertion	Tachyarhythmias Reduced renal blood flow at >5 mg kg per minute
		5–10	beta-1adrengic effect	
		10–15	Mixed alpha1-beta1 adrenergic effect	Increased myocardial oxygen demand
		>20	Predominantly alpha1-adrenergic effect	Ectopy
Dobutamine	Sympathomimetic	2–20	Pure beta1-adrenergic effect	Tachycardia Tachyarhythmias Hypotension
Epinephrine	Sympathomimetic	0.1–1.0	Adrenergic agoinst effect, predominatly alpha1-adrenergic effect	Tachyarrhythmias Ventricular ectopy Hypertension Myocardial ischemia
Milrinone	Phosphodiesterase enzyme inhibitor	May use loading dose of 50–75 µg/kg before infusion	Improves contractility Alterload reduction	Hypotension Thrombocytopenia Ventricular ectopy

Table 13.5: Intravenous antiarrhythmic agents

Drug	Classification	Dose	Action	Adverse effect
Adenosine	Antiarrhythmic	0.05–0.1 mg/kg rapid intravenous bolus Repeated to a maximum of 0.3 mg/kg total Can give 12 mg maximum dose for children who weigh > 50 kg	Slows conduction time through the atriventricular node, interrupting reentry pathways	Arhythmias Bradycardia Heart block Hypotension
Digoxin	Cardiac glycoside *Rapid:* 0.4–0.6 mg IV *Contineously:* 0.1–0.3 mg/6–8 hourly		Positive inotropic effects Decreases conduction through the sinoatrial and atrioventricular nodes	Sinus bradycardia Atrioventricular block, sinoalrial block Ventricular arrhythmias Hyperkalemia with toxic effects
Amiodarone	Antriarrhythmic	Loading: 1 mg/kg given over 5–10 minutes, can be repeated 5 times	Inhibits adrenergic stimulation	Bradycardia, heart block, sinus arrest, paroxysmal ventricular tachycardia stimulation
		Continuous intravenous infusion at 10–15 mg/kg per day	Decreases atrioventricular node conduction and sinus function	Congestive heart failure, cardiogemic shock, hypotension Pulmonary toxic effect (pneumonitis, fibrosis, acute respiratory distress syndrome)
Lidocaine	Antiarrhythmic	Loading: 1 mg/kg followed by a continous infusion of 20–50 ug/kg per minute	Suppressess automatically of the conduction system	Bradycardia, heart block arrhythmias, hypotension, seizures

children with patent coronary arteries, coronary blood flow, and oxygen supply to the heart actually increase.

Dopamine has both inotropic and vasopressor properties and is useful in patients who are in shock with cardiac dysfunction and associated mild-to-moderate hypotension. Dopamine is not routinely used to tidal volume (pressure ventilation), a decrease in oxygen saturation, and asymmetric chest rise. If the tube migrates into the right main bronchus, the child should immediately be placed back in the previous position and reassessed. Breath sounds should be assessed after any change in body position.

Neck extension increases airway length, potentially causing unintentional extubation because the uncuffed tube can easily pass upward through the vocal cords. Immediate respiratory distress, decrease in oxygen saturation, marked decrease in or undetectable end-tidal carbon dioxide levels, grunting, or vocalization can indicate possible inadvertent extubation. If dislodgement of the endotracheal tube into the esophagus is suspected, the tube should be removed and bag-valve-mask ventilation performed until reintubation or effective spontaneous breathing occurs.

Although a common practice in intensive care units, endotracheal suctioning should not be performed routinely. Suctioning can be associated with complications, including hypoxemia, bradycardia, atelectasis, and dysrhythmias. Suctioning should be done on an as-needed basis rather than routinely. Indications for suctioning include increase in airway pressure, decrease in tidal volume, decrease in oxygen saturation, visualization of secretions in the tube, development of rhonchi, and coughing. Hyperoxygenation may or may not be required before suctioning, depending on the child's arterial oxygenation and tolerance to the procedure. The catheter should not be deeper than the end of the endotracheal tube. Catheters inserted to the point of resistance (carina) cause tissue inflammation and damage. Instillation of normal saline for lavage should be avoided because that practice is not supported by research and may actually be harmful.

Routine bedside nursing interventions such as dressing changes, bathing, weighing, and repositioning all significantly increase tissue oxygen consumption. Delay in carrying out these procedures may be necessary. Conversely, some or all of these activities may be clustered if tolerated in order to allow longer periods of rest.

Fever increases oxygen consumption 10% for each 1°C elevation in body temperature. Although not all fever is 'bad,' treatment of fever is recommended in children with cardiopulmonary disease. Attempts should be made to maintain normothermia. Unless contraindicated, antipyretics (acetaminophen, ibuprofen) should be administered. Fever reduction can also be attempted with external cooling, usually by sponging with tepid water.

Pain and anxiety significantly increase oxygen demand and consumption and cause considerable distress for children in the PICU. Assessment and management of pain and anxiety should be ongoing.

Arrhythmias

Heart rate and rhythm require monitoring. Arrhythmias are a significant life-threatening complication of myocarditis. Development of bradycardia or tachyarrhythmias is unlikely to be tolerated and requires immediate recognition and treatment (Figs 13.7–13.9).

Infants and small children depend on heart rate for adequate cardiac output because stroke volume is relatively fixed; in young children, bradycardia can rapidly diminish cardiac output. Because chronotropic drugs can induce ventricular tachycardia in patients with viral myocarditis,

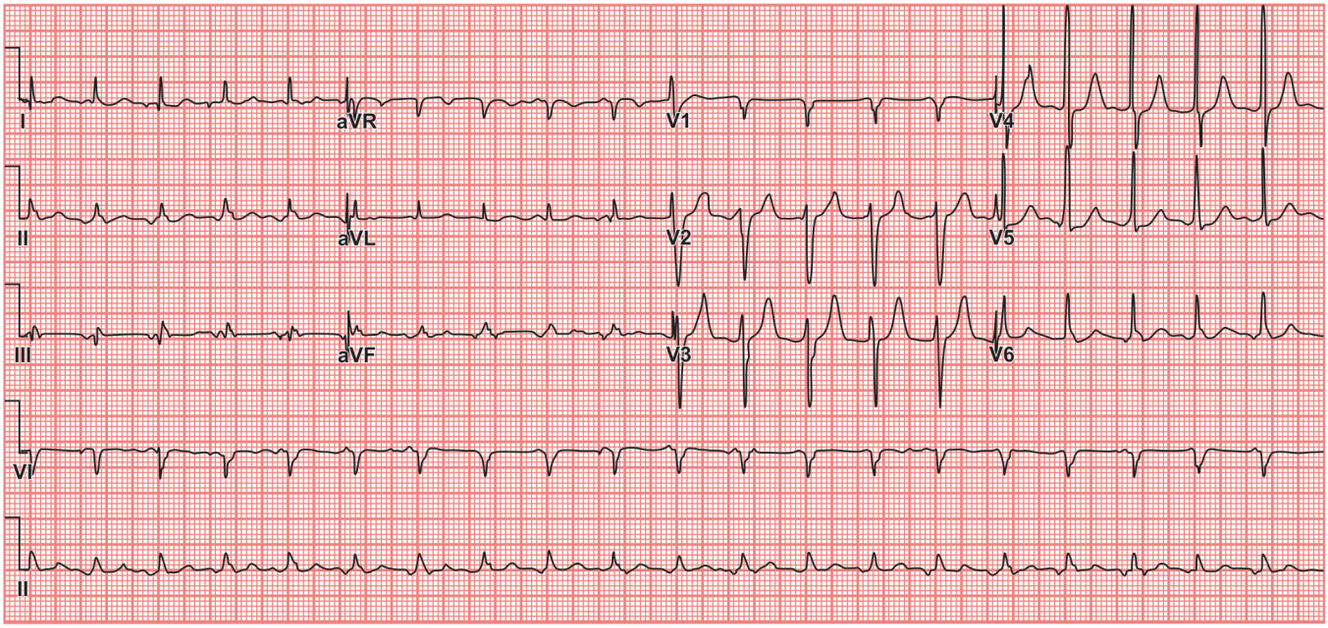

Fig. 13.7: Ectopic atrial tachycardia. There is a narrow complex tachycardia at 120 bpm. Each QRS complex is preceded by an abnormal P-wave—upright in V1, inverted in the inferior leads II, III and aVF

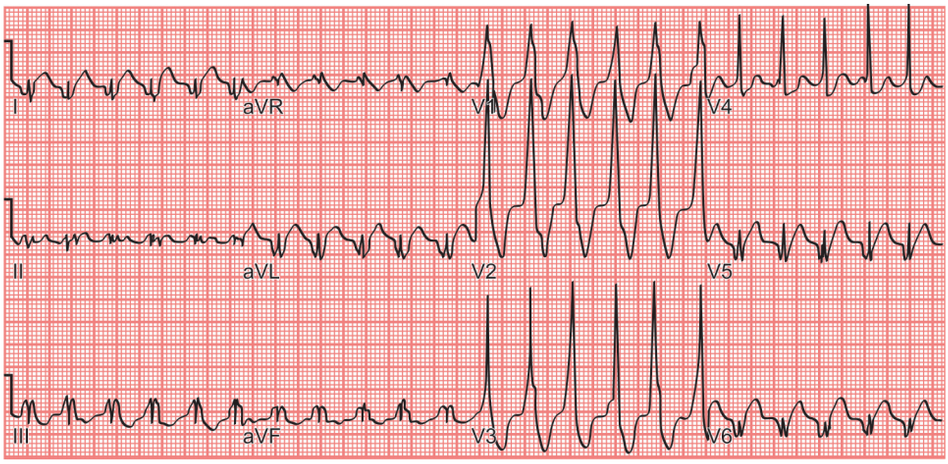

Fig. 13.8: ECG demonstrating ventricular tachycardia with right bundle branch block morphology in a patient with myocarditis

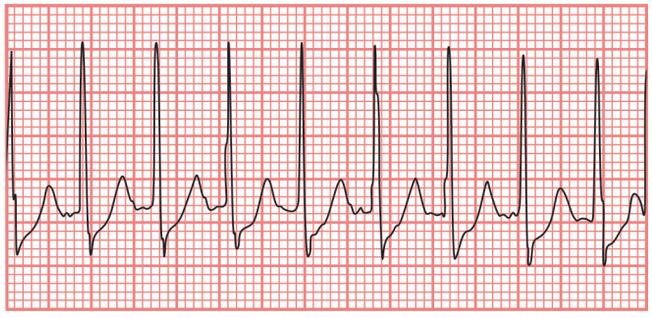

Fig. 13.9: ECG showing features of supraventricular tachycardia in a patient with myocarditis

cardiac pacing is the preferred treatment for life-threatening bradyarrhythmias, including atrioventricular block.

Transcutaneous or transthoracic pacing is a noninvasive procedure that can be done rapidly. Two electrodes are placed on the patient with the anterior electrode in the V_2 to V_5 position and the posterior electrode under the scapula to the left of the spine. Electrode adherence should be checked frequently, especially if the child is diaphoretic. If needed for prolonged periods, electrodes should be changed a minimum of every 24 hours to maintain effectiveness of the contact gel.

For ongoing bradyarrhythmias, invasive pacing should be considered. Transvenous leads are placed percutaneously via a large vessel into the right atrium or ventricle. Leads are stiff; nurses must be alert for indications of ventricular perforation, including cardiac tamponade. An extra battery should be kept at the bedside of any patient who is pacemaker dependent. Hospital policy should be followed when caring for the insertion site and catheter.

Conversely, an excessively rapid heart rate will decrease ventricular filling time, resulting in inadequate preload and subsequent cardiac output. Tachycardias also result in inadequate coronary artery filling time. Coronary arteries fill and perfuse the myocardium during diastole; the faster the heart rate, the shorter is diastole, leading to a decrease in myocardial oxygen supply during a time of increasing consumption.

Differentiation between sinus tachycardia and supraventricular tachycardia is critical. Typically, sinus tachycardia is heart rate greater than 140/min in children, greater than 160/min in infants, and varies from beat to beat. Heart rate generally remains less than 200/min. Sinus tachycardia can be the result of a variety of factors, including fear, anxiety, fever, pain, intravascular dehydration, and marked vasodilatation. Sinus tachycardia will resolve, or partially resolve, with resolution of the inciting factor.

Supraventricular tachycardia is an extremely rapid heart rate (200–280/min); is unresponsive to resolution of fever, pain, hypovolemia, and so on; and has no beat-to-beat variability. Rates of sinus tachycardia and supraventricular tachycardia can overlap, making determination of the type of tachycardia difficult. A 12-lead electrocardiogram may be necessary to differentiate between the two. Once supraventricular tachycardia has been established, rapid treatment with adenosine in the patients with stable hemodynamic status or cardioversion in patients with unstable hemodynamic status is performed. A defibrillator should remain near any child who has myocarditis or recurring supraventricular tachycardia.

Hemodynamic Monitoring

With invasive hemodynamic monitoring, physiological variables specific to cardiovascular function can be monitored and, when coupled with clinical examination, the results provide data for sound clinical decision making.

Arterial Pressure

Continuous blood pressure monitoring via an arterial catheter is preferred in children with severe cardiac dysfunction, particularly those who require infusions of vasoactive agents (Fig. 13.10). Noninvasive measurements may be inaccurate or impossible to obtain because of impaired peripheral perfusion and vasoconstriction. Arterial catheters can be placed peripherally (radial artery) or centrally (femoral artery) and provide a dynamic picture of systolic, diastolic, and mean blood pressures. Because evaluations of interventions and their effectiveness will be

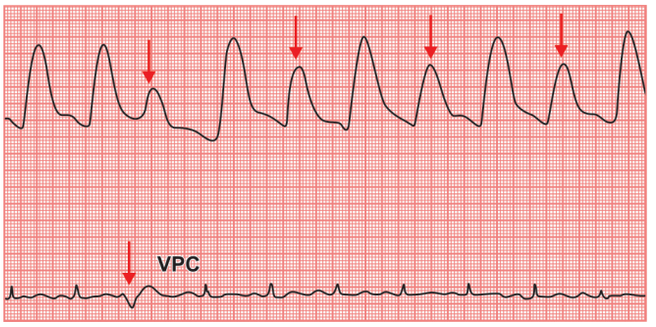

Fig. 13.10: Hemodynamic study shows an alternating pulse-arterial pressure recording in severe left ventricular failure. After the second beat a ventricular premature beat triggers an episode of alternating pulse

based partly on invasive measurement of blood pressure, care must be taken to ensure accuracy of readings. Routinely inspecting for proper transducer placement (phlebostatic axis), zeroing the transducer a minimum of once a shift, inspecting for and eliminating air bubbles in the system, and using noncompliant pressure tubing will help ensure accurate measurements.

Normal blood pressure in children is dependent on age and size. As previously noted, however, children with myocarditis can maintain a blood pressure within normal limits for age until very late in the disease. No single clinical parameter should determine critical care interventions, and this rule is particularly true for blood pressure, unless hypotension is present. Adequacy of tissue perfusion is determined by analysis of clinical findings on bedside examination along with blood pressure. The extremity distal to the arterial catheter should be assessed at least once a shift to monitor for any compromise in perfusion related to catheter placement. Extremity coolness, color changes, delayed capillary refill, and diminishing pulse quality can indicate inadequate perfusion. Numbness, tingling, and motor deficit can also be indicators of impaired circulation. Development or change in any one or more of these variables requires immediate attention and potentially removal of the catheter.

Central Venous Pressure

Central venous pressure (CVP) or right atrial monitoring provides a continual reflection of intravascular volume status and is a good determinant of right ventricular end-diastolic volume, or preload. CVP should be interpreted along with other measures of cardiac function (heart rate, peripheral perfusion, urine output). In critically ill children, the absolute value is not as important as serial measurements and changes in response to interventions.

CVP monitoring should be done via the distal lumen of the catheter. Monitoring can be continual or intermittent, depending on availability of intravenous access. If the distal lumen is being used for continuous intravenous administration of fluids and/or drugs, CVP should be assessed a minimum of once an hour and after any administration of fluid boluses or diuresis. When inter mittent CVP monitoring is used, care must be taken to ensure that no cardiotonic medications are infused through the distal port. If such infusions are used, turning the stopcock for pressure readings causes a disruption in the delivery of medication and potential hemodynamic compromise. Ideally, infusions of inotropic or vasoactive agents should be given through the medial or proximal lumen only.

Normal CVP values can vary widely in infants and children, depending on age, disease, concomitant conditions, and critical care therapies. In healthy infants, normal values can range from –2 to +4 mmHg, from 4 to 8 mmHg in those with congenital heart disease, and from 2 to 6 mmHg in those with respiratory disease requiring mechanical ventilation. In this age group, measurements above 8 mmHg are generally indicative of myocardial dysfunction or high intrathoracic pressure. In older children without underlying disease, a CVP range of 2 to 6 mmHg is considered normal. Values can vary markedly and should be interpreted along with the child's underlying disease state, concomitant conditions, and critical care therapies.

CVP measurements do not stand alone and must be considered in context of the entire clinical picture. Any changes in intrathoracic pressure will affect CVP values; spontaneous respirations decrease CVP, whereas increased intrathoracic pressure increases CVP. Values lower than expected may or may not indicate hypovolemia; high CVP values may or may not indicate hypervolemia. Elevated CVP values may also occur in patients receiving positive pressure ventilation and with the addition of positive end-expiratory pressure. Conditions that increase pulmonary vascular resistance (hypothermia, hypoxemia, acidosis, severe respiratory disease, underlying pulmonary hypertension) also increase CVP. High CVP values do not necessarily reflect cardiac disease but may be an indication of elevated right ventricular end-diastolic pressure, suggesting right ventricular dysfunction. Variables that affect interpretation of CVP values must be considered when therapies are determined.

Complications of central venous catheters include bloodstream infection (increased risk with multilumen catheters), venous thrombosis, thrombophlebitis, and catheter occlusion. Routine maintenance of the catheter and insertion site should be done per hospital policy.

Pulmonary Artery Pressure

Pulmonary artery catheters can provide valuable information in children with cardiopulmonary failure. The ability to measure pulmonary artery pressures, cardiac output/index, and systemic and pulmonary vascular resistance can provide important data for directing therapies. However, because of potential complications, pulmonary artery catheters tend to be used less often in children than in adults. Pulmonary artery catheters are therefore indicated only when the additional data obtained will enhance clinical decision making.

Hospital-acquired Infections

Hospital-acquired infections are a constant threat for any critically ill child in the PICU. Acquired nosocomial infection coupled with extreme severity of illness in a child with myocarditis significantly increases morbidity and mortality. Nurses' diligence in preventing and monitoring for infection is essential. Within hours of admission, hospital-associated bacteria can be detected on skin and in the respiratory and genitourinary tracts. Invasive devices, antibiotic use, and/or critical care procedures increase the risk of bacterial invasion. Some of the highest rates of hospital-acquired infection occur in PICUs; bloodstream infection and ventilator-associated pneumonia are the most common.

Fever is often the first sign of infection in children; however, infants often have decreases in body temperature because of the immaturity of the brain's temperature-regulating center. Monitoring of temperature changes in this age group can be complicated by the use of radiant warmers, designed to maintain normothermia. Radiant warmer temperature is adjusted according to an infant's skin temperature; consequently, decreases in body temperature related to infection may be masked. Although skin temperature is continuously monitored in infants under a radiant warmer, core body temperature should be monitored a minimum of once an hour, if not continuously, in all age groups. White blood cell count with a differential count should be assessed closely. Leukocytosis (elevation) or leukopenia (decrease) develop in children with infection, depending on age. A normal total white blood cell count is 5000–10 000 cells/μL but varies depending on the age of the child; the younger the child, the higher the upper range limit. Monitoring trends is as important as getting absolute counts.

The differential count provides the percentage of each subset of white blood cells (eosinophils, neutrophils, basophils, monocytes, and lymphocytes) and can aid in differentiating the type of infection. In older infants and children, a 'shift to the left,' or an excess of immature neutrophils (bands), usually indicates bacterial infection. An increase in the number or percentage of bands along with fever may warrant further workup (e.g. blood cultures for detection of secondary bacterial infection). Coagulase-negative staphylococci are the most common cause of nosocomial bloodstream infections in the PICU. Unlike older children, young infants commonly have neutropenia when infected because of their small storage pools and inability to produce white blood cells at a fast rate.

Pulmonary secretions should be monitored for changes in viscosity, color, and amount. Changes in the character of the secretions along with evidence of new pulmonary infiltrates may indicate the development of ventilator-associated pneumonia (the second most common hospital-acquired infection in PICUs) in intubated patients. Although nosocomial urinary tract infections occur less often than do acquired bloodstream or pulmonary infections in children, urine should be routinely examined for color, odor, and changes in opacity, particularly if a child has a urinary catheter in place.

Any invasive catheter is a potential source of infection. Insertion sites should be routinely inspected for edema, redness, and drainage. Although central venous catheters are not routinely changed in children, signs of infection at the site may warrant removal of the catheter. Factors increasing the risk for bloodstream infection include multilumen catheters, repeated catheterizations, and certain types of dressing. In order to minimize risk of infection, catheters should be manipulated as little as possible and should be removed as soon as they are no longer needed.

Immobility and alteration in tissue perfusion increase the potential for skin breakdown. Skin should be kept free from exposure to moisture and secretions; moisture-barrier products can be applied to the perineal area. Application of topical moisturizers, with avoidance of products containing perfume or alcohol, aids in maintaining skin hydration. Mouth care, a minimum of every 8 hours, helps keep oral mucosa clean and moist. In children without a blink response (chemically paralyzed) or with incomplete lid closure, the eyes should be kept moist with artificial tears and/or lubricant as needed. Frequent turning (as tolerated), alleviation of pressure points on bony prominences (use of pillows, stuffed animals), and alternating pressure points related to mechanical devices (oxygen saturation probes, blood pressure cuffs, and electrodes) should be performed on a routine basis. Air mattresses or rotating beds can also be used to prevent skin breakdown. Any evidence of altered skin integrity should be immediately addressed.

Prognosis in Myocarditis

The survival rate in children and adults with myocarditis is approximately 80%. Lee et al. found that patients who died almost always did so within the first few hospital days. Survival after 72 hours in patients not requiring ECMO is as high as 97%. Some centers have had a 1-year survival rate of 80% in children who required mechanical circulatory support.

Unfortunately, survival to discharge does not imply full recovery. Although Lee et al. found that recovery of ventricular function without the need for ongoing cardiac medications or restrictions in physical activity was the norm, some evidence suggests that myocarditis can progress to dilated cardiomyopathy. Viral persistence in the myocardium has been associated with progressive impairment of left ventricular function and is predictive of adverse outcomes. Progression from myocarditis to dilated cardiomyopathy is further supported by the finding of a coxsackie virus B—adenovirus receptor gene present in larger amounts in the myocardium of patients with dilated cardiomyopathy than in healthy hearts. The discovery of this receptor also suggests a role in not only the viral origin of myocarditis but also the occasional 'familial' case of myocarditis. Survival in children with dilated cardiomyopathy ranges from 60% to 70% at 1 year to 34–56% at 5 years. Gagliardi et al. reported that in children with

dilated cardiomyopathy, the first 2 years after diagnosis are the most crucial. Favorable events (nearly complete recovery) and worse outcomes (death or need for a transplant) occur during this period. For children with residual myocardial dysfunction at discharge, diuretics and afterload reducers are considered first-line agents. Diuretics are used for congestive heart failure of any cause because they reduce respiratory signs and symptoms associated with heart failure. Thiazides (diuril, hydrochlorothiazide) are often used; the addition of spironolactone may obviate potassium supplementation. Angiotensin-converting enzyme inhibitors (captopril and enalapril) may also improve chronic signs and symptoms

The use of digoxin in patients with chronic congestive heart failure as a result of myocarditis remains controversial. The poor diastolic function associated with myocarditis is not improved with digoxin. Digoxin also increases the risk of ventricular arrhythmias if myocardial inflammation is still present. If digoxin is used, digitalization should be accomplished during a 24–36-hour period with 75% of the usual total loading dose to minimize the possibility of arrhythmia development.

Beta-blockade may improve outcome in children with dilated cardiomyopathy. Carvedilol, a nonselective beta-blocker used in adults, has been examined as an adjunct therapy for management of heart failure in children. Carvedilol may improve congestive heart failure through several mechanisms, including decreased heart rate leading to improved myocardial oxygen consumption and enhanced coronary artery blood flow, improvement in left ventricular ejection fraction, and reduction in neurohormonal vasoconstrictor systems. Carvedilol may also prevent ventricular arrhythmias and sudden death.

Use of carvedilol in children remains controversial. Bruns et al. studied the use of carvedilol in 46 children with heart failure in 6 different centers and found improvement in left ventricular function and overall signs and symptoms in 67%. Schwartz and Wessel also examined use of carvedilol in children with heart failure and found no statistically significant effect; left ventricular ejection fraction improved in both the carvedilol and the placebo groups. Although carvedilol is effective in reducing mortality in adults, more research into the use of carvedilol is needed in children with heart failure.

Transplantation is sometimes the only option for children with significant cardiac failure or dilated cardiomyopathy due to myocarditis. Preferably, children are not put on a list for transplantation until they have progressed to the chronic phase of the disease, because recovery is possible in even the most severe cases. Transplantation may, however, be considered an option for a child who requires ECMO for more than 10 days and has no clinical signs of improvement.

SUMMARY

Viral myocarditis remains an uncommon but challenging illness. In children, the initial signs and symptoms are often those of common pediatric illnesses and without any obvious cardiac signs. Adding to the challenge is the potential inability of the child to convey precise symptoms or describe location or intensity of pain or discomfort. A history of asthma or congenital heart disease can skew the clinical picture. Although few children actually have viral myocarditis diagnosed and require admission to the PICU, practitioners must maintain a heightened sense of awareness for the 'zebra in the herd of horses.' Concomitantly, for any previously healthy child with sudden cardiogenic shock, myocarditis must be included in the differential diagnosis.

Most children with myocarditis recover without requiring admission to the PICU; only a small percentage progress to development of significant cardiopulmonary compromise that requires intensive cardiopulmonary support and monitoring. Critical care management is aimed at supportive rather than curative measures and depends on the severity of myocardial dysfunction. The most common techniques used in the PICU for children with cardiovascular compromise or collapse include invasive hemodynamic monitoring, infusions of inotropic agents, antiarrhythmics, afterload reducers, mechanical ventilation, prevention of complications, and, when a child is unresponsive to ordinary PICU therapies, extracorporeal life support.

KEY POINTS IN ACUTE MYOCARDITIS

Myocarditis, an inflammation of the myocardium, is classified as idiopathic in more than 50% of patients. Other causes include viruses or bacteria, various toxins including alcohol, or those causes secondary to a coexisting systematic disease such as HIV or lupus erythematosus.

Although myocarditis often resolves spontaneously without treatment, some patients present with heart failure, cardiogenic shock, or cardiac arrhythmias, all of which require urgent treatment as appropriate.

Diagnosis is complicated owing to the highly variable clinical presentation of myocarditis and the difficulty in providing laboratory confirmation of the diagnosis and etiology. Blood troponin I (TnI) and creatine kinase (CK)-MB cardiac enzyme levels and imaging studies such as echocardiography or magnetic resonance imaging (MRI) may be helpful, but a myocardial biopsy remains the gold standard.

Treatment includes therapy targeted at the cause of myocarditis if an infectious agent or toxic substance, and supportive therapy aimed at the clinical manifestations such as congestive heart failure and arrhythmias. Multiple treatment approaches for viral myocarditis are currently under evaluation. In particular, immunoglobulin and immunosuppressive therapy have shown promise in selected small clinical trials.

Contd...

Contd...

Prognosis depends on both the individual patient and the causative agent. Overall mortality rates vary. The Myocarditis Treatment trial, currently the largest clinical study to evaluate long-term prognosis of myocarditis, showed a 20% mortality rate at 1.0 year and a 56% mortality rate at 4.3 years

Urgent antitoxin treatment may be indicated in cases in which myocarditis is caused by the *Corynebacterium diphtheriae* bacteria.

BIBLIOGRAPHY

1. Adhoot J, Galindo A, Alejos JC, et al. Use of OKT3 for acute myocarditis in infants and children. J Heart Lung Transplant 2000;19(11):1118–21.
2. Akhtar N, Ni J, Stromberg D, Rosenthal GL, Bowles NE, Towbin JA. Tracheal aspirate as a substrate for polymerase chain reaction detection of viral genome in childhood pneumonia and myocarditis. Circulation 1999;99(15): 2011–8.
3. American Heart Association 2006.
4. Archard LC, Khan MA, Soteriou BA, Why HJ, Robinson NM, Richardson PJ. Characterization of coxsackie B virus RNA in myocardium from patients with dilated cardiomyopathy by nucleotide sequencing of reverse transcription-nested polymerase chain reaction products. Hum Pathol 1998; 29(6):578–84.
5. Aretz HT, Billingham ME, Edwards WD, et al. Myocarditis: a histopathologic definition and classification. Am J Cardiovasc Pathol 1987;1(1):3–14.
6. Baboonian C, McKenna W. Eradication of viral myocarditis: is there hope? J Am Coll Cardiol 2003;42(3):473–6.
7. Batra AS, Lewis AB. Acute myocarditis. Curr Opin Pediatr 2001;13(3):234–9.
8. Baughman KL. Diagnosis of myocarditis: death of Dallas criteria. Circulation 2006;113(4):593–5.
9. Bohn D, Macrae D, Chang AC. Acute viral myocarditis: mechanical circulatory support. Pediatr Crit Care Med 2006;7(6)(Suppl):S21–S24.
10. Bowles NE, Towbin JA. Molecular aspects of myocarditis. Curr Infect Dis Rep 2000;2(4):308–14.
11. Calabrese F, Rigo E, Milanesi O, et al. Molecular diagnosis of myocarditis and dilated cardiomyopathy in children: clinicopathologic features and prognostic implications. Diagn Mol Pathol 2002;11(4):212–21.
12. Chavda KK, Dhuper S, Makhok A, Chowdjury D. Seizures secondary to a high-grade atrioventricular block as a presentation of acute myocarditis. Pediatr Emerg Care 2004; 20(6):387–90.
13. Craig J, Fineman LD, Moynihan P, Baker AL. Cardiovascular critical care problems.In: Curley MAQ, Moloney-Harmon PA, eds. Critical Care Nursing of Infants and Children, 2nd ed. Philadelphia, PA: WB Saunders Co, 2001;629–31.
14. Curley MAQ, Meyer EC. Caring practices: the impact of the critical care experience on the family. In: Curley MAQ, Moloney-Harmon PA. Critical Care Nursing of Infants and Children. 2nd ed. Philadelphia, PA: WB Saunders Co, 2001;47–67.
15. Curley MAQ, Thompson JE. Oxygenation and ventilation. In: Curley MAQ, Moloney-Harmon, PA. Critical Care Nursing of Infants and Children. 2nd ed. Philadelphia, PA: WB Saunders Co, 2001;233–308.
16. Drucker NA, Colan SD, Lewis AB, et al. Gamma-globulin treatment of acute myocarditis in the pediatric population. Circulation 1994;89(1):252–7.
17. Drucker NA, Newburger JW. Viral myocarditis: diagnosis and management. Adv Pediatr 1997;44:141–69.
18. Feldman AM, McNamara D. Medical progress: myocarditis. N Engl J Med 2000;343(19):1388–98.
19. Friedman RA. Myocarditis. In: Garson A, Bricher JT, McNamara DG, eds. The Science and Practice of Pediatric Cardiology. Philadelphia, PA: Lea & Febiger 1990;1577–89.
20. Fujioka S, Kitaura Y, Ukimara A, et al. Evaluation of viral infection in the myocardium of patients with idiopathic dilated cardiomyopathy. J Am Coll Cardiol 2000;36(6):1920–6.
21. Gagliardi MG, Bevilacqua M, Bassano C, et al. Long-term follow-up of children with myocarditis treated by immuno-suppression and of children with dilated cardiomyopathy. Heart 2004;90(10):1167–71
22. Hastings LA, Heitmiller ES, Nyhan D. Peri-operative monitoring. In: Nichols DG, Ungerleider RM, Spevak PJ, et al. Critical Heart Disease in Infants and Children. 2nd ed. Philadelphia, PA: Mosby 2006;479–506.
23. Hazinski MF. Children are different. In: Hazinski MF. Nursing Care of the Critically Ill Child. 2nd ed. St Louis, MO: Mosby, 1992;1–17.
24. Hoffman TM, Wernovsky G, Atz AM, et al. Efficacy and safety of milrinone in preventing low cardiac output syndrome in infants and children after corrective surgery for congenital heart disease. Circulation 2003;107(7):996–1002.
25. Kawai C. From myocarditis to cardiomyopathy: mechanisms of inflammation and cell death. Circulation 1999;99(8):1091–1100.
26. Kühl U, Pauschinger M, Noutsias, M, Kapp JF, Schultheiss HP. Diagnosis and treatment of patients with virus induced inflammatory cardiomyopathy. Eur Heart J Suppl 2002; 4(Suppl I):I73–I80.
27. Lauer B, Neiderau C, Kuhl U, et al. Cardiac troponin T in patients with clinically suspected myocarditis. J Am Coll Cardiol 1997;30(5):1354–9
28. Lee KJ, McCrindle BW, Bohn DJ, et al. Clinical outcomes of acute myocarditis in childhood. Heart 1999;82(2):226–33.
29. Leonard EG. Viral myocarditis. Pediatr Infect Dis J 2004; 23(7):665–66.
30. Levi D, Alejos J. Diagnosis and treatment of pediatric viral myocarditis. Curr Opin Cardiol 2001;16:77–83.
31. Macrae D, Chang AC. Pediatric cardiac intensive care consensus: myocarditis. Paper presented at: Pediatric Cardiac Intensive Care Symposium; December 11, 2005; Miami, FL.
32. Martin AB, Webber S, Fricker FJ, et al. Congenital cardiovascular disease/diabetes: acute myocarditis: rapid diagnosis by PCR in children. Circulation 1994;90(1):330–9.
33. Matsumori A, Igata H, Ono K, et al. High doses of digitalis increase the myocardial production of proinflammatory cytokines and worsen myocardial injury in viral myocarditis: a possible mechanism of digitalis toxicity. Jpn Circ J 1999;63(12):934–40.

34. McCarthy RE, Boehmer JP, Hruban RH, et al. Long-term outcome of fulminant myocarditis as compared with acute (non-fulminant) myocarditis. N Engl J Med 2000; 342(10):690–5.
35. Mecham N. Acute viral myocarditis in the ED pediatric patient: three case presentations. J Emerg Nurs 2004;30(2): 179–82.
36. Nguyen QV. Hospital-acquired infections. http://www.emedicine.com/ped/topic1619.htm. Updated August 21, 2007. Accessed November 27, 2007.
37. Park MK, Troxler RG. Pediatric Cardiology for Practitioners. 4th ed. St Louis, MO: Mosby 2002;289–90.
38. Pophal SG, Sigfusson G, Booth KL, et al. Complications of endomyocardial biopsy in children. J Am Coll Cardiol 1999; 34(7): 2105–10.
39. Pres S, Lipkind RS. Acute myocarditis in infants: initial presentation. Clin Pediatr. 1990;29(2):73–6.
40. Schwartz SM, Wessel DM. Medical cardiovascular support in acute viral myocarditis in children. Pediatr Crit Care Med 2006;7(6)(Suppl):S12–S16.
41. Slota MC. Clinical assessment of cardiovascular function. In: Slota MC (Ed.). Core Curriculum for Pediatric Critical Care Nursing. 2nd ed. Philadelphia, PA: WB Saunders Co, 2006; 176–85.
42. Thompson A. Pediatric emergency airway management. In: Dieckmann RA, Fiser DH, Selbst SM (Eds.) Illustrated Textbook of Pediatric Emergency and Critical Care Procedures. Louis, MO: Mosby-Yearbook Inc, 1997;104–15.
43. Throckmorton AL, Lim DS, McCulloch MA, et al. Computational design and experimental performance testing of an axial-flow pediatric ventricular assist device. ASAIO J 2005; 51(5):629–35.
44. Tobias JD, Deshpande JK, Johns JA, Nichols DG. Inflammatory heart disease. In: Nichols DG, Ungerleider RM, Spevak PJ, et al. (Eds.) 2nd ed. Critical Heart Disease in Infants and Children. Philadelphia, PA: Mosby, 2006:899–925.
45. Weiss WJ. Pulsatile pediatric ventricular assist devices. ASAIO J 2005;51(5):540–5.
46. Woodruff JF. Viral myocarditis. Am J Pathol 1980;101(2): 427–84.
47. Yong ES, Timmons OD, Uhl MW, et al. Reduction of blood gases in a pediatric ICU (PICU): a process improvement. Paper presented at: 11th Annual Pediatric Critical Care Colloquium; September 1998; Chicago, IL.

14 Cardiac Tamponade

Cardiac tamponade is a clinical syndrome caused by the accumulation of fluid in the pericardial space, resulting in reduced ventricular filling and subsequent hemodynamic compromise. Cardiac tamponade is a medical emergency. The overall risk of death depends on the speed of diagnosis, the treatment provided, and the underlying cause of the tamponade.

PATHOPHYSIOLOGY

The pericardium, which is the membrane surrounding the heart, is composed of 2 layers. The thicker parietal pericardium is the outer fibrous layer; the thinner visceral pericardium is the inner serous layer. The pericardial space normally contains 20–50 ml of fluid. Pericardial effusions can be serous, serosanguineous, hemorrhagic, or chylous (Fig. 14.1).



Fig. 14.1: This anteroposterior view chest radiograph shows a massive bottle-shaped heart and conspicuous absence of pulmonary vascular congestion

Stages of Hemodynamic Changes in Tamponade

- **Phase I:** The accumulation of pericardial fluid causes increased stiffness of the ventricle, requiring a higher filling pressure. During this phase, the left and right ventricular filling pressures are higher than the intrapericardial pressure.
- **Phase II:** With further fluid accumulation, the pericardial pressure increases above the ventricular filling pressure, resulting in reduced cardiac output.
- **Phase III:** A further decrease in cardiac output occurs, which is due to equilibration of pericardial and left ventricular (LV) filling pressures.

The underlying pathophysiologic process for the development of tamponade is markedly diminished diastolic filling because transmural distending pressures are insufficient to overcome the increased intrapericardial pressures. Tachycardia is the initial cardiac response to these changes to maintain the cardiac output. Systemic venous return is also altered during tamponade. Because the heart is compressed throughout the cardiac cycle due to the increased intrapericardial pressure, systemic venous return is impaired and right atrial and right ventricular collapse occurs. Because the pulmonary vascular bed is a vast and compliant circuit, blood preferentially accumulates in the venous circulation, at the expense of LV filling. This results in reduced cardiac output and venous return. The amount of pericardial fluid needed to impair the diastolic filling of the heart depends on the rate of fluid accumulation and the compliance of the pericardium. Rapid accumulation of as little as 150 ml of fluid can result in a marked increase in pericardial pressure and can severely impede cardiac output, whereas 1000 ml of fluid may accumulate over a longer period without any significant effect on diastolic filling of the heart. This is due to adaptive stretching of the pericardium over time. A more compliant pericardium can allow considerable fluid accumulation over a longer period without hemodynamic insult.

Mortality/Morbidity

Cardiac tamponade is a medical emergency. Early diagnosis and treatment are crucial to reduce morbidity and mortality. Untreated, it is rapidly and universally fatal.

Sex

In children, cardiac tamponade is more common in boys than in girls, with a male-to-female ratio of 7:3. In adults, cardiac tamponade appears to be slightly more common in men than in women. The male-to-female ratio of 1.25:1 observed at author's referral center based on the international classification of diseases (ICD) code 423.9. However, a male-to-female ratio of 1.7:1 is observed at another level 1 trauma center.

Age

Cardiac tamponade related to trauma or HIV is more common in young adults, whereas tamponade due to malignancy and/or renal failure occurs more frequently in elderly individuals.

Clinical History

Symptoms vary with the underlying cause and the acuteness of the tamponade. Patients with acute tamponade may present with dyspnea, tachycardia, and tachypnea. Cold and clammy extremities from hypoperfusion are also observed in some patients.

A comprehensive review of the patient's history usually helps identify the probable etiology of a pericardial effusion, which may result in cardiac tamponade.

- Patients with systemic or malignant disease present with weight loss, fatigue, or anorexia.
- Chest pain may be the presenting symptom in patients with pericarditis or myocardial infarction.
- Musculoskeletal pain or fever may be present in patients with an underlying connective tissue disorder.
- A history of renal failure can lead to a consideration of uremia as a cause of pericardial effusion.
- Careful review of a patient's medications may indicate drug-related lupus leading to a pericardial effusion.
- Recent cardiovascular surgery, coronary intervention, or trauma can lead to the rapid accumulation of pericardial fluid and tamponade.
- Recent pacemaker lead implantation or central venous catheter insertion can lead to the rapid accumulation of pericardial fluid and tamponade.
- Consider HIV-related pericardial effusion and tamponade if the patient has a history of intravenous drug abuse or opportunistic infections.
- Inquire about chest wall radiation (i.e. for lung, mediastinal, or esophageal cancer).
- Inquire about symptoms of night sweats, fever, and weight loss, which may be indicative of tuberculosis.

PHYSICAL EXAMINATION

In a retrospective study, the most common symptoms noted by Roy et al are dyspnea, tachycardia, and elevated jugular venous pressure. Evidence of chest wall injury may be present in trauma patients. Tachycardia, tachypnea, and hepatomegaly are observed in more than 50% of patients with cardiac tamponade, and diminished heart sounds and a pericardial friction rub are present in approximately one third of patients. Some patients may present with dizziness, drowsiness, or palpitations. Cold, clammy skin and weak pulse due to hypotension are also observed in patients with tamponade.

- The **Beck triad** or acute compression triad
  - Described in 1935, this complex of physical findings refers to increased jugular venous pressure, hypotension, and diminished heart sounds.
  - These findings result from a rapid accumulation of pericardial fluid. However, this classic triad is usually observed in patients with acute cardiac tamponade.
- **Pulsus paradoxus or paradoxical pulse**
  - This is an exaggeration (>12 mmHg or 9%) of the normal inspiratory decrease in systemic blood pressure.
  - To measure the pulsus paradoxus, patients are often placed in a semirecumbent position; respirations should be normal. The blood pressure cuff is inflated to at least 20 mmHg above the systolic pressure and slowly deflated until the first Korotkoff sounds are heard only during expiration. At this pressure reading, if the cuff is not further deflated and a pulsus paradoxus is present, the first Korotkoff sound is not audible during inspiration. As the cuff is further deflated, the point at which the first Korotkoff sound is audible during both inspiration and expiration is recorded. If the difference between the first and second measurement is greater than 12 mmHg, an abnormal pulsus paradoxus is present.
  - The paradox is that while listening to the heart sounds during inspiration, the pulse weakens or may not be palpated with certain heartbeats, while S1 is heard with all heartbeats.
  - A pulsus paradoxus can be observed in patients with other conditions, such as constrictive pericarditis, severe obstructive pulmonary disease, restrictive cardiomyopathy, pulmonary embolism, rapid and labored breathing, and right ventricular infarction with shock.
  - A pulsus paradoxus may be absent in patients with markedly elevated LV diastolic pressures, atrial septal defect, pulmonary hypertension, and aortic regurgitation.
- **Kussmaul sign**
  - This was described by Adolph Kussmaul as a paradoxical increase in venous distention and pressure during inspiration.

  - This sign is usually observed in patients with constrictive pericarditis but occasionally is observed in patients with effusive-constrictive pericarditis and cardiac tamponade.
- **Ewart sign**
  - Also known as the Pins sign, this is observed in patients with large pericardial effusions.
  - It is described as an area of dullness, with bronchial breath sounds and bronchophony below the angle of the left scapula.
- **The y descent**
  - The y descent is abolished in the jugular venous or right atrial waveform.
  - This is due to an increase in intrapericardial pressure, preventing diastolic filling of the ventricles.
- **Dysphoria:** Behavioral traits such as restless body movements, unusual facial expressions, restlessness, sense of impending death were reported by Ikematsu in about 26% patients with cardiac tamponade.
- **Low-pressure tamponade:** In severely hypovolemic patients, classical physical findings such as tachycardia, pulsus paradoxus, and jugular venous distension were infrequent. Sagrista-Sauleda et al. identified low-pressure tamponade in 20% of patients with cardiac tamponade. They also reported low-pressure tamponade in 10% of large pericardial effusions.

AETIOLOGICAL FACTORS

For all patients, malignant diseases are the most common cause of pericardial tamponade. Among etiology of tamponade, Merce et al. reported malignant diseases in 30–60% of cases, uremia in 10–15% of cases, idiopathic pericarditis in 5–15%, infectious diseases in 5–10%, anticoagulation in 5–10%, connective tissue diseases in 2–6%, and Dressler or postpericardiotomy syndrome in 1–2%. Tamponade can occur as a result of any type of pericarditis.

- HIV infection
- Infection—viral, bacterial (tuberculosis), fungal
- Drugs—hydralazine, procainamide, isoniazid, and minoxidil
- Postcoronary intervention (i.e. coronary dissection and perforation)
- Trauma to the chest
- Cardiovascular surgery (postoperative pericarditis)
- Postmyocardial infarction (free wall ventricular rupture, Dressler syndrome)
- Connective tissue diseases—systemic lupus erythematosus, rheumatoid arthritis, and dermatomyositis
- Radiation therapy to the chest
- Iatrogenic—after sternal biopsy, transvenous pacemaker lead implantation, pericardiocentesis, or central line insertion
- Uremia
- Anticoagulation treatment
- Idiopathic pericarditis
- Complication of surgery at the esophagogastric junction such as antireflux surgery
- Pneumopericardium (due to mechanical ventilation or gastropericardial fistula)
- Other causes include hypothyroidism, acupuncture, Still disease, and Duchenne muscular dystrophy
- Type A aortic dissection

DIFFERENTIAL DIAGNOSES

- Cardiogenic shock
- Pericarditis, constrictive
- Pericarditis, constrictive-effusive
- Pulmonary embolism
- Tension pneumothorax

Other Problems may Cause Concern

Large pleural effusion: Cases of cardiac tamponade have been reported with large pleural effusions. The increased intrapleural pressure resulting from large pleural effusions can be transmitted to the pericardial space and impair ventricular filling, thus simulating the hemodynamic equivalent of cardiac tamponade.

Tension pneumopericardium: The hemodynamic changes simulate acute cardiac tamponade. Clinically, distant heart sounds, bradycardia, and shifting tympany occur over the precordium and a characteristic murmur is heard, termed bruit de la roue de moulin. This is usually observed in infants with mechanical ventilation but is also observed after sternal bone marrow aspiration, penetrating chest wall injury, esophageal rupture, and bronchopericardial fistula.

Rapid and labored breathing: Large decreases in intrathoracic pressure with deep inspirations, often observed during respiratory failure, can accentuate the pulsus paradoxus, simulating pericardial tamponade.

LABORATORY STUDIES

- *Creatine kinase and isoenzymes:* Levels are elevated in patients with myocardial infarction and cardiac trauma.
- *Renal profile and CBC count with differential:* These tests are useful in the diagnosis of uremia and certain infectious diseases associated with pericarditis.
- *Coagulation panel:* The prothrombin time and activated partial thromboplastin time are useful for determining bleeding risk during interventions, such as pericardial drainage, the placement of pericardial windows, or both.
- *Antinuclear antibody assay, erythrocyte sedimentation rate, and rheumatoid factor:* Although nonspecific, results from these tests may give clues to a connective tissue disease predisposing to the development of pericardial effusion.
- *HIV testing:* Approximately 24% of all pericardial effusions are reported to be associated with HIV infection.
- *Purified protein derivative testing:* This is used to diagnose tuberculosis, which is an important and not uncommon cause of pericardial effusion and tamponade.

Imaging

Chest radiography findings may show cardiomegaly, water bottle-shaped heart, pericardial calcifications, or evidence of chest wall trauma. This anteroposterior-view chest radiograph shows a massive bottle-shaped heart and conspicuous absence of pulmonary vascular congestion.

- Bowed catheter sign on chest radiograph in children after central venous catheter insertion may be suggestive of tamponade.

  Echocardiography provides useful information, cardiac tamponade is a clinical. The following may be observed with 2-dimensional echocardiography (Figs 14.2–14.5):

  - An echo-free space posterior and anterior to the left ventricle and behind the left atrium: After cardiac surgery, a localized posterior fluid collection without significant anterior effusion may occur and may readily compromise cardiac output.
  - Early diastolic collapse of the right ventricular free wall
  - Early diastolic collapse of right ventricular free wall (subcostal view)
  - Early diastolic collapse of right ventricular free wall (parasternal short-axis view at aortic valve)
  - Late diastolic compression/collapse of the right atrium
  - Late diastolic collapse of right atrium (subcostal view)
  - Swinging of the heart in its sac
  - LV pseudohypertrophy
  - Inferior vena cava plethora with minimal or no collapse with inspiration
  - Dilated inferior vena cava
  - A greater than 40% relative inspiratory augmentation of right-side flow
  - A greater than 25% relative decrease in inspiratory flow across the mitral valve

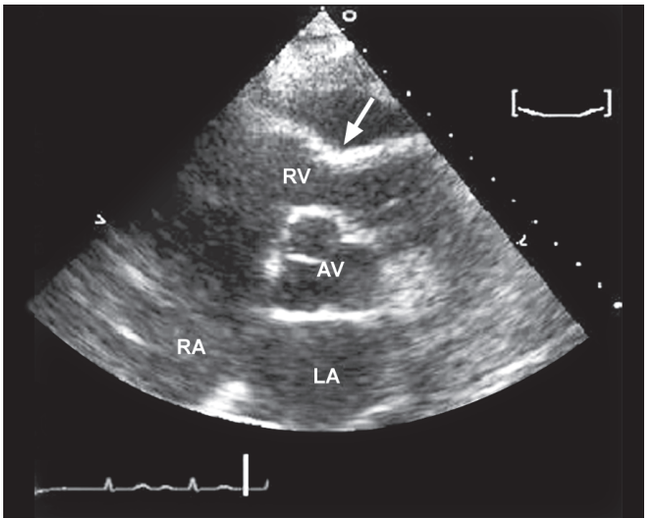

Fig. 14.2: Early diastolic collapse of right ventricular free wall (parasternal short-axis view at aortic valve)

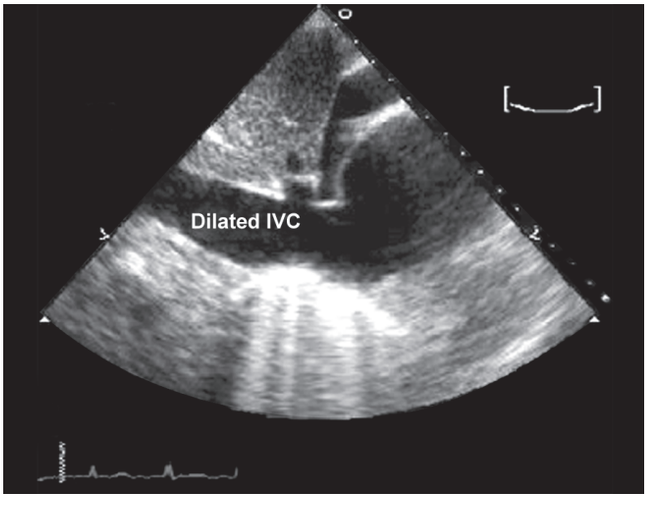

Fig.14.3: Dilated inferior vena cava in cardiac tamopnade

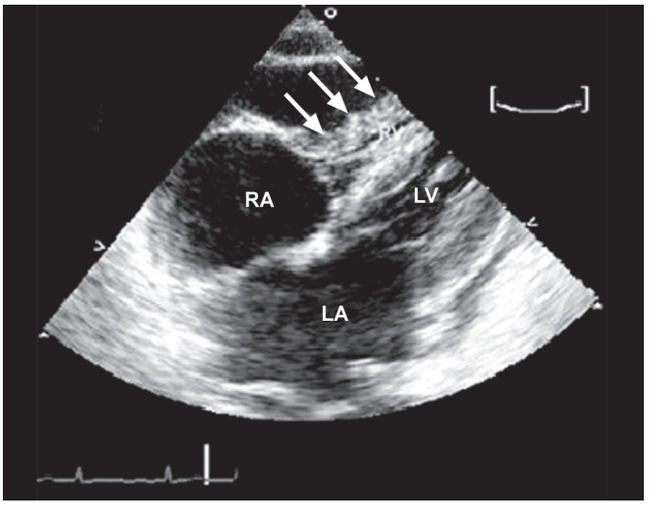

Fig.14.4: Early diastolic collapse of right ventricular free wall (subcostal view)

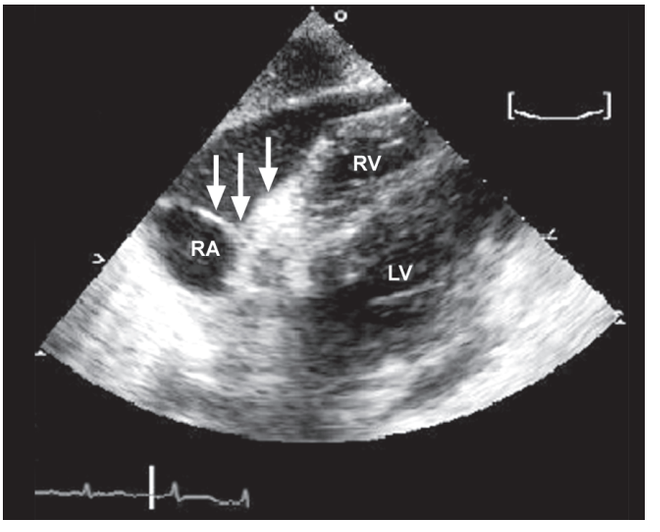

Fig. 14.5: Late diastolic collapse of right atrium (subcostal view)

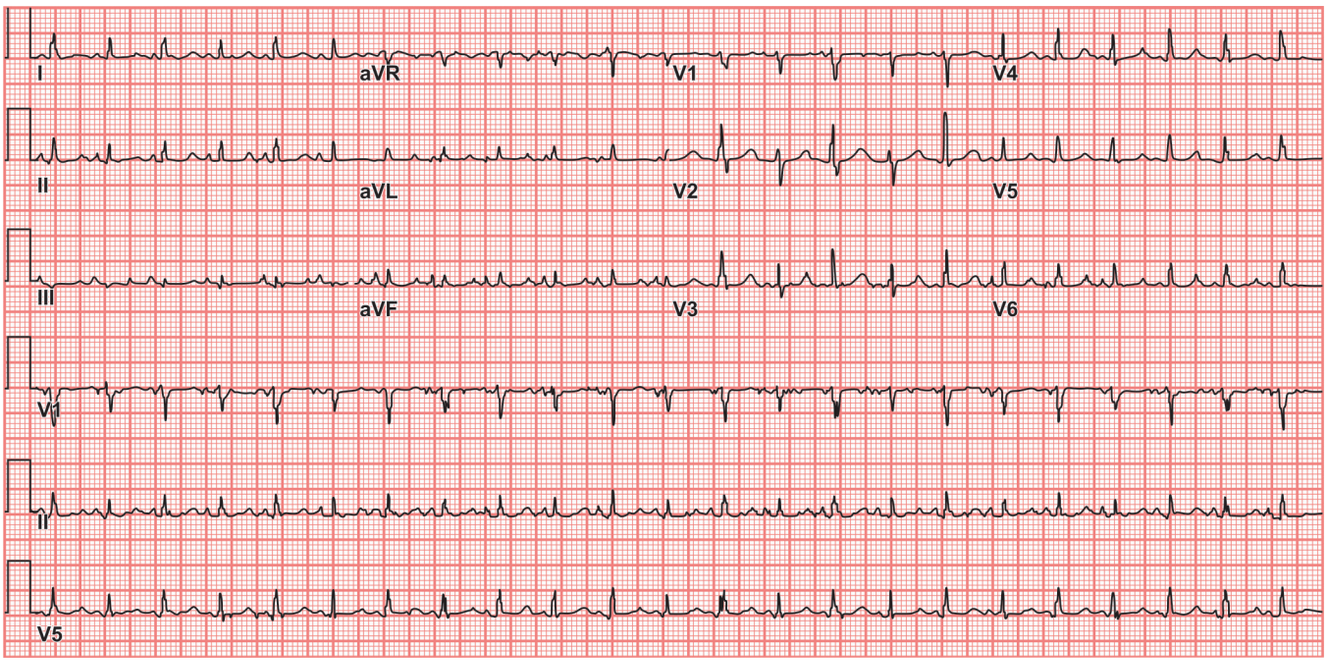

Fig. 14.6: ECG shows low voltage graph, QRS alterans and sinus tachycardia in cardiac tamponade

- Conditions that may simulate pericardial effusion on 2-dimensional echocardiography include the following:
  - A large left pleural effusion
  - Any tumor surrounding the heart
  - Mitral annular calcification
  - A descending thoracic aorta
  - A catheter in the right ventricle
  - An enlarged left atrium
  - An annular subvalvular LV aneurysm
  - A bronchogenic cyst

Other Sective Tests

12-lead electrocardiogram: The following findings are suggestive but not diagnostic of pericardial tamponade.

- Sinus tachycardia (Figs 14.6)
- Low-voltage QRS complexes
- Electrical alternans (also observed during supraventricular and ventricular tachycardia): Alternation of QRS complexes, usually in a 2:1 ratio, on electrocardiogram findings is called electrical alternans. This is due to movement of the heart in the pericardial space. Electrical alternans is also observed in patients with myocardial ischemia, acute pulmonary embolism, and tachyarrhythmias.
- PR segment depression
- A 12-lead electrocardiogram showing sinus tachycardia with electrical alternans.

Computed tomography (CT) imaging of the heart: Gold et al. reported compression of the coronary sinus as observed by CT imaging as an earlier marker for cardiac tamponade in 46% of patients (Figs 14.7, 14.9 and 14.10).

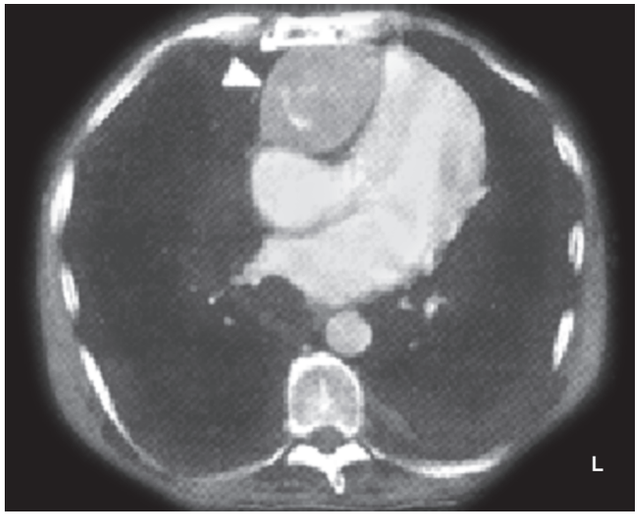

Fig.14.7: CAT scan showing localised cardiac tamponad caused by intrapericardial hematoma after 10 years of open heart surgery

Pulse-oximetry: Respiratory variability in pulse-oximetry waveform noted in patients with pulsus paradoxus. In a small group of patients with tamponade, Stone et al. noted increased respiratory variability in pulse-oximetry waveform in all patients. This should raise the suspicion for hemodynamic compromise. In patients with atrial fibrillation, pulse-oximetry may aid to detect the presence of pulsus paradoxus.

Procedures

- Before or after insertion of the Swan-Ganz catheter, the system must be zeroed after positioning the transducer

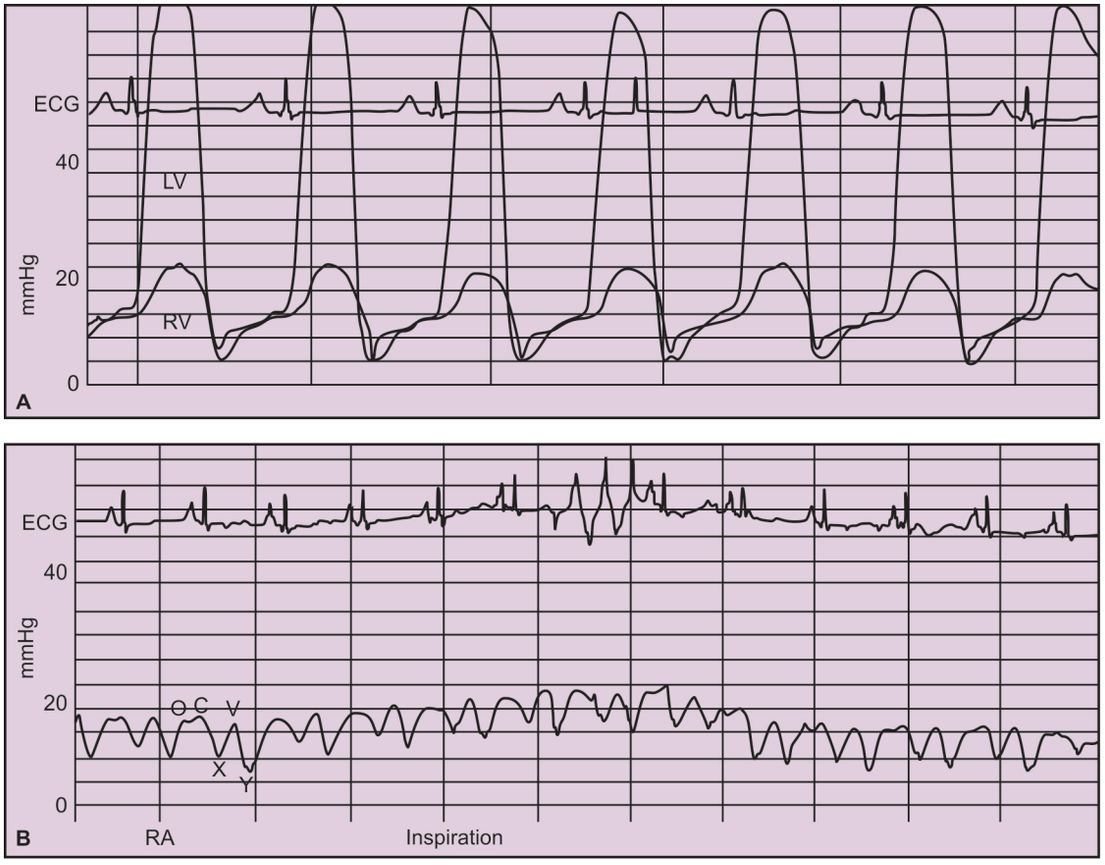

Fig. 14.8: Hemodynamic monitoring can confirm the diagnosis of pericardial tamponade. Equalization of diastolic pressures on the left and right sides of the heart, elevated right atrial pressure, and Kussmaul sign (i.e. increase in right atrial pressure with inspiration) are noted

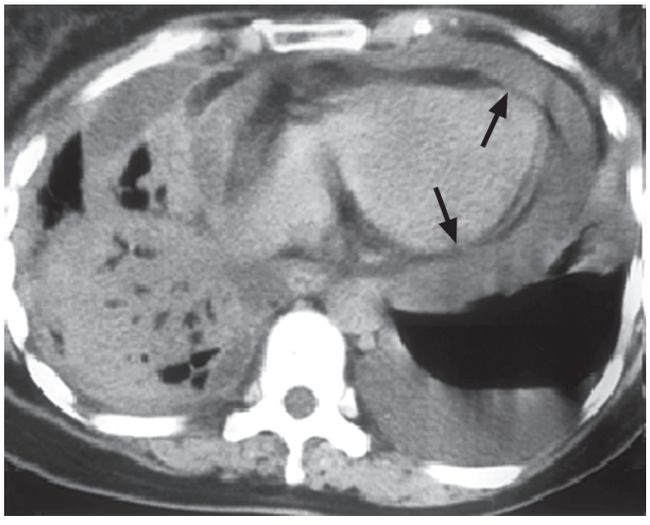

Fig. 14.9: Cardiac tamponade. CT scan shows a large pericardial effusion (arrows), which was positive for ovarian cancer. There are also malignant pleural effusions with consolidation of the right lung base

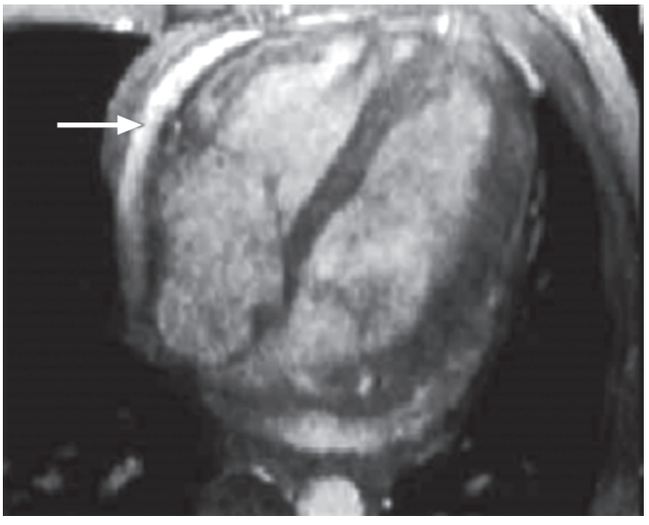

Fig. 14.10: This two chamber long axis gradient echo image shows a bright fluid collection in the pericardial space (arrowhead). If this fluid accumulated quickly, the patient may experience symptoms of cardiac tamponade

at the midpoint of the left atrium. Then calibrate the monitoring system. Prior to insertion, test the balloon and flush all the ports. Then insert the catheter into one of the major veins. At a depth of 20 cm, inflate the balloon and slowly advance the catheter, while continuously monitoring the pressure from the distal lumen. Always

deflate the balloon before withdrawing the Swan-Ganz catheter. The waveforms help indicate the position of the catheter tip if fluoroscopy is not readily accessible. At approximately the 40–50 cm mark, the wedge pressure is usually recorded. Secure the catheter position, and obtain a chest radiograph to confirm the position (Fig. 14.8).

- In tamponade, near equalization (within 5 mmHg) of the right atrial, right ventricular diastolic, pulmonary arterial diastolic, and pulmonary capillary wedge pressure (reflecting left atrial pressure) occurs. The right atrial pressure tracings display a prominent systolic x descent and abolished systolic y descent.
- Boltwood et al. described the diastolic equalization of pulmonary capillary and right atrial pressures as predominantly inspiratory, known as the inspiratory traction sign. This is due to inspiratory traction of the taut pericardium by the diaphragm.

HISTOLOGIC FINDINGS

Occasionally, a pericardial biopsy is performed when the etiology of the pericardial effusion that caused the tamponade is unclear. This is especially useful in cases of tuberculous pericardial effusions because cultures of the pericardial fluid in these cases rarely yield a positive result for mycobacteria. However, granulomas seen on pericardial biopsy specimens are often seen in patients with tuberculous pericarditis. In general, cytopathologic findings from pericardial fluid and histologic findings from pericardial biopsy specimens depend on the underlying pathology. Cytological examination identifies etiopathological cause of tamponade in about 75% of cases.

MANAGEMENT

Medical Care

Cardiac tamponade is a medical emergency. Preferably, patients should be monitored in an intensive care unit.

- All patients should receive the following:
  - Oxygen
  - Volume expansion with blood, plasma, dextran, or isotonic sodium chloride solution, as necessary to maintain adequate intravascular volume: Sagrista-Saauleda et al. noted significant increase in cardiac output after volume expansion.
  - Bed rest with leg elevation: This may help increase venous return.
  - *Inotropic drugs (e.g. dobutamine):* These can be useful because they do not increase systemic vascular resistance while increasing cardiac output.
- Positive-pressure mechanical ventilation should be avoided because it may decrease venous return and aggravate signs and symptoms of tamponade.
- Further medical care includes pericardiocentesis. Removal of pericardial fluid is the definitive therapy for tamponade and can be done by the following methods.

Emergency Subxiphoid Percutaneous Drainage

This is a life-saving bedside procedure. The subxiphoid approach is extrapleural; hence, it is the safest for blind pericardiocentesis. A 16- or 18-gauge needle is inserted at an angle of 30–45° to the skin, near the left xiphocostal angle, aiming towards the left shoulder. When performed emergently, this procedure is associated with a reported mortality rate of approximately 4% and a complication rate of 17% (Fig. 14.11).

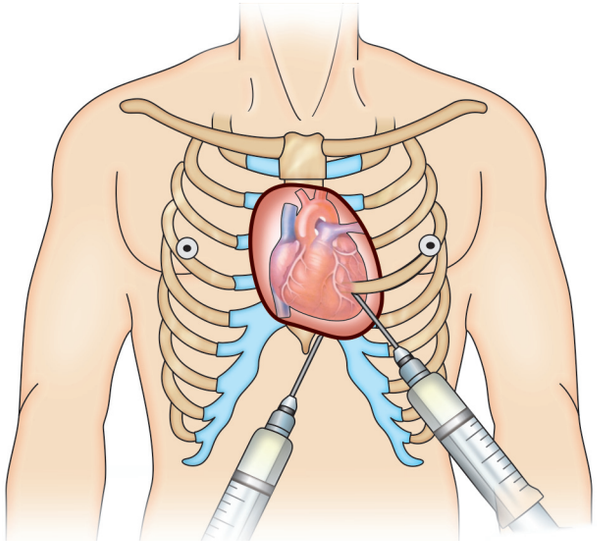

Fig. 14.11: Cardiac tamponade pericardiocentesis, a potentially lethal procedure, should be done using echocardiographic guidance in a cardiac catheterization laboratory and should be supervised by a cardiologist or thoracic surgeon if possible. Resuscitation equipment must be at hand. IV sedation (e.g. morphine 0.1 mg/kg or meperidine 1 mg/kg plus midazolam 3 to 5 mg) is desirable. The patient should be recumbent, with the head elevated 30° from the horizontal. Under aseptic conditions, the skin and subcutaneous tissues are infiltrated with lidocaine A 75 mm short-beveled, 16-gauge needle is attached via a 3-way stopcock to a 30 or 50 ml syringe. The pericardium may be entered via the right or left xiphocostal angle or from the tip of the xiphoid process with the needle directed inward, upward, and close to the chest wall. The needle is advanced with constant suction applied to the syringe. Echocardiography may be used to guide the needle as agitated saline is injected through it. Echocardiography is also increasingly used to identify the optimal puncture site and the needle trajectory. Once in place, the needle should be clamped next to the skin to prevent it from entering further than necessary and possibly puncturing the heart or injuring a coronary vessel. ECG monitoring is essential for detecting arrhythmias produced when the myocardium is touched or punctured. As a rule, right atrial pressure and pulmonary artery occlusion pressure (pulmonary capillary wedge pressure) are monitored. Fluid is withdrawn until intrapericardial pressure falls below right atrial pressure, usually to subatmospheric levels. If continued drainage is needed, a plastic catheter may be passed through the needle into the pericardium and the needle withdrawn. The catheter may be left in place for 2–4 days

Echocardiographically Guided Pericardiocentesis

This is usually performed from the left intercostal space. First, mark the site of entry based on the area of maximal fluid accumulation closest to the transducer. Then, measure the distance from the skin to the pericardial space. The angle of the transducer should be the trajectory of the needle during the procedure. Avoid the inferior rib margin while advancing the needle to prevent neurovascular injury. Leave a 16-gauge catheter in place for continuous drainage (Figs 14.12–14.15).

- **Percutaneous balloon pericardiotomy:** This can be performed using an approach similar to that for echo-guided pericardiocentesis, in which the balloon is used to create a pericardial window.
- Patients should receive treatment of the underlying cause to prevent recurrence.

Surgical Care

For a hemodynamically unstable patient or one with recurrent tamponade, provide the following care:

- *Surgical creation of a pericardial window:* This involves the surgical opening of a communication between the pericardial space and the intrapleural space. This is usually a subxiphoidian approach with resection of xiphoid. Recently, a left paraxiphoidian approach with preservation of xiphoid has been described. Open thoracotomy and/or pericardiotomy may be required in some cases, and these should be performed by an experienced surgeon.
- *Pericardiocentesis or sclerosing the pericardium:* This is a therapeutic option for patients with recurrent pericardial effusion or tamponade. Through the intrapericardial catheter, corticosteroids, tetracycline, or antineoplastic drugs (e.g. anthracyclines, bleomycin) can be instilled into the pericardial space.
- *Pericardio-peritoneal shunt:* In some patients with malignant pericardial effusions, creation of a pericardio-peritoneal shunt helps prevent recurrent tamponade.
- *Pericardiectomy:* Resection of the pericardium (pericardiectomy) through a median sternotomy or left thoracotomy is rarely required to prevent recurrent pericardial effusion and tamponade. Monaco et al. investigated the efficacy of a modified, video-assisted thoracoscopic procedure in the treatment of 15 patients with cardiac tamponade. Using a right hemithoracic approach, a 15-mm trocar was employed on the fourth right intercostal space on the anterior axillary, and a 10-mm trocar was used on the seventh right intercostal space on the median axillary line. Utilization of a 5-mm optic allowed 2 instruments, for the optic and for the endoscopic forceps, to be employed simultaneously

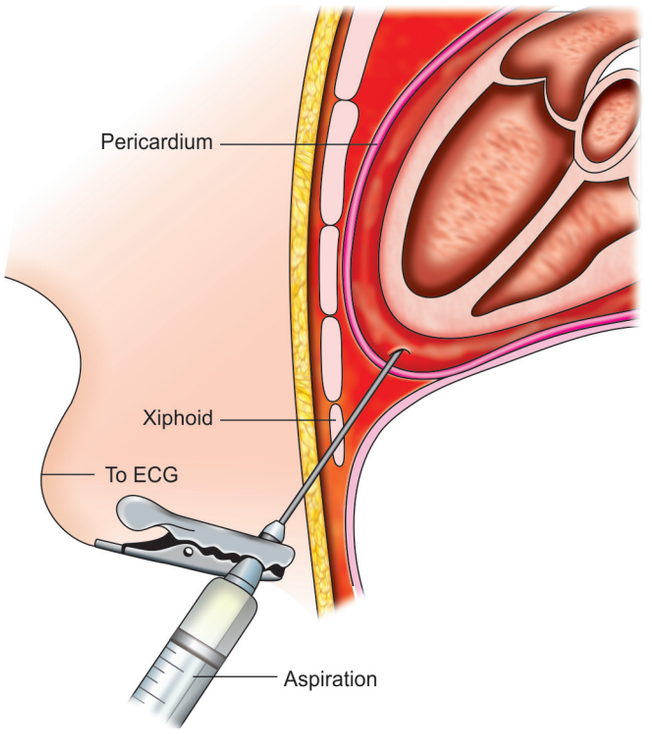

Fig. 14.12: Steps and proper positioning of pericardiocentesis needle

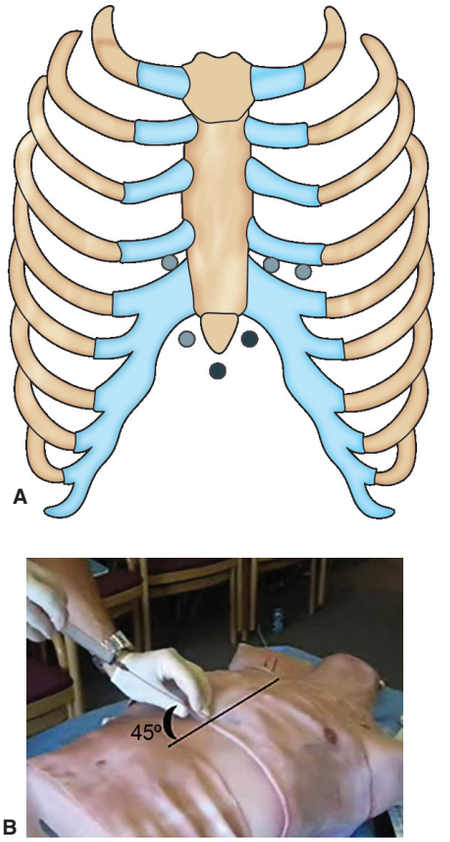

Fig. 14.13: (A) Pericardiocentesis needle insertion sites. The subxiphoid and the left sternocostal margin are the most commonly used sites (black dots). (B) Needle insertion—insert the spinal needle through the skin incision directed toward the left shoulder at a 45-degree angle to the abdominal wall and 45 degrees off the midline sagittal plane

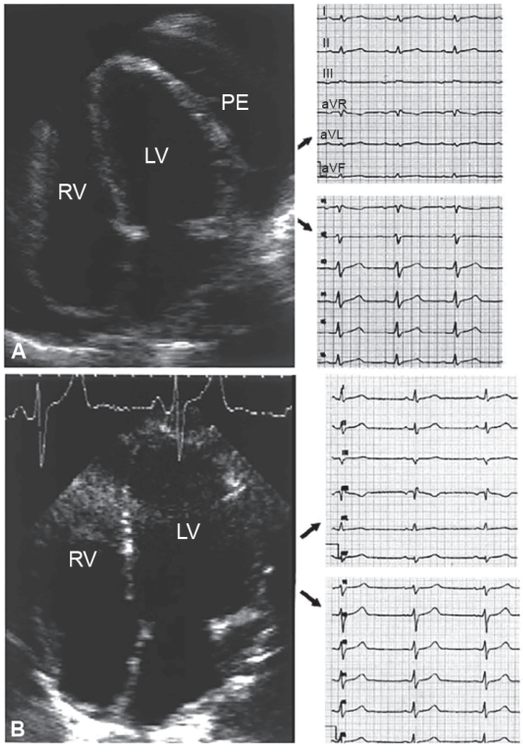

Fig.14.14: (A) A 23-year-old man with acute lymphatic leukemia who was treated with prednisolone due to recurrent malignant pericardial effusion. Note low QRS voltage in the limb leads before initiation of medical treatment. (B) Same patient as in (A) 6 days after initiation of anti-inflammatory treatment. Note the change of the QRS axis and the significant increase of maximum QRS amplitude in the limb leads. LV=left ventricle; RV=right ventricle

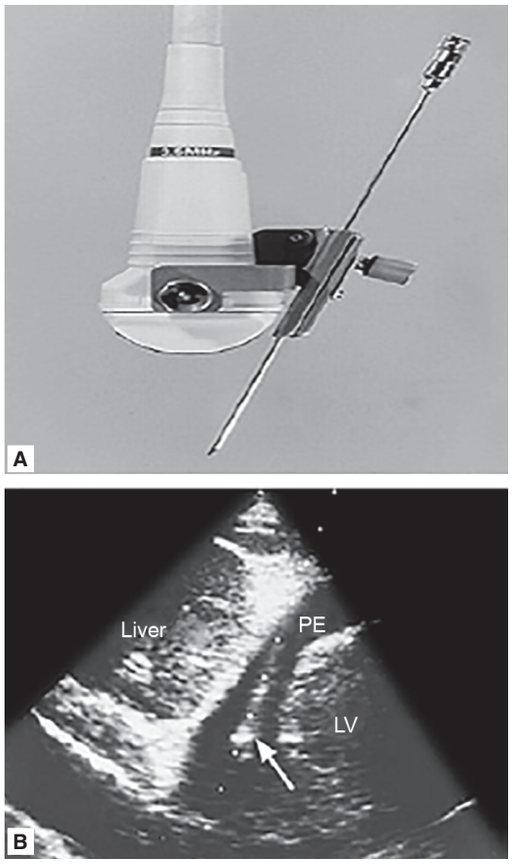

Fig.14.15: (A) Echocardiographic probe (UST-944B) with needle attached. The needle is held at an invariable angle with respect to the probe. (B) Two-dimensional echocardiographic image obtained during pericardiocentesis before introduction of the guidewire. The line of dots shows the direction of the puncture

using 1 trocar; this left the second trocar available for dissecting scissors. All patients underwent a pericardial resection equal to those achieved via anterolateral thoracotomy.

The pericardial effusion was effectively drained in all patients, with no intraoperative mortality or perioperative morbidity encountered. The investigators concluded, therefore, that the modified, video-assisted procedure employed in the study seems to be a feasible treatment for cardiac tamponade.

Consultations

- Hemodynamically stable patients—cardiologist
- Hemodynamically unstable patient—cardiologist, cardiothoracic surgeon

Activity

Initially, the patient should be on bed rest with leg elevation to increase the venous return. Once signs and symptoms of tamponade resolve, activity can be increased as tolerated.

Medication

The role of medication therapy in cardiac tamponade is limited. Occasionally, inotropic agents that do not increase the peripheral vascular resistance, such as dobutamine, may be used.

Adrenergic Agonist Agents

By stimulating beta-1 receptors in the heart, stroke volume and cardiac output are increased.

Dobutamine (Dobutrex)

Synthetic catecholamine and a direct inotropic agent that stimulates cardiac beta-receptors with minimal increase in systemic vascular resistance.

Adult

0.5–1 mcg/kg/min IV initially; titrate until desired therapeutic effect attained

Pediatric

Follow-up.

Further Inpatient Care

- After pericardiocentesis, leave the intrapericardial catheter in place after securing it to the skin using sterile

procedure and attaching it to a closed drainage system via a 3-way stopcock. Periodically check for reaccumulation of fluid, and drain as needed. The catheter can be left in place for 1–2 days and can be used for pericardiocentesis. Serial fluid cell counts can be useful for helping discover an impending bacterial catheter infection, which could be catastrophic. If the WBC count rises significantly, the pericardial catheter must be removed immediately.

- A Swan-Ganz catheter can be left in place for continuous monitoring of hemodynamics and to assess the effect of reaccumulation of pericardial fluid.
- A repeat echocardiogram should be performed within 24 hours.
- A repeat chest radiograph should be performed within 24 hours.

FURTHER OUTPATIENT CARE

A follow-up echocardiogram and chest radiograph should be performed at a monthly follow-up examination to check for recurrent fluid accumulation.

Complications

- Pulmonary edema
- Shock
- Death

Prognosis

Prognosis depends on prompt recognition and management of the condition and the underlying cause of the tamponade. Cornily et al. reported 1-year mortality of 76.5% in patients with malignant disease compared with 13.3% in patients without malignant disease. They also noted a median survival of 150 days in patients with malignant disease.

Medicolegal Pitfalls

- Be aware of clinical conditions that may simulate tamponade or pericardial effusion on two-dimensional echocardiography findings.
- Pulsus paradoxus may be absent in patients with low-pressure tamponade, right heart tamponade, or atrial septal defects.
- Pulsus paradoxus can be observed in patients with nontamponade conditions involving labored breathing (e.g. asthma, severe chronic obstructive pulmonary disease) and in those with right ventricular infarction.
- Tension pneumothorax may clinically simulate cardiac tamponade.
- Early diagnosis with a high index of suspicion is necessary to minimize the morbidity and mortality from tamponade.

QUICK READINGS IN CARDIAC TAMPONADE

Cardiac tamponade is accumulation of blood in the pericardial sac of sufficient volume and pressure to impair cardiac filling. Patients typically have hypotension, muffled heart tones, and distended neck veins. Diagnosis is made clinically and often with bedside echocardiography. Treatment is immediate pericardiocentesis or pericardiotomy.

Fluid in the pericardial sac can impair cardiac filling, leading to low cardiac output and sometimes shock and death. If fluid accumulates slowly (e.g. due to chronic inflammation), the pericardium can stretch to accommodate up to 1–1.5 L of fluid before cardiac output is compromised. However, with rapid fluid accumulation, as occurs with traumatic hemorrhage, as little as 150 ml may cause tamponade.

In trauma, the cause is more often penetrating than blunt trauma. The wound is often medial to the nipples (for anterior wounds) or the scapulae (for posterior wounds). Tamponade due to blunt trauma involves cardiac chamber rupture, which is typically fatal before patients can be brought for treatment.

Symptoms and Signs

Classically, patients have Beck triad, which consists of the following:

- Hypotension
- Muffled heart tones
- Venous pressure increase (e.g. neck vein distention)

However, hypotension has multiple potential causes in trauma patients, muffled heart tones can be difficult to assess during a noisy trauma resuscitation, and neck vein distention can be absent due to hypovolemia. Pulsus paradoxus (*see* pulsus paradoxus), a decrease in systolic BP during inspiration of >10 mmHg, is also suggestive, but again not easy to assess in a noisy setting.

Diagnosis

- Clinical evaluation
- Often bedside echocardiography

Diagnosis can be difficult. Beck triad is considered diagnostic but may not be present or easy to recognize. In addition, tension pneumothorax (*see* pneumothorax (tension) also should be considered in patients with hypotension and neck vein distention, although this disorder typically causes markedly decreased breath sounds and hyperresonance on the affected hemithorax. Bedside transthoracic echocardiography can be diagnostic and can be done during the initial evaluation and resuscitation but may be falsely negative. The diagnosis sometimes is suggested by unexplained failure to respond to volume resuscitation.

Treatment

Pericardiocentesis

Sometimes pericardiotomy or creation of a pericardial window.

Subxiphoidal pericardiocentesis is done in unstable patients when cardiac tamponade is suspected. Electrocardiographic monitoring during the insertion needle for ST-segment elevation (indicating contact with the epicardium and the need to withdraw the needle) is done if possible. Pericardiocentesis is a temporizing measure. Removal of as little as 10 ml of blood may normalize BP. However, failure to aspirate blood does not exclude the diagnosis; fresh blood in the pericardium is often clotted. Thoracotomy with pericardiotomy or establishment of a subxiphoidal pericardial window are more definitive treatments, which are indicated in patients in whom the diagnosis is confirmed or strongly suspected. If adequately trained personnel are available and the patient is unstable and fails to respond to other resuscitative measures, one of these procedures can be done at the bedside in the emergency setting. Otherwise, the procedure is done in the operating room as soon as feasible.

KEY POINTS

1. Cardiac tamponade is most often caused by a penetrating wound medial to the nipples (for anterior wounds) or the scapulae (for posterior wounds).
2. The triad of muffled heart tones, hypotension, and neck vein distention is diagnostic but not always present; in their absence, bedside echocardiography should be done if the diagnosis is suspected.
3. Subxiphoidal pericardiocentesis is a temporizing measure and may be falsely negative; a pericardial window or pericardiotomy are more definitive.

BIBLIOGRAPHY

1. Aikat S, Ghaffari S. A review of pericardial diseases: clinical, ECG and hemodynamic features and management. Cleve Clin J Med 2000;67(12):903–14.
2. Alam HB, Levitt A, Molyneaux R, et al. Can pleural effusions cause cardiac tamponade. Chest 1999;116(6):1820–2.
3. Allen KB, Faber LP, Warren WH, Shaar CJ. Pericardial effusion: subxiphoid pericardiostomy versus percutaneous catheter drainage. Ann Thorac Surg 1999;67(2):437–40.
4. Beauchamp KA. Pericardial tamponade: an oncologic emergency. Clin J Oncol Nurs 1998;2(3):85–95.
5. Best Evidence] Roy CL, Minor MA, Brookhart MA, Choudhry NK. Does this patient with a pericardial effusion have cardiac tamponade. JAMA 2007;297(16):9.
6. Boltwood C, Rieders D, Gregory KW. Inspiratory tracking sign in pericardial disease. Circulation 1984;70(Suppl II):103.
7. Chen Y, Brennessel D, Walters J, et al. Human immunodeficiency virus-associated pericardial effusion: report of 40 cases and review of the literature. Am Heart J 1999; 137(3): 516–21.
8. Cornily JC, Pennec PY, Castellant P, et al. Cardiac tamponade in medical patients: a 10-year follow-up survey. Cardiology 2008;111(3):197–201.
9. Eisenberg MJ, de Romeral LM, Heidenreich PA, et al. The diagnosis of pericardial effusion and cardiac tamponade by 12-lead ECG. A technology assessment. Chest 1996;110(2): 318–24.
10. Gold MM, Spindola-Franco H, Jain VR, et al. Coronary sinus compression: an early computed tomographic sign of cardiac tamponade. J Comput Assist Tomogr 2008;32(1):72–7.
11. Goldstein JA. Cardiac tamponade, constrictive pericarditis, and restrictive cardiomyopathy. Curr Probl Cardiol 2004; 29(9):503–67.
12. Griffin S, Fountain W. Pericardio-peritoneal shunt for malignant pericardial effusion. J Thorac Cardiovasc Surg 1989; 98(6):1153–4.
13. Guberman BA, Fowler NO, Engel PJ, et al. Cardiac tamponade in medical patients. Circulation. 1981;64(3):633–40.
14. Holmes DR Jr, Nishimura R, Fountain R, et al. Iatrogenic pericardial effusion and tamponade in the percutaneous intracardiac intervention era. JACC Cardiovasc Interv 2009; 2(8):705–17.
15. Ikematsu Y. Incidence and characteristics of dysphoria in patients with cardiac tamponade. Heart Lung 2007;36(6): 440–9.
16. Kaplan LM, Epstein SK, Schwartz SL, et al. Clinical, echocardiographic, and hemodynamic evidence of cardiac tamponade caused by large pleural effusions. Am J Respir Crit Care Med 1995;151(3 Pt 1):904–8.
17. Lee YM, Kim HJ, Lee JE, et al. Cardiac tamponade following insertion of an internal jugular vein catheter for hemodialysis. Clin Nephrol 2009;72(3):220–3.
18. Medary I, Steinherz LJ, Aronson DC, La Quaglia MP. Cardiac tamponade in the pediatric oncology population: treatment by percutaneous catheter drainage. J Pediatr Surg 1996;31(1): 197–9; discussion 199–200.
19. Monaco F, Barone M, David A, et al. [Cardiac tamponade: a modified video-assisted thoracoscopic approach]. Chir Ital 2009;61(3):321–6.
20. Motas C, Motas N, Rus O, Horvat T. Left paraxiphoidian approach for drainage of pericardial effusions. Interact Cardiovasc Thorac Surg 2010;10(1):4–5.
21. Müller-Stich BP, Linke G, Leemann B, Lange J, Zerz A. Cardiac tamponade as a life-threatening complication in antireflux surgery. Am J Surg 2006;191(1):139–41.
22. Parvez N, Carpenter JL. Cardiac tamponade in Still disease: a review of the literature. South Med J 2009;102(8):832–7.
23. Patel MR, Meine TJ, Lindblad L, Griffin J, Granger CB, Becker RC. Cardiac tamponade in the fibrinolytic era: analysis of >100,000 patients with ST-segment elevation myocardial infarction. Am Heart J 2006;151(2):316–22.
24. Paunovic B, Sharma S, Miller A. Swan-Ganz Catheterization. eMedicine Journal [serial online]. 2005.
25. Petcu DP, Petcu C, Popescu CF, Bataiosu C, Alexandru D. Clinical and cytological correlations in pericardial effusions with cardiac tamponade. Rom J Morphol Embryol 2009; 50(2):251–6.
26. Reddy PS, Curtiss EI, Uretsky BF. Spectrum of hemodynamic changes in cardiac tamponade. Am J Cardiol 1990; 66(20): 1487–91.
27. Reddy PS, Curtiss EI. Cardiac tamponade. Cardiol Clin 1990; 8(4):627–37.

28. Rylski B, Siepe M, Schoellhorn J, et al. Endoscopic treatment for delayed cardiac tamponade. Eur J Cardiothorac Surg 2009.
29. Sagristà-Sauleda J, Angel J, Sambola A, et al. Low-pressure cardiac tamponade: clinical and hemodynamic profile. Circulation 2006;114(9):945–52.
30. Sagristà-Sauleda J, Angel J, Sambola A, et al. Hemodynamic effects of volume expansion in patients with cardiac tamponade. Circulation 2008;117(12): 1545–9.
31. Saito Y, Donohue A, Attai S, et al. The syndrome of cardiac tamponade with 'small' pericardial effusion. Echocardiography 2008;25(3):321–7.
32. Spodick DH. Diseases of the pericardium. In: Chatterjee K, (Ed.) Cardiology: An Illustrated Text/Reference. Vol 2. New York, NY: Gower Medical. 1991:10.38–10.64.
33. Spodick DH. Pericarditis, pericardial effusion, cardiac tamponade, and constriction. Crit Care Clin 1989;5(3): 455–76.
34. Stone MK, Bauch TD, Rubal BJ. Respiratory changes in the pulse-oximetry waveform associated with pericardial tamponade. Clin Cardiol 2006;29(9):411–4.
35. Towbin R. The bowed catheter sign: a risk for pericardial tamponade. Pediatr Radiol 2008;38(3):331–5.

15 Recognition and Management of Cardiomyopathies

Cardiomyopathy, or heart muscle disease, is a type of progressive heart disease in which the heart is abnormally enlarged, thickened, and/or stiffened. As a result, the heart muscle's ability to pump blood is weakened, often causing heart failure and the backup of blood into the lungs or rest of the body. The disease can also cause abnormal heart rhythms.

Usually, cardiomyopathy begins in the heart's lower chambers (the ventricles), but in severe cases can affect the upper chambers or atria as well.

DEFINITION AND CLASSIFICATION

Cardiomyopathies are defined as diseases of the myocardium associated with cardiac dysfunction. They are classified as dilated cardiomyopathy, hypertrophic cardiomyopathy, restrictive cardiomyopathy, and arrhythmogenic right ventricular cardiomyopathy (Figs 15.1, 15.2 and Table 15.1).

Dilated Cardiomyopathy

Dilated cardiomyopathy is characterized by dilatation and impaired contraction of the left ventricle or both ventricles. It may be idiopathic, familial/genetic, viral and/or immune, alcoholic/toxic, or associated with recognized cardiovascular disease in which the degree of myocardial dysfunction is not explained by the abnormal loading conditions or the extent of ischemic damage. Histology is nonspecific. Presentation is usually with heart failure, which is often progressive. Arrhythmias, thromboembolism, and sudden death are common and may occur at any stage.

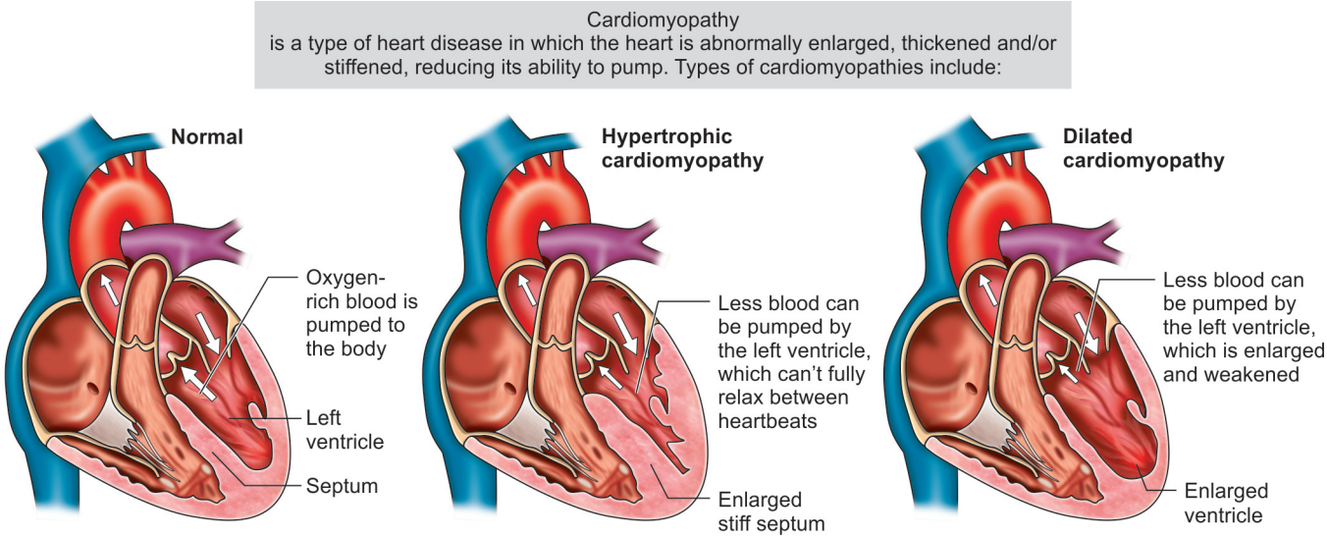

Fig. 15.1: Comparative description of normal heart functioning with two common types of cardiomyopathies

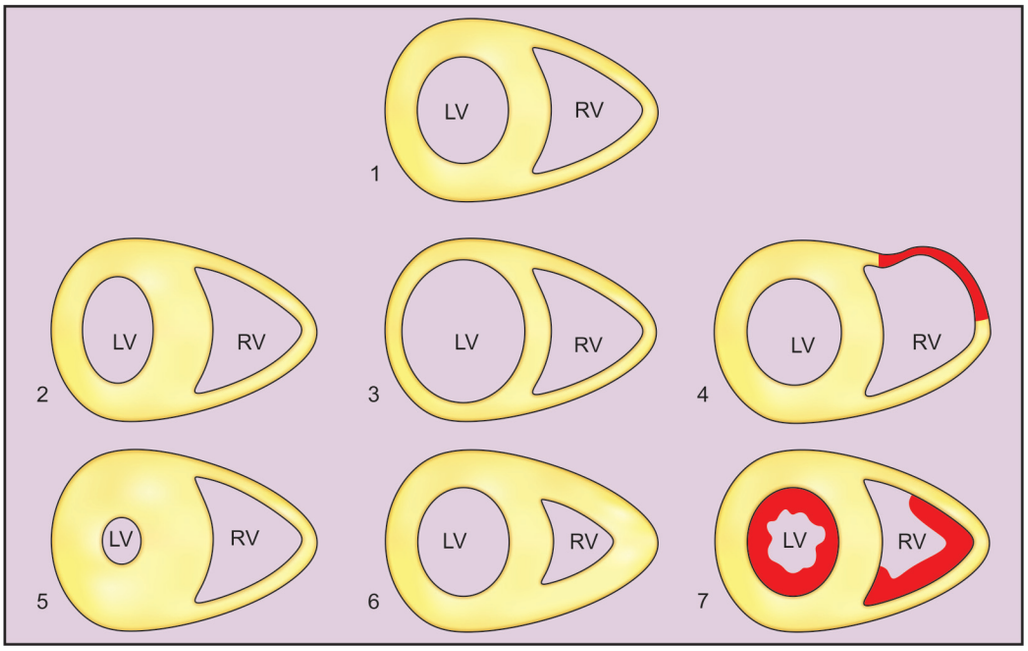

Fig. 15.2: Diagrammatic representation of different types of cardiomyopathies at short axis views and right and left ventricles at mid-septal levels. (1) Normal, (2) HCM, nonobstructive hypertrophic cardiomyopathy, (3) DCM, dilated cardiomyopathy, (4) ARVD, arrhythmogenic right ventricular dysplasia, (5) HOCM, hypertrophic obstructive cardiomyopathy, (6) RCM, restrictive cardiomyopathy, (7) EMF, endomyocardial fibrosis or obliterative cardiomyopathy

Table 15.1: Classification of cardiomyopathies

Primary/intrinsic cardiomyopathies	Secondary/extrinsic cardiomyopathies
Genetic	**Metabolic/storage**
• Hypertrophic cardiomyopathy (HCM or HOCM)	• Amyloidosis
• Arrhythmogenic right ventricular cardiomyopathy (ARVC)	• Hemochromatosis
• Isolated ventricular noncompaction	**Inflammatory**
• Mitochondrial myopathy	• Chagas disease
Mixedc	**Endocrine**
• Dilated cardiomyopathy (DCM)	• Diabetic cardiomyopathy
• Restrictive cardiomyopathy (RCM)	• Hyperthyroidism
Acquired	• Acromegaly
• Takotsubo cardiomyopathy	**Toxicity**
• Loeffler endocarditis	• Chemotherapy
	• Alcoholic cardiomyopathy
	Neuromuscular
	• Muscular dystrophy
	Nutritional diseases
	• Obesity-associated cardiomyopathy
	Other
	• 'Ischemic cardiomyopathy' is a weakness in the muscle of the heart due to inadequate oxygen delivery to the myocardium with coronary artery disease being the most common cause. Not supported by caurent cardiomyopathies classification schemes.

Hypertrophic Cardiomyopathy

Hypertrophic cardiomyopathy is characterized by left and/or right ventricular hypertrophy, which is usually asymmetric and involves the interventricular septum. Typically, the left ventricular volume is normal or reduced. Systolic gradients are common. Familial disease with autosomal dominant inheritance predominates. Mutations in sarcomeric contractile protein genes cause disease. Typical morphological changes include myocyte hypertrophy and disarray surrounding areas of increased loose

connective tissue. Arrhythmias and premature sudden death are common.

Restrictive Cardiomyopathy

Restrictive cardiomyopathy is characterized by restrictive filling and reduced diastolic volume of either or both ventricles with normal or near-normal systolic function and wall thickness. Increased interstitial fibrosis may be present. It may be idiopathic or associated with other disease (e.g. amyloidosis; endomyocardial disease with or without hypereosinophilia).

Arrhythmogenic Right Ventricular Cardiomyopathy

Arrhythmogenic right ventricular cardiomyopathy is characterized by progressive fibrofatty replacement of right ventricular myocardium, initially with typical regional and later global right and some left ventricular involvement, with relative sparing of the septum. Familial disease is common, with autosomal dominant inheritance and incomplete penetrance; a recessive form is described. Presentation with arrhythmias and sudden death is common, particularly in the young.

Unclassified Cardiomyopathies

Unclassified cardiomyopathies include a few cases that do not fit readily into any group (e.g. fibroelastosis, non-compacted myocardium, systolic dysfunction with minimal dilatation, and mitochondrial involvement).

Some diseases may present with features of more than one type of cardiomyopathy (i.e. amyloidosis, systemic hypertension). It is recognized that arrhythmias and conduction disease may be primary myocardial disorders. At this time, however, it was elected not to include them as cardiomyopathies.

Specific Cardiomyopathies

The term specific cardiomyopathies is now used to describe heart muscle diseases that are associated with specific cardiac or systemic disorders. These were previously defined as specific heart muscle diseases.

Ischemic cardiomyopathy presents as a dilated cardiomyopathy with impaired contractile performance not explained by the extent of coronary artery disease or ischemic damage.

Valvular cardiomyopathy presents with ventricular dysfunction that is out of proportion to the abnormal loading conditions.

Hypertensive cardiomyopathy often presents with left ventricular hypertrophy in association with features of dilated or restrictive cardiomyopathy with cardiac failure.

Inflammatory cardiomyopathy is defined by myocarditis in association with cardiac dysfunction. Myocarditis is an inflammatory disease of the myocardium and is diagnosed by established histological, immunological, and immunohistochemical criteria. Idiopathic, autoimmune, and infectious forms of inflammatory cardiomyopathy are recognized. Inflammatory myocardial disease is involved in the pathogenesis of dilated cardiomyopathy and other cardiomyopathies, e.g. Chagas' disease, HIV, enterovirus, adenovirus, and cytomegalovirus.

Metabolic cardiomyopathy includes the following categories: Endocrine, e.g. thyrotoxicosis, hypothyroidism, adrenal cortical insufficiency, pheochromocytoma, acromegaly, and diabetes mellitus; familial storage disease and infiltrations, e.g. hemochromatosis, glycogen storage disease, Hurler's syndrome, Refsum's syndrome, Niemann-Pick disease, Hand-Schüller-Christian disease, Fabry-Anderson disease, and Morquio-Ullrich disease; deficiency, e.g. disturbances of potassium metabolism, magnesium deficiency, and nutritional disorders such as kwashiorkor, anemia, beri-beri, and selenium deficiency; amyloid, e.g. primary, secondary, familial, and hereditary cardiac amyloidoses, familial mediterranean fever, and senile amyloidosis.

General system disease includes connective tissue disorders, e.g. systemic lupus erythematosus, polyarteritis nodosa, rheumatoid arthritis, scleroderma, and dermatomyositis. Infiltrations and granulomas include sarcoidosis and leukemia.

Muscular dystrophies include Duchenne, Becker-type, and myotonic dystrophies.

Neuromuscular disorders include Friedreich's ataxia, Noonan's syndrome, and lentiginosis.

Sensitivity and toxic reactions include reactions to alcohol, catecholamines, anthracyclines, irradiation, and miscellaneous. Alcoholic cardiomyopathy may be associated with a heavy alcohol intake. At present we cannot define a causal versus a conditioning role of alcohol or apply precise diagnostic criteria.

Peripartal cardiomyopathy may first manifest in the peripartum period. This is probably a heterogeneous group.

DILATED CARDIOMYOPATHY

Dilated cardiomyopathy (DCM) is a condition in which the heart becomes weakened and enlarged, and it cannot pump blood efficiently. The decreased heart function can affect the lungs, liver, and other body systems.

There are several different types of cardiomyopathy. Dilated cardiomyopathy is the most common form.

Aetiological Factors

There are many causes of dilated cardiomyopathy. Some of these are:

- Alcohol (alcoholic cardiomyopathy) or cocaine abuse
- Atrial fibrillation, supraventricular tachycardia, or other heart rhythm problems in which the heart beats very fast for a long period of time (called tachycardia-mediated cardiomyopathy)
- Autoimmune illnesses that involve the heart, such as systemic lupus erythematosus and rheumatoid arthritis
- Catecholamine excess from a tumor that releases catecholamines (pheochromocytoma)

- Coronary artery disease (*see* ischemic cardiomyopathy)
- Deficiencies of certain vitamins and minerals (thiamine, calcium, and magnesium)
- End-stage kidney disease
- Family history of cardiomyopathy (some cardiomyopathies run in families and have a genetic component)
- Infections that involve the heart muscle, such as viruses, HIV infection, Chagas disease, and Lyme disease
- Inherited disorders such as muscular dystroph
- Medications that can be toxic to the heart (such as some chemotherapy drugs used to treat cancer)
- Poorly controlled high blood pressure
- Pregnancy
- Stress-induced cardiomyopathy
- Trace elements, such as lead, arsenic, or mercury

This condition can affect anyone at any age. However, it is most common in adult men.

The most common causes of dilated cardiomyopathy in children are:

- Heart (coronary) disease
- Myocarditis
- Some infections
- Unknown cause (idiopathic dilated cardiomyopathy)

Symptoms in Dilated Cardiomyopathy

Symptoms of heart failure are most common. Usually, they develop slowly over time. However, sometimes symptoms start very suddenly and are severe. Common symptoms are:

- Shortness of breath with activity or after lying down (or being asleep) for a while
- Swelling of feet and ankles (in adults)
- Irregular or rapid pulse
- Fatigue, weakness, and faintness
- Swollen liver
- Loss of appetite
- Cough

Other symptoms may include:

- Failure to thrive (in children)
- Need to urinate at night (in adults)

Physical Exams and Laboratory Tests

Cardiomyopathy is usually discovered when the doctor is examining and testing you for the cause of heart failure.

- Tapping over the heart with the fingers and feeling the area may indicate that the heart is enlarged.
- Listening to the chest with a stethoscope reveals lung crackles, heart murmur, or other abnormal sounds.
- The liver may be enlarged.
- Neck veins may be bulging.

A number of laboratory tests may be done to determine the cause:

- Antinuclear antibody (ANA), erythrocyte sedimentation rate (ESR), and other tests to diagnose autoimmune illnesses
- Antibody test to identify infections such as Lyme disease and HIV
- Serum TSH and T4 test to identify thyroid problems

Children will have:

- Poor growth
- Pale skin
- Difficulty feeding
- Weak pulses in the legs and arms

Heart enlargement, congestion of the lungs, decreased movement/functioning of the heart, or heart failure may show on these tests:

- **Echocardiogram (ultrasound of the heart** (Figs 15.3–15.6)
- **Cardiac stress tests**
- **Cardiac catheterization and coronary angiography**

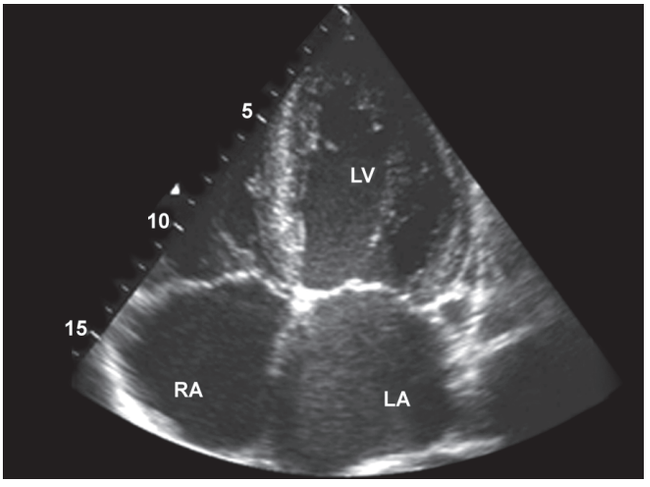

Fig. 15.3: Dilated cardiomyopathy in a 45-year-old woman with AIDS. Apical 4-chamber echocardiographic view shows marked enlargement of all four chambers, as well as spontaneous echo contrast ('smoke') in the left-sided chambers because of a very low ejection fraction and sluggish flow. LA=left atrium, LV=left ventricle, RA=right atrium, RV=right ventricle

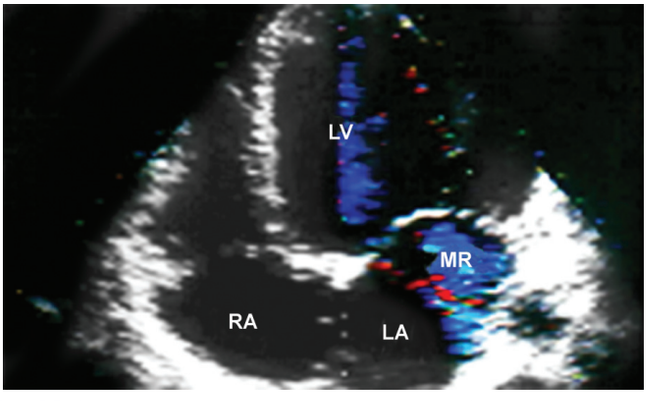

Fig. 15.4: Apical two-dimensional echocardiogram with color Doppler display (systolic image) in a patient with dilated cardiomyopathy shows a jet of mitral regurgitation (MR) into a large left atrium (LA) (Doppler encoded blue). Note the dilatation of the left ventricle (LV) compared with the right ventricle

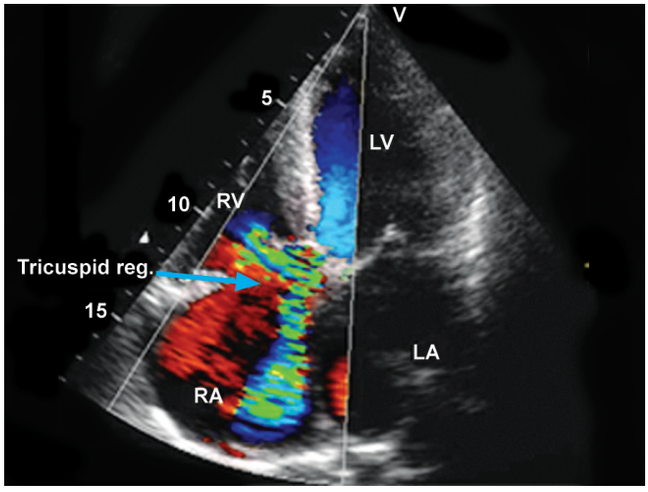

Fig. 15.5: Dilated cardiomyopathy in a 45-year-old woman with AIDS. Apical four-chamber view obtained with color-Doppler flow imaging shows an eccentric jet of severe regurgitation through the tricuspid valve. LA=left atrium, LV=left ventricle, RA=right atrium, RV=right ventricle

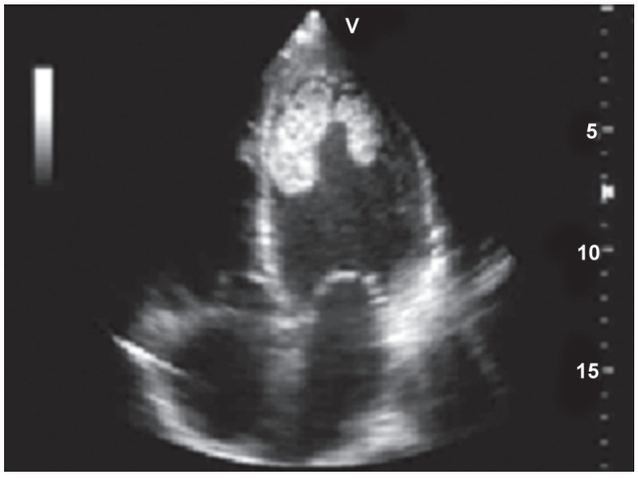

Fig. 15.6: Peripartum cardiomyopathy with left ventricular thrombus

- **Chest CT scan or MRI of the heart** (Figs 15.7 and 15.8)
- **Chest X-ray** (Fig. 15.9)
- **Nuclear heart scan (MUGA, RNV)** (Fig. 15.10)

Other tests may include:

- **ECG** (Fig. 15.11)
- **Heart biopsy**

Lab tests vary depending on the suspected cause.

Treatment in DCM

Treatment for cardiomyopathies focuses on treating heart failure. They include (Fig. 15.12):

- Making important changes in your lifestyle
- Knowing your body and the symptoms of heart failure
- Taking medicines for heart failure
- A pacemaker to help treat slow heart rates or help your heart contract in a more coordinated fashion.

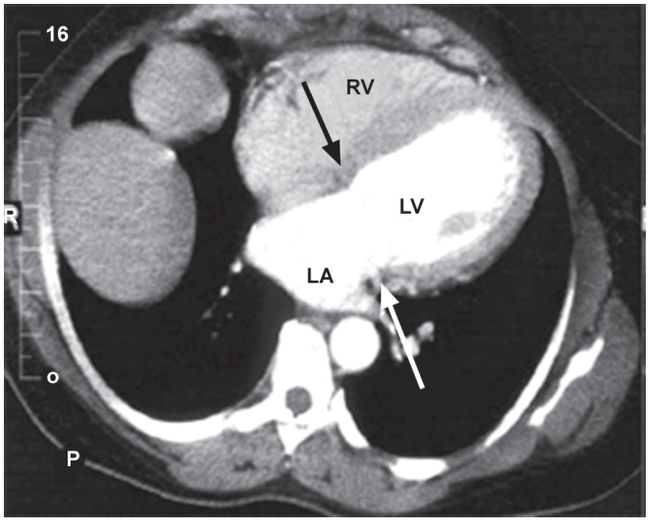

Fig. 15.7: Spiral computed tomography (CT) scan obtained with intravenous contrast enhancement at the level of the center of the mitral valve (between arrows) and tricuspid valve in a patient with dilated cardiomyopathy. Left ventricle (LV) is dilated compared with the right ventricle (RV)

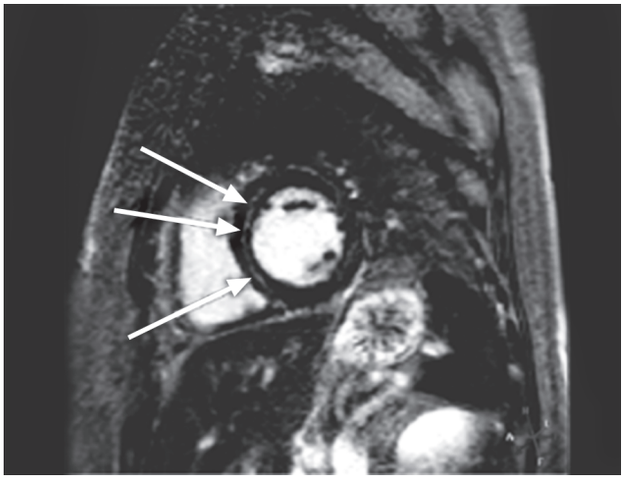

Fig.15.8: Typical mid-septal rim of nonischemic hyperenhancement in a patient with dilated cardiomyopathy

- A defibrillator that recognizes life-threatening, abnormal heart rhythms and sends an electrical pulse to stop them.

Cardiac catheterization might be done to see if you may benefit from coronary artery bypass (CABG) surgery or a balloon procedure (angioplasty), which could improve blood flow to the damaged or weakened heart muscle.

A heart transplant may be recommended for patients who have failed all the standard treatments and still have very severe symptoms.

Prognosis in DCM

The outcome varies. Some people remain in a stable condition for long periods of time, some continue to gradually get sicker, and others quickly get worse. Cardiomyopathy can only be corrected if the disease that caused it can be cured.



Fig. 15.9: Chest radiograph in a patient presenting with heart failure, which was subsequently found to be the result of dilated cardiomyopathy. Although cardiac size is at the upper limit of normal, left ventricular function is poor, causing severe pulmonary edema with bilateral alveolar edema and marked dilatation of the superior vena cava

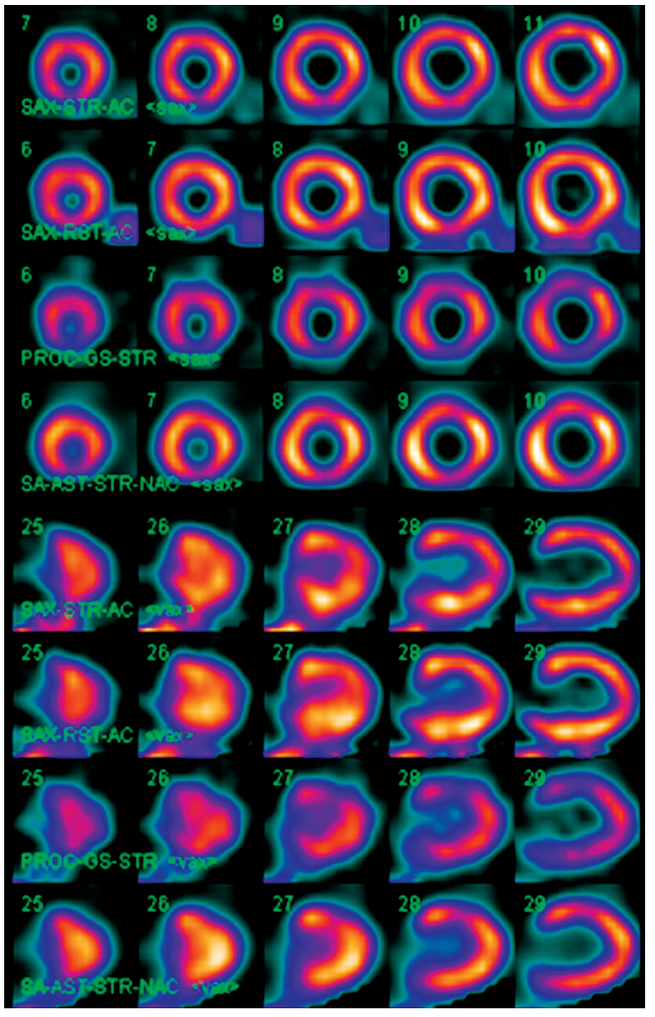

Fig. 15.10: Tec99 Sestamibi cardiac perfusion study demonstrates dilated left ventricular cavity

About one-third of children recover completely, one-third recover but continue to have some heart problems, and one-third die.

Possible Complications

- Arrhythmias (Fig. 15.13)
- Congestive heart failure
- Pulmonary edema
- Side effects of medications, including:
  - » Headache
  - » Gastrointestinal upset
  - » Light-headedness and fainting
  - » Low blood pressure
  - » Lupus reaction (a group of symptoms including a skin rash and arthritis)

When to contact a medical professional

- Call your health care provider if you have symptoms of cardiomyopathy.
- If chest pain, palpitations, or faintness develop seek emergency medical treatment immediately.

Prevention in DCM

- Eat a well-balanced and nutritious diet
- Exercise to improve heart fitness
- Stop smoking
- Minimize alcohol consumption

HYPERTROPHIC CARDIOMYOPATHY

Hypertrophic cardiomyopathy (HCM) is a condition in which the heart muscle becomes thick. The thickening makes it harder for blood to leave the heart, forcing the heart to work harder to pump blood.

Aetiological Factors

Hypertrophic cardiomyopathy is often asymmetrical, meaning one part of the heart is thicker than the other parts. The condition is usually passed down through families (inherited). It is believed to be a result of several problems (defects) with the genes that control heart muscle growth. Younger people are likely to have a more severe form of hypertrophic cardiomyopathy. However, the condition is seen in people of all ages.

Symptoms in HCM

- Chest pain
- Dizziness
- Fainting, especially during exercise
- Heart failure (in some patients)
- High blood pressure (hypertension)
- Light-headedness, especially with or after activity or exercise
- Sensation of feeling the heart beat (palpitations)
- Shortness of breath

Other symptoms that may occur are:

- Fatigue, reduced activity tolerance
- Shortness of breath when lying down

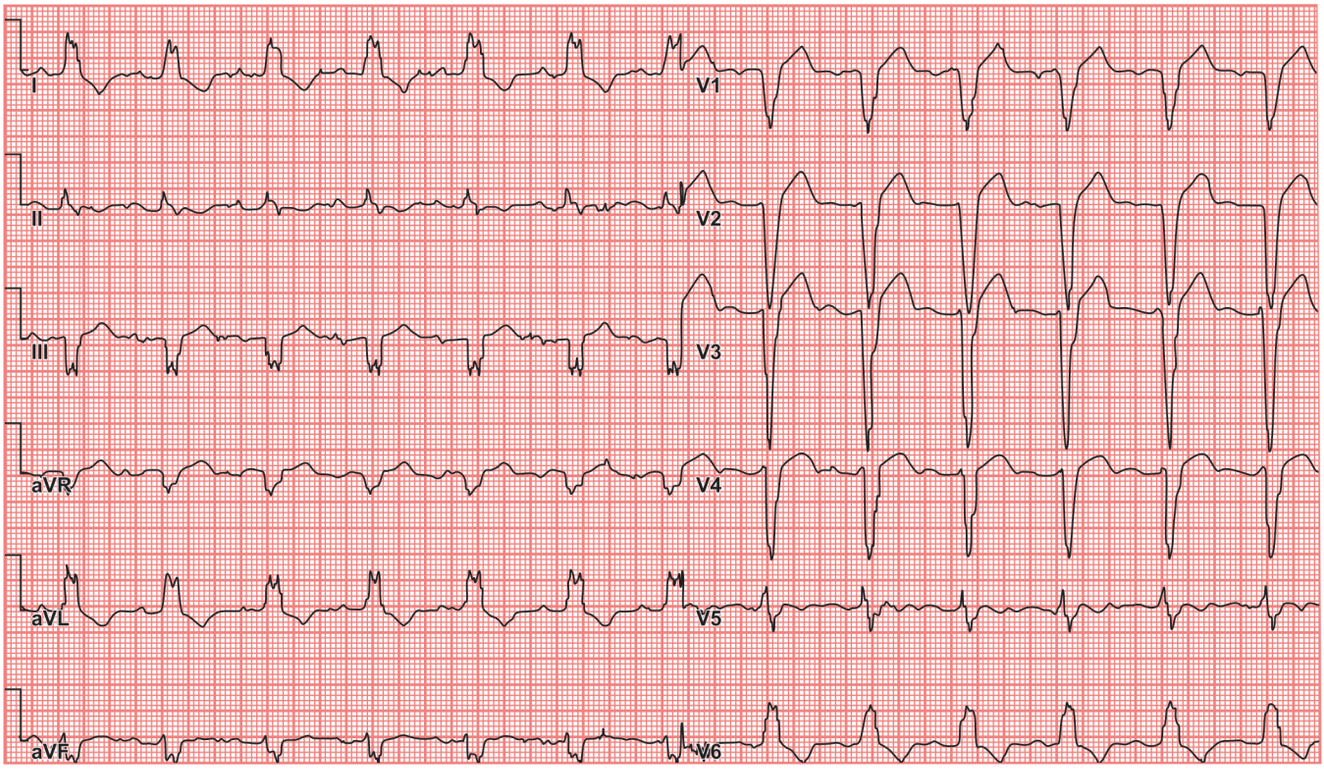

Fig. 15.11: LBBB in dialated cardiomyopathy

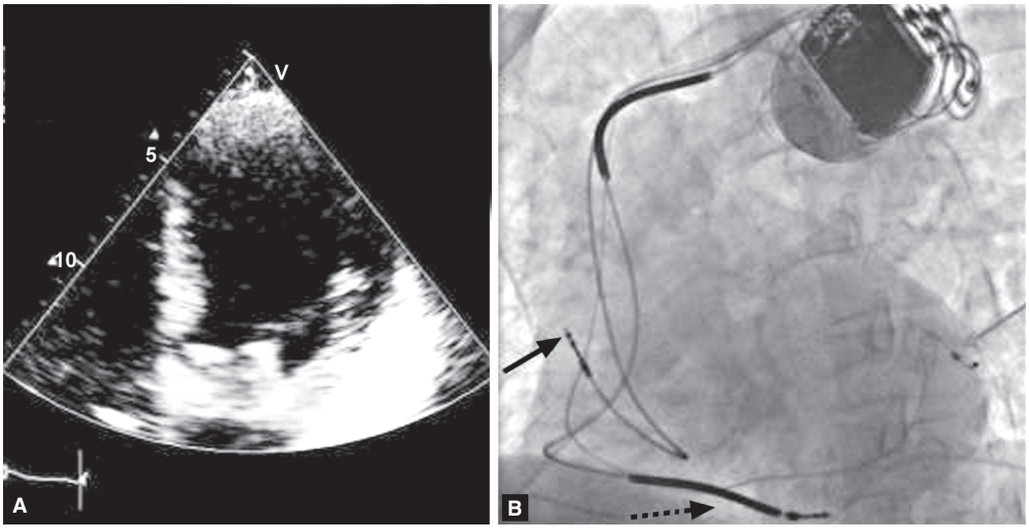

Fig. 15.12: (A) Echocardiography showing diastolic wall motion defect in cardiac failure. (B) CRT in dilated cardiomyopathy

Some patients have no symptoms. They may not even realize they have the condition until it is found during a routine medical exam.

The first symptom of hypertrophic cardiomyopathy among many young patients is sudden collapse and possible death. This is caused by very abnormal heart rhythms (arrhythmias), or from the blockage of blood leaving the heart to the rest of the body.

Hypertrophic cardiomyopathy is a major cause of death in young athletes who seem completely healthy but die during heavy exercise. However, certain normal changes in athletes' hearts can confuse the diagnosis.

Physical Examination

The health care provider will perform a physical exam and listen to the heart and lungs with a stethoscope. Listening with a stethoscope may reveal abnormal heart sounds or a murmur. These sounds may change with different body positions.

The pulse in your arms and neck will also be checked. The doctor may feel an abnormal heartbeat in the chest.

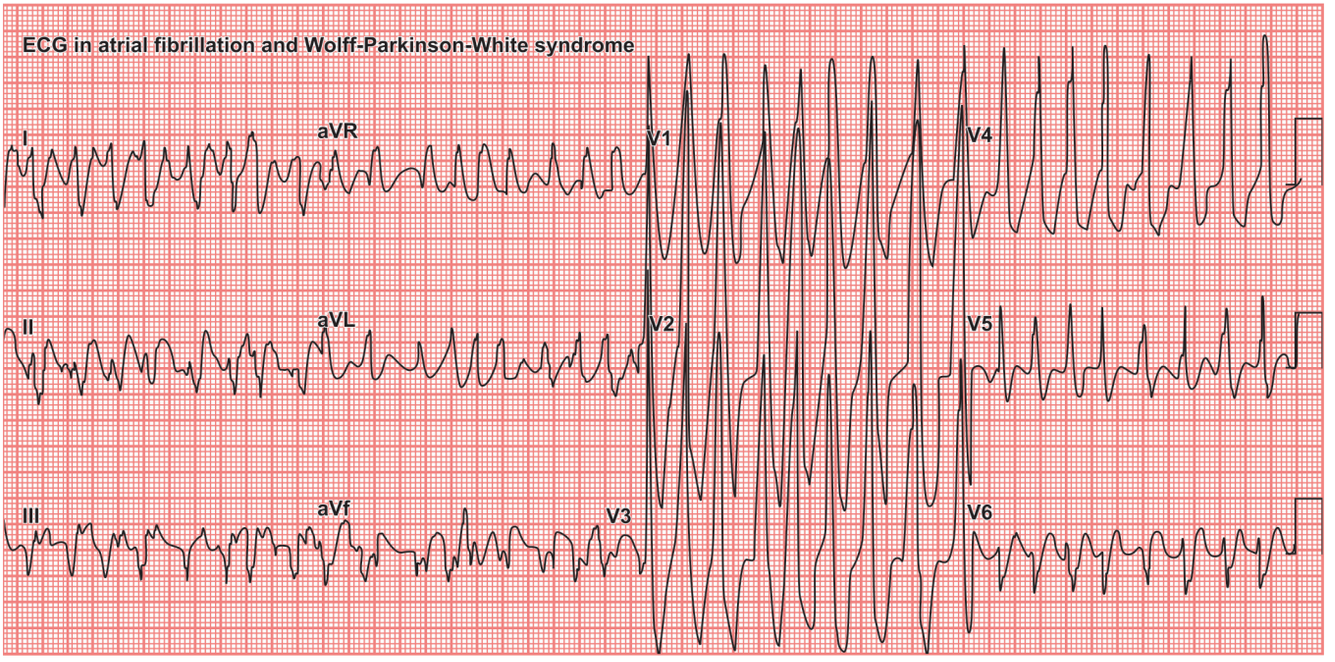

Fig. 15.13: This ECG shows preexcited atrial fibrillation. The shortest RR interval is 200 milliseconds; intervals <260 milliseconds are associated with a risk of sudden death in patient with DCM

Laboratory and Imaging Studies

Tests used to diagnose heart muscle thickness, problems with blood flow, or leaky heart valves (mitral valve regurgitation) may include:

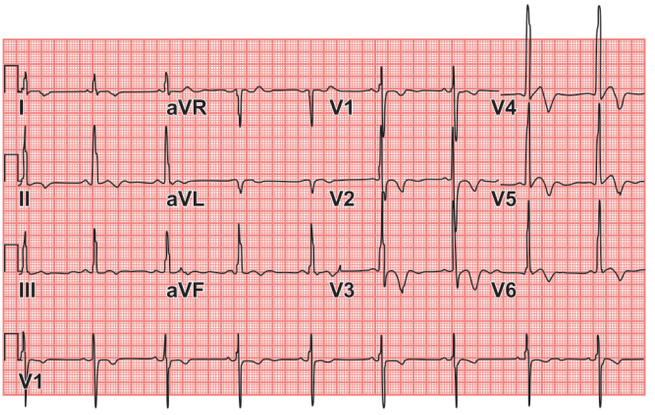

Fig. 15.14: ECG from a 53-year-old man with apical hypertrophic cardiomyopathy. Note elevated QRS voltages associated with left ventricular hypertrophy and inverted T-waves in all precordial leads

- ECG (Fig. 15.14)
- 24-hour Holter monitor (heart monitor) (Fig. 15.15)
- Echocardiography (the most common test) with Doppler ultrasound (Figs 15.16–15.19)

MRI/CT Scan (Fig. 15.20)

Cardiac catheterization (Figs 15.21 and 15.22)

Not all of these tests are useful for evaluating all of these conditions.

Blood tests may be done to rule out other possible diseases. If you are diagnosed with hypertrophic cardiomyopathy, your health care provider may recommend that your close blood relatives (family members) be screened for the condition.

Treatment in HCM

The goal of treatment is to control symptoms and prevent complications. Some patients may need to stay in the hospital until the condition is under control (stabilized).

If you have symptoms, you may need medication to help the heart contract and relax correctly. Some medications



Fig. 15.15: Nonsustained ventricular tachycardia in a patient with hypertrophic cardiomyopathy

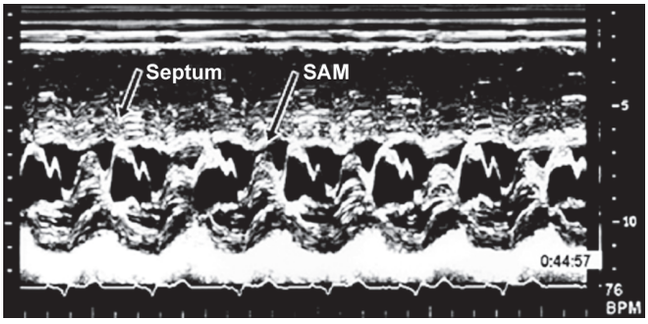

Fig. 15.16: M-mode echocardiogram in obstructive hypertrophic cardiomyopathy showing systolic anterior motion of the mitral valve (SAM) (arrows indicating septum and mitral valve leaflet contact)

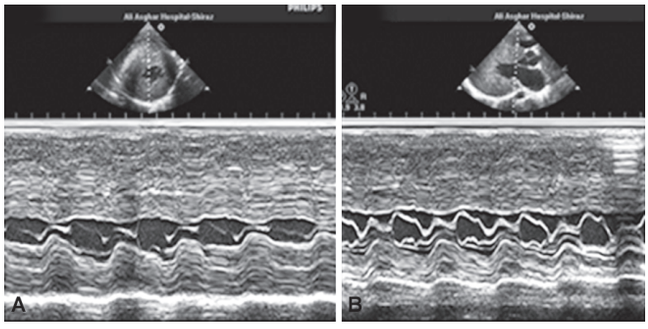

Fig. 15.17: M-mode echocardiography in parasternal window of a patient presented with recurrent episodes of syncope. (A) Short axis view of the left ventricle at the level of papillary muscle which shows severe hypertrophy of the left ventricle more prominently in the septum. (B) M-mode echocardiography of the mitral valve in long axis view demonstrates systolic anterior motion of the mitral valve leaflets

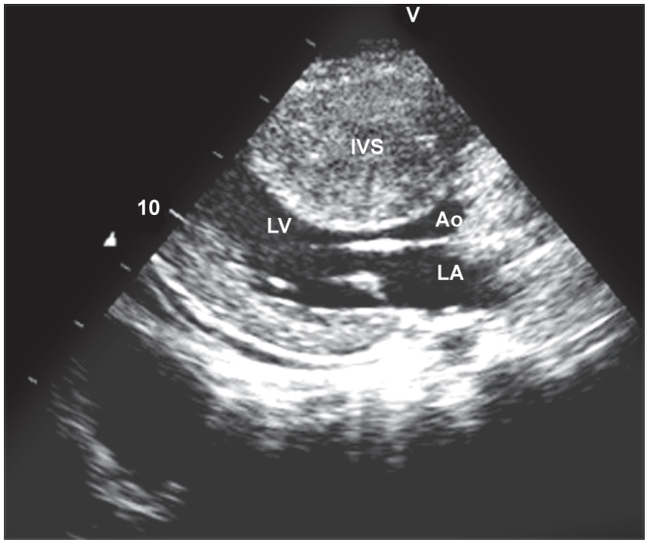

Fig. 15.19: Diffuse hypertrophy variant of hypertrophic cardiomyopathy (HCM). This pattern of hypertrophy is classically seen in younger patients. Ao, aorta; IVS, interventricular septum; LA, left atrium; LV, left ventricle

used include beta-blockers and calcium channel blockers, which may reduce chest pain and other symptoms, particularly with exercise. Medications will often relieve symptoms so patients do not need more invasive treatments.

Some people with arrhythmias may need anti-arrhythmic medications. If the arrhythmia is due to atrial fibrillation, blood thinners may also be used to reduce the risk of blood clots.

Some patients may have a permanent pacemaker placed. However, pacemakers are used less often today than they were in the past.

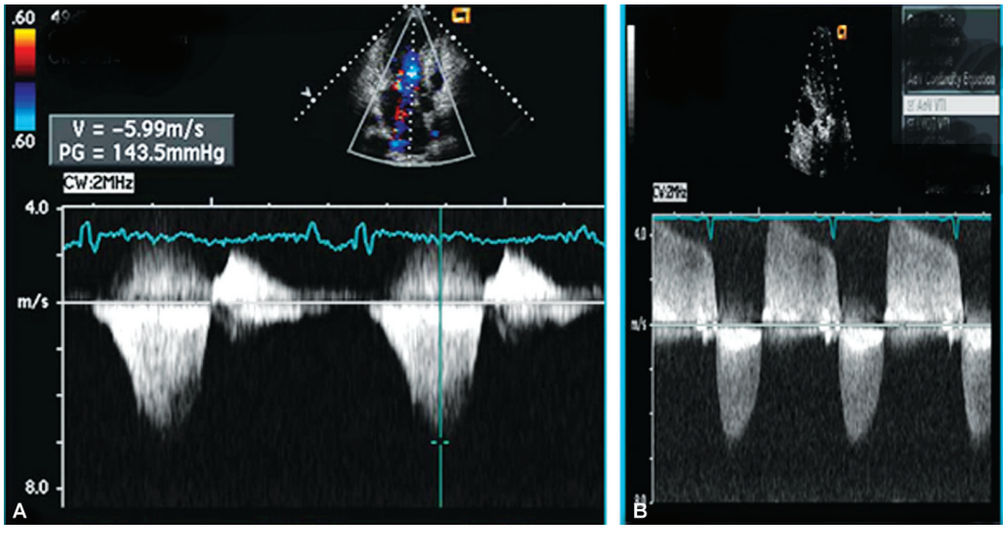

Fig. 15.18: Comparison of Doppler profiles of hypertrophic cardiomyopathy (HCM) (A), and aortic stenosis (B). Because aortic stenosis is a fixed obstruction, a contour of the aortic valve gradient can be seen. In contrast, the Doppler profile of HCM is seen as the classic dagger shape, reflecting the dynamic obstruction

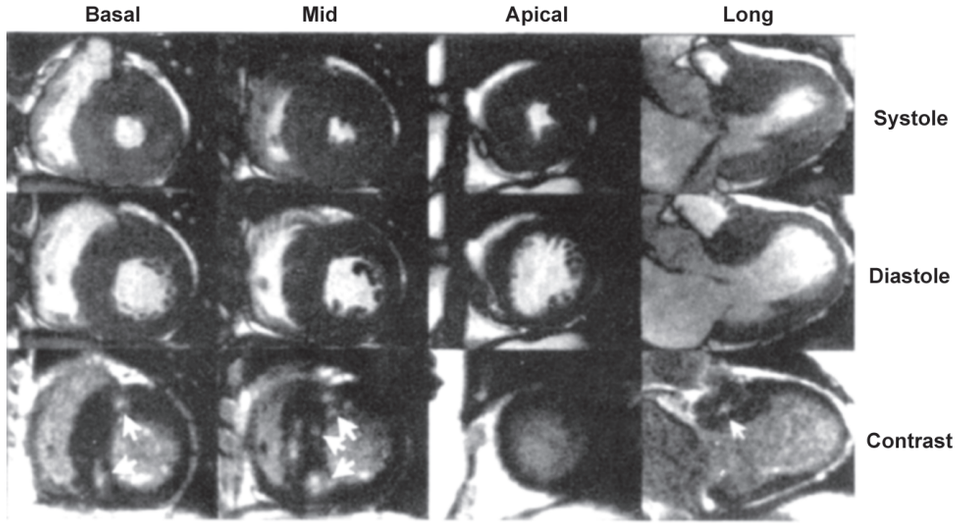

Fig. 15.20: Scans showing hypertrophy (maximum wall thickness, 27 mm) and scarring. There are multiple foci of scar tissue, which are located predominantly in the mid-myocardial region *(Mid)* and are not present in the lateral free wall. The long-axis *(Long)* cine images demonstrate systolic anterior motion of the mitral valve, systolic flow turbulence in the left ventricular outflow tract, and mitral regurgitation in patient with myocardial scarring in asymptomatic or mildly symptomatic hypertrophic cardiomyopathy

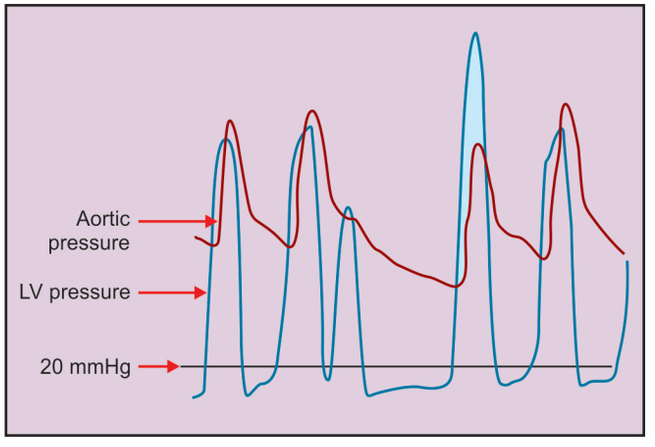

Fig. 15.21: Brockenbrough's response. The Brockenbrough's response in the postpremature ventricular contraction (PVC) is classic for hypertrophic cardiomyopathy (HCM). Post-PVC, there is increased preload secondary to a compensatory pause. The increased contractility associated with the post-PVC beat results in increased left ventricular outflow tract (LVOT) obstruction in HCM patients and a subsequent increase in the left ventricular-aortic gradient and decreased aortic pulse pressure during the post-PVC beat. In contrast, in subjects with no LVOT obstruction, a PVC results in increased cardiac contractility, but there is no left ventricle aortic gradient, either at rest or in the post-PVC beat. The aortic pulse pressure in the post-PVC beat usually increases because of the increased contractility. LV=left ventricular

When blood flow out of the heart is severely blocked, an operation called surgical myectomy may be done. This procedure cuts and removes a portion of the thickened part of the heart. Patients who have this procedure often show significant improvement. If the heart's mitral valve is leaking, surgery may be done to repair or replace the valve.

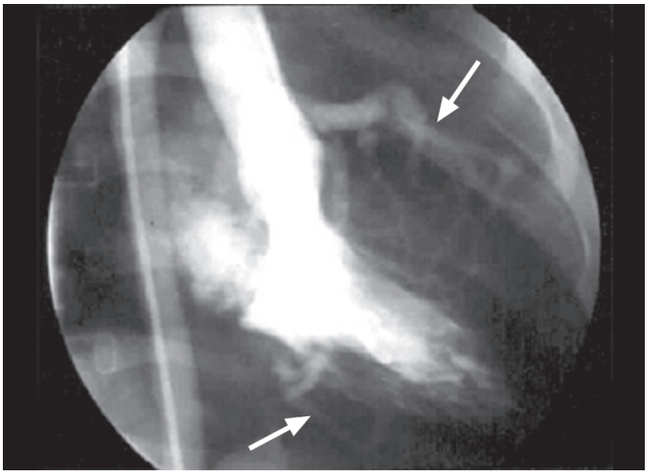

Fig. 15.22: Cardiomyopathy, hypertrophic. Conventional end-systolic right anterior oblique left ventriculogram acquired during the same cardiac catheterization study as in the previous image shows a small left-ventricular cavity with mild-mitral regurgitation (M). Note the increased distance between the ventricular cavity and the coronary arteries (arrows), which define the epicardial surface of the heart as the myocardium becomes thickened in systole

In some cases, patients may be given an injection of alcohol into the arteries that feed the thickened part of the heart (alcohol septal ablation), essentially causing a controlled heart attack (Figs 15.23–15. 25).

An implantable-cardioverter defibrillator (ICD) may be needed to prevent sudden death. ICDs are used in high-risk patients. High risks include (Fig. 15.26):

- Drop in blood pressure during exercise
- Family history of cardiac arrest
- History of cardiac arrest or ventricular tachycardia
- History of unexplained fainting

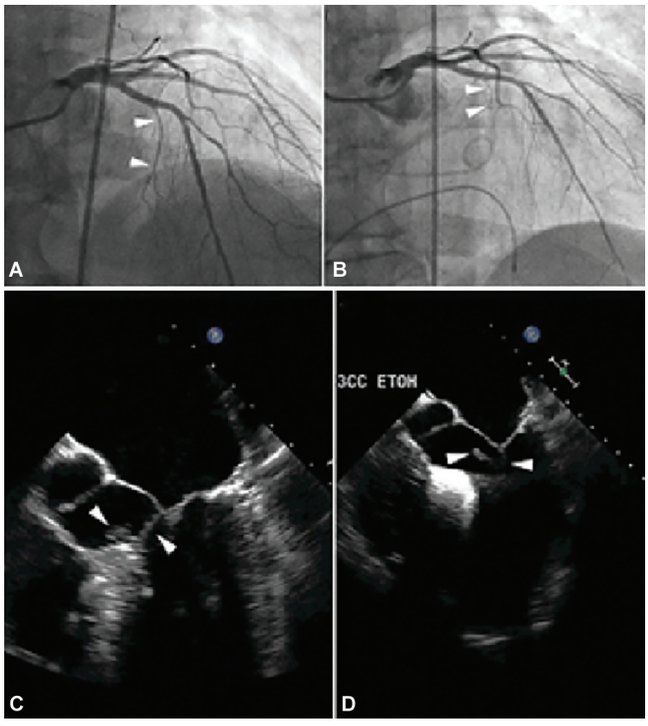

Fig.15.23: (A) Pre-alcohol septal ablation left coronary angiography highlighting the first septal perforator (arrowheads), (B) post-alcohol septal ablation left coronary angiography demonstrating subtotal occlusion of the first septal perforator (arrowheads). Echo scan shows change in systolic anterior motion of the accessory mitral valve tissue (arrowheads) following alcohol septal ablation, (C) pre-alcohol septal ablation; (D) post-alcohol septal ablation

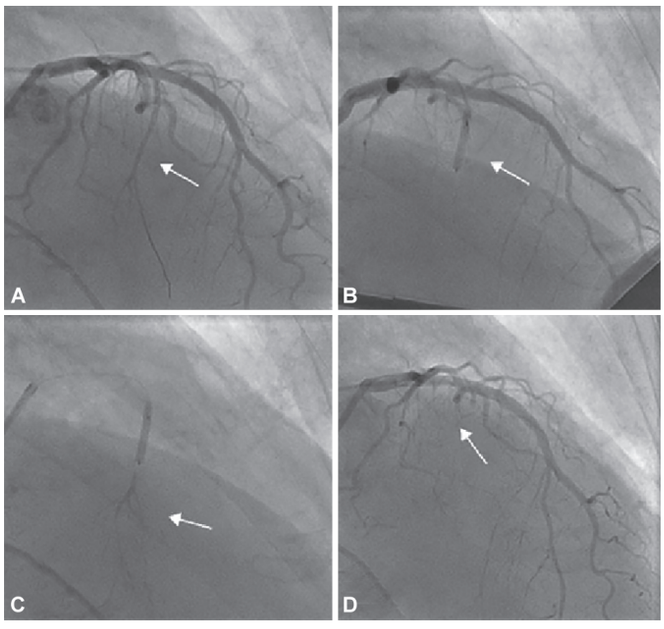

Fig. 15.24: Angiographic demonstration of alcohol septal ablation technique. Left coronary angiography shows the target septal branch (arrow); an angioplasty guidewire is already inserted inside the septal branch (A); optimal positioning of the balloon catheter (arrow) in the proximal part of the septal artery without compromise of the left anterior descending artery (B); injection of angiographic contrast dye through the central lumen of the inflated balloon catheter (arrow) determines the supply area of the septal branch and excludes leakage into the left anterior descending artery or other coronary vessels (C); final demonstration of the septal artery stump (arrow) after alcohol-induced occlusion (D)

- Life-threatening heart rhythms on a Holter monitor
- Severe heart muscle thickness

Prognosis In HCM

Some people with hypertrophic cardiomyopathy may not have symptoms and live a normal lifespan. Others may get worse gradually or rapidly. The condition may develop into a dilated cardiomyopathy in some patients.

People with hypertrophic cardiomyopathy are at higher risk for sudden death than the normal population. Sudden death can occur at a young age.

Hypertrophic cardiomyopathy is a well-known cause of sudden death in athletes. Almost half of deaths in hypertrophic cardiomyopathy happen during or just after the patient has done some type of physical activity.

If you have hypertrophic cardiomyopathy, always follow your doctor's advice concerning exercise and medical appointments. Patients are sometimes advised to avoid strenuous exercise.

Possible Complications in HCM

- Dilated cardiomyopathy
- Heart failure
- Life-threatening heart rhythm problems (arrhythmias)
- Severe injury from fainting

When to Contact a Medical Professional

Call for an appointment with your health care provider if:

- You have any symptoms of hypertrophic cardiomyopathy
- You develop chest pain, palpitations, faintness, or other new or unexplained symptoms

Prevention in HCM

If you are diagnosed with hypertrophic cardiomyopathy, your health care provider may recommend that your close blood relatives (family members) be screened for the condition.

Some patients with mild forms of hypertrophic cardiomyopathy are only diagnosed by screening echocardiograms because of their known family history.

If you have high blood pressure, make sure you take your medication and follow your doctor's recommendations.

ISCHEMIC CARDIOMYOPATHY

Ischemic cardiomyopathy is a term used to describe patients whose heart can no longer pump enough blood to the rest of their body due to coronary artery disease.

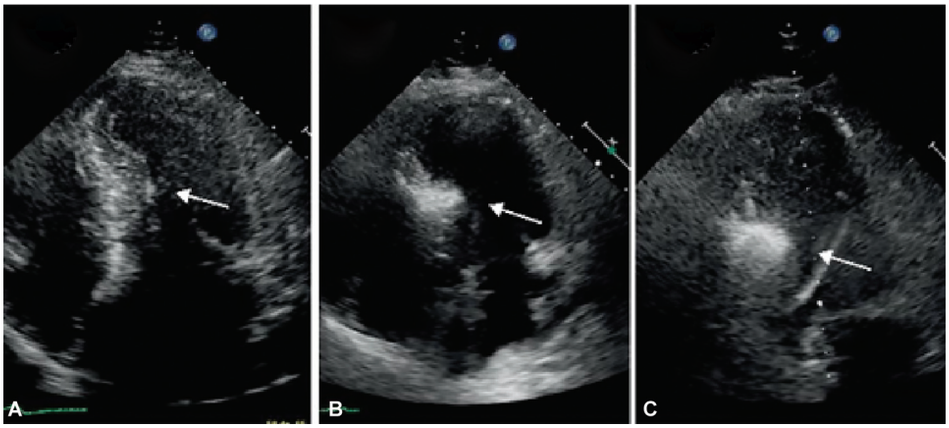

Fig.15.25: Myocardial contrast echocardiography during alcohol septal ablation. (A) First, the anatomy of the heart is presented and the target septal area is identified. (B) Injection of echocardiographic contrast into the target septal branch opacifies the basal part of the septum, verifying the optimal choice of septal branch. (C) A more sustained opacification of the basal septum after alcohol injection signifies a good alcohol depot

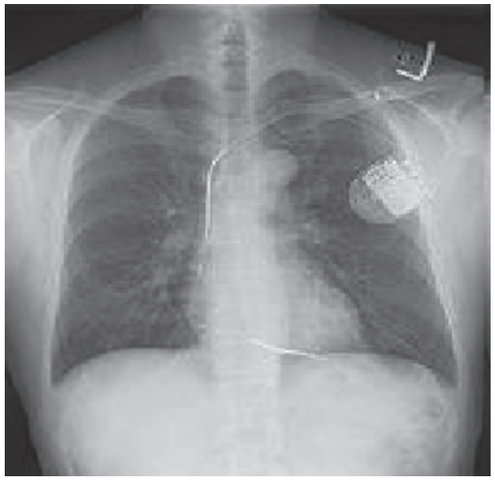

Fig. 15.26: Chest X-ray showing an implantable cardioverter-defibrillator in patient with hypertrophic obstructive cardiomyopathy

Coronary artery disease is a narrowing of the small blood vessels that supply blood and oxygen to the heart.

These patients often have heart failure.

Aetiological Factors

Ischemic cardiomyopathy is caused by coronary heart disease—the buildup of a hard substance called plaque in the arteries to the heart. This may also be called hardening of the arteries.

When the arteries that bring blood and oxygen to the heart are blocked or very narrowed, over time, the heart muscle does not work as well. It becomes harder for the heart to fill and pump blood to the body. Patients with this condition usually have a history of heart attacks or angina (chest pain).

Ischemic cardiomyopathy is a common cause of heart failure. It is the most common type of cardiomyopathy in the United States. It most often affects middle-aged and elderly people

Patients with this condition often have had symptoms of angina or a heart attack. Sometimes, patients do not notice any symptoms

Symptoms in ICM

Symptoms of heart failure usually develop slowly over time. Common symptoms include:

- Cough
- Fatigue, weakness, and faintness
- Irregular or fast pulse, or a sensation of feeling the heart beat (palpitations)
- Loss of appetite
- Shortness of breath, especially with activity
- Shortness of breath that occurs after lying down
- Swelling of feet and ankles (in adults)
- Swelling of the abdomen (in adults)
- Waking up from sleep after a couple of hours due to shortness of breath

Physical Exams and Lab Tests

The physical exam may be normal, or there may be signs that fluid is building up in the body:

- 'Crackles' in the lungs (heard with a stethoscope)
- Enlarged liver
- Extra heart sounds
- Leg swelling
- Raised pressure in the neck vein

There may be other signs of heart failure.

This condition is usually diagnosed if a test shows that the heart is not pumping as well as it should. This is called a decreased ejection fraction. A normal ejection fraction is around 55–65%. Many patients with this disorder have ejection fractions much less than this.

People with ischemic heart disease can have the symptoms and signs of ischemic cardiomyopathy even when their ejection fraction is normal or near normal. This is

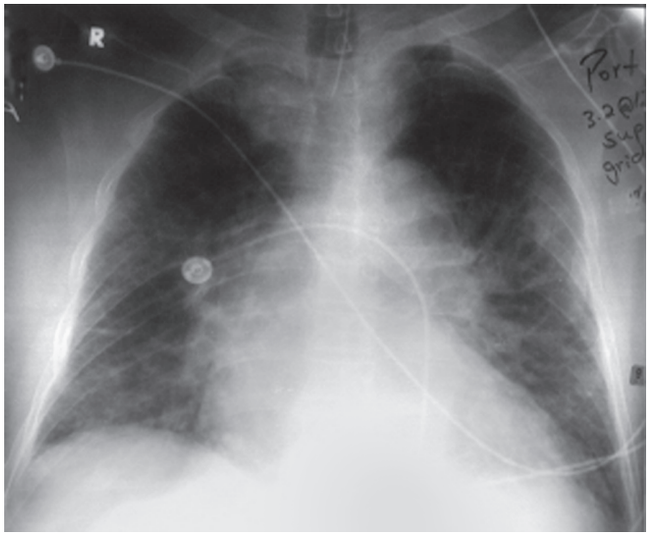

Fig. 15.27: Chest X-ray showing gross cardiomegaly with bilateral congestion due to congestive heart failure in ischemic cardiomyopathy

because the heart does not fully relax (impaired filling). It is sometimes called 'diastolic heart failure' or 'heart failure with preserved ejection fraction.'

Tests used to measure ejection fraction include:

- Chest X-ray (Fig. 15.27)
- Electrogardiogram (Figs 15.28 and 15.29)
- Echocardiogram (Fig. 15.30)
- Gated SPECT (Fig. 15.31)
- MRI of heart/CT angiography (Fig.15.32)
- Ventriculogram or cardiac blood pooling imaging (Fig. 15.33)

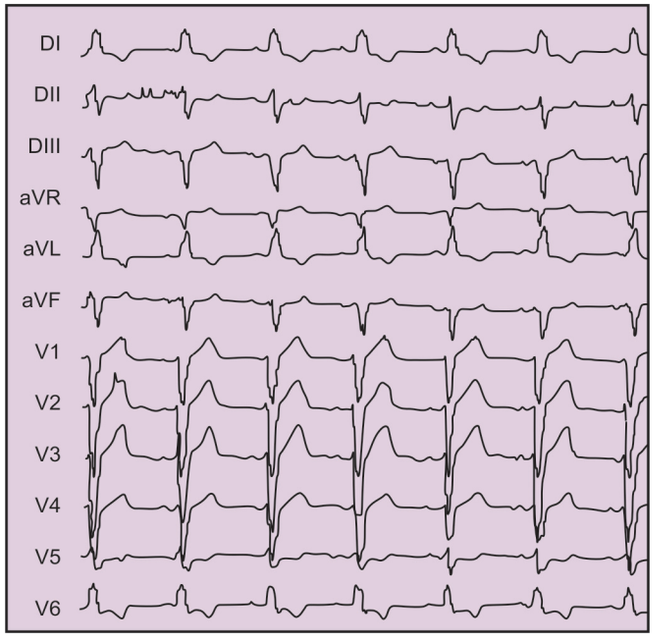

Fig. 15.29: Resynchronization therapy in a man of 57 years old with ischemic cardiomyopathy, ejection fraction 20%-NYHA Class III-optimal medical therapy-QRS 145 ms aspect of left bundle branch

Biopsy of the heart is needed in rare cases to rule out other conditions.

Treatment in ICM

To treat ischemic cardiomyopathy, your doctor will treat and manage your heart failure by

- Showing you how to make important changes in your lifestyle

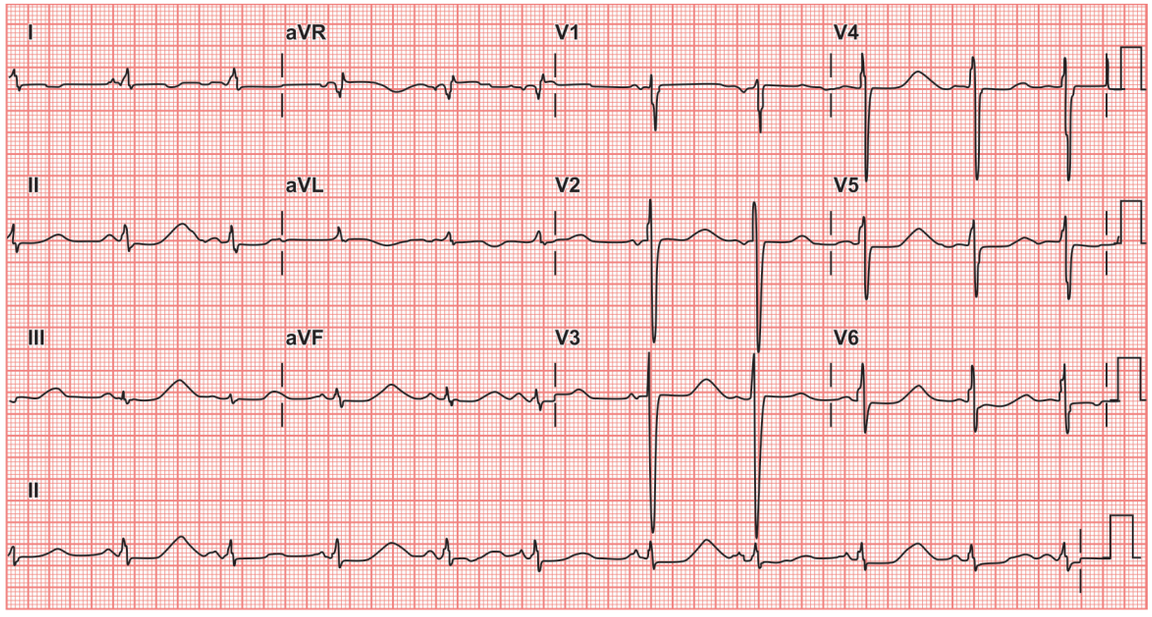

Fig.15.28: ECG morphology of a 83-year-old man with known ischemic cardiomyopathy with prolonged Qt interval, had an out-of-hospital cardiac arrest. He is rushed to the ED by paramedics

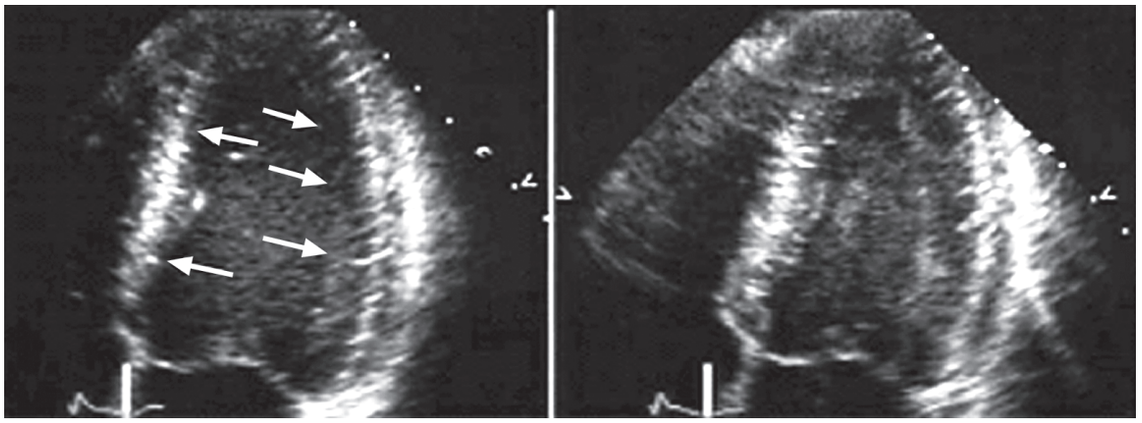

Fig. 15.30: Transthoracic two-dimensional echocardiogram (apical four chamber view, end systolic) at rest (left panel) and during infusion of low dose dobutamine (right panel) in a patient with ischemic cardiomyopathy and severe hypokinesia of the septum and lateral wall. During low dose dobutamine, improved contraction of the dysfunctional segments indicates myocardial viability

- Teaching you about the symptoms of heart failure
- Giving you medicines for heart failure
- Giving you a pacemaker to help treat a slow heart rate or help the heart beat in a more normal way
- Implanting a defibrilator, which recognizes abnormal heart rhythms and sends an electrical pulse to stop them.

A cardiac catheterization might be done to see if you need coronary artery bypass (CABG) surgery or a balloon procedure (angioplasty). These procedures can improve blood flow to the damaged or weakened heart muscle.

You may need a heart transplant if you have tried all the standard treatments and still have very severe symptoms. Implantable, artificial heart pumps are now available. However, very few patients are able to have these advanced treatments (Fig. 15.34).

Prognosis in ICM

Often, heart failure can be controlled with medicine, lifestyle changes, and by treating the disease that caused it.

Heart failure may suddenly become worse due to angina, heart attack, infections, other illnesses, eating foods that high in salt, and not taking medicines correctly.

Heart failure is usually a long-term (chronic) illness. It may get worse over time.

Some people develop severe heart failure. Medicines, surgery, and other treatments no longer help. They are at risk for dangerous heart rhythm problems.

When to Contact a Medical Professional

- You have symptoms of ischemic cardiomyopathy

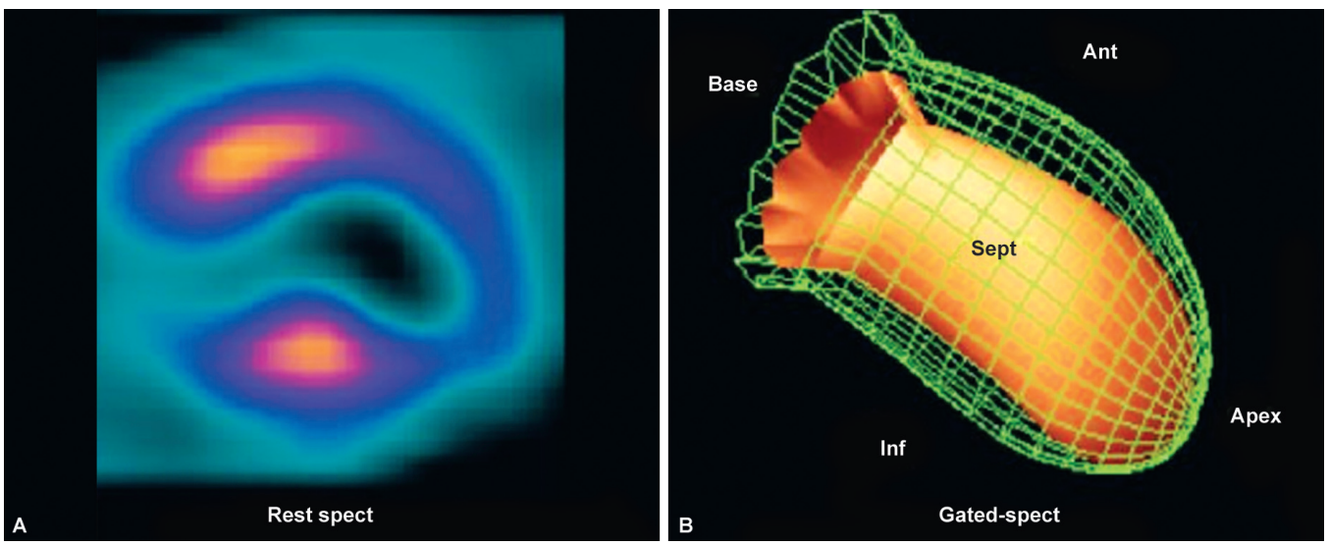

Fig. 15.31: Ischemic cardiomyopathy. (A) Divergent left ventricular pattern (transversal diameter at the apical level > transversal diameter at the basal level in vertical long-axis view) and absence of anteroapical uptake in myocardial perfusion SPECT at rest in a patient with anterior infarction. These criteria are highly specific for myocardial nonviability. (B) Gated-SPECT of the same patient in whom anterior akinesia and septal and apical dyskinesia can be observed. End-diastolic volume, 248 ml; end-systolic volume, 203 ml; ejection fraction, 18%. Ant=anterior; Inf=inferior; SPECT=single-photon emission computed tomography

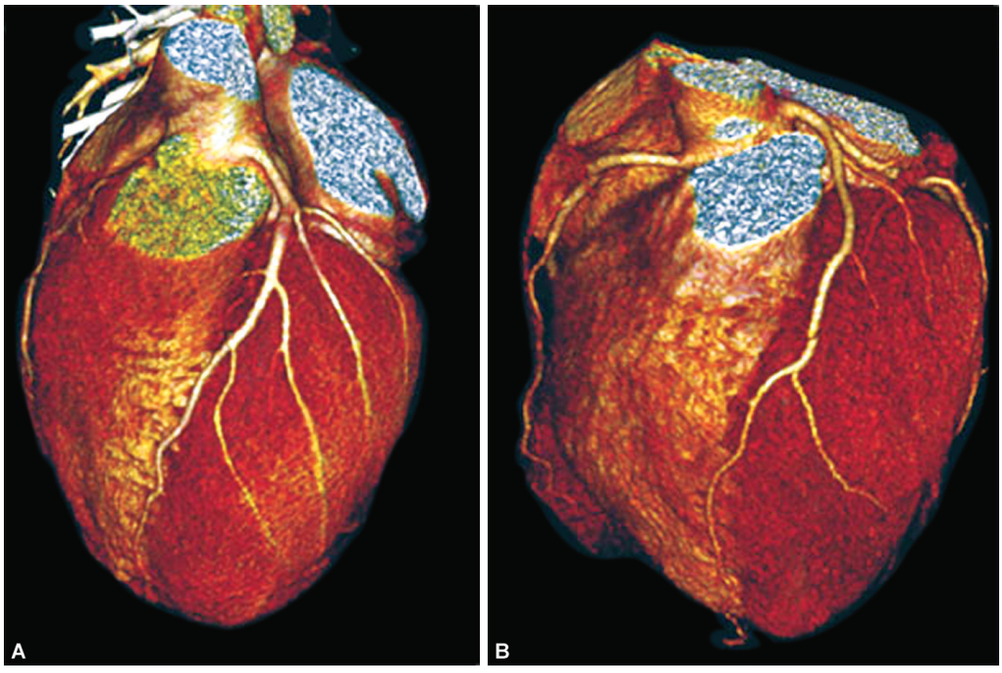

Fig. 15.32: Multislice CT reconstructions of (A) control heart and (B) a heart affected by IDCM, showing marked epicardial coronary artery mismatch for left ventricular mass and side-branch reduction. IDCM=idiopathic dilated cardiomyopathy

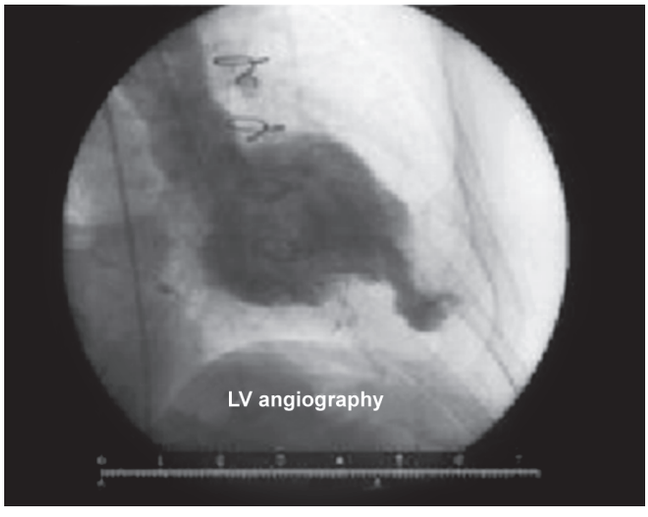

Fig. 15.33: LV angiography showing apical left ventricular dyskinesis (ventricular aneurysm) after an anterior myocardial infarction

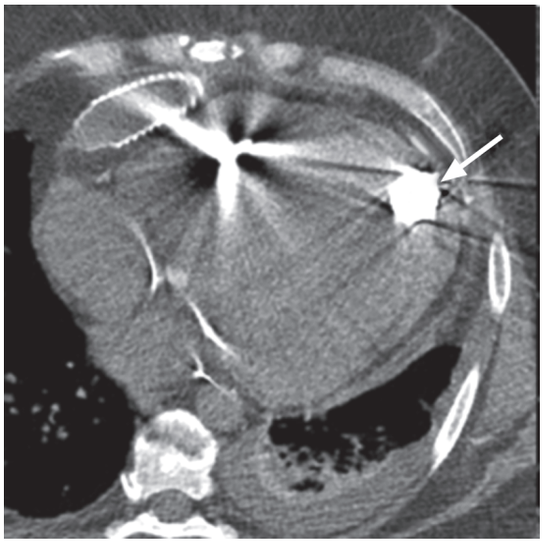

Fig. 15.34: 67-year-old man with HeartMate II (Thoratec) that was implanted for ischemic cardiomyopathy and ejection fraction of 10%

- You have chest pain that is not relieved by rest or nitroglycerin
- You pass out (syncope)

Prevention in ICM

Some of the risks for heart disease that you CAN change are:

- Do not smoke or use tobacco.
- Get plenty of exercise—at least 30 minutes a day, at least 5 days a week (talk to your doctor first)
- Stay at a healthy weight. Try for a body mass index (BMI) of between 18.5 and 24.9.
- Get checked and treated for depression.
- Women at high risk for heart disease should take omega-3 fatty acid supplements.

If you drink alcohol, limit yourself to no more than one drink a day for women, and no more than two drinks a day for men. Because alcohol in large amounts can be toxic to the heart, you may be asked to limit your alcohol even more, or stop drinking it completely.

Good nutrition is important for your heart health and will control some of your risk factors. See also heart disease and diet.

RESTRICTIVE CARDIOMYOPATHY

Restrictive cardiomyopathy (RCM) refers to a group of disorders in which the heart chambers are unable to properly fill with blood because of stiffness in the heart.

Aetiological Factors

In restrictive cardiomyopathy, the heart is of normal size or only slightly enlarged. However, it cannot relax normally during the time between heartbeats when the blood returns from the body to the heart (diastole).

Later in the disease, the heart may not pump blood efficiently. The abnormal heart function can affect the lungs, liver, and other body systems. Restrictive cardiomyopathy may affect either or both ventricles. It may be associated with a disease of the heart muscle.

The most common causes of restrictive cardiomyopathy are amyloidosis and scarring of the heart from an unknown cause (idiopathic myocardial fibrosis). It frequently occurs after a heart transplant.

Other causes of restrictive cardiomyopathy include:

- Carcinoid heart disease
- Diseases of the heart lining (endocardium), such as endomyocardial fibrosis and Loeffler's syndrome (rare)
- Iron overload (hemochromatosis)
- Radiation fibrosis
- Sarcoidosis
- Scleroderma
- Tumors of the heart

Symptoms in RCM

Symptoms of heart failure are most common. Usually, these symptoms develop slowly over time. However, sometimes symptoms start very suddenly and are severe.

Common symptoms are:

- Cough
- Difficulty breathing
  - at night
  - especially with exertion
  - when lying flat
- Fatigue, poor exercise tolerance
- Irregular or rapid pulse
- Loss of appetite
- Swelling of the abdomen
- Swelling of the feet and ankles

Other symptoms may include:

- Chest pain
- Decreased alertness or concentration
- Failure to thrive (in children)
- Low urine production
- Need to urinate at night (in adults)
- Shock (low blood pressure)

Physical Examination and Laboratory Tests

An examination may show:

- Enlarged (distended) or bulging neck veins
- Enlarged liver
- Lung crackles and abnormal or distant heart sounds when listening to the chest with a stethoscope (auscultation)
- Fluid backup into the hands and feet
- Signs of heart failure

Children will have:

- Difficulty feeding
- Pale skin
- Poor growth
- Weak pulses in the legs and arms

Laboratory and Imaging studies in restrictive cardiomyopathy include:

- Chest X-ray (Fig. 15.35)
- ECG (electrocardiogram) (Fig. 15.36)
- Echocardiogram and Doppler study (Figs 15.37–15.42)
- Chest CT scan (Fig. 15.43)
- Cardiac catheterization and coronary angiography
- MRI of the heart (Fig. 15.44)

Nuclear Heart Scan (MUGA, RNV)

Occasionally, patients with dilated or restrictive cardiomyopathy may have a nuclear cardiac stress test to evaluate how well the heart muscle is being supplied with blood and how well the ventricles or chambers are working. This information is used to determine the best way to treat their symptoms.

Serum Iron Studies

The term iron overload cardiomyopathy describes the different forms of cardiac dysfunction secondary to myocardial iron deposition. Besides being a major cause of morbidity, IOC accounts for one-third of deaths in hereditary hemochromatosis, especially in young male patients; it is the leading cause of mortality in thalassemia

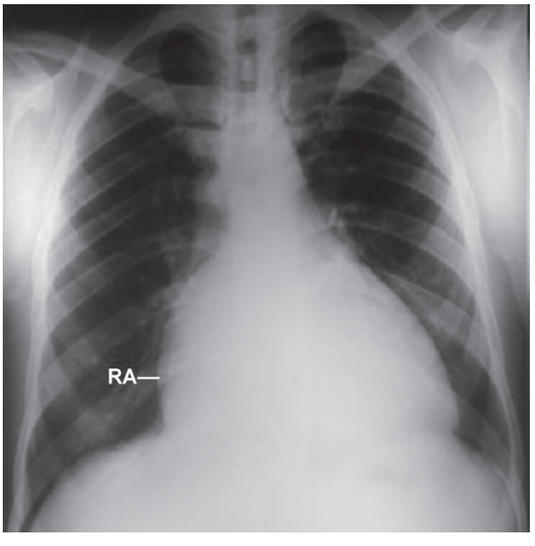

Fig. 15.35: X-ray chest PA view showing cardiomegaly with right atrial enlargement in restrictive cardiomyopathy

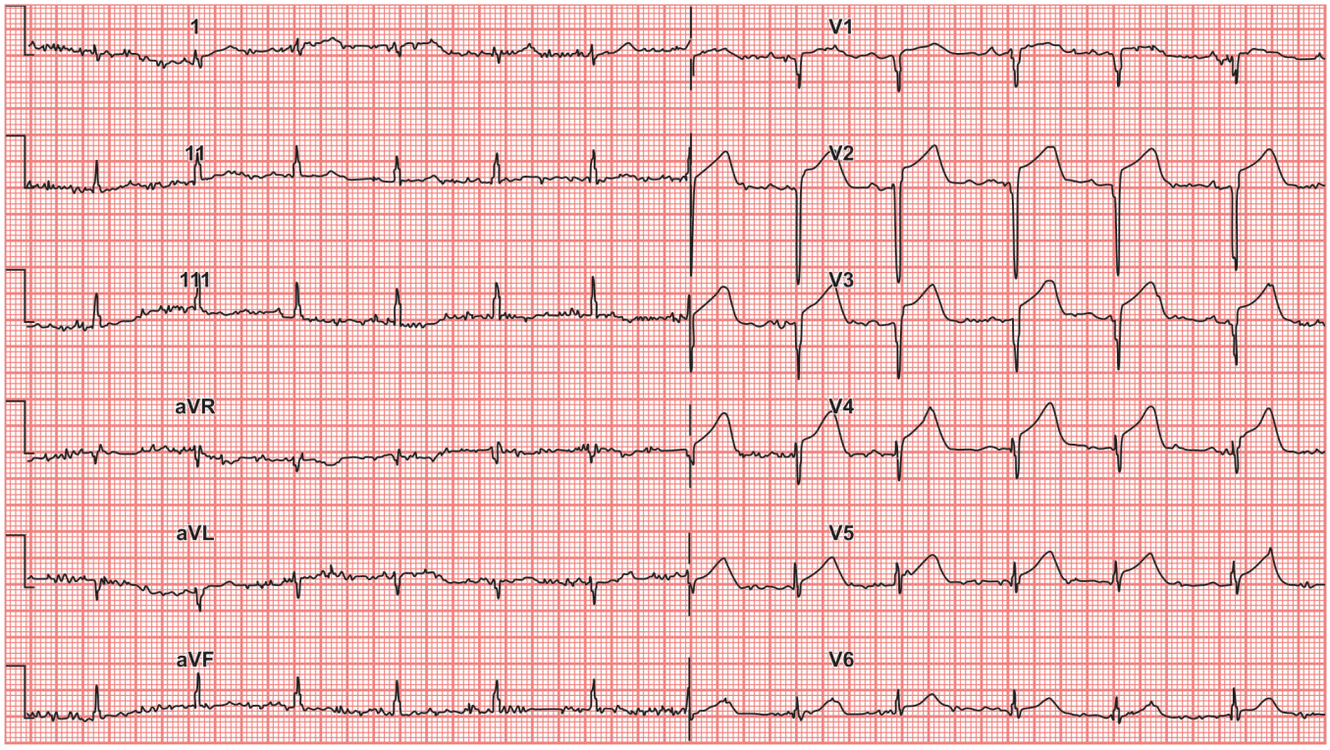

Fig. 15.36: Mixed constrictive-restrictive cardiomyopathy. ECG shows sinus rhythm (79/min) with absent progression of R-wave (V1–V4) and ST-elevation in precardial leads (V1–V6)

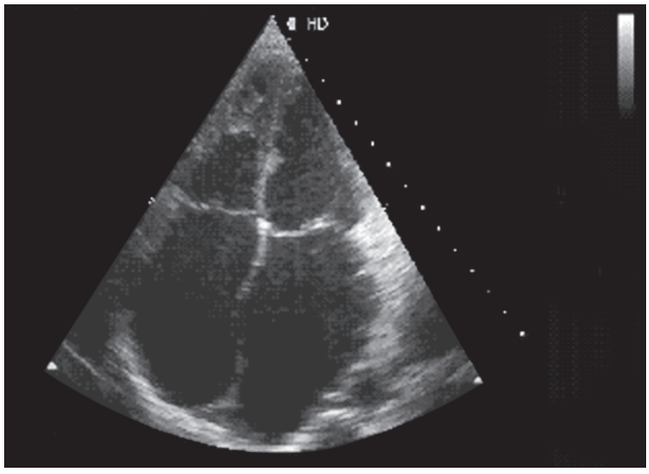

Fig. 15.37: A classical restrictive cardiomyopathy. Both atria balloon out as they face stiff resistance from the ventricles

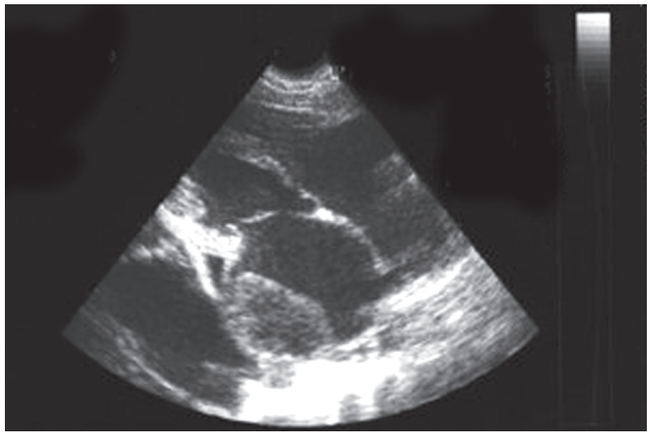

Fig. 15.38: Real-time ultrasound from a 5-year-old boy with restrictive cardiomyopathy showing pleural effusion and a thrombus in the left atrium

major; and it is also a major cause of death in other conditions associated with secondary iron overload.

Restrictive cardiomyopathy may be hard to tell apart from constrictive pericarditis. A biopsy of the heart muscle or cardiac catheterization may help confirm the diagnosis.

Treatment in RCM

When the cause of any cardiomyopathy can be found, that condition is treated.

Few treatments are known to be effective for restrictive cardiomyopathy. The main goal of treatment is to control symptoms and improve quality of life.

The following treatments may be used to control symptoms or prevent problems:

- Blood thinning medications, either aspirin or warfarin
- Chemotherapy (in some situations)
- Diuretics to remove fluid and help improve breathing
- Medications to prevent or control irregular or abnormal heart rhythms
- Steroids for specific causes

A heart transplant may be considered if the heart function is very poor and the patient has many symptoms.

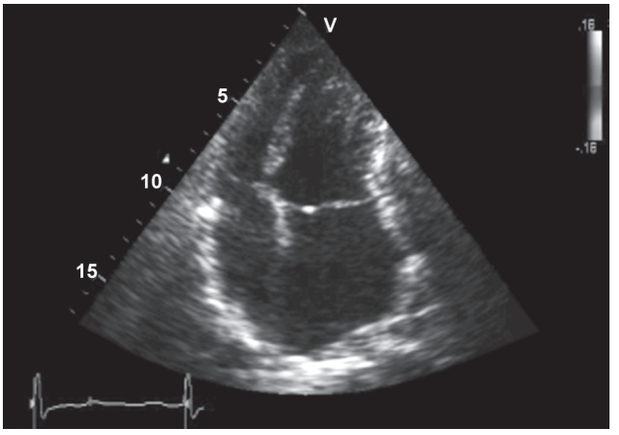

Fig. 15.39: Two-dimensional apical four-chamber image showing moderate to severe bi-atrial enlargement in a patient with restrictive cardiomyopathy

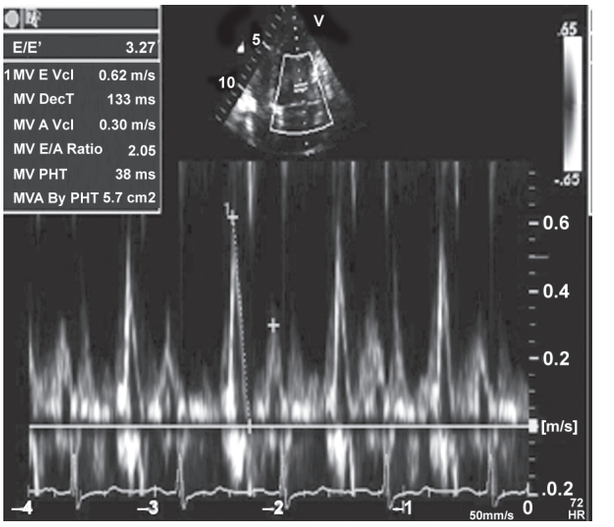

Fig. 15.40: Pulsed wave Doppler of transmitral flow; mitral valve E and A velocity measured 0.74 and 0.36 m/s, respectively. in restrictive cardiomyopathy

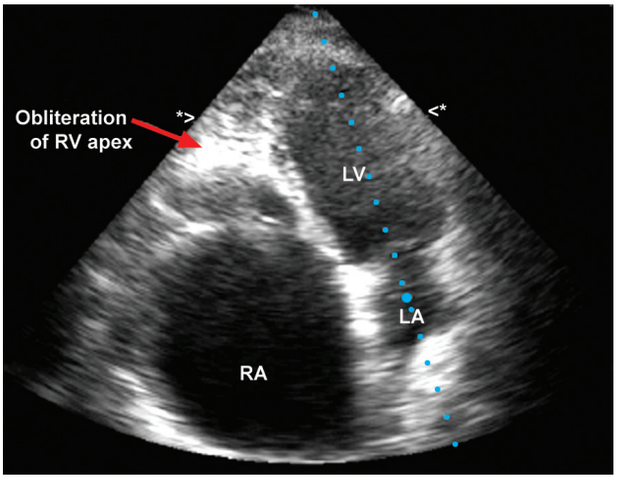

Fig. 15.42: Echocardiogram in right ventricular endomyocardial fibrosis

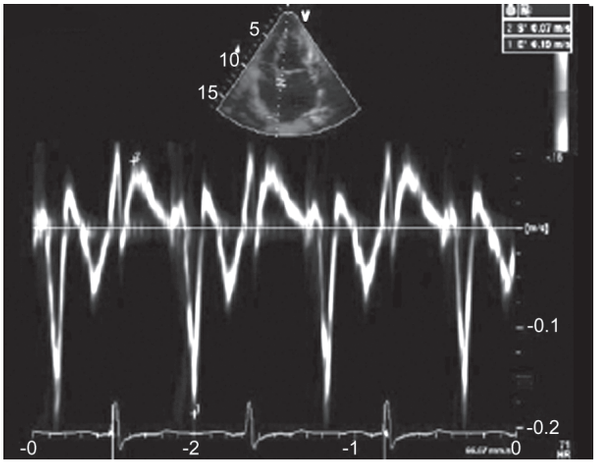

Fig. 15.41: Tissue Doppler imaging; E and S measured 19 and 7 cm/s, respectively, E/E ratio was 3 in case of a restrictive cardiomyopathy

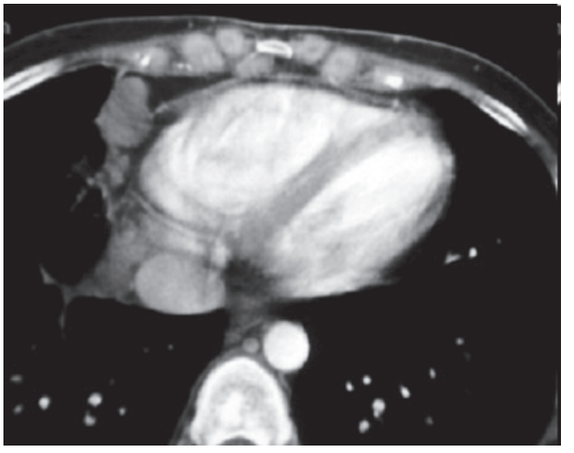

Fig. 15.43: Restrictive cardiomyopathy. Axial contrast-enhanced CT image through the heart (same patient as in previous image) shows a thin pericardium without calcification. Note the cardiophrenic and internal mammary lymph nodes. The patient had extensive mediastinal and hilar adenopathy, as well as interstitial lung changes

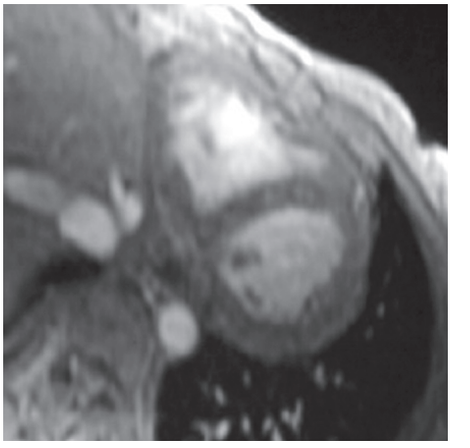

Fig. 15.44: Restrictive cardiomyopathy. Axial double inversion-recovery MRI of the heart in a 30-year-old woman with sarcoid demonstrates a normal pericardium

Prognosis in RCM

People with restrictive cardiomyopathy may be heart transplant candidates. The outlook depends on the cause of the condition, but it is usually poor. Average survival after diagnosis is 9 years.

Possible complications

- Arrhythmias
- Mitral regurgitation
- Progressive heart failure
- Tricuspid regurgitation

When to Contact a Medical Professional

Call your health care provider if you have symptoms of restrictive cardiomyopathy.

NONCOMPACTION CARDIOMYOPATHY

Noncompaction cardiomyopathy (NCC), also called spongiform cardiomyopathy, is a rare congenital cardiomyopathy that affects both children and adults. It results from the failure of myocardial development during embryogenesis.

During development, the majority of the heart muscle is a sponge-like meshwork of interwoven myocardial fibers. As normal development progresses, these trabeculated structures undergo significant compaction that transforms them from spongy to solid. This process is particularly apparent in the ventricles, and particularly so in the left ventricle. Noncompaction cardiomyopathy results when there is failure of this process of compaction. Because the consequence of noncompaction is particularly evident in the left ventricle, the condition is also called left ventricular noncompaction. Other hypotheses and models have been proposed, none of which is as widely accepted as the noncompaction model.

Symptoms can range however are often a result of a poor pumping performance by the heart. The disease can be associated with other problems with the heart and the body.

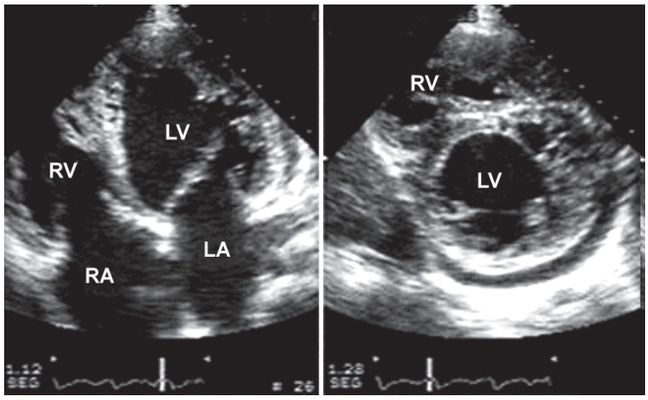

Fig. 15.45: Two-dimensional apical four chamber and parasternal short axis images at the level of the ventricles show dilatation of both ventricles, multiple trabeculae and intertrabecular recesses in inferior, lateral, anterior walls, middle and apical portions of the septum and apex of the left ventricle in a case with noncompacted cardiomyopathy

Diagnosis

Trabeculation of the ventricles is normal, as are prominent, discrete muscular bundles greater than 2 mm. In noncompaction there is excessively prominent trabeculations. Chin et al. described echocardiographic method to distinguish noncompaction for normal trabeculation. They described a ratio of the distance from the trough and peak, of the trabeculations, to the epicardial surface. Noncompaction is diagnosed when the trabeculations are more than twice the thickness of the underlying ventricular wall.

Imaging Studies

- Echocardiography (Figs 15.45–15.50)
- MRI (Fig. 15.51)

Genetics

The American Heart Association's 2006 classification of cardiomyopathies considers noncompaction cardiomyopathy a genetic cardiomyopathy. Mutations in LDB3 (also known as 'Cypher/ZASP') have been described in patients with the condition. There is recent information in which

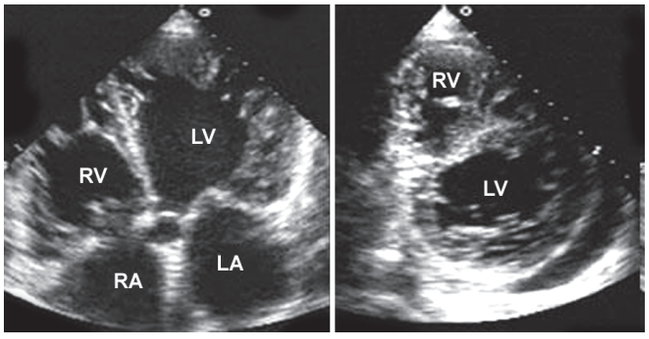

Fig. 15.46: Transthoracic two-dimensional echocardiogram in apical four chamber and parasternal short axis at the level of both ventricles demonstrate dilatation, deep trabeculae and intertrabecular recesses in the inferior, lateral, anterior walls, middle and apical portions of the septum and apex of the left ventricle in a case with noncompacted cardiomyopathy

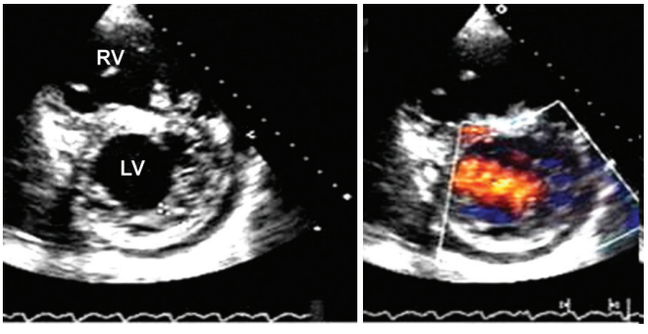

Fig. 15.47: Two-dimensional parasternal and color-Doppler images at the level of both ventricles that show the noncompacted-compacted wall ratio and how the color enters the intertrabecular recesses in a case with noncompacted cardiomyopathy

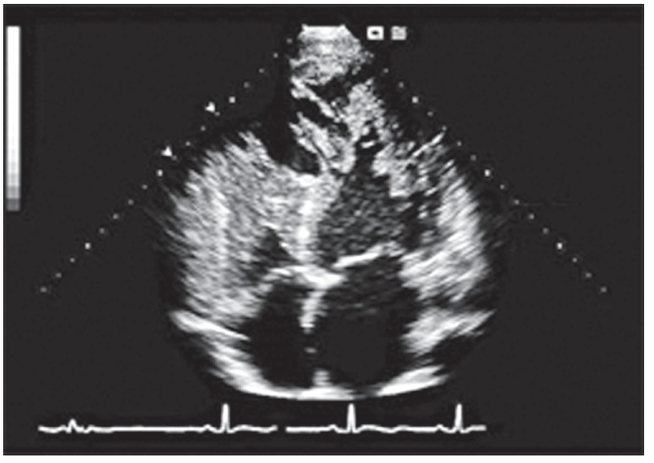

Fig. 15.48: Apical four chamber view on transthoracic echocardiogram (apex up) revealing a left ventricle with a thick spongy endocardial surface that is severely trabeculated at the apex characteristic of left ventricular noncompaction

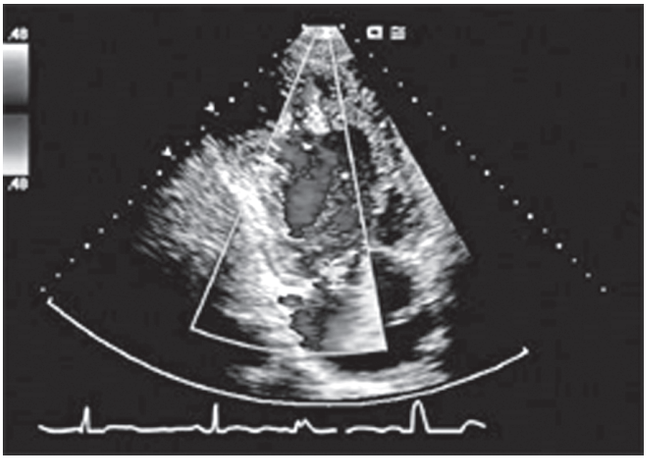

Fig. 15.50: Apical two chamber view on transthoracic echocardiogram (apex up) with low-scale color-Doppler showing multiple large recesses in the left ventricular apex being perfused from the left ventricular cavity

NCC has been seen in combination with 1q21.1 deletion syndrome.

Symptoms in NCC

Subjects' symptoms from noncompaction cardiomyopathy range widely. It is possible to be diagnosed with the condition, yet not to suffer from any of the symptoms associated with heart disease. Likewise it possible to suffer from severe heart failure, which even though the condition is present from birth, may only manifest itself later in life. Differences in symptoms between adults and children are also prevalent with adults more likely to suffer from heart failure and children from depression of systolic function.

Common symptoms associated with a reduced pumping performance of the heart include:

- Breathlessness
- Fatigue
- Swelling of the ankles
- Limited physical capacity and exercise intolerance

Two conditions though that are more prevalent in noncompaction cardiomyopathy are: tachyarrhythmia which can lead to sudden cardiac death and clotting of the blood in the heart.

Complications

The presence of NCC can also lead to other complications around the heart and elsewhere in the body. These are not necessarily common complications and no paper has yet commented on how frequently these complications occur with NCC as well.

- Cardiac

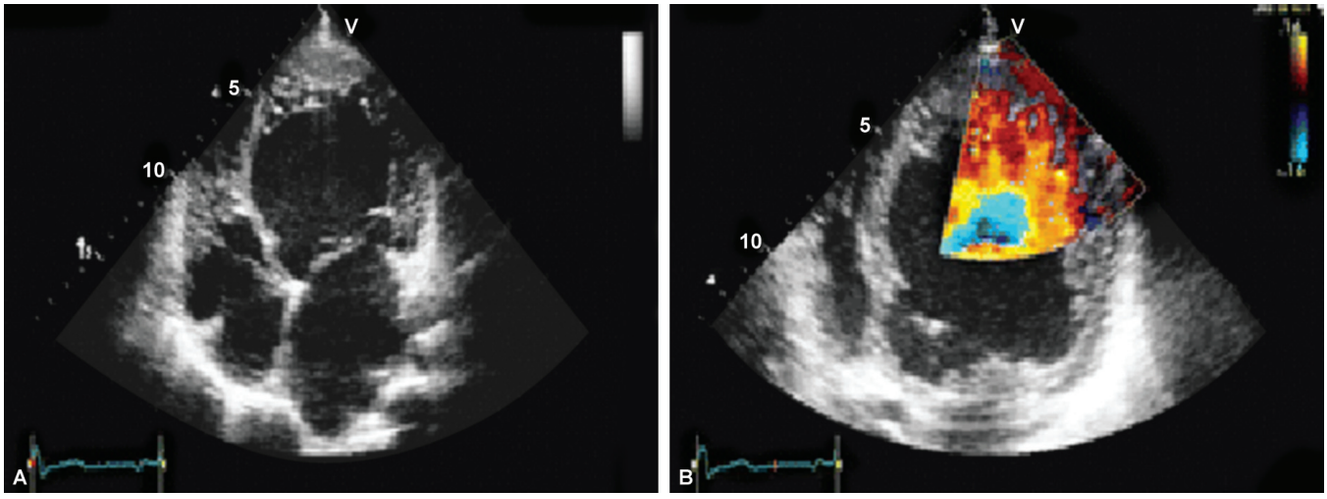

Fig. 15.49: Left ventricular noncompaction. (A) There is marked LV dilatation and dysfunction, thinning of the septum and hypertrophy, excessive trabeculation of the lateral wall and apex. (B) Color flow mapping shows flow within deep recesses, extending to the epicardium at the apex

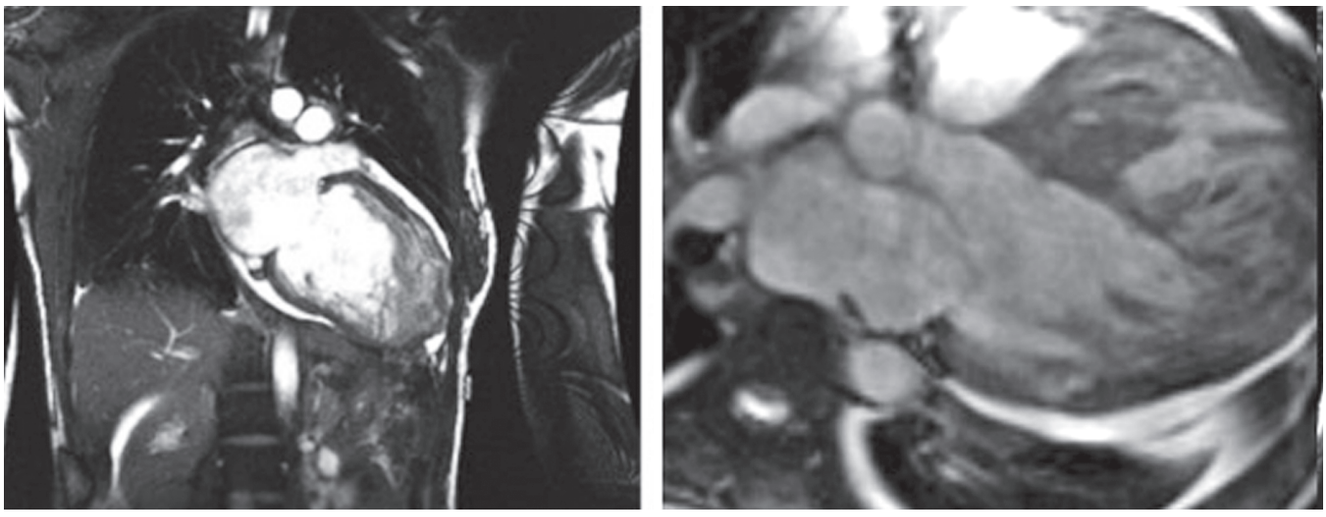

Fig. 15.51: Images from cardiac MRI showing a markedly dilated left ventricle and left atrium. The left ventricle shows prominent trabeculation particularly along the apex. A small pericardial effusion and a small pleural effusion are also noted in a case with non-compacted cardiomyopathy

- Abnormalities of the origin of the left coronary artery
- Pulmonary atresia
- Stenosis
- Right or left ventricle obstruction
- Hypoplastic left ventricle
- Mitral regurgitation

- Neuromuscular (pertaining to both nerves and muscles)
  - Becker's muscular dystrophy
  - Mitochondrial myopathy
  - Polyneuropathy and metabolic myopathy
- Genetic related
  - Emery-dreifuss muscular dystrophy
  - Myotubular cardiomyopathy
  - Barth syndrome

Prognosis in NCC

Due to noncompaction cardiomyopathy being a relatively new disease, its impact on human life expectancy is not very well understood. In a 2005 study which documented the long term follow up of 34 patients with NCC, 35% had died at the age of 42 +/– 40 months with a further 12% having to undergo a heart transplant due to heart failure. However, this study was based upon symptomatic patients referred to a tertiary care center, and so were suffering from more severe forms of NCC than might be found typically in the population. As NCC is a genetic disease, immediate family members are being tested as a precaution which is turning up more supposedly healthy people with NCC who are asymptomatic. The long term prognosis for these people is currently unknown.

Management in NCC

These are similar to management programs for other types of cardiomyopathies which include the use of ACE inhibitors, beta-blockers and aspirin therapy to relieve the pressure on the heart, surgical options such as the installation of pacemaker is also an option for those thought to be at a high risk of arrhythmia problems.

In severe cases, where NCC has led to heart failure, with resulting surgical treatment including a heart valve operation, or a heart transplant.

ARRHYTHMOGENIC RIGHT VENTRICULAR CARDIOMYOPATHY

Arrhythmogenic right ventricular cardiomyopathy (ARVC) is a primary disease of heart muscle that results in fibrofatty replacement of the right ventricle and the subepicardial region of the left ventricle. Patients are at high risk for ventricular tachyarrhythmias and sudden death (see the image below).

Arrhythmogenic right ventricular cardiomyopathy, biventricular, autopsy heart in a young man who died suddenly playing basketball. Top left demonstrates increased fat in the outer walls of the right ventricle and left ventricular posterolateral walls. A higher magnification of the right ventricle is seen at the top right image; the anterior wall is nearly completely replaced with fat, and fibrofatty irregular posterior wall involvement is seen. Note that no actual thinning of the wall itself exists, although the muscular portion is in some areas completely missing. The bottom left image demonstrates a full thickness of the right ventricle stained with Masson trichrome. The residual muscle is present only in a band like area of scarring, and subepicardial scarring is present as well. The characteristic myocyte vacuolization, depicted in the bottom right image, is seen in nearly all areas of ARVC within the scarred areas.

Although ARVC was initially described in the right ventricle, examination of the heart in autopsy cases of ARVC, microscopically or with sensitive imaging techniques, has established that most patients with ARVC have biventricular involvement.

The left ventricular involvement is typically subepicardial, and the changes are related more to fibrosis than to fat or fibrofatty infiltration, although at times the changes are probably similar to those seen in the right ventricle. However, because the right ventricle is relatively thin, the subepicardial nature of disease is difficult to appreciate in imaging studies and has only infrequently been investigated at autopsy. Atrial involvement appears not to have been adequately investigated.

Previously, investigators postulated that ARVC begins in the right ventricle and progresses to biventricular involvement and heart failure. However, newer imaging techniques have revealed that left ventricular involvement is typical from the onset.

Some patients with ARVC develop heart failure and intractable arrhythmias and are treated with heart transplantation. A subset of these patients carries the clinical diagnosis of idiopathic dilated cardiomyopathy. In such patients, the pathologic diagnosis of ARVC is made initially on finding fibrofatty replacement on histologic sections of the recipient's explanted heart.

Aetiological Factors

The aetiology of arrhythmogenic right ventricular cardiomyopathy is unknown. The presence of inflammatory infiltrates in most cases that have been seen at autopsy has led to the theory that it is a resolving myocarditis. Families have been described with phenotypic alterations ranging from myocarditis to fibrofatty cardiac infiltrates, and imaging studies have demonstrated a progression from myocarditis to ARVC.

Family studies have suggested that ARVC is caused by genetic alterations in desmosomal proteins, especially plakoglobin and desmoplakin. One family study demonstrated desmosomal mutations in just fewer than 20% of patients. ARVC is possibly an inflammatory process that is modulated by genetic influences in desmosome-related proteins.

Prognosis in ARVC

Because autopsy studies are skewed toward fatal arrhythmogenic right ventricular cardiomyopathy and by consent for autopsy, it has been assumed that ARVC is uniformly lethal. The clinical diagnosis has been hampered by the nonspecificity of electrocardiographic and imaging findings. However, with improvements in cardiac MRI and computed tomography scanning, the clinical diagnosis has become more precise.

Studies of families with ARVC have suggested that with antiarrhythmic treatment, including the implantation of defibrillators, the prognosis may be improved. Young age, a family history of juvenile sudden death, QRS dispersion greater than or equal to 40 ms, T-wave inversion, left ventricular involvement, ventricular tachycardia, syncope, and previous cardiac arrest are the major risk factors for adverse prognosis. Preparticipation screening for sport eligibility has been proven to be effective in detecting asymptomatic patients and sport disqualification has saved lives; sudden death in young athletes has substantially declined.

Diagnosis in ARVC

Laboratory and imaging studies
Electrocardiogram (Fig. 15.52 and 15.53)
Electrophysiological study (Fig. 15.54)

MRI Studies

The primary symptoms of arrhythmogenic right ventricular cardiomyopathy are related to arrhythmias and conduction

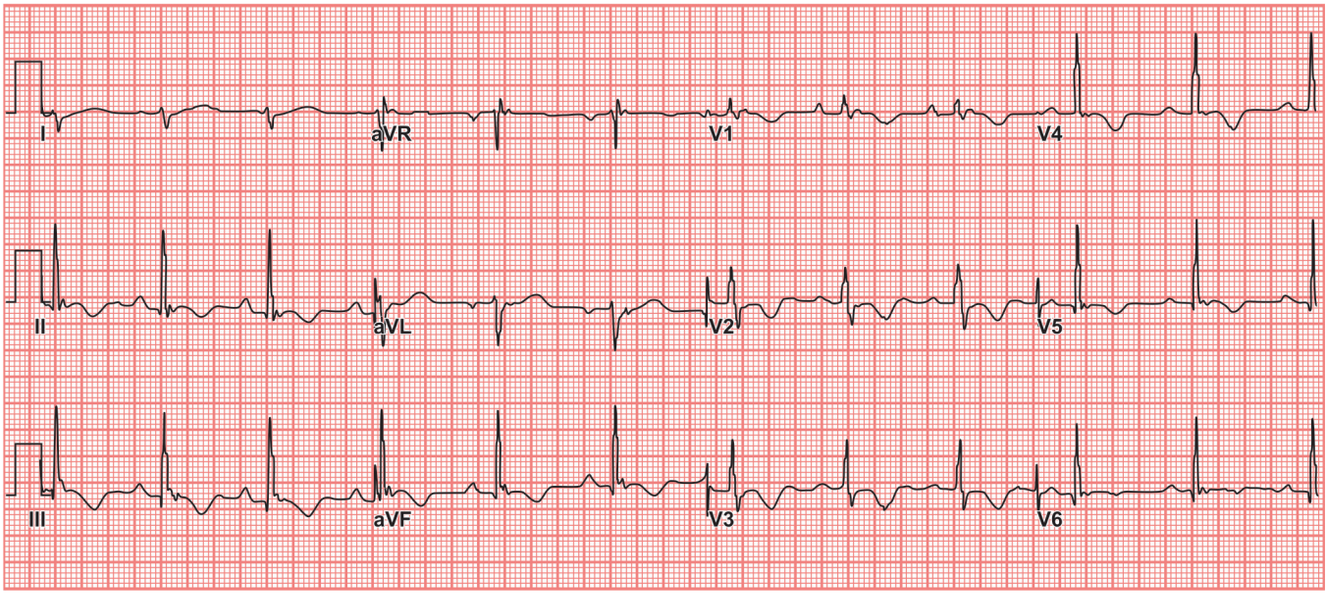

Fig. 15.52: Right ventricular hypertrophy in a patient with arrhythmogenic right ventricular cardiomyopathy—right axis deviation. R/S ratio in V1 > 1 Right ventricular strain pattern with T-wave inversion and ST-depression in the right precordial (V1–3) and inferior (II, III, aVF) leads

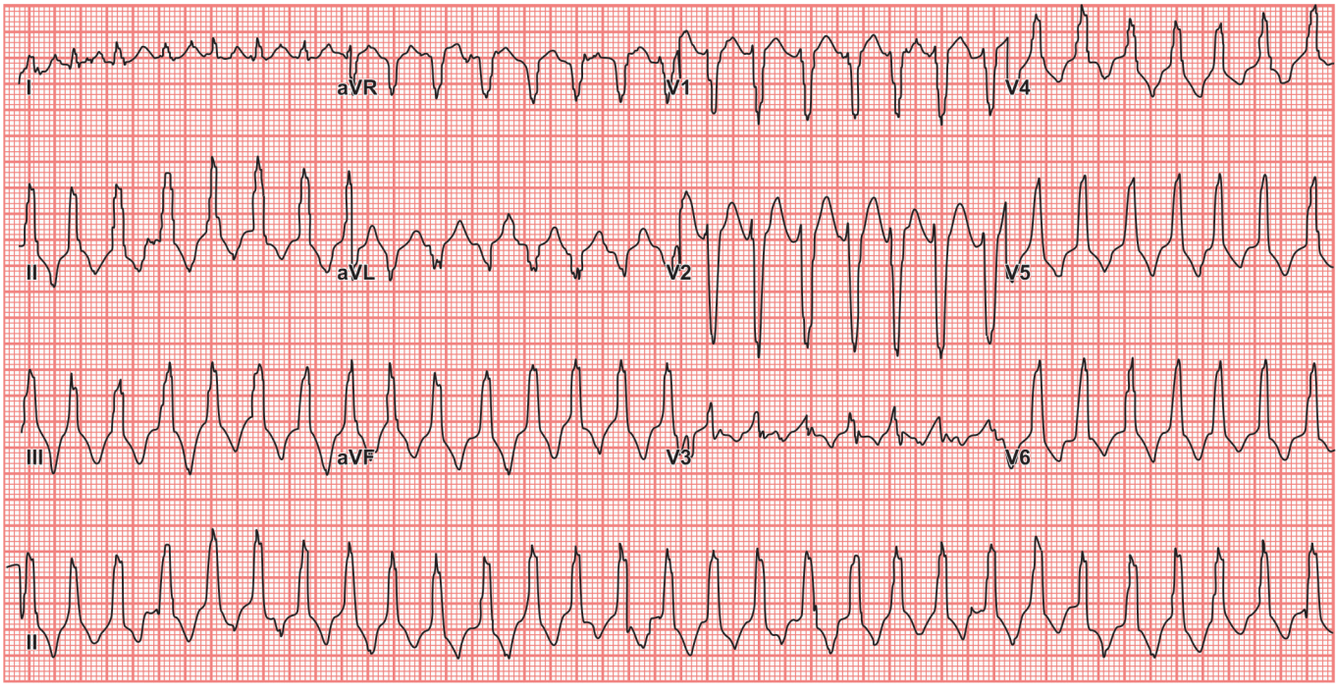

Fig. 15.53: Arrhythmogenic right ventricular cardiomyopathy with evidence of biventricular involvement. Electrocardiogram obtained on admission showing monomorphic ventricular tachycardia with left superior axis and left bundle branch block type configuration, indicating origin in the right ventricle

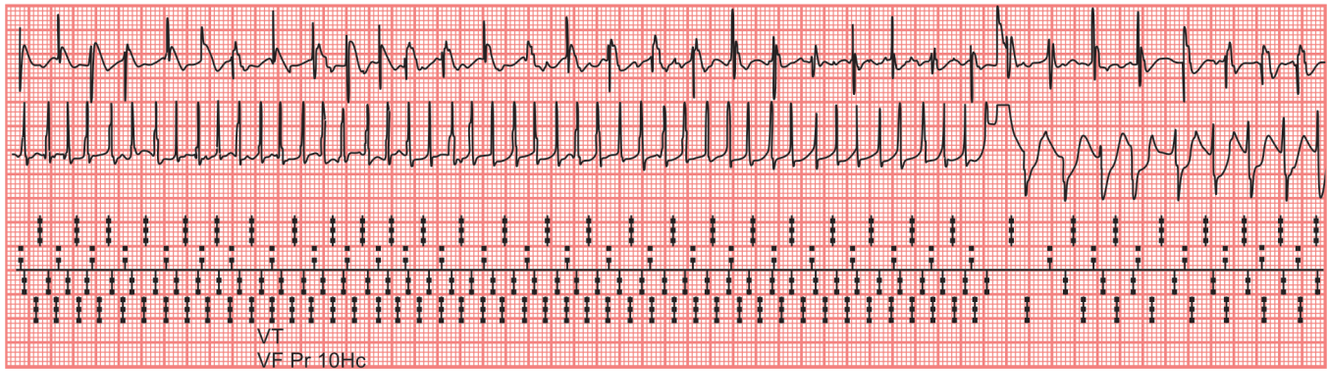

Fig. 15.54: Electrophysiological study—it showed caffeine-induced malignant ventricular arrhythmia in a young patient with arrhythmogenic cardiomyopathy. At electrophysiological study, long runs of self-terminating atrial and ventricular tachycardia were inducible from the right-ventricular upper lateral regions of RV

disturbances. However, the condition is frequently symptomless, with the first manifestation being sudden, unexpected death. Moreover, symptoms, hemodynamics, and electrocardiographic findings are relatively nonspecific, although advances in cardiac imaging, especially magnetic resonance imaging (MRI), have increased the reproducibility of clinical diagnosis (Figs 15.55–15.59).

The diagnosis of ARVC is generally made pathologically at autopsy or at examination of explanted hearts at orthotopic heart transplantation. Endomyocardial biopsy is unreliable, as sampling the apical septum does not typically reveal diagnostic material, and biopsies of the septal endomyocardium may not show the characteristic lesions.

At autopsy, the major differential diagnosis includes normal fat deposits in the right ventricle, and subepicardial scars of ischemic origin. Adipose tissue is normally present in the right ventricle, especially in the anterior wall toward the apex, but no associated fibrosis or myocyte changes exist. In the left ventricle, subepicardial scars can be associated with ischemic heart disease, especially if there is embolization of thromboembolic material from epicardial coronary lesions.

In cases of unexplained exertional death in young adults, submitting multiple sections of ventricular septum and right ventricle to exclude arrhythmogenic forms of cardiomyopathy is reasonable, as ARVC most typically involves

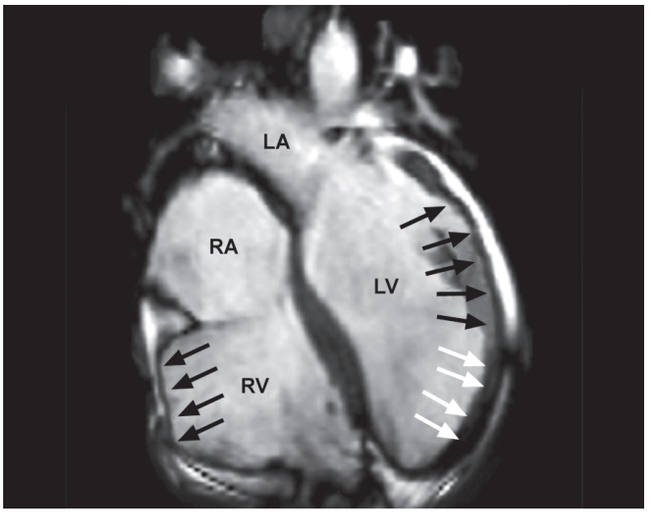

Fig. 15.55: Four chamber view shows severe global enlargement of the right ventricle (RV) with localised dilation at the inflow tract (black arrows). The left ventricle (LV) is also moderately dilated. Regional thinning of the posterolateral LV wall is observed (black arrows). Normal LV wall thickness is highlighted by white arrows for comparison. LA=left atrium; RA=right atrium

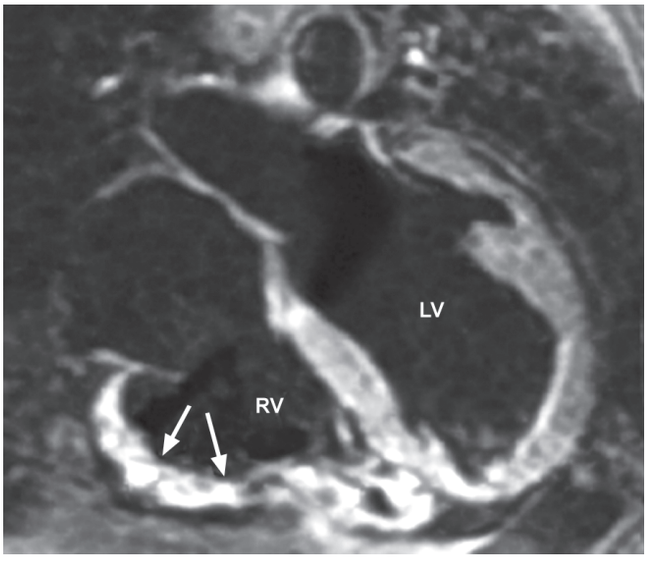

Fig. 15.57: T2 weighted spin echo image in the four chamber view with fat suppression. The bright areas within the grey myocardium (white arrows) are likely to represent edema, suggesting the presence of patchy inflammatory infiltrates

the right ventricle and may be difficult to see grossly; additionally, hypertrophic cardiomyopathy may involve the interventricular septum without obvious grossly abnormalities. Because both of these entities often cause exertional death, taking multiple sections of right ventricle and ventricular septum in cases of exertional deaths is prudent.

Several clinical criteria for the diagnosis of ARVC have been proposed, including those of the working groups on Myocardial and Pericardial Disease and Arrhythmias of the European Society of Cardiology and of the Scientific

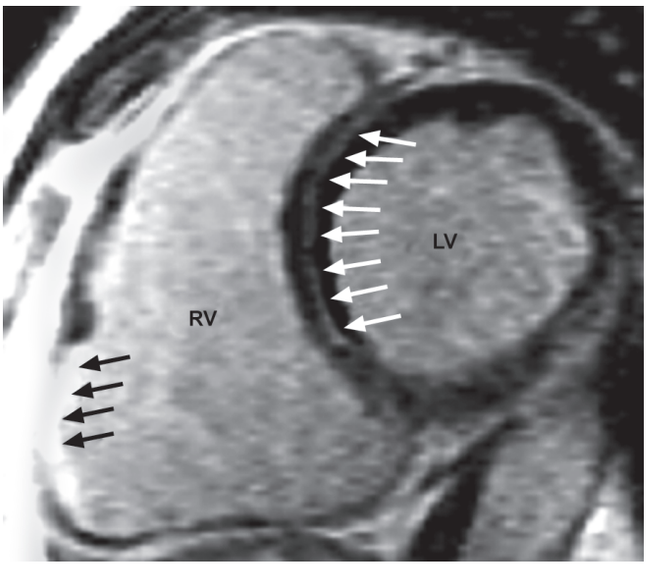

Fig. 15.56: Following intravenous administration of gadolinium-DTPA, late enhancement was observed in both the right ventricle (RV) (black arrows) and the septum (white arrows). Since fat was absent from these regions on corresponding T1 weighted turbospin images, the appearances are consistent with myocardial fibrosis. The mid-myocardial distribution is typical of fibrosis secondary to cardiomyopathy

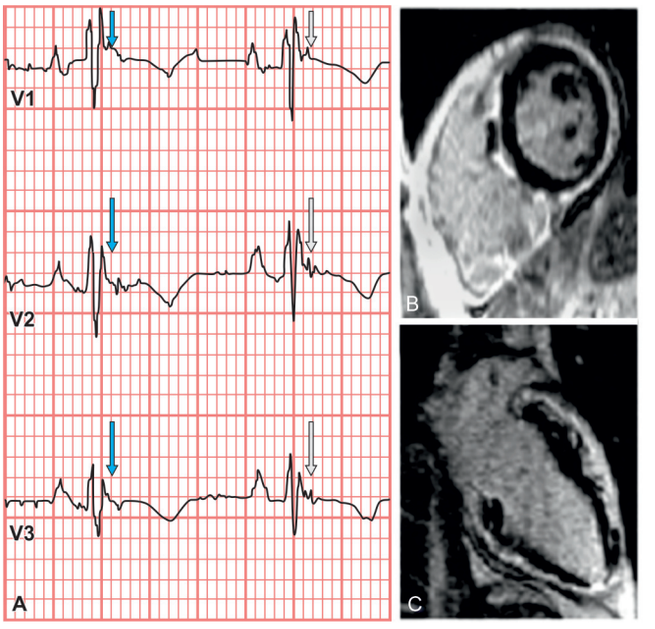

Fig. 15.58: A 48-year-old man presented with syncope due to ventricular tachycardia of left ventricular origin and was electrically cardioverted to sinus rhythm. Resting electrocardiography displayed epsilon waves. (A) Coronary angiography revealed unobstructed arteries. Cardiac magnetic resonance (CMR) demonstrated a severely dilated right ventricle and biventricular systolic dysfunction. Short axis imaging following gadolinium at mid-ventricular level. (B) Identified patchy late enhancement of the right ventricular border of the septum, extending into the subepicardium of the anterior and inferior walls. A two chamber view of the left ventricle. (C) Demonstrated extensive mid-myocardial and subepicardial enhancement

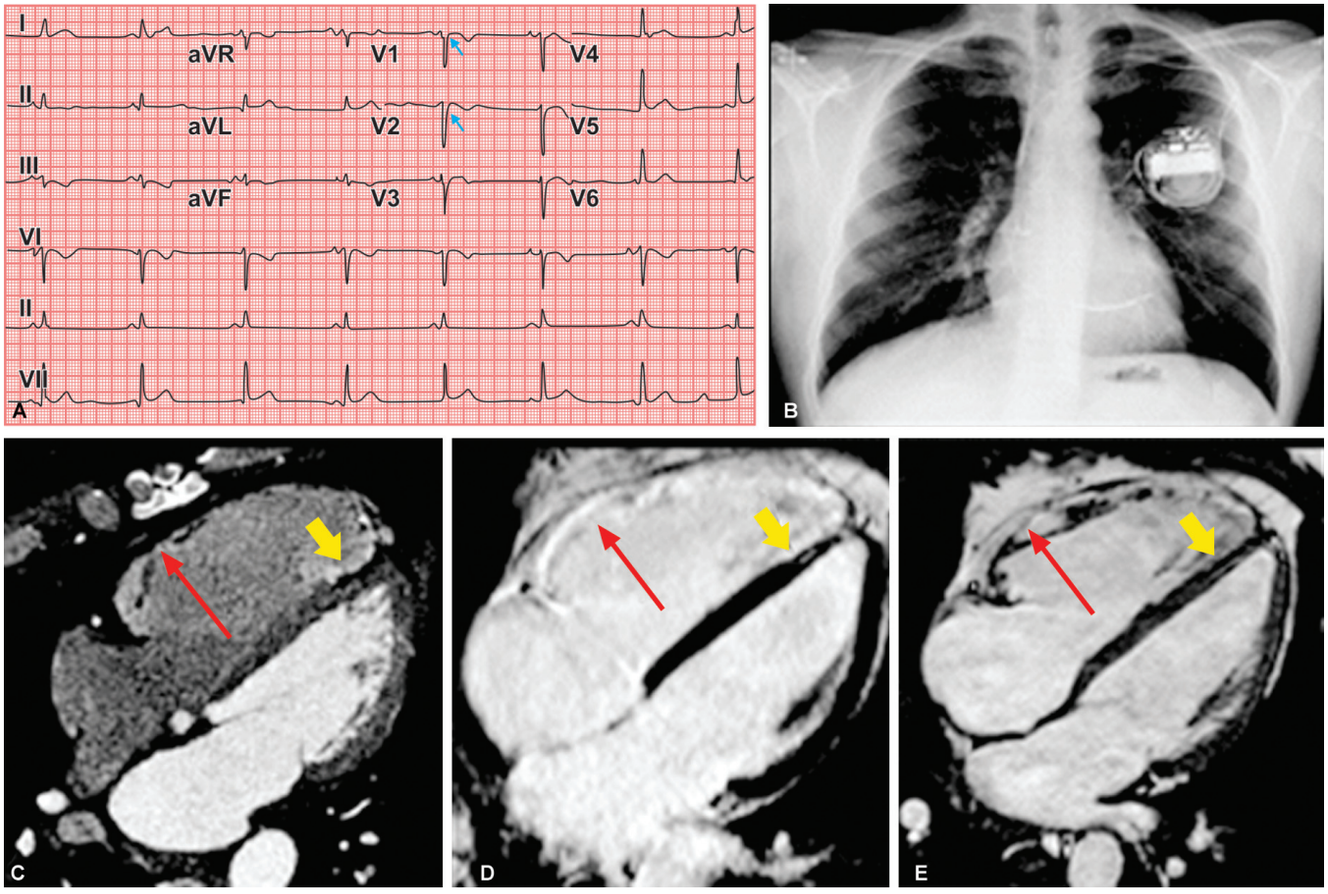

Fig. 15.59: (A) ECG with typical signs for ARVC; negative T-waves and epsilon waves in the precordial leads (arrow). (B) Chest X-ray after ICD implantation. Both the atrial and ventricular leads are visible. (C through E) signal attenuation in RV septum on MDCT. (D) Increased signal intensity on delayed enhancement images. (E) Decreased signal intensity on steady-state free precession images

Council on Cardiomyopathies of the World Heart Federation in 2000, with a revision in 2002).

Immunohistochemistry

In general, immunohistochemistry (IHC) is not useful in the diagnosis arrhythmogenic right ventricular cardiomyopathy. Some investigators have postulated that diffuse loss of desmosomal proteins, as seen immunohistochemically, is suggestive of the diagnosis of ARVC. These proteins include connexin-43 and plakoglobi.

TAKOTSUBO CARDIOMYOPATHY

Takotsubo cardiomyopathy, also known as transient apical ballooning syndrome, apical ballooning cardiomyopathy stress-induced cardiomyopathy, Gebrochenes-Herz-syndrom, and simply stress cardiomyopathy, is a type of nonischemic cardiomyopathy in which there is a sudden temporary weakening of the myocardium (the muscle of the heart). Because this weakening can be triggered by emotional stress, such as the death of a loved one, a break-up, or constant anxiety, the condition is also known as broken heart syndrome. Stress cardiomyopathy is a well-recognized cause of acute heart failure, lethal ventricular arrhythmias, and ventricular rupture.

Clinical Presentation

The typical presentation of someone with takotsubo cardiomyopathy is a sudden onset of congestive heart failure associated with ECG changes suggestive of an anterior wall myocardial infarction. During the course of evaluation of the patient, a bulging out of the left ventricular apex with a hypercontractile base of the left ventricle is often noted. It is the hallmark bulging out of the apex of the heart with preserved function of the base that earned the syndrome its name 'takotsubo', or octopus trap in Japan, where it was first described. The cause appears to involve high circulating levels of catecholamines (mainly adrenaline/epinephrine). Evaluation of individuals with takotsubo cardiomyopathy typically includes a coronary angiogram, which will not reveal any significant blockages that would cause the left ventricular dysfunction. Provided that the individual survives their initial presentation, the left ventricular function improves within 2 months. Takotsubo cardiomyopathy is more commonly seen in

post-menopausal women. Often there is a history of a recent severe emotional or physical stress.

Aetiological Factors

The aetiology of takotsubo cardiomyopathy is not fully understood, but several mechanisms have been proposed.

1. *Wraparound LAD:* The left anterior descending artery (LAD) supplies the anterior wall of the left ventricle in the majority of patients. If this artery also wraps around the apex of the heart, it may be responsible for blood supply to the apex and the inferior wall of the heart. Some researchers have noted a correlation between takotsubo and this type of LAD. Other researchers have shown that this anatomical variant is not common enough to explain takotsubo cardiomyopathy. This theory would also not explain documented variants where the midventricular walls or base of the heart does not contract (akinesis).
2. *Transient vasospasm:* Some of the original researchers of takotsubo suggested that multiple simultaneous spasms of coronary arteries could cause enough loss of blood flow to cause transient stunning of the myocardium. Other researchers have shown that vasospasm is much less common than initially thought. It has also been noted that when there are vasospasms, even in multiple arteries, that they do not correlate with the areas of myocardium that are not contracting.
3. *Microvascular dysfunction:* The theory gaining the most traction is that there is dysfunction of the coronary arteries at the level where they are no longer visible by coronary angiography. This could include microvascular vasospasm, however it may well also have some similarities to the diseases such as diabetes mellitus. In such disease conditions the microvascular arteries fail to provide adequate oxygen to the myocardium.
4. *Mid-ventricular obstruction,* apical stunning It has also been suggested that a mid-ventricular wall thickening with outflow obstruction is important in the pathophysiology.

It is likely that there are multiple factors at play which could include some amount of vasospasm, failure of the microvasculature, and an abnormal response to catecholamines (such as epinephrine and norepinephrine, released in response to stress).

Case series looking at large groups of patients report that some patients develop takotsubo cardiomyopathy after an emotional stress, while others have a preceding clinical stressor (such as an asthma attack or sudden illness). Roughly one-third of patients have no preceding stressful event. A recent large case series from Europe found that takotsubo was slightly more frequent during the winter season. This may be related to two different possible/suspected pathophysiological causes coronary spasms of microvessels, which are more prevalent in cold weather, and viral infections such as parvovirus B19, which occur more frequently during the winter season.

- Laboratory and imaging studies
- Electrocardiogram (Fig. 15.60)
- Echocardiogram (Fig. 15.61)
- MRI (Fig. 15.62)

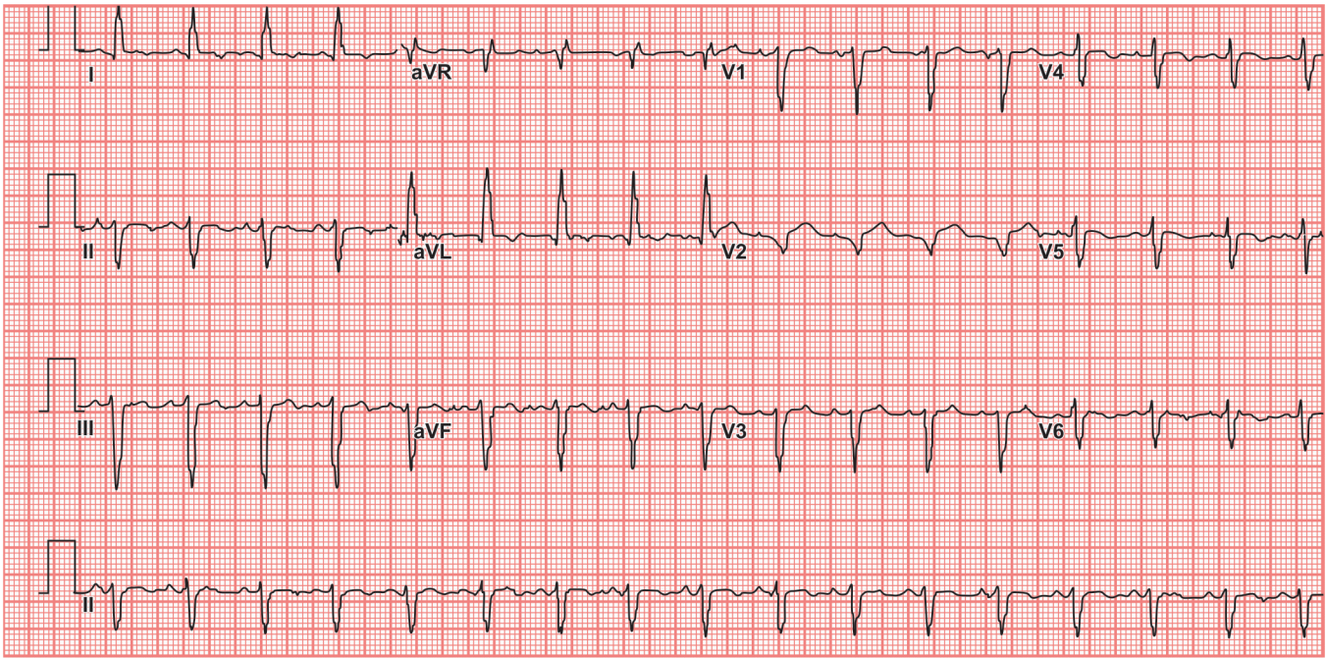

Fig. 15.60: ECG showing sinus tachycardia and nonspecific ST- and T-wave changes from a patient with confirmed takotsubo cardiomyopathy

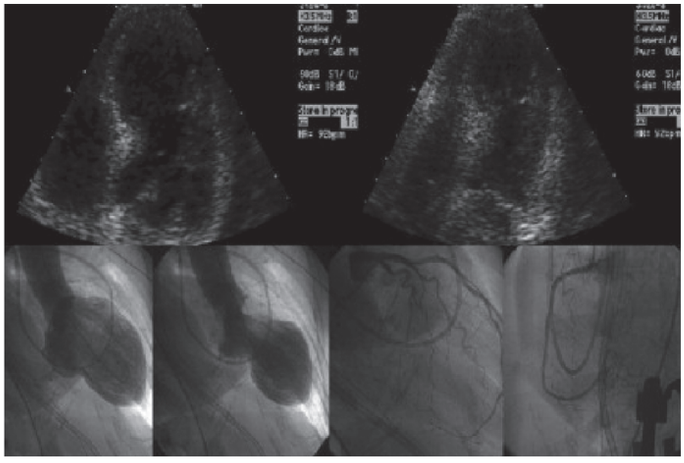

Fig. 15.61: Classic echocardiographic feature of apical ballooning, as can be seen in systole and diastole by echocardiography (upper panel), apical ballooning involving all left ventricular walls not limited to any single coronary territory, confirmed by ventriculography with normal angiogram (lower panel)



Fig.15.62: MRI scan shows dilated left ventricle with apical ballooning is demonstrated with slightly reduced left ventricular function (left ventricular ejection fraction 46%, normalized end diastolic volume 87 ml/m^2, normalized end systolic volume 47 ml/m^2, normalized stroke volume 40 ml/m^2). No myocardial hypertrophy (SWT 6 mm, PWT 9 mm, normalized myocardial mass 35 g/m^2) or myocardial scar formation was found. These findings are compatible with a Takotsubo-cardiomyopathy. Accompanying pleural effusions were also noted (not illustrated) I /CT scan

Cardiac Catheterization Procedure

Transient apical ballooning syndrome or takotsubo cardiomyopathy is found in 1.7–2.2% of patients presenting with acute coronary syndrome. While the original case reports reported on individuals in Japan, takotsubo cardiomyopathy has been noted more recently in the United States and Western Europe. It is likely that the syndrome went previously undiagnosed before it was described in detail in the Japanese literature (Figs 15.63 and 15.64).

The diagnosis of takotsubo cardiomyopathy may be difficult upon presentation. The ECG findings are often confused with those found during an acute anterior wall myocardial infarction. It classically mimics ST-segment elevation myocardial infarction, and is characterised by acute onset of transient ventricular apical wall motion abnormalities (ballooning) accompanied by chest pain, dyspnea, ST-segment elevation, T-wave inversion or QT-interval prolongation on ECG. Elevation of myocardial enzymes is moderate at worst and there is absence of significant coronary artery disease. The diagnosis is made by the pathognomonic wall motion abnormalities, in which the base of the left ventricle is contracting normally or is hyperkinetic while the remainder of the left ventricle is akinetic or dyskinetic. This is accompanied by the lack of significant coronary artery disease that would explain the wall motion abnormalities. Although, apical ballooning has been classically described as the angiographic manifestation of takotsubo, it has been shown that left ventricular dysfunction in this syndrome includes not only the classic apical ballooning, but also different angiographic morphologies such as mid-ventricular ballooning and rarely local ballooning of other segments.

The ballooning patterns were classified by Shimizu et al. as takotsubo type for apical akinesia and basal hyperkinesia, reverse takotsubo for basal akinesia and apical hyperkinesia, mid-ventricular type for mid-ventricular ballooning accompanied by basal and apical hyperkinesia and localised type for any other segmental left ventricular ballooning with clinical characteristics of takotsubo-like left ventricular dysfunction.

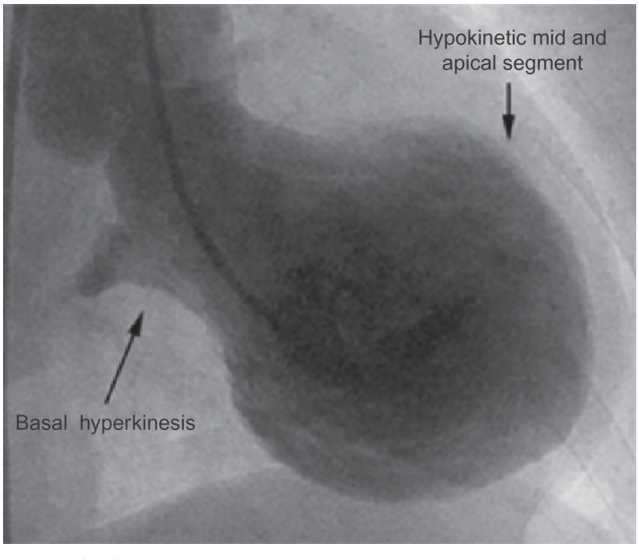

Fig. 15.63: Cardiac catheterization shows hypokinesia of basal, mid and apical segments of LV with ballooning features in takotsubo cardiomyopathy

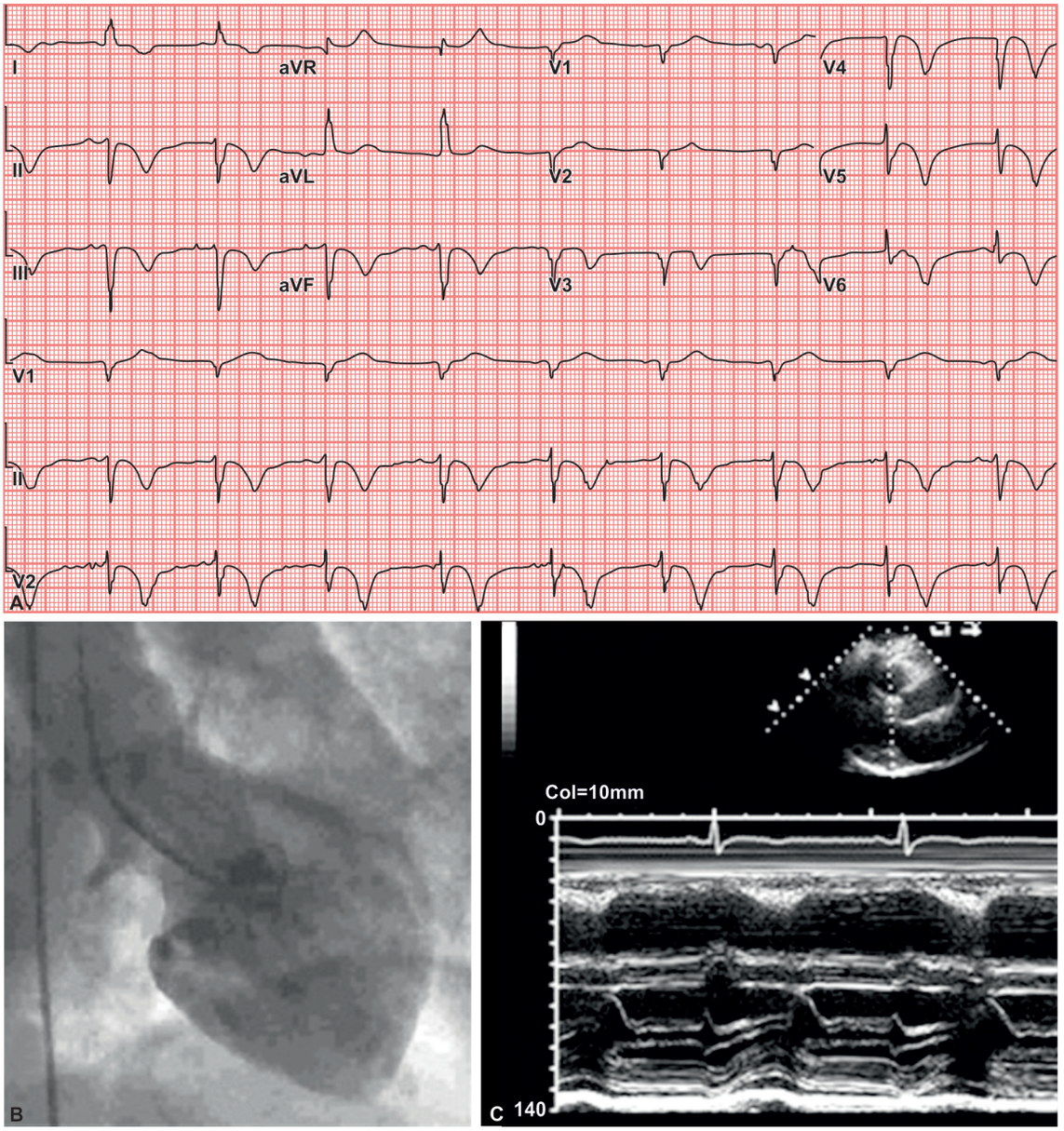

Fig.15.64: First episode of takotsubo cardiomyopathy. (A) ECG at time of admission consistent with ischemia, (B) left ventriculography during first episode of takotsubo cardiomyopathy 6 years earlier at end-systolic phase showing similar features as the second presentation, (C) M-mode 2D echocardiography 4 years after the initial episode revealing normal function of the left ventricle and complete recovery

Prognosis

Despite the grave initial presentation in some of the patients, most of the patients survive the initial acute event, with a very low rate of in-hospital mortality or complications. The patients are expecting a favorable outcome once recovering from the acute stage of the syndrome, and the long-term prognosis is excellent. Even when ventricular systolic function is heavily compromised at presentation, it typically improves within the first few days and normalises within the first few months. Although infrequent, recurrence of the syndrome has been reported and seems to be associated with the nature of the trigger.

Treatment

The treatment of takotsubo cardiomyopathy is generally supportive in nature. Although patients with takotsubo heart disease may be hypotensive, treatment with inotropes will usually exacerbate the disease. Since the disease is due to a high catecholamine state, patients should not be given inotropes. Treatment recommendations include intra-aortic balloon pump, fluids, and negative inotropes such as beta-blockers or calcium channel blockers. In many individuals, left ventricular function normalizes within 2 months. Aspirin and other heart drugs also appear to help in the treatment of this disease, even in extreme cases.

BIBLIOGRAPHY

1. Basso C, Thiene G, Corrado D, Angelini A, Nava A, Valente M. Arrhythmogenic right ventricular cardiomyopathy. Dysplasia, dystrophy, or myocarditis? Circulation 1996; 94(5):983-91.
2. Bauce B, Basso C, Rampazzo A, et al. Clinical profile of four families with arrhythmogenic right ventricular cardiomyopathy caused by dominant desmoplakin mutations. Eur Heart J 2005;26(16):1666–75.
3. Bernstein D. Diseases of the myocardium. In: Kliegman RM, Behrman RE, Jenson HB, Stanton BF, (Eds.) Nelson Textbook of Pediatrics. 18th ed. Philadelphia, Pa: Saunders Elsevier; 2007:chap 439.
4. Burke AP, Farb A, Tashko G, Virmani R. Arrhythmogenic right ventricular cardiomyopathy and fatty replacement of the right ventricular myocardium: are they different diseases? Circulation 1998;97(16):1571–80.
5. Chin TK, Perloff JK, Williams RG, et al. Isolated noncompaction of left ventricular myocardium. A study of eight cases. Circulation 1990;82(2):507–13.
6. Dokuparti MV, Pamuru PR, Thakkar B, et al. Etiopathogenesis of arrhythmogenic right ventricular cardiomyopathy. J Hum Genet 2005;50(8):375–81.
7. Engberding R, Bender F. Identification of a rare congenital anomaly of the myocardium by two-dimensional echocardiography: Persistence of isolated myocardial sinusoids. Am J Cardiol 1984;53(11):1733–4.
8. Espinola-Zavaleta Nilda, Soto Elena, Castellanos Luis Munoz, Játiva-Chávez Silvio, Keirns Candace (2006). "Non-compacted Cardiomyopathy: Clinical-Echocardiographic Study". Cardiovasc Ultrasound 4 (1): 35. doi:10.1186/1476-7120-4-35.
9. Ferreira AC, Garcia SA, Pasquale MA, Canoniero MJ, Peter A. Arrhythmogenic right ventricular dysplasia in the elderly. Heart Dis 2003;5(6):393–6.
10. Fidler LM, Wilson GJ, Liu F, et al. Abnormal connexin in arrhythmogenic right ventricular cardiomyopathy caused by plakophilin-2 mutations. J Cell Mol Med 2009;13(10): 4219–28.
11. Francés RJ. Arrhythmogenic right ventricular dysplasia/ cardiomyopathy. A review and update. Int J Cardiol 2006; 110(3):279–87.
12. Hare JM. The dilated, restrictive, and infiltrative cardiomyopathies. Bonow RO, Mann DL, Zipes DP, Libby P, (Eds.) In: Braunwald's Heart Disease: A Textbook of Cardiovascular Medicine. 9th ed. Philadelphia, Pa: Saunders Elsevier; 2011:chap 68.
13. Hare JM. The dilated, restrictive, and infiltrative cardiomyopathies. Libby P, Bonow RO, Mann DL, Zipes DP. In: Braunwald's Heart Disease: A Textbook of Cardiovascular Medicine, 8th ed. Philadelphia, Pa: Saunders Elsevier; 2007:chap 64.
14. Lobo FV, Silver MD, Butany J, Heggtveit HA. Left ventricular involvement in right ventricular dysplasia/cardiomyopathy. Can J Cardiol 1999;15(11):1239–47.
15. Maron BJ. Hypertrophic cardiomyopathy. Zipes DP, Libby P, Bonow RO, Braunwald E, (Eds.) Braunwald's Heart Disease: A Textbook of Cardiovascular Medicine. 8th ed. St. Louis, Mo: WB Saunders; 2007:chap 65.
16. Maron B, Towbin J, Thiene G, Antzelevitch C, Corrado D, Arnett D, Moss AJ, Seidman CE, et al. Contemporary Definitions and Classification of the Cardiomyopathies (webpage). American Heart Association Journals (American Heart Association) 2006;113(14):1807.
17. Morrow DA, Boden WE. Stable ischemic heart disease. In: Bonow RO, Mann DL, Zipes DP, Libby P, (Eds.) Braunwald's Heart Disease: A Textbook of Cardiovascular Medicine. 9th ed. Philadelphia, Pa; Saunders Elsevier; 2011:chap 57.
18. Oechslin, Erwin; Jenni, Rolf (2005). Non-compaction of the Left Ventricular Myocardium—From Clinical Observation to the Discovery of a New Disease. Archived from the original on 2007-09-29.
19. Pignatelli RH, McMahon CJ, Dreyer WJ, et al. Clinical characterization of left ventricular non-compaction in children: a relatively common form of cardiomyopathy. Circulation 2003;108(21):2672–8.
20. Rampazzo A, Nava A, Malacrida S, et al. Mutation in human desmoplakin domain binding to plakoglobin causes a dominant form of arrhythmogenic right ventricular cardiomyopathy. Am J Hum Genet 2002;71(5):1200–6.
21. Sen-Chowdhry S, Syrris P, Ward D, Asimaki A, Sevdalis E, McKenna WJ. Clinical and genetic characterization of families with arrhythmogenic right ventricular dysplasia/ cardio-myopathy provides novel insights into patterns of disease expression. Circulation 2007;115(13):1710–20.
22. Syrris P, Ward D, Evans A, et al. Arrhythmogenic right ventricular dysplasia/cardiomyopathy associated with mutations in the desmosomal gene desmocollin-2. Am J Hum Genet 2006;79(5):978–84.
23. Thiene G, Corrado D, Basso C. Arrhythmogenic right ventricular cardiomyopathy/dysplasia. Orphanet J Rare Dis 2007; 2:45.
24. Vatta M, Mohapatra B, Jimenez S, et al. Mutations in Cypher/ ZASP in patients with dilated cardiomyopathy and left ventricular non-compaction. J Am Coll Cardiol 2003;42(11): 2014–27.
25. Weiford BC, Subbarao VD, Mulhern KM. Noncompaction of the ventricular myocardium. Circulation 2004;109(24): 2965–71.
26. Wexler RK, Elton T, Pleister A, Feldman D. Cardiomyopathy: An overview. Am Fam Physician 2009;79:778–784.

16 Recognition and Management of Cardiac Valvular Emergencies

Chronic rheumatic valvular dysfunctions can lead to very high morbidity and mortality among patients unless they are helped with either reconstructive surgery or replacement of an artificial valve. Two types of artificial valves which are available today have their own limitations and till date there is no ideal valve which could closely resemble with natural valve in terms of cost and postoperative long term outcome. Recently attempts have been made in constructing artificial heart valves with the help of stem cell modification and genetic engineering techniques though long term follow up is still awaited. Synthetic valve do give rise to bleeding disorders due to anticoagulants and predispose to thromboembolic phenomenon and infection leading to vital organ dysfunctions.

Although tissue valves do not need anticoagulants but still it could be the seat of infections and are often rejected in mismatched cases. Undoubtedly, tissue valve is preferable in pregnant women and younger children where anticoagulants may pose life-threatening complications. The life span of this valve is shorter than the synthetic valve due to its rapid degeneration.

In developing countries, rheumatic process is so extensive that often more than one valves (multivalvular) are affected which further complicates the final management of the patients besides the cost implications among poor patients (Fig. 16.1).

Sincere efforts are still continued to manufacture such a valve which could satisfy all the properties of an ideal valve and come within the reach of low socioeconomic strata of people where a large segment of population is affected every year particularly in developing countries of South-East Asia. Valvular heart disease is an important cause of cardiac morbidity in developed countries despite a decline in the prevalence of rheumatic disease in those countries. Valvular heart disease can give rise to stenosis, regurgitation or a combination of lesions at one or more valves. The more common significant anomalies currently encountered are mitral regurgitation, caused by mitral valve prolapse; aortic stenosis, caused by a congenital bicuspid valve or by senile valvular calcification; and aortic regurgitation, caused by a bicuspid aortic valve or dilatation of the aorta. Valvular lesions can occur as a result of pathologic changes in the valve leaflets or supporting structures (i.e. the chordae or papillary muscles). Ventricular or aortic enlargement can also produce valvular regurgitation as a result of annular dilatation and inadequate leaflet coaptation in the absence of any specific valve pathology. Valvular heart disease tends to progress over time as degenerative changes are superimposed on the primary pathology. Iatrogenic causes of valvular disease are increasingly recognized.

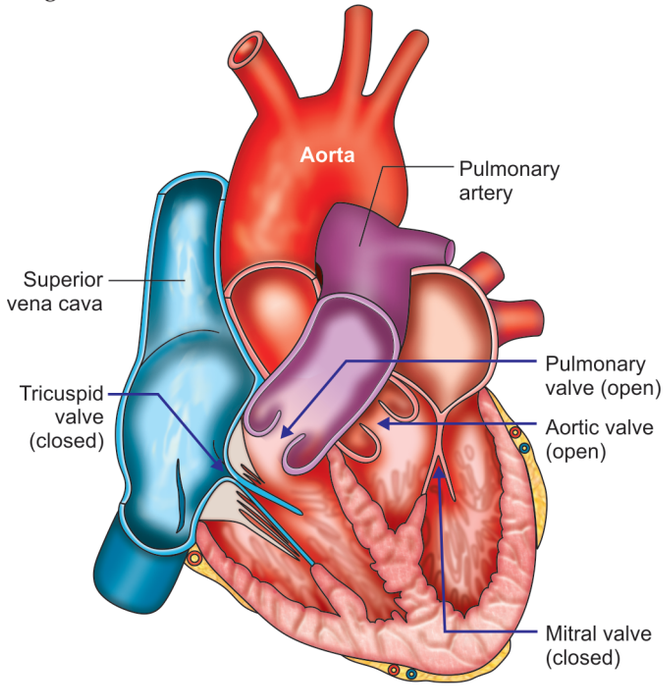

Fig. 16.1: Anatomical placement of four native valves in human body

Valvular problems may be caused by infection, heart disease, trauma or congenital valvular conditions and may be isolated to a single valve or effect multiple valves. Right sided (tricuspid, pulmonary) valvular disease is much less common than left sided (aortic, mitral) valvular disease. Roughly 90% of valvular disease is chronic, having developed gradually over many years. Complications of rheumatic fever, congenital disorders and aging cause the vast majority of chronic valvular disease. The remaining 10% of valvular disease that develops acutely (over days to weeks) is often due to complications of recent heart attack or infections.

AETIOLOGICAL FACTORS IN VALVULAR DYSFUNCTIONS

Congenital Disorders

Anomalies in the development of valve cusps are common at the aortic or pulmonary positions. The normal configuration of these valves is tricuspid. Stenosis is the rule when only one cusp develops, whereas bicuspid valves may be stenotic or regurgitant. Congenital anomalies of the atrioventricular valves are uncommon; the most common abnormality is congenital cleft mitral valve. Valvular abnormalities can be seen in specific developmental syndromes, such as pulmonary stenosis in rubella syndrome and supravalvular aortic stenosis in Williams syndrome.

Myxomatous Degeneration

Myxomatous degeneration most often involves the mitral or tricuspid valve. In this condition, leaflet tissue, particularly chordal tissue, is abnormally extensible and weak. The affected valves are therefore more likely to prolapse, leading to significant regurgitation. Chordal rupture is common and may precipitate a rapid clinical deterioration from sudden severe regurgitation. The precise abnormality in valvular tissue is unknown but is thought to involve the structural proteins, such as collagen. A familial tendency is often noted in this disease. Inherited connective tissue diseases such as Marfan syndrome produce valvular abnormalities similar to those found in myxomatous degeneration.

Rheumatic Heart Disease

Rheumatic heart disease remains the most common cause of mitral stenosis and a frequent cause of aortic regurgitation. It is the most common cause of multivalvular heart disease. Isolated outbreaks of rheumatic fever continue to be reported in the United States, even in affluent communities. Rheumatic heart disease remains a significant problem in immigrants, especially those from Latin America and Southeast Asia. Rheumatic fever appears to cause valvular heart disease by an autoimmune phenomenon whereby antibodies against streptococcal antigens cross-react with valvular tissue. Valvular involvement can present acutely as a result of edema of valvular tissue. Progressive fibrosis, superimposed calcification, and scarring with retraction of leaflet tissue lead to valvular stenosis, incompetence, or both. The interval between the occurrence of rheumatic fever and clinical manifestations varies, as does the degree of involvement. Both mitral and aortic valves are usually involved.

Degenerative Disease

Degenerative calcification can occur in aortic stenosis among the elderly and in patients with renal dysfunction; it results from calcium deposition on the body of the valvular leaflets rather than on the commissures. Factors found to promote degenerative valvular changes are increasing age, a low body mass index, hypertension, and hyperlipidemia. Histologic changes that simulate atheroma and involve lipid deposition and inflammatory cell infiltration of the leaflets have been described in patients with early degenerative changes in the aortic leaflets. Even mild degenerative changes in the aortic valve have been reported to be adverse prognostic factors. Calcification of the mitral annulus is common in the elderly; it is more common in women than in men and can produce mitral regurgitation. Occasionally, mitral annular calcification extends onto the valvular leaflets, causing stenosis.

Endocarditis

Endocarditis usually occurs on previously abnormal valves, although overwhelming sepsis can infect normal valves. The predominant hemodynamic manifestation of endocarditis is valvular regurgitation. Contributory causes of endocarditis include leaflet prolapse (resulting from a large vegetation), leaflet perforation, and chronic scarring of infected tissue. In rare cases, large vegetations lead to valvular stenosis.

Coronary Artery Disease

Mitral regurgitation is common in coronary artery disease; it has a number of causal mechanisms. Acute ischemia or infarction of a papillary muscle or of the wall to which the papillary muscle is attached leads to impaired leaflet coaptation and mitral regurgitation. Regurgitation can be severe and can vary with the severity of the ischemia. Papillary head rupture or, more rarely, muscle rupture, leads to catastrophic regurgitation that is often fatal.

Connective Tissue Disease

Libman-Sacks endocarditis consists of noninfected warty vegetations involving predominantly the mitral valve; it is characteristic of systemic lupus erythematosus (SLE). Significant regurgitation and stenosis rarely occur acutely but are seen with scarring from chronic disease. Valvular involvement in rheumatoid arthritis is common and leads to valvular thickening but is usually not of hemodynamic significance. Aortitis in ankylosing spondylitis may produce significant aortic regurgitation.

Iatrogenic Causes of Valvular Heart Disease

Iatrogenic causes include radiation therapy, the use of serotonin agonists such as methysergide, and the use of anorexiants such as fenfluramine and phentermine in combination. Radiation leads to scarring and calcification

of valvular leaflets many years after the initiating radiation. The effects of both methysergide and anorexiant agents on valvular tissue often simulate rheumatic disease, but regurgitation rather than stenosis predominates as the hemodynamically severe lesion. Serotonin is also thought to play a role in the valvulopathy produced by anorexiants; the precise mechanism by which this occurs remains to be established.

Other Causes of Valvular Heart Disease

Amyloid disease causes valvular thickening but rarely causes significant stenosis. The carcinoid syndrome most often involves the valves on the right side of the heart and leads to stenosis or incompetence of the tricuspid or pulmonary valve.

Secondary Involvement

Left ventricular dilatation can cause dilatation of the mitral annulus and, thereby, mitral regurgitation. Common secondary causes of mitral regurgitation include coronary artery disease, aortic valvular disease, and dilated cardiomyopathy. Similarly, tricuspid regurgitation results from right ventricular enlargement secondary to pulmonary hypertension or an atrial septal defect. Dilatation of the ascending aorta, especially involving the annulus of the aortic valve, can lead to aortic regurgitation. This condition is seen in hypertension and in aneurysms of the ascending aorta.

Assessment and Management

Valvular heart disease often remains asymptomatic for many years, but once symptoms develop, survival is reduced if the lesion is not corrected. The evaluation of symptoms can require a stress test or stress echocardiogram in addition to a careful history. Characterization of the lesions and assessment of hemodynamic severity are often possible on physical examination but are aided by additional testing, such as Doppler echocardiography and cardiac catheterization. Doppler echocardiography measures the flow velocity across a narrowed valve. By use of the modified Bernoulli equation, the pressure gradient (P), measured in mmHg, may be estimated from the flow velocity (v), which is measured in m/sec: $P = 4v^2$. Therefore, if the peak velocity recorded across the aortic valve by Doppler echocardiography is 4 m/sec, then the peak pressure gradient will be estimated as $4(4^2)$ or 64 mmHg. The effects of valvular heart disease on chamber size and function are best assessed serially by echocardiography or, at the time of cardiac catheterization, by ventriculography. In cases of stenotic lesions, intervention is rarely required until symptoms occur. Indications for intervention in regurgitant lesions are more complex; such indications include significant symptoms or, in the absence of symptoms, increasing ventricular size, overt ventricular contractile dysfunction, or both.

All patients with even mild valvular heart disease require prophylaxis against endocarditis at the time of dental procedures or other procedures that can produce significant bacteremia. The prophylactic regimens recommended by the American Heart Association have been revised despite the increase in intravascular volume, pregnancy is usually well tolerated in previously asymptomatic patients with valvular heart disease. Patients with hemodynamically significant valvular heart disease should generally avoid participation in competitive sports. Reference should be made to the recommendations of the American College of Cardiology for more information about specific lesions. Valvular heart disease is a chronic disease requiring periodic examination and follow-up, even in asymptomatic patients and in those who have had corrective surgical or other procedures. Patients with prosthetic valves should be seen at least yearly.

VALVULAR EMERGENCIES

Common valvular emergencies found in emergency department are as follows:

- Mitral stenosis
- Mitral regurgitation
- Mitral valve prolapse
- Aortic stenosis
- Aortic regurgitation
- Right-sided valvular heart disease

Newly Discovered Heart Murmur (Fig. 16.2)

Ruptured Sinus of Valsalva Aneurysm

Sinus of Valsalva aneurysms are rare congenital or acquired cardiac anomalies, most commonly involving the right or noncoronary sinuses. (1) Congenital sinuses of Valsalva aneurysm account for ~0.5% to 3% of all congenital cardiac defects. In addition, inflammatory diseases, such as syphilis, tuberculosis, endocarditis, and Behçet disease, as well as traumatic events and connective tissue disorders,

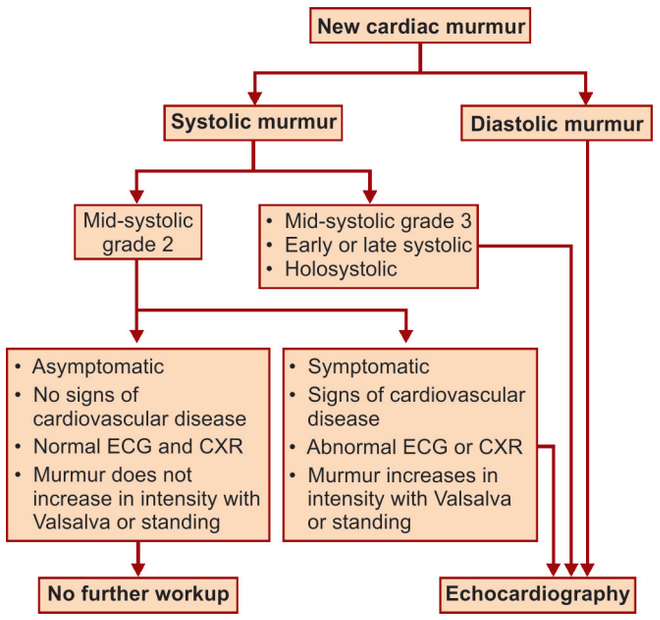

Fig. 16.2: Evaluation of newely discovered murmur

such as Marfan syndrome, can be the cause of this anomaly. (2) Rupture of a sinus of Valsalva aneurysm requires definitive repair because of progressive right heart failure. Magnetic resonance imaging with the phase-contrast method is a reliable noninvasive way to assess the cardiac shunt ratio, thereby helping to guide therapy. The treatment of choice is a surgical approach, although transcatheter occlusion has occasionally been shown to be an alternative. Sudden onset of a cardiac murmur should always include the differential diagnosis of a ruptured sinus of Valsalva aneurysm.

BOX 16.1: Grading of murmurs

Murmurs are graded on a four point or, more commonly, a six-point scale. A common six-point scale is:
Grade 1—audible with difficulty
Grade 2—faint but recognizable
Grade 3—moderate intensity
Grade 4—loud
Grade 5—louder, but still needing a stethoscope
Grade 6—audible without a stethoscope.

SPECIFIC VALVULAR LESIONS

MITRAL VALVE DISORDERS

The mitral valve normally allows one way flow of blood from the left atrium to the left ventricle. Disorders of the mitral valve may cause mitral valve stenosis, mitral valve regurgitation or mitral valve prolapse (previously discussed).

1. Mitral Valvular Stenosis

It is narrowing of the mitral valve opening that usually gradually occurs over time due chronic scarring. Rheumatic fever is still the most common cause of mitral valve stenosis.

As the mitral opening narrows the left atrium enlarges (dilates) over time because it must work harder to pump blood into the left ventricle. Many people (up to 50%) eventually develop atrial fibrillation because of progressive dilatation of the left atrium. In atrial fibrillation the left atrium quivers instead of effectively pumping blood to the left ventricle causing a decreased amount of blood to the left ventricle.

Severe stenosis may also cause pressure to built up in the lung blood vessels (pulmonary veins) that supply blood to the left atrium. The lung blood vessels are normally under much lower pressure (as is the right side of the heart that pumps blood to the lungs) than the left ventricle, aorta and its arterial branches. Increased blood pressure in the lungs is called pulmonary hypertension.

Aetiology of Mitral Stenosis

1. Rheumatic fever
2. Cardiac tumors
3. Rheumatologic disorders (lupus, rheumatoid arthritis)
4. Myxoma
5. Congenital defects: Parachute valve

Clinical Manifestations

A. Symptoms:

1. **Dyspnea** on exertion is usually the first symptom. It may progress from grade 1 to 4 in severe cases in which case it may be accompanied by orthopnea or paroxysmal nocturnal dyspnea. Acute pulmonary edema is a grave and dreaded complication of mitral stenosis.
2. **Palpitation** on exertion is also a frequent symptom, representing an increased awareness by the patient of her precordial impulse, which in turn may be due to the hypertrophied right ventricle. At times, when the onset of a palpitation is sudden, it may be a manifestation of a transient paroxysmal atrial tachycardia or atrial fibrillation.
3. **Cough** is usually brought on by exertion. Some patients develop a chronic bronchitis precipitated by chilly weather, which is very similar to the usual idiopathic chronic bronchitis.
4. **Chest pain:** Noncardiac localised in left inframammary region is common in neurotic individuals. True angina pectoris can also occur, especially in patients with severe pulmonary hypertension or associated with coronary artery disease in elderly group of patients.
5. **Hemoptysis** is frequent, and often the presenting complaint. It is usually the result of rupture of congested veins in the bronchial mucosa, but occasionally it may be the presenting symptom of pulmonary infarction.
6. **Embolic phenomenon** results in blocking of a cerebral artery presenting as a sudden stroke, of the splenic or renal artery manifesting with acute abdominal pain, or of a peripheral limb artery with acute pain and other manifestations of ischemia. Obstruction of the aortic bifurcation by a large embolus is a particularly serious complication.
7. Due to compression of the left recurrent laryngeal nerve by a dilated and tense main pulmonary artery, it may lead to paralysis of left vocal cord presenting as hoarseness of the voice (Ortner's syndrome).

B. Physical examination:

1. The patients may have a typical mitral facies with pinkish purple patches on the cheeks.
2. The pulse is usually normal, but may be weak if stroke volume is reduced (Fig 16.3).
3. A prominent 'a' wave may be present in the jugular venous pulse of patients in sinus rhythm with pulmonary hypertension.
4. A palpable first heart sound (S1) suggests a pliable anterior mitral valve leaflet. A right ventricular heave and a palpable pulmonic component of the second heart sound (P2) suggests pulmonary hypertension.
5. Aloud first heart sound (S1) occurs because the valve is fibrotic but pliable and higher than normal left ventricular systolic pressure is required to close it.



Fig 16.3: Photograph of a young lady with 8 months pregnancy with tight mitral valvular stenosis

6. The opening snap (OS) is best heard at the apex and is as a result of the sudden tensing and deceleration of the mitral valve leaflets when they are fully open. It usually suggests that the valve is still pliable and not rigidly calcified. The duration of the interval between the aortic component of the second heart sound and the opening snap correlates inversely with left atrial pressure.
7. A low-pitched diastolic rumble which is produced by blood flow across the narrowed mitral valve can be best heard at the apical region, often best heard with the patient in the left lateral decubitus position. The duration of the rumble roughly correlates with increasing severity of mitral stenosis. It may be masked by noisy respirations or by low cardiac output and may be accentuated by increasing cardiac output with exercise. One may encounter a palpable diastolic thrill at the apex.
8. There may be an apical holosystolic murmur of associated rheumatic mitral regurgitation.
9. There may be a holosystolic murmur of tricuspid regurgitation from right ventricular dilatation along the lower left sternal border.
10. There could be a mixture of murmurs produced as a result of involvement of their respective valves, such as aortic, tricuspid and pulmonary inorigion. Normally, the cross-sectional area of the mitral valve is at least 4 cm^2. Mitral stenosis leads to a reduction in valve area and is considered severe when the valve area is less than 1 cm^2. To maintain flow through the valve, leftatrial pressure rises, leading to an increase in the pressure gradient across the valve and to increased pulmonary venous and capillary pressures, with resultant dyspnea. Flow through the stenotic valve is dependent on the duration of diastole. Tachycardia shortens diastole disproportionately and causes a further elevation in left atrial pressure and can precipitate symptoms even in patients with relatively mild stenosis. Elevated left atrial pressure contributes to left atrial enlargement, which in turn predisposes the patient to atrial fibrillation, atrial thrombus formation, and thromboembolism, all of which are common complications of mitral stenosis. Severe mitral stenosis is often associated with an increase in pulmonary arterial pressure, leading to right-sided heart failure and secondary tricuspid and pulmonary incompetence. In patients with severe pulmonary hypertension, cardiac output at rest is reduced; this output reduction can cause a relatively low pressure gradient across the mitral valve even in patients with severe stenosis.

Diagnosis of Mitral Stenosis

It is suspected in a person with a history of congestive heart failure, findings of a specific type of mitral heart murmur on physical exam, and confirmed with the following set of examination.

Chest Radiography

For patients with mitral stenosis, the chest radiograph may exhibit certain specific and nonspecific findings that are generally a consequence of left atrial enlargement, mitral calcification, pulmonary hypertension, and congestive heart failure (CHF). The degree of confidence is reasonably good for mitral stenosis. Findings are sometimes non-specific (Figs 16.4–16.7).

Electrocardiography: If the patient is in sinus rhythm, the electrocardiogram shows abnormality of the LA. LA abnormality is manifested by prolongation of the P-wave, with a double-saddleback contour (p mitrale) in limb lead II. This contour represents a right atrial P-wave followed by delayed LA P-wave associated with an enlarged left atrium. LA abnormality is seen as a terminal negative deflection following the initial upright P-wave in

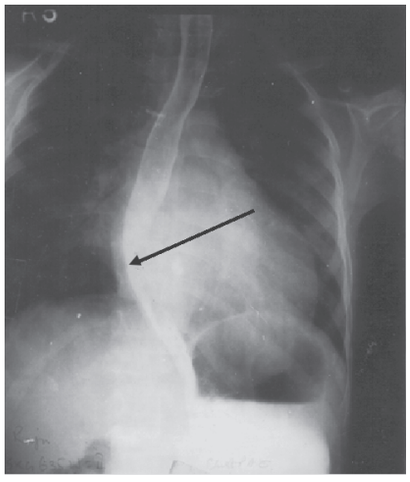

Fig. 16.4: Photograph of barium meal study (arrow) showing indentation of barium filled esophagus in moderate enlargement of LA in rheumatic MS

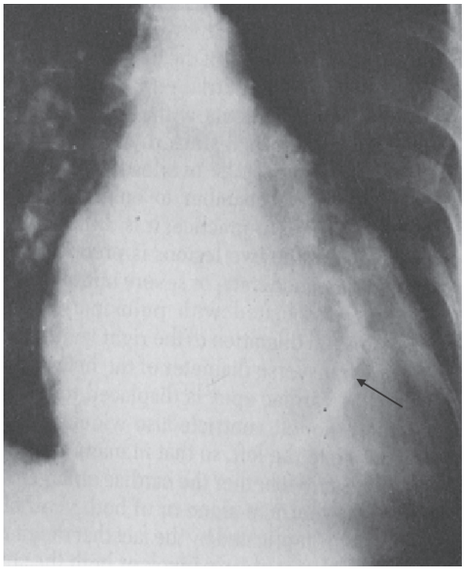

Fig. 16.5: Calcification of mitral annulus as indicated by broad and curved density (arrow) in chronic mitral valve disease

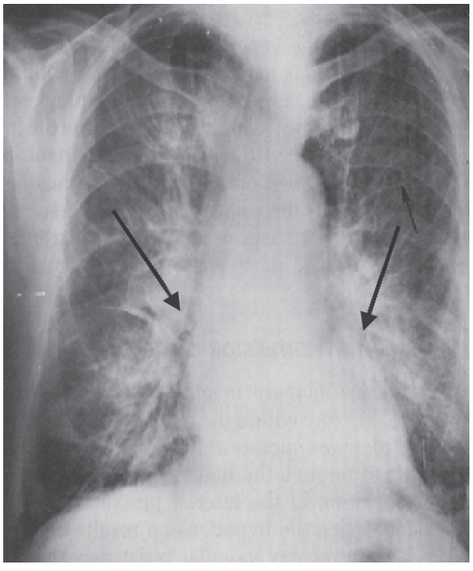

Fig. 16.6: Interstitial pulmonary edema as indicated by indistinct haze in the perihilar region (arrow) in a patient with critical mitral stenosis

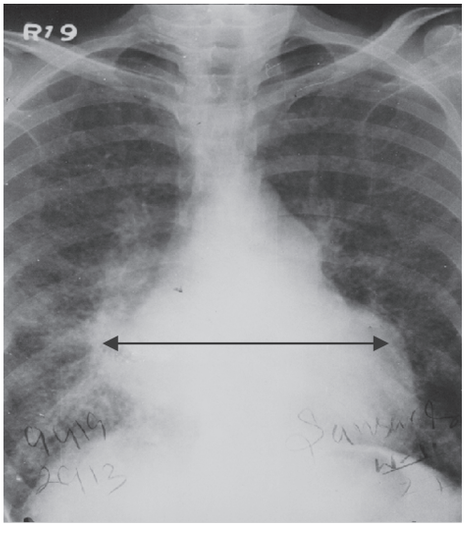

Fig. 16.7: X-ray chest PA view (arrow) showing moderate enlargement of RA in patient with rheumatic MS, TR and PAH

the chest lead V1. The main rhythm is usually sinus in the beginning. However, atrial fibrillation increases in frequency as mitral stenosis advances. If pulmonary arterial hypertension has developed, electrocardiography may show signs of RV hypertrophy (Fig. 16.8).

Echocardiography: Definitive diagnosis is made using of echocardiography when entire valve can be visualized Echocardiography, especially Doppler echocardiography, is the procedure of choice for evaluating the degree of mitral stenosis; in most of the patients, echocardiography may be adequate for the planning of therapeutic interventions. Echocardiography generally provides sufficiently detailed images of the mitral valve and is the most important diagnostic tool in establishing the diagnosis. Doppler echocardiography is used to accurately depict the severity of mitral stenosis. Typical two-dimensional (2D) echocardiographic findings include thickening of the mitral valve cusps; enlargement of the LA, with a normal or small LV; and a reduction in the size of the mitral valve orifice in diastole. A diminished E-F slope is noted on M-mode images. Doppler studies demonstrate an increase in the mean pressure gradient across the mitral orifice; Doppler studies are also helpful in quantifying the severity of mitral stenosis (Figs 16.9–16.14).

Computed Tomography

CT scans occasionally depict calcification in the enlarged LA in patients with mitral stenosis. It may be seen to occupy the wall of the atrium, or it may appear within a thrombus attached to the wall.

Whenever calcification is observed in the atrial appendage, it generally indicates associated mitral stenosis. Calcification in the wall of the atrium or in the appendage is usually considered an unfavorable prognostic sign.

When calcification in the atrium is suspected but is not positively identified on the chest radiograph, fluoroscopy or CT may be used to confirm the diagnosis. In the current era, CT scanning is rarely performed; rather, echocardiography has gained widespread use, owing to its portability and the fact that there is none of the risk associated with the use of radiation (Fig. 16.15).

Magnetic Resonance Imaging

For patients with mitral stenosis, MRI may be helpful if Doppler echocardiographic findings are insufficient or are inconsistent with clinical data. This problem occurs in

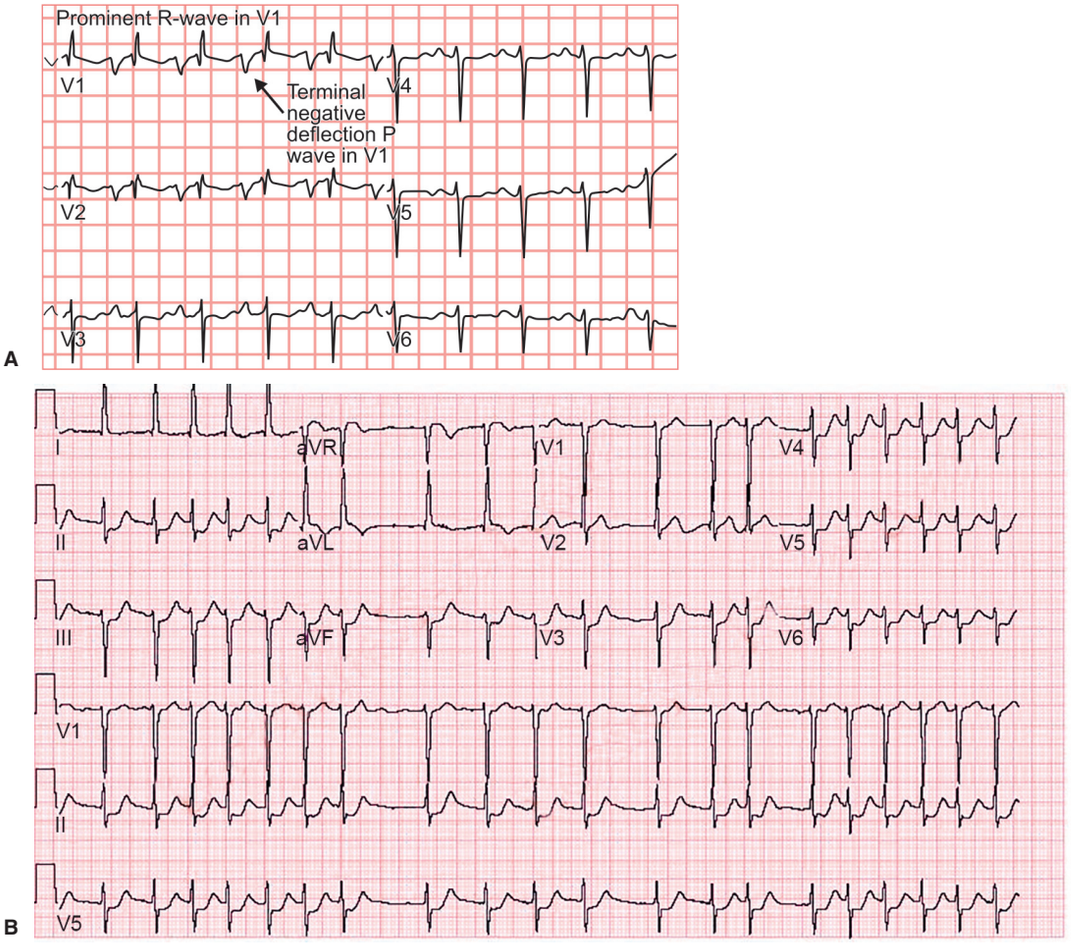

Fig. 16.8: (A) ECG trace shows terminal negative deflection of P-wave in V1 due to LA enlargement and right ventricular hypertrophy in a young patient with chronic mitral valvular stenosis. (B) Shows atrial fibrillation with rapid ventricular response in a pregnant women with severe type of mitral stenosis

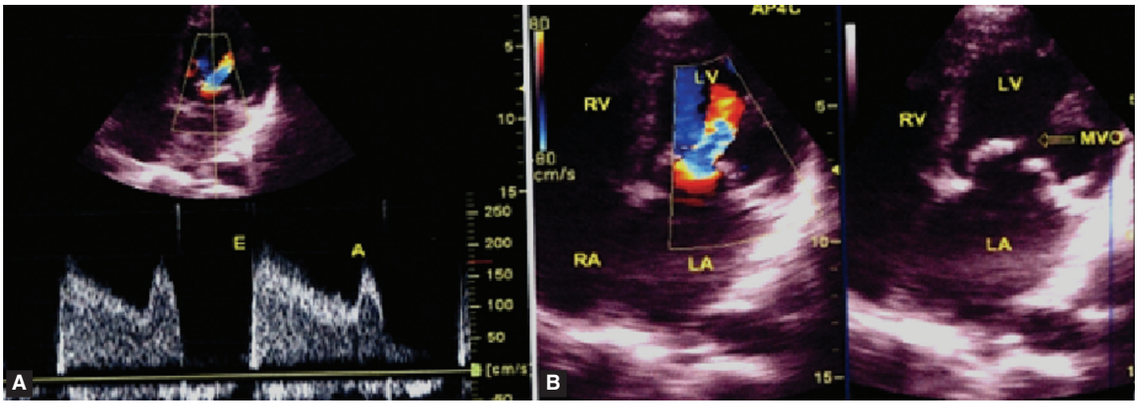

Fig. 16.9: (A) Pulse Doppler tracing with an early diastolic E-wave and a late diastolic A-wave (during atrial systole). In normal persons, there will be a gap between the two waves, when the atrial and ventricular diastolic pressures are equal (diastasis). Diastasis is absent in mitral stenosis as the pressures do not equalise—left atrial pressure is always higher and there is a gradient throughout diastole. Mitral valve area can be estimated from the downward slope of the E-wave. The slope becomes more flat as the severity of the mitral stenosis increases. The A-wave is absent in atrial fibrillation. (B) Two pictures, one with colour flow mapping and another without the color flow mapping. The colour flow mapping shows the turbulent flow from left atrium to left ventricle through the stenosed mitral valve. The domed mitral leaflets in the open position with a narrow orifice is visible in the frame without colour flow mapping. Both images are in the apical four chamber view. RA=right atrium; LA=left atrium; LV=left ventricle; RV=right ventricle; MVO=mitral valve orifice

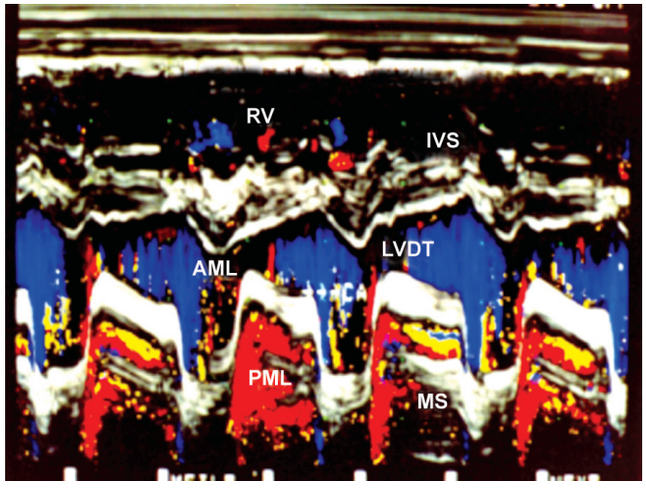

Fig. 16.10: Color flow M-mode showing markedly thickened anterior and posterior mitral leaflets with paradoxical movement of posterior leaflet in patient with rheumatic mitral native valvular stenosis alongwith dilated and hypertrophied RV

approximately 10% of patients because of air-tissue attenuation of ultrasound. MRI is often used in cases in which there is associated complex congenital heart disease because of its three-dimensional (3D) capabilities and high resolution (Fig. 16.16).

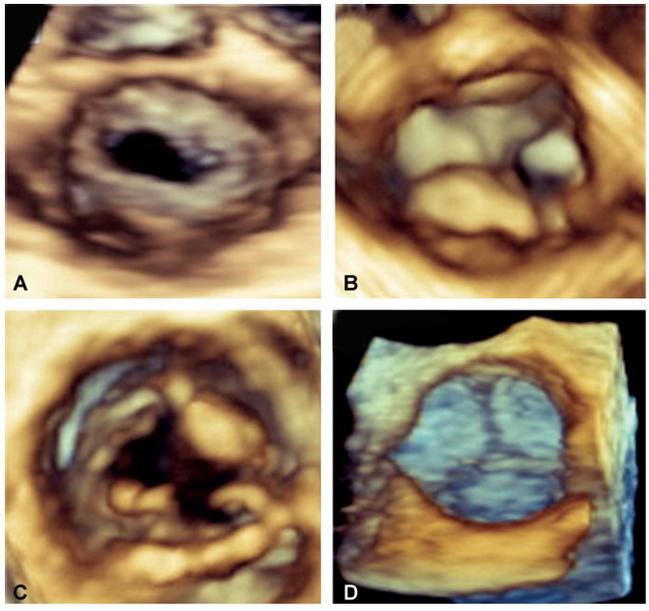

Fig. 16.11: Valvular anatomic features displayed by 3D TTE. Three-dimensional (3D) transthoracic echocardiography (TTE) images of (A) a stenotic rheumatic mitral valve from the left atrial perspective, (B) a mitral valve with P2 segmental prolapse from the left atrial perspective, (C) a normal tricuspid valve from the right ventricular perspective, and (D) a normal aortic valve as viewed from the aorta

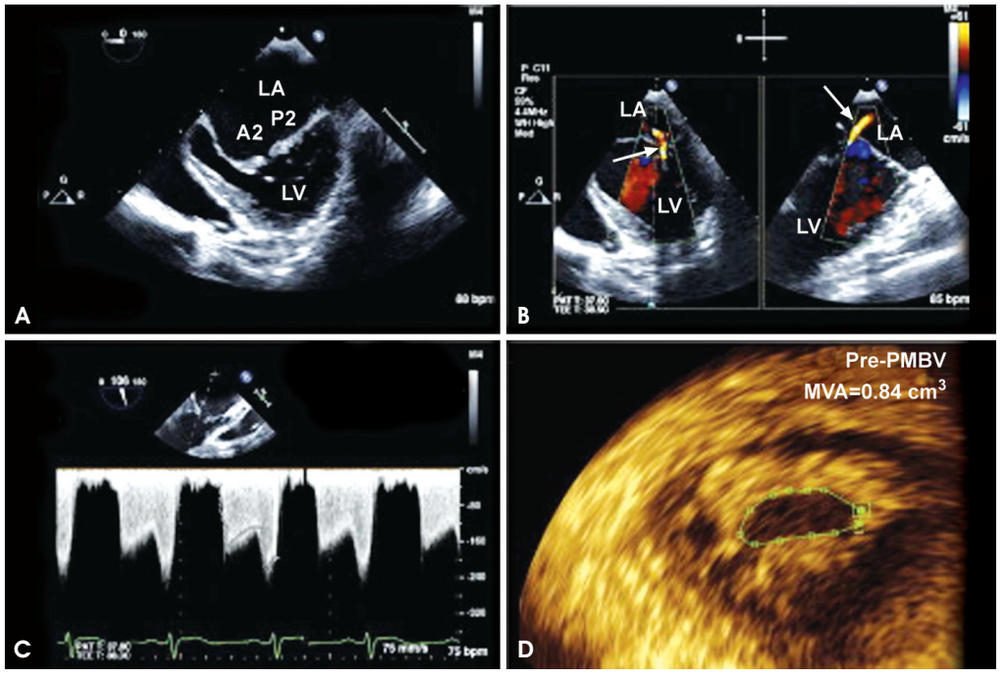

Fig. 16.12: Pre-procedural assessment of a stenotic MV by TEE. (A) Transesophageal echocardiography (TEE) at mid-esophageal level at 0° (4-chamber view). Note moderate bileaflet thickening involving the mid-distal segments of the mitral valve (MV) with reduced opening. (B) Simultaneous biplane imaging of the MV at the mid-esophageal level at 0° and 90° (right) with color-Doppler showing mild mitral regurgitation (arrow) at baseline. (C) Continuous-wave Doppler indicating increased transmitral gradients. (D) Real-time three-dimensional imaging with multiplanar reformatting showing a severely stenotic MV with important commissural fusion (MVA=0.84 cm^2). A2=middle anterior scallop; LA=left atrium; LV=left ventricle; MVA=mitral valve area; P2=middle posterior scallop; PMBV=percutaneous mitral balloon valvuloplasty

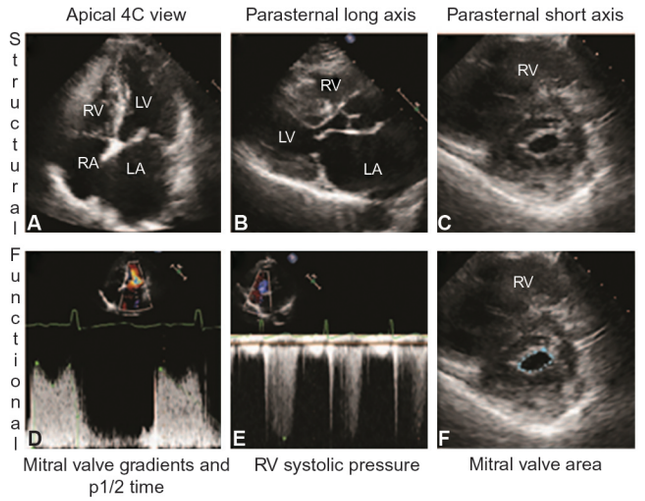

Fig. 16.13: Two-dimensional and Doppler echocardiography in mitral stenosis. Traditionally 2D echocardiography has provided structural information regarding the morphology of the mitral valve in mitral stenosis. In addition chamber size, and ventricular function is assessed by echocardiography. Doppler methods provide hemodynamic functional information regarding the mitral valve in mitral stenosis. Peak and mean mitral valve gradients, pressure half time derived mitral valve area and systolic pulmonary pressure are usually recorded in these patients. RV=right ventricle; LV=left ventricle; RA=right atrium; LA=left atrium

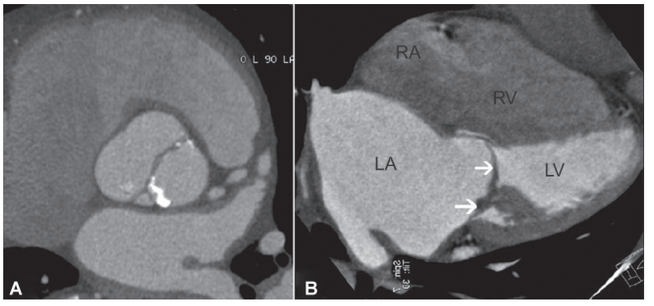

Fig. 16.15: Valvular lesions. Short-axis CT image (A) through the aortic valve shows a bicuspid valve, with calcification of the leaflet. Four-chamber reconstructed CT image. (B) Shows severe thickening of the mitral leaflets (arrows) in a patient with mitral stenosis with associated severe left atrial enlargement

MRI is of limited use in patients with atrial fibrillation, a common finding in mitral stenosis. Irregular rhythm may be a potential source of error in the measurements.

Cardiac Catheterization

Cardiac catheterization is usually unnecessary for assessing the severity of mitral stenosis. Nonetheless, coronary arteriography is performed in many patients with mitral stenosis who are in an age group in which there is a relatively high incidence of coronary disease and for whom heart surgery is anticipated or who have coexistent angina. In such cases, left- and right-sided heart catheterizations

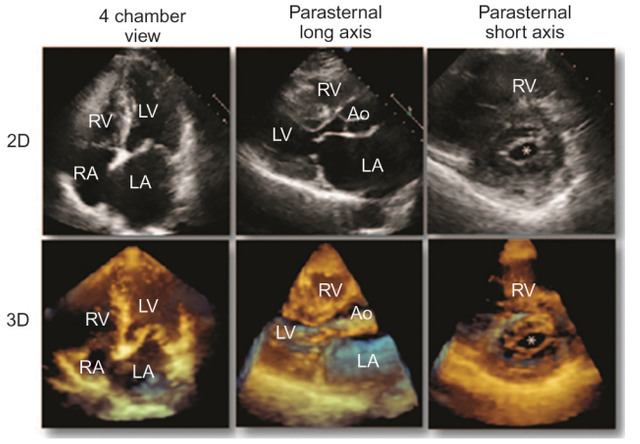

Fig. 16.14: Comparison of 2D and 3D transthoracic echocardiography in mitral stenosis. The most useful views to evaluate patients with mitral stenosis include the apical 4 chamber view as well as the parasternal long and short axis views. This figure illustrates the added value of 3D imaging in better characterizing the mitral valve apparatus. The third dimension increases the anatomic detail of the leaflets, commissures and subvalvular tissue. RV=right ventricle; LV=left ventricle; RA=right atrium; LA=left atrium; Ao=aorta

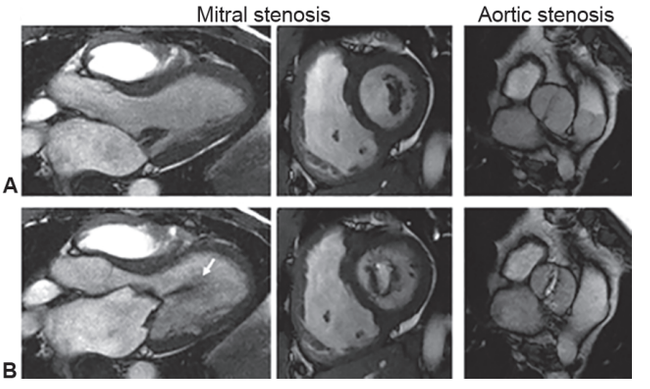

Fig. 16.16: SSFP images of abnormal mitral and aortic valves with the abnormal valve leaflets (A) closed and (B) at maximal opening. Rheumatic mitral stenosis is shown in the 3-chamber and short-axis image plane. Note significant thickening and calcification of both the mitral valve leaflets and chordae tendineae, along with chordal fusion, as well as severe left atrial enlargement. At maximal opening of the mitral valve leaflets, the signal void seen within the left ventricle represents turbulent diastolic filling of the left ventricle (arrow). A bicuspid aortic valve with significant aortic stenosis is shown in a short-axis image plane (MR images courtesy of Raymond J. Kim, MD, Duke Cardiovascular Magnetic Resonance Center, Durham, NC)

are performed to evaluate the coronary arteries, to confirm the transmitral gradient, and to determine the valve area. The valve area is determined by use of the Gorlin equation: Mitral valve area = [CO(DFP × HR)]/37.6 × h½), where CO is cardiac output (in milliliters per minute), DFP is the diastolic filling period, HR is the heart rate, and h is the mean gradient.

Management

Once symptoms develop in mitral stenosis, the chance of survival decreases without surgical or balloon dilatation or valve replacement. In the absence of symptoms, management is directed at preventing recurrence of rheumatic fever.

Medical Therapy

Patients in atrial fibrillation require heart-rate control with a beta-blocker (e.g. atenolol, 50 mg q.d.), digoxin (0.125–0.25 mg q.d.), or both. Systemic anticoagulation with warfarin is definitely indicated to prevent thromboembolism under the following situations when

1. Atrial fibrillation is present
2. There is a history of embolism, or
3. A thrombus is detected in the atrium.

Anticoagulation should be considered for patients with paroxysmal atrial fibrillation, a dilated left atrium (>50 mm in diameter on echocardiography), or severe atrial stasis (as evidenced by swirling echoes or smoke in the left atrium on echocardiography). Regarding symptomatic patients for whom surgical intervention poses a relatively high risk, the judicious use of diuretics and drugs to control heart rate (i.e. digoxin, calcium channel blockers, or beta-blockers) may allow symptomatic relief without the need for surgical intervention.

SURGICAL INTERVENTION

Intervention to increase valve area is indicated before the onset of symptoms of dyspnea in the following patients—women with severe stenosis who wish to become pregnant but are unlikely to tolerate the volume load of pregnancy, patients who experience recurrent thromboembolic events, and patients who have severe pulmonary hypertension. A number of interventions are currently available to increase the valve area in mitral stenosis. These interventions include:

1. Percutaneous balloon valvuloplasty performed in the cardiac catheterization laboratory
2. Surgical commissurotomy
3. Replacement of the mitral valve with a prosthesis.

1. Percutaneous Balloon Valvuloplasty

- Percutaneous balloon mitral valvulotomy—a balloon tipped catheter is threaded through an artery into the heart. The balloon is inflated to expand the mitral valve. This technique has been very effective in younger patients with valves that are not calcified (excessively stiff) (Figs 16.17–16.18).
- It is now usually performed under direct vision after cardiopulmonary bypass. Surgical commissurotomy may be feasible when balloon valvuloplasty is impossible, such as in patients with significant mitral regurgitation, subvalvular stenosis, or atrial thrombus. A number of studies comparing surgical commissurotomy with balloon commissurotomy have shown equivalent immediate and medium-term (3–4 years) results regarding increase in valve area, improvement in symptoms, and freedom from repeat intervention in appropriately selected patients. However, commissurotomy, whether effected by a balloon or surgically, is a palliative procedure, and in most cases further intervention is eventually required.
- Repeat commissurotomy is sometimes feasible; but most often, mitral valve replacement is also necessary is heavily scarred or calcified or if severe mitral regurgitation is present. Morbidity and mortality are higher with

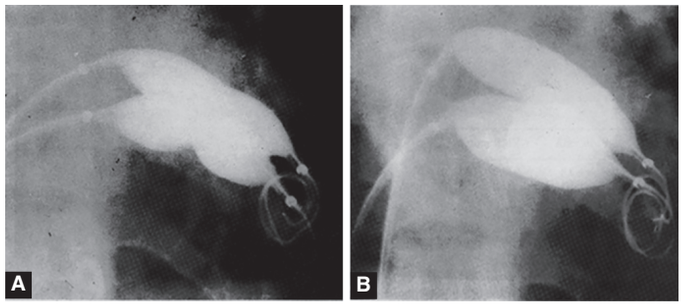

Fig. 16.17: (A) Double balloon across the mitral valve indicating the waist found by the stenotic valve. (B) Fully inflated balloon with disappearance of the waist as seen in (A)

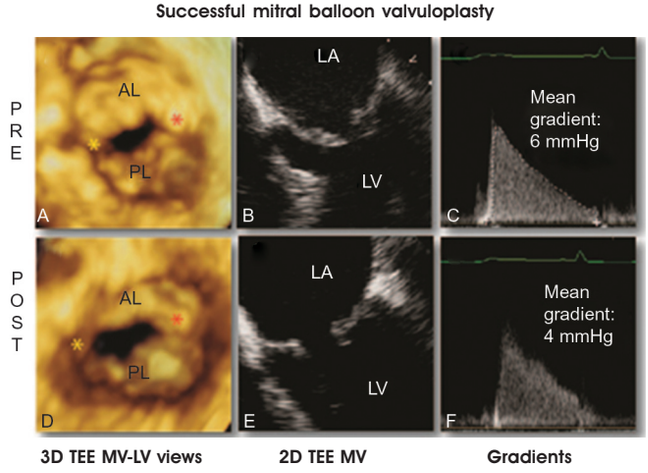

Fig. 16.18: (A) and (D) depict the mitral valve orifice as seen from the LV. Note the commissural fusion and the small mitral orifice in the pre-procedure image (A). In (D) the commissures are now split and the area of the mitral orifice has increased. (B) and (E) illustrate the 2D TEE views of the mitral valve pre- and post-procedure. Note the increased leaflet distance post-procedure. (C) and (F) illustrate the transmitral Doppler gradients pre- and post-procedure. The pre-procedure gradients had already diminished under general anesthesia and the post-procedure gradients showed only a mild drop despite good bi-commissural splitting. This is not uncommon to see in the immediate post-procedure studies and is probably related to decreased left atrial compliance, therefore to gauge procedural success; we rely mostly on the 3D visualization of the mitral orifice size and commissural splitting.Yellow asterisk-lateral commissure; red asterisk-medial commissure

prosthetic replacement than with either surgical or balloon commissurotomy.

- It is performed by inflating a specially designed balloon catheter in the mitral orifice to split the fused commissures. Excellent symptomatic relief is obtained in suitable patients. This intervention is currently the initial choice in mitral stenosis. Typically, the mitral valve area doubles in size from 1.0 to 2.0 cm^2, with a concomitant reduction in the pressure gradient.

Complications of balloon mitral valvuloplasty include:

1. Severe mitral regurgitation (3%)
2. Thromboembolism (3%),
3. Residual atrial septal defect with significant shunting (10–20%).
4. Mortality associated with the procedure is less than 1%.

Contraindications to balloon mitral valvuloplasty include significant mitral regurgitation, which will likely increase after balloon inflation; left atrial thrombus, which can be dislodged at the time of the procedure; and significant subvalvular involvement or leaflet calcification, each of which increases the risk of complications and limits the degree of dilatation produced.

2. Surgical Intervention

A. **Mitral valvulotomy (commissurotomy)** the natural valve is widened by making a cut in the mitral valve.

B. **Total valve replacement—the mitral valve is replaced by a prosthetic ('artificial') valve.** Valves may be either bioprosthetic (pig, cow, or human) or synthetic (usually metal alloys). Valvular replacement is usually required in older patients with heavily calcified (stiff) mitral valves (Fig. 16.19).

C. **Mitral valve repair:** Mitral valve repair is an open heart procedure performed by cardiothoracic surgeons to treat stenosis (narrowing) or regurgitation (leakage) of the mitral valve. The mitral valve is the 'inflow valve' for the left side of the heart. Blood flows from the lungs, where it picks up oxygen, and into the left atrium (Fig. 16.20).

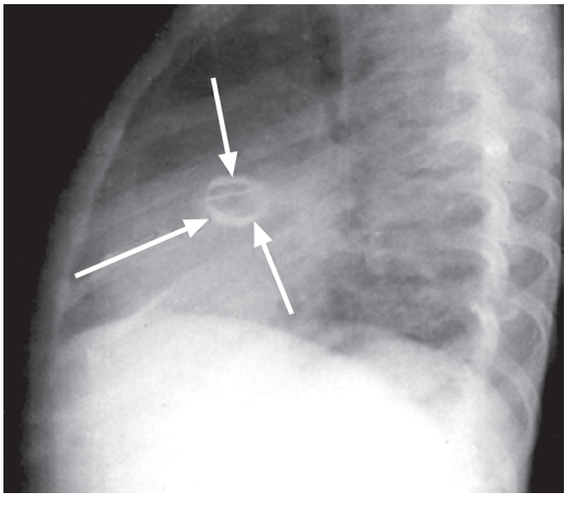

Fig. 16.19: Anatomical location of Bjork Shilley mitral valve visualised in lateral position of X-ray chest PA view with mitral valve replacement in a patient with calcified native mitral valve

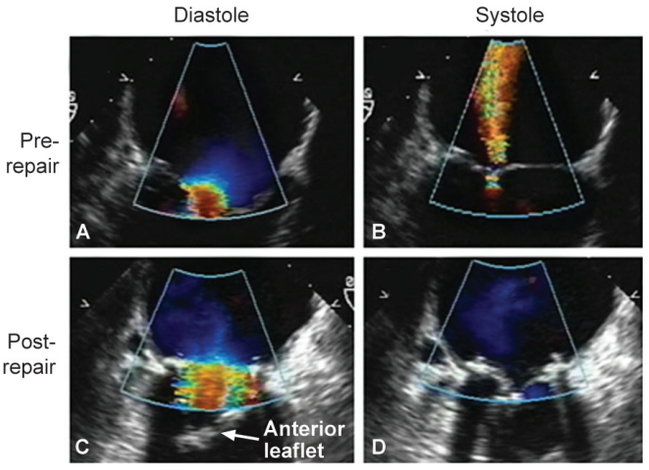

Fig. 16.20: A patient with long-standing rheumatic mitral stenosis and regurgitation undergoing a rheumatic repair. (A and B) on pre-bypass echo, the stenotic and insufficient mitral valve is demonstrated. (C and D) after insertion of an autologous pericardial patch into the posterior leaflet, decalcifying commissurotomy, resection of the submitral apparatus to the anterior leaflet, and re-attachment of the mobile anterior leaflet to both papillary muscles with adjustable ACR, the valve is fully competent with insignificant gradient. A full rigid ring also is placed (AnnuloFlow, Sorin Group). These types of more comprehensive ACR repairs for rheumatic valves have been quite stable in the intermediate term

Prognosis

Most people have no symptoms for the first 10 years, increasing shortness of breath on exertion for the next 10 years followed by worsening symptoms that may begin to occur at rest during the next decade.

All people having mitral stenosis of any degree require antibiotic prophylaxis to prevent infective endocarditis prior to dental or surgical procedures.

MITRAL REGURGITATION

It occurs when blood flows back into the left atrium from the left ventricle during left ventricular contraction because of a 'leaky' mitral valve. Mitral regurgitation can occur acutely (suddenly) with infective endocarditis or with a heart attack that causes rupture of the papillary muscles or chordae tendineae. Symptoms of severe congestive heart failure (severe shortness of breath, fast heart rate, and fluid in the lungs) requiring urgent surgical intervention usually occur with acute mitral valve rupture.

Rheumatic fever is the most common cause of chronic (gradual over many years) mitral regurgitation. Chronic regurgitation, even with large regurgitant blood flow, is often tolerated for years due to compensatory changes in the heart. The left atrium dilates over time to handle the increased blood volume.

Aetiology

- Mitral regurgitation (acute)
- Ruptured papillary muscle (infarction, trauma)
- Papillary muscle dysfunction (ischemia)
- Ruptured chordae tendineae (trauma, endocarditis and myxomatous)
- Valve perforation (endocarditis)
- Weight-loss medications (fenfluramine, dexfenfluramine)

Signs and Symptoms

Signs and symptoms of mitral regurgitation are as follows:

- Acute pulmonary edema
- Jugular venous pressure (JVP) exhibits cannon A waves and giant V-waves.
- Harsh blowing apical crescendo-decrescendo murmur radiating to the axilla
- Palpable thrill at apex
- S3 and S4
- Palpitations
- Atrial fibrillation
- Dyspnea
- Orthopnea
- Nocturnal paroxysmal dyspnea
- Peripheral edema
- Systemic emboli
- Normal JVP
- Left ventricular hypertrophy (LVH)
- Apical high-pitched pansystolic murmur
- Decreased or obscured S1
- Widely split S2 sound
- S3 sound

Diagnosis of Mitral Regurgitation

Clinical Manifestations

In most patients, mitral regurgitation remains asymptomatic for many years. Dyspnea, fatigue from low cardiac output, and edema occur late in the course of the disease. Mitral regurgitation is recognized clinically by a systolic murmur at the apex, radiating to the axilla and increasing on expiration. In patients with a posteriorly directed jet of mitral regurgitation, the murmur is heard well at the back. In more severe cases, the murmur lasts throughout systole, the first and second heart sounds are soft or difficult to hear, and a third heart sound is present. A midsystolic click can be present in myxomatous disease; in less severe cases, this click can precede the murmur. The murmur can also be confined to late systole, with papillary muscle dysfunction. Mitral regurgitant murmurs caused by ischemia can be variable in duration and intensity, depending on the degree of ischemia and the loading conditions.

Imaging Studies

1. **2D and 2D Doppler echocardiography:** Doppler echocardiography is the noninvasive method of choice in confirming the presence of mitral regurgitation. Echocardiography is used to diagnose the mechanism of the regurgitation (e.g. prolapse or annular dilatation); color-flow mapping is used to provide a semi-quantitative assessment of severity based on the size and penetration of the left atrium by the regurgitant jet. Additionally, echocardiography can be used to assess the effects of the regurgitation on left ventricular size and function. Quantitative measurements of regurgitation, such as the regurgitant volume, regurgitant fraction [(regurgitant volume) plus stroke volume) divided by regurgitant volume)], and regurgitant orifice area (the area through which the valve leaks), are now possible with newer Doppler techniques. These techniques are useful in determining the true severity of the lesion and following it over time. Left ventricular size and volume, as well as contractile function assessed by the ejection fraction, are used to determine the need for surgical intervention (Figs 16.21–16.23).

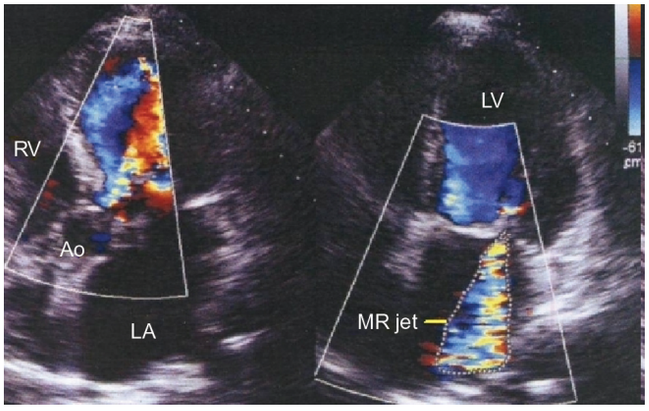

Fig. 16.21: 2D color-Doppler echocardiogram in RHD, showing moderate mitral regurgitation

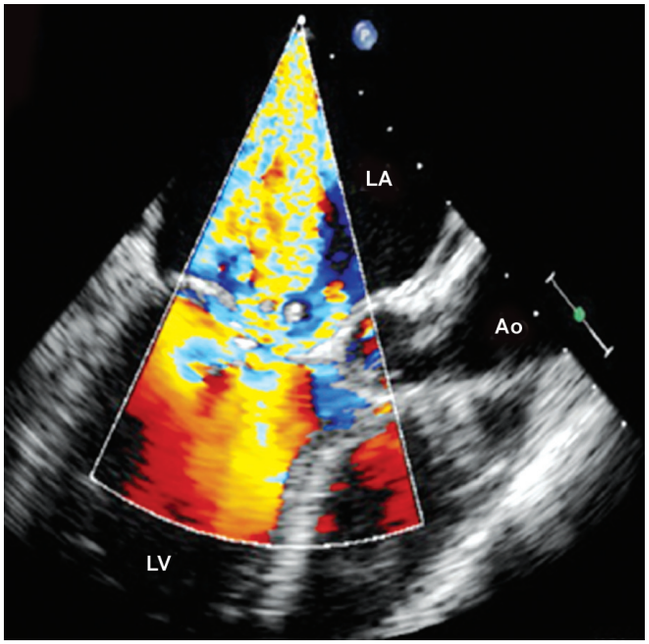

Fig. 16.22: Color-Doppler imaging in 4C view reveals severe mitral regurgitation. LA=left atrium; LV=left ventricle; Ao=aorta

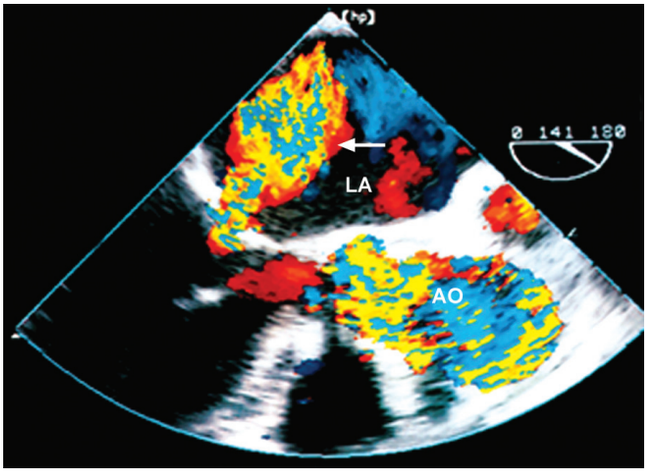

Fig. 16.23: Transesophageal echocardiography image (three-chamber plane) demonstrating a jet of mitral regurgitation (arrow) in the left atrium (LA). Ao=aorta; LV=left ventricle

However, asymptomatic mitral regurgitation is more difficult to assess and manage than other valvular lesions because in this condition, the true contractile function of the left ventricle is difficult to determine with conventional measures such as the ejection fraction. These measurements of contractility are confounded by the increase in ventricular preload caused by the extra volume of blood in the left atrium and the variable effect on afterload. Afterload is increased by left ventricular dilatation, but this effect is offset as the ventricle ejects much of its blood into a relatively low pressure system (the left atrium). The left ventricular ejection fraction can appear falsely elevated in mitral regurgitation and usually falls after surgical correction. An ejection fraction of less than 60% should be considered abnormally low in patients with mitral regurgitation.

2. **Transesophageal echocardiography** is very sensitive in the detection of mitral regurgitation and is used mainly in those patients who are difficult to evaluate by the transthoracic approach. Contrast ventriculography is used to determine the severity of mitral regurgitation in patients undergoing cardiac catheterization. This procedure involves injecting radiopaque contrast medium into the left ventricle and assessing the extent and duration of opacification of the left atrium. In patients undergoing hemodynamic monitoring, large systolic V waves on the pulmonary arterial wedge tracing raise the suspicion of acute severe mitral regurgitation, as can occur in acute ischemia, but such V waves can occur in the absence of severe regurgitation.
3. **Stress echocardiography** is useful in detecting latent left ventricular dysfunction not evident on a resting study. Failure of the left ventricular ejection fraction to increase on exercise or of the left ventricular end-systolic volume to decrease on exercise is predictive of incipient left ventricular dysfunction and should be considered an indication for early surgery.
4. **Other echocardiographic indices** that have been associated with a less favorable surgical outcome include an absolute end-systolic dimension that is greater than 4.5 cm or that is greater than 2.6 cm/m^2 when indexed for body surface area; an end-systolic volume of greater than 50 ml/m^2; and a resting ejection fraction of less than 60%. Surgical referral should be considered if ventricular size and function approach these indices. Serial echocardiographic evaluation should be performed at least yearly and should be performed more frequently as ventricular dilatation progresses in patients with severe asymptomatic mitral regurgitation. Studies indicate a better long-term survival rate in patients with severe mitral regurgitation when surgery is performed early. Symptomatic severe mitral regurgitation is considered an indication for surgical intervention if the valve is primarily involved.

Management of mitral regurgitation: In the management of asymptomatic mitral regurgitation, it should be borne in mind that left ventricular dysfunction is often latent and that, once present, the dysfunction cannot be corrected by operative intervention. Therefore, it is important to refer patients for surgery before the onset of true left ventricular dysfunction even in the absence of symptoms. Unfortunately, no load-independent measure of contractile function is readily available. In order to manage mitral regurgitation, one should always differentiate between acute and chronic MR.

Acute:

- Afterload reduction (nitroglycerin, morphine, or sodium nitroprusside)
- Diuresis
- Intra-aortic balloon pump (temporizing for urgent surgery)

Chronic:

- Diuresis
- Nitrates
- Hydralazine
- ACE inhibitor
- Digoxin
- Adrenergic blocker (ventricular rate control)
- Calcium antagonist (ventricular rate control)
- Heparin (if atrial fibrillation)
- Endocarditis
- Endocarditis prophylaxis/education

Surgical Intervention

- Decisions in regard to the treatment of acute mitral regurgitation are strongly influenced by the cause of the regurgitation. In 1 series, the causes were acute MI in 45% of cases, degenerative valvular disease in 26%, and infective endocarditis in 28%. Although the technical treatment of the mitral valve may be similar, each cause requires a different approach and has a different outcome. Furthermore, unlike aortic regurgitation—wherein repair is rarely possible—mitral regurgitation can be treated by means of repair or replacement.

- Adequate surgical exposure of the mitral valve is crucial. Exposure is often difficult when regurgitation is acute and the left atrium is not dilated; therefore, surgery must be approached carefully. Expeditious use of CPB, optimal myocardial protection, and excellent valve exposure yield the best results. The intraoperative approach to the mitral valve is also crucial, a variety of techniques should be considered, particularly when endocarditis affects multiple structures or the annulus, or when extensive annular reconstruction is needed. Approaches include a lateral Sondergaard incision in the groove in the left atrium, transatrial incisions, left atrial dome incisions, or transection of the superior vena cava with a more anterolateral approach to the left atrium. This last is particularly useful when endocarditis is noticeably destructive and more extensive annular reconstruction is required. Although median sternotomy is typical, experienced surgeons can execute less invasive approaches.
- Symptomatic patients with ischemic mitral regurgitation often require mitral valve surgery in addition to revascularization. Mitral regurgitation secondary to left ventricular dilatation often improves with afterload reduction, and surgical intervention is not usually indicated. Patients with moderately severe left ventricular dysfunction (ejection fraction <35%) and significant mitral regurgitation were thought in the past to be poor surgical candidates because of high operative risk. However, recent research has shown that there is acceptable risk associated with operations in these patients. Symptoms usually improve, but a survival benefit associated with surgery in this group has not yet been shown. Patients who are not considered suitable for surgery because of left ventricular dysfunction often benefit from afterload reduction and diuretics. However, in patients who have primary asymptomatic mitral regurgitation with preserved left ventricular function, afterload reduction has not been shown to delay surgery or improve left ventricular function in the few small studies that have addressed this issue; afterload reduction is not currently recommended to treat such patients. Afterload reduction is beneficial for stabilizing patients with hemodynamically significant acute mitral regurgitation in preparation for surgery. Mitral valve repair is currently the technique of choice in the surgical management of mitral regurgitation because the operative mortality is lower, ventricular function is better preserved, and long-term complications such as thromboembolism and infection are lower with repair than with replacement. Valve repair is most likely to be feasible in patients with myxomatous disease, especially if such disease involves the posterior leaflet, and is least likely to be successful in patients with rheumatic disease and endocarditis. Valve repair is accomplished by use of a variety of techniques, depending on the mechanism and aetiology of the regurgitation. Such techniques include partial leaflet resection, chordal shortening or transfer, and insertion of an annuloplasty ring to reduce the size of the annulus. Long-term failure of repair occurs at a rate of 1–2% a year, but is higher in patients with rheumatic disease. If mitral valve repair is not possible, a mitral prosthesis is implanted. Chordal and papillary muscle preservation is increasingly being employed when a mitral prosthesis is inserted, because preserving the muscles has been shown to help conserve left ventricular function after surgery.
- Organic causes of mitral regurgitation are managed similarly to those of acute aortic regurgitation. Supportive therapy can provide patients with stability and resuscitation en route to the operating room. The use of IABPs can be beneficial. In organic mitral regurgitation, the fundamental abnormality is structural and therefore requires surgical intervention. In functional mitral regurgitation, medical therapy may be sufficient to avoid immediate operative intervention; however, surgery should be considered if therapy fails.
- In patients with acute functional mitral regurgitation, therapy is directed at restoring blood flow to the territory at risk. Severe mitral regurgitation affects 7% of patients who experience cardiogenic shock. Acute mitral regurgitation in these patients is a sign of a poor prognosis: an observed mortality rate of 55% improved to only 39% in patients who were selected for emergency surgery. The SHOCK trial determined that early revascularization improved outcomes at 6 months in patients with cardiogenic shock and acute MI. Upon further analysis, the prognostic importance of mitral regurgitation to the short- and long-term survival of such patients was inversely related to the degree of regurgitation. This suggests that aggressive treatment with early revascularization may improve survival in patients with severe mitral regurgitation after acute MI. Therefore, if revascularization is needed, the presence of severe mitral regurgitation should prompt surgical intervention.
- Acute mitral regurgitation in the presence of acute cardiomyopathy or decompensated heart failure can respond to aggressive heart-failure therapy. The use of IABPs is effective in patients with acute functional mitral regurgitation of any cause, and IABPs are particularly useful in patients with underlying myocardial ischemia or cardiomyopathy. Although the role of LV assist devices has not been well studied in acute mitral regurgitation, these devices may be used in cases of decompensated heart failure that does not respond to medical therapy.
- Valvular thrombosis that results in acute regurgitation sometimes responds to thrombolytic therapy. However, in patients whose prosthetic valve dysfunction is severe and symptomatic, the ACC/AHA and ESC guidelines recommend surgery first. Thrombolytic agents should be reserved to treat patients who have confirmed valvular thrombosis when surgery is risky or unavailable, or when the thrombus burden is small and the patient has few symptoms.

Anesthetic Considerations

Patients with acute mitral regurgitation can experience acute cardiopulmonary collapse at any time; however, the instability of their condition may not be as clear as it is in patients with acute aortic regurgitation. The surgical team should be present during the induction of anesthesia, in case CPB is urgently needed. Acute mitral regurgitation from profound, ongoing myocardial ischemia often requires additional anesthetic techniques that will optimize myocardial oxygen supply and demand, preload and afterload, and coronary perfusion pressure. The preoperative placement of an IABP can improve coronary perfusion and mitigate the effects of anesthetic induction

Mitral valve repair: It is almost always preferable to replacement. Therapeutic options, technical feasibility, and surgical priorities depend upon cause, acute pathophysiology, underlying pathology, and comorbidities. If the initial repair is unsatisfactory, further CPB and either repeat repair or valve replacement is necessary. Repair should therefore be undertaken when procedural success is likely, because a hemodynamically unstable patient might not be able to tolerate additional CPB. Influential factors include papillary muscle rupture; chordal rupture; annular dilation; hibernating, stunned, or infarcted myocardium; and the severity of coronary artery disease. Repair techniques include ring annuloplasty, annular reconstruction with pericardium, leaflet resection, leaflet reconstruction with pericardium, chordal replacement, vegetation excision, and edge-to-edge (Alfieri) approximation. Valve repair is more usual when acute annular dilation is the cause, such as in ischemia, or when the pathology involves the posterior leaflet only, such as in myxomatous valve disease or endocarditis with or without annular dilation. In annular involvement with infection or in anterior leaflet involvement with degenerative disease, the ability to repair the mitral valve dramatically decreases (Figs 16.24–16.28).

- Having to replace a mitral valve after an unsuccessful repair should not be viewed as a failure. Patients with acute regurgitation are less likely to tolerate repeat exploration and repair. The loss of tolerance is more pronounced after a complex, time-consuming repair attempt, as in cases involving tissue destruction due to endocarditis. Frequently, annular involvement precludes simple repair with predictably good initial results.
- In valve replacement, adequate débridement can avoid periprosthetic leaks due to inadequate visualization, poor tissue quality, or an undrained abscess. Preservation of the posterior and anterior chordae tendineae is ideal, because the LV has not adapted as in chronic regurgitation. Either a mechanical valve or a bioprosthesis can be used in cases of degenerative, ischemic, or infectious disease. Mechanical prostheses are

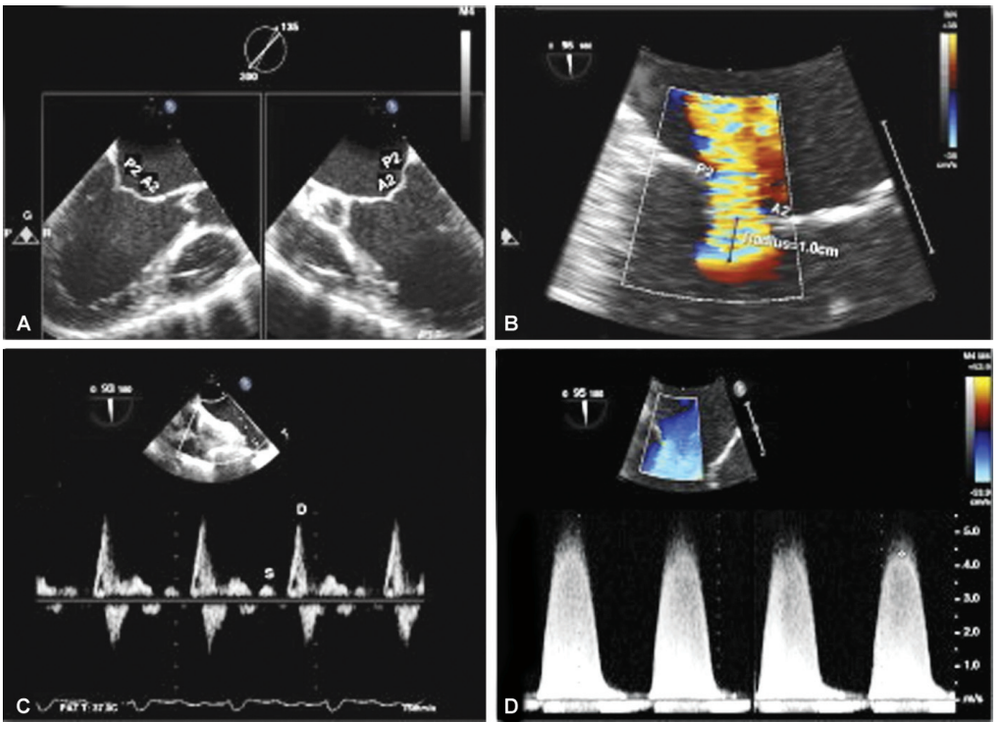

Fig. 16.24: TEE assessment of MV morphology, regurgitation mechanism, and quantification. (A) Two-dimensional TEE at mid-esophageal level 0° using real-time biplane imaging with orthogonal planes showing functional MR with MV annular dilation and leaflet tethering leading to central malcoaptation between A2 and P2 scallops, (B) Mid-esophageal zoomed view at 95° of the MV with color-Doppler showing systolic frame representing severe central mitral regurgitation jet. Note the proximal flow convergence zone with large radius (1.0 cm). (C) Pulse-wave Doppler interrogation of the right upper pulmonary vein flow showing marked systolic blunting (S) indicative of elevated LA pressures. (D) Continuous-wave Doppler through the MV, which demonstrates a dense holosystolic regurgitant jet with high peak velocity. All these features are consistent with severe MR

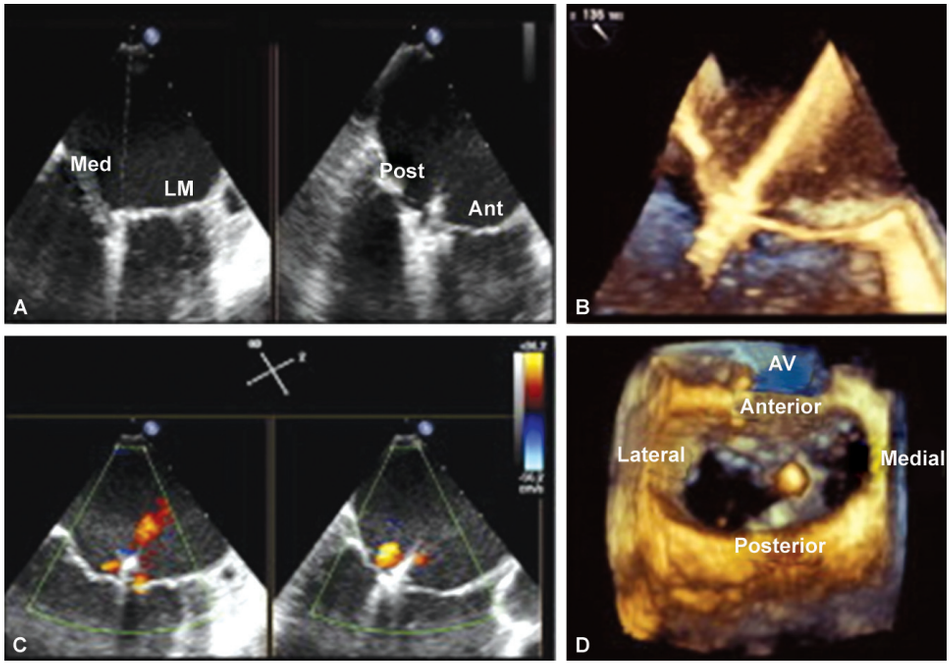

Fig. 16.25: Sequence of events in the deployment of edge-to-edge MV repair technique (MitraClip). (A) Simultaneous biplane imaging at 60° and 150° demonstrates the exact location of the MitraClip within the MV structure. Once the position is confirmed, grasping of the MV leaflet occurs, (B) live 3D zoomed view of the delivery catheter and MitraClip grasping the A2 and P2 scallops of the MV, (C) similar to A, simultaneous biplane imaging at 60° and 150° demonstrates trivial to mild (1+) MR after MitraClip grasps the MV leaflets, (D) MitraClip system is finally released from the delivery system and seen (arrow) in the center of the new 'figure-of-8' MV. Ant=anterior; Post=posterior

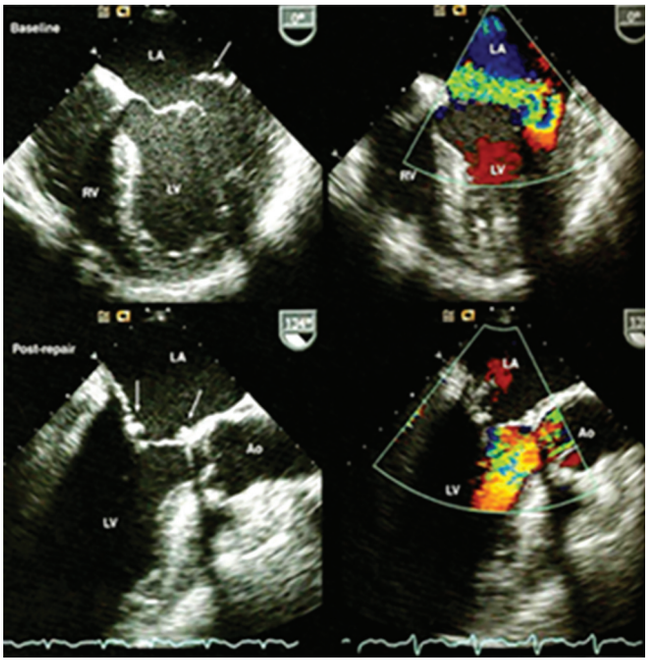

Fig. 16.26: Mitral valve repair. 2D (left) and color-Doppler (right) intraoperative TEE images were taken in a patient with myxomatous mitral valve defect before (top) and after (bottom) mitral valve repair, before repair severe mitral prolapse with partial flail leaflet segment and moderate to severe MR in the four chamber view. After repair, the long axis view shows the annuloplasty ring (arrows). Regurgitation was not detected after successful repair

often preferred because of their durability, low profile, and ease of insertion.

Ischemic Mitral Regurgitation

Ischemic mitral regurgitation is caused by wall-motion abnormalities that in turn cause tethering, papillary muscle dysfunction, or annular dilation. In myocardial ischemia, revascularization is mandatory. Cardiac catheterization is important in the evaluation and stabilization of patients who present with an acute coronary syndrome, with or without cardiogenic shock (Fig. 16.29).

Careful review of the preoperative coronary angiograms is essential during preparation for coronary artery bypass grafting (CABG). In patients who are hemodynamically unstable, too much time may be needed to prepare the internal mammary artery, and CABG might be best completed with the use of venous conduits. In addition, myocardial protection in the presence of acute MI is challenging. Either antegrade or retrograde delivery of cardioplegic solution is feasible; antegrade delivery through the newly placed venous conduits can increase myocardial protection. In contrast, particularly when ischemia is acute, the metabolically enhanced, slow induction of warm-blood cardioplegic solution can avoid systolic contracture of the LV ('stone heart' syndrome).

- Controlled and potentially prolonged reperfusion at the conclusion of the operation may enable the recovery of myocardial function. For the same purpose, intra-aortic balloon counterpulsation is typically maintained for at

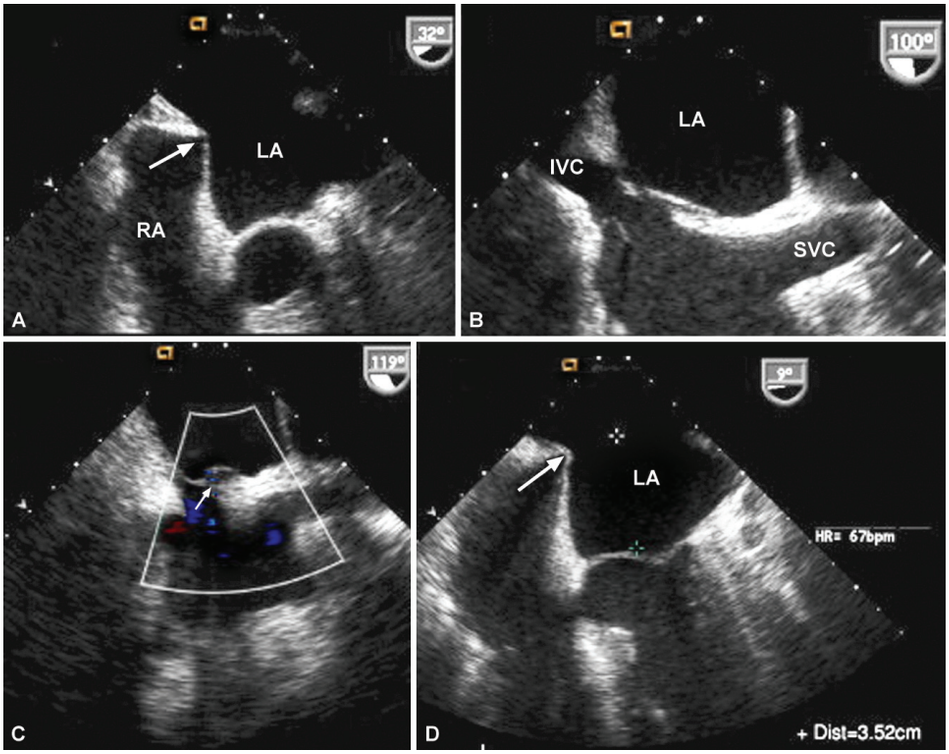

Fig. 16.27: TEE during initial stages of percutaneous MV repair by Evalve clip mid-esophageal transesophageal views used for guided transseptal puncture during percutaneous edge to edge MV repair. (A) Short-axis view at the base (showing the anterior–posterior portion of the interatrial septum with tenting (white arrow) at the junction of septum primum with septum secundum or the edge of the fossa, (B) Bicaval view showing the superior–inferior portion of the interatrial septum, (C) Bicaval view with tenting at the junction of ostium primum with ostium secundum (white arrow), (D) Mid-esophageal 4-chamber view (for assessing height of the tenting site above the MV plane) to allow perpendicular approach of the guide and device catheter towards the MV. IVC=inferior vena cava; SVC=superior vena cava

least 24 hours postoperatively. Papillary muscle rupture, a rare complication of MI, occurs in 1–3% of MIs and is associated with a mortality rate of 80% with medical therapy alone. Historically, operative mortality rates were as high as 67%, and patients were frequently denied surgery for this reason. With the addition of CABG to mitral valve replacement or repair, the operative mortality rate is now less than 10%.

Mitral Valve Endocarditis

- Acute mitral valve regurgitation consequent to endocarditis requires operative debridement and reconstruction. The therapeutic approach is driven by the principle that all sites of active infection must be excised. The decision to repair the leaflet, to replace the chordae or the entire valve, or to reconstruct the annulus is best made after debridement. It can be especially challenging to reconstruct the fibrous trigone of the heart, which involves the annular support of both the aortic and mitral valves. The tissues are edematous and friable, and even the most experienced surgeon may find it difficult to achieve a 3-dimensional view. The use of aortic homografts may be optimal when both the mitral and aortic annuli show active infection or abscess. Repeat mitral valve surgery, such as in prosthetic valve endocarditis, poses a unique challenge. Even gentle manipulation of the mitral annulus, coupled with ongoing infection and previous scarring, can result in atrioventricular disruption. This catastrophic event is high-risk and must be anticipated. All people having mitral regurgitation require antibiotic prophylaxis to prevent infective endocarditis prior to dental or surgical procedures.

MITRAL VALVE PROLAPSE (CLICK MURMUR SYNDROME)

It is a condition that has caused much debate and controversy in the medical community. Mitral valve prolapse (MVP) occurs when one or both of the mitral valve leaflets push back (bow) into the left atrium during contraction of the left ventricle. MVP is probably only important if a person has both excess bowing of the mitral leaflets into the atrium and actual regurgitation of blood from the left ventricle to the left atrium when the heart contracts (Figs 16.30–16.32).

People, particularly women, with heart palpitations due to anxiety often see a doctor and have heart evaluation (including ultrasound) performed. Many persons with a panic (anxiety) disorder were found to have mild mitral valve bowing on ultrasound. It was believed that panic attacks were more common in people with mitral valve

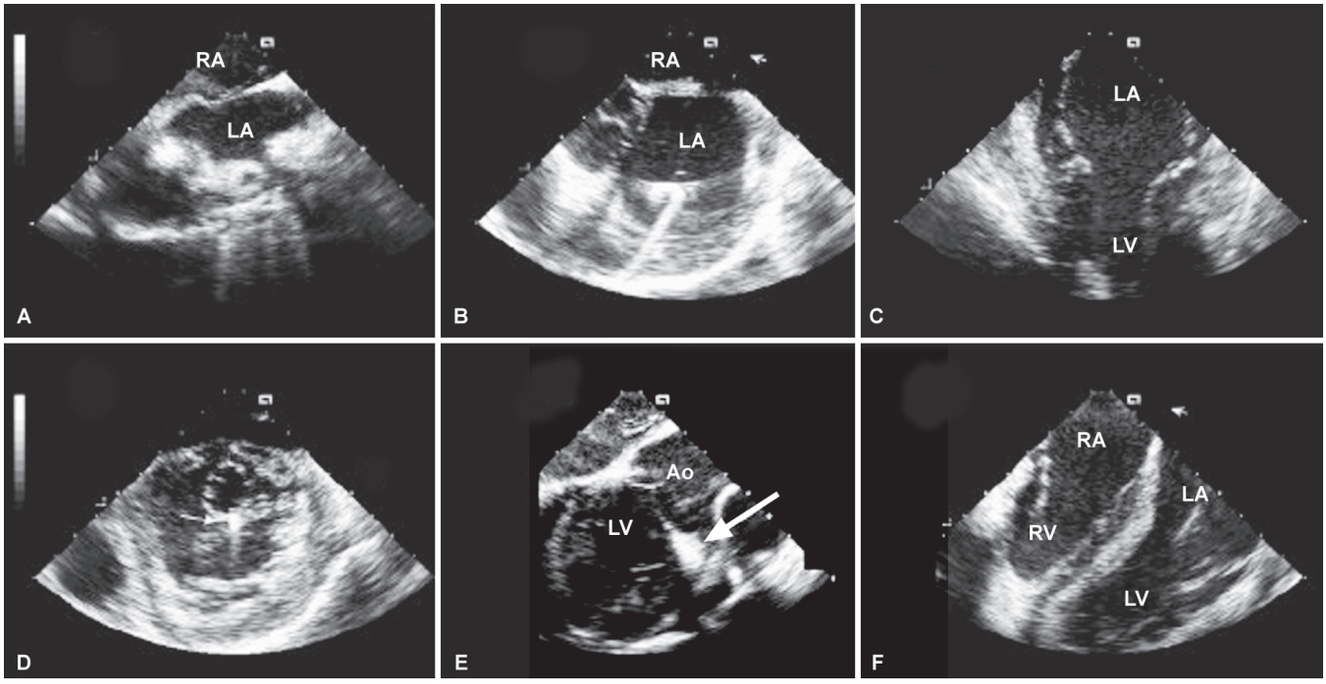

Fig. 16.28: Intracardiac echocardiography during percutaneous MV therapy. Intracardiac views obtained by Acunav catheter in the right atrium of a swine. (A) Tenting of the interatrial septum (white arrow) by the Brockenbrough needle. (B) J-shaped tip of guidewire in the LA after transseptal puncture. (C) Anterior and posterior leaflets of the MV with the ICE catheter advanced across the interatrial septum into the LA and the transducer facing down. (D) A short-axis view of the MV at the base with a central suture and clip (white arrow) and a double orifice MV created after the deployment of suture and clip (Edwards Lifesciences, Irvine, California). The SAX view was obtained by advancing the ICE catheter across the tricuspid and pulmonic valves. (E) Aortic root, left main coronary artery (white arrow), and LV, and F is a 4-chamber view obtained by advancing the ICE catheter tip into the right ventricle

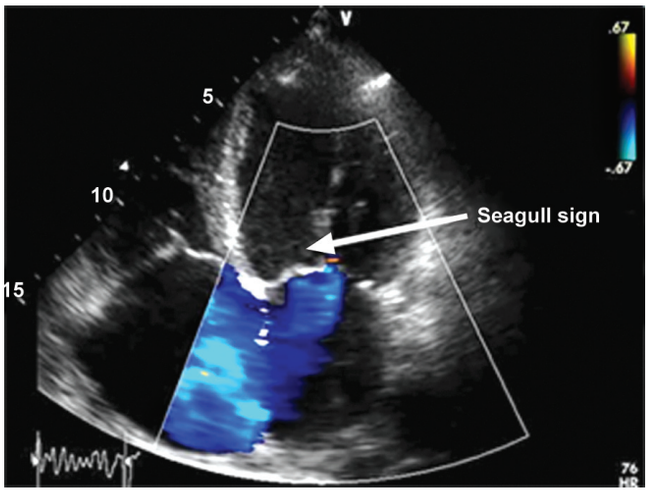

Fig. 16.29: 'Seagull sign' on transthoracic echocardiography of moderate-severe ischemic mitral regurgitation (IMR). A transthoracic echocardiographic image demonstrating the 'seagull sign' present in moderate-severe IMR. The shape of the anterior mitral valve leaflet is distorted by tethering of secondary strut chordae tendineae. This tethering impairs leaflet coaptation resulting in MR

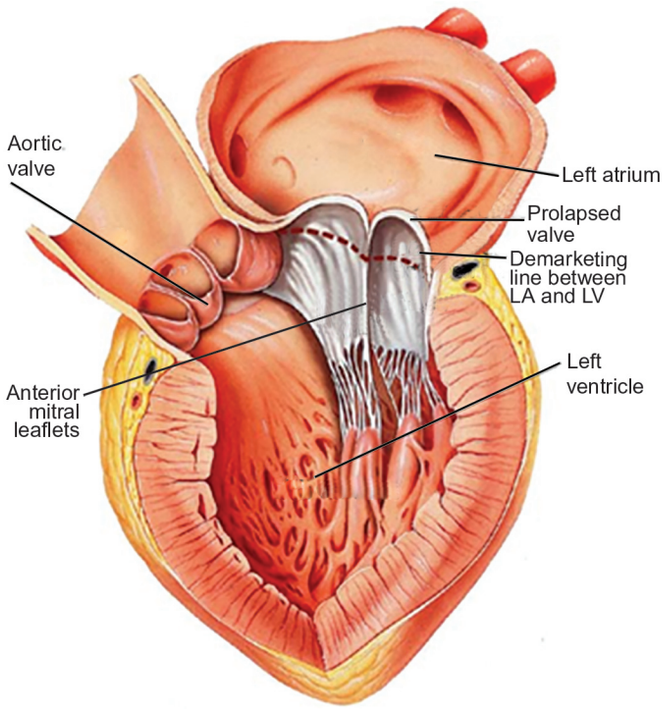

Fig. 16.30: A normal demarkating line between LA and LV with mitral valve that separates the left atrium from the left ventricle. It also shows mitral valve prolapsing into the LA

prolapse. Newer studies suggest there is no correlation between panic attacks and mitral valve prolapse. Most patients who had ultrasounds and were diagnosed with

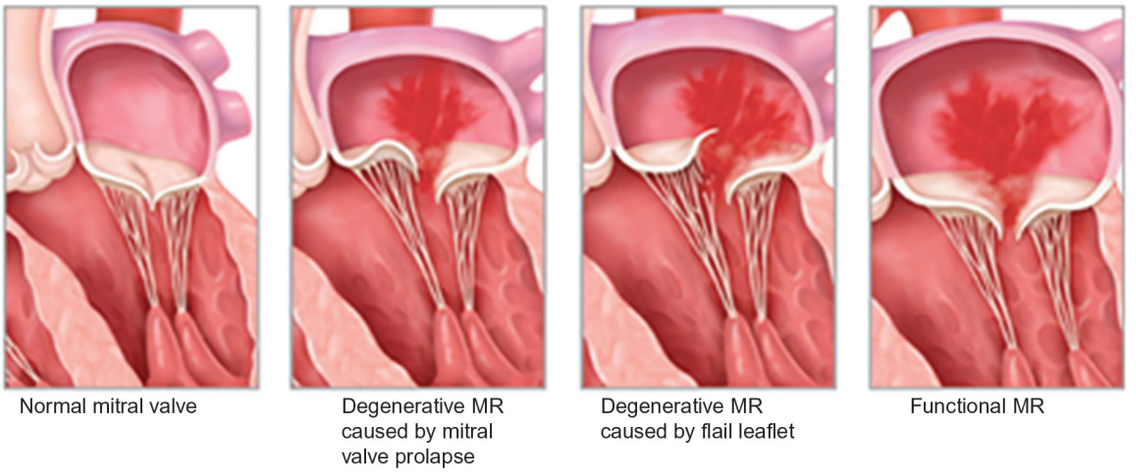

Fig. 16.31: Valvular positions in normal MV and comparing with mitral regurgitation of MVP and other common causes of MR

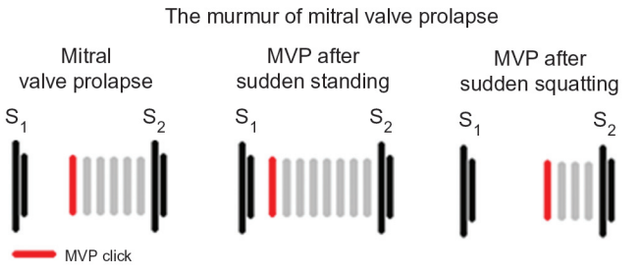

Fig. 16.32: Mitral valve prolapse responds to dynamic auscultation. MVP click and murmur varies after sudden standing and sudden squatting as demonstrated in this illustration. It therefore helps in differentiating other conditions with click and murmur

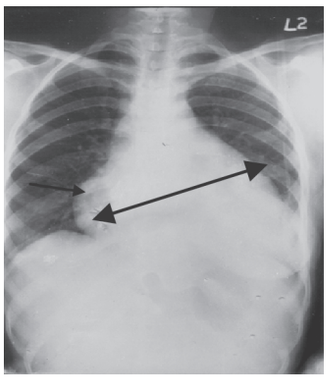

Fig. 16.33: X-ray chest (PA view) shows cardomegaly (LV type) in mitral valve prolapse with MR

MVP did not have true MVP but simply normal variation in the shape of their mitral valve. For many patients and physicians it may have been easier to accept that a physical condition was responsible for panic attacks. Most people have no symptoms of MVP.

Persons with MVP having demonstrated regurgitation are at slightly increased risk of developing endocarditis during dental/surgical procedures and should receive antibiotic prophylaxis. A very small number are at increased risk of sudden death.

Invasive and Noninvasive Procedures

Chest Radiography

Radiographs may demonstrate the progression from asymptomatic to chronic, severe mitral regurgitation with the development of cardiomegaly secondary to left atrial and left ventricular dilatation and evidence of heart failure (Fig. 16.33).

Electrocardiography

The ECG usually is normal, but can show nonspecific ST-segment and T-wave abnormalities especially in leads II, III, Avf (Fig. 16.34).

Echocardiography

The use of echocardiogram (ultrasound of the heart) over the past 20 years has revolutionized examination of the heart. Using earlier ultrasound criteria it was estimated 5–10% of the population has MVP. However, recent studies suggest that slight bowing of the mitral valve (not accompanied by regurgitation) is normal for many people and that MVP was likely over diagnosed because of the ability of ultrasound to see extremely small variations in the mitral valve shape. Using revised criteria it is believed that MVP is present in less than 1% of the general population (Figs 16.35–16.41).

Diagnostic criteria: Perloff et al. set the stage for accurately diagnosing mitral valve prolapse (MVP) by expanding the diagnostic standards to include clinical and echocardiographic criteria. In a Framingham Heart Study, Freed et al. historically described echocardiographic criteria for MVP as classic versus nonclassic. Use of the parasternal long-axis view reduce the over diagnosis of MVP.

Findings are as follows:

1. Classic MVP: The parasternal long-axis view shows >2 mm superior displacement of the mitral leaflets into

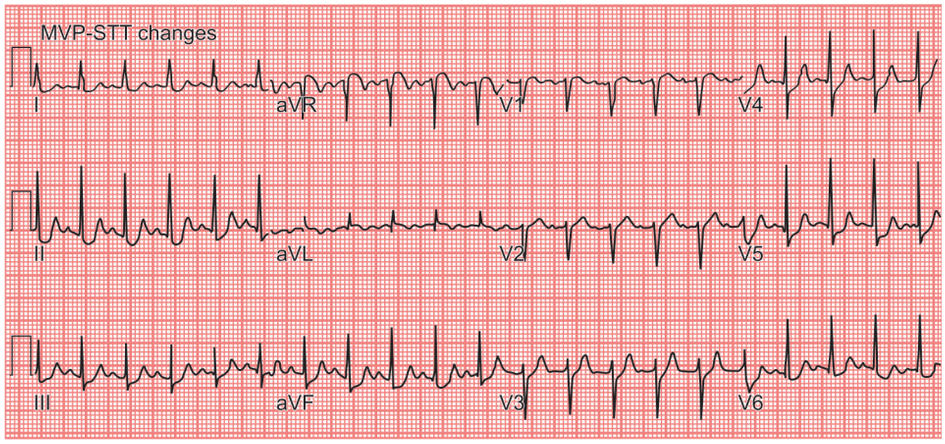

Fig. 16.34: ECG shows nonspecific ST-segment and T-wave depression in inferior leads II, III, aVF

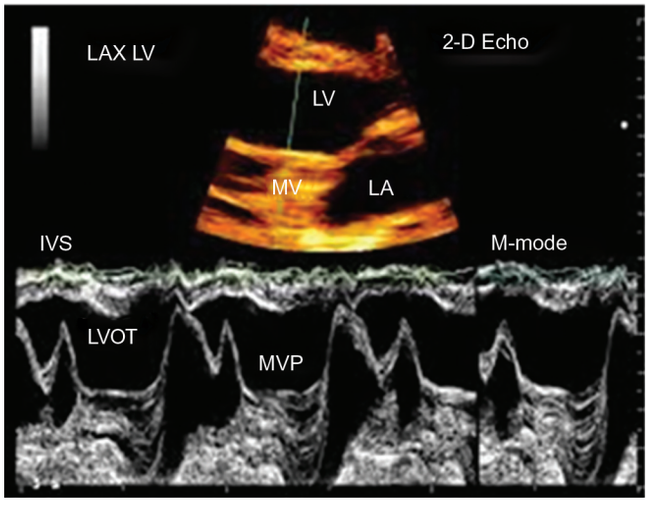

Fig. 16.35: M-mode study shows abrupt posterior displacement in midsystole (MVP) of the anterior and posterior mitral leaflets

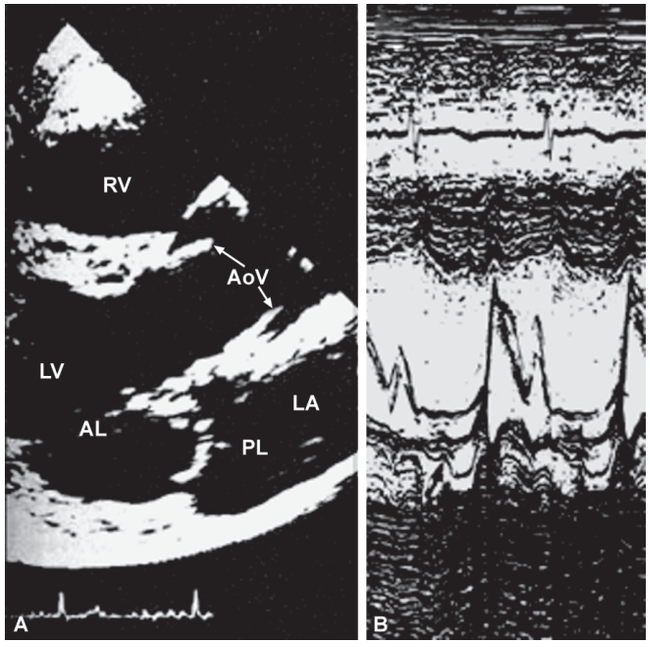

Fig. 16.36: Echocardiogram from a patient with mitral valve prolapse. (A) Parasternal long-axis view in systole show the posterior leaflet (PL) of the mitral valve with superior displacement (bowing) into the left atrium (LA), i.e. arching posteriorly above the level of the atrioventricular groove and behind the normal coaptation point of the left atrium. (B) M-mode study shows abrupt posterior displacement in midsystole (arrow) of the posterior mitral leaflet. There are multiple echoes arising in the area of the valve during systole as a result of the redundancy of the leaflets. These findings are characteristic of mitral valve proplapse. LV=left ventricle; AL=anterior leaflet of mitral valve; RV=right ventricle; AoV=aortic valve

the left atrium during systole, with a leaflet thickness of at least 5 mm.

2. Nonclassic MVP: Displacement is >2 mm, with a maximal leaflet thickness of <5 mm.
3. Other: Other echocardiographic findings that should be considered as criteria are leaflet thickening, redundancy, annular dilatation, and chordal elongation.

Ambulatory 24-hour Electrocardiogram

A Holter monitor may help identify the nature and frequency of arrhythmic activity. Premature ventricular beats (38%), multiform couplets, and tachyarrhythmias (8%) are usual findings (Fig. 16.42).

Exercise testing: This is useful in patients with palpitations and exercise-related symptoms.

Premature ventricular beats (16%), ventricular tachycardia (4%), and supraventricular ectopy are common findings. Ventricular fibrillation is a rare finding.

Cardiovascular Magnetic Resonance Imaging

(Fig. 16.43)

Cardiovascular magnetic resonance (CMR) has the potential to visualize all parts of the valve (leaflets, chordae tendineae, and papillary muscles) throughout the entire cardiac cycle. Congenitally abnormal valve leaflets

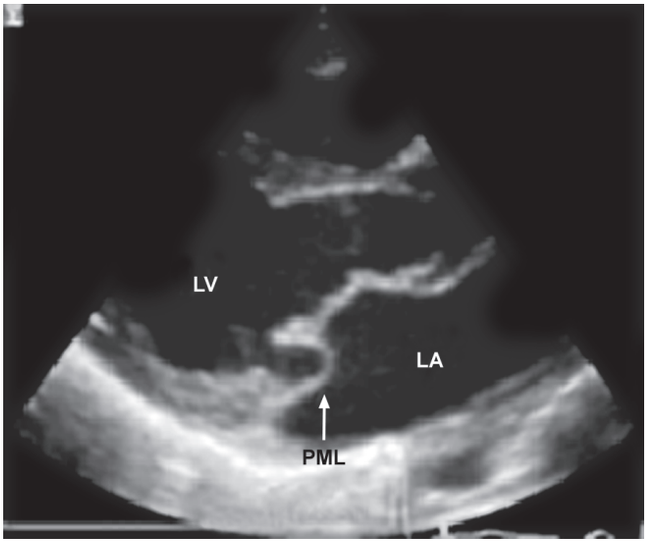

Fig. 16.37: Two-dimensional echocardiographic long axis parasternal view of mitral valve prolapse (arrow). MV=mitral valve, LV=left ventricle, LA=left atrium, RV=right ventricle, Ao=aorta

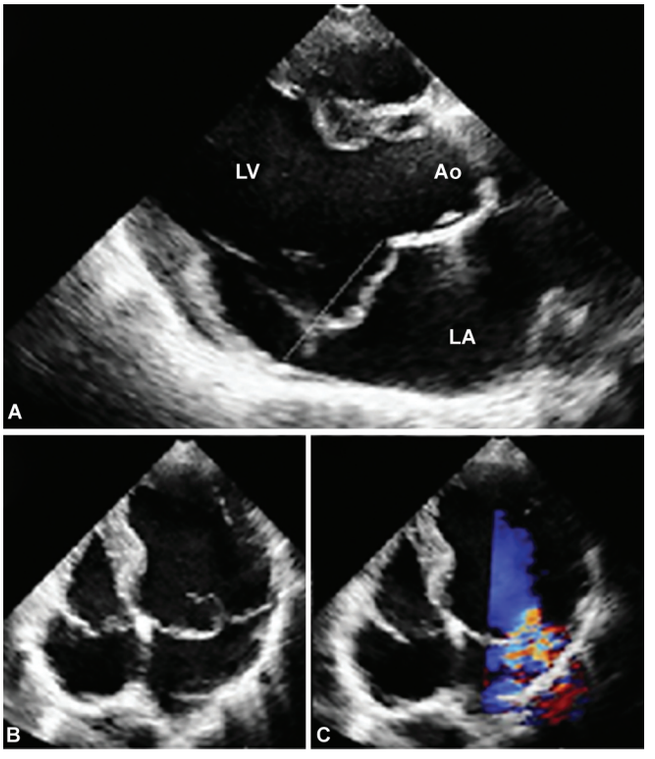

Fig. 16.38: Mitral valve prolapse. (A) Echocardiographic parasternal long-axis view showing the mitral leaflets prolapsing more than 2 mm above the plane of the mitral annulus (dotted line) during systole in a child with Marfan syndrome. (B) Echocardiographic apical four-chamber view showing bileaflet prolapse in the same patient. (C) Color-Doppler view showing moderate mitral regurgitation. Ao=aorta; LA=left atrium; LV=left ventricle

(bicuspid), aberrant papillary muscles or aberrant chordal attachments (parachute mitral valve), leaflet thickening, presence and extent of calcification, leaflet redundancy and

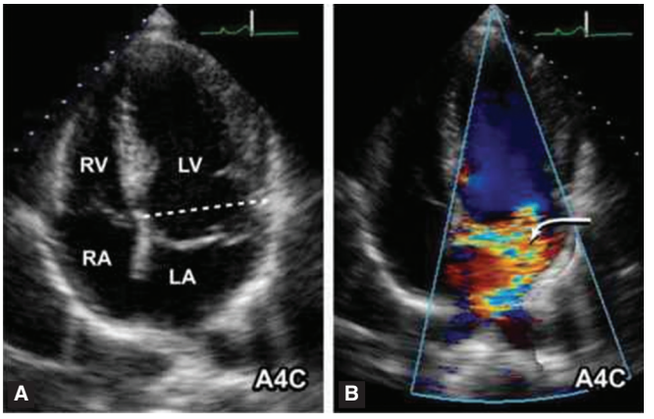

Fig. 16.39: Bileaflet prolapse is easily visualized in the apical four-chamber (A4C) view. However the mitral valve profile is normally exaggerated in this view and may lead to overdiagnosis of mitral valve prolapse (A). Severe mitral regurgitation was present (B)

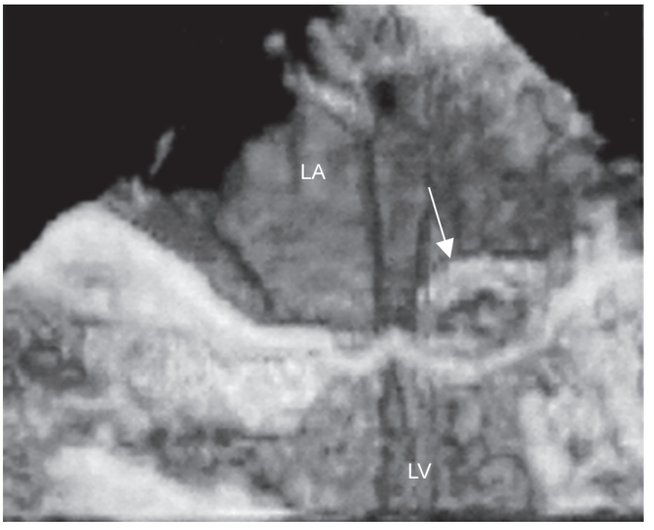

Fig. 16.40: Three-dimensional reconstruction obtained from the TEE in a patient with prolapse posterior mitral valve leaflet (arrow)

prolapse, and commissural fusion are all anatomic descriptions that have been reported by CMR. However, two-dimensional (2D) echocardiography is superior for imaging structures that are thin and highly mobile owing to its greater temporal resolution and the absence of partial volume effects. Although 2D echocardiography remains the primary approach for visualization of valve anatomy, CMR is a reasonable alternative if ultrasound windows are poor.

Cardiac Catheterization and Angiography

These tests are generally restricted to patients with MVP and severe MR who may require valve repair or replacement. Associated coronary artery disease can also be confirmed or excluded. A left ventricular angiogram, taken in the right anterior oblique view, best shows the posterior leaflet. A left anterior oblique projection shows the anterior leaflet. Other abnormalities that may be revealed include

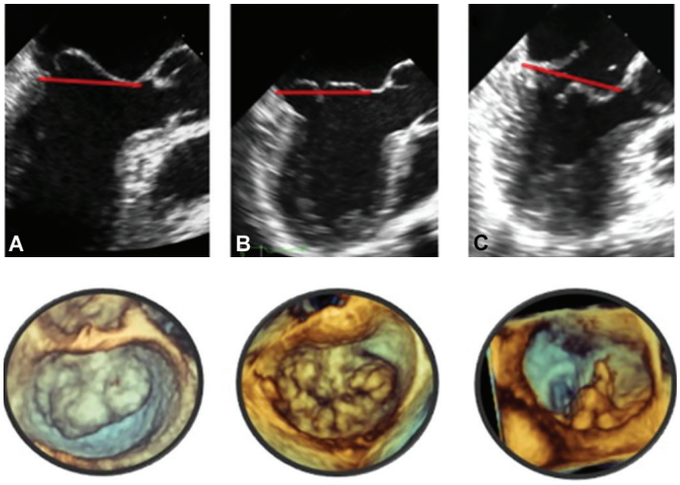

Fig. 16.41: Differential diagnoses of mitral leaflet prolapse. 2D TEE long-axis view demonstrating anterior leaflet prolapse (A, top) with a 3D transesophageal example as seen from the left atrium (A, bottom). Leaflet prolapse should be diagnosed when the free edge of the leaflet overrides the plane of the mitral annulus during systole. 2D TEE long-axis view demonstrating bileaflet billowing of the mitral valve with prolapse due to chordae elongation (B, top) with 3D transesophageal example as seen from the left atrium (B, bottom). Leaflet billowing is diagnosed when there is systolic excursion of the leaflet body into the left atrium due to excess leaflet tissue, with the leaflet free edge remaining below the plane of the mitral annulus. 2D TEE long-axis view demonstrating flail valve due to chordae rupture (C, top) with a 3D transesophageal example of P2 flail as viewed from the left atrium

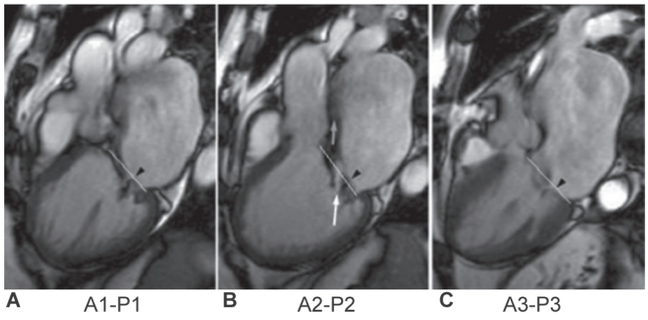

Fig. 16.43: Prolapse of P2 causing mitral regurgitation. (A) A1-P1, (B) A2-P2, (C) A3-P3. Arrowhead shows the posterior leaflet. This can be seen to be prolapsed at (B) P2. The yellow line shows the mitral annular plane. The arrows show the eccentric jet of mitral regurgitation which results from failure of coaptation of A2-P2 and is anteriorly directed along the wall of the left atrium. The white arrow points to a central bright jet core in the A2-P2 bSSFP image, with a dark streak of signal loss beyond (grey arrow). This is in accord with relatively severe regurgitation

dilatation, decreased systolic contraction, calcification of the mitral annulus, and poor contraction of the basal portion of the left ventricle (Fig. 16.44).

Electrophysiology

Indications for electrophysiology (EPS) are similar to those in general clinical practice. EPS is useful in the presence of

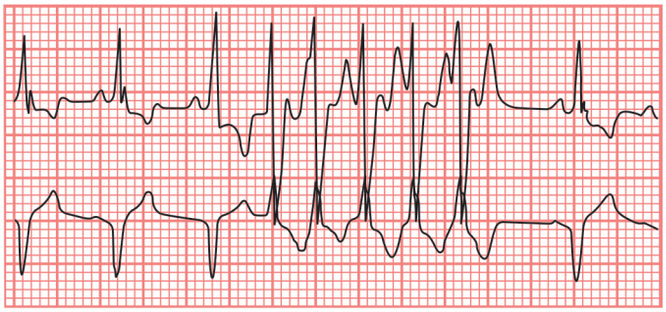

Fig. 16.42: Two channel Holter recording strip with 5 beats run of ventricular tachycardia in patient with mitral valve prolapse with mitral regurgitation

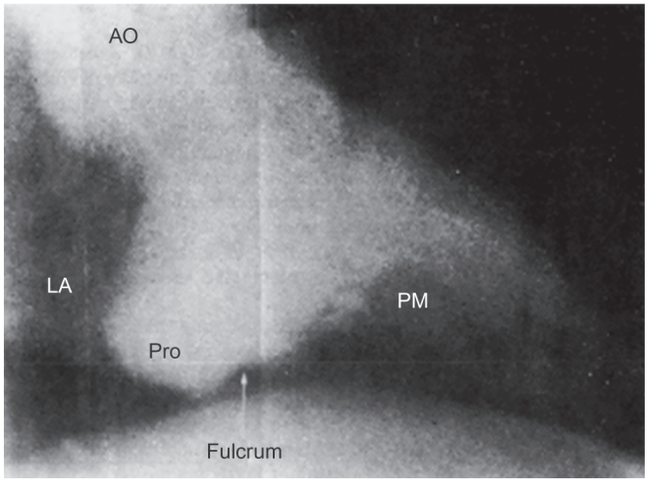

Fig. 16.44: Left ventricular angiogram during systole demonstrating prolapse of mitral valve (Pro). The posteromedial commissural scallop of the posterior mitral leaflet extends posteriorly and inferiorly to the fulcrum (arrow)

supraventricular tachycardia because accessory atrioventricular pathways are common in patients with MVP. In this subset of patients, EPS is important because radiofrequency ablation can be performed during the same procedure, with a very high curative success rate.

Tilt test: Upright tilt studies with blood pressure and cardiac rhythm monitoring may be valuable in patients with light-headedness or syncope when vasodepressor-vasovagal reaction is suspected and confirmation of clinical symptoms is desired.

Histologic Findings

Mitral valves excised from patients with severe MR secondary to MVP have large leaflets and show various alterations. The most specific, fundamental, and characteristic histologic changes are (1) collagen dissolution and disruption in the pars fibrosa of the mitral valve leaflet and (2) replacement of the dense collagenous fibrosa by loose myxomatous connective tissue with high acid mucopolysaccharide content.

Similar histologic abnormalities are observed in chordae tendineae. Scanning electron photomicrographs demonstrate surface folds and focal loss of endothelial cells on mitral valve leaflets obtained from patients with severe MVP and significant MR. These surface abnormalities may predispose to thromboembolic complications and/or infectious endocarditis. Continuous pressure and stress on the leaflets and chordae tendineae during left ventricular systole contribute to gradual progression of these histologic changes.

Medical Treatment

In childhood, the condition is not progressive, and specific therapy is not indicated for the vast majority. Asymptomatic patients with isolated mitral systolic clicks need only counseling and reassurance. Avoid excessive use of caffeine, cigarettes, alcohol, and prescription or over-the-counter drugs that contain stimulants such as epinephrine or ephedrine to minimize catecholamine and cyclic adenosine monophosphate (AMP) stimulation. Prevention of volume depletion before, during, and immediately after exercise may help. Subacute bacterial endocarditis antibiotic prophylaxis coverage for at-risk procedures is indicated in patients with mitral valve prolapse (MVP) and MR.

Additional dental care recommended for patients at risk for infective endocarditis includes the following:

- Regular toothbrushing after eating. No cookies, sweets, or sweet drinks between meals.
- Regular dental checks every 6 months. Fluoride supplements in locations where the fluoride in drinking water is less than 0.3 ppm for children younger than 2 years or less than 0.7 ppm for children younger than 2 years. Dental treatments (more than 2) scheduled at an interval of 14 days or longer.

Surgical intervention: Recent advances have made reconstructive mitral valve surgery feasible in patients with congestive heart failure, severe MR secondary to MVP, or both (Fig. 16.45).

Robotic mitral valve repair: Robotic mitral valve repair (Fig. 16.46) allows complete anatomic correction of all categories of leaflet prolapse using techniques identical to open approaches. Robotic repair effectively corrects mitral regurgitation, offers excellent freedom from adverse events, and facilitates rapid weaning from ventilation, translating into earlier hospital dismissal. Safety and efficacy after both open and robotic mitral valve repair are higher than recently reported in the EVEREST II trial and establish a benchmark against which nonsurgical therapies should be evaluated.

Group consultations: A multidisciplinary approach is preferable, with a team from the following specialties:

- Pediatrics
- Pediatric cardiology
- Radiology
- Genetics
- Cardiothoracics
- Physiotherapy
- Family medicine
- Orthopedics

Advice for physical activity: A gradual return to exercise may be tolerated. In the absence of studies on the effect of exercise on the progression of MVP, the best approach at present is based on common sense and good clinical judgment.

- Patients with symptoms of syncope, presyncope, or palpitations upon exertion should undergo thorough evaluations and avoid competitive sports for at least 6 months after the last significant episode.
- In the presence of significant MR, limitations apply as for any other cause of MR.
- Coexisting aortic root dilatation and aortic regurgitation can further limit activity.
- Patients with cardiac arrhythmia should have periodic exercise tests performed and ambulatory ECG recordings obtained while doing the type of exercise they are likely to undertake.
- Sudden death is extremely uncommon in MVP.

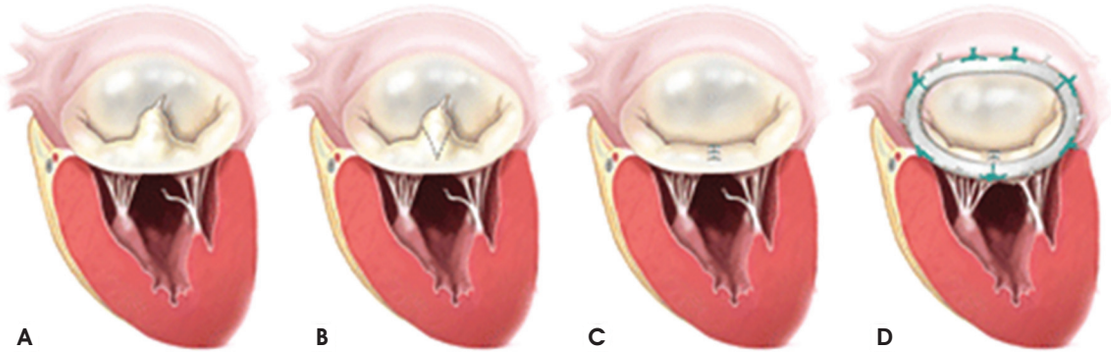

Fig. 16.45: Triangular resection and ring annuloplasty. (A) Fibroelastic deficiency with P2 (posterior middle scallop) prolapse. (B) Dashed lines represent area of leaflet to be excised. (C) Reconstructed leaflet after triangular resection. (D) Completed repair after ring annuloplasty

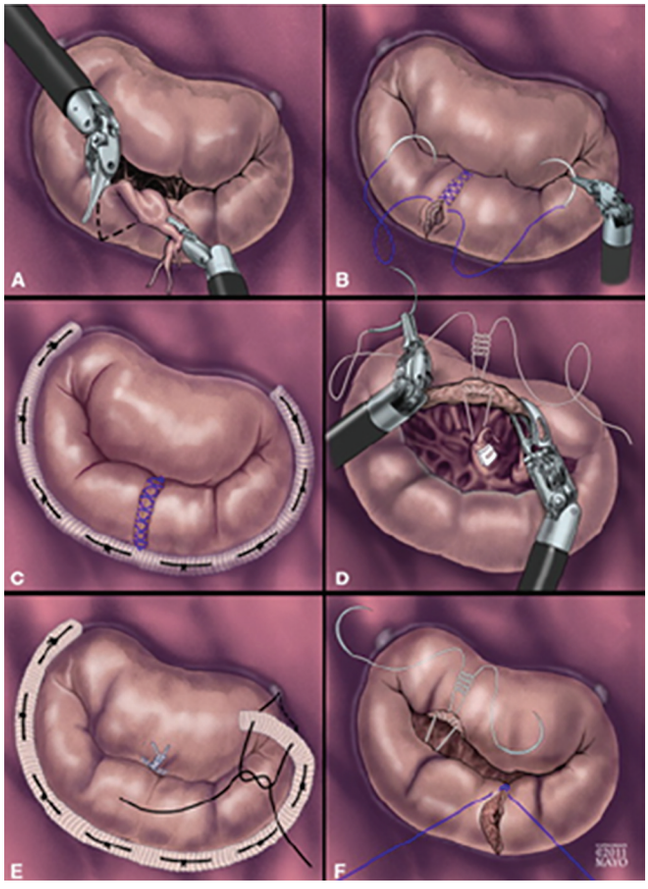

Fig. 16.46: Robotic mitral valve repair for all prolapse subsets using techniques identical to open valvuloplasty. Standard Mayo Clinic mitral valve repair techniques using robotic instrumentation. (A) The extent of posterior leaflet prolapse is determined and a triangular-shaped resection performed to eliminate redundancy predominating at the leading edge, restoring the position of the coapting margin to the annular plane and decreasing leaflet height. (B) The remaining leaflet edges are reapposed using a 2-layer prolene stitch, restoring normal leaflet coaptation. (C) After posterior leaflet correction, a standard-length 63-mm flexible posterior annuloplasty band is inserted using interrupted Ethibond sutures from right to left fibrous trigones. (D) Anterior leaflet prolapse is corrected by placing two 5–0 Gore-Tex (WL Gore and Associates, Inc. Flagstaff, Ariz) neochords between the subtending papillary muscle to the unsupported leaflet edge using a double-armed Gore-Tex pledget-backed mattress stitch. (E) After anterior leaflet correction, a 63-mm flexible posterior annuloplasty band is inserted using interrupted Ethibond sutures from right to left fibrous trigones. (F) Bileaflet repair is performed using a combination of posterior leaflet resection/reconstruction, anterior leaflet neochord resuspension, and standard-length 63-mm flexible posterior annuloplasty band

AORTIC VALVE DISORDERS

The aortic valve normally allows one way flow of blood from the left ventricle to the aorta. Disorders of the aortic valve may cause aortic valve stenosis or aortic valve regurgitation.

1. AORTIC STENOSIS

It is defined as narrowing of the aortic valve from its normal diameter due to numerous conditions as follows:

Aetiological Factors

- Congenital aortic stenosis: Male > Female (4:1)
- Congenital bicuspid valve (1–2%)
- Rheumatic aortic stenosis
- Calcific aortic stenosis

Signs and Symptoms

- Exertional angina
- Syncope (during exercise)
- CHF (initially diastolic failure, then systolic)
- Sudden death secondary to ventricular fibrillation
- Harsh crescendo-decrescendo (diamond-shaped) systolic murmur at aortic focus radiating to carotids
- Absent aortic component of S2
- Delayed upstroke in peripheral pulse (pulsus parvus et tardus)
- S4 gallop
- Ejection click

Aetiology of Aortic Stenosis?

Most people do not develop symptoms until late in the course of aortic stenosis. Age at onset of symptoms (clinically apparent aortic stenosis) usually indicates the cause of aortic stenosis. Symptoms in people younger than 30 years is almost always due to congenital causes (usually bicuspid aortic valve). Symptoms in people 30–70 years may be due to either bicuspid valve or rheumatic heart disease. Aortic stenosis caused by rheumatic fever occurs 10–15 years later than mitral stenosis caused by rheumatic fever. Symptoms developing in the elderly are usually due to calcific degenerative changes of a normal aortic valve (wear and tear of aging).

Clinical Diagnosis of Aortic Stenosis

People may see their doctor concerning symptoms of aortic stenosis. Chest pain or passing out during exertion is very concerning and may prompt a doctor into examining the heart in detail. If aortic stenosis is present a certain type of heart murmur may be detected when a doctor listens with a stethoscope. The doctor may order further tests. Aortic stenosis can be definitively diagnosed using echocardiogram (heart ultrasound). Atrial fibrillation and traveling emboli are less common in isolated aortic stenosis (Fig. 16.47).

Laboratory Studies

Chest radiography: Chest radiographs may show several significant findings consistent with aortic stenosis. The aortic valve may appear calcified. With plain images, calcification is best detected on the lateral view. Calcification of the aortic valve is found in almost all adults with hemodynamically significant aortic stenosis. The LV



Fig. 16.47: A 68-year-old person sought consultation of a cardiologist for syncopal attack who was found to be suffering from degenerative type of valvular aortic stenosis

may be slightly enlarged, with a rounded apex; this is a nonspecific finding. The left atrium may be enlarged as well. Visible calcification on plain chest films usually indicates a gradient of 50 mmHg or more across the valve, which is severe enough to require surgery (Fig. 16.48).

Electrocardiography

Generally, ECG is not a reliable test for aortic stenosis. The results vary widely in patients with this disorder and overlap with other cardiac conditions (Fig. 16.49).

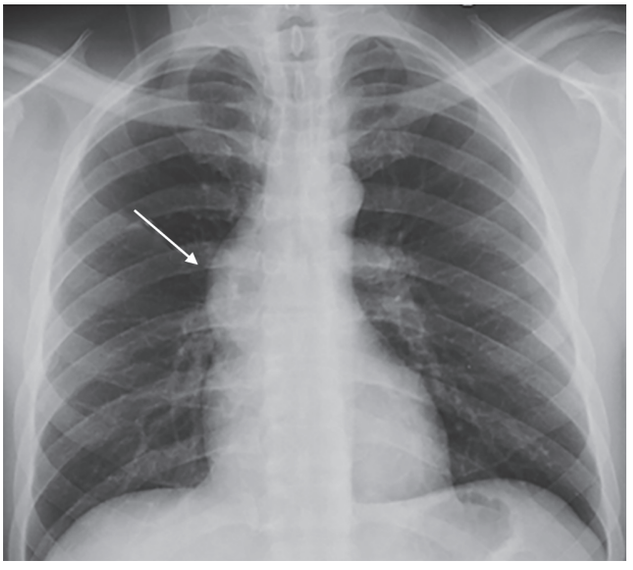

Fig. 16.48: Frontal chest radiograph in another patient with aortic stenosis shows a dilated ascending aorta 9 (white arrow) that abnormally projects farther to the right than the right heart border. This is caused by poststenotic dilatation of the aorta

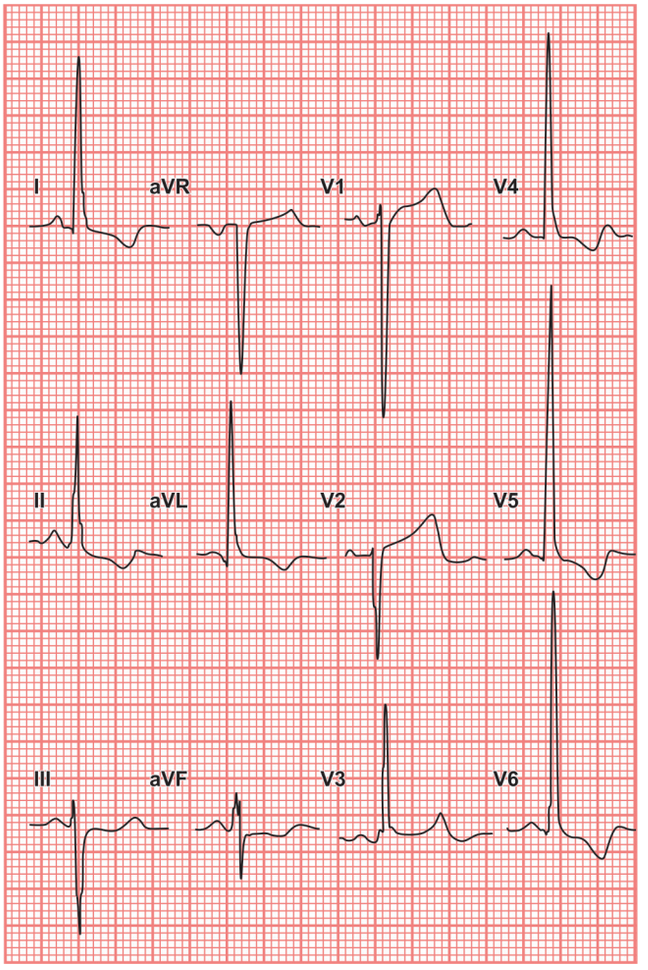

Fig. 16.49: ECG showing deep S-waves in V1–V2 and tall R-waves in V4–V6 as voltage criteria of LVH in patient with aortic stenosis

Although the ECG findings may be entirely normal, the principal finding is left ventricular hypertrophy (LVH), which is found in 85% of patients with severe aortic stenosis; however, its absence does not preclude critical aortic stenosis. Patients with significant aortic stenosis who may not show clear ECG evidence of ventricular hypertrophy include elderly persons with significant myocardial fibrosis and adolescents, who may experience ST-segment changes before QRS changes.

T-wave inversion and ST-segment depression in leads with predominantly positive QRS complexes are common. ST-depression exceeding 0.3 mV in patients with aortic stenosis indicates LV strain and suggests severe LVH. Occasionally, a septal pseudoinfarct pattern can be seen. Left atrial enlargement with a preterminal negative P-wave in lead V1 is noted in 80% of cases of severe isolated aortic stenosis. The presence of left atrial enlargement suggests an associated mitral valve process.

The correlation between absolute voltages in precordial leads and the severity of obstruction, unlike in children with congenital aortic stenosis, is poor in adults.

The rhythm usually is normal sinus. Atrial fibrillation can be seen at late stages or as a consequence of coexistent MV disease or hyperthyroidism.

Extension of calcification into the conduction system can cause atrioventricular or intraventricular block in 5% of cases of aortic stenosis. Approximately 10% of all cases of left anterior fascicular block are secondary to calcific aortic valve disease. Ambulatory ECG monitoring frequently shows complex ventricular arrhythmias, particularly in cases with myocardial dysfunction.

While the degree of severity of changes on a single ECG does not correlate well with the degree of hemodynamic compromise, serial ECGs performed over time (months to years) can be valuable in demonstrating the progression of the disease.

Echocardiography

Echocardiography is the preferred imaging test for aortic stenosis. Echocardiography is indispensable to the assessment of the extent of LV hypertrophy, systolic ejection performance, and anatomy of the aortic valve. Doppler interrogation of the aortic valve makes use of the modified Bernoulli equation (gradient = 4 × velocity^2) to assess the severity of the stenosis. As blood flows from the body of the LV across the stenotic valve, the flow rate must accelerate for the volume to remain constant. Doppler interrogation of the valve detects this increase in velocity and helps estimate the valvular gradient. In summary, echocardiography may demonstrate the following findings (Figs 16.50–16.53):

- Concentric LV hypertrophy
- Reduced separation of the cusp of the aortic valve
- Mean gradients greater than 50 mmHg in patients with severe aortic stenosis on Doppler echocardiography.

CT Scanning

CT scans may exhibit chamber enlargement and calcification of the aortic valve. This calcification is a reliable indicator of severe stenosis, particularly when it is present in a young patient (Fig. 16.54).

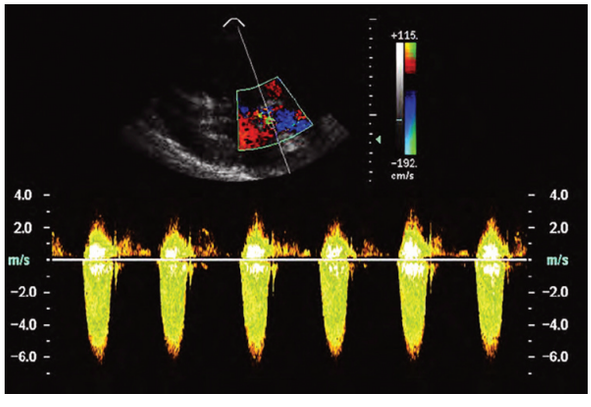

Fig. 16.50: Color flow guided evaluation of aortic stenosis jet from apical five chamber view with continuous wave Doppler interrogation

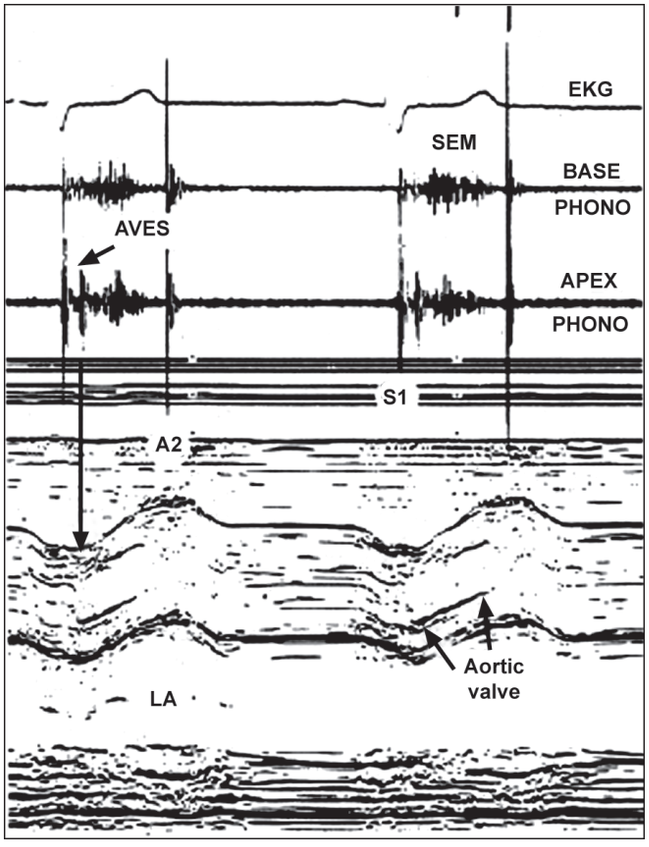

Fig. 16.51: Simultaneous recordings of base, apexcardiograms and aortic valve echocardiogram showing a prominent aortic valvular ejection click (AVES) is recorded at the apex and is coincident with the maximal excursion of the aortic valve in early systole. It is followed by a crescendo-decrescendo SEM that ends well before a loud A2 in young patient with valvular aortic stenosis

Magnetic Resonance Imaging

Cine MRI may be used to depict the signal void caused by high-velocity jet flow across a narrow valvular orifice associated with the opened valve in aortic stenosis. The signal void is projected into the ascending aorta in systole. Despite the good anatomic detail obtainable with MRI, echocardiography has superseded MRI because of its improved portability (Fig. 16.55).

Cardiac Catheterization and Angiography

During catheterization, the transvalvular pressure gradient across the aortic valve is measured by use of a catheter in the LV and another in the proximal aorta or femoral artery. A mean pressure gradient greater than 30 mmHg usually represents clinically significant aortic stenosis. As a result of the dire consequences of missing the diagnosis of symptomatic aortic stenosis, the physician must have a low threshold for obtaining an echocardiogram whenever the possibility of aortic stenosis cannot be excluded during physical examination (Figs 16.56 and 16.57).

Asymptomatic patients with suggestive murmurs benefit from early diagnosis, which allows both the patient

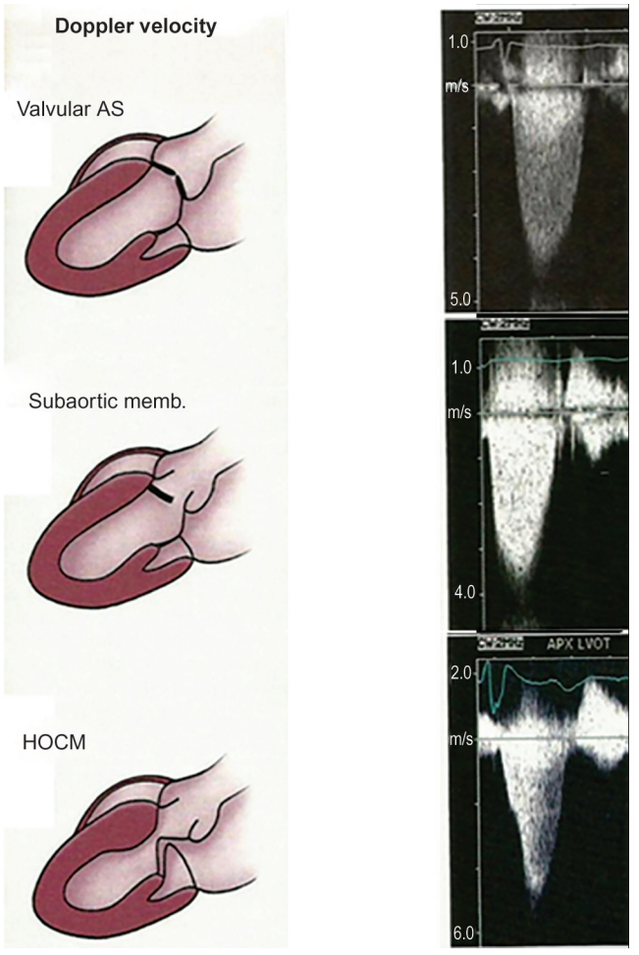

Fig. 16.52: CW Doppler study in different types of LV outflow obstructions

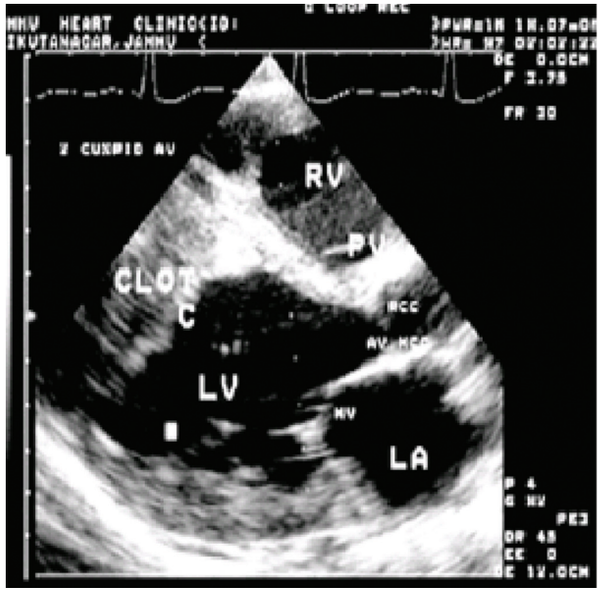

Fig. 16.53: 2D LAX view of LV showing dilated LV cavity with apical clot in patient with severe type of aortic stenosis

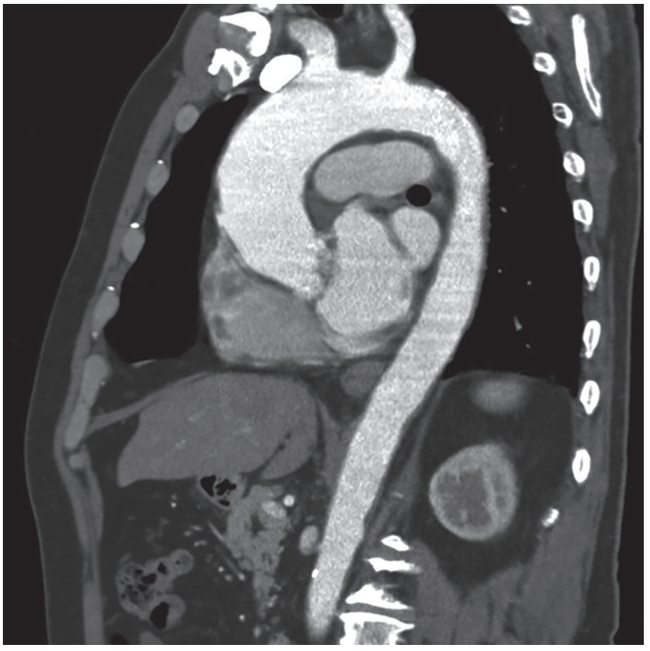

Fig. 16.54: CTA of the thorax confirms enlargement of the ascending aorta with a normal caliber descending aorta. Non-contrast CT image depicts aortic valve calcification

and the physician to be most vigilant regarding possible early signs and symptoms and to guide the use of prophylactic regimens to prevent bacterial endocarditis.

Treatment of Aortic Stenosis

- Gentle diuresis if CHF
- Mild hydration if hypotensive and not in CHF
- Avoid nitrates and afterload reduction
- Digoxin
- Intra-aortic balloon pump (temporize for surgery)
- Endocarditis prophylaxis/education
- Asymptomatic persons with mild stenosis do not have to limit physical activity.
- Periodic monitoring should be done because rapid narrowing can occur over as little as a few years.
- Persons with more severe stenosis should be evaluated by a cardiologist whether or not they have symptoms.
- Persons with symptoms of passing out on exertion, angina or congestive heart failure due to aortic stenosis require immediate evaluation by a cardiologist and may be considered for valve repair or replacement.
- Your doctor may treat symptoms of either angina or congestive heart failure with medications as they occur. If these symptoms are caused by aortic stenosis definitive treatment is valve repair or replacement. Very old age (80s) is not a contraindication to valve replacement as long heart function and overall health are reasonable. Persons requiring treatment for this disorder must be under the care of a physician (Figs 16.58–16.60).

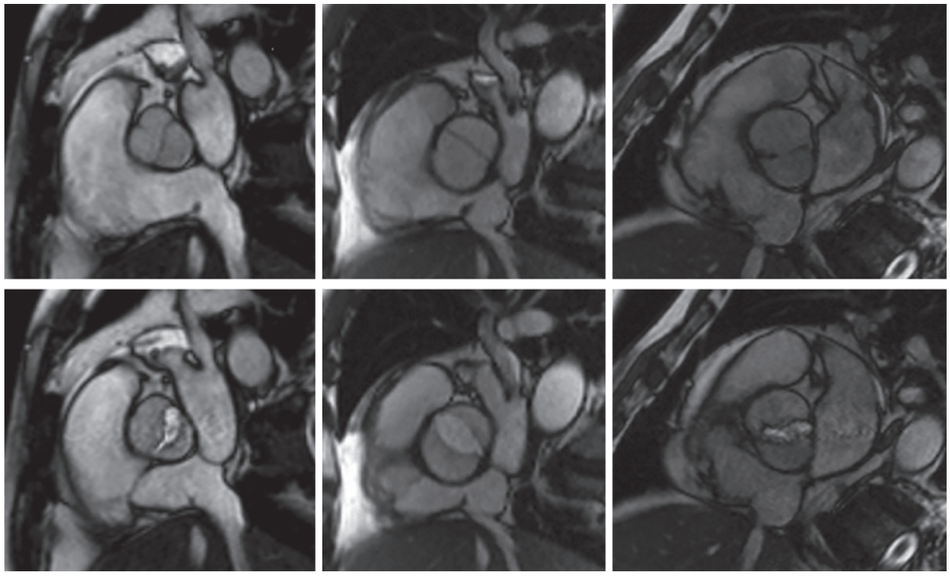

Fig. 16.55: Typical SSFP cine CMR still frames of BAV. An oblique orientation is given through the aortic valve. The perspective is from the left-anterior side of the LV towards the aorta. CMR visualizes different types of BAV in diastole (top row) and systole (bottom row). Type 1 LR (left), type 0-lateral (centre), and type 0-AP (right)

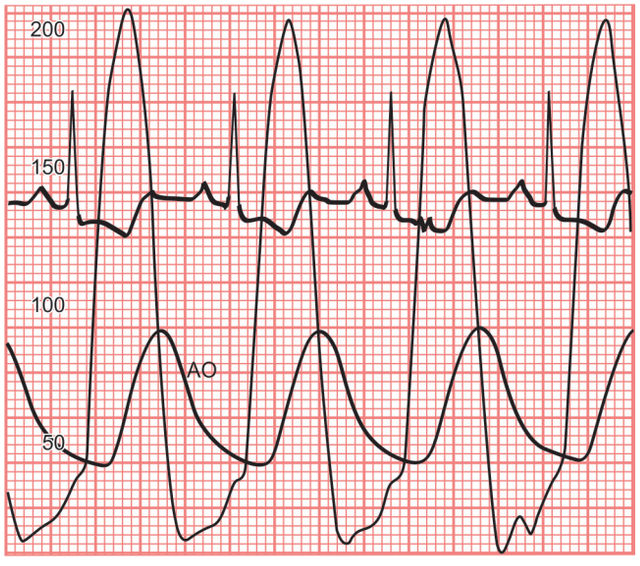

Fig. 16.56: Simultaneous tracing of ECG and hemodynamic pressure recording across aorta and LV showing marked gradient between LV and aorta in patient with moderately severe AS

Prognosis in Aortic Stenosis

Once symptoms develop aortic stenosis is very serious. The presence of symptoms almost always means that the aortic valve is extremely narrow and will not tolerate further narrowing. Once symptoms occur with aortic stenosis, particularly angina or shortness of breath with minimal exertion or congestive heart failure, many people die within several years if not treated. Sudden death, due to cardiac arrhythmias, may occur in up to 20% of people with aortic stenosis. The cause of sudden death is speculative (unknown).

2. AORTIC REGURGITATION

It is defined as leakage of blood from either malformed aortic valve or damaged due to number of conditions as follows:

Aetiology

- Infective endocarditis
- Rupture of sinus of Valsalva
- Acute aortic dissection
- Chest trauma
- Following valve surgery
- Bicuspid aortic valve
- Rheumatic fever
- Weight-loss medications (fenfluramine, dexfenfluramine)
- Collagen vascular or connective-tissue diseases
- Systematic lupus erythematosus
- Marfan syndrome
- Pseudoxanthoma elasticum
- Ankylosing spondylitis
- Ehlers-Danlos syndrome
- Polymyalgia rheumatic

Signs and Symptoms (Tables 16.1 and 16.2)

- Fatigue
- Dyspnea on exertion
- Paroxysmal nocturnal dyspnea
- Orthopnea
- Syncope
- Acute pulmonary edema

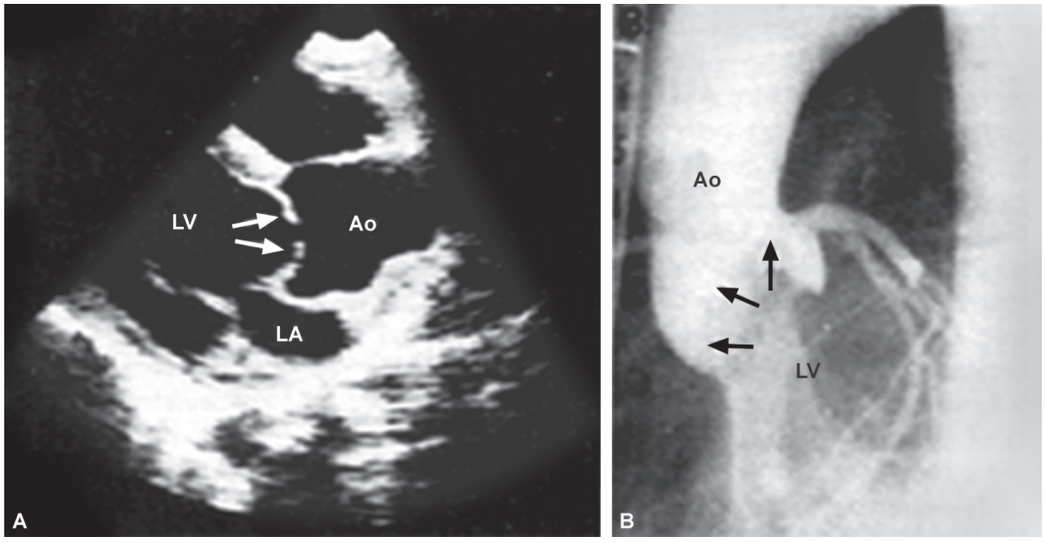

Fig. 16.57: (A) 2D echocardiographic study with the transducer in the long-axis parasternal position demonstrating leaflet doming and thickening. (B) Aortogram from the same patient showing doming of the aortic valve leaflets. The negative shadow in the proximal aortic root (Ao) is caused by a jet of non-opacified blood from the left ventricle (LV) as it exits through the stenotic aortic valve

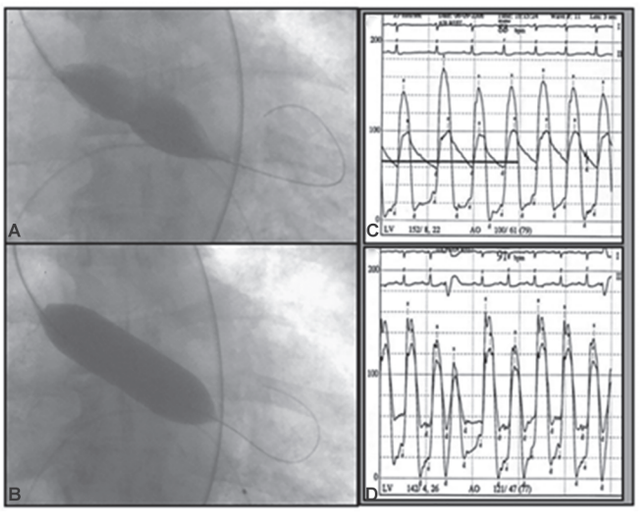

Fig. 16.58: (A) Preinflated balloon catheter across aortic valve (B) Fully inflated aortic valve. Aortic and left ventricular traces pre-(C) and post-(D) valvuloplasty. The mean aortic pressure gradient has reduced significantly from 50 mmHg to 25 mmHg

- High-pitched blowing decrescendo diastolic murmur at aortic area
- Accentuated A2 heart sound
- Wide pulse pressure
- Corrigan pulse (collapsing pulse)
- Duroziez sign (to and fro murmur)
- De Musset sign (head bobbing with systole)
- Quincke pulse (nail bed pulsations)
- Austin Flint murmur (soft diastolic rumble)

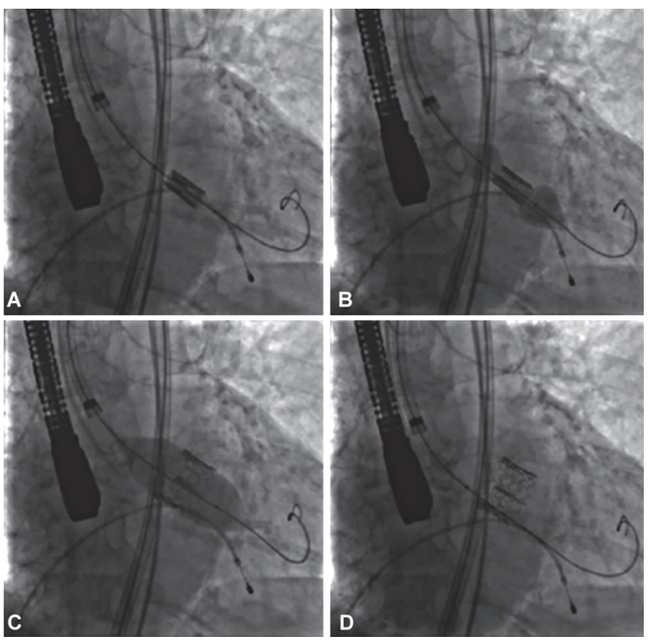

Fig. 16.59: Phases of percutaneous heart valve replacement (TAVI). (A) Edwards heart valve is guided under fluoroscopy imaging into the correct position. (B) Balloon is inflated to expand the prosthetic valve. (C) Maximal balloon inflation for valve delivery; (D) Definitive valve positioning

Diagnosis in Aortic Regurgitation

All patients in whom acute valvular regurgitation is suspected should undergo electrocardiography and chest radiography. Electrocardiograms typically reveal sinus tachycardia with nonspecific ST- and T-wave abnormalities. Ischemic ST changes can indicate regurgitation mediated by ischemia—coronary artery disease, or aortic dissection

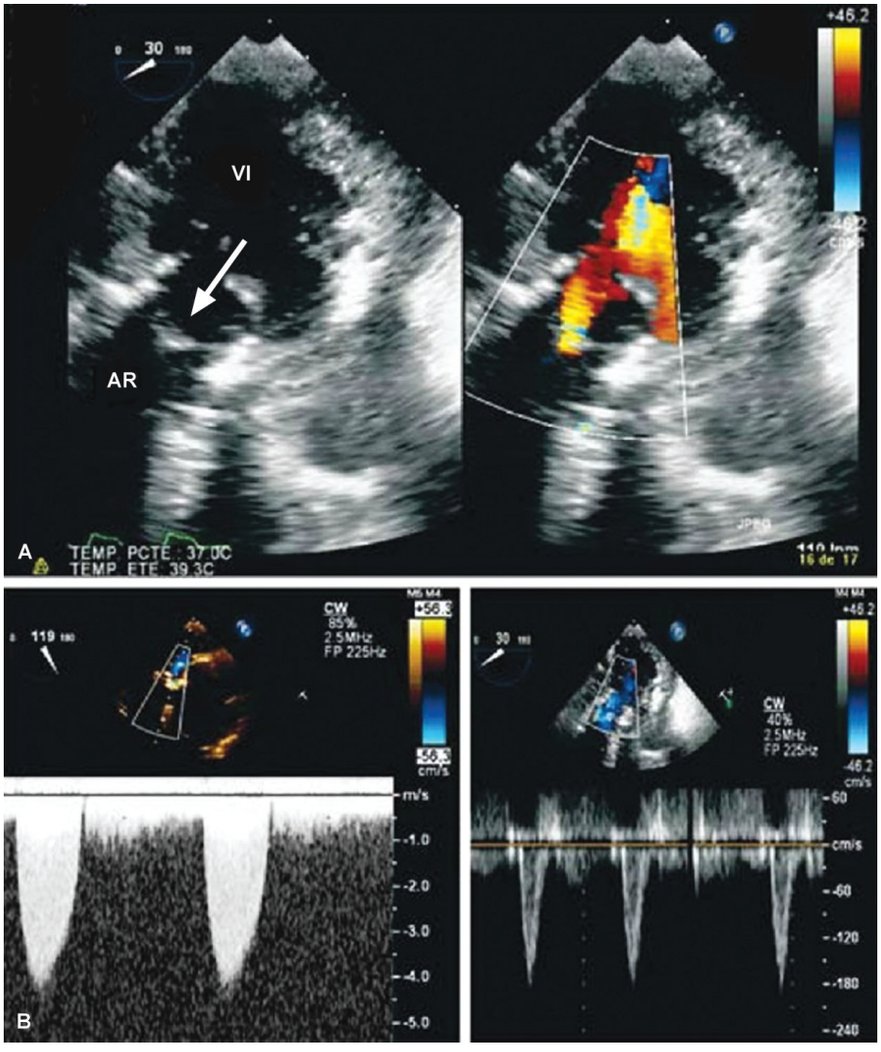

Fig. 16.60: Aortic valve hemodynamic assessment before and after transthoracic implantation of the aortic valve prosthesis. (A) Two-dimensional deep transgastric transesophageal view (left) and color-Doppler (right); the prosthesis is well-positioned, the leaflets show coaptation, and there is mild central regurgitation. (B) Spectral Doppler data obtained continuously during intraoperative transesophageal echocardiography before (left) and after (right) transthoracic implantation of the aortic valve prosthesis; note the normalization of the transvalvular flow velocity. AR=aortic root; LV=left ventricle

Table 16.1: Physical signs associated with hyperdynamic pulse in chronic aortic regurgitation

Physical sign	Description
Water-hammer or Corrigan's pulse	Rapid upstroke followed by quick collapse
DeMusset's sign	Head bob with each heartbeat
Traube's sign	Pistol shot sound heard over the femoral arteries in both systole and diastole
Muller's sign	Systolic pulsation of the uvula
Duroziez's sign	Systolic murmur over the femoral artery with compressed proximally ad diastolic murmur when compressed distally or systolic-diastolic murmur with increasing compression over femoral artery
Quincke's sign	Capillary pulsations visible in the lunula of the nailbed
Hill's sign	Popliteal cuff systolic pressure exceeding brachial cuff systolic pressure by >60 mmHg
Becker's sign	Arterial pulsations visible in the retinal arteries and pupils

Table 16.2: Indications for aortic valve replacement in severe chronic aortic regurtitation

Indication	Class
Patients with NYHA functional class III or IV symptoms and preserved left ventricular (LV) systolic function, defined as normal ejection fractinal rest (ejection fraction ≥0.50)	I
Patients with NYHA functional class II symptoms and preserved LV systolic function (ejection fraction ≥0.50) but with progressive LV dilatation or declining ejection fraction at rest on serial studies or declining effort tolerance on exercise testing	I
Patients with Canadian Heart Association functional class II or greater angina with or without coronary artery disease	I
Asymptomatic or symptomatic patients with mild to moderate LV dysfunction at rest (ejection fraction 0.25–0.49). Patients undergoing coronary artery bypass surgery or surgery on the aorta or other heart values	I
Patients with HYHA functional class II symptoms and preserved LV systolic function (ejection fraction ≥0.50 at rest) with stable LV size and systolic function on serial studies and stable exercise tolerance	IIa
Asymptomatic patients with normal LV systolic function (ejection fraction >0.50) but with severe LV dilation (end-diastolic dimension >75 mm or end-systolic dimension >55 mm)	IIa
Patients with severe LV dysfunction (ejection fraction <0.25)	IIb
Asymptomatic patients with normal systolic function at rest (ejection fraction >0.50) and progressive LV dilatation when the drgree of dilatation is moderalelly severe (end-diastolic dimension 70–75 mm, end-systolic dimension 50–55 mm)	IIb
Asymptomatic patients with normal systolic function at rest (ejection fraction >0.50) but with a decline in ejection fraction during	III
Exercise radionuclide angiography	IIb
Stress echocardiography	III
Asymptomatic patients with normal systolic function at rest (ejection fraction >0.50). LV dilatation when degree of dilatation is not severe (end-diastolic dimension <70 mm, end-systolic dimension <50 mm)	III

NYHA, New York Heart Association.

Adapted from Bonow HO, Carabello B, de leon AC Jr, et al. Guidelines for the management of patients with valvular heart disease; a report of the American College of Cardiology/Americal Heart Association Task Force on Practice Guidelines (Committee on Management of Patients with Valvular Heart Disease). J AM Coll Cardiol 1998;32:1496.

that affects the coronary ostia. Hemodynamic disturbances, such as very high LVEDP, can exacerbate coronary insufficiency. Chest radiographs typically show pulmonary edema and a left heart of normal size. Cardiomegaly can indicate the worsening of an existing valvular condition, and a widened mediastinum suggests aortic dissection. This may be mistaken for pneumonia, particularly if the patient has endocarditis or is not severely ill. Measuring cardiac biomarkers aids the diagnosis of acute coronary syndromes and ischemia; determining the level of B-type natriuretic peptide can help distinguish cardiac causes from non-cardiac causes of dyspnea and shock

Chest Radiography

Standard chest radiography may show evidence of structural abnormalities (aortic dilation, prosthetic valve dislodgement, and aortic valvular calcification) or functional compromise (pulmonary edema, cardiomegaly). In acute aortic regurgitation, the following may be seen (Fig. 16.61):

- Minimal cardiac enlargement
- Normal aortic root/arch
- Pulmonary venous pattern increased
- In chronic aortic regurgitation, the following may be seen:

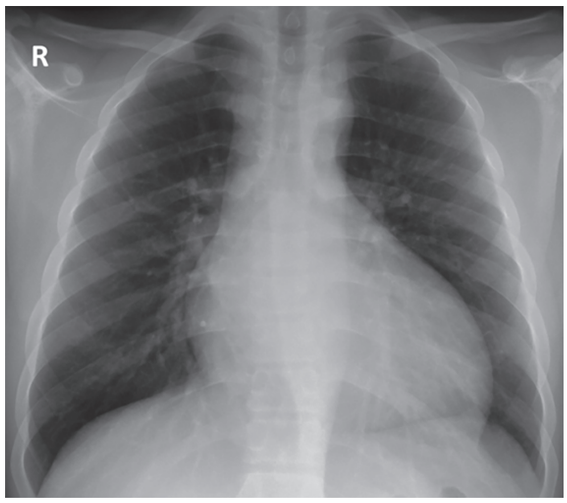

Fig. 16.61: Chest radiograph demonstrating *left ventricular enlargement* secondary to chronic aortic regurgitation as a result of increased left ventricular systolic pressure and volume overload

- Marked cardiac enlargement
- Prominent aortic root/arch
- Normal pulmonary venous pattern

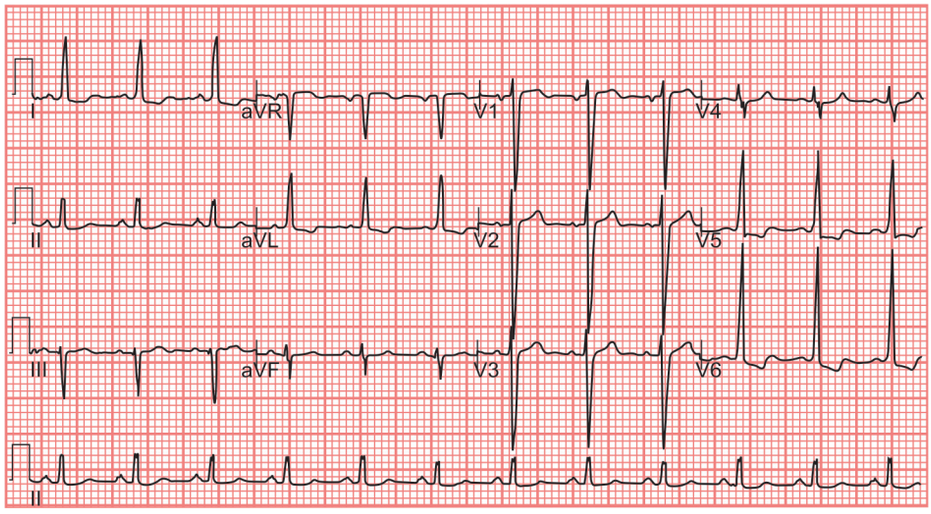

Fig. 16.62: ECG demonstrates many of the features of LV hypertrophy—markedly increased LV voltages; S wave in V1 +R wave in V6 >35 mm; R wave in aVL >11 mm. Increased R wave peak time—the upstroke of the QRS complex is slurred in V5-6, resulting in minor QRS broadening. Left ventricular strain pattern—T-wave inversion in the lateral leads V5-6, I and aVL. Left axis deviation. Signs of *left atrial enlargement*

Electrocardiography (Fig. 16.62)

Electrocardiographic findings are nonspecific but may include evidence of the following:

- LV hypertrophy
- Left axis deviation
- Left atrial enlargement
- LV volume overload pattern—prominent Q-waves in leads I, aVL, and V_3 to V_6 and relatively small r waves in V_1
- LV conduction defects—typically late in the disease process

Echocardiography is essential in the diagnosis of acute valvular dysfunction. Severe aortic or mitral regurgitation, normal LV size, and normal or hyperdynamic ventricular function all point to an acute process. Quantitative measures are more useful in chronic regurgitation than in acute regurgitation. The estimation of effective regurgitant orifice area and regurgitant volume can be inaccurate in acute regurgitation (particularly in the presence of tachycardia) and depends upon dynamic loading conditions. Echocardiography typically reveals the mechanism of regurgitation, such as aortic dissection or ruptured mitral chordae tendineae. In patients whose chronic regurgitation has led to ventricular enlargement, the acuteness of regurgitation is difficult to evaluate unless a clinical examination is performed and comparisons with prior studies are made (Figs 16.63–16.66).

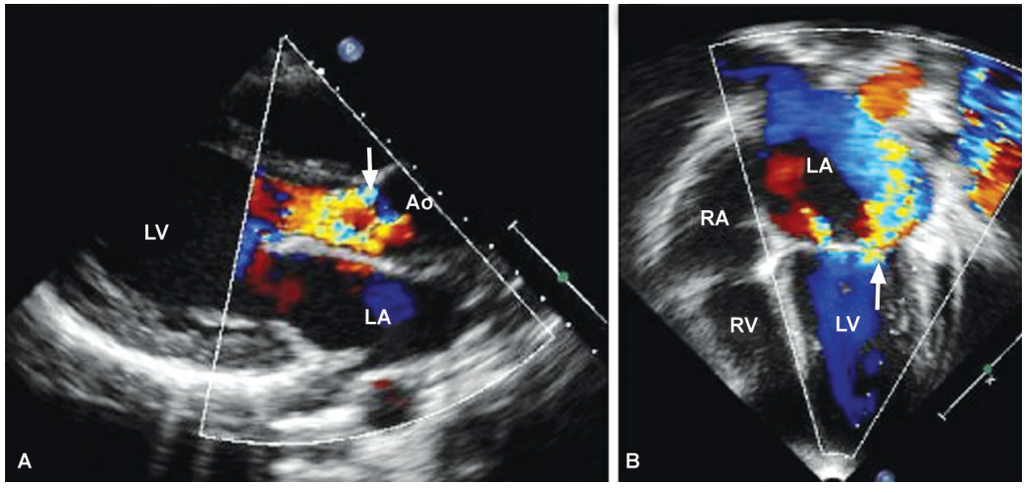

Fig. 16.63: Two-dimensional color and spectral Doppler echocardiographic studies of patients with rheumatic heart disease show moderate to severe aortic valve insufficiency with no stenosis (A, arrow) and bowing of the anterior mitral leaflet with severe insufficiency and no stenosis (B, arrow)

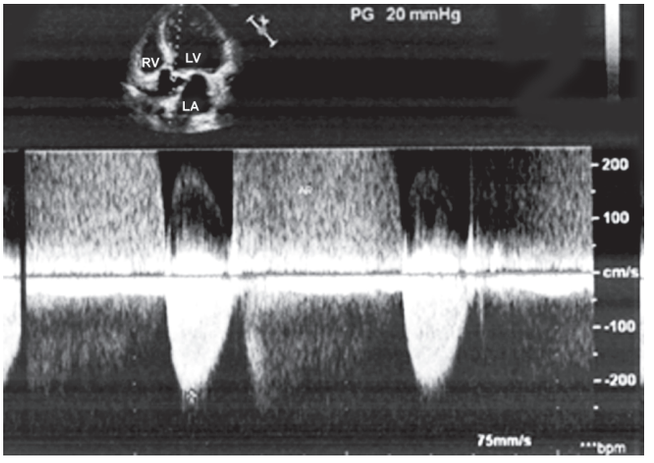

Fig. 16.64: Doppler tracing in aortic regurgitation (bottom) in apical five chamber view (top)

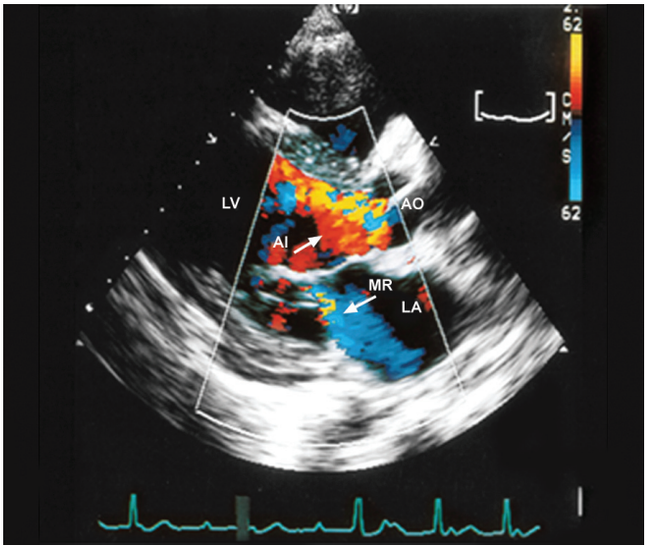

Fig. 16.66: Parasternal long-axis image of acute severe aortic regurgitation (AR). The accompanying marked elevation of LV diastolic pressure causes diastolic mitral regurgitation (MR). Ao=aorta; LA=left atrium; LV=left ventricle

Doppler echocardiography can lead to an underestimation of the severity of regurgitation, particularly if the regurgitant jet is eccentric. If a transthoracic study is not conclusive, transesophageal echocardiography (TEE) can reveal the mechanism and severity of the regurgitation. In prosthetic valve dysfunction, TEE can also show artifacts. Interpreting the results of TEE is often crucial to the planning of operative repair, such as the identification of leaflet or annular involvement. During planning for the use of aortic homografts or a Ross repair, TEE data on annular size are indispensable. However, if TEE results will not change the decision to perform surgery, the images can be obtained in the operating room.

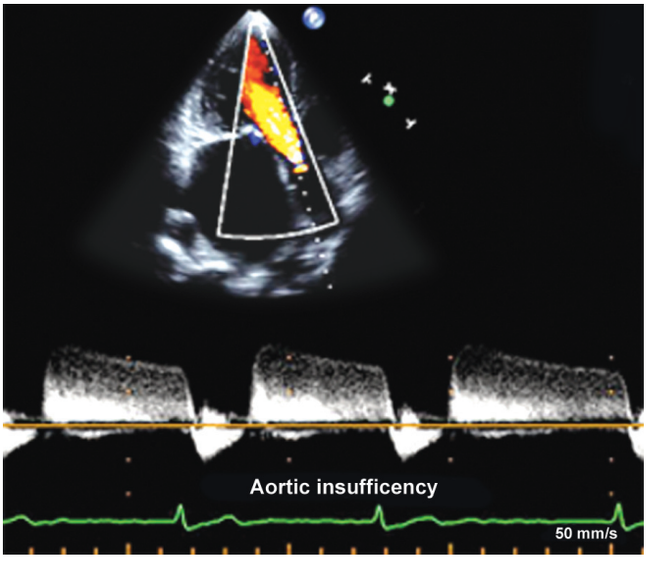

Fig. 16.65: Color-Doppler tracing in aortic regurgitation

Cardiac CT Scanning and Magnetic Resonance Imaging

Cardiac computed tomography (CT) scanning and magnetic resonance imaging (MRI) have not yet achieved widespread adoption in the management of AR, although support in the literature is increasing for the potential clinical use of these imaging techniques (Figs 16.67 and 16.68).

Radionuclide Imaging

Radionuclide imaging may provide complementary clinical information, including the AR regurgitant fraction and the LV/right ventricular (RV) stroke volume ratio. In the absence of mitral regurgitation and tricuspid regurgitation,

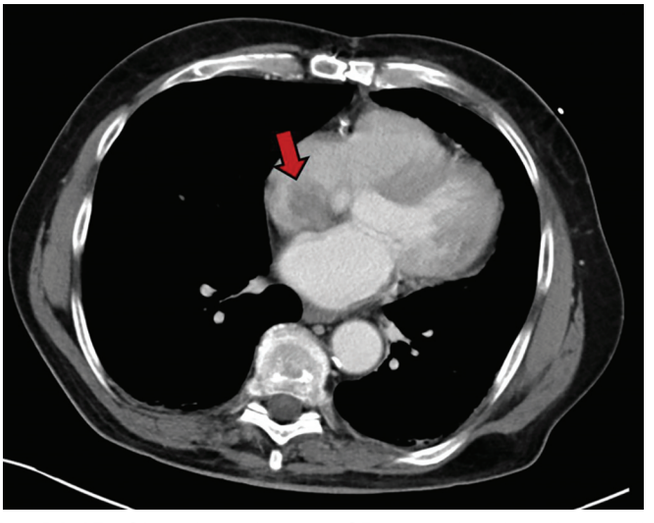

Fig. 16.67: Chamber view on CT scan showing the aortic regurgitation

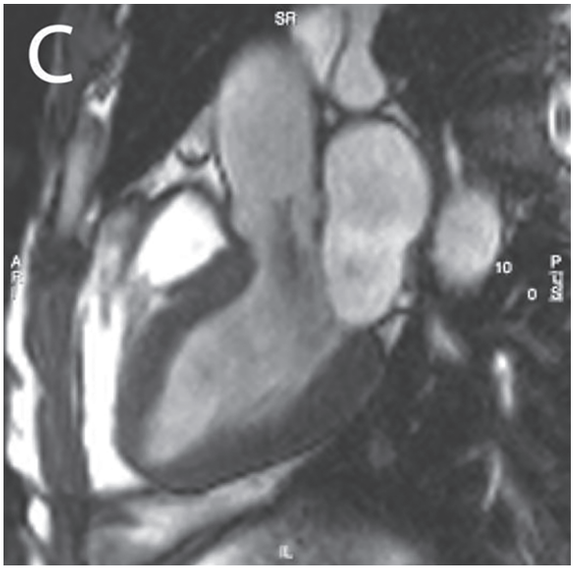

Fig. 16.68: Chamber view showing the aortic regurgitation. Cardiac magnetic resonance (CMR) imaging confirmed a quadricuspid valve with four equal and fully separated cusps (Hurwitz and Roberts type A) and a central regurgitation orifice

an LV/RV stroke volume ratio of 2.5 or more denotes severe aortic regurgitation. Demonstration of a fall in the EF with exercise is one of the most important indications for surgery in patients who are asymptomatic (Fig. 16.69).

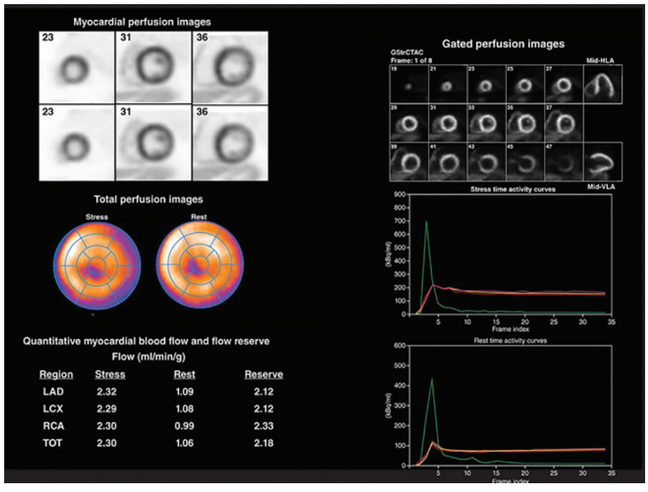

Fig. 16.69: Multidimensional cardiac imaging protocol with positron emission tomography. The *left upper panel* demonstrates stress and rest short-axis images of the left and right ventricles demonstrating normal regional myocardial perfusion. The middle panel demonstrates the quantitative bull's-eye display to evaluate the extent and severity of perfusion defects. The *lower right panel* illustrates the time-activity curves for quantification of myocardial blood flow. The *right upper panel* demonstrates electrocardiogram-gated myocardial perfusion images from which one can determine the presence of regional wall motion abnormalities and calculate left ventricular volumes and ejection fraction. LAD=left anterior descending artery; LCX=left circumflex artery; RCA=right coronary artery; TOT=total left ventricle

Left-heart Catheterization

It is not routinely indicated in the preoperative evaluation of patients with acute valvular regurgitation. Catheterization can be considered when electrocardiographic changes suggest acute ischemia. Patients with acute mitral regurgitation from ischemia or papillary muscle rupture may benefit from revascularization along with mitral valve repair or replacement. Conversely, patients whose mechanisms of regurgitation are nonischemic (such as mitral regurgitation due to chordal rupture or aortic regurgitation) may poorly tolerate the contrast medium and the time needed for catheterization. Patients with aortic dissection rarely require cardiac catheterization, and the procedure may worsen the dissection. When the aortic dissection is diagnosed by use of echocardiography, cross-sectional imaging can fully reveal the dissection anatomy; however, in most instances, cross-sectional imaging leads to the diagnosis before echocardiography does. Because the morbidity and mortality rates of acute severe regurgitation are high if it is untreated, rapid diagnosis is crucial. Definitive treatment should not be delayed (Fig. 16.70).

Aortic Angiography

Aortic angiography, which may be performed during a cardiac catheterization procedure, may provide useful information regarding the severity of the patient's AR (Fig. 16.71). Traditional angiographic grading is as follows:

- Mild (1+): A small amount of contrast enters the LV during diastole and clears with each systole.
- Moderate AR (2+): Contrast enters the LV with each diastole, but the LV chamber is less dense than the aorta.
- Moderately severe AR (3+): The LV chamber is equal in density to the ascending aorta.
- Severe AR (4+): Complete, dense opacification of the LV chamber occurs on the first beat, and the LV is more densely opacified than the ascending aorta.

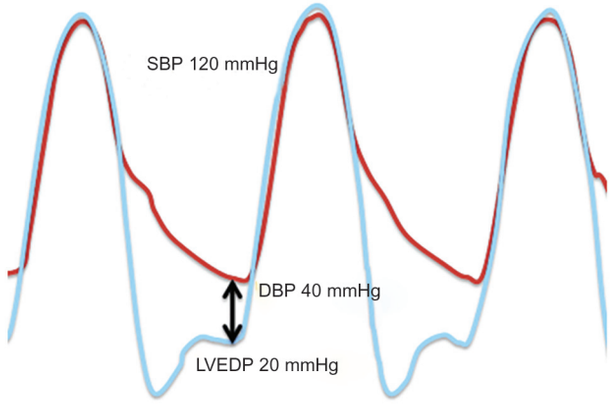

=[(DBP – LVEDP)/SBP]×100
=[(40–20)/120]×100 = 16.7

Fig. 16.70: The AR index is strongly associated with the severity of peri-AR and independently predicts 1-year mortality after TAVI. It provides prognostic information that is complementary to the degree of peri-AR and can be used to guide periprocedural clinical decisions

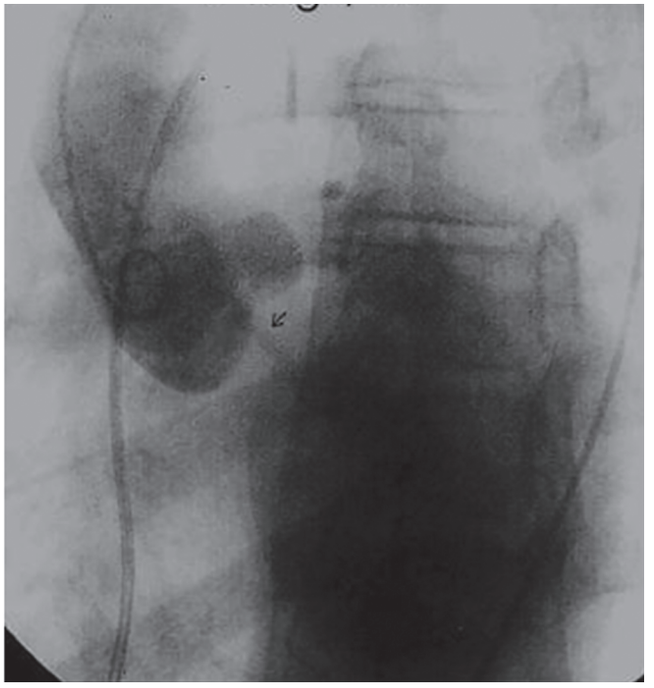

Fig. 16.71: Aortic regurgitation. Aortic-root angiography shows regurgitation of contrast material into the left ventricle (LV)

Assessment of the anatomy of the aorta and coronary ostia usually produces normal findings, except for the visible reflux of dye from the aortic root into the ventricle.

Medical Therapy

Chronic:

- Preload and afterload reduction
- Digoxin
- Diuretics
- Endocarditis prophylaxis/education

Acute

- Preload and afterload reduction
- Intra-aortic balloon pump
- Urgent surgery

The treatment for acute aortic regurgitation is aortic valve repair or replacement. Medical therapy can stabilize the patient's condition before surgery, but it is not a substitute for surgery. Vasodilators such as sodium nitroprusside can be used to improve forward flow, and inotropic agents such as dobutamine can improve the patient's cardiac output. Intra-aortic balloon pumps (IABPs) tend to be contraindicated in acute aortic regurgitation, because balloon inflation during diastole may impair LV hemodynamics. Balloon use is specifically contraindicated in cases of aortic dissection.

Surgical Treatment of Acute Aortic Valve Regurgitation

- *Anesthetic Considerations:* Inducing anesthesia in a critically ill patient who has acute aortic regurgitation can be a challenge. Low diastolic pressure, tachycardia, and increased wall stress can impair coronary flow. If anesthesia further reduces blood pressure, coronary ischemia can exacerbate the patient's unstable condition. Therefore, the anesthesiologist should try to prevent tachycardia or hypotension during intubation and the induction of anesthesia. Hemodynamic monitoring is also crucial, and in many cases monitoring lines will have been placed before the patient's arrival in the operating room. The appropriate use of inotropic drugs, vasoconstrictors, sedatives, and anesthetic agents can increase the chances of optimal outcomes. The surgical team should be present during induction, ready to initiate support if the patient experiences cardiopulmonary collapse.
- *Surgical Considerations:* Surgical options depend upon the pathophysiology and anatomy of the valve and the expected long-term outcome of correcting the acute aortic regurgitation. Myocardial protection is crucial, because the incompetent aortic valve and any associated aortic root disorder makes the antegrade delivery of cardioplegic solution ineffective or even dangerous. The reliable placement of a coronary sinus cannula for retrograde delivery of cardioplegic solution is essential. Necessity may justify placing bicaval cannulae and directly intubating the coronary sinus. Then, after the aortic valve and root have been properly evaluated, adjuvant cardioplegic solution can be delivered from a handheld apparatus through the coronary ostia. A LV vent placed through the right superior pulmonary vein may aid ventricular decompression and diastolic arrest. The value of other protective adjuncts, such as topical cooling or systemic hypothermia on cardiopulmonary bypass (CPB), is unclear (Fig. 16.72).

Aortic Valve Endocarditis

- Aortic valve endocarditis can prevent leaflet coaptation, lead to leaflet erosion, or affect the aortic annulus—singly or in combination. During planning for surgery, directly evaluating the aortic annulus by use of intraoperative TEE is important. Annular integrity can be compromised by abscess formation and endocarditic

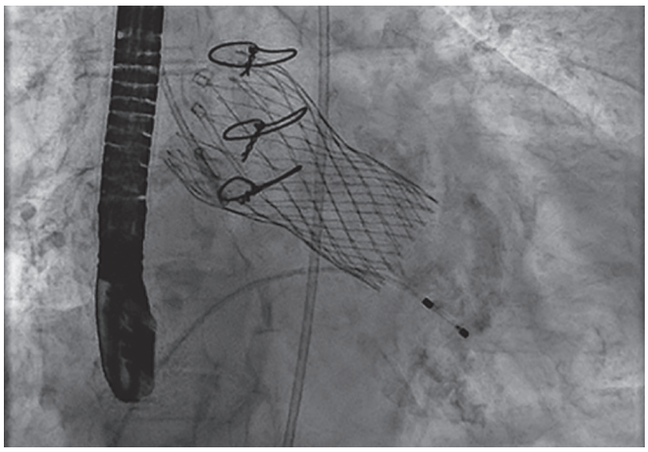

Fig. 16.72: Self-expanding replacement aortic valve placed during TAVR procedure

erosion. In cases of annular involvement, the use of a homograft is typically recommended. Although aortic homografts are susceptible to prosthetic valve endocarditis, the additional tissue included with the homograft (the LV outflow tract and the anterior leaflet of the mitral valve) is sometimes essential for successful aortic root reconstruction. When endocarditis is limited to the valve leaflets, procedures beyond leaflet excision and aortic valve replacement are not indicated. Because the rates of infection are similar between mechanical and bioprosthetic replacement valves, after native-valve endocarditis, either type is suitable.

- Some centers use a pulmonary autograft (the Ross procedure), particularly in children. However, as in elective aortic valve surgery, the benefits and risks of the Ross repair are debatable. In theory, a durable aortic valve replacement will grow with a child and not require future intervention. On the other hand, 'single-valve disease' becomes 'double-valve disease,' and data suggest that the new aortic valve requires replacement in 10–20% of patients within 10 years of the operation. Thus, the long-term outcomes may offset the theoretical benefit. Some patients cannot tolerate additional CPB time, so Ross repair is limited to a specific patient population in centers that have had extensive surgical experience. Finally, depending upon the clinical status of the patient and the condition of the aortic root, a 2-staged approach may be beneficial; simple valve replacement, followed by root reconstruction after the patient has recovered from multisystem organ failure.

Aortic Dissection

- Stanford type A dissection can lead to aortic insufficiency through various pathophysiologic processes, and the cause dictates the treatment. When an aortic valve is trileaflet, reconstructing the aortic root with valve resuspension and replacing the ascending aorta with an interpositional graft can frequently correct valvular regurgitation. This is accomplished by reestablishing the commissural heights at the sinotubular junction and reattaching the sinuses of Valsalva to the aortic wall. When an aortic valve is bicuspid or when there is an aneurysm of the ascending aorta, correction can be achieved by performing a modified Bentall procedure, using a valved conduit with direct coronary reimplantation. A study of aortic root replacement with the use of mechanical conduits and aortic allografts revealed no significant difference in 1-and 5-year survival rates on the basis of conduit choice, including in patients with aortic dissection. Aortic root remodeling surgery (the Yacoub procedure) and aortic root reimplantation (the David procedures) have also been used successfully in aortic dissection. However, coronary ischemia can occur due to coronary artery involvement from aortic dissection or technical problems with coronary artery reimplantation, and surgical expertise is necessary for optimal outcomes.

Trauma or Ruptured Fenestration

- Leaflet disruption can occur consequent to trauma or ruptured fenestration. Anatomy permitting, the leaflets can be successfully repaired most commonly by patching with autologous pericardium. Other pericardial substitutes have also been used. Nonetheless, valve replacement is the safest choice for most surgeons. In blunt chest trauma, aortic valve regurgitation most often occurs because of leaflet perforation, dissection, or loss of commissural suspension. The choice of repair, replacement, or reconstruction depends upon the surgical anatomy.

TRICUSPID VALVE DISORDERS

Isolated valvular disorders of the right side of the heart (receiving and pumping venous blood to the lungs for oxygenation) are much less common than left sided valvular disease. Combined left (mitral and/or aortic) and right (tricuspid and/or pulmonic) heart valvular disease is more common.

1. TRICUSPID VALVE STENOSIS

It is defined as narrowing of valvular area from its normal range due to many causes as follows:

Aetiology

At least four conditions can cause obstruction of the native tricuspid valve. These include (1) rheumatic heart disease, (2) congenital abnormalities, (3) metabolic or enzymatic abnormalities, (4) active infective endocarditis.

- **Rheumatic tricuspid stenosis:** In this entity, diffuse thickening of the leaflets occurs, with or without fusion of the commissures. The chordae tendineae may be thickened and shortened. Calcification of the valve rarely occurs. The leaflet tissue is composed of dense collagen and elastic fibers that produce a major distortion of the normal leaflet layers.
- **Carcinoid heart disease:** Carcinoid valve lesions characteristically manifest as fibrous white plaques located on the valvular and mural endocardium. The valve leaflets are thickened, rigid, and reduced in area. Fibrous tissue proliferation is present on the atrial and ventricular surfaces of the valve structure.
- **Congenital tricuspid stenosis:** These lesions are observed more commonly in infants. They may manifest as incompletely developed leaflets, shortened or malformed chordae, small annuli, abnormal size and number of the papillary muscles, or any combination of these defects.
- **Infective endocarditis:** Large infected vegetations obstructing the orifice of the tricuspid valve may produce stenosis. This condition is relatively uncommon, even in those who abuse intravenous drugs.
- **Unusual causes:** Rare causes of tricuspid stenosis include Fabry disease and giant blood cysts.

- **Mimickers of tricuspid stenosis:** Several conditions may mimic tricuspid stenosis by obstructing flow through the valve. These conditions include supravalvular obstruction from congenital diaphragms, intracardiac or extracardiac tumors, thrombosis or emboli, or large endocarditis vegetations. In addition, conditions that impair right-sided filling can produce similar symptoms and physical findings. These conditions include *constrictive pericarditis* and *restrictive cardiomyopathy*.

Symptoms and Signs

- Fatigue, due to limited cardiac output, may be present.
- Systemic venous congestion leads to abdominal discomfort and swelling. The onset is usually gradual, but it may be rapid if atrial fibrillation or flutter develops.
- Dyspnea may be present but is not severe unless concomitant mitral valve disease is present.
- Patients may complain about prominent pulsations in the neck.
- When tricuspid stenosis occurs concomitantly with mitral stenosis, the decrement of cardiac output to the pulmonary bed may paradoxically diminish the dyspnea, hemoptysis, and orthopnea typically seen with mitral stenosis.
- Obtain information regarding preceding rheumatic fever, symptoms of the carcinoid syndrome, and possible congenital abnormalities.

Physical Examination

- With sinus rhythm (more common with tricuspid stenosis than with mitral stenosis), the jugular venous pulse increases and the A wave is prominent (may be confused with an arterial pulse).
- If atrial fibrillation occurs, the A wave is lost.
- Peripheral edema and ascites are frequent.
- Without significant mitral pathology, the patient should not be dyspneic and can probably lie flat without symptoms.
- A prominent right atrium may be palpable to the right of the sternum. If not obscured by mitral stenosis sounds, a tricuspid opening snap may be heard. A diastolic murmur is audible along the left sternal border or at the xiphoid, which increases with inspiration. Often, *tricuspid regurgitation* is also present, represented by a holosystolic murmur in a similar location.
- The first heart sound may be split widely. The second heart sound may be single. This single sound is due to the inaudible closure of the pulmonary valve from the decrease in blood flow through the stenotic tricuspid valve.

Chest radiography: Cardiac size may range from normal to enlarged, (i.e. cardiomegaly). Right atrial enlargement may be prominent. Findings specific to a particular associated congenital heart disease may also be seen (Fig. 16.73).

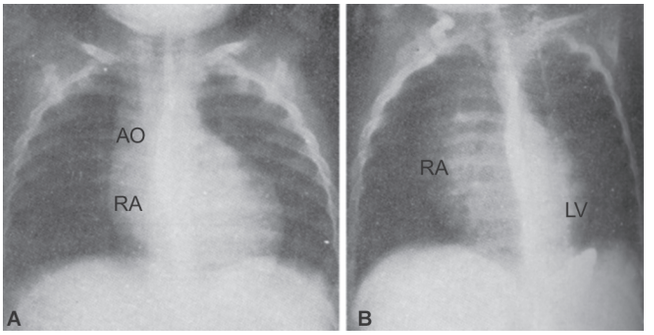

Fig. 16.73: Chest X-ray in a patient withsevere form of *tricuspid stenosis* demonstrating the following features: (A) reduced pulmonary blood flow, prominent *aortic root* (AO) and *right atrium* (RA), (B) the left anterior oblique projection on the right side shows distinctive humped appearance of the anterior cardiac silhouette due to *right atrial* (RA) enlargement in the absence of a *right ventricle*. The *left ventricle* (LV) is enlarged

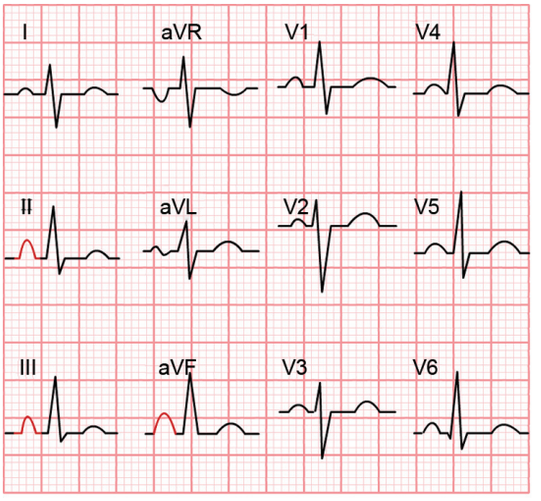

Fig. 16.74: Right atrial enlargement produces a peaked P-wave (P pulmonale) with amplitude >2.5 mm in the inferior leads (II, III and AVF) >1.5 mm in V1 and V2 in a patient with tricuspid stenosis

Electrocardiogram: Arrhythmias are frequent in this patient population. Because of the enlargement of the right atrium, the presence of atrial flutter and/or fibrillation should not be surprising. In sinus rhythm, right atrial enlargement or abnormality (tall P-waves on inferior leads) may be noted (Fig. 16.74).

Echocardiography: This test has become the procedure of choice for the diagnosis of valvular disorders. The test results help delineate the structure of the tricuspid valve and any other intracardiac pathology that may contribute to the pathophysiology of the process (Fig. 16.75).

Procedures

Cardiac catheterization: This may be required prior to surgery in older patients to assess for concomitant coronary artery disease. Right heart catheterization can be used to determine the gradient across the valve and valve area (i.e.

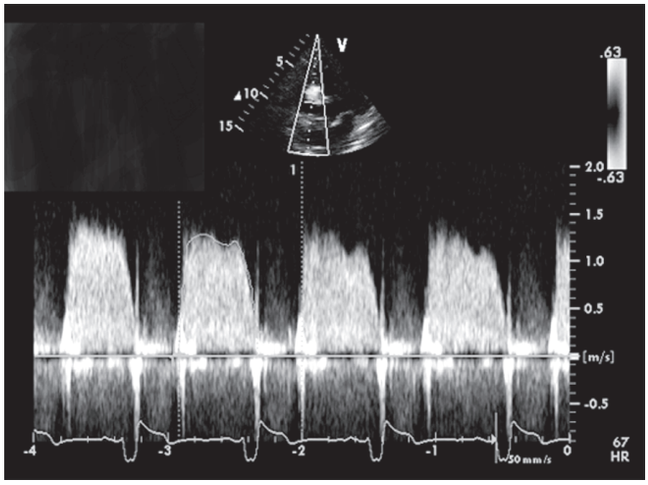

Fig. 16.75: CW Doppler echocardiogram of a patient showing tricuspid valve stenosis

severity of stenosis) and assess the presence of associated congenital defects (e.g. septal defects, intracardiac shunts, anomalous veins) if present. Assessment of aortic and mitral valves via left heart catheterization is useful in patients with rheumatic disease (Fig 16.76).

Management of Tricuspid Stenosis

Medical Treatment

Digoxin (Lanoxin): Used for prophylaxis and treatment of venous thrombosis, pulmonary embolism, and thromboembolic disorders. Cardiac glycoside with direct inotropic effects and indirect effects on the cardiovascular system. Acts directly on cardiac muscle and increases myocardial systolic contractions. Indirect actions result in increased carotid sinus nerve activity and enhanced sympathetic withdrawal for any given increase in mean arterial pressure.

Warfarin (Coumadin): Interferes with hepatic synthesis of vitamin K-dependent coagulation factors. Tailor dose to maintain an INR in the range of 2–3.

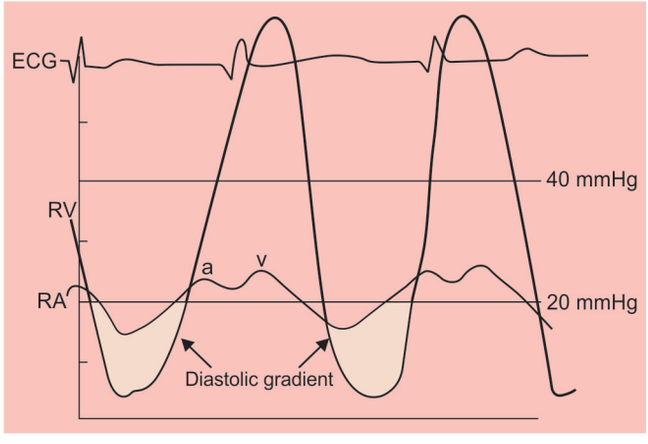

Fig 16.76: Tracings of simultaneous right atrial (RA) and right ventricular (RV) pressure waveforms in a patient with tricuspid stenosis

Surgical Care (Fig. 16.77)

- Tricuspid stenosis remains a surgical disease and requires either commissurotomy or replacement of the valve if right heart failure or low cardiac output has resulted. Surgery is rarely performed solely on the tricuspid valve; it is usually performed in combination with mitral and/or aortic valve disease repair.
- With tricuspid valve replacement, the risk of thrombosis is significant and many surgeons advise warfarin therapy for either mechanical or bioprosthetic valve placement.
- Percutaneous balloon valvuloplasty has been used successfully, as long as concomitant regurgitation is not significant.
- The therapy chosen depends on the structure of the valve and the degree of deformity encountered.
- When possible, excise intracavitary pathology, whether it be tumors or other structural abnormalities.
- Redundant portions of the dilated right atrium can be excised during the same procedure for restoring the atrium back to normal size.

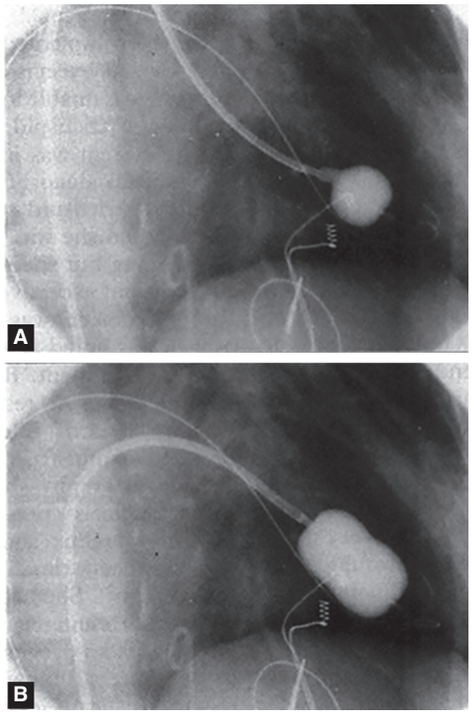

Fig. 16.77: The Inoue balloon was used for dilatation of tricuspid stenosis in an adolescent. The valve was reached by an over-the-wire approach with a 0.025 exchange length guide wire. The Inoue stylet would not reach the tricuspid orifice because the right atrium was so large. The Inoue balloon's special dilatation characteristics allowed good positioning at the tricuspid orifice. After dilatation to 27.5 mm, the pressure drop across the valve was reduced from 12–5 mmHg. Further dilatation at 30 mm, however, created moderately severe tricuspid reflux without a further reduction of gradient. The Inoue balloon is suitable for dilatation of tricuspid stenosis but small increments in dilatation size may be required for optimal reduction in gradient without creating significant reflux

- In selected patients with prior tricuspid valve surgery and significant stenosis of a bioprosthetic tricuspid valve or a right atrium to right ventricle (RA-to-RV) conduit, percutaneous tricuspid valve replacement may be an option.
- Transcatheter valve-in-valve implantation with either the Melody or Edwards SAPIEN valve may be a potential procedure for patients with significant tricuspid stenosis, significant tricuspid regurgitation, or a mixed lesion and a failing bioprosthesis.

Complications

Complications that can be encountered after tricuspid valve replacement include infection of the prosthetic valve, particularly in those instances when endocarditis was present preoperatively. Tricuspid insufficiency and thromboembolization can also occur.

Prognosis

The prognosis is generally good if therapy is provided for tricuspid stenosis. For those cases in which tumors are the cause of the stenosis, the prognosis is directly related to the prognosis of the underlying disease. In those cases of precipitating infection, if the behavior that caused the initial infection (e.g. intravenous drug use) can be modified, prognosis for the patient is good.

Further inpatient care: Inpatient care consists of treating the underlying precipitating condition. For acute bacterial endocarditis or rheumatic causes, antibiotic therapy is indicated until the acute phase has resolved. Then, valve surgery can be considered, if indicated. After valve replacement, inpatient care consists of regulating the anticoagulation and treating postoperative arrhythmias until stability has been achieved. After valve replacement, adjust anticoagulation to an international normalized ratio (INR) of 3–4 because of the low-pressure and low-flow state of the right side. Because of the high risk of thrombosis in this low-pressure system, some authors recommend warfarin therapy for bioprosthetic or mechanical valves.

2. TRICUSPID VALVE REGURGITATION

It is defined as leakage of blood into the right atrium during systole of right ventricle.

Clinical History

Patients with tricuspid regurgitation present with the signs and symptoms of right-sided heart failure. The spectrum of presenting symptoms depends on whether the condition is secondary to left ventricular (LV) dysfunction.

Common presenting complaints in patients with LV dysfunction include the following:

- Dyspnea on exertion
- Orthopnea
- Paroxysmal nocturnal dyspnea
- Ascites
- Peripheral edema
- Exercise intolerance may also be observed. Rarely, patients report angina, which may result from RV overload and strain, even in the absence of coronary artery disease
- These patients, especially those experiencing febrile episodes, must be questioned regarding risk factors for *infective endocarditis*, which is a common cause of tricuspid valvular disease. Risk factors include intravenous drug use, alcoholism, and a history of *rheumatic fever*.

Physical Examination

Findings on cardiovascular examination in patients with tricuspid regurgitation include the following:

- S_3 gallop
- Jugular venous distention with a prominent V wave
- In some patients, a pansystolic murmur
- Diminished peripheral pulse volume secondary to impaired forward blood flow; patients with this sign may have relative hypotension secondary to therapeutic interventions used to decrease volume overload
- Pulmonary rales, if the tricuspid regurgitation is associated with left ventricular dysfunction or *mitral stenosis*
- Right ventricular heave and S_4 gallop that increases with inspiration
- Ascites
- Peripheral edema
- Cachexia and jaundice
- Atrial fibrillation
- The pansystolic murmur associated with tricuspid regurgitation is high pitched and is loudest in the fourth intercostal space in the parasternal region. The murmur is usually augmented during inspiration and is reduced in intensity and duration in the standing position and during a Valsalva manoeuvre. A short, early diastolic flow rumble may be present due to increased flow across the tricuspid valve.

Laboratory Studies

Serum chemistry: Findings in patients with tricuspid regurgitation may include abnormal liver function and hyperbilirubinemia secondary to liver congestion.

Chest radiography: Findings on chest radiography in patients with tricuspid regurgitation include the following (Fig. 16.78):

- Marked cardiomegaly
- Evidence of elevated right atrial pressure may include distention of the azygous vein and pleural effusions.
- Ascites with diaphragmatic elevation may be present.
- Pulmonary arterial and venous hypertension is common.

Electrocardiography

ECG findings are usually nonspecific. Typical abnormalities are incomplete right bundle-branch block, Q-waves in lead V1, and atrial fibrillation (Fig. 16.79).

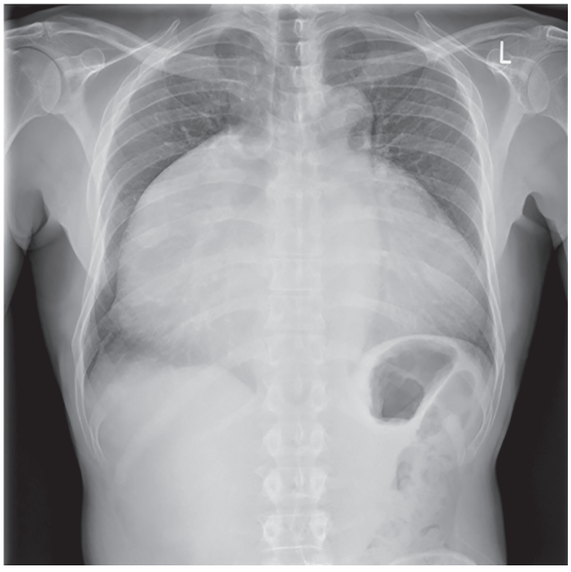

Fig. 16.78: Chest X-ray (PA view) showing cardiomegaly with dilatation of RV which was severely impaired, a gigantic RA with free TR and a normal sized LV

Echocardiography

Color flow Doppler echocardiography is a mainstay for evaluating tricuspid regurgitation. Doppler techniques are used to directly visualize regurgitant jets, measure the flow velocities of the regurgitant jets, and accurately estimate right ventricular systolic pressure (Figs 16.80–16.83).

In trivial-to-mild tricuspid regurgitation, the jet is central and narrow. In moderate-to-severe pulmonic regurgitation, the width of the jet increases, as does the penetration of the jet into the right atrium.

European Society of Cardiology (ESC)/European Association for Cardio-Thoracic Surgery (EACTS) echocardiographic criteria for severe tricuspid regurgitation include the following:

- Abnormal/flail/large coaptation defect
- Very large color flow central jet or eccentric wall impinging jet
- Dense/triangular continuous-wave signal of regurgitant jet with early peaking

Echocardiography is also extremely useful in determining whether the incompetence of the valve is from primary

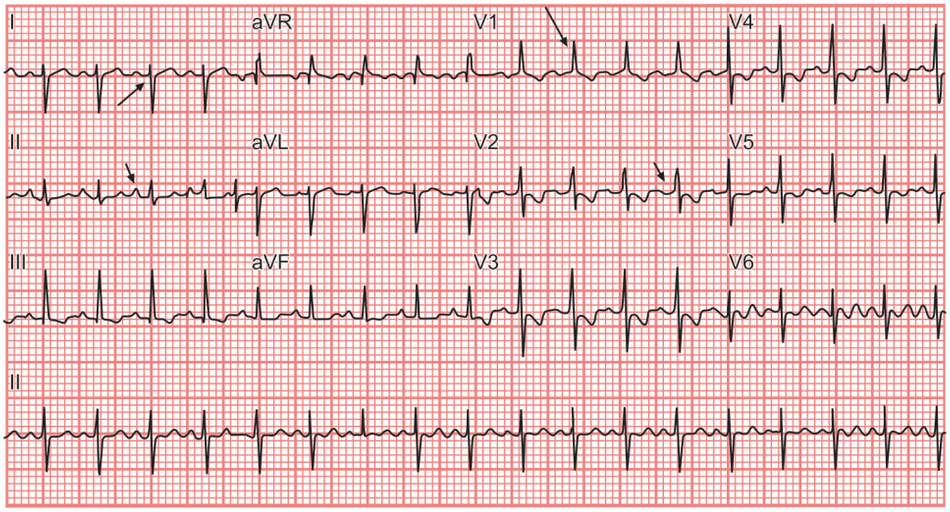

Fig. 16.79: Electrocardiogram demonstrating the changes of right ventricular hypertrophy (long arrow) with strain in a patient with primary pulmonary hypertension. Right axis deviation (short arrow), increased P-wave amplitude in lead II (black arrowhead), and incomplete right bundle branch block (white arrowhead) are highly specific but lack sensitivity for the detection of right ventricular hypertrophy

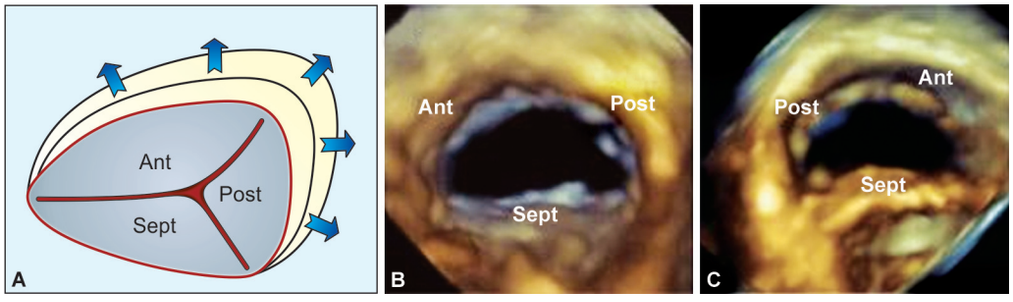

Fig. 16.80: 3D TTE assessment of the tricuspid valve. (A) Schematic of the tricuspid valve annulus as it becomes more dilated and circular with tricuspid regurgitation. 3D TTE zoomed view of a normal tricuspid valve from the (B) right atrial and (C) right ventricular perspectives. Ant=anterior; Post=posterior; Sept=septum

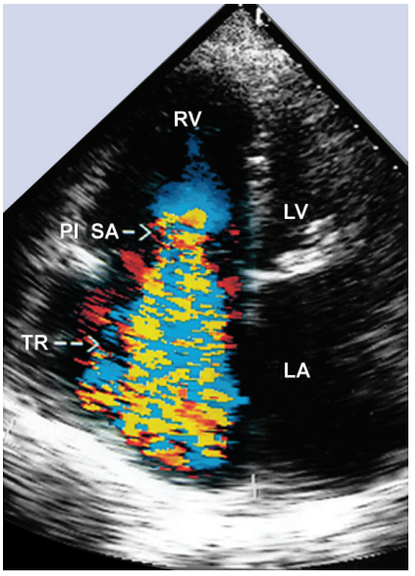

Fig. 16.81: Apical four-chamber view of severe tricuspid regurgitation. The Doppler color jet fills the tricuspid regurgitation. LA=left atrium; LV=left ventricle; PISA=proximal isovelocity surface area; RV=right ventricle; TR=tricuspid regurgitation

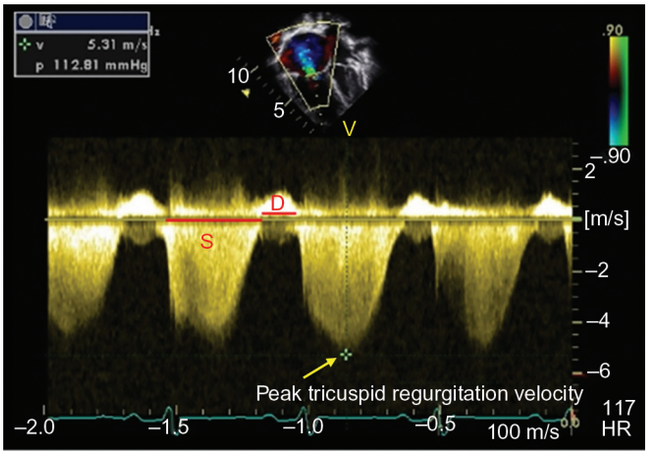

Fig. 16.83: Tricuspid regurgitation estimating right ventricular pressure in a patient with pulmonary hypertension. Systolic (S) to diastolic (D) ratio from tricuspid regurgitation velocity can be measured

structural abnormalities of the leaflets and chordae or from secondary myocardial dysfunction and dilatation.

Other possible findings on echocardiography include the following:

- Prolapse of the tricuspid valve, endocarditis, rheumatic heart disease, or Ebstein anomaly may be evident
- The right ventricle is dilated
- Paradoxical motion of the ventricular septum is observed and is similar to that found in an *atrial septal defect*

Using pulsed wave and continuous wave Doppler, right ventricular and pulmonary arterial systolic pressure can be estimated (using continuous wave Doppler) by measuring the peak regurgitant flow velocity across the

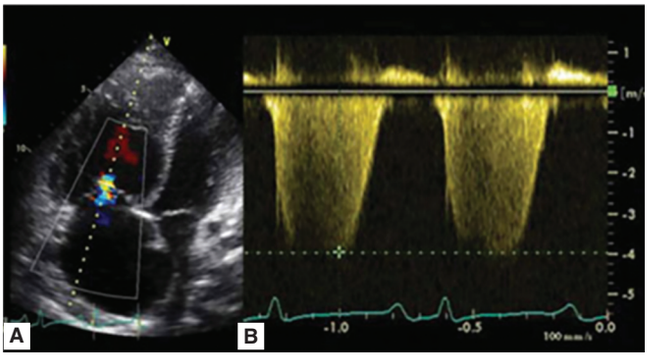

Fig. 16.82: (A) 2D Apical 4C view showing tricuspid regurgitation jet into right atrium. (B) Continuous wave (CW)-color Doppler showing tricuspid regurgitant jet

tricuspid valve, converting it to a pressure gradient (by use of the modified Bernoulli equation), and then adding the gradient to an estimate of the right atrial pressure Yang and colleagues proposed that quantification of tricuspid regurgitation by Doppler echocardiography is crucial for estimating prognosis. Their study in patients with severe isolated tricuspid regurgitation found that vena contracta width (VCW) of more than 7 mm is a powerful independent predictor of worsening heart failure, tricuspid valve surgery, and cardiovascular death.

Cardiac catheterization: On cardiac catheterization, right atrial pressure and right ventricular end-diastolic pressure are elevated. A rise or no change in right atrial pressure on deep inspiration is characteristic of tricuspid regurgitation. The use of angiography in this setting is controversial (Fig. 16.84).

Medical Therapy

The medical therapy used in the treatment of tricuspid regurgitation is directed toward the control of heart failure that is causing or contributing to the problem. Drugs used include diuretics, digoxin, and angiotensin-converting enzyme (ACE) inhibitors. Patients who have atrial fibrillation

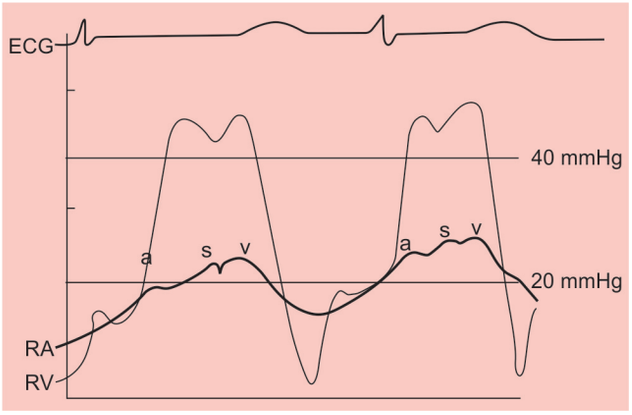

Fig. 16.84: Tracings of simultaneous right atrial (RA) and right ventricular (RV) pressure waveforms in a patient with tricuspid regurgitation

or who have received a prosthetic valve require anticoagulation. For patients in whom tricuspid regurgitation is secondary to left-sided heart failure, treatment centers on adequate control of fluid overload and failure symptoms (e.g. diuretic therapy). Patients should be instructed to reduce their intake of salt. Elevation of the head of the bed may improve symptoms of shortness of breath.

Furosemide (Lasix): Furosemide increases excretion of water by interfering with the chloride-binding cotransport system, which in turn inhibits sodium and chloride reabsorption in the ascending loop of Henle and distal renal tubule. The dose must be individualized to the patient. Depending on response, administer at increments of 20–40 mg, no sooner than 6–8 h after the previous dose, until desired diuresis occurs. When treating infants, titrate with 1 mg/kg/dose increments until a satisfactory effect is achieved.

Digoxin (Lanoxin, Digox): Digoxin is a cardiac glycoside with direct inotropic effects in addition to indirect effects on the cardiovascular system. This agent acts directly on cardiac muscle, increasing myocardial systolic contractions. Its indirect actions result in increased carotid sinus nerve activity and enhanced sympathetic withdrawal for any given increase in mean arterial pressure.

ACE inhibitors are used to provide afterload reduction, thereby decreasing the volume load on the right ventricle.

Captopril: Captopril prevents conversion of angiotensin I to angiotensin II, a potent vasoconstrictor, resulting in increased levels of plasma renin and a reduction in aldosterone secretion.

Enalapril (Vasotec): Enalapril is a competitive ACE inhibitor that reduces angiotensin II levels and decreases aldosterone secretion.

Lisinopril (Zestril, Prinivil): Lisinopril prevents conversion of angiotensin I to angiotensin II, resulting in decreased aldosterone secretion.

Anticoagulants, Cardiovascular: In patients who have undergone valve replacement for treatment of severe tricuspid regurgitation, anticoagulants are used to prevent thrombosis and embolization from the prosthetic valve.

Warfarin (Coumadin, Jantoven): Warfarin interferes with hepatic synthesis of vitamin K-dependent coagulation factors. It is used for prophylaxis and treatment of venous thrombosis, pulmonary embolism, and thromboembolic disorders. Tailor the dose to maintain an international normalized ratio (INR) in the range of 2–3.

Surgical Care: Guidelines from the European Society of Cardiology and the European Association for Cardio-Thoracic Surgery (ESC/EACTS) note that the need for correction of tricuspid regurgitation is usually considered at the time of surgical correction of left-sided valve lesions (Fig. 16.85).

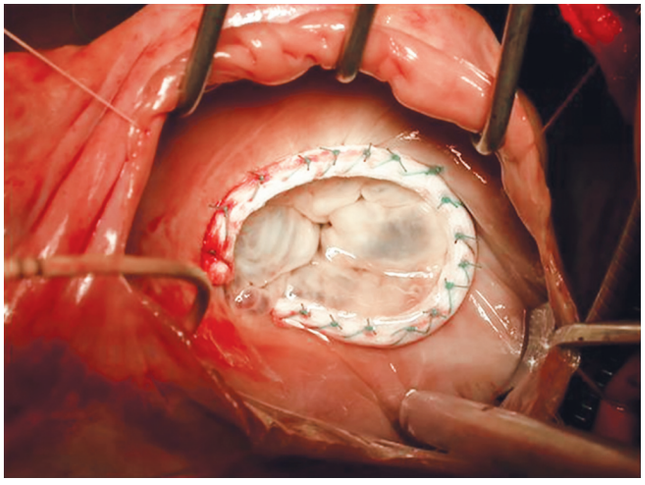

Fig. 16.85: Tricuspid valve annuloplasty using semiflexible ring (provided Doc. Petr Nìmec, M.D., PhD., Center of Cardiovascular and Transplant Surgery, Brno, Czech Republic)

Class I ESC/EACTS indications for tricuspid valve surgery are as follows:

- Symptomatic patients with severe tricuspid stenosis
- Patients with severe tricuspid stenosis undergoing left-sided valve intervention
- Patients with severe primary or secondary tricuspid regurgitation undergoing left-sided valve surgery
- Symptomatic patients with severe isolated primary tricuspid regurgitation without severe right ventricular (RV) dysfunction

Class IIa ESC/EACTS indications for tricuspid valve surgery are as follows:

- Patients with moderate primary tricuspid regurgitation undergoing left-sided valve surgery
- Patients with mild or moderate secondary tricuspid regurgitation with dilated annulus undergoing left-sided valve surgery
- Asymptomatic or mildly symptomatic patients with severe isolated primary tricuspid regurgitation and progressive RV dilatation or deterioration of RV function

The ESC/EACTS guidelines also recommend that after left-sided valve surgery, isolated tricuspid valve surgery should be considered in patients with severe tricuspid regurgitation who are symptomatic or who have progressive RV dilatation/dysfunction, provided that they do not have left-sided valve dysfunction, severe right or left ventricular dysfunction, or severe pulmonary vascular disease.

Severe regurgitation has been successfully treated with tricuspid annuloplasty. Long-term results with prosthetic rings are superior to those achieved with suture annuloplasty.

Long-term Monitoring

Patients with a history of tricuspid regurgitation should be carefully monitored for control of any heart failure. Repeat echocardiography is indicated at 6-month intervals

for patients in whom the valve has been removed. Annual echocardiography should be considered in patients whose valve has been replaced.

PULMONARY VALVULAR DISORDERS

Diseases of the pulmonary valve are most often congenital, and only rarely do acquired disorders such as carcinoid and *rheumatic fever* affect the pulmonary valve. The pulmonary valve may be stenotic or atretic, or the leaflets of the valve may be absent. Pulmonary stenosis may be valvar, supravalvar, or subvalvar (i.e. *double-chambered right ventricle*); it may also be in the branch pulmonary arteries. These lesions are collectively described as right ventricular outflow tract obstructions.

1. PULMONIC STENOSIS

A stenotic pulmonary valve usually occurs without associated congenital abnormalities, although it may be associated with other structural abnormalities of the heart. To distinguish the former from the latter, terms such as pulmonary stenosis with a normal aortic root or pulmonary stenosis with an intact ventricular septum have been used. However, the term isolated pulmonary valve stenosis is preferred. The term isolated may be used even when a patent foramen ovale or a small atrial septal defect is present. The term congenital need not be used because most are congenital.

Pathologic Anatomy

Pathologic features of the stenotic pulmonary valve vary. The most common pathology is a dome-shaped pulmonary valve. The fused leaflets of the pulmonary valve protrude from their attachment into the pulmonary artery as a conical, windsock-like structure. The size of the pulmonary valve orifice varies from a pinhole to several millimeters. The orifice is most usually central but can be eccentric. Raphae, presumably fused commissures of the valve, extend from the stenotic orifice to a variable distance down lmonary valve stenosis into the base of the dome-shaped valve. The number of the raphe may vary from 0–7. Relatively uncommon variants are unicommissural, bicuspid, and tricuspid valves. The valve annulus is abnormal in most cases, and the fibrous back bone is partially or completely lacking; therefore, a true annulus may not be present.

Hypoplasia of the pulmonary valve ring and dysplastic pulmonary valves may be present in a few of patients. Pulmonary valve dysplasia is characterized by thickened, nodular, and redundant valvular leaflets with minimal or no commissural fusion; hypoplasia of the valve ring; and lack of poststenotic dilatation of the pulmonary artery. The obstruction is mainly related to thickened, myxomatous, immobile pulmonary valve cusps and hypoplasia of the valve ring.

Changes secondary to pulmonary valve obstruction occur in the right ventricle and pulmonary artery. Hypertrophy of the right ventricular muscle is proportional to the degree (and perhaps the duration) of obstruction. The muscle hypertrophy is particularly prominent in the infundibular region and may become physiologically important; this appears to be related to the degree and duration of obstruction. Mild dilatation of the right ventricular cavity is present. In extremely severe or critical obstruction, the right ventricular cavity may be markedly dilated. In rare cases, the right ventricle may be hypoplastic.

The main pulmonary artery is dilated in almost all cases. This dilatation is independent of the severity of the pulmonary valve obstruction and presumably related to a high-velocity jet across the stenotic valve. As noted above, such poststenotic dilatation is remarkably absent in patients with dysplastic pulmonary valves. An interatrial communication, a *patent foramen ovale* or an *atrial septal defect* may be present and may be the seat for right-to-left shunt in patients with severe or long-standing pulmonary stenosis.

Pulmonary valve stenosis is the most common cardiac lesion in *Noonan syndrome* [phenotypically *Turner syndrome* and genotypically normal (XX or XY)]. Supravalvar pulmonary stenosis is often associated with rubella syndrome and Williams syndrome (i.e. elfin facies, supravalvar aortic stenosis, and hypercalcemia with or without mental retardation). Isolated infundibular or subvalvar pulmonary stenosis is uncommon and usually associated with a *ventricular septal defect (VSD)*, such as in tetralogy of Fallot. Peripheral pulmonary stenosis is frequently observed in newborns. It is related to relative narrowing of the branch pulmonary arteries and the acute angle of the origin of the branch pulmonary arteries at this age. This represents fetal pattern and, in most cases, resolves over time.

Clinical History

Most children with pulmonic stenosis, particularly those with trivial and mild pulmonary stenosis, present with asymptomatic cardiac murmurs that are detected during routine examination.

Patients with moderate or severe pulmonary stenosis may have mild exertional dyspnea. Adults may be asymptomatic irrespective of the severity of their obstruction.

Patients with severe or critical obstruction may present with signs of systemic venous congestion, which are usually interpreted as signs of congestive heart failure (CHF). The signs are due to severe right ventricular dysfunction or to cyanosis secondary to a right-to-left shunt across a patent foramen ovale or an atrial septal defect.

Lightheadedness, *syncope*, and chest pain that resembles angina pectoris are rare, even in patients with severe obstruction.

Of note, many patients with moderate or severe pulmonary stenosis remain asymptomatic.

Physical Examination

Degree of Obstruction

Physical findings depend on the degree of obstruction. Most patients with pulmonary stenosis appear healthy and are

well developed. Indeed, the chubby and rounded faces, described as moon facies, were initially thought to be characteristic for this anomaly, but this facial appearance is not a helpful diagnostic tool. Most patients with trivial, mild, or moderate stenosis, and many with severe stenosis, are acyanotic. However, some may have cyanosis secondary to an interatrial right-to-left shunt.

The jugular venous pulse is normal. However, in patients with decreased right ventricular compliance (i.e. severe stenosis), a prominent α wave may be visualized in the neck pulsation. Patients may have a concomitant presystolic pulsation in the liver as well.

In patients with trivial or mild obstruction, the right ventricular impulse is normal. When the pulmonary stenosis is moderate to severe, a sustained and forceful right ventricular impulse and a right ventricular heave are felt.

A thrill may be felt in the suprasternal notch and at the left upper sternal border (pulmonic area). The precordial thrill is most likely to be associated with severe obstruction, although no consistent relationship is observed between the thrill and the degree of obstruction.

Upon auscultation, the first heart sound may be normal in intensity or may be loud. The second heart sound is widely split. The width of the split increases with worsening stenosis. The intensity of pulmonary component of the second heart sound may be loud (in mild stenosis) or may be soft, diminished, or absent, depending on the severity of obstruction. A fourth heart sound may be heard at the left lower sternal border in patients with severe obstruction and is usually associated with prominent α wave in the jugular pulse.

An ejection systolic click is heard along the left sternal border and varies with respiration (decreases or disappears during inspiration). With increasing severity, the click comes closer to the first heart sound.

An ejection systolic murmur of grade II/VI to V/VI is best heard at the left upper sternal border with radiation into infraclavicular regions, axillae, or back. The intensity of the murmur is not necessarily related to the severity of pulmonary valve obstruction, but the duration and timing of peaking of the murmur are related to the severity of stenosis.

An early diastolic decrescendo murmur of pulmonary regurgitation is not usually heard in the typical case of pulmonary stenosis. Previous surgical or balloon intervention or valvar calcification may result in such a murmur.

A holosystolic murmur at the left lower sternal border, which indicates *tricuspid regurgitation,* may be audible in some patients with extremely severe pulmonary stenosis.

Hepatosplenomegaly is not usually present and may develop in cases of CHF.

Peripheral pulmonary stenosis (commonly encountered in the neonate) is usually associated with a grade II/VI ejection systolic murmur that radiates into the posterior lung fields and axillae. The pathology of peripheral pulmonary stenosis is related to branch pulmonary arteries that are relatively small compared with the large main pulmonary artery, as well as to the acute angular takeoff of the branch pulmonary arteries from the main pulmonary artery specific to a neonate's anatomy. This condition and the associated murmur usually resolve spontaneously in the first month of life.

Clinical Assessment of Severity

The severity of the obstruction of the pulmonary valve can often be estimated by carefully analyzing the ausculatory findings. The timing of the ejection click, the extent of splitting of the second heart sound, the intensity of the pulmonary component of the second sound, the duration of the systolic murmur, and the timing of the peaking of the ejection murmur usually indicate the severity of pulmonary valve stenosis.

In valvar pulmonic stenosis, the severity of obstruction may be judged by auscultatory findings. In mild stenosis, the ejection click (EC) is clearly separated from the first heart sound (S1). The murmur starts with the click, peaks in early systole, and ends way before the aortic component of the second heart sound (A2) The pulmonary component of the second heart sound (P2) is normal to increased in intensity. In moderate pulmonic stenosis, the click is closer to the first heart sound, the ejection murmur peaks later in the systole and the murmur reaches the A2, and the second heart sound is widely split with soft pulmonary component. In severe valvar obstruction, the click is either absent or occurs so close to S1 that it cannot be heard separately, and the murmur peaks late in systole and extends beyond the A2. The second heart sound is widely split with an extremely soft or inaudible P2.

1. **With trivial and mild cases of pulmonary valve obstruction**, the click is clearly separated from the first heart sound. Almost normal splitting of the second heart sound with normal or slightly increased pulmonary component of the second heart sound is heard. An ejection systolic, diamond-shaped murmur that peaks early in systole and that ends much before the aortic component of the second heart sound is appreciated.
2. **Findings in moderate pulmonary valve stenosis** include an ejection systolic click that is closer to the first heart sound than it is in mild forms, a widely split second sound with a diminished pulmonary component, and an ejection systolic murmur that peaks in mid-to-late systole and that ends just before the aortic component of the second heart sound.
3. **In severe narrowing of the pulmonary valve**, ausculatory features are an ejection systolic click that is absent or that occurs so close to the first heart sound that it becomes inseparable from it, markedly increased splitting with a soft or inaudible pulmonary component of the second heart sound, and a long ejection systolic murmur that peaks late in systole and that extends beyond the aortic component of the second heart sound so that the latter cannot be heard. The duration and time of peaking of the ejection systolic murmur, and not its intensity, indicate the severity of the pulmonary valve obstruction. The longer the murmur and the later it

peaks, the more severe the obstruction. Likewise, the shorter the interval between the first heart sound and ejection click, the wider the splitting of the second heart sound, and the softer the pulmonary component, the more severe the stenosis of the pulmonary valve.

Aetiological Factors

Pulmonary valve stenosis is primarily due to maldevelopment of the pulmonary valve tissue and the distal portion of the bulbus cordis, which is characterized by fusion of leaflet commissures, resulting in a thickened and domed appearance of the valve. Although familial forms of pulmonary stenosis are described, it is generally considered to be multifactorial in origin. Rates of recurrence in siblings are on the order of 2–3%. The prevalence of pulmonary stenosis in the offspring of a parent with pulmonary stenosis is 3.6%. Aberrant flow patterns in utero may also be partly associated with maldevelopment of the pulmonary valve.

Laboratory Studies

Laboratory evaluation is usually not helpful in pulmonary valve stenosis.

Hemoglobin and hematocrit measurements in patients with cyanosis may be helpful in that they are increased in patients with right-to-left shunt. The degree of polycythemia is proportional to the degree and duration of right to left shunt. Microcytosis and hypochromia suggest iron deficiency and warrant treatment with iron supplement.

Oximetry provides information of potential right-to-left shunting in borderline cyanotic lesions but does not help in identifying the cause of the shunt (pulmonary, interatrial, interventricular, and great arterial).

Although arterial blood gas (*ABG*) analysis is usually not needed, one notable exception is the hyperoxia test in the newborn with cyanosis of undetermined origin.

The fraction of inspired oxygen (FIO2) of 1 (100% oxygen) generally does not increase the partial pressure of oxygen to more than 100 mmHg in patients with a cyanotic congenital heart defect (right-to-left intracardiac shunt).

Chest Radiography

Chest radiographs reveal a prominent main pulmonary artery segment, but the size of the heart is usually normal posteroanterior chest roentgenogram in a patient with valvar pulmonic stenosis shows normal-sized heart with normal pulmonary vascular markingswith prominent main pulmonary (Fig. 16.86).

Pulmonary vascular markings are usually normal, but they may be decreased in severe pulmonary stenosis with associated right-to-left shunt. Cardiomegaly with right ventricular and right atrial enlargement may be seen in severe valvar pulmonary stenosis, with or without tricuspid insufficiency.

Electrocardiography

Electrocardiographic (ECG) findings are usually normal in mild pulmonary stenosis. Right-axis deviation and right ventricular hypertrophy occur in moderate and severe valvar pulmonary stenosis. The degree of right ventricular hypertrophy is well correlated with the severity of pulmonary stenosis. Some studies demonstrated good correlation between the height of the R wave in lead V1 and right ventricular peak systolic pressure; the height of the R wave in V1 in mm multiplied by 5 is predictive of right ventricular peak systolic pressure. While the electrocardiogram is a useful noninvasive tool in the evaluation of severity of pulmonary stenosis, Doppler echocardiography provides a more direct indication of the severity of obstruction. Right atrial hypertrophy and right ventricular hypertrophy with strain pattern are observed when pulmonary stenosis is severe. A superior QRS axis (left-axis deviation) is seen with dysplastic pulmonary valves and Noonan syndrome (Fig. 16.87).

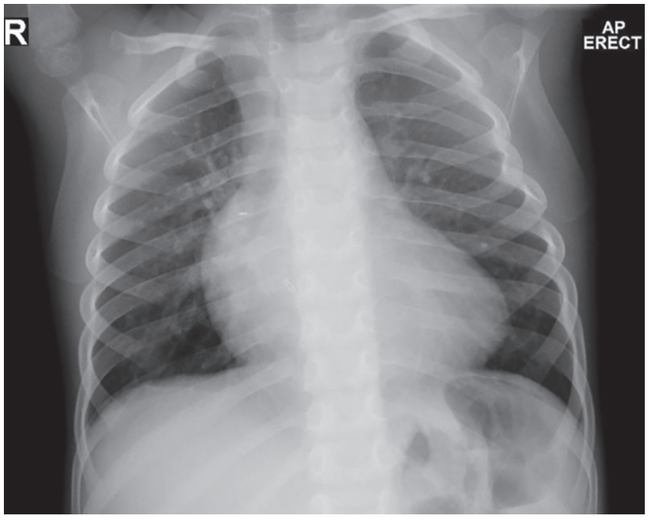

Fig. 16.86: Elevation of the cardiac apex and cardiomegaly with peripheral pruning of the pulmonary vasculature

Echocardiography

The sine qua non of diagnosis is two-dimensional and Doppler echocardiography. A thickened pulmonary valve with restricted systolic motion (doming) in the parasternal short axis and subcostal views is demonstrated. Multiple views are used to confirm the absence of coexistent congenital cardiac disease. Dilatation of the main pulmonary artery distal to the stenotic orifice commonly occurs. Markedly thickened, nodular, and immobile pulmonary valve leaflets may be recognized easily and suggest dysplastic pulmonary valves (Figs 16.88 and 16.89).

The pulmonary valve annulus can also be visualized and measured. Measurements can be compared with normal values to determine if the annulus is hypoplastic. Such measurements are also useful in selecting the diameter of the balloon to be used during balloon valvuloplasty.

Pulsed, continuous-wave (or high-frequency pulsed), and color-Doppler evaluation, in conjunction with two-dimensional echocardiography, is most useful in confirming the clinical diagnosis and in quantitating the degree of obstruction.

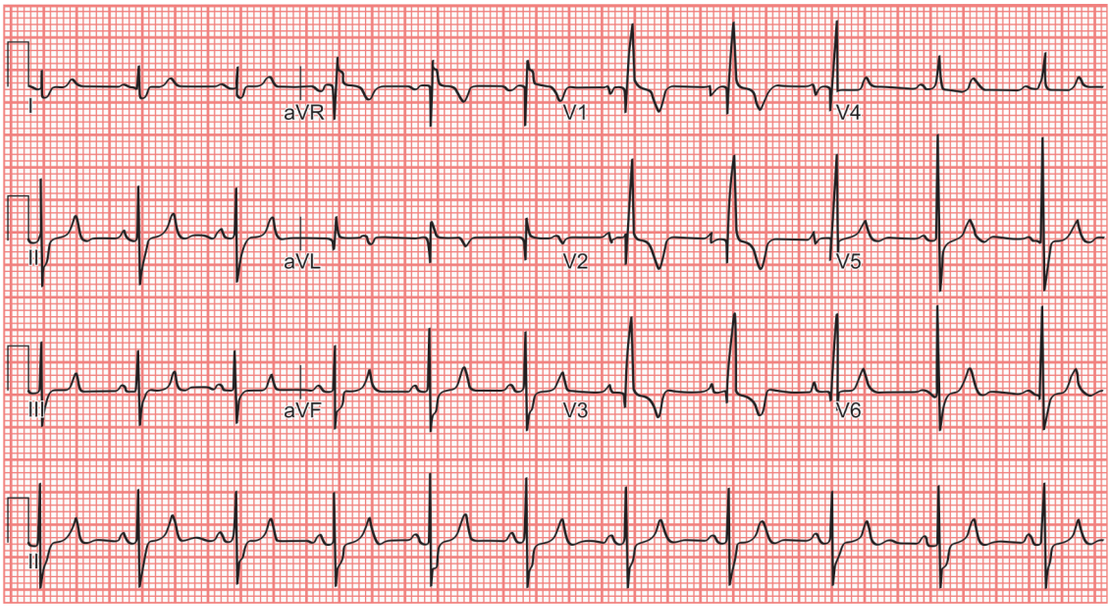

Fig. 16.87: Patient with severe pulmonary stenosis. The ECG shows right bundle branch block with right ventricular hypertrophy

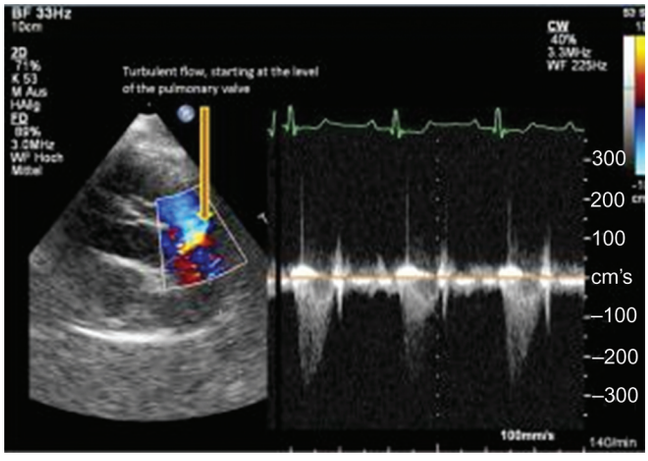

Fig. 16.88: Color flow Doppler—systolic turbulence starting at the pulmonic valve and extending into the pulmonary artery. Mild pulmonic insufficiency. Mild tricuspid regurgitation

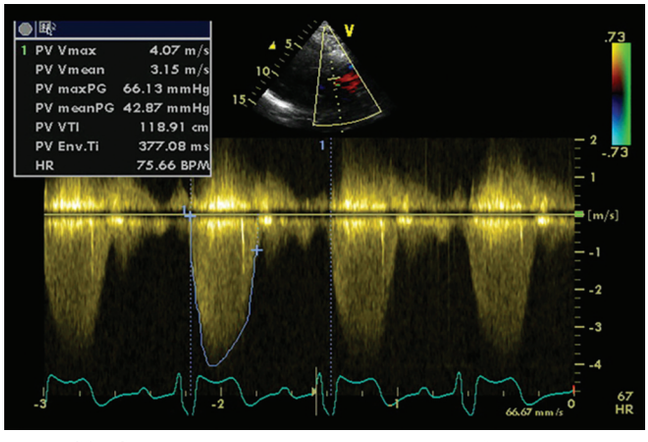

Fig. 16.89: Continuous-wave Doppler signal of transpulmonary flow in pulmonic stenosis

Pulsed Doppler interrogation of the right ventricular outflow tract with sample volume moved across the pulmonary valve demonstrates an abrupt increase in peak Doppler flow velocity, which suggests pulmonary valve obstruction. In addition, the flow pattern in the main pulmonary artery is turbulent instead of laminar. Color-Doppler imaging also shows smooth, laminar subpulmonary flow (blue) and some flow acceleration (red) immediately beneath the pulmonary valve, with turbulent (mosaic) flow beginning immediately distal to the pulmonary valve leaflets.

Doppler studies can be used to accurately determine the velocity of flow at single or multiple levels, which then can be converted to reproducible pressure gradients by applying the modified Bernoulli equation, as follows: pressure gradient (in millimeters of mercury) = 4 × (velocity in meters/second) 2.

The use of several views and measurements increases the accuracy of the predicted gradient of peak systolic pressure.

Doppler study should be performed when the patient is quiet and in a resting state. Young children and patients who are extremely anxious may have to be mildly sedated.

Severe pulmonary stenosis with gradients of more than 50 mmHg, as diagnosed using a continuous-wave Doppler recording through the pulmonary valve, should be treated with balloon valvuloplasty or surgery. However, Doppler measurements represent peak instantaneous gradients, whereas catheterization gradients are peak-to-peak gradients; recognition of this concept is more important with aortic-valve gradients than with pulmonary-valve gradients. The peak instantaneous gradient was initially thought to reflect the peak-to-peak systolic gradient measured during cardiac catheterization. However, this peak instantaneous gradient overestimates the peak-to-peak gradient, presumably because of a pressure-recovery phenomenon. In the authors' experience, the catheter peak-

to-peak gradient is somewhere in between the Doppler peak instantaneous and mean gradients.

Infundibular gradients secondary to severe right ventricular hypertrophy may be present, but these are not usually observed because severe obstruction of the distal pulmonary valve masks infundibular gradients. However, the infundibular gradients do appear after balloon pulmonary valvuloplasty. A triangular pattern of Doppler signal, similar to that described in subaortic obstruction, is characteristic of infundibular obstruction.

Pulmonary insufficiency is easily seen during pulsed, continuous-wave, or color-Doppler imaging, but is unlikely to be present without previous surgical or balloon pulmonary valvuloplasty.

Color-Doppler and pulsed Doppler interrogation of the atrial septum is useful and may reveal a left-to-right or right-to-left shunt. Because of high sensitivity of color-Doppler imaging, contrast echocardiography is not routinely used to document right-to-left shunt. Most children with pulmonary stenosis do not require evaluation beyond echocardiograph.

Computed Tomography Scanning and Magnetic Resonance Imaging

Computed tomography (CT) scanning and magnetic resonance imaging (MRI) may reveal pulmonary valve stenosis, but the state-of-the-art echocardiography and Doppler studies are more useful than CT or MRI in diagnosing and quantitating pulmonary valve obstruction (Fig. 16.90).

Nuclear Studies

Myocardial energy demands and perfusion may be evaluated by performing magnetic resonance spectroscopy and positron emission tomography (PET), respectively. However, the clinical use of these techniques in the management of pulmonic stenosis has not been established.

Cardiac Catheterization and Selective Cineangiography

Catheterization is not indicated in mild pulmonary stenosis but is essential in severe stenosis and is an integral part of balloon pulmonary valvuloplasty. This procedure is used to confirm the diagnosis; to discern the degree of obstruction; to assess the morphology of the right ventricle, pulmonary outflow tract, and pulmonary arteries; and to exclude other associated cardiac abnormalities.

Staging

The severity of pulmonary valve obstruction may be categorized (staged) as follows, based on peak-to-peak catheter-measured pulmonary valvar gradient:

- Trivial: Gradient of less than 25 mmHg
- Mild: Gradient of 25–49 mmHg
- Moderate: Gradient of 50–79 mmHg
- Severe: Gradient of more than 80 mmHg

This severity classification is useful in categorizing patients as per the natural history studies and in formulating treatment algorithms.

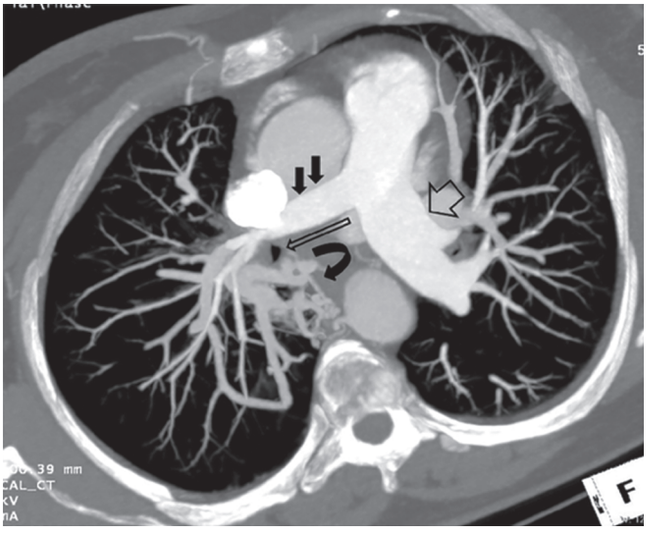

Fig. 16.90: On axial MIP CT image; at the upper and lower branches of the right main pulmonary artery (black arrows) diffuse hypoplasia, left main pulmonary artery (open thick arrow), hypoplasia of the right intermediate and middle lobe bronchus (open long arrow) was detected

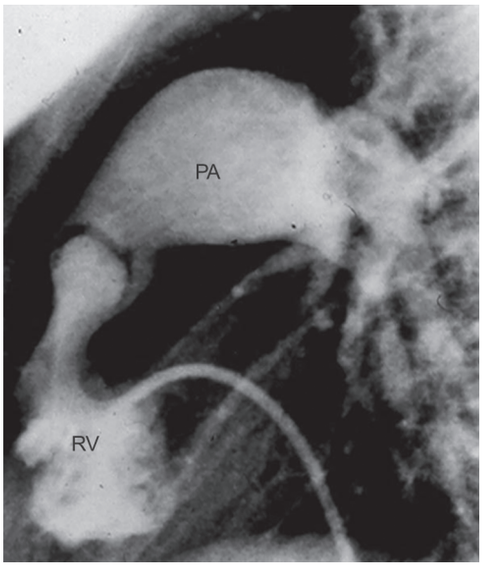

Fig. 16.91: Right ventricular (RV) cineangiogram in lateral view in a child with valvar pulmonary stenosis demonstrating thickened and domed pulmonary valve leaflets and poststenotic dilatation of the pulmonary artery (PA). Reproduced with permission from Rao PS. Diagnosis and management of acyanotic heart disease: Part I–obstructive lesions. Indian J Pediatr 2005;72:495–502

Patients with echocardiographic evidence of clinically significant pulmonary stenosis (50–60 mmHg) should undergo diagnostic and therapeutic cardiac catheterization with preparation for balloon dilatation of the pulmonary valve.

Oxygen-saturation data usually do not show evidence of left-to-right shunts. A right-to-left shunt across the patent foramen ovale (or an atrial defect) may be present in moderate-to-severe obstruction of the pulmonary valve.

Pressure Measurements

Note the following:

- Right atrial pressure (particularly a wave) may be increased.
- Right-ventricular peak systolic pressure is increased; the magnitude of the pressure is proportional to the degree of obstruction.
- The transpulmonary valve peak-to-peak gradient also indicate the severity of obstruction. A peak-to-peak gradient in excess of 50 mmHg is usually considered an indication for therapeutic intervention. Some workers use 40 mmHg as an indication for intervention.

Cine-Angiography

Right ventricular angiography usually reveals thickened and domed leaflets of the pulmonary valve (see the image below) with a thin jet of contrast material across the pulmonary valve. Enlargement and hypertrophy of the right ventricle and a dilated main pulmonary artery are also seen. In patients with severe or long-standing pulmonary valve obstruction, infundibular constriction may be seen.Additional cineangiograms at other locations are not necessary unless the echocardiographic and hemodynamic data suggest other abnormalities (Fig. 16.91).

Medical Care

Prehospital Care in Patients with Pulmonary Valve Stenosis

Collect essential information about vital signs, including the patient's pulse, respiratory rate, work of breathing, and blood pressure (BP) in the upper and lower extremities. Note the presence or absence of cyanosis.

Associated congenital cardiac anomalies should be anticipated until proven otherwise.

If the patient has a known large left-to-right shunt, such as *patent ductus arteriosus (PDA)* or ventricular septal defect (VSD), and if the patient is in respiratory distress, diuresis should be attempted. Diuresis is effective in reducing the cyanosis secondary to pulmonary edema, which is unusual in patients with isolated pulmonary valve stenosis.

Use of oxygen may reduce pulmonary artery pressure in patients with a reactive pulmonary vasculature, increasing pulmonary blood flow, which is also unusual in patients with isolated pulmonary valve stenosis.

Administer oxygen to any patient with cyanosis and respiratory distress. However, cyanosis-related intracardiac right-to-left shunting does not resolve hypoxemia.

Emergency Department Care

Limited diagnostic tests are needed after the structural diagnosis is made. Workup performed for the cyanotic infant with respiratory distress and hypotension or shock is often the same as that performed in a septic patient.

If a neonate or young infant presents to the emergency room with severe cyanosis, ductal dependent lesions should be considered. Prostaglandin infusion may open the ductus, augment pulmonary blood flow, and improve oxygen saturation.

Therapeutic Approach

Patients with trivial (gradient <25 mmHg) or mild (gradient <50 mmHg) pulmonary stenosis do not need intervention to relieve the obstruction of the pulmonary valve. They should be clinically followed up at periodic intervals, perhaps on a yearly basis. During the period of rapid growth (infancy and adolescence), follow-up more frequent than this may be indicated. Routine well-child care, including immunizations by the primary physician, should be provided. Patients with pulmonary stenosis are candidates for infective endocarditis prophylaxis before they undergo any *bacteremia*-producing procedures and surgery, as indicated in the recommendations of the American Heart Association. Limitations in exercise or activity levels are not needed. Patients with moderate (gradient, 50–79 mmHg) and severe (gradient, >80 mmHg) obstruction should undergo intervention to relieve the stenosis of the pulmonary valve. After the obstruction is relieved, recommended routine care, endocarditis prophylaxis, and exercise limitations are the same as those described for trivial and mild stenosis.

Patients with signs of right ventricular failure should be promptly treated with anticongestive measures, including digitalis and diuretics. However, the problem does not resolve until the obstruction is relieved. Therefore, prompt balloon or surgical intervention should be undertaken. Right ventricular function may not recover completely if intervention is withheld for too long and if myocardial damage sets in.

A fetus with critical pulmonary stenosis or atresia with intact ventricular septum may benefit from pulmonary balloon valvuloplasty in utero, which promotes growth of the right ventricle.

Although the consensus is to offer relief of pulmonary valve obstruction in children with moderate or severe stenoses, this approach is somewhat controversial in adults because of reported lack of progression and the lack of complications in 1 group of adults monitored for 5–24 years in the 1970s. However, a prudent strategy may be to relieve pulmonary valve obstruction in adults with moderate-to-severe pulmonary stenosis, irrespective of their symptoms, because of the potential (1) for myocardial damage associated with long-term pressure overload of the right ventricle, (2) for generally lowered cardiac indices both before and after exercise in adults compared with children, and (3) for exercise-induced hemodynamic abnormalities in adults.

Surgical Care

Balloon Pulmonary Valvuloplasty

Rubio-Alverez et al. first attempted to relieve pulmonary valve obstruction with transcatheter methods in the early 1950s. They used a ureteral catheter with a wire to cut open the stenotic pulmonary valve.

In 1979, Semb et al. used a balloon-tipped angiographic (Berman) catheter to rupture pulmonary valve commissures by rapidly withdrawing the inflated balloon across the valve. More recently, Kan et al. applied the techniques of Dotter and Judkin and Gruntzig et al. to relieve

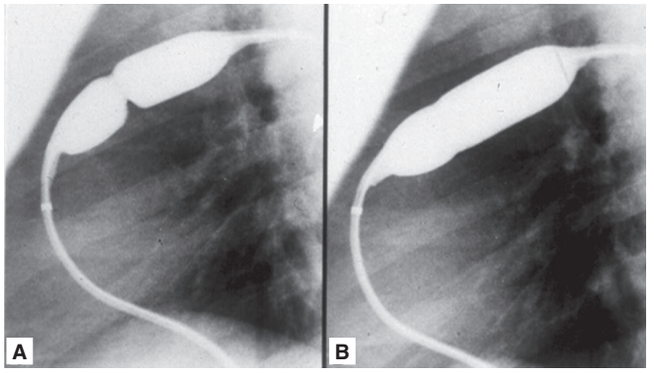

Fig. 16.92: Selected cineradiographic frames of a balloon dilatation catheter placed across a stenotic pulmonary valve. Note 'waisting' of the balloon during the initial phases of the balloon inflation (A), which was almost completely abolished during the later phases of balloon inflation (B) (reproduced from Rao PS. Balloon pulmonary valvuloplasty for isolated pulmonic stenosis. In: Rao PS, ed: Transcatheter Therapy in Pediatric Cardiology New York, NY: Wiley-Liss. 1993;59–104)

pulmonary valve obstruction by using the radial forces of balloon inflation of a balloon catheter positioned across the pulmonic valve. This static balloon-dilation technique is currently performed worldwide to relieve pulmonary valve obstruction.

The general consensus based on current data is that balloon valvuloplasty is the treatment of choice for managing isolated pulmonary valve stenosis (Fig. 16.92).

Indications: In general, indications for balloon pulmonary valvuloplasty are similar to those used in surgical pulmonary valvotomy (i.e. moderate pulmonary valve stenosis with a peak-to-peak gradient >50 mmHg with a normal cardiac index). Some cardiologists change this criterion to a gradient of 40 mmHg or right ventricular pressure of 50 mmHg. Careful evaluation of the available data suggests that (1) right ventricular pressure is only marginally reduced if mildly stenotic valves are dilated, (2) trivial and mild stenoses (gradient <50 mmHg) are likely to remain mild at follow-up (as shown in natural-history studies) and (3) an increase in gradient is easily quantitated on follow-up Doppler echocardiography. If an increased gradient is documented, the patient can then undergo balloon dilatation. Given these observations, balloon dilation should be performed only in patients with peak-to-peak gradient of more than 50 mmHg.

More recently, the interventional procedures are increasingly performed under general anesthesia and the gradients are usually lower with general anesthesia than with conscious sedation. Consequently, the same criteria should not be applied. Therefore, the Doppler gradients (discussed in echocardiography) should be used in making the decision regarding balloon pulmonary valvuloplasty.

Technique: The technique of balloon pulmonary valvuloplasty involves positioning a balloon catheter across the stenotic valve, usually over an extra-stiff exchange-length guide wire and inflating the balloon with diluted contrast material to accomplish valvotomy. The initially recommended balloon-to-annulus ratio was 1.2–1; subsequent data suggested a ratio of 1.2–1.25. When the pulmonary valve annulus is too large to dilate with a single balloon (about 20 mm), valvuloplasty with simultaneous inflation of 2 balloons across the pulmonary valve may be performed, although the current availability of large-diameter balloons make this technique unnecessary. However, the double balloon technique may be more effective and stable in some cases. The Inoue balloon has been used in adults with success. The major advantage of the Inoue balloon over conventional balloons is its adjustable diameter that makes stepwise dilation possible. Nucleus balloons with a waist in the middle have been approved by FDA. They do have theoretical advantage; however, these balloons require large sheaths and not a lot of clinical experience has been accumulated so far. The results of balloon pulmonary valvuloplasty for patients with dysplastic pulmonary valves are generally poor with the use of conventional balloon pulmonary valvuloplasty techniques. Use of large balloons, up to 150% of pulmonary valve annulus, or high-pressure balloons may increase the effectiveness of balloon therapy and avoid the need for surgery.

Mechanism of valvuloplasty: Inflation of a balloon placed across an obstructive lesion exerts radial forces on the stenotic lesion without any axial component. The mechanism of valvuloplasty is assessed by directly visualizing the valvar mechanism during surgeryand postmortem examination and by indirect means, such as angiography and echocardiography. Splitting of the valve commissures and tearing and avulsion of the valve leaflets have been observed and are conceivably the mechanism by which balloon dilation relieves pulmonary valve obstruction. The circumferential dilating force that balloon inflation exerts is likely to rupture (tear) the weakest part of the valve mechanism. The fused commissures are the likely weakest links that can be broken with balloon dilation. However, when fused commissures are strong and cannot be torn, the valve cusps can be torn or the valve leaflet avulse. These events are likely to worsen pulmonary insufficiency.

Pulmonary valve dysplasia, if severe, may preclude successful balloon valvuloplasty unless an associated commissural fusion is present.

Immediate results: Results observed immediately after balloon valvuloplasty include reduced peak-to-peak gradients and right ventricular-to-left ventricular pressure ratios and increased pulmonary artery pressures, jet widths, and free motion of the pulmonary valve leaflets with decreased doming. Improvement of right ventricular function, tricuspid insufficiency, and right-to-left shunt, if present before dilation, are also documented.

Infundibular stenosis: Infundibular gradients occur in nearly 30% patients. The older the patient's age and the greater the severity of obstruction, the greater the prevalence of infundibular reaction. When residual infundibular gradient is >50 mmHg beta-blockade is generally recommended. Infundibular obstruction greatly regresses at follow-up (see the image below), as demonstrated for infundibular

reactions after surgical valvotomy. Rare patients require surgical intervention.

Follow-up evaluation: Clinical, ECG, and Doppler echocardiographic evaluations are generally recommended at 1 month, 6 months, and 12 months after the procedure and yearly thereafter. Regression of right ventricular hypertrophy, as shown on ECG after balloon dilatation, is well documented. ECG is a useful adjunct in the evaluation of follow-up results. However, ECG evidence of hemodynamic improvement does not become apparent until 6 months after valvuloplasty. The Doppler gradient generally reflects residual obstruction and is a useful and reliable noninvasive monitoring tool.

Intermediate-term results: At intermediate-term follow-up (usually <2 years), both catheterization-measured peak-to-peak and Doppler-measured peak instantaneous gradients remain improved as a whole. However, restenosis (gradient >50 mmHg) is observed in nearly 10% patients.

Predictors of restenosis include a balloon-to-annulus ratio of less than 1.2 and a gradient of more than 30 mmHg immediately after valvuloplasty. In addition, early in the study period, a small valve annulus, and a postsurgical or complex pulmonary stenosis were also predictive of restenosis.

Patients with restenosis have been successfully treated with redilatation with balloons larger than those used for initial balloon valvuloplasty. Redilatation is the procedure of choice for managing restenosis after previous balloon dilatation. However, if the pulmonary valve annulus is hypoplastic, if the pulmonary valve leaflets are dysplastic, or if clinically significant supravalvar pulmonary artery stenosis is the major reason for the restenosis, surgery is recommended.

Long-term follow-up results: Although immediate and short-term results have been documented, data on long-term results are scarce. Published studies reveal generally low residual peak instantaneous Doppler gradients with minimal (1–2%) late recurrence of pulmonary stenosis (beyond that seen at intermediate follow-up).

In one study, approximately 5% of patients needed surgical intervention to relieve fixed subvalvar or **supravalvar stenosis**. Actuarial freedom for reintervention was 88% and 84%, respectively, at 5 and 10 years. Pulmonary valve insufficiency was noted in 80–90% patients, but right ventricular volume overloading did not develop, and none of the patients required surgical intervention because of pulmonary insufficiency. Based on these data, the authors concluded that balloon pulmonary valvuloplasty may continue to be the treatment of choice for moderate-to-severe valvar pulmonary stenosis, and 10-year to 20-year follow-up studies to evaluate the clinical significance of residual pulmonary insufficiency should be undertaken.

Clinically significant pulmonary insufficiency: One report documented the development of clinically significant pulmonary insufficiency in 6 (6%) of 107 patients at late follow-up. Some of these patients required pulmonary valve replacement. In a recent report, 53 patients with pulmonary valve stenosis who had percutaneous balloon valvuloplasty were followed for 10–24 years (median, 15 years); there was only 2% prevalence of restenosis, but late pulmonary regurgitation developed in 89% patients.

Comparison with Surgical Valvotomy

Comparison of balloon therapy with surgical valvotomy has limitations, but the mortality and morbidity rates are generally higher after surgery. Greater reduction of the gradient is observed after surgery, but the degree and frequency of pulmonary insufficiency may be higher after surgery than after balloon therapy.

Critical pulmonary stenosis in the neonate: The term critical pulmonary stenosis with intact ventricular septum is applied to severe pulmonary valvar obstruction resulting in suprasystemic right ventricular systolic pressure with resultant tricuspid insufficiency, a right-to-left shunt across the atrial septum, and often a ductal-dependent pulmonary circulation.

Although the surgical approach to relieve the obstruction with or without aorta-pulmonary shunt was standard treatment in the past, transcatheter treatment is now first-line therapy.

Prostaglandin E1 is infused to augment pulmonary blood flow and improve systemic arterial desaturation, followed by cardiac catheterization and biplane (sitting-up and lateral views) right ventricular cineangiography. A right coronary artery, angled glide, balloon wedge, or cobra catheter (according to the operator's preference) is placed in the right ventricular outflow tract, and a floppy-tipped coronary guidewire is advanced across the pulmonary valve and into the right or left pulmonary artery or into the descending aorta through the ductus. The catheter is advanced across the pulmonary valve into a distal pulmonary artery or the descending aorta. The guidewire is then exchanged for a guidewire that is suited to position the balloon-dilation catheter. Then, balloon pulmonary valvuloplasty is performed in manner described earlier.

In some cases, the balloon catheter cannot be advanced across a severely stenotic pulmonary valve, and balloon catheters 3–6 mm in diameter may be used for initial predilation and then replaced with larger, more appropriately sized balloon catheters (Fig. 16.93).

Although the results of this approach are reasonably good, the need for reintervention to address the complications associated with the procedure, residual obstruction, or associated defects is 25% in neonates compared with older children 8–10%.

Other Catheter Interventions

Numerous other catheter interventions may become necessary in patients with pulmonary stenosis.

Transcatheter occlusion of a patent ductus arteriosus (PDA): Some patients with pulmonary stenosis may have a PDA of significant size. In such patients, transcatheter occlusion of the PDA performed with a coil (for small PDAs) or with an Amplatzer duct occluder (for medium or large PDAs)

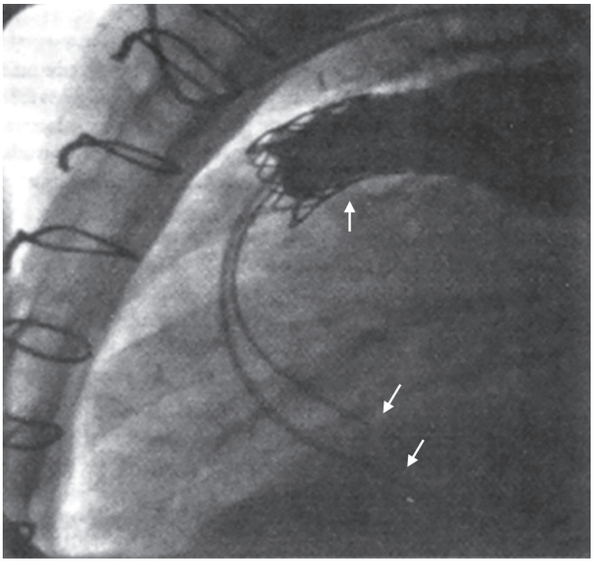

Fig. 16.93: Double balloon (arrows) across PV for dilatation of valve in patient with pulmonic stenosis

is recommended immediately after balloon pulmonary valvuloplasty.

Occlusion of a patent foramen ovale or atrial septal defect: A patent foramen ovale or atrial septal defect may occur in association with pulmonary stenosis. If these atrial defects do not spontaneously close during follow-up after balloon valvuloplasty, they may be closed with an Amplatzer septal occluder or Helex device, if the criteria for their closure are met. Sometimes, the defects may need to be closed to prevent recurrent paradoxical embolisms.

Balloon atrial septostomy: In neonates with a severely hypoplastic right ventricle, balloon atrial septostomy may be necessary to provide adequate egress to the systemic venous return. Indications are clinical signs of systemic venous congestion, restrictive patent foramen ovale on Doppler echocardiography, markedly elevated right atrial pressure with tall a waves, and/or a mean atrial pressure difference of more than 5 mmHg.

In neonates, Rashkind balloon septostomy is effective. Beyond the neonatal period, Park blade septostomy or surgical septostomy may be necessary. In patients with only mild or moderate right ventricular hypoplasia, balloon septostomy should be avoided so that forward flow through the right ventricle is encouraged with a consequent opportunity for its growth.

Cardiac catheterization with balloon valvuloplasty: This is the preferred therapy for severe or critical valvar pulmonary stenosis. In neonates with critical valvar pulmonary stenosis, mortality rates related to balloon dilation are lower than those related to surgery mortality, and balloon dilation is the treatment of choice.

Other Surgical Techniques

Since the first description of surgical relief of pulmonary stenosis by closed pulmonary valvotomy in the late 1940s, various techniques were developed and include valvotomy with inflow occlusion, hypothermia and cardiopulmonary bypass. The currently preferred approach is transpulmonary arterial valvotomy under cardiopulmonary bypass.

Results: Results of surgery are generally good with low mortality rate (3–7%) and decreased right ventricular pressures and pulmonary valve gradients. In a natural-history study in the United States, only 3% of 294 operated patients had gradients of more than 50 mmHg at 4–8 years after surgery. The incidence of pulmonary insufficiency at follow-up was 60–90%. Despite these good results, transluminal balloon pulmonary valvuloplasty (discussed above) has replaced surgical pulmonary valvotomy.

Indications: Surgery is reserved for cases in which balloon valvuloplasty is not feasible or not successful. One example is dysplastic pulmonary valve with valve ring hypoplasia. The treatment of this disorder is to excise the obstructive valve leaflets and enlarge the annulus by a transannular patch. Other examples are fixed infundibular and supravalvar stenosis after successful balloon valvuloplasty.

Blalock-Taussig shunt: Patients with critical pulmonary stenosis and marked hypoplasia of the right ventricle may need a Blalock-Taussig shunt in addition to or instead of balloon or surgical valvotomy.

Right ventricular repair/bypass: Right ventricular hypoplasia, as alluded to above, occurs in some patients with pulmonary stenosis, although this hypoplasia is most common in patients with pulmonary atresia and an intact ventricular septum. The right ventricle may enlarge after right ventricular outflow obstruction is relieved, particularly in tripartite right ventricles. If the right ventricle does not grow adequately to support the pulmonary circulation, 1.5 or single ventricular repair should be considered. In 1.5-ventricular repair, a bidirectional Glenn procedure (superior vena cava-to-right pulmonary artery anastomosis, end to side) is performed to divert the blood from the upper part of the body directly into the pulmonary artery, and the atrial septal defect is closed to allow the blood from the lower part of the body to go into the lungs through the right ventricle. In the single ventricle repair, the right ventricle is bypassed by the Fontan procedure. In the Fontan procedure, staged total cavopulmonary connection is performed by bidirectional Glenn initially and then extra conduit diversion of the inferior cava into the pulmonary artery.

2. PULMONIC REGURGITATION

The pulmonic valve is normally a thin tricuspid structure that prevents blood from regurgitating into the right ventricle once ejected into the low-pressure pulmonary circulation. Pulmonic regurgitation refers to retrograde flow from the pulmonary artery into the right ventricle during diastole. Physiologic (trace-to-mild) pulmonic regurgitation is present in nearly all individuals, particularly in those with advanced age. However, pathologic conditions that produce excessive and clinically

significant regurgitation can result in impairment of right ventricular function and eventual clinical manifestations of right-sided volume overload and heart failure. Often, pulmonic regurgitation is not the primary process but a finding secondary to an underlying process such as pulmonary hypertension or dilated cardiomyopathy.

Clinical History

Pulmonic regurgitation is seldom clinically significant. However, symptoms of right-sided *heart failure* can occur when the severity and duration of the regurgitation result in right ventricular enlargement and decompensation. Dyspnea on exertion is the most common complaint. Easy fatigability, light-headedness, peripheral edema, chest pain, palpitations, and frank syncope may occur in patients with any cause of right-sided heart failure and do little to elucidate the aetiology of the right-sided failure. Patients who experience these symptoms may attribute them to poor physical fitness or anxiety, delaying evaluation until their condition worsens. In more advanced presentations of right-sided heart failure, abdominal distension secondary to ascites, right upper quadrant pain secondary to hepatic distension, and early satiety may occur.

Other symptoms specific to the underlying disease process causing pulmonic regurgitation may occur. Such disease processes include connective-tissue disease, infective endocarditis, carcinoid heart disease, rheumatic heart disease, and primary or secondary pulmonary hypertension. For example, hemoptysis is generally not associated with pulmonic regurgitation *perse*, but, in severe pulmonary hypertension causing pulmonic regurgitation, it may occur as a result of the associated pulmonary arteriole rupture and hemorrhage and/or parenchymal inflammation.

Physical Examination

Jugular venous pressure (JVP) is usually increased. Often, an increased A wave is present, but this may be less apparent when significant tricuspid regurgitation with a dominant V wave is also present. When right ventricular enlargement is present, a palpable impulse (lift or heave) is usually present at the left lower sternal border. Palpable pulmonary artery pulsation at the left upper sternal border may be present in the setting of significant pulmonary artery dilatation. With significant pulmonary hypertension, pulmonic valve closure can be palpated.

The pulmonic component of the second heart sound (P_2) is inaudible in the absence of a pulmonic valve, whether congenital or secondary to surgical resection. In pulmonic regurgitation due to pulmonary hypertension, P_2 is accentuated; with increased right ventricular end-diastolic volume, the ejection time is increased, P_2 is delayed, and the S_2 split is widened.

A low-pressure regurgitant flow across the pulmonic valve, as occurs when the pulmonary arterial pressure is normal, is heard as a brief, decrescendo early diastolic murmur at the upper left sternal border. It is made louder by squatting or inspiration and softer by Valsalva manoeuvres or expiration. An S_3 or S_4 may be noted at the left mid-to-lower sternal border because of the presence of right ventricular hypertrophy or failure and is augmented by inspiration.

The Graham Steell murmur of pulmonary hypertension is a high-pitched, early diastolic decrescendo murmur noted over the left upper-to-left midsternal area and is a result of high-velocity regurgitant flow across an incompetent pulmonic valve. The regurgitant flow murmur may be present during the whole of diastole because there is a pulmonary-to-right ventricular pressure gradient throughout this time period. Typically, the murmur occurs in severe pulmonary hypertension when the pulmonary artery systolic pressure is more than 60 mmHg. The quality of this high-pitched early decrescendo diastolic murmur is identical to that of aortic insufficiency. However, the peripheral manifestations of aortic insufficiency are absent. The associated findings of tricuspid regurgitation are frequently present, that is, prominent JVP with surging V waves, holosystolic murmur at the lower left sternal border (louder with inspiration), and enlarged, pulsatile liver.

Aetiological Factors

Significant pulmonic regurgitation occurs variably as a complication of various conditions.

Primary and Pulmonary Hypertension

Primary pulmonary hypertension occurs in approximately 1 instance per 500,000 cases. This diagnosis can be made only after all other causes have been excluded.

Secondary pulmonary hypertension (multiple causes) is the most common cause of pulmonic regurgitation in adults.

Tetralogy of Fallot

Tetralogy of Fallot, especially with congenital absence of the pulmonary valve or postoperative following surgical repair of this condition (e.g. pulmonary valvotomy), may cause significant pulmonic regurgitation.

Infective endocarditis: In rare cases, *infective endocarditis* results in significant pulmonic regurgitation. It may occur in an intravenous drug user or an individual with an atrial septal defect and a large left-to-right intracardiac shunt.

Rheumatic and Carcinoid Heart Diseases

In *rheumatic heart disease* leading to significant pulmonic regurgitation, the pulmonary valve is affected following mitral, aortic, and tricuspid valve involvement.

Medications

- Medications that act via serotoninergic pathways may result in significant pulmonic regurgitation (e.g. methysergide, pergolide and fenfluramine).
- Disorders that dilate the pulmonic valve ring to create valvular incompetence.

These are the most common cause of pulmonic regurgitation and include primary or secondary pulmonary hyper-

tension, dilatation of the pulmonary trunk in Marfan syndrome or Takayasu arteritis, and idiopathic causes.

Acquired disorders that alter pulmonic valve morphology:
These conditions include the following:

- ***Rheumatic heart disease:*** In most cases, the other valves (i.e. mitral, aortic, and tricuspid) are also substantially affected.
- ***Trauma from a Swan-Ganz catheter:*** This cause is unusual, but it can result if the catheter tip is withdrawn across the pulmonic valve with the balloon inflated.
- ***Complications related to therapeutic balloon catheter dilatation of a stenotic pulmonic valve*** (e.g. pulmonary balloon valvuloplasty). Such complications are not uncommon; however, in most cases, the degree of regurgitation is clinically insignificant, rendering pulmonic valve balloon catheter dilation a safe and effective treatment for moderate-to-severe pulmonic stenosis in adult and pediatric patients.
- ***Complications of surgical repair of pulmonic stenosis or congenital heart disease,*** such as:
  1. Tetralogy of Fallot
  2. Syphilis infection
  3. *Carcinoid heart disease:* The heart is affected in up to 60% of patients in whom carcinoid has metastasized to the liver, most commonly manifesting as valvular disease. In Pellikka and colleagues' 1993 series of 74 patients, the pulmonic valve was involved in 88%. Of those, 49% exhibited significant pulmonic stenosis, and 81% had significant pulmonic regurgitation.
- ***Congenital disorders that produce an incompetent pulmonic valve:*** These include complete absence of the pulmonic valve and valvular abnormalities (e.g. fenestrations or redundant leaflets).

Laboratory Studies

Japanese investigators suggest that evels of plasma brain natriuretic peptide (BNP) have the potential to be useful for postsurgical long-term monitoring of patients with tetralogy of Fallot who are under consideration for pulmonary valve replacement to correct pulmonary regurgitation or right-ventricular dysfunction. In their study of 33 patients who underwent repair of tetralogy of Fallot, significantly higher plasma BNP levels were found not only in patients with moderate-severe pulmonary regurgitation compared to those with insignificant or mild pulmonary regurgitation ($P = 0.013$.) but also in patients with cardiac symptoms compared to asymptomatic patients ($P = 0.005$). Following pulmonary valve replacement, there was a significant reduction in mean BNP levels, and the plasma BNP level correlated with the right-ventricular end-diastolic pressure. The investigators reported 32.15 pg/ml was the optimal BNP cut-off level for considering pulmonary valve replacement.

Chest Radiography

Plain radiographs change little with pulmonic regurgitation unless tricuspid regurgitation also occurs, in which case cardiomegaly and enlargement of the right-sided heart contour are observed.

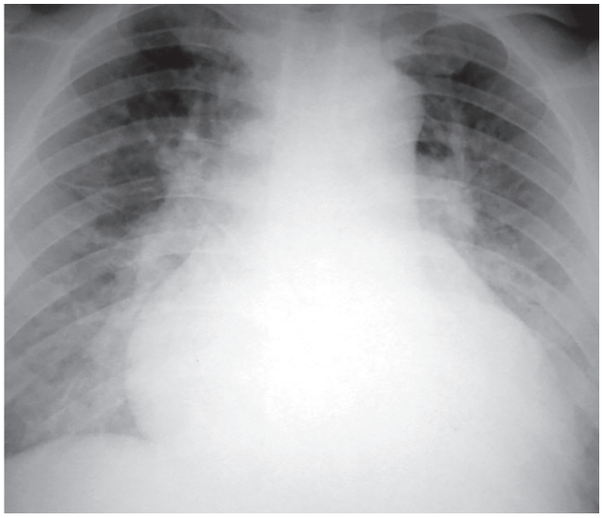

Fig. 16.94: Prominent central pulmonary arteries with enlarged hilar vessels and loss of vascularity in the peripheral lung fields ('pruning') suggests severe pulmonary hypertension with valvular regurgitation

Prominent central pulmonary arteries with enlarged hilar vessels and loss of vascularity in the peripheral lung fields ('pruning') suggests severe pulmonary hypertension (Fig. 16.94).

Electrocardiography

ECG may demonstrate findings of right ventricular dilatation (occurs either while in a compensated volume overload state or in a decompensated pressure overload state), including incomplete right bundle branch block and right axis deviation. Right ventricular hypertrophy may be present by ECG criteria (Fig. 16.95).

In the presence of right ventricular hypertrophy (representing a compensated state of pressure overload), the following may be present:

- Tall R wave in V_1 or qR in V_1
- R wave greater than S wave in V_1
- R wave progression reversal in the precordial leads
- Inverted T-wave in the anterior precordial leads
- Right axis deviation
- Right atrial enlargement

Echocardiography

Two-dimensional echocardiography (2DE) and M-mode echocardiography can reveal right ventricular hypertrophy and dilatation. Right ventricular volume overload may induce a characteristic abnormal septal wall motion, which appears as flattening of the septum during diastole. Conversely, right ventricular pressure overload usually appears as flattening of the septum during systole. The lack of a pulmonic valve or valve deformities can be noted with 2DE, but the pulmonic valve apparatus typically appears unremarkable. In some cases, pulmonic ring dilatation with poor valve leaflet coaptation may be observed (Figs 16.96–16.98).

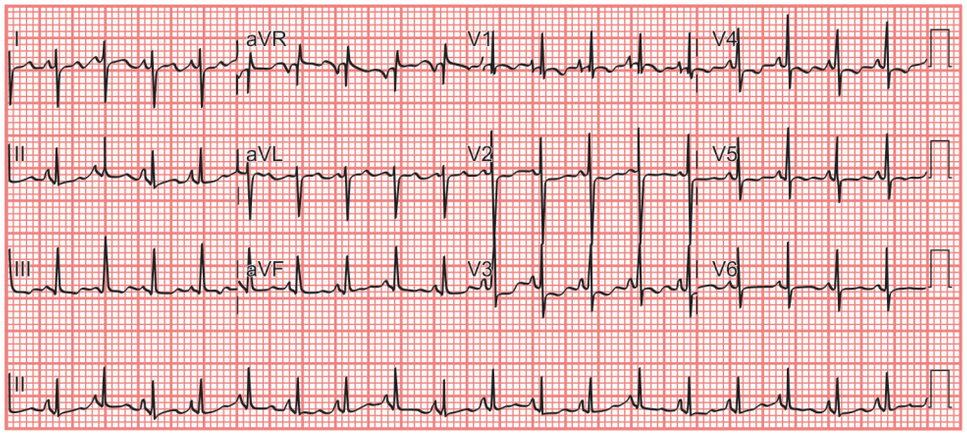

Fig. 16.95: ECG showing tall R-wave in V1 or qR in V1, R-wave progression reversal in the precordial leads right axis deviation and right atrial enlargement in pulmonary regurgitation

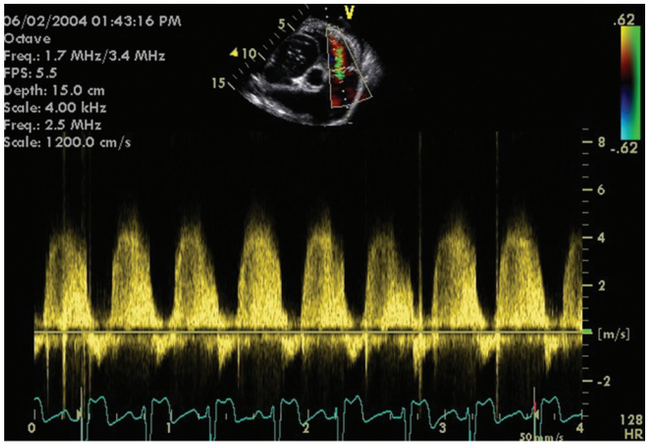

Fig. 16.96: Doppler echo scan showing severe type of pulmonary regurgitation in patient with pulmonary valvular insufficiency. Note the positive wave which is consistent with pulmonary insufficiency (positive signals are directed toward the transducer while negative signals are away from the trasducer

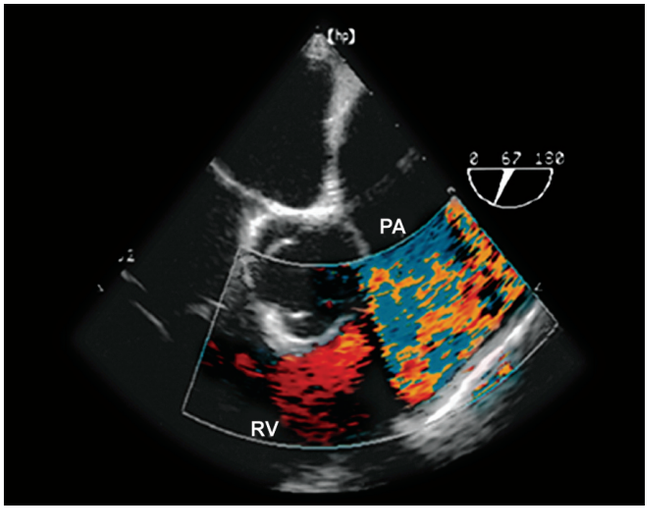

Fig. 16.97: Transesophageal echocardiography image with color-Doppler, showing high-velocity, turbulent flow in the main pulmonary artery. Ao=aorta; LA=left atrium; PA=pulmonary artery; RA=right atrium; RV=right ventricle

Doppler techniques are used to visualize the regurgitant flow. These techniques are useful to directly visualize regurgitant jets, measure the flow velocities of the regurgitant jets, and accurately estimate pulmonary pressures. Regurgitation that persists throughout diastole suggests the presence of pulmonary hypertension, whereas regurgitation that diminishes earlier in diastole suggests more normal pulmonary arterial pressures. Normally, peak flow velocity across the pulmonic valve is achieved within 140 milliseconds of systole. With pulmonary hypertension, the peak flow velocity is reached faster. The shortening of the interval within which the peak velocity is reached (acceleration time) is linearly inversely proportional to the severity of the pulmonary hypertension.

Color flow Doppler echocardiography is the mainstay for recognizing pulmonic regurgitation. In trivial-to-mild pulmonic regurgitation, the jet is central and narrow. In moderate-to-severe pulmonic regurgitation, the width of the jet increases, as does the penetration of the jet into the right ventricular outflow tract. In free or open pulmonic regurgitation (usually due to congenitally absent pulmonic valve), color-Doppler can miss the jet altogether due to the brisk and laminar regurgitant flow.

Using pulsed wave and continuous wave Doppler, pulmonary artery systolic and diastolic pressures can be calculated. Pulmonary artery systolic pressure can be estimated (using continuous wave Doppler) in the presence of tricuspid regurgitation by measuring the peak regurgitant flow velocity across the tricuspid valve, converting it to a pressure gradient (by use of the modified Bernoulli equation), and then adding the gradient to an estimate of the right atrial pressure.

Pulmonary artery diastolic pressure can be estimated by measuring the end-diastolic regurgitant flow velocity across the pulmonic valve (at the QRS complex on the ECG), converting it to a pressure gradient, and then adding the

gradient to the estimated right atrial pressure. Both pulmonary artery systolic pressure and diastolic pressure are predictors of cardiac status and outcome.

Pulmonary arterial mean pressure can also be estimated by converting the early diastolic regurgitation velocity to a pressure gradient, and then adding it to the estimated right atrial pressure.

Fluoroscopy and Catheterization

Cardiac catheterization is usually not necessary for diagnosis but may be helpful in determining the underlying aetiology and for determining coexisting conditions that may influence treatment and/or repair decisions (Fig. 16.99).

Pulmonary artery angiography may reveal evidence of multiple pulmonary emboli as a cause of pulmonary hypertension when the degree of clinical suspicion is high. Ventilation/perfusion scanning or CT angiography is now more commonly performed in most hospitals. Pulmonary emboli must be excluded before the diagnosis of primary pulmonary hypertension is possible.

If pressure measurements are performed, the pulmonary artery and right ventricular pressure curves equalize in late diastole in individuals with severe pulmonary regurgitation.

Cardiac Magnetic Resonance Imaging

Cardiac magnetic resonance imaging (CMRI) has shown promise based on recent studies of pulmonary regurgitation. CMR has excellent temporal and spacial resolution and can provide accurate estimation of the severity of regurgitation, mechanism of regurgitation, and right ventricular size and function. However, size and time constraints limit the use of CMR in clinical practice (Fig. 16.100).

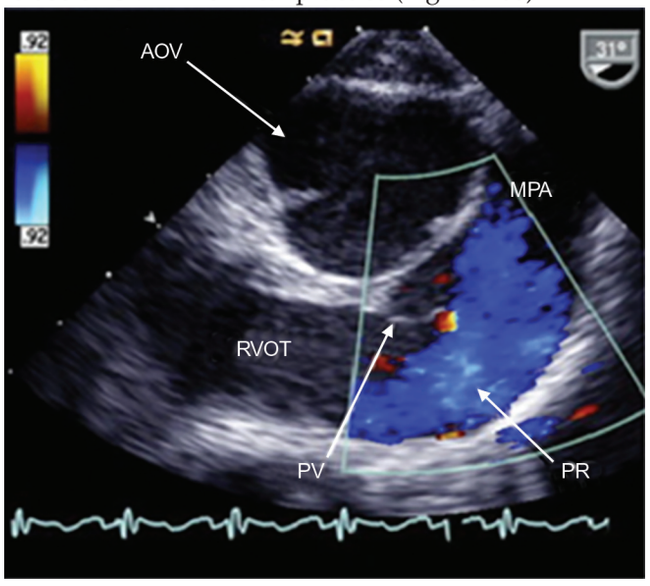

Fig. 16.98: Preoperative echocardiogram demonstrating severe pulmonary valve regurgitation located anteriorly through the gap created by the transannular patch. AOV=aortic valve; MPA=main pulmonary artery; PR=pulmonary regurgitation; PV=pulmonary valve; RVOT=right ventricular outflow tract

Medical Management

Medications are directed according to the specific aetiology resulting in pulmonic regurgitation in addition to the treatment of heart failure (if present). Complete infective endocarditis antibiotic prophylaxis should be considered for patients whose pulmonic regurgitation is due to valve leaflet abnormalities. Pulmonic regurgitation is seldom severe enough to warrant special treatment because the right ventricle normally adapts to low-pressure volume

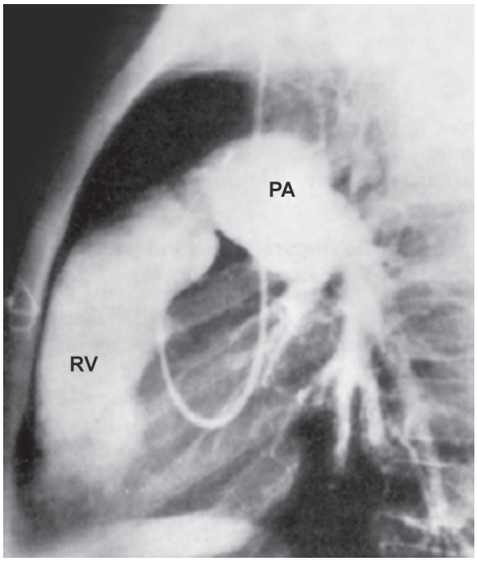

Fig. 16.99: Contrast medium has been injected into the main pulmonary artery (PA) and regurgitation back into an enlarged right ventricle (RV) in patient with pulmonic valvular regurgitation

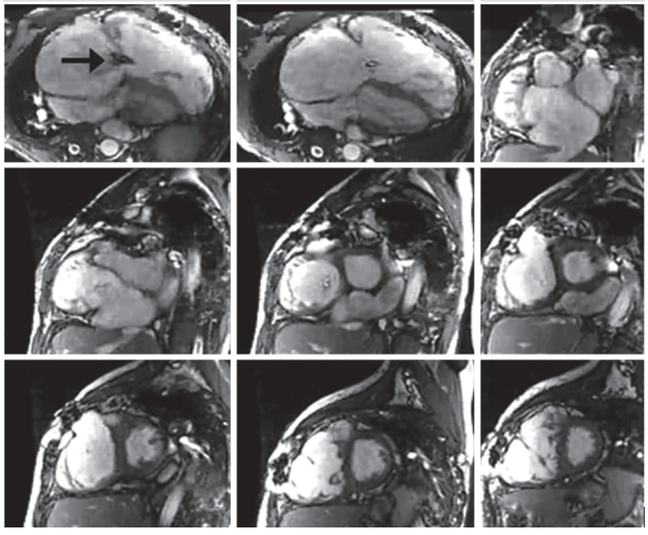

Fig. 16.100: CMR imaging in a 37-year-old patient with repaired TOF, severe pulmonary regurgitation, moderate tricuspid regurgitation (arrow), and severe right ventricular dilatation (end-diastolic volume index 386 ml/m^2) and dysfunction (ejection fraction 15%). This patient who also exhibited severe heart failure symptoms had only modest decrease in RV size and no improvement in RV function after pulmonary valve replacement. Geva Journal of Cardiovascular Magnetic Resonance 2011;13:9

overload without difficulty. High-pressure volume overload leads to right-sided heart strain and, ultimately, heart failure. Underlying etiologies causing severe pulmonic regurgitation, whether congenital or acquired, must be treated to prevent or reverse right-sided heart strain and failure that may further complicate the clinical picture. A discussion of therapeutic interventions in pulmonary hypertension by aetiology is beyond the scope of this article. Refer to the articles for each entity under differentials for a detailed discussion of treatment options.

If pulmonary hypertension is identified with pulmonic regurgitation, determining the aetiology is essential to institute appropriate therapy as expeditiously as possible. For instance, primary pulmonary hypertension, secondary pulmonary hypertension due to thromboembolism, severe mitral stenosis, and pulmonary carcinomatosis can all manifest as severe pulmonary hypertension with pulmonic regurgitation.

No aspect of medical management of heart failure is uniquely applicable to pulmonic regurgitation, and the discussion of management of right-sided heart failure is beyond the scope of this article. In general, similar approaches to those used in the treatment of patients with left-sided congestive heart failure can be useful. In some circumstances, such as in patients with pulmonary hypertension, vasodilator therapies must be very carefully considered and monitored. In addition, therapies aimed toward the underlying aetiology may also reduce pulmonic regurgitation. The American Heart Association and the American College of Cardiology have published guidelines on the management of patients with valvular heart disease.

Surgical Care

When right-sided heart failure due to pulmonic regurgitation from an abnormal pulmonic valve cannot be ameliorated by medical management, appropriate options include surgical reconstruction or replacement of the pulmonic valve, preferably with a bioprosthetic valve. Although congenital pulmonic regurgitation is usually well tolerated, the much more rare congenital absence of the pulmonic valve usually requires valve replacement.

Percutaneous Intervention

More recently, percutaneous intervention for dysfunctional right ventricular outflow tract conduits has become available. The intermediate-term results have shown that percutaneous bioprosthetic valve implantation is a reasonable option for patients with dysfunctional right ventricular outflow tract conduits, especially those with high surgical risk. Freedom from valve dysfunction or reintervention following percutaneous bioprosthetic valve placement was 93.5% at 1 year (Figs 16.101 and 16.102).

Complications

Right-sided heart failure is a complication of volume overload of the right ventricle due to severe pulmonic regurgitation. Other complications are related to the underlying disease processes resulting in pulmonic regurgitation.

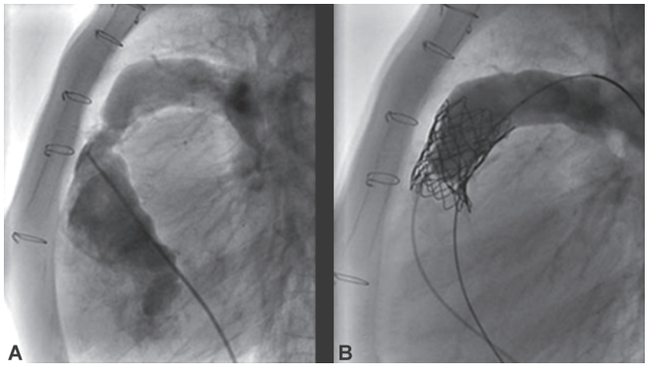

Fig. 16.101: The implantation of the percutaneous pulmonary valve was performed with excellent results. (A) Severe stenosis of the homograft. (B) Resolution of the stenosis, no regurgitation

Prognosis

In general, survival is not significantly affected by mild-to-moderate pulmonic regurgitation. If pulmonic regurgitation is severe, the right ventricle is initially able to compensate for the volume overload state, and the state may remain well compensated for years. Persistently elevated right ventricular volumes may eventually cause right ventricular dilatation, and, finally, failure. As previously stated, the various disorders causing pulmonary hypertension are the most common causes of clinically significant pulmonic regurgitation. The principal prognostic indicators of mortality in pulmonic regurgitation associated with pulmonary hypertension are (1) the severity and duration of the pulmonary hypertension at the time of diagnosis and (2) the right ventricular response to the state of volume overload. In all etiologies of pulmonary hypertension, early diagnosis that allows for intervention to slow or reverse the cause of pulmonary hypertension is essential, although, in many cases, diagnosis is difficult and requires a high degree of clinical suspicion. In primary pulmonary hypertension, the pathologic process is often insidious, and symptoms manifest at an advanced disease state, resulting in an average survival period of 2.5 years from the time of diagnosis. In congenital regurgitation of the pulmonic valve, the prognosis depends upon the initial severity, progression of the regurgitation, and the ability of the right ventricle to adapt to volume overload. Usually, the degree of regurgitation in this condition is no more than moderate, so no clinical sequelae occur. Congenital absence of the pulmonic valve, a much rarer condition, confers an increased risk of morbidity and mortality because of more severe regurgitation and usually warrants pulmonic valve replacement for improved prognosis.

Activity

Since pulmonic regurgitation is usually of a mild-to-moderate degree, restriction of athletic activities is unnecessary. Follow-up echocardiographic studies can provide data to assess for changes in pulmonic regurgitation and right ventricular functional status in order to more objectively base activity limitation recommendations.

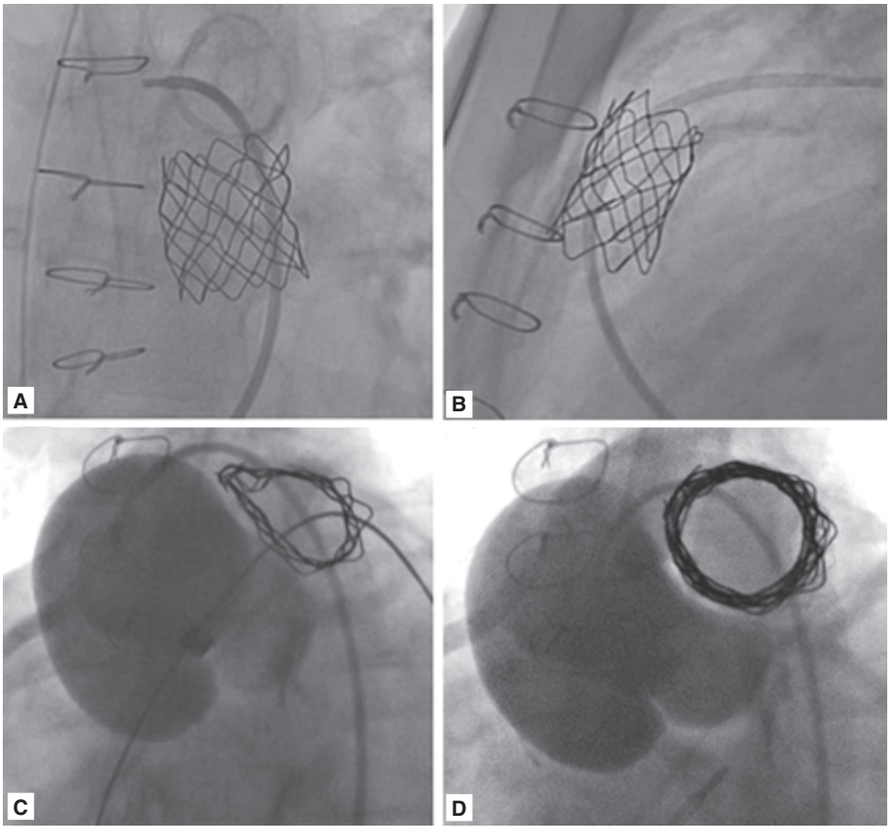

Fig. 16.102: (A and B) Anteroposterior and lateral fluoroscopic images demonstrating compression of the implanted Melody valve stent in a patient with a heavily calcified right ventricular outflow tract homograft conduit that is directly apposed to the anterior chest wall. (C) Aortic root angiogram in a caudal left anterior oblique projection demonstrates distortion and compression of the Melody valve from the rightward posterior aspect by a dilated neoaortic root in a patient with conduit obstruction after a Ross procedure. (D) After placement of 2 bare metal stents and a second transcatheter pulmonary valve within the fractured Melody valve, the cylindrical valve can be seen to indent the dilated neoaortic root

Further Outpatient Care

Regurgitation may worsen with time. Therefore, periodic echocardiographic reassessment with Doppler color flow studies provides a longitudinal comparison of the progression of both the regurgitation and right ventricular size and function. In cases of significant pulmonic regurgitation, exercise capacity should be assessed and quantitated serially, observing for a change or decrease in function, the goal being to accurately assess the need and potential timing for surgical repair.

Further Inpatient Care

Aspects of inpatient care are primarily governed by the treatment indicated for the particular disorder that causes pulmonic regurgitation. As previously mentioned, if heart failure is present that is due to or exacerbated by pulmonic regurgitation, usual heart failure management applies.

EMERGENCY PROSTHETIC VALVULAR HEART DISEASES

Replacement of diseased valves with prosthetic heart valves reduces the morbidity and mortality associated with native valvular disease, but it comes at the expense of risking complications related to the implanted prosthetic device. Emergency physicians must be able to rapidly identify patients at risk and begin appropriate diagnostic testing, stabilization, and treatment. Even when promptly recognized and treated, acute prosthetic valve failure is associated with a high mortality rate (Figs 16.103–16.113). FDA approves CoreValve self-expanding transcatheter aortic valve.

In January 2014, the FDA approved the self-expanding transcatheter aortic valve CoreValve (Medtronic, Minneapolis, MN) for patients unable to undergo aortic-valve surgery. Approval included the 23 mm, 26 mm, 29 mm, and 31 mm valves. The approval was based on a study of patients too sick or frail to be treated with conventional aortic-valve replacement surgery; the study demonstrated CoreValve to be safe and effective, with low rates of stroke and paravalvular leak. The rate of all-cause death and stroke among patients who received CoreValve in the study was 25.5%.

Signs and Symptoms

Signs and symptoms of prosthetic heart valve malfunction depend on the type of valve, its location, and the

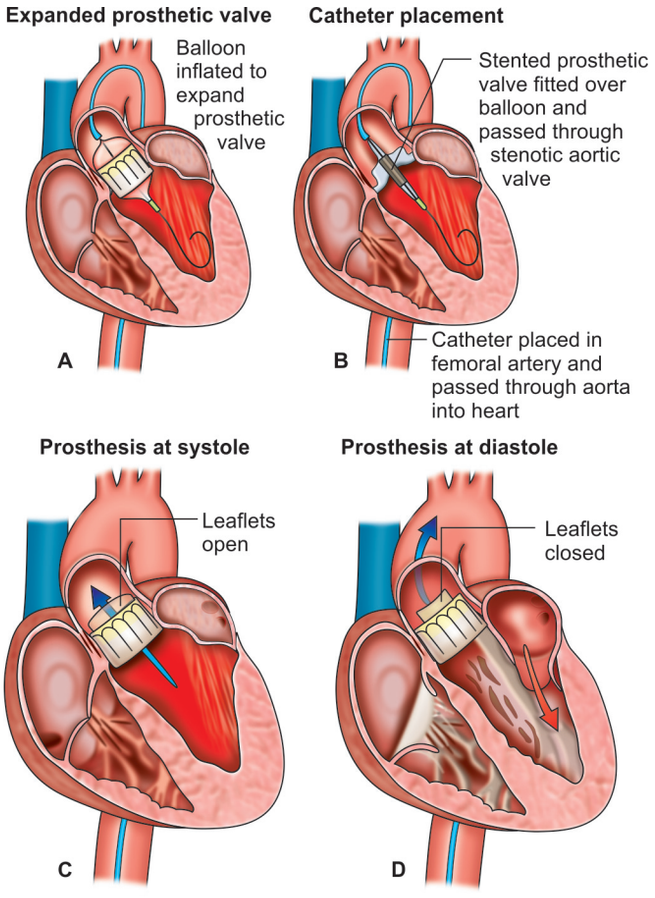

Fig. 16.103: (A) Expanded prosthetic aortic valve. (B) Catheter placement of aortic valve. (C) Aortic valve prosthesis during systole and (D) in diastole

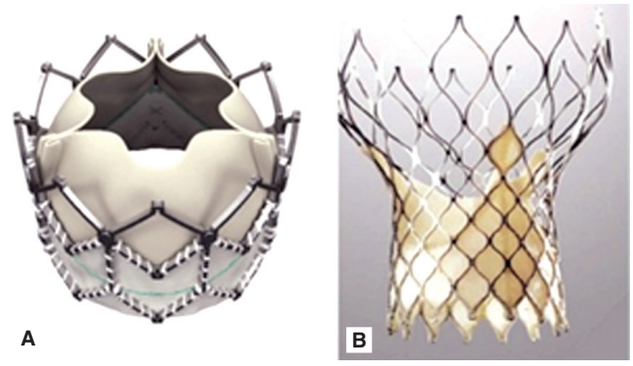

Fig. 16.104: Biological aortic valve prothesis with stent. (A) SAPIEN XT™, Edwards make (B) CoreValve™ medtronic make

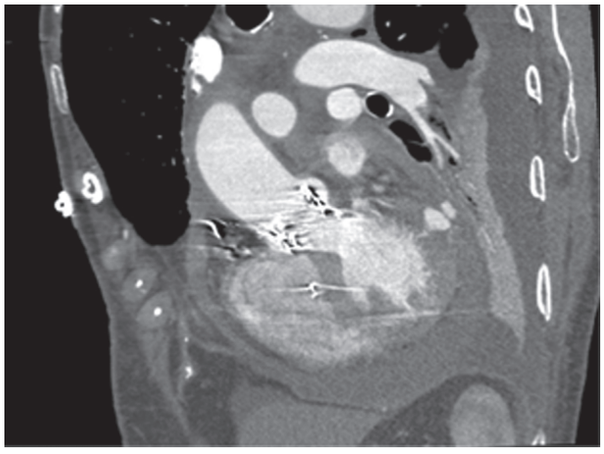

Fig. 16.105: Sagittal CT reconstruction of the thorax showing the implanted aortic valve. The left ventricle free wall defect with small pseudoaneurysm is also again noted

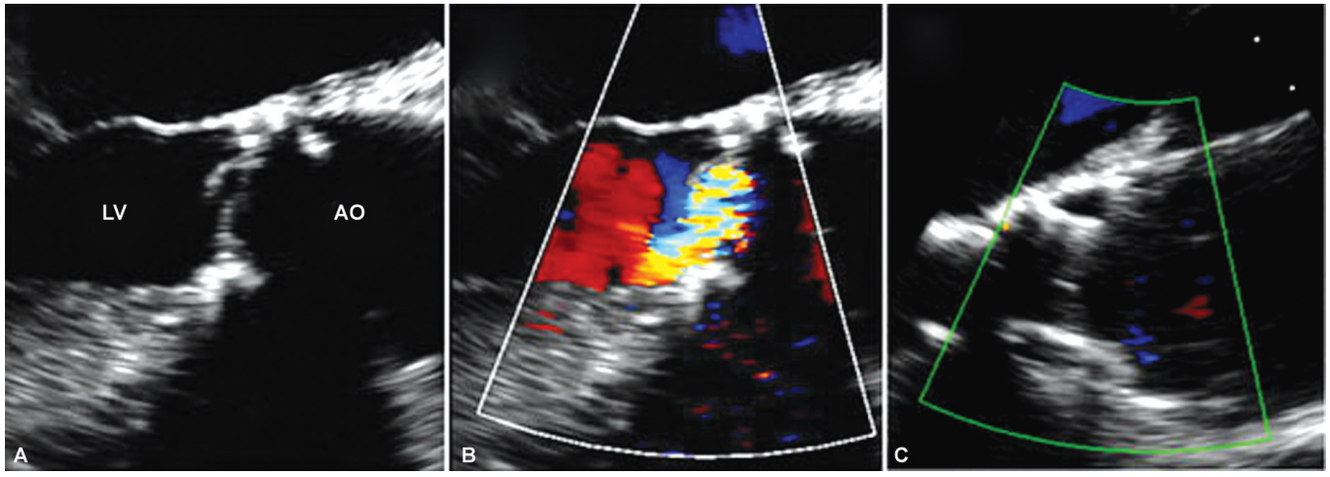

Fig.16.106: Echocardiographic results of 'valve-in-valve' implantation in a patient with degenerated aortic bioprosthesis. (A) and (B)—Carpentier-Edwards bioprosthesis with severe aortic regurgitation. (C) Absence of residuel regurgitation after Medtronic CoreValve implantation. AO=aorta, LV=left ventricle

nature of the complication. Presentations may include the following:

- **Acute prosthetic valve failure:** Sudden onset of dyspnea, syncope, or precordial pain
- **Acute aortic valve failure:** Sudden death; survivors have acute severe dyspnea, sometimes accompanied by precordial pain, or syncope
- **Subacute valvular failure:** Symptoms of gradually worsening congestive heart failure; they also may present

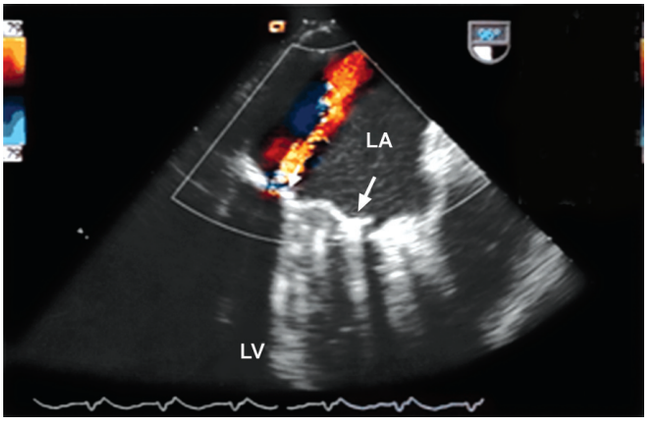

Fig. 16.107: Paravalvar leak. Transoesophageal, two-dimensional, color-Doppler image (longitudinal section) of the left atrium (LA) and left ventricle (LV) showing a bileaflet mitral prosthesis with the sewing ring marked by arrows and a posteriorly located paravalvar leak causing mild mitral regurgitation

with unstable angina or, at times, may be entirely asymptomatic

- **Embolic complications:** Symptoms related to the site of embolization [e.g. stroke, myocardial infarction (MI), sudden death, or symptoms of visceral or peripheral embolization].
- **Anticoagulant-related hemorrhage**: Symptoms related to the site of hemorrhage

A history of fever should raise the possibility of prosthetic valve endocarditis (PVE).

On physical examination, normal prosthetic heart valve sounds include the following:

- **Mechanical valves**: Loud, high-frequency, metallic closing sound; soft opening sound (tilting disc and bileaflet valves); low-frequency opening and closing sounds of nearly equal intensity (caged ball valves).
- **Tissue valves:** Closing similar to those of native valves, low-frequency early opening sound in the mitral position.

Prosthetic heart valve murmurs noted include the following:

- **Aortic prosthetic valves:** Some degree of outflow obstruction with a resultant systolic ejection murmur (loudest in caged ball and small porcine valves); low-intensity diastolic murmur (tilting disc and bileaflet valves).
- **Mitral prosthetic valves:** Low-grade systolic murmur (caged ball valves); short diastolic murmur (bioprostheses and, occasionally, St. Jude bileaflet valves).

Additional findings may include the following:

- ***Acute valvular failure:*** Evidence of poor tissue perfusion; hyperdynamic precordium and right ventricular impulse (50% of cases); absence of a normal valve closure sound or presence of an abnormal regurgitant murmur.
- ***Subacute valvular failure:*** Rales and jugular venous distention; signs of right-side failure; a new regurgitant murmur or absence of normal closing sounds; a new or worsening hemolytic anemia (may be the only presenting abnormality)
- ***PVE (often obscure):*** Fever (97% of cases); a new or changing murmur (56% of cases); classic signs of native

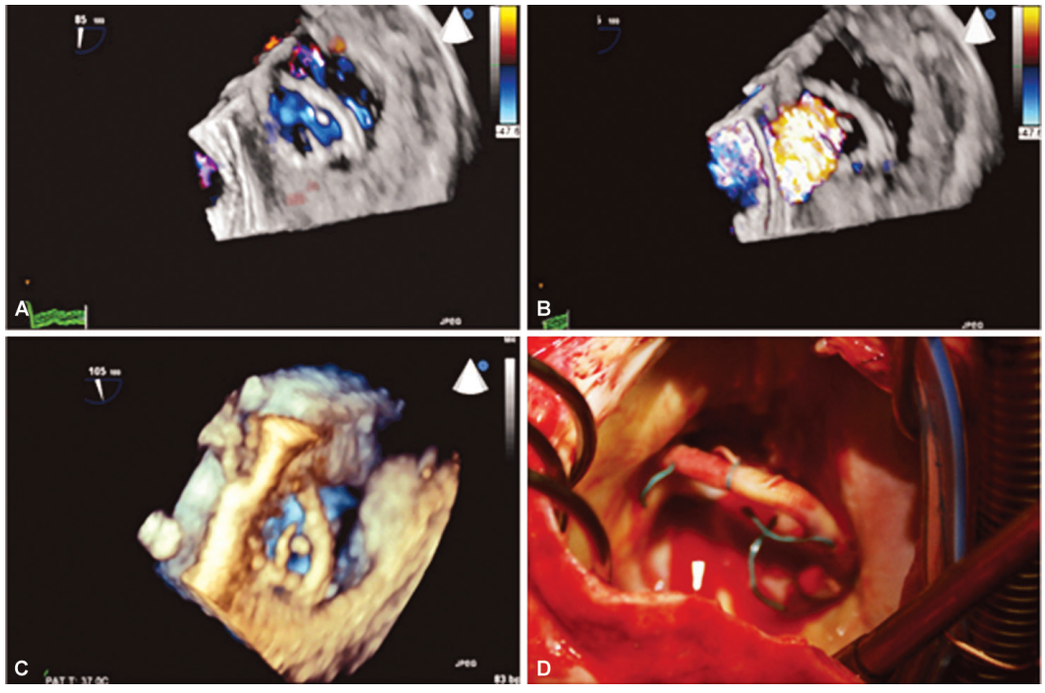

Fig. 16.108: A real-time three-dimensional (3D) transesophageal echocardiography zoom image demonstrates a peri-ring tissue defect (arrow) of the mitral posterior ring (arrow) on surgeon's view in end-systole (A) and mid-diastole (B). A full-volume 3D color image reveals the regurgitant jet from the peri-ring defect (arrow), differentiated from valvular regurgitation (C); this view is similar to what the surgeon saw (D)

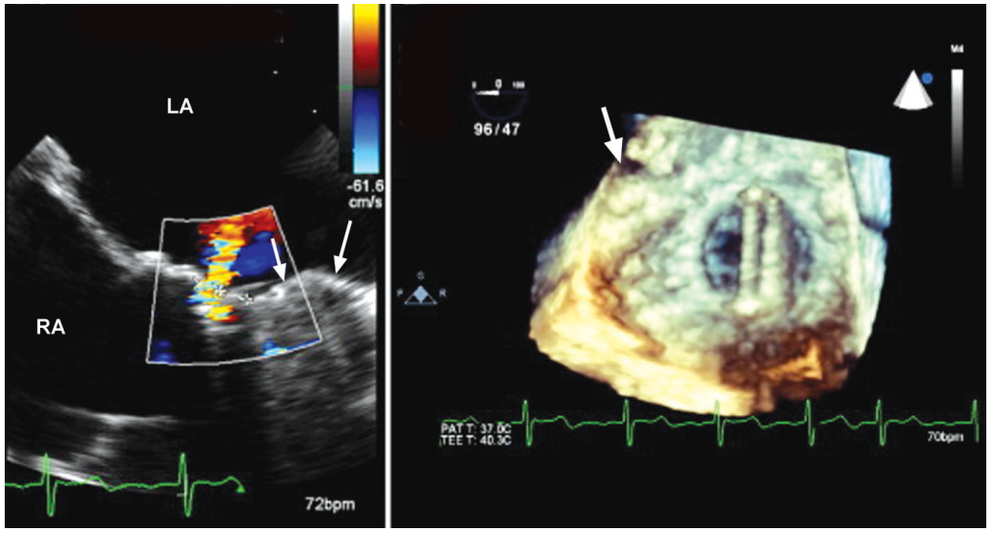

Fig. 16.109: 2D and 3D TEE in PV leak. Mid-esophageal 2D TEE view at 0° showing paravalvular (PV) leak located anteromedially between St. Jude's aortic and mitral prostheses. St. Jude's mitral valve disks in the closed position are shown by white arrows in A. (B) is the 3D TEE view showing St. Jude's mitral valve disks in the open position from the atrial aspect. A PV hole is seen at the 10 o'clock position (white arrow). The location of the PV leak made percutaneous repair nonfeasible. LA=left atrium; RA=right atrium

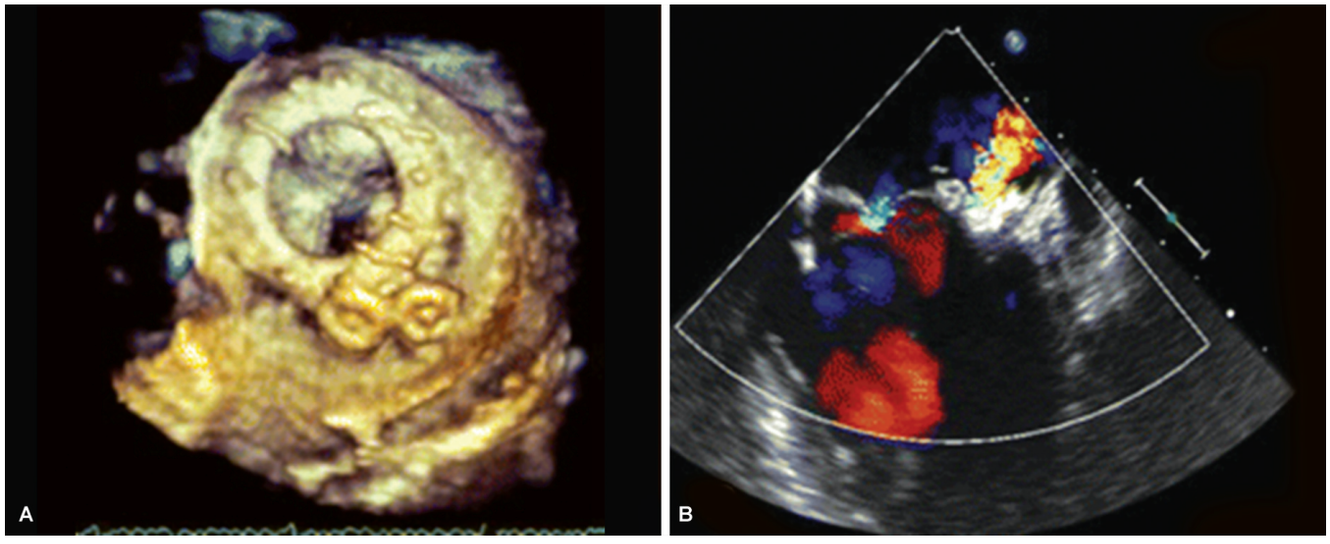

Fig. 16.110: (A) Two-dimensional TEE image with colour of mitral bioprosthesis demonstrating a significant reduction in the paravalvular leak after placement of two Amplatzer occluder devices. The degree of paravalvular regurgitation is significantly reduced after device placement (compare with figure prior to device placement). (B) Real-time 3D TEE assisted in the placement of this second Amplatzer Duct Occluder device (10/8 mm) deployed posterior to the first device occluding the majority of the paravalvular defect

valve endocarditis; splenomegaly; congestive heart failure, septic shock, or primary valvular failure; systemic emboli

Diagnosis

A. Laboratory studies that may be useful include the following:
- Complete blood count
- Blood urea nitrogen (BUN) and creatinine levels
- Urinalysis
- Blood culture
- Prothrombin time (PT) or international normalized ratio (INR)

B. Imaging studies that may be helpful include the following:
- **Chest radiography:** This can help in delineating the valvular morphology and determining whether the valve and occluder are intact; each of the most commonly used valve types has its own characteristic radiographic appearance

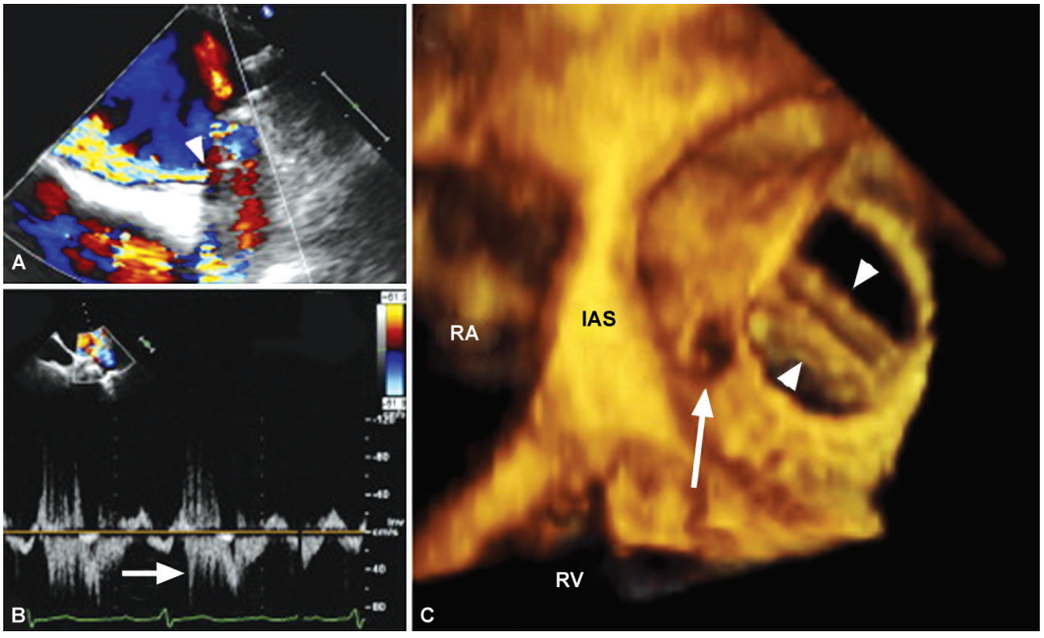

Fig. 16.111: Multidimensional echocardiographic evaluation of a prosthetic mitral PVL. (A) A 2D TEE demonstrating the paravalvular defect (arrowhead) with severe paravalvular regurgitation. (B) A 2D TEE pulse wave Doppler demonstrating marked systolic flow reversal (arrow) in the right upper pulmonary vein. (C) Real-time 3D TEE volumetric reconstruction demonstrating the anteromedial location of the paravalvular defect (arrow) and mechanical mitral valve leaflets (arrowheads). IAS=interatrial septum; PVL=paravalvular leak; RA=right atrium; RV=right ventricle; TEE=transesophageal echocardiography; 2D=2-dimensional; 3D=3-dimensional

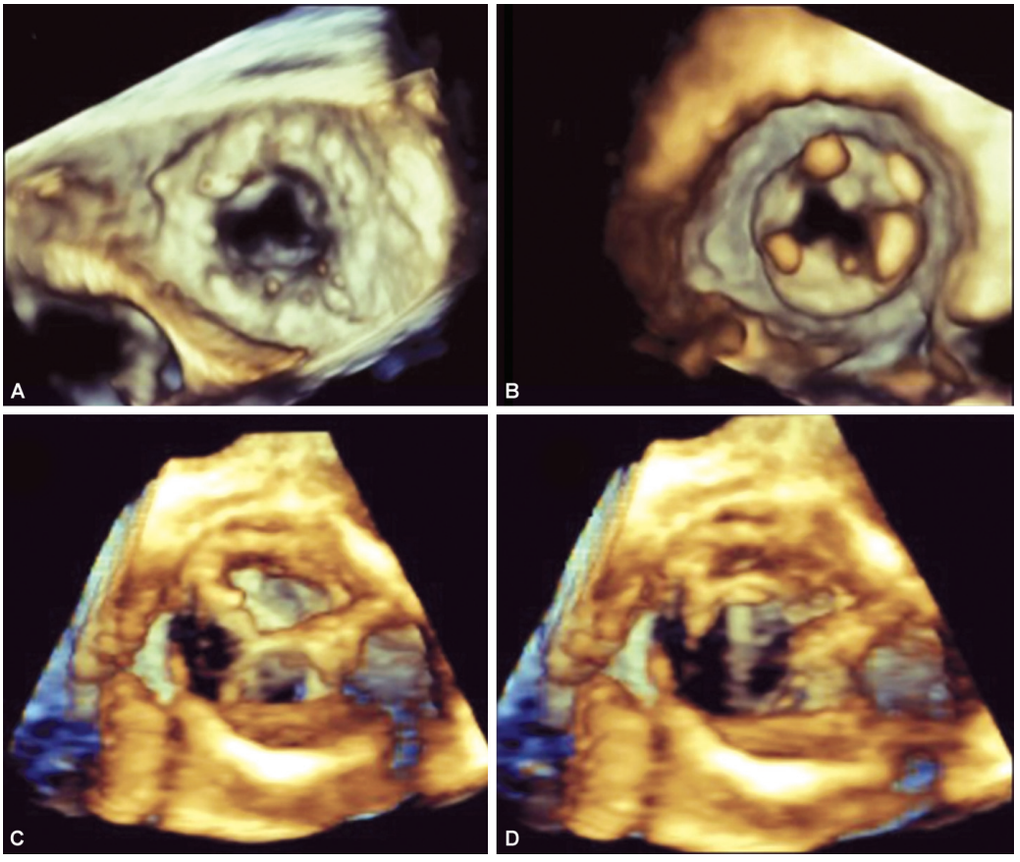

Fig. 16.112: Real-time three-dimensional transesophageal echocardiography (RT3D TEE) of a normal bioprosthetic tricuspid valve during diastole oriented as seen from the right atrium (A) and the right ventricle (B). The tricuspid ring is easily visualized but the leaflets are poorly seen. RT3D TEE of a normal bioprosthetic aortic valve oriented as seen from the aorta (C) and the left ventricular outflow tract (D). Again, the aortic leaflets, in contrast to the ring, are poorly visualized

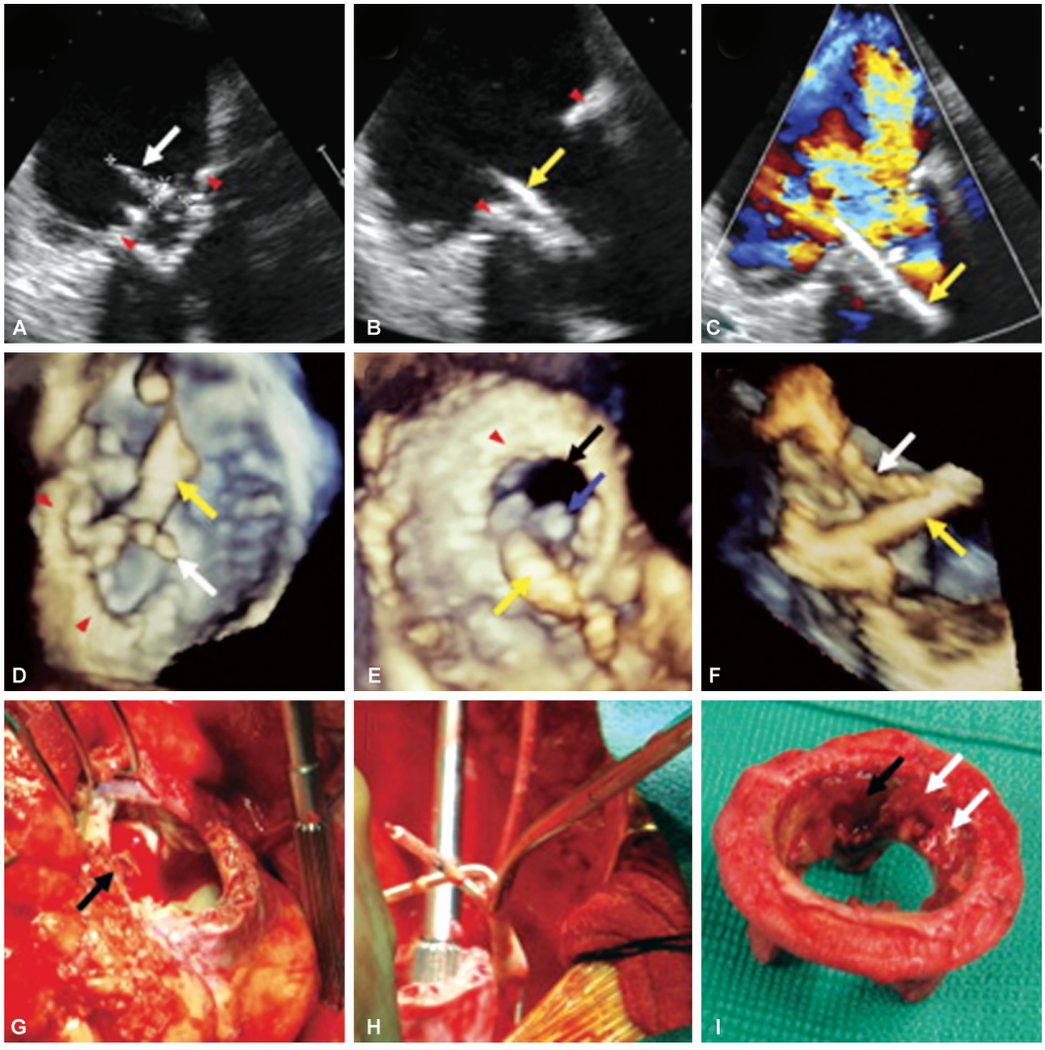

Fig. 16.113: Bioprosthetic tricuspid valve vegetation visualization by TEE and RT3D TEE and at valve explantation patient is a 53-year-old man with a history of intravenous drug abuse, hepatitis C infection, end-stage renal disease on hemodialysis, porcine tricuspid valve replacement, and a pacemaker placement 6 years ago. He had two episodes of infective endocarditis with enterococcus treated with vancomycin. Loud systolic murmur of tricuspid regurgitation and chest pain prompted echocardiographic evaluation. 2D TEE at mid-esophageal views of tricuspid inflow (A and B) demonstrate a vegetation (white arrows) protruding into the right atrium in proximity to the bioprosthetic tricuspid valve ring (red arrowheads) and an ICD lead (yellow arrows) that is traversing the tricuspid valve apparatus. Color-Doppler in the same plane (C) shows severe transvalvular tricuspid valve regurgitation. RT3D TEE full volume data sets show the tricuspid valve from the right atrial aspect (D and E) and in a longitudinal view (F). The entire profile of the bioprosthetic tricuspid valve ring is seen and can be distinguished from the ICD lead. A large perforation (black arrow) in the bioprosthetic tricuspid valve leaflet is seen in E. A large vegetation is seen in D and F (white arrows), originating from the tricuspid valve leaflet and sliding along the ICD lead. Intraoperative view of the bioprosthetic tricuspid valve (G) shows bioprosthetic tricuspid valve leaflet tear (black arrow). No vegetation is seen involving the atrial or ventricular pacemaker leads (H). The patient underwent tricuspid valve replacement. Leaflet tear is shown adjacent to the vegetation on the explanted tricuspid valve bioprosthesis (I)

- **Echocardiography** [two-dimensional, Doppler, transesophageal (the study of choice for a suspected prosthetic valve complication), transthoracic]
- **Cinefluorography:** This may detect impaired occluder movement but often cannot readily determine the aetiology
- **Computed tomography:** A consensus statement from the Society of Cardiovascular Computed Tomography (SCCT) states that CT should be performed as part of the evaluation of all patients being considered for transcatheter aortic valve implantation (TAVI)/transcatheter aortic valve replacement (TAVR), except those in whom CT is contraindicated, and that the CT images should be interpreted with a member of the TAVI/TAVR team or reviewed with the operator before the procedure.

Management

In patients with acute valvular failure, diagnostic studies must be performed simultaneously with resuscitative efforts.

Treatment approaches to primary valve failure include the following:

- Emergency valve replacement
- Concomitant adjunctive therapy
- Afterload reduction and inotropic support
- In selected cases, intra-aortic balloon counterpulsation

Treatment approaches to PVE include the following:

- Intravenous antibiotics administered as soon as two sets of blood cultures are drawn
- Cessation of warfarin until central nervous system involvement is ruled out and invasive procedures are determined to be unnecessary
- **Consideration of anticoagulation**
- Consideration of emergency surgery in patients with moderate to severe heart failure or with an unstable prosthesis noted on echocardiography or fluoroscopy

Treatment approaches to thromboembolic complications include the following:

- Anticoagulation (if it has not already been initiated or if the patient has a subtherapeutic INR)
- Assessment of valve function

Treatment approaches to prosthetic valve thrombosis include the following:

- Surgery (historically the mainstay of treatment but associated with a high mortality)
- Thrombolytic therapy (appropriate for selected patients with thrombosed prosthetic valves)—should always be performed in conjunction with cardiovascular surgical consultation
- In cases of major anticoagulant-related hemorrhage, reversal of anticoagulation

KEY POINTS

- In patients evaluated in the emergency department for chest pain, dyspnea, syncope, arrhythmia, or shock, the possibility of valvular heart disease should be considered.
- Emergency echocardiography is essential in elucidating whether acute valvular pathology is responsible for hemodynamic collapse in a patient with cardiogenic shock.
- An asymptomatic patient with a grade 2/6 systolic murmur needs no further work-up.
- Diastolic murmurs are always pathologic and require echocardiography.
- Endocarditis prophylaxis is recommended only for dental procedures and no longer needed for gastrointestinal or genitourinary procedures.

Medication in Valvular Heart Diseases

- *Atenolol:* 0.3–2 mg/kg/d PO, max. 2 mg/kg/d (peds: 1–2 mg/kg/dose PO daily suggested)
- *Digoxin:* 0.5 mg bolus IV, then 0.25 mg IV q2h up to 1 mg; 0.125–0.375 mg/d PO
- *Diltiazem:* 0.25 mg/kg IV over 2 min (repeat in 15 min PRN with 0.35 mg/kg) then 5–15 mg/h
- *Enalapril:* 1.25 mg IV q6h; PO 2.5–10 mg b.i.d. (peds: 0.1–0.5 mg/kg/d PO div. q12–24h; max: 0.58 mg/kg/d or 40 mg/d
- *Esmolol:* IV: 500 ¼g bolus, then 50–400 ¼g/kg/min
- *Furosemide:* 20–80 mg/d PO/IV/IM; titrate up to 600 mg/d for severe edematous states (peds: 1 mg/kg IV/IM slowly under close supervision; not to exceed 6 mg/kg)
- *Heparin:* 80 IU/kg IV bolus, then 18 IU/kg/hr drip, adjust to maintain partial thromboplastin time 1.5–2 × control (INR 2–3)
- *Hydralazine:* 10–25 mg IV q2–4h (peds: 0.1–0.5 mg/kg IM/IV q4–6h; max. 20 mg/dose)
- *Metoprolol:* 5 mg IV q2min × 3 doses; then 50 mg PO q6h × 48 hr
- *Nitroglycerin:* Start at 20 mcg/min IV and titrate to effect (up to 300 mcg/min); SL 0.3–0.6 mg p.r.n.; Topical 1–2 inches of 2% q6h (peds: 0.25–0.5 ¼ g/kg/min IV, increase by 0.5–1 mg/kg/min; max. 20¼g/kg/min)
- *Phentolamine:* 5 mg bolus IV, then 1–2 mg/min IV infusion
- *Propranolol IV:* 1–3 mg at 1 mg/min
- *Sodium nitroprusside IV:* 0.5 ¼g/kg/min; increase in increments of 0.5 to 1.0 ¼g/kg/min q5–10 min up to 10¼g/kg/min
- *Amoxicillin:* 2 g PO 1h before the procedure; alternatively, 3 g PO 1h before the procedure, followed by 1.5 g PO 6h after the initial dose:
- *Pediatric dose:* 50 mg/kg PO 1h before procedure
- *Ampicillin:* 2 g IV/IM 30 min before the procedure (peds: 50 mg/kg IV/IM 30 min before the procedure)
- *Clindamycin:* 600 mg PO 1h before procedure (peds: 20 mg/kg PO 1h before procedure; not to exceed 600 mg).

BIBLIOGRAPHY

1. Acikel M, Erol MK, Yekeler I, Ozyazicioglu A. A case of free-floating ball thrombus in right atrium with tricuspid stenosis. Int J Cardiol 2004;94(2–3):329–30.
2. Acker MA, Parides MK, Perrault LP, et al, for The Cardiothoracic Surgical Trials Network. Mitral-valve repair versus replacement for severe ischemic mitral regurgitation. N Engl J Med 2013.
3. Adachi O, Saiki Y, Akasaka J, Oda K, Iguchi A, Tabayashi K. Surgical management of aortic regurgitation associated with takayasu arteritis and other forms of aortitis. Ann Thorac Surg 2007;84(6):1950–3.
4. Aggarwal A, Raghuvir R, Eryazici P, Macaluso G, Sharma P, Blair C, et al. The development of aortic insufficiency in continuous-flow left ventricular assist device-supported patients. Ann Thorac Surg 2013;95(2):493–8.
5. Aggarwal A, Raghuvir R, Eryazici P, Macaluso G, Sharma P, Blair C, et al. The development of aortic insufficiency in continuous-flow left ventricular assist device-supported patients. Ann Thorac Surg 2013;95(2):493–8.

6. Alpert MA, Mukerji V, Sabeti M, et al. Mitral valve prolapse, panic disorder, and chest pain. Med Clin North Am 1991; 75(5):1119–33.
7. American College of Cardiology/American Heart Association. ACC/AHA 2006 guidelines for the management of patients with valvular heart disease. A report of the American College of Cardiology/American Heart Association Task Force on Practice Guidelines (writing committee to revise the 1998 guidelines for the Manag. J Am Coll Cardiol 2006;48:1–148.
8. American College of Cardiology/American Heart Association. ACC/AHA guidelines for the management of patients with valvular heart disease. A report of the American College of Cardiology/American Heart Association. Task Force on Practice Guidelines (Committee on Management of Patients with Valvular Heart Disease. J Am Coll Cardiol 1998;32(5):1486–588.
9. Anderson C, Filsoufi F, Farivar RS, Adams DH. Optimal management of severe tricuspid regurgitation in cardiac transplant recipients. J Heart Lung Transplant. 2001; 20(2):247.
10. Antonini-Canterin F, Moura LM, Enache R, Leiballi E, Pavan D, Piazza R. Effect of hydroxymethylglutaryl coenzyme-a reductase inhibitors on the long-term progres-sion of rheumatic mitral valve disease. Circulation 2010; 121(19):2130–6.
11. Atalar E, Yorgun H, Canpolat U, Sunman H, Kepez A, Kocabas U, et al. Prevalence of coronary artery disease before valvular surgery in patients with rheumatic valvular disease. Coron Artery Dis 2012;23(8):533–7.
12. Avierinos JF, Gersh BJ, Melton LJ 3rd, Bailey KR, Shub C, Nishimura RA, et al. Natural history of asymptomatic mitral valve prolapse in the community. Circulation 2002; 106(11):1355–61.
13. Babu AN, Kymes SM, Carpenter Fryer SM. Eponyms and the diagnosis of aortic regurgitation: what says the evidence?. Ann Intern Med 2003;138(9):736–42.
14. Badheka AO, Shah N, Ghatak A, Patel NJ, Chothani A, Mehta K, et al. Balloon Mitral Valvuloplasty in United States: A 13 year perspective. Am J Med 2014.
15. Barbieri A, Bursi F, Grigioni F, Tribouilloy C, Avierinos JF, Michelena HI, et al. Prognostic and therapeutic implications of pulmonary hypertension complicating degenerative mitral regurgitation due to flail leaflet: A Multicenter Long-term International Study. Eur Heart J 2011;32(6):751–759.
16. Barnett HJ, Boughner DR, Taylor DW, Cooper PE, Kostuk WJ, Nichol PM. Further evidence relating mitral-valve prolapse to cerebral ischemic events. N Engl J Med 1980; 302(3):139–44.
17. Bekeredjian R, Grayburn PA. Valvular heart disease: aortic regurgitation. Circulation 2005;112(1):125–34.
18. Bhudia SK, McCarthy PM, Kumpati GS, Helou J, Hoercher KJ, Rajeswaran J, et al. Improved outcomes after aortic valve surgery for chronic aortic regurgitation with severe left ventricular dysfunction. J Am Coll Cardiol 2007;49(13): 1465–71.
19. Bonow RO, Carabello BA, Chatterjee K, de Leon AC Jr, Faxon DP, Freed MD. 2008 focused update incorporated into the ACC/AHA 2006 guidelines for the management of patients with valvular heart disease: a report of the American College of Cardiology/American Heart Association Task Force on Practice Guidelines (Writing Committee to revise the 1998 guidelines for the management of patients with valvular heart disease). Endorsed by the Society of Cardiovascular Anesthesiologists, Society for Cardiovascular Angiography and Interventions, and Society of Thoracic Surgeons. J Am Coll Cardiol 2008;52(13):e1–142.
20. Bonow RO, Carabello BA, Chatterjee K, et al. 2008 focused update incorporated into the ACC/AHA 2006 guidelines for the management of patients with valvular heart disease: a report of the American College of Cardio-logy/American Heart Association Task Force on Practice Guidelines (Writing Committee to revise the 1998 guidelines for the management of patients with valvular heart disease). Endorsed by the Society of Cardiovascular Anesthesiologists, Society for Cardiovascular Angiography and Interventions, and Society of Thoracic Surgeons. J Am Coll Cardiol 2008; 52(13):e1–142.
21. Bonow RO, Carabello BA, Kanu C, et al. ACC/AHA 2006 guidelines for the management of patients with valvular heart disease: a report of the American College of Cardiology/American Heart Association Task Force on Practice Guidelines (writing committee to revise the 1998 Guidelines for the Management of Patients With Valvular Heart Disease): developed in collaboration with the Society of Cardiovascular Anesthesiologists: endorsed by the Society for Cardiovascular Angiography and Interventions and the Society of Thoracic Surgeons. Circulation 2006; 114(5): e84–231.
22. Bonow RO, Cheitlin MD, Crawford MH, Douglas PS. Task Force 3: valvular heart disease. J Am Coll Cardiol 2005; 45(8):1334–40.
23. Braunwald E. Heart Disease: A Textbook of Cardiovascular Medicine. 3rd ed. Philadelphia, Pa: Saunders; 1988.
24. Bruce CJ, Nishimura RA. Newer advances in the diagnosis and treatment of mitral stenosis. Curr Probl Cardiol 1998; 23(3):125–92.
25. Bryhn M, Persson S. The prevalence of mitral valve prolapse in healthy men and women in Sweden. An echocardiographic study. Acta Med Scand 1984;215(2): 157–60.
26. Carabello BA, Paulus WJ. Aortic stenosis. Lancet 2009; 373(9667):956–66.
27. Carabello BA. Progress in mitral and aortic regurgitation. Prog Cardiovasc Dis 2001;43(6):457–75.
28. Chambers JB. Aortic stenosis. Eur J Echocardiogr 2009; 10(1):i11–9.
29. Chand EM, Freant LJ, Rubin JW. Aortic valve rheumatoid nodules producing clinical aortic regurgitation and a review of the literature. Cardiovasc Pathol 1999;8(6): 333–8.
30. Christ T, Grubitzsch H, Claus B, Konertz W. Long-term follow-up after aortic valve replacement with Edwards Prima Plus stentless bioprostheses in patients younger than 60 years of age. J Thorac Cardiovasc Surg 2012.
31. Ciancamerla F, Paglia I, Catuzzo B, Morello M, Mangiardi L. Sudden death in mitral valve prolapse and severe mitral regurgitation. Is chordal rupture an indication to early surgery? J Cardiovasc Surg (Torino) 2003;44(2):283–6.
32. Collins MJ, Butany J, Borger MA, Strauss BH, David TE. Implications of a congenitally abnormal valve: a study of

1025 consecutively excised aortic valves. J Clin Pathol 2008; 61(4):530–6.
33. DeLeon MA, Gidding SS, Gotteiner N, Backer CL, Mavroudis C. Successful palliation of Ebstein's malformation on the first day of life following fetal diagnosis. Cardiol Young 2000; 10(4):384–7.
34. Ducharme V, Guauque-Olarte S, Gaudreault N, Pibarot P, Mathieu P, Bossé Y. NOTCH1 genetic variants in patients with tricuspid calcific aortic valve stenosis. J Heart Valve Dis 2013;22(2):142–9.
35. Dujardin KS, Enriquez-Sarano M, Schaff HV, Bailey KR, Seward JB, Tajik AJ. Mortality and morbidity of aortic regurgitation in clinical practice. A long-term follow-up study. Circulation 1999;99(14):1851–7.
36. Duncan AI, Lin J, Koch CG, Gillinov AM, Xu M, Starr NJ. The impact of gender on in-hospital mortality and morbidity after isolated aortic valve replacement. Anesth Analg 2006; 103(4):800–8.
37. Eberhardt RT, Dhadly M. Giant cell arteritis: diagnosis, management, and cardiovascular implications. Cardiol Rev 2007;15(2):55–61.
38. Ennezat PV, Marechaux S, Iung B, Chauvel C, LeJemtel TH, Pibarot P. Exercise testing and exercise stress echocardio-graphy in asymptomatic aortic valve stenosis. Heart 2009; 95(11):877–84.
39. Enriquez-Sarano M, Avierinos JF, Messika-Zeitoun D, Detaint D, Capps M, Nkomo V, et al. Quantitative determinants of the outcome of asymptomatic mitral regurgitation. N Engl J Med 2005;352(9):875–83.
40. Etchells E, Bell C, Robb K. Does this patient have an abnormal systolic murmur? JAMA 1997;277(7):564–71.
41. Faletra F, La Marchesina U, Bragato R, De Chiara F. Three dimensional transthoracic echocardiography images of tricuspid stenosis. Heart 2005;91(4):499.
42. Fann JI, Ingels NB, Miller DC. Pathophysiology of Mitral Valve Disease. Cardiac Surgery in the Adult. 3rd ed. New York, NY: McGraw-Hill; 2008. chap 41.
43. Fedak PW, Verma S, David TE, Leask RL, Weisel RD, Butany J. Clinical and pathophysiological implications of a bicuspid aortic valve. Circulation 2002;106(8):900–4.
44. Feldman T, Cilingiroglu M. Percutaneous leaflet repair and annuloplasty for mitral regurgitation. J Am Coll Cardiol 2011; 57(5):529–37.
45. Feldman T, Foster E, Glower DG, et al. Percutaneous repair or surgery for mitral regurgitation. N Engl J Med 2011; 364(15):1395–406.
46. Feldman T. Rheumatic heart disease. Curr Opin Cardiol 1996; 11(2):126–30.
47. Feldman T. Rheumatic Mitral Stenosis. Curr Treat Options Cardiovasc Med 2000;2(2):93–104.
48. Filsoufi F, Anyanwu AC, Salzberg SP, et al. Long-term outcomes of tricuspid valve replacement in the current era. Ann Thorac Surg 2005;80(3):845–50.
49. Frater R. Tricuspid insufficiency. J Thorac Cardiovasc Surg 2001;122(3):427–9.
50. Freed LA, Levy D, Levine RA, et al. Prevalence and clinical outcome of mitral-valve prolapse. N Engl J Med 1999; 341(1):1–7.
51. Friedman T, Mani A, Elefteriades JA. Bicuspid aortic valve: clinical approach and scientific review of a common clinical entity. Expert Rev Cardiovasc Ther 2008;6(2):235–48.
52. Gatti G, Maffei G, Lusa AM, Pugliese P. Tricuspid valve repair with the Cosgrove-Edwards annuloplasty system: early clinical and echocardiographic results. Ann Thorac Surg 2001;72(3):764–7.
53. Gaztanaga J, Pizarro G, Sanz J. Evaluation of cardiac valves using multidetector CT. Cardiol Clin 2009;27(4): 633–44.
54. Gerber IL, Stewart RA, Legget ME, et al. Increased plasma natriuretic peptide levels reflect symptom onset in aortic stenosis. Circulation 2003;107(14):1884–90.
55. Gerber MA, Baltimore RS, Eaton CB, Gewitz M, Rowley AH, Shulman ST, et al. Prevention of rheumatic fever and diagnosis and treatment of acute Streptococcal pharyngitis: a scientific statement from the American Heart Association Rheumatic Fever, Endocarditis, and Kawasaki Disease Committee of the Council on Cardiovascular Disease in the Young, the Interdisciplinary Council on Functional Genomics and Translational Biology, and the Interdisciplinary Council on Quality of Care and Outcomes Research: endorsed by the American Academy of Pediatrics. Circulation 2009;119(11): 1541–51.
56. Giuliani E. Cardiology: Fundamentals and Practice. 2nd ed. Philadelphia, Pa: Mosby Year Book; 1991.
57. Godart F, Baruteau AE, Petit J, et al. Transcatheter tricuspid valve implantation: A multicentre French study. Arch Cardiovasc Dis 2014;107(11):583–91.
58. Gorlin R, Gorlin SG. Hydraulic formula for calculation of the area of the stenotic mitral valve, other cardiac valves, and central circulatory shunts. Am Heart J 1951;41(1): 1–29.
59. Gould KL, Carabello BA. Why angina in aortic stenosis with normal coronary arteriograms?. Circulation 2003; 107(25):3121–3.
60. Gould ST, Srigunapalan S, Simmons CA, Anseth KS. Hemodynamic and cellular response feedback in calcific aortic valve disease. Circ Res 2013;113(2):186–97.
61. Ha JW, Chung N, Jang Y, Rim SJ. Tricuspid stenosis and regurgitation: Doppler and color flow echocardiography and cardiac catheterization findings. Clin Cardiol 2000; 23(1): 51–2.
62. Henri C, Pierard LA, Lancellotti P, Mongeon FP, Pibarot P, Basmadjian AJ. Exercise Testing and Stress Imaging in Valvular Heart Disease. Can J Cardiol 2014;30(9): 1012–26.
63. Holmes DR Jr, Mack MJ. Transcatheter valve therapy a professional society overview from the american college of cardiology foundation and the society of thoracic surgeons. J Am Coll Cardiol 2011;58(4):445–55.
64. Horstkotte D, Niehues R, Strauer BE. Pathomorphological aspects, aetiology and natural history of acquired mitral valve stenosis. Eur Heart J. 1991; Suppl B:55–60.
65. Iwataki M, Takeuchi M, Otani K, et al. Calcific extension towards the mitral valve causes non-rheumatic mitral stenosis in degenerative aortic stenosis: real-time 3D transoesophageal echocardiography study. Open Heart 2014; 1(1):e000136.

66. Jain D, Halushka MK. Cardiac pathology of systemic lupus erythematosus. J Clin Pathol 2009;62(7):584–92.
67. Jeserich M, Ihling C, Holubarsch C. Aortic valve endocarditis with Whipple disease. Ann Intern Med 1997;126(11): 920.
68. Kaden JJ, Eckert JP, Poerner T, et al. Prevalence of atherosclerosis of the coronary and extracranial cerebral arteries in patients undergoing aortic valve replacement for calcified stenosis. J Heart Valve Dis 2006;15(2):165–8.
69. Keane MG, Pyeritz RE. Medical management of Marfan syndrome. Circulation 2008;117(21):2802–13.
70. Khan IA. Ebstein's anomaly of the tricuspid valve with associated mitral valve prolapse. Tex Heart Inst J 2001; 28(1):72.
71. Khanna D, Miller AP, Nanda NC, et al. Transthoracic and transesophageal echocardiographic assessment of mitral regur-gi-tation severity: usefulness of qualitative and semi-quantitative techniques. Echocardiography 2005;22(9): 748–69.
72. Kloner R. The Guide to Cardiology. 2nd ed. New York: Le Jacq Communications; 1990.
73. Kulbertus HE. Ventricular arrhythmias, syncope and sudden death in aortic stenosis. Eur Heart J 1988; Suppl E: 51–2.
74. Lancellotti P, Tribouilloy C, Hagendorff A, Moura L, Popescu BA, Agricola E, et al. European Association of Echocardiography recommendations for the assessment of valvular regurgitation. Part 1: aortic and pulmonary regurgitation (native valve disease). Eur J Echocardiogr 2010;11(3): 223–44.
75. Leach RM, McBrien DJ. Brachioradial delay: a new clinical indicator of the severity of aortic stenosis. Lancet 1990; 335(8699):1199–201.
76. Lee JL, Naguwa SM, Cheema GS, Gershwin ME. Acute rheumatic fever and its consequences: a persistent threat to developing nations in the 21st century. Autoimmun Rev 2009;9(2):117–23.
77. Lee JL, Naguwa SM, Cheema GS, Gershwin ME. Revisiting Libman-Sacks endocarditis: a historical review and update. Clin Rev Allergy Immunol 2009;36(2–3):126–30.
78. Lev M, Liberthson RR, Joseph RH, Seten CE, Eckner FA, Kunske RD, et al. The pathologic anatomy of Ebstein's disease. Arch Pathol 1970;90(4):334–43.
79. Levine RA, Triulzi MO, Harrigan P, Weyman AE. The relationship of mitral annular shape to the diagnosis of mitral valve prolapse. Circulation 1987;75(4):756–67.
80. Libby P, Bonow RO, MD, Zipes DP, Mann DL. Valvular Heart Disease. Braunwald's Heart Disease. 8th ed. Philadelphia, PA: Saunders Elsevier; 2008. chap. 62.
81. Luo GH, Ma WG, Sun HS, et al. Correction of traumatic tricuspid insufficiency using the double orifice technique. Asian Cardiovasc Thorac Ann 2005;13(3):238–40.
82. Magne J, Lancellotti P, O'Connor K, et al. Prediction of exer-cise pulmonary hypertension in asymptomatic degenerative mitral regurgitation. J Am Soc Echocardiogr 2011;24(9): 1004–12.
83. Marcus RH, Sareli P, Pocock WA, et al. The spectrum of severe rheumatic mitral valve disease in a developing country. Correlations among clinical presentation, surgical pathologic findings, and hemodynamic sequelae. Ann Intern Med 1994;120(3):177–83.
84. Matsunaga A, Duran CM. Progression of tricuspid regurgitation after repaired functional ischemic mitral regurgitation. Circulation 2005;112(9 Suppl):I453–7.
85. Maurer G. Aortic regurgitation. Heart 2006;92(7):994–1000.
86. Mehta RH, Eagle KA, Coombs LP, Peterson ED, Edwards FH, Pagani FD, et al. Influence of age on outcomes in patients undergoing mitral valve replacement. Ann Thorac Surg. 2002;74(5):1459–67.
87. Mehta Y, Singh R. Quantification of AS and AR. Ann Card Anaesth 2009;12(2):166.
88. Minners J, Allgeier M, Gohlke-Baerwolf C, Kienzle RP, Neumann FJ, Jander N. Inconsistencies of echocardiographic criteria for the grading of aortic valve stenosis. Eur Heart J 2008;29(8):1043–8.
89. Morello A, Gelfand EV. Cardiovascular magnetic resonance imaging for valvular heart disease. Curr Heart Fail Rep 2009; 6(3):160–6.
90. Moyssakis I, Tektonidou MG, Vasilliou VA, Samarkos M, Votteas V, Moutsopoulos HM. Libman-Sacks endocarditis in systemic lupus erythematosus: prevalence, associations, and evolution. Am J Med 2007;120(7):636–42.
91. Myerson SG. Valvular and hemodynamic assessment with CMR. Heart Fail Clin 2009;5(3):389–400.
92. Nishimura RA, Carabello BA, Faxon DP, et al. ACC/AHA 2008 Guideline update on valvular heart disease: focused update on infective endocarditis: a report of the American College of Cardiology/American Heart Asso-ciation Task Force on Practice Guidelines endorsed by the Society of Cardiovascular Anesthesiologists, Society for Cardiovascular Angiography and Interventions, and Society of Thoracic Surgeons. J Am Coll Cardiol 2008;52(8):676–85.
93. Nishimura RA, Otto CM, Bonow RO, Carabello BA, Erwin JP 3rd, Guyton RA, et al. 2014 AHA/ACC guideline for the management of patients with valvular heart disease: a report of the American College of Cardiology/American Heart Association Task Force on Practice Guidelines. J Am Coll Cardiol 2014;63(22):e57–185.
94. Nishimura RA, Otto CM, Bonow RO, et al. AHA/ACC guideline for the management of patients with valvular heart disease: a report of the American College of Cardiology/American Heart Association Task Force on Practice Guidelines. J Am Coll Cardiol 2014;63(22):e57–185.
95. Normand J, Loire R, Zambartas C. The anatomical aspects of adult aortic stenosis. Eur Heart J 1988; Suppl E: 31–6.
96. O'Brien KD, Reichenbach DD, Marcovina SM, et al. Apolipo-proteins B, (a), and E accumulate in the morphologically early lesion of 'degenerative' valvular aortic stenosis. Arterioscler Thromb Vasc Biol 1996;16(4): 523–32.
97. O'Riordan M. Early surgery bests "watchful waiting" in severe MR patients without symptoms. Medscape Medical News. Accessed August 19, 2013.
98. O'Riordan M. FDA approves MitraClip for degenerative MR. Oct. 25, 2013. Abbott. Abbott's first-in-class MitraClip device now available for U.S. patients [press release]. 2013.
99. O'Riordan M. Repair and surgery fare equally well in ischemic MR. Heartwire 2013.
100. Ortiz JT, Shin DD, Rajamannan NM. Approach to the patient with bicuspid aortic valve and ascending aorta

aneurysm. Curr Treat Options Cardiovasc Med 2006;8(6): 461–7.
101. Otto CM, Kuusisto J, Reichenbach DD, Gown AM, O'Brien KD. Characterization of the early lesion of 'degenerative' valvular aortic stenosis. Histological and immunohistochemical studies. Circulation 1994;90(2):844–53.
102. Otto CM. Surgery for mitral regurgitation: sooner or later?. JAMA 2013;310(6):587–8.
103. Palazzi C, D'Angelo S, Lubrano E, Olivieri I. Aortic involvement in ankylosing spondylitis. Clin Exp Rheumatol 2008; 26(3 Suppl 49):S131–4.
104. Palta S, Pai AM, Gill KS, Pai RG. New insights into the progression of aortic stenosis: implications for secondary prevention. Circulation 2000;101(21):2497–502.
105. Perloff JK, Child JS, Edwards JE. New guidelines for the clinical diagnosis of mitral valve prolapse. Am J Cardiol 1986;57(13):1124–9.
106. Perloff JK, Child JS. Mitral valve prolapse. Evolution and refinement of diagnostic techniques. Circulation 1989; 80(3):710–1.
107. Picano E, Pibarot P, Lancellotti P, Monin JL, Bonow RO. The emerging role of exercise testing and stress echocardiography in valvular heart disease. J Am Coll Cardiol 2009;54(24):2251–60.
108. Pizarro R, Bazzino OO, Oberti PF, Falconi M, Achilli F, Arias A, et al. Prospective validation of the prognostic usefulness of brain natriuretic peptide in asymptomatic patients with chronic severe mitral regurgitation. J Am Coll Cardiol 2009; 54(12):1099–106.
109. Quere JP, Monin JL, Levy F, et al. Influence of preoperative left ventricular contractile reserve on postoperative ejection fraction in low-gradient aortic stenosis. Circulation. 2006; 113(14):1738–44.
110. Rahimtoola SH. Choice of prosthetic heart valve in adults an update. J Am Coll Cardiol 2010;55(22):2413–26.
111. Rahimtoola SH. Choice of Prosthetic Heart Valve in Adults An Update. J Am Coll Cardiol. 2010;55(22):2413–26.
112. Rajamannan NM, Bonow RO, Rahimtoola SH. Calcific aortic stenosis: an update. Nat Clin Pract Cardiovasc Med 2007; 4(5):254–62.
113. Roberts PA, Boudjemline Y, Cheatham JP, et al. Percutaneous Tricuspid Valve Replacement in Congenital and Acquired Heart Disease. JACC 2011;58:117–22.
114. Roberts PA, Boudjemline Y, Cheatham JP. Percutaneous Tricuspid Valve Replacement in Congenital and Acquired Heart Disease. JACC 2011;58:117–22.
115. Roberts WC, Vowels TJ, Ko JM. Natural history of adults with congenitally malformed aortic valves (unicuspid or bicuspid). Medicine (Baltimore) 2012;91(6):287–308.
116. Rosenhek R, Rader F, Klaar U, Gabriel H, Krejc M, Kalbeck D, et al. Outcome of watchful waiting in asymptomatic severe mitral regurgitation. Circulation 2006;113(18): 2238–44.
117. Rossi A, Dini FL, Faggiano P, et al. Independent prognostic value of functional mitral regurgitation in patients with heart failure. A quantitative analysis of 1256 patients with ischaemic and non-ischaemic dilated cardiomyopathy. Heart 2011;97(20):1675–80.
118. Sambola A, Tornos P, Ferreira-Gonzalez I, Evangelista A. Prognostic value of preoperative indexed end-systolic left ventricle diameter in the outcome after surgery in patients with chronic aortic regurgitation. Am Heart J 2008; 155(6):1114–20.
119. Sampat U, Varadarajan P, Turk R, Kamath A, Khandhar S, Pai RG. Effect of beta-blocker therapy on survival in patients with severe aortic regurgitation results from a cohort of 756 patients. J Am Coll Cardiol 2009;54(5):452–7.
120. Saura D, Peñafiel P, Martínez J, de la Morena G, García-Alberola A, Soria F, et al. [The frequency of systolic aortic regurgitation and its relationship to heart failure in a consecutive series of patients]. Rev Esp Cardiol 2008; 61(7):771–4.
121. Schirmer M, Weidinger F, Sandhofer A, Gschwendtner A, Wiedermann C. Valvular disease and myocardial infarctions in a patient with Behçet disease. J Clin Rheumatol 2003; 9(5):316–20.
122. Schlosshan D, Aggarwal G, Mathur G, Allan R, Cranney G. Real-time 3D transesophageal echocardiography for the evaluation of rheumatic mitral stenosis. JACC Cardiovasc Imaging 2011;4(6):580–8.
123. Shah PM, Raney AA. Tricuspid valve disease. Curr Probl Cardiol 2008;33(2):47–84.
124. Simula DV, Edwards WD, Tazelaar HD, et al. Surgical pathology of carcinoid heart disease: a study of 139 valves from 75 patients spanning 20 years. Mayo Clin Proc 2002; 77(2):139–47.
125. Singh JP, Evans JC, Levy D, et al. Prevalence and clinical determinants of mitral, tricuspid, and aortic regurgitation (the Framingham Heart Study). Am J Cardiol 1999; 83(6): 897–902.
126. Sinning JM, Vasa-Nicotera M, Chin D, Hammerstingl C, Ghanem A, Bence J, et al. Evaluation and management of paravalvular aortic regurgitation after transcatheter aortic valve replacement. J Am Coll Cardiol 2013;62(1): 11–20.
127. Sugimoto T, Okada M, Ozaki N, et al. Long-term evaluation of treatment for functional tricuspid regurgitation with regurgitant volume: characteristic differences based on primary cardiac lesion. J Thorac Cardiovasc Surg 1999; 117(3):463–71.
128. Suri RM, Vanoverschelde JL, Grigioni F, Schaff HV, Tribouilloy C, Avierinos JF, et al. Association between early surgical intervention vs watchful waiting and outcomes for mitral regurgitation due to flail mitral valve leaflets. JAMA 2013;310(6):609–16.
129. Thourani VH, Weintraub WS, Guyton RA, Jones EL, Williams WH, Elkabbani S, et al. Outcomes and long-term survival for patients undergoing mitral valve repair versus replacement: effect of age and concomitant coronary artery bypass grafting. Circulation 2003;108(3):298–304.
130. Topilsky Y, Khanna AD, Oh JK, et al. Preoperative factors associated with adverse outcome after tricuspid valve replacement. Circulation 2011;123(18):1929–39.
131. Topilsky Y, Tribouilloy C, Michelena HI, Pislaru S, Mahoney DW, Enriquez-Sarano M. Pathophysiology of tricuspid regurgitation: quantitative Doppler echocardiographic assessment of respiratory dependence.Circulation. 2010; 122(15):1505–13.
132. Towler DA. Molecular and cellular aspects of calcific aortic valve disease. Circ Res 2013;113(2):198–208.

133. Tribouilloy C, Grigioni F, Avierinos JF, Barbieri A, Rusinaru D, Szymanski C, et al. Survival implication of left ventricular end-systolic diameter in mitral regurgitation due to flail leaflets a long-term follow-up multicenter study. J Am Coll Cardiol 2009;54(21):1961–8.
134. Vahanian A, Alfieri O, Andreotti F, Antunes MJ, Barón-Esquivias G, Baumgartner H, et al. Guidelines on the management of valvular heart disease (version 2012): The Joint Task Force on the Management of Valvular Heart Disease of the European Society of Cardiology (ESC) and the European Association for Cardio-Thoracic Surgery (EACTS). Eur Heart J 2012;33(19):2451–96.
135. Vahanian A, Alfieri O, Andreotti F, Antunes MJ, Barón-Esquivias G, Baumgartner H, et al. Guidelines on the management of valvular heart disease (version 2012). Eur Heart J 2012;33(19):2451–96.
136. Vahanian A, Alfieri O, Andreotti F, Antunes MJ, Barón-Esquivias G, Baumgartner H, et al. Guidelines on the management of valvular heart disease (version 2012): The Joint Task Force on the Management of Valvular Heart Disease of the European Society of Cardiology (ESC) and the European Association for Cardio-Thoracic Surgery (EACTS). Eur Heart J 2012;33(19):2451–96.
137. Vahanian A, Alfieri O, Andreotti F, Antunes MJ, Barón-Esquivias G, Baumgartner H, et al. Guidelines on the management of valvular heart disease (version 2012): The Joint Task Force on the Management of Valvular Heart Disease of the European Society of Cardiology (ESC) and the European Association for Cardio-Thoracic Surgery (EACTS). Eur Heart J 2012;33(19):2451–96.
138. Vahanian A, Alfieri O, Andreotti F, et al. Guide-lines on the management of valvular heart disease (version 2012): The Joint Task Force on the Management of Valvular Heart Disease of the European Society of Cardiology (ESC) and the European Association for Cardio-Thoracic Surgery (EACTS).Eur Heart J 2012;33(19):2451–96.
139. Vahanian A, Baumgartner H, Bax J, et al. Guidelines on the management of valvular heart disease: The Task Force on the Management of Valvular Heart Disease of the European Society of Cardiology. Eur Heart J 2007;28(2): 230–68.
140. Vlahos AP, Feinstein JA, Schiller NB, Silverman NH. Extension of Doppler-derived Echocardiographic Measures of Pulmonary Vascular Resistance to Patients with Moderate or Severe Pulmonary Vascular Disease. J Am Soc Echocardiogr 2008.
141. Waller BF. Morphological aspects of valvular heart disease: Part I. Curr Probl Cardiol 1984;9(7):1–66.
142. Waller BF. Morphological aspects of valvular heart disease: Part II. Curr Probl Cardiol 1984;9(8):1–74.
143. Wann LS, Curtis AB, Ellenbogen KA, et al. 2011 ACCF/AHA/HRS focused update on the management of patients with atrial fibrillation (update on dabigatran): a report of the American College of Cardiology Foundation/American Heart Association Task Force on practice guidelines. J Am Coll Cardiol 2011;57(11):1330–7.
144. Warnes CA, Williams RG, Bashore TM, Child JS, Connolly HM, Dearani JA, et al. ACC/AHA 2008 Guide-lines for the Management of Adults with Congenital Heart Disease: a report of the American College of Cardiology/American Heart Association Task Force on Practice Guidelines (writing committee to develop guidelines on the management of adults with congenital heart disease). Circulation 2008; 118(23):e714–833.
145. Wilson W, Taubert KA, Gewitz M, Lockhart PB, Baddour LM, Levison M, et al. Prevention of infective endocarditis: guidelines from the American Heart Asso-ciation: a guideline from the American Heart Association Rheu-matic Fever, Endocarditis, and Kawasaki Disease Com-mittee, Council on Cardiovascular Disease in the Young, and the Council on Clinical Cardiology, Council on Cardio-vascular Surgery and Anesthesia, and the Quality of Care and Outcomes Research Interdisciplinary Working Group. Circulation 2007;116(15):1736–54.
146. Wunderlich NC, Beigel R, Siegel RJ. Management of mitral stenosis using 2D and 3D echo-Doppler imaging. JACC Cardiovasc Imaging 2013;6(11):1191–205.
147. Yang WI, Shim CY, Kang MK, et al. Vena contracta width as a predictor of adverse outcomes in patients with severe isolated tricuspid regurgitation. J Am Soc Echocardiogr 2011; 24(9):1013–9.
148. Yeow WL, Roberts-Thomson P, Shetty S, Yong G. Expanding Role for Transcatheter Aortic Valve Replacement: Successful Transfemoral Implantation of a Medtronic CoreValve for Severe Aortic Regurgitation. Heart Lung Circ 2012;21(11): 754–8.

17 Deep Vein Thrombosis and Pulmonary Embolism

Pulmonary embolism (PE) is a blockage of the main artery of the lung or one of its branches by a substance that has travelled from elsewhere in the body through the bloodstream (embolism). PE most commonly results from deep vein thrombosis (a blood clot in the deep veins of the legs or pelvis) that breaks off and migrates to the lung, a process termed venous thromboembolism (VTE). A small proportion of cases are caused by the embolization of air, fat, or talc in drugs of intravenous drug abusers or amniotic fluid. The obstruction of the blood flow through the lungs and the resultant pressure on the right ventricle of the heart lead to the symptoms and signs of PE. The risk of PE is increased in various situations, such as cancer or prolonged bed rest (Fig. 17.1).

A pulmonary embolus is one of the life-threatening causes of chest pain and should always be considered when a patient presents to a healthcare provider with complaints of chest pain and shortness of breath. There are special types of pulmonary embolus that are not due to blood clots, but instead are due to other body materials. These are rare occurrences and include:

1. Fat emboli from a broken femur,
2. An amniotic fluid embolus in pregnancy, and
3. In some cases, tumor tissue from cancer.

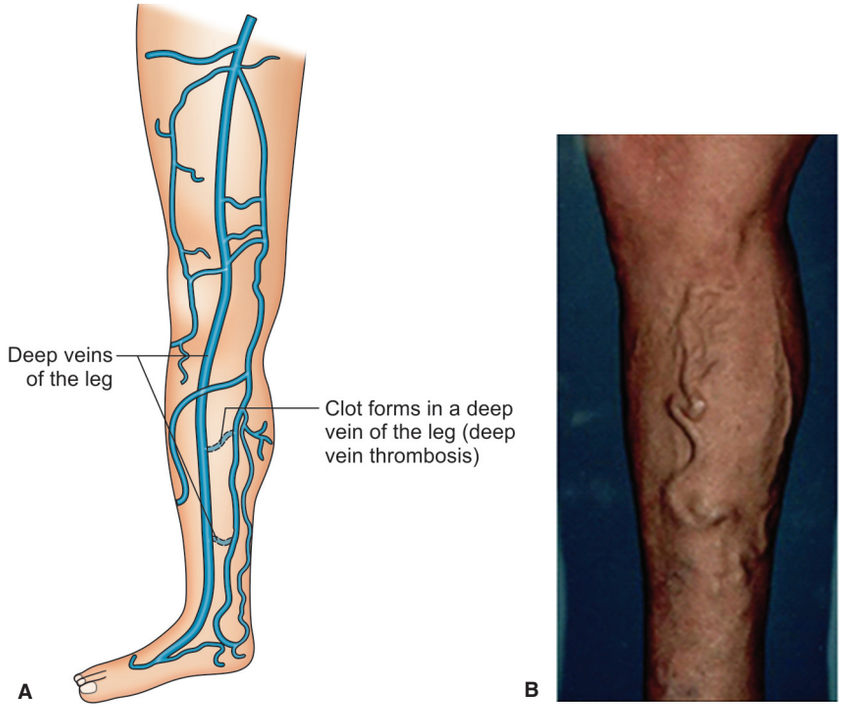

Fig. 17.1: (A) Anatomy of vein thrombosis. (B) Thrombosis of the varicose veins

The signs and symptoms are the same as that of a blood clot, and is caused by blockage of part of the arterial tree of the lung, and prevents the bloods ability to reach all parts of the lung tissue. Pulmonary embolus is the end result of a deep vein thrombosis or blood clot elsewhere in the body. Most commonly, the DVT begins in the leg, but they also can occur in veins within the abdominal cavity or in the arms. Symptoms of pulmonary embolism include difficulty breathing, chest pain on inspiration, and palpitations. Clinical signs include low blood oxygen saturation and cyanosis, rapid breathing, and a rapid heart rate. Severe cases of PE can lead to collapse, abnormally low blood pressure, and sudden death. Diagnosis is based on these clinical findings in combination with laboratory tests (such as the D-dimer test) and imaging studies, usually CT pulmonary angiography. Treatment is typically with anticoagulant medication, including heparin and warfarin. Severe cases may require thrombolysis ("clot busting") with drugs such as tissue plasminogen activator (tPA) or may require surgical intervention via pulmonary thrombectomy.

EPIDEMIOLOGY

Pulmonary embolism occur in more than 0.6 million people in the United States each year. It results in between 50,000 and 200,000 deaths per year in the United States. The risk in those who are hospitalized is around 1%. The rate of fatal pulmonary emboli has declined from 6–2% over the last 25 years in the United States.

MEDICAL HISTORY

The challenge in dealing with pulmonary embolism is that patients rarely display the classic presentation of this problem, that is, the abrupt onset of pleuritic chest pain, shortness of breath, and hypoxia. Studies of patients who died unexpectedly from pulmonary embolism have revealed that often these individuals complained of nagging symptoms for weeks before death. Forty percent of these patients had been seen by a physician in the weeks prior to their death (Fig. 17.2).



Fig. 17.2: A patient with deep vein thrombosis in the right arm developed in ICU

The following risk factors can be indications for the presence of pulmonary embolism:

- Venous stasis
- Hypercoagulable states
- Immobilization
- Surgery and trauma
- Pregnancy
- Oral contraceptives and estrogen replacement
- Malignancy
- Hereditary factors resulting in a hypercoagulable state
- Acute medical illness
- Drug abuse [intravenous (IV) drugs]
- Drug-induced lupus anticoagulant
- Hemolytic anemias
- Heparin-associated thrombocytopenia
- Homocystinemia
- Homocystinuria
- Hyperlipidemias
- Phenothiazines
- Thrombocytosis
- Varicose veins
- Venography
- Venous pacemakers
- Venous stasis
- Warfarin (first few days of therapy)
- Inflammatory bowel disease

The PIOPED II study listed the following indicators for pulmonary embolism:

1. Travel of 4 hours or more in the past month
2. Surgery within the last 3 months
3. Malignancy, especially lung cancer
4. Current or past history of thrombophlebitis
5. Trauma to the lower extremities and pelvis during the past 3 months
6. Smoking
7. Central venous instrumentation within the past 3 months
8. Stroke, paresis, or paralysis
9. Prior pulmonary embolism
10. Heart failure
11. Chronic obstructive pulmonary disease

PATHOPHYSIOLOGY

Pulmonary emboli most often arise from the deep veins of the lower extremity and pelvis. Thrombi dislodge from these veins and embolize to the pulmonary arteries, where they cause abnormalities in hemodynamics and gas exchange (Fig. 17.3).

The hemodynamic response to PE is determined by the size of the embolus, the patient's underlying cardiopulmonary status, and compensatory neurohumoral adaptations. In addition to physical obstruction, acute PE leads to the release of pulmonary artery vasoconstrictors and hypoxemia, with a subsequent increase in pulmonary vascular resistance and right ventricular (RV) afterload. The

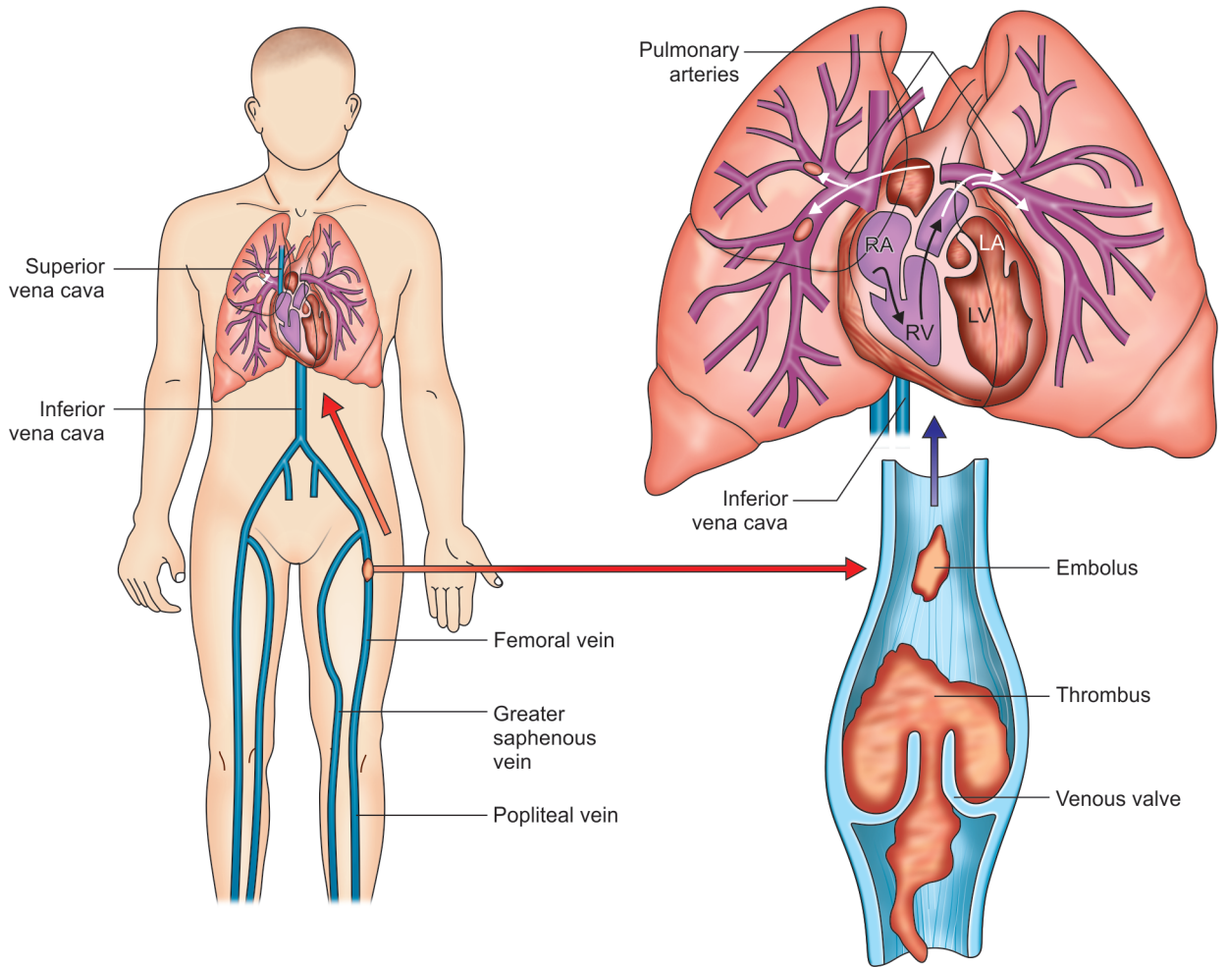

Fig. 17.3: The pathophysiology of pulmonary embolism. Although pulmonary embolism can arise from anywhere in the body, most commonly it arises from the calf veins. The venous thrombi predominately originate in venous valve pockets (inset) and at other sites of presumed venous stasis. To reach the lungs, thromboemboli travel through the right side of the heart. RA=right atrium; RV=right ventricle; LA=left atrium; LV=left ventricle

abrupt increase in RV afterload can cause RV dilatation and hypokinesis, tricuspid regurgitation, and ultimately RV failure. Patients with RV failure may rapidly progress to systemic arterial hypotension and cardiac arrest. RV pressure overload can also lead to interventricular septal flattening and deviation toward the left ventricle (LV) in diastole, thereby impairing LV filling. This manifestation of interventricular dependence also leads to an alteration of normal transmitral flow with left atrial contraction, represented by the A wave on Doppler echocardiography, making a greater contribution to LV diastole than passive filling, represented by the E wave. RV pressure overload also increases wall stress and leads to ischemia by increasing myocardial oxygen demand while limiting supply. Mechanisms leading to impaired gas exchange include ventilation-to-perfusion mismatch, increases in total dead space, and right-to-left shunting. Arterial hypoxemia and an increased alveolar-arterial oxygen gradient are the two most common abnormalities of gas exchange. Hyperventilation may contribute to hypocapnia and respiratory alkalosis. The presence of hypercapnia suggests massive PE leading to increased anatomic and physiological dead space and impaired minute ventilation.

SIGNS AND SYMPTOMS

Symptoms of PE are typically sudden in onset and include dyspnea (shortness of breath), tachypnea (rapid breathing), chest pain of a "pleuritic" nature (worsened by breathing), cough and hemoptysis (coughing up blood). More severe cases can include signs such as cyanosis (blue discoloration, usually of the lips and fingers), collapse, and circulatory instability because of decreased blood flow through the lungs and into the left side of the heart. About 15% of all cases of sudden death are attributable to PE.

On physical examination, the lungs are usually normal. Occasionally, a pleural friction rub may be audible over the affected area of the lung (mostly in PE with infarct). A pleural effusion is sometimes present that is exudative, detectable by decreased percussion note, audible breath sounds and vocal resonance. Strain on the right ventricle may be detected as a left parasternal heave, a loud pulmonary component of the second heart sound, and raised

jugular venous pressure. A low-grade fever may be present, particularly if there is associated pulmonary hemorrhage or infarction.

More rarely, inability of the right ventricle to remove fluid from the tissues leads to fluid accumulation in the legs (peripheral edema), congestion of the liver with mild jaundice and tenderness, and ascites (fluid in the abdominal cavity).

PHYSICAL EXAMINATION

Physical examination findings (Fig. 17.4 and Tables 17.1–17.3) are quite variable in pulmonary embolism and, for convenience, may be grouped into four categories as follows:

- Massive pulmonary embolism
- Acute pulmonary infarction
- Acute embolism without infarction
- Multiple pulmonary emboli or thrombi



Fig. 17.4: (A) Deep vein thrombosis in the left leg, (B) Skin ulceration in the lateral malleolus from postthrombotic syndrome of the leg

The presentation of pulmonary embolism may vary from sudden catastrophic hemodynamic collapse to gradually progressive dyspnea (prior poor cardiopulmonary status of the patient is an important factor leading to hemodynamic collapse.) Most patients with pulmonary embolism have no obvious symptoms at presentation. In contrast, patients with symptomatic DVT commonly have pulmonary embolism confirmed on diagnostic studies in the absence of pulmonary symptoms. Sickle cell disease often creates a diagnostic difficulty with regard to pulmonary embolism. A chest infection is often the presenting symptom.

Patients with pulmonary embolism may present with atypical symptoms. In such cases, strong suspicion of pulmonary embolism based on the presence of risk factors can lead to consideration of pulmonary embolism in the differential diagnosis. These symptoms include the following:

- Seizures
- Syncope
- Abdominal pain
- Fever
- Productive cough
- Wheezing
- Decreasing level of consciousness
- New onset of atrial fibrillation
- Flank pain
- Delirium (in elderly patients)

The diagnosis of pulmonary embolism should be sought actively in patients with respiratory symptoms unexplained by an alternative diagnosis. The symptoms of pulmonary embolism are nonspecific therefore, a high index of suspicion is required, particularly when a patient has risk factors for the condition.

Acute respiratory consequences of pulmonary embolism include the following:

1. Increased alveolar dead space
2. Hypoxemia
3. Hyperventilation

Table 17.1: Clinical feautres/Risk factors in DVT

	Score
• Active cancer within 6 months (ongoing treatment or palliative)	1
• Immobilization by paralysis or plaster dressings	1
• Recent surgery (within 4 weeks) or bed rest longer than 3 days	1
• Localized tenderness along distribution of the deep venous system	1
• Calf swelling (>3 cm increase in calf circumference compared to asymptomatic leg) measured 10 cm below tibial tuberosity	1
• Thigh and calf swelling (entire swollen leg)	1
• Pitting edema confined to symptomatic leg	1
• Collateral superficial veins (nonvaricosed)	1
• Alternative diagnosis as likely or greater than that of DVT	–2

Pretest probability calculated as the total score—low 0; moderate 1 or 2; high 3. In the newer scoring system proposed by Wells et al. the probability of having a DVT is likely if a score of two or higher is obtained; a score of less than two indicates that the probability of acute DVT is unlikely. The more symptomatic leg is used if patients have symptoms in both legs.

Table 17.2: Quick Assessment of Deep vein thrombosis

Physical: Massive pulmonary embolism (PE) causes hypotension due to acute cor pulmonale, but the physical examination findings early in submassive PE may be completely normal.

- After 24–72 hours, loss of pulmonary surfactant often causes atelectasis and alveolar infiltrates that are indistinguishable from pneumonia on clinical examination and by radiography.
- New wheezing may be appreciated. If pleural lung surfaces are affected, a pulmonary rub may be heard.
- In patients with recognized PE, the incidence of physical signs has been reported as follows:
  - 96% have tachypnea (respiratory rate >16/min)
  - 53% have an accentuated second heart sound
  - 43% have fever (temperature >37.8°C)
  - 34% have an S3 or S4 gallop
  - 24% have lower extremity edema
  - 23% have a cardiac murmur
  - 58% develop rales
  - 44% have tachycardia (heart rate >100/min)
  - 36% have diaphoresis
  - 32% have clinical signs and symptoms suggesting thrombophlebitis
  - 19% have cyanosis

Causes: As stated in the pathophysiology section, the aetiology of venous thrombosis and subsequent thromboembolism results from a distortion in Virchow's triad by venostasis, hypercoagulability, or vessel wall inflammation. These risk factors for venous thrombosis and pulmonary embolism can be broken down into hereditary factors and acquired factors.

- Hereditary factors (most result in a hypercoagulable state)
  - Antithrombin III deficiency
  - Protein S deficiency
  - Plasminogen abnormality
  - Plasminogen activator abnormality
  - Resistance to activated protein C
  - Protein C deficiency
  - Factor V Leiden (most common genetic risk factor for thrombophilia)
  - Fibrinogen abnormality
- Acquired factors (the most important clinically identifiable risk factors for DVT and PE are a prior history of DVT or PE, recent surgery or pregnancy, prolonged immobilization, or underlying malignancy.)
  - Reduced mobility
    - Fractures
    - Immobilization
    - Burns
    - Obesity
  - Acute medical illness
    - AIDS (lupus anticoagulant)
    - Behçet disease
    - Congestive heart failure (CHF)
    - Myocardial infarction
    - Polycythemia
    - Systemic lupus erythematosus
    - Ulcerative colitis
  - Hemolytic anemias
  - Homocysteinemia
  - Hyperlipidemias
  - Thrombocytosis
  - Venography
  - Venous stasis
  - Old age
  - Malignancy
    - Chemotherapy
  - Trauma/major surgery
    - Spinal cord injury
    - Catheters (indwelling venous infusion catheters)
    - Postoperative
  - Pregnancy
    - Postpartum period
    - Oral contraceptives
    - Estrogen replacements (high dose only)
  - Drug abuse [intravenous (IV) drugs]
  - Drug-induced lupus anticoagulant
  - Heparin-associated thrombocytopenia
  - Homocystinuria
  - Phenothiazines
  - Varicose veins
  - Venous pacemakers
  - Warfarin (first few days of therapy)

In patients with recognized pulmonary embolism, the incidence of physical signs has been reported as follows:

- Tachypnea (respiratory rate >16/min)—96%
- Rales—58%
- Accentuated second heart sound—53%
- Tachycardia (heart rate >100/min)—44%
- Fever (temperature >37.8°C)—43%
- Diaphoresis—36%
- S3 or S4 gallop—34%
- Clinical signs and symptoms suggesting thrombophlebitis—32%
- Lower extremity edema—24%
- Cardiac murmur—23%
- Cyanosis—19%
- The PIOPED study reported the following incidence of common symptoms of pulmonary embolism:
- Dyspnea (73%)
- Pleuritic chest pain (66%)
- Cough (37%)
- Hemoptysis (13%)
- Fever of less than 39°C may be present in 14% of patients; however, temperature higher than 39.5°C is not from pulmonary embolism.
- Chest wall tenderness upon palpation, without a history of trauma, may be the sole physical finding in rare cases.

Table 17.3: Wells clinical score for DVT

Clinical parameter score	Score
Active cancer (treatement ongoing, or within 6 months or palliative	+1
Paralysis or recent plaster immobile	+1
Recently bedridden for >3 days or major surgery 4 weeks	+1
Localized tenderness along the distribution of the deep venous system	+1
Entire leg swelling	+1
Calf swelling >3 cm compared with the asymptomatic leg	+1
Pitting edema (greater in the symptomatic leg)	+1
Previous DVT documented	+1
Collateral superficial veins (non varicose)	+1
Alternative diagnosis (as likely or greater than that of DVT)	–2
Total of above score	
High probability	≥3
Moderate probability	1 or 2
Low probability	? 0
Clinical parameter score	
Active cancer (treatment ongoing, or within 6 months or paliative)	+1
Paralysis or recent plaster immobilization of the lower extremities	+1
Recently bedridden for >3 days or major surgery 4 weeks	+1
Localized tenderness along the distribution of the deep venous system	+1
Entire leg swelling	+1
Calf swelling >3 cm compared with the asymptomatic leg	+1
Pitting edema (greater in the symptomatic leg)	+1
Previous DVT documented	+1
Collateral superfacial venis (nonvaricose)	+1
Alternative diagnosis (as likely or greater than that of DVT)	–2
Total of above score	
High probability	≥3
Moderate probability	1 or 2
Low probability	? 0

- **Pleuritic chest** pain without other symptoms or risk factors may be a presentation of pulmonary embolism. Pleuritic or respirophasic chest pain is a particularly worrisome symptom. Pleuritic chest pain is reported to occur in as many as 84% of patients with pulmonary emboli. Its presence suggests that the embolus is located more peripherally and thus may be smaller. Pulmonary embolism has been diagnosed in 21% of young, active patients who come to emergency departments (EDs) complaining only of pleuritic chest pain. These patients usually lack any other classical signs, symptoms, or known risk factors for pulmonary thromboembolism. Such patients often are dismissed inappropriately with an inadequate workup and a nonspecific diagnosis, such as musculoskeletal chest pain or pleurisy.

Massive Pulmonary Embolism

Patients with massive pulmonary embolism are in shock. They have systemic hypotension, poor perfusion of the extremities, tachycardia, and tachypnea. In addition, patients appear weak, pale, sweaty, and oliguric and develop impaired mentation. Signs of pulmonary hypertension, such as palpable impulse over the second left intercostal space, loud P2, right ventricular S3 gallop, and a systolic murmur louder on inspiration at left sternal border (tricuspid regurgitation), may be present.

Massive pulmonary embolism has been defined by hemodynamic parameters and evidence of myocardial injury rather than anatomic findings because the former is associated with adverse outcomes. Although previous studies of CT scans in the diagnosis of pulmonary embolus suggested that central obstruction was not associated with adverse outcomes, a new multicenter study clarifies this observation. Vedovati et al. found no association between central obstruction and death or clinical deterioration in 579 patients with pulmonary embolus. However, when a subset of 516 patients who were hemodynamically stable was assessed, central localization of emboli was found to be an independent mortality risk factor while distal localization was inversely associated with adverse events. Thus, anatomic findings by CT scan may be important in assessing risk in hemodynamically stable patients with pulmonary embolus.

Acute Pulmonary Infarction

Approximately 10% of patients have peripheral occlusion of a pulmonary artery, causing parenchymal infarction. These patients present with acute onset of pleuritic chest pain, breathlessness, and hemoptysis. Although the chest pain may be clinically indistinguishable from ischemic myocardial pain, normal ECG findings and no response to nitroglycerin rules out myocardial pain. Patients with acute pulmonary infarction have decreased excursion of the involved hemithorax, palpable or audible pleural friction rub, and even localized tenderness. Signs of pleural effusion, such as dullness to percussion and diminished breath sounds, may be present.

Acute Embolism without Infarction

Patients with acute embolism without infarction have nonspecific physical signs that may easily be secondary to another disease process. Tachypnea and tachycardia frequently are detected, pleuritic pain sometimes may be present, crackles may be heard in the area of embolization, and local wheeze may be heard rarely.

Multiple Pulmonary Emboli or Thrombi

Patients with pulmonary emboli and thrombi have physical signs of pulmonary hypertension and cor pulmonale. Patients may have elevated jugular venous pressure, right ventricular heave, palpable impulse in the left second intercostal space, right ventricular S3 gallop, systolic murmur over the left sternal border that is louder during inspiration, hepatomegaly, ascites, and dependent pitting edema. These findings are not specific for pulmonary embolism and require a high index of suspicion for pursuing appropriate diagnostic studies.

Pulmonary Emboli in Children

Many physical findings are typically less marked in children than they are in adults, presumably because children have greater hemodynamic reserve and, thus, are better able to tolerate the significant hemodynamic and pulmonary changes. Because of the rarity of pulmonary emboli in children, these patients are probably underdiagnosed. For the same reason, much of the information pertaining to diagnosis and management of pulmonary embolism has been derived from adult practice.

1. Cough is present in approximately 50% of children with pulmonary emboli.
2. Tachypnea occurs with the same frequency. Hemoptysis is a feature in a minority of children with pulmonary emboli, occurring in about 30% of cases.
3. Crackles are heard in a minority of cases.
4. Cyanosis and hypoxemia are not prominent features of pulmonary embolism. If present, cyanosis suggests a massive embolism leading to a marked ventilation-perfusion (V/Q) mismatch and systemic hypoxemia. Some case reports have described massive pediatric pulmonary embolism with normal saturation.
5. A pleural rub is often associated with pleuritic chest pain and indicates an embolism in a peripheral location in the pulmonary vasculature. Signs that indicate pulmonary hypertension and right ventricular failure include a loud pulmonary component of the second heart sound, right ventricular lift, distended neck veins, and hypotension. An increase in pulmonary artery pressure is reportedly not evident until at least 60% of the vascular bed has been occluded.
6. A gallop rhythm signifies ventricular failure, while peripheral edema is a sign of congestive heart failure. Various heart murmurs may be audible, including a tricuspid regurgitant murmur signifying pulmonary hypertension.
7. Fever is an unusual sign that is nonspecific, and diaphoresis is a manifestation of sympathetic arousal. Signs of other organ involvement in patients with sickle cell disease would be elicited, such as sequestration crisis, priapism, anemia, and stroke.

Blood Testing

Clinical Scoring Systems

Evidence-based literature supports the practice of determining the clinical probability of pulmonary embolism before proceeding with testing. A clinical practice guideline from the American Academy of Family Physicians (AAFP) and the American College of Physicians (ACP) recommends that validated clinical prediction rules be used to estimate pretest probability of pulmonary embolism and to interpret test results. The guideline, current diagnosis of venous thromboembolism in primary care, advocates use of the Wells prediction rule for this purpose but notes that the Wells rule performs better in younger patients without comorbidities or a history of venous thromboembolism than in other patients.

One study assessed the performance of four clinical decision rules in addition to D-dimer testing to exclude acute PE. All four rules, Wells rule, simplified Wells rule, revised Geneva score, and simplified revised Geneva score, showed similar performance for excluding acute PE when combined with a normal D-dimer result.

D-Dimer Follow-Up on Low-to-Moderate Pretest Probability

When clinical prediction rule results indicate that the patient has a low or moderate pretest probability of pulmonary embolism, D-dimer testing is the usual next step.

D-Dimer, a degradation product produced by plasmin-mediated proteases of cross-linked fibrin, is measured by a variety of assay types, including quantitative, semiquantitative, and qualitative rapid enzyme-linked immunosorbent assays (ELISAs); quantitative and semiquantitative latex; and whole-blood assays. A systematic review of prospective studies of high methodologic quality concluded that the ELISAs—especially the quantitative rapid ELISA—dominate the comparative ranking among the D-dimer assays for sensitivity and negative likelihood ratio. The

quantitative rapid ELISA has a sensitivity of 0.95 and negative likelihood ratio of 0.13; the latter is similar to that for a normal to near-normal lung scan in patients with suspected pulmonary embolism. Negative results on a high-sensitivity D-dimer test in a patient with a low pretest probability of pulmonary embolism indicate a low likelihood of venous thromboembolism and reliably exclude pulmonary embolism. A large, prospective, randomized trial found that in patients with a low probability of pulmonary embolism who had negative D-dimer results, forgoing additional diagnostic testing was not associated with an increased frequency of symptomatic venous thromboembolism during the subsequent 6 months. D-dimer testing is most reliable for excluding pulmonary embolism in younger patients who have no associated comorbidity or history of venous thromboembolism and whose symptoms are of short duration. However, it is of questionable value in patients who are older than 80 years, who are hospitalized, who have cancer, or who are pregnant, because nonspecific elevation of D-dimer concentrations is common in such patients.

D-dimer testing should not be used when the clinical probability of pulmonary embolism is high, because the test has low negative predictive value in such cases. Combining D-dimer results with measurement of the exhaled end-tidal ratio of carbon dioxide to oxygen ($etCO_2/O_2$) can be useful for diagnosis of pulmonary embolism. Kline et al found that, in moderate-risk patients with a positive D-dimer (>499 ng/ml), an $etCO_2/O_2$ <0.28 significantly increased the probability of finding segmental or larger pulmonary embolism on computed tomography multidetector-row pulmonary angiography, while an $etCO_2/O_2$) >0.45 predicted the absence of segmental or larger pulmonary embolism. Because of the poor specificity, positive D-dimer measurements are generally not helpful in diagnosis. In addition, the use of D-dimers in children is not well studied. A small pediatric series reported that D-dimers findings are negative in 40% of patients.A retrospective series reported an elevated D-dimer in 86% of patients at presentation.

Ischemia-modified Albumin Levels

A potential alternative to D-dimer testing is assessment of the ischemia-modified albumin (IMA) level, which data suggest is 93% sensitive and 75% specific for pulmonary embolism. Notably, in a study comparing the prognostic value of IMA to D-dimer testing, IMA assessment in combination with Wells and Geneva probability scores appeared to positively impact overall sensitivity and negative predictive value. The positive predictive value of IMA, in particular, is better than D-dimer. However, it should not be used alone.

White Blood Cell Count

The white blood cell (WBC) count may be normal or elevated in patients with pulmonary embolism, with a WBC count as high as 20,000 being not uncommon in patients with this condition.

Arterial Blood Gases

Arterial blood gas determinations characteristically reveal hypoxemia, hypocapnia, and respiratory alkalosis; however, the predictive value of hypoxemia is quite low. The PaO_2 and the calculation of alveolar-arterial oxygen gradient contribute to the diagnosis in a general population thought to have pulmonary embolism. Nonetheless, in high-risk settings such as patients in postoperative states in whom other respiratory conditions can be ruled out, a low PaO_2 in conjunction with dyspnea may have a strong positive predictive value.

The PO_2 on arterial blood gases analysis (ABG) has a zero or even negative predictive value in a typical population of patients in whom pulmonary embolism is suspected clinically. This is contrary to what has been taught in many textbooks, and even though it seems counterintuitive, it is demonstrably true. This is because other etiologies that masquerade as pulmonary embolism are more likely to lower the PO_2 than pulmonary embolism. In fact, because other diseases that may masquerade as pulmonary embolism [e.g. chronic obstructive pulmonary disease (COPD), pneumonia, CHF] affect oxygen exchange more than does pulmonary embolism, the blood oxygen level often has an inverse predictive value for pulmonary embolism.

In most settings, fewer than half of all patients with symptoms suggestive of pulmonary embolism actually turn out to have pulmonary embolism as their diagnosis. In such a population, if any reasonable level of PaO_2 is chosen as a dividing line, the incidence of pulmonary embolism will be higher in the group with a PaO_2 above the dividing line than in the group whose PaO_2 is below the divider. This is a specific example of a general truth that may be demonstrated mathematically for any test finding with a Gaussian distribution and a population incidence of less than 50%. Conversely, in a patient population with a very high incidence of pulmonary embolismand a lower incidence of other respiratory ailments (e.g. postoperative orthopedic patients with sudden onset of shortness of breath), a low PO_2 has a strongly positive predictive value for pulmonary embolism.

The discussion above holds true not only for arterial PO_2 but also for the alveolar-arterial oxygen gradient and for the oxygen saturation level as measured by pulse oximetry. In particular, pulse oximetry is extremely insensitive, is normal in the majority of patients with pulmonary embolism, and should not be used to direct a diagnostic workup.

Troponin Levels

Serum troponin levels can be elevated in up to 50% of patients with a moderate to large pulmonary embolism, presumptively due to acute right ventricular myocardial stretch.

Although troponin assessment is not currently recommended as part of the diagnostic workup, studies have shown that elevated troponin levels in the setting of pulmonary embolism correlate with increased mortality.

However, further studies need to be performed to identify subsets of patients with pulmonary embolism who might benefit from this testing. Serum troponin, although seemingly marginal for purposes of diagnosis of pulmonary embolism, may contribute significantly to the ability to stratify patients by risk for short-term death or adverse outcome events when they reach the ED. In patients with pulmonary embolism and normal blood pressure specifically, elevated serum troponin level has been associated with right ventricular overload.

Leptin: It is another cardiovascular risk factor that may be associated with outcome in acute pulmonary embolism. Dellas et al conducted a prospective analysis of 264 patients with acute pulmonary embolus and found that serum leptin levels were inversely associated with the risk of adverse outcomes. Further study will be needed to confirm these findings and determine the clinical utility of leptin measurement.

Brain Natriuretic Peptide

Although brain natriuretic peptide (BNP) tests are neither sensitive nor specific, patients with pulmonary embolism tend to have higher BNP levels. BNP testing had a sensitivity and specificity of only 60% and 62%, respectively, in a case-control study of 2213 hemodynamically stable patients with suspected acute pulmonary embolism. Elevated levels of BNP or of its precursor, N-terminal pro-brain natriuretic peptide (NT-proBNP), do correlate with an increased risk of subsequent complications and mortality in patients with acute pulmonary embolism. One meta-analysis revealed that patients with a BNP level greater than 100 pg/ml or an NT-proBNP level greater than 600 ng/L had an all-cause in-hospital mortality rate 6- and 16-fold higher than those below these cutoffs, respectively. In a second smaller observational study, serum BNP levels greater than 90 pg/ml were associated with a higher rate of complications, such as the need for cardiopulmonary resuscitation, need for mechanical ventilation, need for vasopressor therapy, and death.

BNP testing is not currently recommended as part of the standard evaluation of acute pulmonary embolism, and future studies may aid in defining its role in this setting.

Elevated levels of brain-type natriuretic peptides (BNP) may also provide prognostic information. A meta-analysis demonstrated a significant association between elevated N-terminal-pro-BNP (NT-pro-BNP) and right ventricular function in patients with pulmonary embolism (P <.001), leading to an increased risk for complicated in-hospital course [odds ratio (OR) 6.8; 95% confidence interval [CI], 9.0–13] and 30-day mortality (OR 7.6; 95% CI, 3.4–17). Importantly, increased NT-pro-BNP alone does not justify more invasive treatment. A recent study by Scherz et al. analyzed a large sample of patients hospitalized with acute pulmonary embolism.

Hyponatremia at presentation was common and was associated with a higher risk of 30-day mortality and readmission.

INVASIVE LABORATORY STUDIES

Venography

Venography is the criterion standard for diagnosing DVT. With the advent of noninvasive imaging, it has become less common in pediatric and adult practice (Figs 17.5–17.8).



Fig. 17.5: Operator performing dual venous ultrasound examination for deep venous thrombosis and venous insuffiency in a young boy



Fig. 17.6: Lower-extremity venogram shows a nonocclusive chronic thrombus. The superficial femoral vein (lateral vein) has the appearance of 2 parallel veins, when in fact, it is 1 lumen containing a chronic linear thrombus. Although the chronic clot is not obstructive after it recanalizes, it effectively causes the venous valves to adhere in an open position, predisposing the patient to reflux in the involved segment

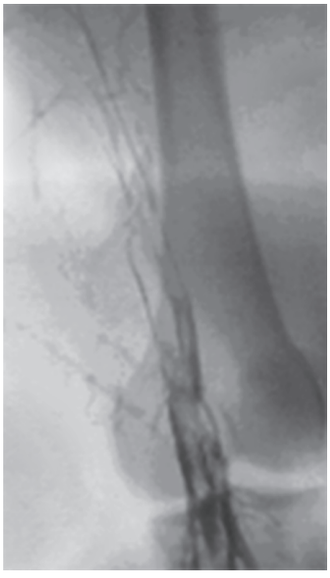

Fig. 17.7: Lower-extremity venogram shows outlining of an acute deep venous thrombosis in the popliteal vein with contrast enhancement



Fig. 17.8: Anteroposterior image from an inferior venacavographic examination demonstrates an inferior vena cava of normal diameter without thrombus. In addition, the inflow from the renal veins can be seen at the level of the L1 vertebral body

NONINVASIVE LABORATORY STUDIES

Chest Radiography

Chest radiographs are abnormal in most cases of pulmonary embolism, but the findings are nonspecific. Common radiographic abnormalities include atelectasis, pleural effusion, parenchymal opacities, and elevation of a hemidiaphragm. The classic radiographic findings of pulmonary infarction include a wedge-shaped, pleura-based triangular opacity with an apex pointing toward the hilus (Hampton hump) or decreased vascularity (Westermark sign). These findings are suggestive of pulmonary embolism but are infrequently observed. A prominent central pulmonary artery (knuckle sign), cardiomegaly (especially on the right side of the heart), and pulmonary edema are other findings. In the appropriate clinical setting, these findings could be consistent with acute cor pulmonale (Fig. 17.9).

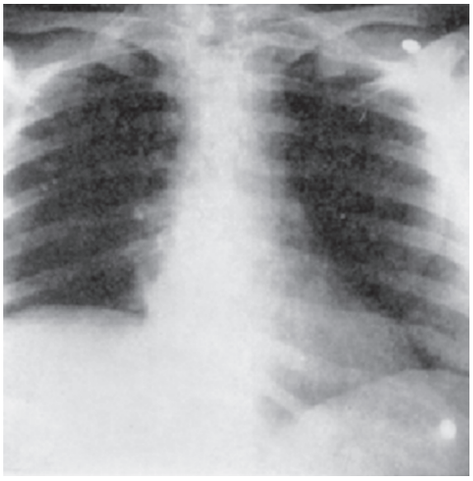

Fig. 17.9: Photograph X-ray chest PA view shows elevation of hemidiaphragm on right side is significant of deep vein thromboembolism

A normal-appearing chest radiograph in a patient with severe dyspnea and hypoxemia, but without evidence of bronchospasm or a cardiac shunt, is strongly suggestive of pulmonary embolism. The ACR recommends chest radiography as the most appropriate study for ruling out other causes of chest pain in patients with suspected pulmonary embolism. Initially, the chest radiographic findings are normal in most cases of pulmonary embolism. However, in later stages, radiographic signs may include a Westermark sign (dilatation of pulmonary vessels and a sharp cutoff), atelectasis, a small pleural effusion, and an elevated diaphragm. Generally, chest radiographs cannot be used to conclusively prove or exclude pulmonary embolism; however, radiography and electrocardiography may be useful for establishing alternative diagnoses.

Electrocardiography

The most common ECG abnormalities in the setting of pulmonary embolism are tachycardia and nonspecific ST-T-wave abnormalities (Figs 17.10 and 17.11). The finding of S1 Q3 T3 is nonspecific and insensitive in the absence of clinical suspicion for pulmonary embolism. The classic findings of right heart strain and acute cor pulmonale are tall, peaked P-waves in lead II (P pulmonale); right axis deviation; right bundle-branch block; an S1 Q3 T3 pattern; or atrial fibrillation.

Unfortunately, only 20% of patients with proven pulmonary embolism have any of these classic electrocardiographic abnormalities. If electrocardiographic abnor-

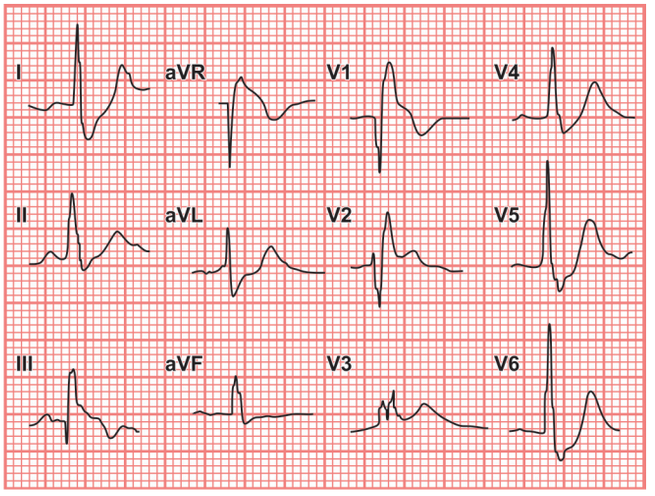

Fig. 17.10: SI, Q3, T3 pattern right bundle branch block (incomplete or complete). T-wave inversion in the right precordial leads P pulmonale. Right axis deviation in a patient with acute pulmonary embolism

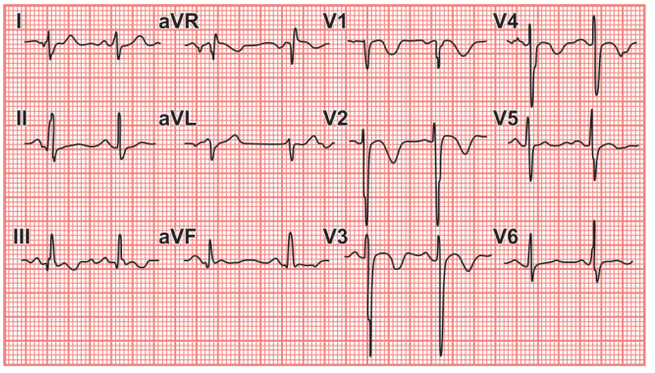

Fig. 17. 11: Acute pulmonary embolism—10 days postoperatively the patient developed acute dyspnea and hypotension (note the T-wave inversion in the right precordial leads and limb lead III)

malities are present, they may be suggestive of pulmonary embolism, but the absence of such abnormalities has no significant predictive value.

Echocardiography

This modality generally has limited accuracy in the diagnosis of pulmonary embolism. Transesophageal echocardiography may identify central pulmonary embolism, and the sensitivity for central pulmonary embolism is reported to be 82%. Overall sensitivity and specificity for central and peripheral pulmonary embolism is 59% and 77%. Echocardiography (ECHO) provides useful information (Figs 17.12–17.14).

It may allow diagnosis of other conditions that may be confused with pulmonary embolism, such as pericardial effusion. ECHO allows visualization of the right ventricle and assessment of the pulmonary artery pressure. ECHO serves a prognostic function; the mortality rate is almost 10% in the presence of right ventricular dysfunction and 0% in the absence of right ventricular dysfunction. (Vanni

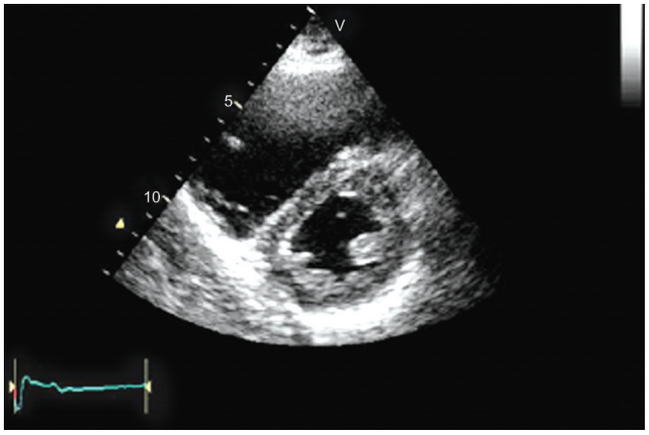

Fig. 17.12: 2D echocardiography parasternal short axis view at the level of papillary muscles—shows right ventricular dilatation, leftward shift of the interventricular septum as seen in pulmonary embolism

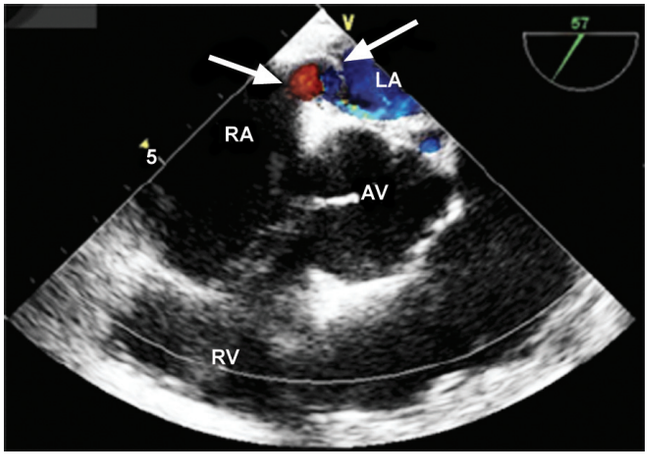

Fig. 17.13: A transesophageal echo was done intraoperatively which revealed normal left ventricle with mildly depressed systolic function, with an estimated ejection fraction of 50%. There was flattening of the interventricular septum consistent with right ventricular pressure overload. The interatrial septum was mobile with a large PFO and a large right to left shunt identified by color-Doppler analysis and agitated saline injection. The right ventricle was severely enlarged and hypokinetic. The right atrium was moderately enlarged. RV systolic pressure is 58 mmHg and the IVC was also dilated. There was mild-to-moderate tricuspid regurgitation with pulmonary hypertension. No other cardiac thrombi were noted

et al. reported that a right ventricular strain pattern is associated with a worse short-term outcome.) ECHO may be used to identify the presence of right-chamber emboli. The subcostal view is preferred at initial screening for mechanical activity and pericardial fluid and for gross assessment of global and regional abnormalities. To obtain a subcostal view, place the transducer on the left subcostal margin with the beam aimed at the left shoulder. The parasternal view allows visualization of the aortic valve, proximal ascending aorta, and posterior pericardium and permits determination of left ventricular size. It is

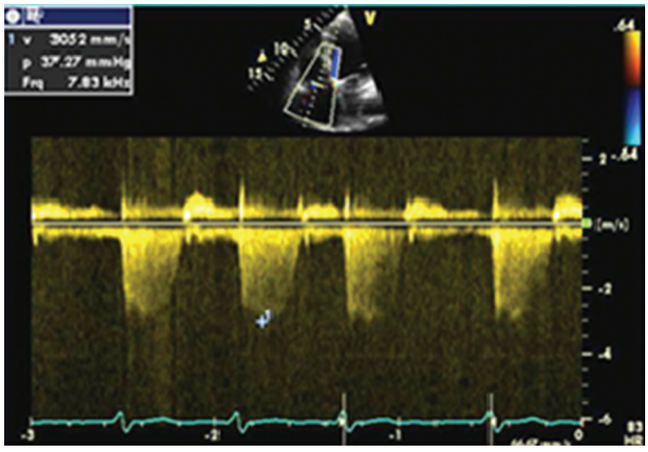

Fig. 17.14: Continuous Doppler echocardiography at the tricuspid valve—Doppler recording indicating tricuspid regurgitation, with an estimated RV-RA gradient of 37 mmHg in a patient with pulmonary embolism

particularly helpful when the subcostal view is difficult to obtain. To obtain a parasternal view, place the transducer in the left parasternal area between the second and fourth intercostal spaces. The plane of the beam is parallel to a line drawn from the right shoulder to the left hip. Several echocardiographic findings have been proposed for noninvasive diagnosis of right ventricular dysfunction at the bedside, including right ventricular enlargement and/or hypokinesis of the free wall, leftward septal shift, and evidence of pulmonary hypertension. If right ventricular dysfunction is seen on cardiac ultrasonography, the diagnosis of acute submassive or massive pulmonary embolism is supported. While the presence of right ventricular dysfunction can be used to support the clinical suspicion of pulmonary embolism, prognostic information can be obtained by assessing the severity of right ventricular dysfunction.

Computed Tomography Scanning

Technical advances in CT scanning, including the development of multidetector-array scanners, have led to the emergence of CT scanning as an important diagnostic technique in suspected pulmonary embolism (Fig. 17.15). Contrast-enhanced CT scanning is increasingly used as the initial radiologic study in the diagnosis of pulmonary embolism, especially in patients with abnormal chest radiographs in whom scintigraphic results are more likely to be nondiagnostic. Computed tomography angiography (CTA) is the initial imaging modality of choice for stable patients with suspected pulmonary embolism. The American College of Radiology (ACR) considers chest CTA to be the current standard of care for the detection of pulmonary embolism. A study by Ward et al. determined that a selective strategy in which CTA is used after compression ultrasonography is cost-effective for patients with a high pretest probability of pulmonary embolism. This strategy may reduce the need for CTA and help eliminate adverse effects associated with CTA.



Fig. 17.15: Coronal maximum intensity projection reconstruction of a computed tomography pulmonary angiogram in a patient with multiple, bilateral pulmonary embolisms (arrows)

Toward a goal of reducing unnecessary CTA and associated radiation exposure, Drescher et al. studied the effect of implementing a computerized decision support system for pulmonary embolism evaluation in the ED. Before implementation, the rate of positive pulmonary embolism diagnosis for CTAs performed was 8.3%; after, the positivity rate rose to 12.7%. The positive yield would have been higher (16.7%) had emergency physicians adhered in all cases to the outcome of the decision support system; in 27% of cases they did not.

Like pulmonary angiography, CT scanning shows emboli directly, but it is noninvasive, cheaper than pulmonary angiography, and widely available. CT scanning is the only test that can provide significant additional information related to alternate diagnoses; spiral (helical) CT scanning results may suggest an alternative diagnosis in up to 57% of patients. This is a clear advantage of CT scanning over pulmonary angiography or scintigraphy.

A study of multidetector computed tomography (MDCTA) for detection of right ventricular dysfunction in 457 patients with acute pulmonary embolism found reasonable correlation with echocardiography, the reference standard. The criterion selected, a right-to-left ventricular dimensional ratio of 0.9 or more at MDCTA, had 92% sensitivity for right ventricular dysfunction. The combination of quantatative assessment of ventricular dimensions by CT and measurement of biomarkers may provide additional diagnostic accuracy for the presence of right ventricular dysfunction.

Magnetic Resonance Imaging

With magnetic resonance imaging (MRI), evidence of pulmonary emboli may be detected by using standard or gated spin-echo techniques (Fig. 17.16). Pulmonary emboli demonstrate increased signal intensity within the pulmonary artery. By obtaining a sequence of images, this signal that is originating from slow blood flow may be distinguished from pulmonary embolism. However, this remains a problem in pulmonary hypertension.

Magnetic resonance angiography is performed following intravenous administration of gadolinium. Gadolinium-based contrast agents [gadopentetate dimeglumine (Magnevist), gadobenate dimeglumine (MultiHance), gadodiamide (Omniscan), gadoversetamide (OptiMARK), gadoteridol (ProHance)] have been linked to the development of nephrogenic systemic fibrosis (NSF) or nephrogenic fibrosing dermopathy (NFD). The disease has occurred in patients with moderate to end-stage renal disease after being given a gadolinium-based contrast agent to enhance MRI or magnetic resonance angiography scans. NSF/NFD is a debilitating and sometimes fatal disease. Characteristics include red or dark patches on the skin; burning, itching, swelling, hardening, and tightening of the skin; yellow spots on the whites of the eyes; joint stiffness with trouble moving or straightening the arms, hands, legs, or feet; pain deep in the hip bones or ribs; and muscle weakness. MRI has a sensitivity of 85% and specificity of 96% for central, lobar, and segmental emboli; MRI is inadequate for the diagnosis of subsegmental emboli. Few data are available regarding the use of MRI in children suspected of having a pulmonary embolism. Its use in these patients should be considered investigational at this time. Few investigators have reported the feasibility of MRI in the evaluation of pulmonary embolism. However, the role of MRI is mostly limited to the evaluation of patients who have impaired renal function or other contraindications for the use of iodinated contrast material. Newer blood-pool contrast agents and respiratory navigators may enhance the role of MRI in the diagnosis of pulmonary embolism.

Ventilation-Perfusion Scanning

V/Q scanning of the lungs is an important modality for establishing the diagnosis of pulmonary embolism. However, V/Q scanning should be used only when CT scanning is not available or if the patient has a contraindication to CT scanning or intravenous contrast material. Children generally have a more homogenous perfusion scan; thus, deficits in perfusion are more likely to represent real or significant pulmonary embolism than they are in adults (Figs 17.17 and 17.18).

A. The high-probability criteria are as follows:

- Two large (>75% of a segment) segmental perfusion defects without corresponding ventilation or chest radiographic abnormalities
- One large segmental perfusion defect and two moderate (25–75% of a segment) segmental perfusion defects

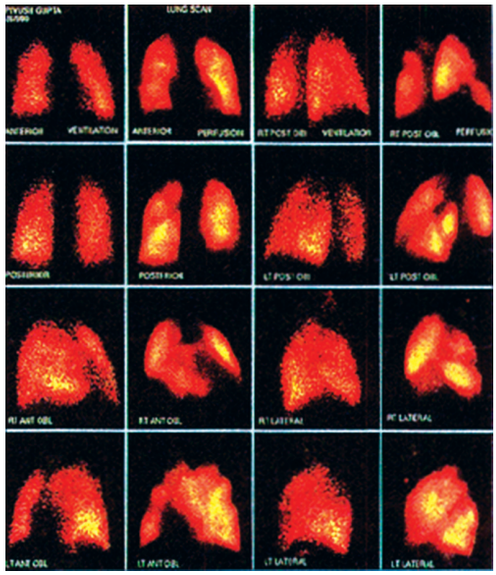

Fig. 17.17: Ventilation-perfusion scan of the patient showing reduced perfusion in right inferior and left upper lobes

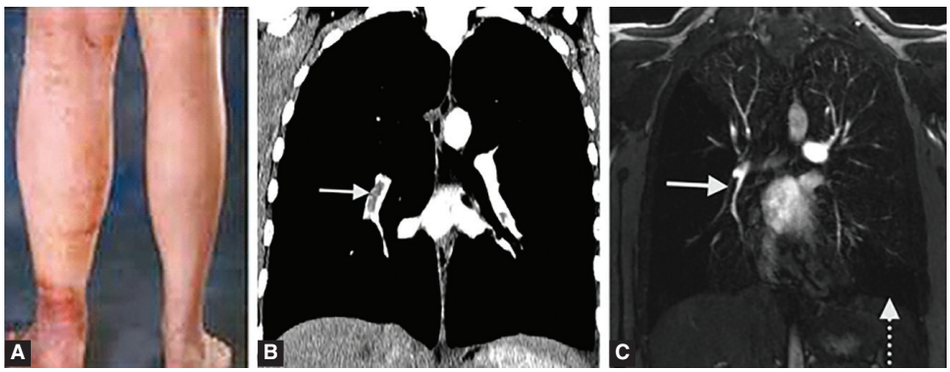

Fig. 17.16: A young female patient with swelling of the left leg. (A) CT angiography demonstrates thromboembolic material in the right (arrow) and left lower pulmonary artery. (B) High spatial resolution MR angiography performed using an intravascular contrast media. Both emboli were visualised; the image shows the thrombus in the right lower lobe (arrow). Also note the perfusion defect on right lower lobe. On the left side, the subsequent perfusion defect (dotted arrow) can be seen as an indirect sign of central vascular obstruction (C)

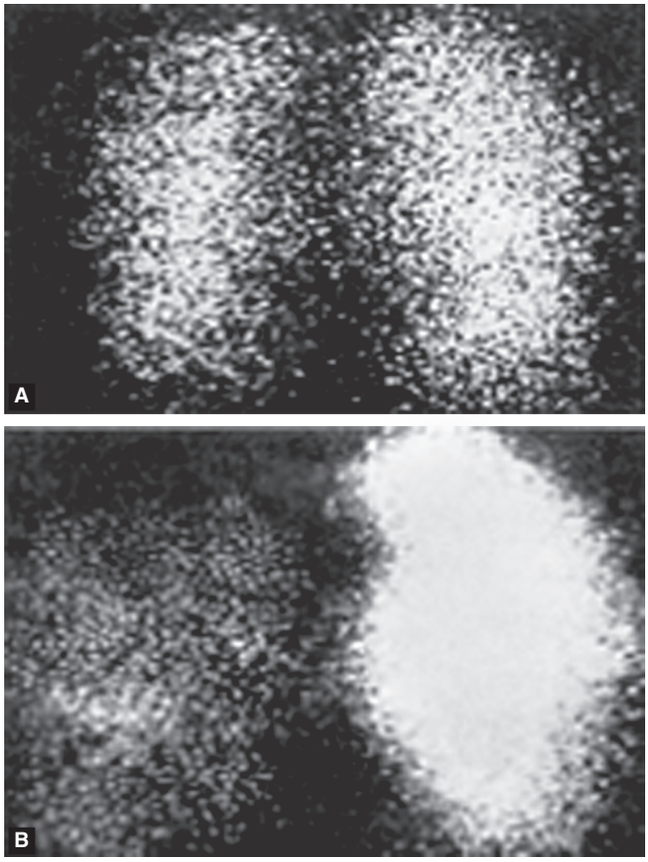

Fig. 17.18: (A) Normal ventilation scan. (B) Scan reveals defect in the right lung. Emboli in left lung not visualised

without corresponding ventilation or radiographic abnormalities
- Four moderate segmental perfusion defects without corresponding ventilation or chest radiographic abnormalities

B. The intermediate-probability criteria are as follows:
- One moderate to fewer than two large segmental perfusion defects without corresponding ventilation or chest radiographic abnormalities
- Corresponding V/Q defects and radiographic parenchymal opacity in lower lung zone
- Single moderate matched V/Q defects with normal chest radiographic findings
- Corresponding V/Q and chest radiography small pleural effusion
- Difficult to categorize as normal, low, or high probability

C. Low probability criteria are as follows:
- Multiple matched V/Q defects, regardless of size, with normal chest radiographic findings
- Corresponding V/Q defects and radiographic parenchymal opacity in upper or middle lung zone
- Corresponding V/Q defects and large pleural effusion
- Any perfusion defects with substantially larger radiographic abnormality
- Defects surrounded by normally perfused lung (**stripe sign**)
- More than three small (<25% of a segment) segmental perfusion defects with normal chest radiographic findings
- Nonsegmental perfusion defects (cardiomegaly, aortic impression, and enlarged hila)
- The normal finding is the presence of no perfusion defects and perfusion outlines the shape of the lung seen on a chest radiograph.
- The very low–probability criterion is the presence of three small (<25% of a segment) segmental perfusion defects with normal chest radiographic findings.

Pulmonary Angiography

Pulmonary angiography (Fig. 17.19) remains the criterion standard for the diagnosis of pulmonary embolism. Following injection of iodinated contrast, anteroposterior, lateral, and oblique studies are performed on each lung. Positive results consist of a filling defect or sharp cutoff of the affected artery (as shown in the image below). Nonocclusive emboli are described as having a tram-track appearance. Abnormal findings on V/Q scans performed prior to angiography guide the operator to focus on abnormal areas. Angiography generally is a safe procedure. The mortality rate for patients undergoing this procedure is less than 0.5%, and the morbidity rate is less than 5%. Patients who have long-standing pulmonary arterial hypertension and right ventricular failure are considered high-risk patients. Negative pulmonary angiogram findings, even if false negative, exclude clinically relevant pulmonary embolism.

A pulmonary angiogram shows the abrupt termination of the ascending branch of the right upper-lobe artery, confirming the diagnosis of pulmonary embolism.

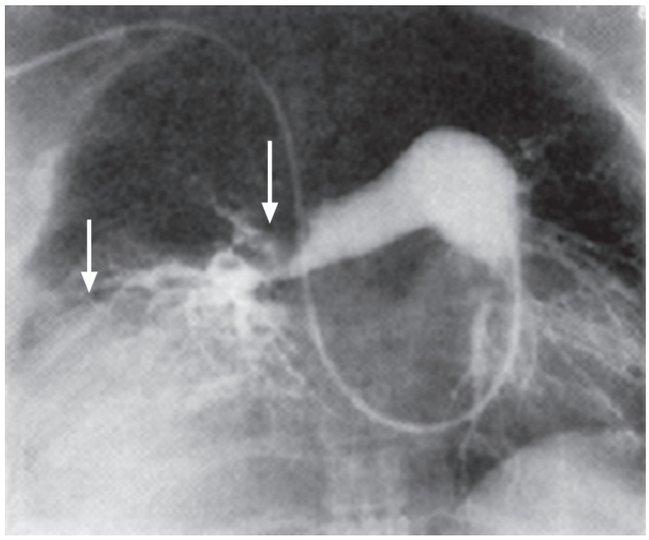

Fig. 17.19: Pulmonary angiography showing massive thrombus in the right pulmonary artery with almost complete obstruction to the blood flow (arrow). Note also the elevation of right hemidiaphragm (arrow)

If multidetector-row computed tomography angiography (MDCTA) is unavailable, conduct pulmonary angiography. Long the criterion standard for pulmonary embolism diagnosis, pulmonary angiography is nevertheless more invasive and harder to perform than MDCTA, and for these reasons, it is rapidly being replaced. However, pulmonary angiography remains a useful diagnostic modality when MDCTA cannot be performed.

When pulmonary angiography has been performed carefully and completely, a positive result provides virtually a 100% certainty that an obstruction to pulmonary arterial blood flow exists. A negative pulmonary angiogram provides a greater than 90% certainty for the exclusion of pulmonary embolism.

A positive angiogram is an acceptable endpoint no matter how abbreviated the study. However, a complete negative study requires the visualization of the entire pulmonary tree bilaterally. This is accomplished via selective cannulation of each branch of the pulmonary artery and injection of contrast material into each branch, with multiple views of each area. Even then, emboli in vessels smaller than third order or lobular arteries are not seen. Small emboli cannot be seen angiographically, yet embolic obstruction of these smaller pulmonary vessels is very common when postmortem examination follows a negative angiogram. These small emboli can produce pleuritic chest pain and a small sterile effusion even though the patient has a normal V/Q scan and a normal pulmonary angiogram. In most patients, however, pulmonary embolism is a disease of multiple recurrences, with large and small emboli already present by the time the diagnosis is suspected. Under these circumstances, the V/Q scan and the angiogram are likely to detect at least some of the emboli. Pulmonary angiography demonstrates subsegmental vessels in more detail than does CT scanning, although the superimposition of the small vessels remains a limiting factor. As a result, the interobserver agreement rate for isolated subsegmental pulmonary embolism is only 45%.

Duplex Ultrasonography and Plethysmography

The diagnosis of pulmonary embolism can be proven by demonstrating the presence of a DVT at any site. This may sometimes be accomplished noninvasively by using duplex ultrasonography. To look for DVT using ultrasonography, the ultrasonographic transducer is placed against the skin and pressed inward firmly enough to compress the vein being examined. In an area of normal veins, the veins are easily compressed completely closed, while the muscular arteries are extremely resistant to compression. Where DVT is present, the veins do not collapse completely when pressure is applied using the ultrasonographic probe. A negative ultrasonographic scan does not rule out DVT, because many DVTs occur in areas that are inaccessible to ultrasonographic examination. Before an ultrasonographic scan can be considered negative, the entire deep venous system must be interrogated using centimeter-by-centimeter compression testing of every vessel. In two-thirds of patients with pulmonary embolism, the site of DVT cannot be visualized with ultrasonography, so a negative duplex ultrasonographic scan does not markedly reduce the likelihood of pulmonary embolism (Figs 17.20–17.27).



Fig. 17.20: Duplex ultrasound investigation of the veins in chronic venous disease of the lower limbs



Fig. 17.21: Hand held Doppler and pneumatic cuff for determining the ankle brachial index in a diabetic patient with venu-arterial disease

Probability Testing

Recent recommendations for a diagnostic algorithm have been published by the PIOPED investigators; however, these recommendations do not reflect research using 64 slice MDCT.

These investigators recommended: Low clinical probability. If negative D-dimer, PE is excluded. If positive D-dimer, obtain MDCT and based treatment on results.

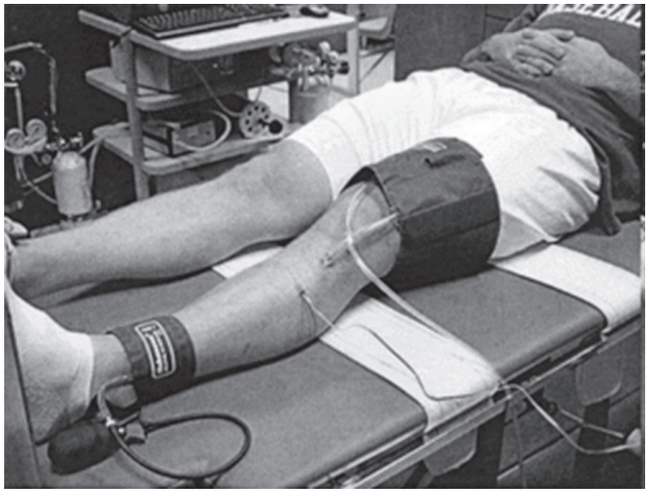

Fig. 17.22: Laboratory setup showing the thigh and ankle cuffs of the plethysmograph with the mercury-in-rubber strain gauge secured to the midcalf region

- ***Moderate clinical probability:*** If negative D-dimer, PE is excluded. However, the authors were not concerned that a negative MDCT with negative D-dimer in this setting has an 5% probability of being false. Presumably, the 5% error rate will fall as 64 slice MDCT is more commonly used. If positive D-dimer, obtain MDCT and based treatment on results.
- ***High clinical probability:*** Proceed to MDCT. If positive, treat, if negative, additional tests are needed to exclude PE.

Pulmonary Embolism Rule-out Criteria

The pulmonary embolism rule-out criteria (PERC) help assess people in whom pulmonary embolism is suspected, but unlikely. Unlike the Wells Score and Geneva score, which are clinical prediction rules intended to risk stratify patients with suspected PE, the PERC rule is designed to rule out risk of PE in patients when the physician has already stratified them into a low-risk category.

Patients in this low risk category without any of these criteria may undergo no further diagnostic testing for PE:

- Hypoxia — SaO_2 <95%,
- Unilateral leg swelling,
- Hemoptysis,
- Prior DVT or PE,
- Recent surgery or trauma,
- Age >50,
- Hormone use,
- Tachycardia.

The rationale behind this decision is that further testing (specifically CT angiogram of the chest) may cause more harm (from radiation exposure and contrast dye) than the risk of PE. The PERC rule has a sensitivity of 97.4% and specificity of 21.9% with a false negative rate of 1.0%.

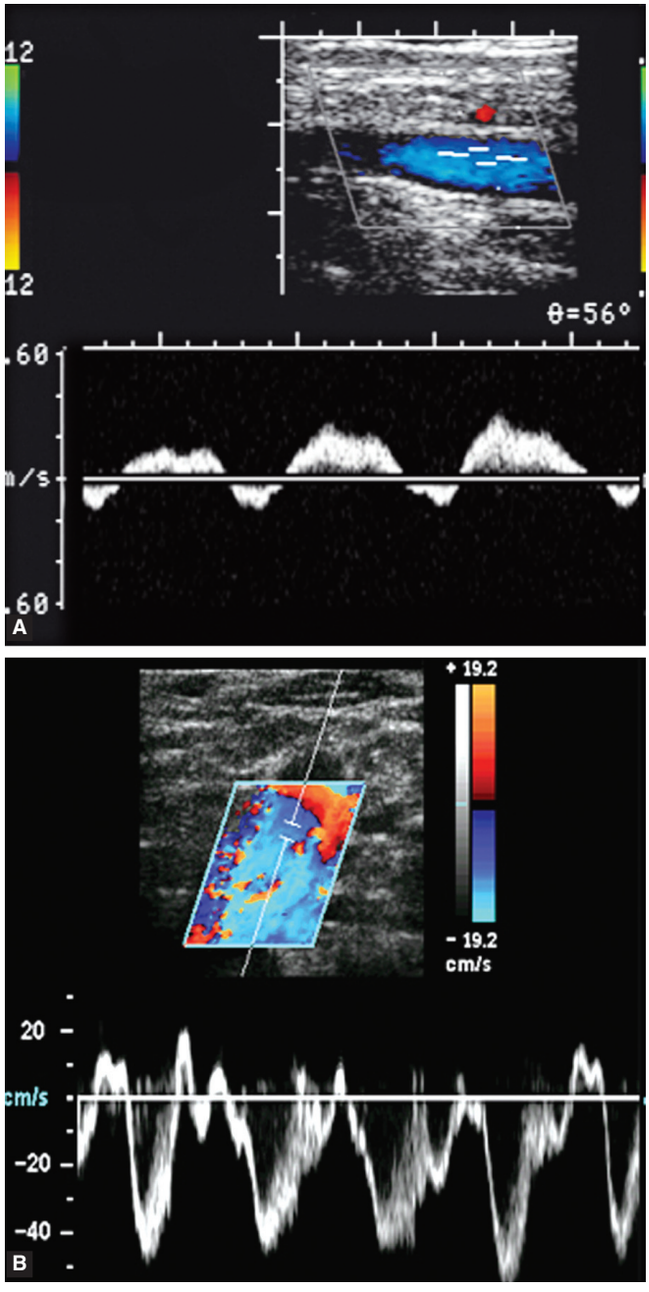

Fig. 17.23: (A) normal peripheral vein. (B) Duplex Doppler demonstrating nonphasic flow in a peripheral vein with thrombosis

Risk Factors in PE

A deep vein thrombosis as seen in the right leg is a risk factor for PE. The most common sources of embolism are proximal leg deep venous thrombosis (DVTs) or pelvic vein thromboses. Any risk factor for DVT also increases the risk that the venous clot will dislodge and migrate to the lung circulation, which may happen in as many as 15% of all DVTs. The conditions are generally regarded as a continuum termed venous thromboembolism (VTE) (Table 17.4).

The development of thrombosis is classically due to a group of causes named Virchow's triad (alterations in blood

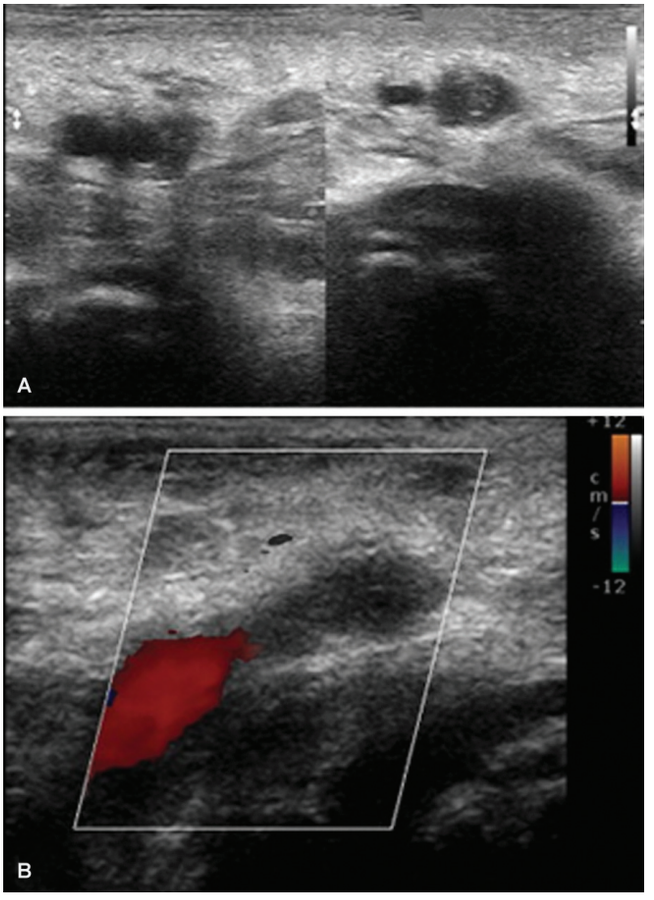

Fig. 17.24: Acute thrombosis of the common femoral vein in 2-year-old boy is demonstrated by cross-sectional imaging of the femoral vessels. (A) The left panel shows a dilated common femoral vein with echolucent luminal material. The right panel shows that the common femoral vein is not compressible, despite the use pressure that reduced the common femoral artery diameter by half. (B) The common femoral vein from the same patient is viewed with color imaging. The vein is dilated, contains echolucent material, and has absence of flow in contrast to normal flow in the adjacent common femoral artery

Table 17.4: Risk factors for DVT have been identified in many different epidemiologic studies

General	• Age • Immobilization longer than 3 days • Pregnancy and the postpartum period • Major surgery in previous 4 weeks • Long plane or car trips (>4 h) in previous 4 weeks
Medical	• Cancer • Previous DVT • Stroke • Acute myocardial infarction (AMI) • Congestive heart failure (CHF) • Sepsis • Nephrotic syndrome • Ulcerative colitis
Trauma	• Multiple trauma • CNS/spinal cord injury • Burns • Lower extremity fractures
Vasculitis	• Systemic lupus erythematosus (SLE) and the lupus anticoagulant • Behçet syndrome • Homocystinuria
Hematologic	• Polycythemia rubra vera • Thrombocytosis • Inherited disorders of coagulation/fibrinolysis • Antithrombin III deficiency • Protein C deficiency • Protein S deficiency • Prothrombin 20210A mutation • Factor V Leiden • Dysfibrinogenemias and disorders of plasminogen activation

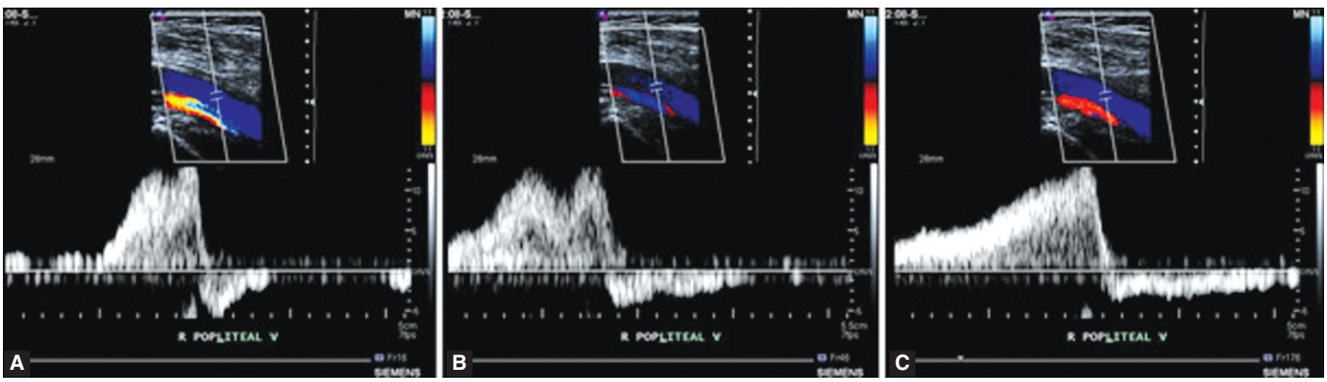

Fig. 17.25: Variability of reflux response. The effect of the length of augmentation on the tendency of lower extremity veins to reflux. All images are obtained from the same sample site in the popliteal vein of the same patient. (A) Short augmentation resulting in reflux time of only 0.7 seconds. (B) Longer augmentation resulting in reflux time of 1.5 seconds. (C) Prolonged augmentation resulting in continuous reflux for many seconds

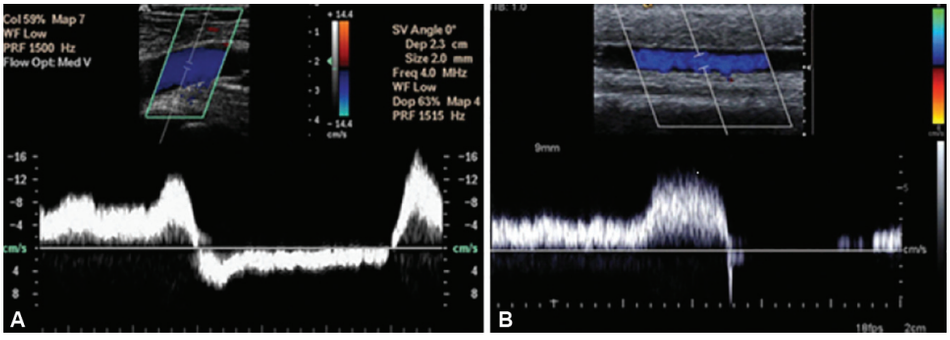

Fig. 17.26: (A) Refluxing deep vein. Reflux in the femoral vein elicited with a sustained Valsalva or simulated Valsalva manoeuvre lasting three seconds. (B) Competent superficial vein. Well-optimised duplex image of flow in a competent superficial vein. Wide color box was used in order for a long segment of the vein to be visualised. Spectral waveform is large and clear. Spontaneous venous flow is seen in the left side of the spectral trace, followed by manual augmentation. There is a sharp 'click' or 'snap' of venous valve closure followed by a period of absent flow. Once arterial inflow refills the peripheral vascular bed, normal antegrade flow resumes again on the right side of the spectral Doppler trace

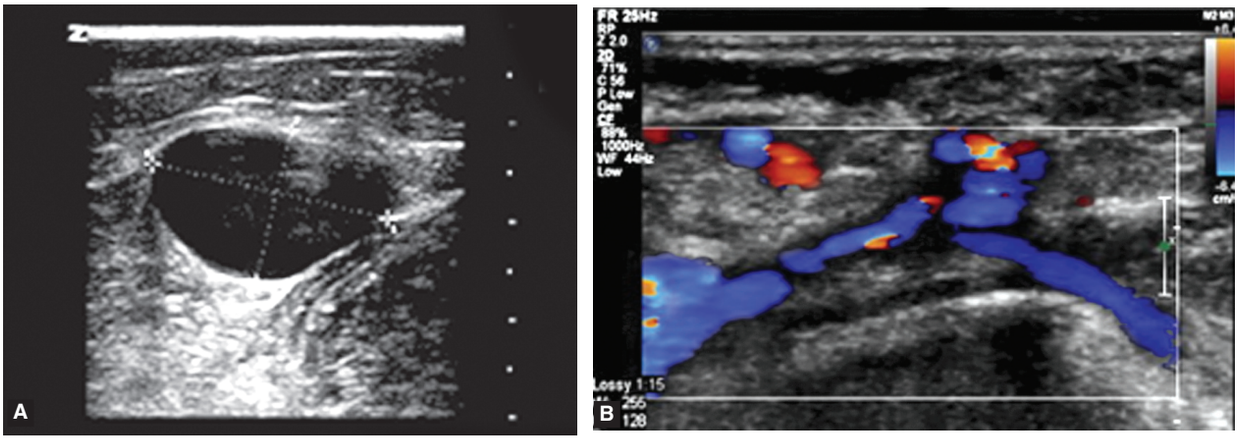

Fig. 17.27: (A) Patient is a 19-year adolescent that presented with swelling and aching of both lower extremities. He had bilateral varicose veins especially on the right with discoloration and stasis changes however no ulceration or previous ulceration was reported. He denied previous deep venous thrombosis or phlebitis. The patient was finally diagnosed as venous aneurysm of inferior vena cava. (B) Chronic thrombosis of the common femoral vein is seen a year after it was diagnosed in a 4-month-old girl. Echogenic material is seen in the lumen of the partially recanalized vein. Irregular flow channels are seen through the old thrombus in the common femoral vein

flow, factors in the vessel wall and factors affecting the properties of the blood). Often, more than one risk factor is present.

Alterations in blood flow—immobilization (after surgery, injury, pregnancy (also procoagulant), obesity (also procoagulant), and cancer (also procoagulant).

Factors in the vessel wall—surgery, catheterizations causing direct injury ('endothelial injury').

Complications of pulmonary embolism include the following:

- Sudden cardiac death
- Obstructive shock
- Pulseless electrical activity
- Atrial or ventricular arrhythmias
- Secondary pulmonary arterial hypertension
- Cor pulmonale
- Severe hypoxemia
- Right-to-left intracardiac shunt
- Lung infarction
- Pleural effusion
- Paradoxical embolism
- Heparin-induced thrombocytopenia
- Thrombophlebitis

PREVENTION OF PULMONARY EMBOLISM

Preventing idiopathic outpatient pulmonary embolism is difficult, if not impossible. That said, the majority of pulmonary embolisms occur in hospitalized patients. The incidence in these cases can be reduced through appropriate prophylaxis, achieved mechanically or via the administration of heparin, LMWH, or warfarin. The incidence of venous thrombosis, pulmonary embolism, and death can

be significantly reduced by embracing a prophylactic strategy in high-risk patients.

Prevention of DVT in the lower extremities inevitably reduces the frequency of pulmonary embolism; therefore, populations at risk must be identified, and safe and efficacious prophylactic modalities should be used. The Q-thrombosis algorithm is intended to identify currently asymptomatic adults at greatest future risk of venous thrombosis based on established risk factors. According to the study in which it was developed and validated, Q-thrombosis estimates the absolute risk of venous thrombosis at 1 year and 5 years into the future, information that can be used to guide prophylaxis and medication decisions.

TREATMENT

Anticoagulant therapy is typically the mainstay of treatment. Acutely, supportive treatments, such as oxygen or analgesia, may be required. People are often admitted to hospital in the early stages of treatment, and tend to remain under inpatient care until the INR has reached therapeutic levels. Increasingly, however low-risk cases are managed at home in a fashion already common in the treatment of DVT.

Anticoagulation

In most cases, anticoagulant therapy is the mainstay of treatment. Unfractionated heparin, low molecular weight heparin (LMWH), or fondaparinux is administered initially, while warfarin, acenocoumarol, or phenprocoumon therapy is commenced (this may take several days, usually while the patient is in the hospital). LMWH may reduce bleeding among patients with pulmonary embolism as compared to heparin according to a systematic review of randomized controlled trials by the Cochrane collaboration. The relative risk reduction was 40%. For patients at similar risk to those in this study (2.0% had bleeding when not treated with low molecular weight heparin), this leads to an absolute risk reduction of 0.8%. 125 patients must be treated for one to benefit.

Warfarin therapy often requires frequent dose adjustment and monitoring of the international normalized ratio (INR). In PE, INRs between 2.0 and 3.0 are generally considered ideal. If another episode of PE occurs under warfarin treatment, the INR window may be increased to e.g. 2.5–3.5 (unless there are contraindications) or anticoagulation may be changed to a different anticoagulant, e.g. LMWH. In patients with an underlying malignancy, therapy with a course of LMWH may be favored over warfarin based on the results of the CLOT trial. Similarly, pregnant women are often maintained on low molecular weight heparin until at least 6 weeks after delivery to avoid the known teratogenic effects of warfarin, especially in the early stages of pregnancy. Warfarin therapy is usually continued for 3–6 months, or 'lifelong' if there have been previous DVTs or PEs, or none of the usual risk factors is present. An abnormal D-dimer level at the end of treatment might signal the need for continued treatment among patients with a first unprovoked pulmonary embolus.

Thrombolysis

Massive PE causing hemodynamic instability (shock and/or hypotension, defined as a systolic blood pressure <90 mmHg or a pressure drop of 40 mmHg for >15 min if not caused by new-onset arrhythmia, hypovolemia or sepsis) is an indication for thrombolysis, the enzymatic destruction of the clot with medication. It is the best available medical treatment in this situation and is supported by clinical guidelines. The use of thrombolysis in nonmassive PEs is still debated. The aim of the therapy is to dissolve the clot, but there is an attendant risk of bleeding or stroke. The main indication for thrombolysis is in submassive PE where right ventricular dysfunction can be demonstrated on echocardiography, and the presence of visible thrombus in the atrium.

Inferior vena cava filter in the prevention of thromboembolism

If anticoagulant therapy is contraindicated and/or ineffective, or to prevent new emboli from entering the pulmonary artery and combining with an existing blockage, an inferior vena cava filter may be implanted (Fig. 17.28).

Catheter-based endovascular therapies in deep venous thrombosis

Acute DVT should be viewed as a chronic disease by treating physicians, because the associated long-term patient disability is quite substantial (Figs 17.29–17.31). Catheter-based endovascular therapies offer the potential to preserve life and limb (for severely affected patients), prevent PTS, and improve quality of life in patients with proximal DVT. Multicenter randomized clinical trials are ongoing to determine which patients should be treated in this manner. Selected patients with established The post-thrombotic syndrome (PTS) may also now have a reasonable chance of experiencing symptom alleviation

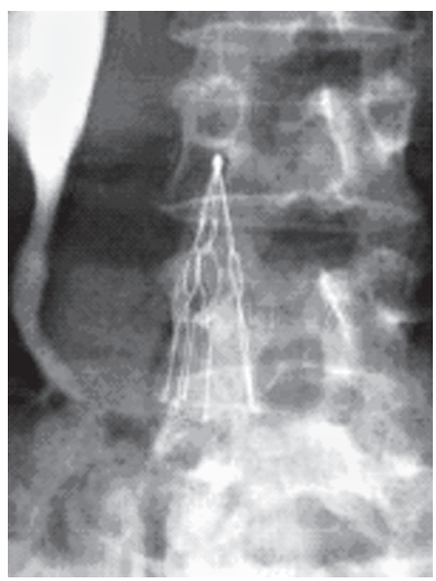

Fig. 17.28: Greenfield filter for the prevention of thromboembolism out of DVT from the lower limb veins

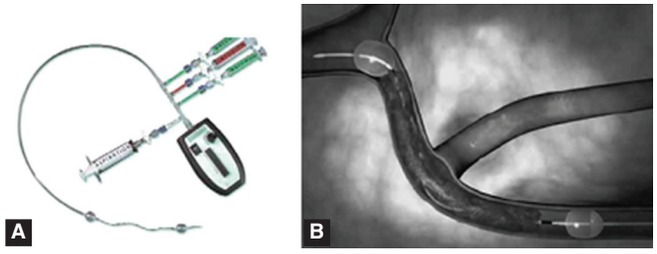

Fig. 17.29: (A) The Trellis-8 system (Bacchus Vascular, Santa Clara, CA) consists of proximal and distal balloons, with balloon inflation syringes, a thrombolysis infusion port, the thrombus aspiration syringe, and a drive unit for mechanical dispersion of the thrombolytic agent. (B) Trellis catheter ablation treatment for deep vein thrombosis

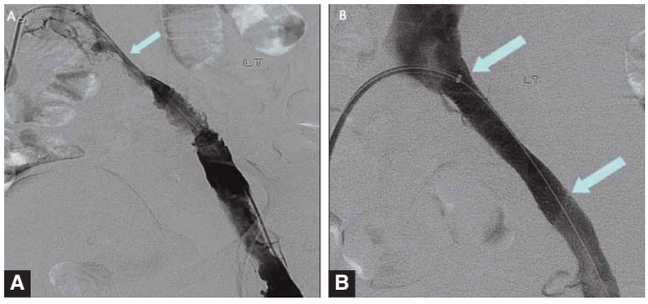

Fig. 17.31: (A) A left iliac vein angiogram reveals stenosis of the proximal left common iliac vein (arrow), suggestive of May-Thurner syndrome. (B) Final angiogram of the left iliac vein after stent deployment reveals complete resolution of thrombus and stenosis (arrows)

with the use of endovascular therapies. Hematologists and other thrombosis physicians should be aware of these options and consult their endovascular colleagues for patients in need of salvage therapy.

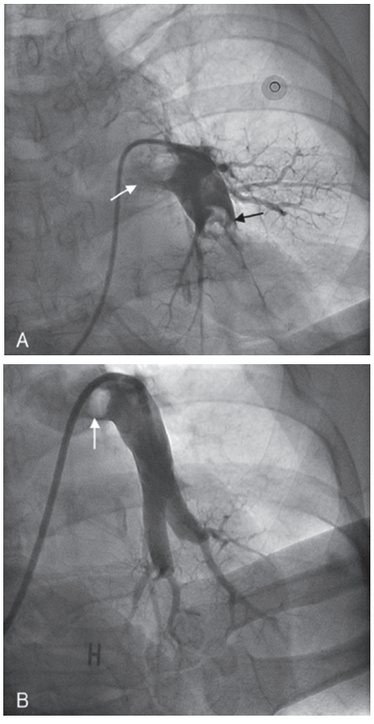

Fig. 17.30: Pulmonary artery angiogram. (A) The pulmonary artery angiogram showed massive thromboembolism at the left main pulmonary artery (arrow) without distal flow. (B) After percutaneous catheter thrombectomy, the opacity and distal flow was improved, but a large thrombus (arrow) remained at the left main pulmonary artery

Stentoplasty in SVC Stenosis

Superior vena cava (SVC) obstruction can occur from extrinsic compression, intrinsic stenosis or thrombosis (Fig. 17.32). Malignancies are the main cause and is

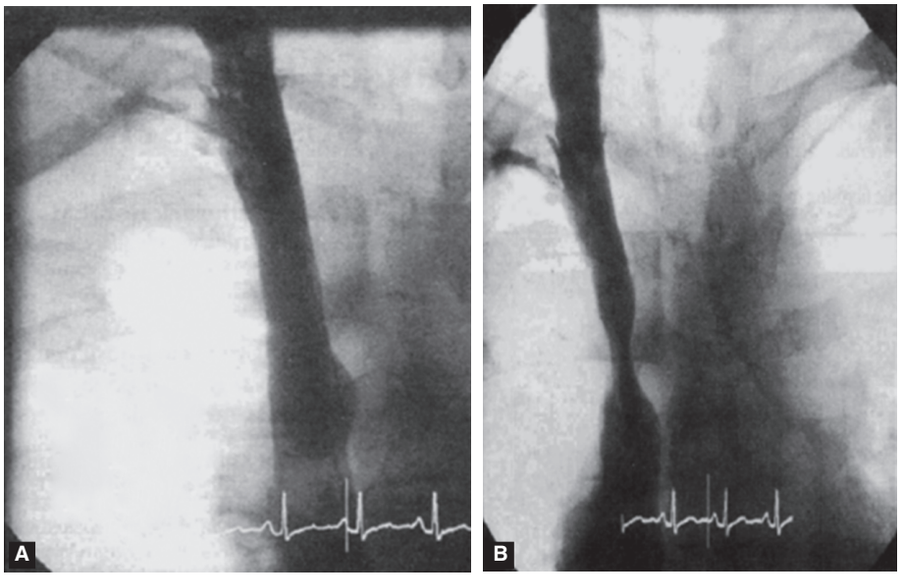

Fig. 17.32: (A) Superior venogram before stent deployment shows narrowing of the SVC. (B) Check angiogram showing no residual stenosis and good antegrade flow in the SVC

considered an oncologic emergency. **Superior vena cava syndrome** (**SVCS**) refers to the clinical syndrome with symptoms that results from this obstruction.

Surgical Intervention

Surgical management of acute pulmonary embolism (pulmonary thrombectomy) is uncommon and has largely been abandoned because of poor long-term outcomes. However, recently, it has gone through a resurgence with the revision of the surgical technique and is thought to benefit certain people. Chronic pulmonary embolism leading to pulmonary hypertension (known as chronic thromboembolic hypertension) is treated with a surgical procedure known as a pulmonary thromboendarterectomy (Fig. 17.33).

Prognosis

Mortality from untreated PE is said to be 26%. This figure comes from a trial published in 1960 by Barrit and Jordan, which compared anticoagulation against placebo for the management of PE. Barritt and Jordan performed their study in the Bristol Royal Infirmary in 1957. This study is the only placebo controlled trial ever to examine the place of anticoagulants in the treatment of PE, the results of which were so convincing that the trial has never been repeated as to do so would be considered unethical. That said, the reported mortality rate of 26% in the placebo group is probably an overstatement, given that the technology of the day may have detected only severe PEs.

Prognosis depends on the amount of lung that is affected and on the coexistence of other medical conditions; chronic embolisation to the lung can lead to pulmonary hypertension. After a massive PE, the embolus must be resolved somehow if the patient is to survive. In thrombotic PE, the blood clot may be broken down by fibrinolysis, or it may be organized and recanalized so that a new channel forms through the clot. Blood flow is restored most rapidly in the first day or two after a PE. Improvement slows thereafter and some deficits may be permanent. There is controversy over whether or not small subsegmental PEs need to be treated at all and some evidence exists that patients with subsegmental PEs may do well without treatment. Once anticoagulation is stopped, the risk of a fatal pulmonary embolism is 0.5% per year.

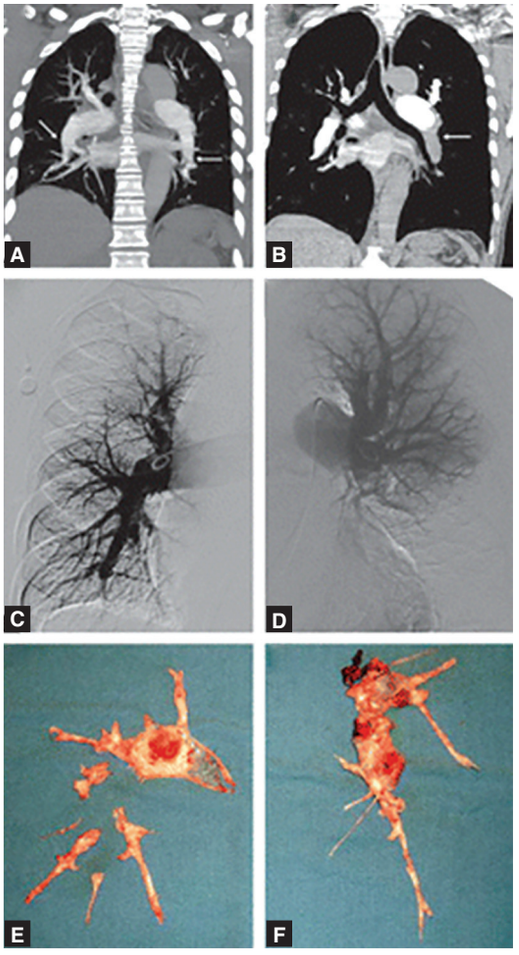

Fig. 17.33. (A) Computed tomography (CT) pulmonary angiogram showing evidence of webs in the descending branch of the right and left pulmonary artery (arrows). (B) CT pulmonary angiogram performed 1 year later after referral to our centre, demonstrating the presence of new large thrombi in the left pulmonary artery (arrow) that occurred despite treatment with low molecular weight heparin. (C) Pulmonary angiogram of the right pulmonary artery showing evidence of segmental defects in the right upper and lower lobes. (D) Pulmonary angiogram of the left pulmonary artery showing an occlusion of the descending branch to the left lower lobe. (E) Pulmonary endarterectomy specimen of the right lung. (F) Pulmonary endarterectomy specimen of the left lung

LONG-TERM MONITORING

PT should be measured on a regular basis; the goal is an INR of 2–3. The length of treatment depends on the presence of risk factors. If no underlying risk factors are present, therapy can be stopped within 1–2 months. If risk factors are present, especially anticardiolipin antibodies, therapy should continue for at least 4–6 months. Long-term anticoagulation is essential for patients who survive an initial DVT or pulmonary embolism. The optimum total duration of anticoagulation is controversial, but general consensus holds that at least 6 months of anticoagulation is associated with significant reduction in recurrences and a net positive benefit. Patients may have treatment initiated using concomitant warfarin and unfractionated heparin for 5 days in the hospital, with discharge on warfarin alone when the international normalized ratio (INR) is 2. Alternatively, patients may be discharged on concomitant therapy with a LMWH and warfarin for at least 5 days. The LMWH is then discontinued in the outpatient setting when the INR reaches 2.

BIBLIOGRAPHY

1. Aklog L, Williams CS, Byrne JG, Goldhaber SZ. Acute pulmonary embolectomy: a contemporary approach. Circulation 2002;105:1416–9.

2. Bauer KA. The thrombophilias: well-defined risk factors with uncertain therapeutic implications. Ann Intern Med 2001; 135:367–73.
3. Brandjes DP, Buller HR, Heijboer H, Huisman MV, de Rijk M, Jagt H, et al. Randomised trial of effect of compression stockings in patients with symptomatic proximal-vein thrombosis. Lancet 1997;349:759–62.
4. Crowther MA, Harrison L, Hirsh J. Reply. Warfarin: less may be better. Ann Intern Med 1997:127:333.
5. Decousus H, Leizorovicz A, Parent F, Page Y, Tardy B, Girard P, et al. A clinical trial of vena caval filters in the prevention of pulmonary embolism in patients with proximal deep-vein thrombosis. N Engl J Med 1998;338:409–15.
6. Geerts WH, Heit JA, Clagett GP, Pineo GF, Colwell CW, Anderson FA Jr, et al. Prevention of venous thrombo-embolism. Chest 2001;119(1 Suppl):132S–75S.
7. Hull RD, Raskob GE, Brant RF, Pineo GF, Elliott G, Stein PD, et al. Low-molecular-weight heparin vs heparin in the treatment of patients with pulmonary embolism. American-Canadian Thrombosis Study Group. Arch Intern Med 2000;160:229–36.
8. Hull RD, Raskob GE, Rosenbloom D, Panju AA, Brill-Edwards P, Ginsberg JS, et al. Heparin for 5 days as compared with 10 days in the initial treatment of proximal venous thrombosis. N Engl J Med 1990;322:1260–4.
9. Hyers TM, Agnelli G, Hull RD, Morris TA, Samama M, Tapson V, et al. Antithrombotic therapy for venous thromboembolic disease. Chest 2001;119(1 suppl): 176S–93S.
10. Juergens CP, Semsarian C, Keech AC, Beller EM, Harris PJ. Hemorrhagic complications of intravenous heparin use. Am J Cardiol 1997;80:150–4.
11. Kearon C, Ginsberg JS, Kovacs MJ, Anderson DR, Wells P, Julian JA, et al. Comparison of low-intensity warfarin therapy with conventional-intensity warfarin therapy for long-term prevention of recurrent venous thrombo-embolism. N Engl J Med 2003;349:631–9.
12. Konstantinides S, Geibel A, Heusel G, Heinrich F, Kasper W. Heparin plus alteplase compared with heparin alone in patients with submassive pulmonary embolism. N Engl J Med 2002;347:1143–50.
13. Kovacs MJ, Anderson D, Morrow B, Gray L, Touchie D, Wells PS. Outpatient treatment of pulmonary embolism with dalteparin. Thromb Haemost 2000;83:209–11.
14. Kovacs MJ, Rodger M, Anderson DR, Morrow B, Kells G, Kovacs J, et al. Comparison of 10-mg and 5-mg warfarin initiation nomograms together with low-molecular-weight heparin for outpatient treatment of acute venous thrombo-embolism. A randomized, double-blind, controlled trial. Ann Intern Med 2003;138:714–9.
15. Lee AY, Levine MN, Baker RI, Bowden C, Kakkar AK, Prins M, et al. Low-molecular-weight heparin versus a coumarin for the prevention of recurrent venous thromboembolism in patients with cancer. N Engl J Med 2003;349:146–53.
16. Levine M, Gent M, Hirsh J, Leclerc J, Anderson D, Weitz J, et al. A comparison of low-molecular-weight heparin administered primarily at home with unfractionated heparin administered in the hospital for proximal deep-vein thrombosis. N Engl J Med 1996;334:677–81.
17. Lilienfeld DE. Decreasing mortality from pulmonary embolism in the United States, 1979–1996. Int J Epidemiol 2000;29:465–9.
18. Pinede L, Ninet J, Duhaut P, Chabaud S, Demolombe-Rague S, Durieu I, et al. Comparison of 3 and 6 months of oral anticoagulant therapy after a first episode of proximal deep vein thrombosis or pulmonary embolism and comparison of 6 and 12 weeks of therapy after isolated calf deep vein thrombosis. Circulation 2001;103:2453–60.
19. Ramzi DW, Leeper KV. DVT and pulmonary embolism: part I. Diagnosis. Am Fam Physician 2004;69:2829–36.
20. Raschke RA, Reilly BM, Guidry JR, Fontana JR, Srinivas S. The weight-based heparin dosing nomogram compared with a "standard care" nomogram. A randomized controlled trial. Ann Intern Med 1993;119:874–81.
21. Ridker PM, Goldhaber SZ, Danielson E, Rosenberg Y, Eby CS, Deitcher SR, et al. Long-term, low-intensity warfarin therapy for the prevention of recurrent venous thrombo-embolism. N Engl J Med 2003;348:1425–34.
22. Savage KJ, Wells PS, Schulz V, Goudie D, Morrow B, Cruickshank M, et al. Out-patient use of low molecular weight heparin (dalteparin) for the treatment of deep vein thrombosis of the upper extremity. Thromb Haemost 1999;82:1008–10.

18 Aortic Dissection

Aortic dissection is defined as separation of the layers within the aortic wall. Tears in the intimal layer result in the propagation of dissection (proximally or distally) secondary to blood entering the intima-media space. Much has been written on the subject of aortic dissections, from the first well-documented case of aortic dissection, when King George II of England died while straining on the commode, to the first successful operative repairs by DeBakey in 1955, to modern techniques of diagnosing and repairing thoracic aortic dissections.

Aortic dissection is the most common catastrophe of the aorta, 2–3 times more common than rupture of the abdominal aorta. When left untreated, about 33% of patients die within the first 24 hours, and 50% die within 48 hours. The 2-week mortality rate approaches 75% in patients with undiagnosed ascending aortic dissection.

CLASSIFICATION

Dissections of the thoracic aorta have been classified anatomically by two different methods. The more commonly used system is the Stanford classification, which is based on involvement of the ascending aorta and simplifies the DeBakey classification (Figs 18.1 and 18.2).

The Stanford classification divides dissections into two types, type A and type B:

- **Type A** involves the ascending aorta (DeBakey types I and II).
- **Type B** descending aorta is involved (DeBakey type III).
- This system also helps delineate treatment. Usually, type A dissections require surgery, while type B dissections may be managed medically under most conditions.

The DeBakey classification divides dissections into three types:

- **Type I** involves the ascending aorta, aortic arch, and descending aorta.
- **Type II** is confined to the ascending aorta.
- **Type III** is confined to the descending aorta distal to the left subclavian artery. Type III dissections are further divided into **IIIa and IIIb.**

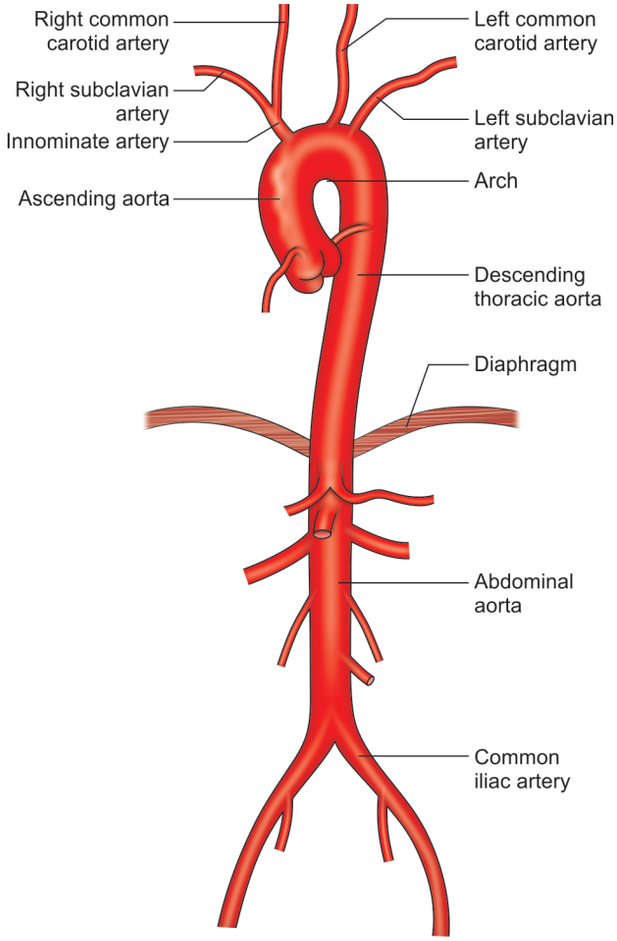

Fig.18.1: Anatomy of human normal aorta showing different branches arising out of ascending, arch, thoracic and abdominal aorta

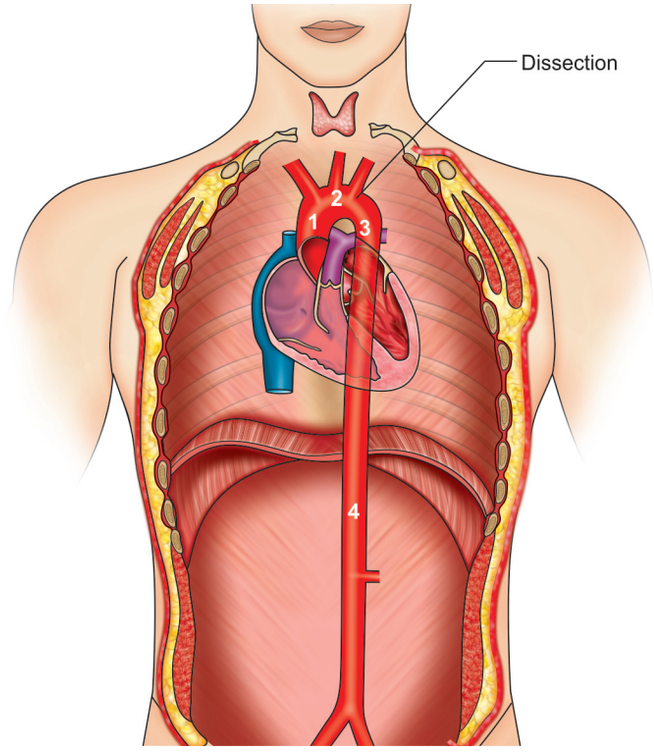

Fig. 18.2: Dissection of the descending part of the aorta (3), which starts from the left subclavian artery and extends to the abdominal aorta (4). The ascending aorta (1) and aortic arch (2) are not involved

- **Type IIIa** refers to dissections that originate distal to the left subclavian artery but extend both proximally and distally, mostly above the diaphragm.
- **Type IIIb** refers to dissections that originate distal to the left subclavian artery, extend only distally and may extend below the diaphragm.

Thoracic aortic dissections should be distinguished from aneurysms (i.e. localized abnormal dilation of the aorta) and transections, which are caused most commonly by high-energy trauma.

Pathophysiology: The essential feature of aortic dissection is a tear in the intimal layer, followed by formation and propagation of a subintimal hematoma. The dissecting hematoma commonly occupies about half and occasionally the entire circumference of the aorta. This produces a false lumen or double-barreled aorta, which can reduce blood flow to the major arteries arising from the aorta. If the dissection involves the pericardial space, cardiac tamponade may result.

Cystic Medial Necrosis

The normal aorta contains collagen, elastin, and smooth muscle cells that contribute the intima, media, and adventitia, which are the layers of the aorta. With aging, degenerative changes lead to breakdown of the collagen, elastin, and smooth muscle and an increase in basophilic ground substance. This condition is termed cystic medial necrosis. Atherosclerosis that causes occlusion of the vasa vasorum also produces this disorder. Cystic medial necrosis is the hallmark histologic change associated with dissection in those with Marfan syndrome.

Cystic medial necrosis was first described by Erdheim in 1929. Sources disagree over the accuracy of this term in elderly patients because the true histopathologic changes are neither cystic nor necrotic. Researchers have used the term cystic medial degeneration. Early on, cystic medial necrosis described an accumulation of basophilic ground substance in the media with the formation of cystlike pools. The media in these focal areas may show loss of cells (i.e. necrosis). This term still is used commonly to describe the histopathologic changes that occur.

DISSECTION SITES

The most common site of dissection is the first few centimeters of the ascending aorta, with 90% occurring within 10 centimeters of the aortic valve (Fig. 18.3). The

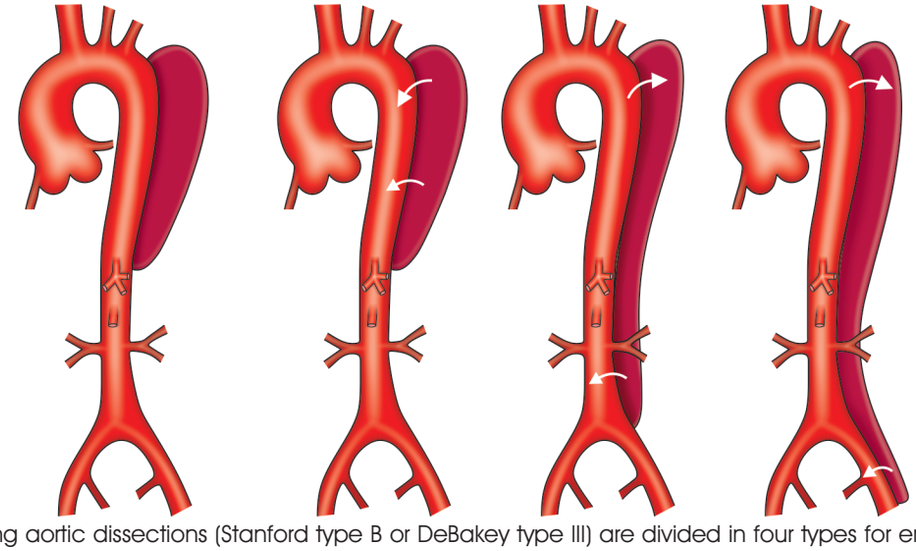

Fig. 18.3: Descending aortic dissections (Stanford type B or DeBakey type III) are divided in four types for endovascular purposes

second most common site is just distal to the left subclavian artery. Between 5% and 10% of dissections do not have an obvious intimal tear. These often are attributed to rupture of the aortic vasa vasorum as first described by Krukenberg in 1920.

DESCENDING AORTIC DISSECTIONS

Descending aortic dissections (Stanford type B or DeBakey type III) are divided in four types for endovascular purposes:

- Type 1 has no identifiable intimomedial tears in the descending thoracic aorta
- Type 2 has one or more intimomedial tears in the descending thoracic aorta and there is no tear at or distal to the level of the celiac artery
- Type 3 has intimomedial tears involving the abdominal aorta (with or without concomitant tears in the descending thoracic aorta)
- Type 4 has intimomedial tears distal to the aortic bifurcation (with or without concomitant tears in the descending thoracic and abdominal aorta

DISEASES LEADING TO AORTIC DISSECTION

Certain diseases, such as Marfan, Ehlers-Danlos, and other connective tissue diseases, affect the media of the aorta and make it prone to dissection. Pulsatile flow and high blood pressure contribute to propagation of the dissection.

Diseases that weaken the aortic wall predispose the patient to aortic dissection. Shearing forces separate the layers in the media of the aorta. Intimal rupture occurs at points of fixation along the aorta where hydraulic stress is maximal (Table 18.1).

INCIDENCE

The true incidence of dissection is difficult to estimate. Most estimates are based on autopsy studies. One population-based study estimated the incidence at roughly 6 new aneurysms per 100,000 person-years. Evidence of dissection is found in 1–3% of all autopsies.

Mortality/Morbidity

- From 1–2% of patients with aortic dissection die per hour for the first 24–48 hours.
- Aortopathy may be present in heritable diseases such as Marfan syndrome, Ehlers-Danlossyndrome, annulo-aortic ectasia, familial aortic dissections, adult polycystic kidney disease, Turner syndrome, Noonan syndrome, osteogenesis imperfecta, bicuspid aortic valve, coarctation of the aorta, and connective tissue disorders. It is also seen in heritable metabolic disorders such as homocystinuria and familial hypercholesterolemia.
- Incidence is increased in pregnancy and syphilis. Thoracic aortic dissection also is associated with **crack cocaine use** and iatrogenic causes, such as cardiac catheterization.

Race: Aortic dissection is more common in blacks than in whites and less common in Asians than in whites.

Sex: The male-to-female ratio is 3:1.

Age: Approximately 75% of dissections occur in those aged 40–70 years, with a peak in the range of 50–65 years.

History: 'Spontaneous tear of the arterial coats is associated with atrocious pain, with symptoms, indeed, in the case of the aorta of angina pectoris and many instances have been mistaken for it' William Osler, 1910.

Chest pain is the most common presenting symptom in patients with an aortic dissection. Consider thoracic aortic dissection in the differential diagnosis of all patients presenting with chest pain.

The pain usually is described as ripping or tearing. The description of ripping or tearing has been shown to have a likelihood ratio for aortic dissection of 1.2 and 10.8.

The sudden onset of chest pain has been shown to have a sensitivity of 84%.

Table 18.1: Causes of thoracic aortic aneurysm

Aetiology	Aortic segment	Pathophysiology
Marfan syndrome	Ascending aorta and root, aortic arch	Defective fibrillin: secondary cystic medial degeneration
Ehlers-Danios syndarome	Ascending aorta, predominantly aortic arch	Defective collagen: secondary cystic medial degeneration
Cystic medial degeneration	Ascending aorta, aortic arch	*De novo* cystic medial degeneration
Atherosclerotic	Descending aorta	Atherosclerotic plaques, weakening vessel walls
Traumatic	Aortic isthmus, proximal descending aorta	Damaged vessel wall, intramural hematoma
Inflammatory	Variable	Takayasu's arteritis, giant cell arteritis, HLA-B27-associated spondyloarthropathies
Infectious	Aortic root (syphilis), variable (mycolic)	CMD (syphilis), inflammatory changes (mycotic)
Posistenotic	Ascending (aortic stenosis), descending (coarctation)	Hemodynamic insult
Postsurgical	Aortic valve replacement, s/p aortic	Weakening of the anastamotic walls

HLA=human leukocyte antigen

This description is not universal, and some patients present with only mild pain, often mistaken for musculoskeletal conditions, located in the thorax, groin, or back.

The pain of aortic dissection typically is distinguished from the pain of acute myocardial infarction (AMI) by its abrupt onset.

Aortic dissection should be considered strongly in all patients reporting acute, sudden, and severe chest pain that is maximal at onset.

The truly sudden onset of chest pain is seen in few other conditions. In 1926, Spiegel and Wassermann found that acute stretching of the aortic wall produces pain.

The nervi vascularis, bundles of nerve fibers found in the aortic adventitia, are involved in the production of pain. Remember to cover the **P, Q, R, S, and T** (pain, quality, radiation, severity, and timing) of pain in all able patients. Assess the following characteristics of pain.

SEVERITY

Character

- **Timing,** including rate of onset, duration, and frequency of episodes
- **Migration,** including aggravating or alleviating factors and associated symptoms

The description of the pain may indicate where the dissection arises.

Anterior chest pain and chest pain that mimics AMI usually are associated with anterior arch or aortic root dissection. This is caused by the dissection interrupting flow to the coronary arteries, resulting in myocardial ischemia.

Pain that is described in the neck or jaw indicates that the dissection involves the aortic arch and extends into the great vessels of the arch.

Tearing or ripping pain that is felt in the intrascapular area may indicate that the dissection involves the descending aorta. The pain typically changes as the dissection evolves.

Aortic dissection is painless in about 10% of patients. Painless dissection is more common in those with neurologic complications from the dissection and those with Marfan syndrome.

Presenting signs and symptoms in acute thoracic aortic dissection include the following:

- Anterior chest pain—ascending aortic dissection
- Neck or jaw pain—aortic arch dissection
- Interscapular tearing or ripping pain; descending aortic dissection

Chest pain myocardial infarction

- Neurologic symptoms
- Syncope
- Stroke symptoms
- Altered mental status
- Limb paresthesias, pain, or weakness
- Hemiparesis or hemiplegia
- Horner syndrome
- Dyspnea
- Dysphagia
- Orthopnea
- Anxiety and premonitions of death
- Flank pain if renal artery is involved
- Dyspnea and hemoptysis if dissection ruptures into the pleura

Physical

- Blood pressure may increase or decrease. Hypertension may result from a catecholamine surge or underlying essential hypertension.

  Hypotension is an ominous finding and may be the result of excessive vagal tone, cardiac tamponade, or hypovolemia from rupture of the dissection.
- A blood pressure differential of greater than 20 mmHg was an independent predictor of aortic dissection. A pressure differential of greater than 20 mmHg should increase the suspicion of aortic dissection. Significant interarm blood pressure differentials may be found in 20% of people without aortic dissection.

Neurologic deficits are a presenting sign in up to 20% of cases.

The most common neurologic findings are syncope and altered mental status.

Syncope is part of the early course of aortic dissection in about 5% of patients and may be the result of increased vagal tone, hypovolemia, or dysrhythmia.

Other causes of syncope or altered mental status include strokes from compromised blood flow to the brain or spinal cord and ischemia from interruption of blood flow to the spinal arteries. Peripheral nerve ischemia can manifest with numbness and tingling in the extremities.

Hoarseness from recurrent laryngeal nerve compression also has been described.

Horner syndrome is caused by interruption in the cervical sympathetic ganglia and presents with ptosis, miosis, and anhidrosis.

Superior vena cava syndrome, caused by compression of the superior vena cava from a large distorted aorta, may occur.

Dyspnea may be caused by congestive heart failure or tracheal or bronchial compression.

Dysphagia from compression of the esophagus may be present.

Findings suggestive of cardiac tamponade, such as muffled heart sounds, hypotension, pulsus paradoxus, jugular venous distension, and Kussmaul sign, must be recognized quickly.

Other diagnostic clues include a new diastolic murmur, asymmetrical pulses, and asymmetrical blood pressure measurements. Pay careful attention to carotid, brachial, and femoral pulses on initial examination and look for progression of bruits or development of bruits on re-examination.

Physical findings of a hemothorax may be found if the dissection ruptures into the pleura.

Causes: Aortic dissection is more common in patients with hypertension, connective tissue disorders, congenital aortic stenosis or bicuspid aortic valve, and in those with first-degree relatives with history of thoracic dissections. These diseases affect the media of the aorta and predispose it to dissection.

Aortopathy may be due to the following heritable diseases:

- Marfan syndrome
  - Ehlers-Danlos syndrome
  - Annuloaortic ectasia
  - Familial aortic dissections
  - Adult polycystic kidney disease
  - Turner syndrome
  - Noonan syndrome
  - Osteogenesis imperfecta
  - Bicuspid aortic valve
  - Coarctation of the aorta
  - Connective tissue disorders
  - Metabolic disorders (e.g. homocystinuria, familial hypercholesterolemia)
  - Hypertension or pulsatile blood flow can propagate the dissection.
  - An estimated 50% of all cases of aortic dissection that occur in women younger than 40 years are associated with pregnancy.
- Syphilis may cause aortic dissection.
  - Crack cocaine use may precipitate aortic dissection.
  - Iatrogenic causes of aortic dissection include cardiac catheterization.

Other Problems to be Considered

Musculoskeletal chest pain

LAB STUDIES

- **Blood studies**
- Usually, the diagnosis is made before the blood work is returned; however, leukocytosis may be present.
- BUN and creatinine are elevated if the dissection involves the renal arteries.
- Troponin and creatine kinase (CK) can be elevated if the dissection has caused myocardial ischemia.
- Decreases in the hemoglobin and hematocrit are ominous findings suggesting the dissection either is leaking or has ruptured.

  Some studies suggest that **D-dimer** should be a part of the initial workup if aortic dissection is suspected. A negative result makes the presence of the disease unlikely.
- Hematuria, oliguria, and even anuria (<50 ml/d) may occur if the dissection involves the renal arteries.

IMAGING STUDIES

Chest Radiography

Findings are abnormal in 80% of patients and are more commonly abnormal in ascending aortic dissections. Findings suggesting hemothorax may be found if the dissection ruptures into the pleura (Figs 18.4 and 18.5).

Radiographic findings in acute thoracic dissection include a widened mediastinum in many cases In 2000, the international registry of acute aortic dissection published data on 464 patients that showed only 25% presenting with this finding. A widened mediastinum is sometimes difficult to identify on a portable anteroposterior (AP) radiograph. If the patient is hemodynamically stable and cooperative, an AP radiograph can be obtained at bedside. Look for a mediastinal width greater than 8 cm on AP chest radiograph.

- A tortuous aorta, common in hypertensive patients, may be hard to distinguish from a widened mediastinum. If in doubt, a good posterior-anterior radiograph is recommended.
- The differential diagnosis of a widened mediastinum includes tumor, adenopathy, lymphoma, and enlarged

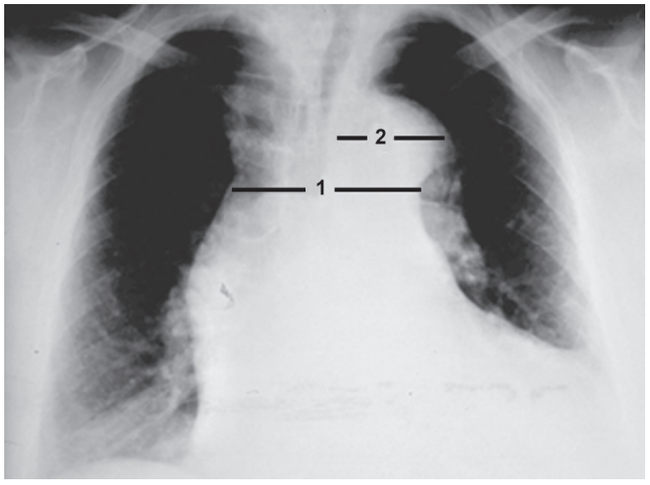

Fig. 18.4: Skiagram of chest PA view showing aortic dissection as wider diameter of aortic knob

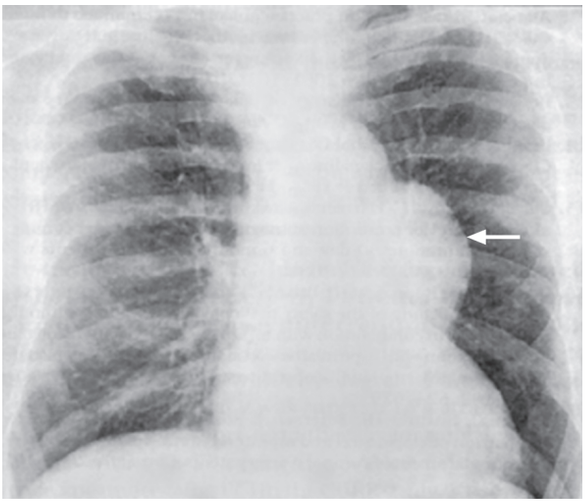

Fig. 18.5: Anteroposterior chest X-ray showing a mediastinal shadow (arrow) extending to the left beyond the cardiac silhouette, in the region of the descending thoracic aorta

thyroid. Abnormal (i.e. blunted) aortic knob was observed in 66% of patients in one study.

- **Ring sign** (displacement of the aorta >5 mm past the calcified aortic intima) is considered a specific radiographic sign. Other radiologic abnormalities seen on chest radiography include the following:

Left apical cap

- Tracheal deviation
- Depression of left main stem bronchus

Esophageal deviation

- Loss of the paratracheal stripe

The international registry for aortic dissection revealed that over 12% of the chest radiographs of patients with aortic dissection were read as normal. Several studies concluded that the overall diagnosis of aortic dissection is not determined by any one sign, rather a combination of all findings leads to suspicion of dissection.

Angiography: Still considered by some as the diagnostic criterion standard test for aortic dissection, it is being replaced by newer imaging modalities.

Angiography leads to accurate diagnosis of aortic dissection in over 95% of patients and aids the surgeon in planning the repair operation because blood vessels of the arch can be assessed easily. Benefits include visualization of the true and false lumens, intimal flap, aortic regurgitation, and coronary arteries

Drawbacks include the following: The procedure is invasive. The patient must be transported to the radiology department, leaving the ED. The use of contrast media may be harmful to patients who have renal insufficiency or an allergy to iodine. Misdiagnoses can occur if the false channel is thrombosed. In this instance, the false lumen and intimal flap may not be visualized. Possible simultaneous opacification of the true and false lumens may make discerning the presence of a dissection difficult.

Computed Tomography Scanning

The accepted diagnostic criterion standard, angiography, is being challenged by state-of-the-art CT angiography. With the advent of helical CT with multiplanar and 3D reconstruction and CT angiography, CT scanning is quickly replacing angiography as the diagnostic test of choice in many institutions.Prospective studies have shown a sensitivity of 83–94% with a specificity of 87–100% (Figs 18.6–18.9).

Spiral CT scanning is associated with a higher rate of detection and better resolution than incremental CT scanning. High-quality 2D and 3D reconstructions are possible with spiral CT scanning, which greatly adds to the usefulness of this imaging modality.

More importantly, imaging information, including the type of lesion, location of the pathologic lesion, extent of the disease, and evaluation of the true and false lumen can be assessed quickly and help the surgeon plan the operation.

- This information helps determine if hypothermic circulatory arrest is necessary for surgery; this procedure increases the complexity, length, morbidity, and mortality associated with surgery.
- Faster scanners have decreased the acquisition time to the range of a breath hold, resulting in less motion artifact from breathing.

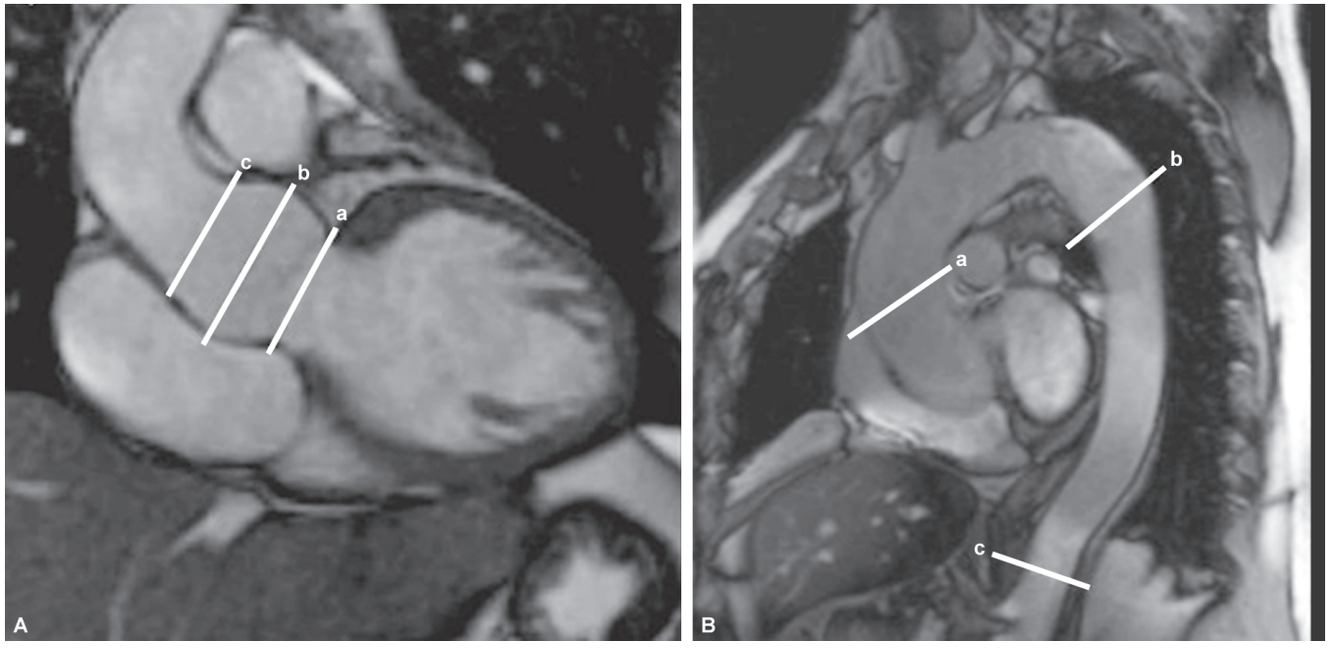

Fig. 18.6: (A) Coronal slice of the aortic root in which the following can be observed—(a) aortic ring; (b) sinuses of Valsalva; and (c) sinotubular junction. (B) oblique sagittal slice of the aorta in which the following are observed—(a) ascending aorta; (b) descending aorta, and (c) abdominal aorta

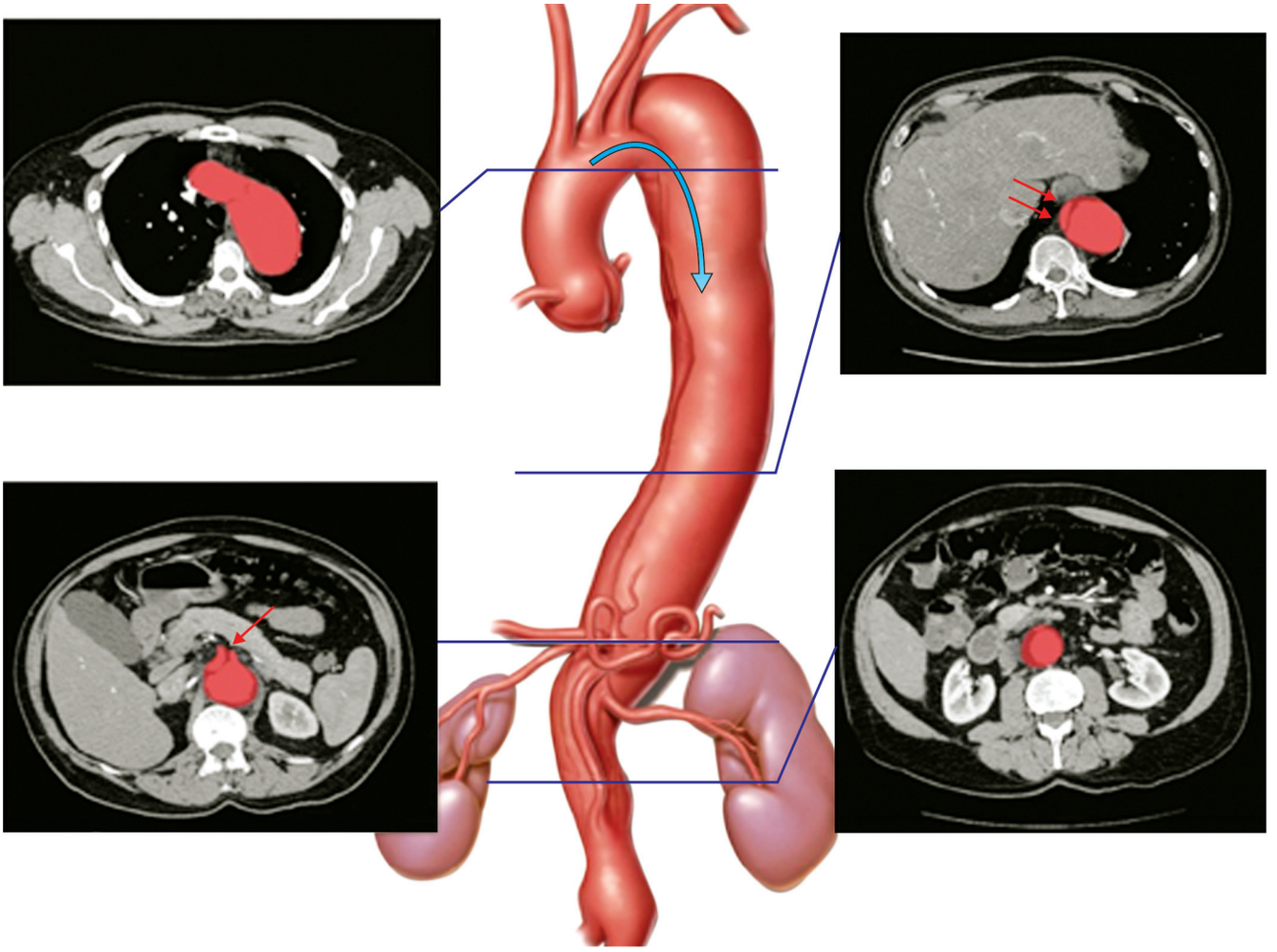

Fig. 18.7: Preoperative anatomy. Illustration and sections from a computed tomography scan showing the patient's thoracoabdominal aortic aneurysm, which was associated with chronic aortic dissection. Note the narrow true lumen (double arrows) and the extension of the dissection into the celiac axis (single white arrow). The aneurysm begins to taper in the infrarenal region

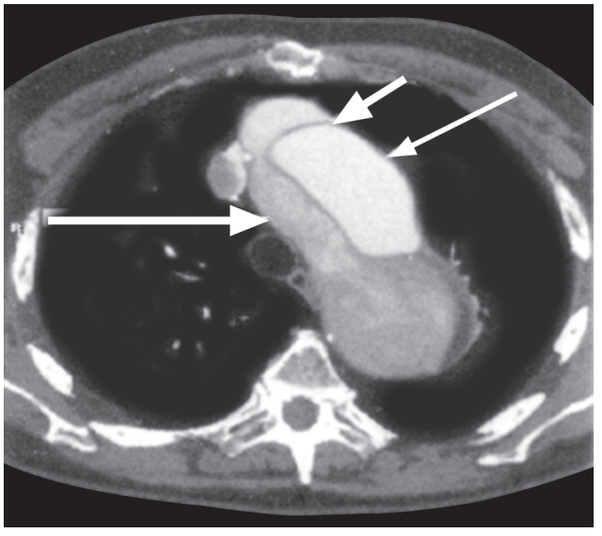

Fig. 18.8: MDCT axial planar view. Dissection flap (arrowhead) separating true lumen (short arrow) and false lumen (long arrow)

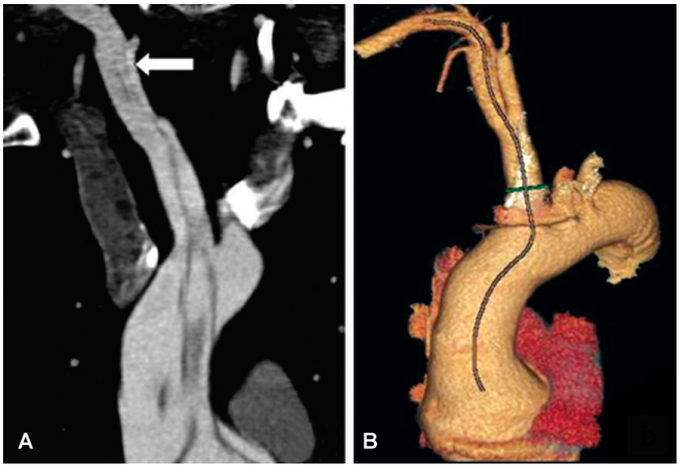

Fig. 18.9: (A) Contrast-enhanced CT scan showing the intimal flap due to dissection from the aortic root to the ascending aorta, innominate artery and subclavian artery. (B) Enhanced reconstructed CT scan image showing the path of dissection

- **Drawbacks include the following:**
  - Transportation of a patient in potentially unstable condition from the ED, even for the relatively short time needed for this procedure, places the patient at risk.
  - CT angiography requires the injection of iodinated contrast.
  - The use of contrast material may harm a patient who has impaired renal function or an allergy to contrast media.
  - CT scanning provides no information on aortic regurgitation.

Magnetic Resonance Imaging (Figs 18.10 and 18.11)

- MRI has over 90% sensitivity and greater than 95% specificity. It is the most sensitive method for diagnosing aortic dissection and has similar specificity to CT scanning.
- MRI shows the site of intimal tear, type and extent of dissection, and presence of aortic insufficiency, as well as the surrounding mediastinal structures.
- Other benefits are that MRI requires no contrast medium and no ionizing radiation. It is the preferred modality for patients with renal failure and those with an allergy to iodine.
- Contrast-enhanced magnetic resonance angiography (CE-MRA) is a principle technique for evaluating the thoracic aorta.
- MRI is the preferred tool for imaging chronic dissections and postsurgical follow-up.
- Contrast 3D MRA is an accurate noninvasive imaging modality. It has the advantage of being able to evaluate the aortic valve more effectively than CT angiography.

Drawbacks include the following: MRI is not readily available at most institutions, requiring transportation of patients in unstable condition away from the ED. MRI requires much more time to acquire images than CT scanning.

Patients with permanent pacemakers cannot undergo MRI. Most patients with prosthetic heart valves or coronary stents can safely have an MRI.

- **Echocardiography** (Figs 18.12–18.23)
- With its increasing acceptance and use in the ED, ultrasonography is becoming a valuable diagnostic aid, although transthoracic echocardiography (TTE) has a much lower sensitivity (80%) and lower specificity (90%) than angiography.
- TTE is most useful in ascending aortic dissections, especially those closest to the aortic root and within a few centimeters of the aortic valve. Sensitivity is highest in this location.
- Echocardiography also is useful in diagnosing cardiac tamponade and aortic regurgitation.
- Benefits include its rapid simple bedside use in the ED and its noninvasive nature.
- Drawbacks include the lack of sensitivity and specificity, especially with arch and descending aortic dissections, and dependence on operator experience.

Transesophageal echocardiography (TEE) has greater sensitivity and specificity than TTE (in the range of 97–99% and 97–100%, respectively).

- Advantages include its quick and easy bedside use in the ED, which makes it ideal for patients in unstable condition. TEE detects involvement of the coronary arteries, aortic insufficiency, and cardiac tamponade.
- It is a relatively quick study to perform and relatively noninvasive. The main drawback of TEE is its strong dependence on operator experience.
- Other drawbacks are that false-positive results can occur from reverberations in the ascending aorta and that the



Fig. 18.10: MDCT MPR. Complex type A dissection flap (arrow)

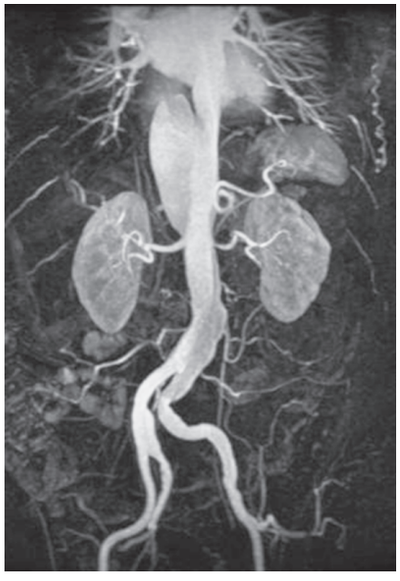

Fig. 18.11: MRI (MRA) AP MIP stanford type B thoracoabdominal dissecting aneurysm

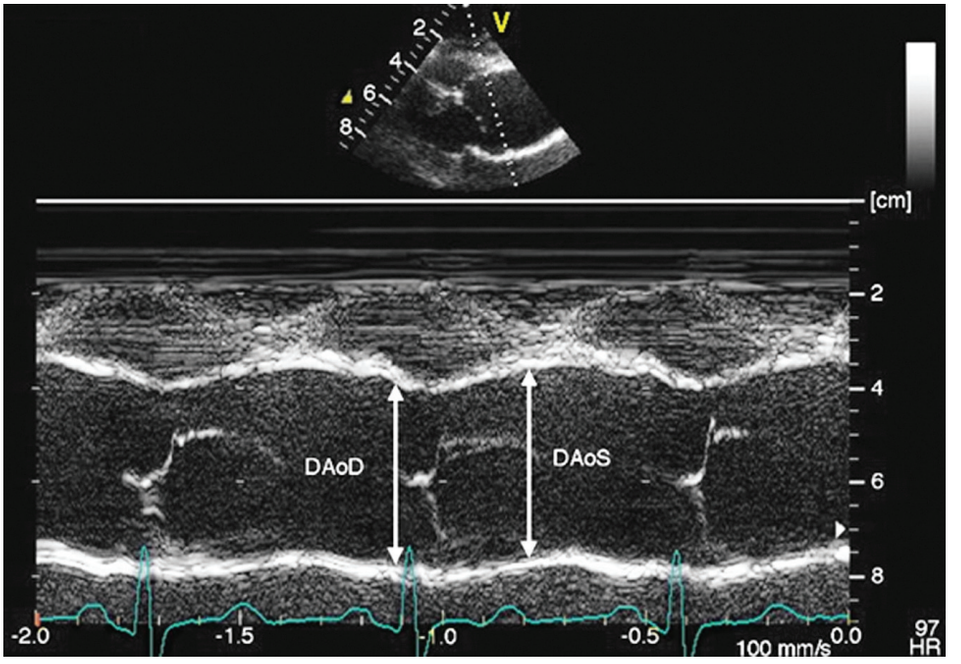

Fig. 18.12: Measurement of aortic diameters using M-mode ultrasound in the aortic sinuses of Valsalva in systolic and diastolic phases. DAoD, diameter of the aorta in diastole; DAoS, diameter of the aorta in systole

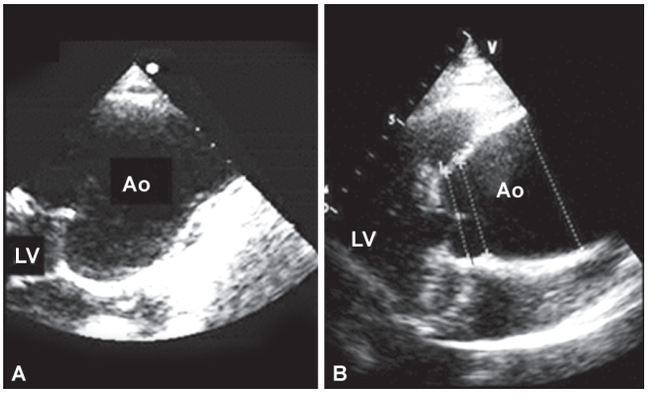

Fig. 18.13: Parasternal long-axis view by transthoracic echocardiography. (A) Annuloaortic ectasia with pyriform morphology. (B) Ascending aorta aneurysm located in the upper part of the sinotubular junction

upper ascending aorta and arch may not be visualized well, leading to false-negative results.

- TEE cannot be performed in patients with esophageal varicosities or stenosis. If the findings are negative and clinical suspicion remains high, a second diagnostic test is recommended.

Other Tests

Electrocardiogram: All patients with suspected thoracic aortic dissection should have an ECG.

- In acute thoracic dissection, ECG can mimic the changes seen in acute cardiac ischemia. In the presence of chest pain, these signs can make distinguishing dissection from AMI very difficult. Keep this in mind when administering thrombolytics to patients with chest pain.
- ST-elevation can be seen in Stanford type A dissections because the dissection interrupts blood flow to the coronary arteries.
- The incidence of abnormal ECG findings is greater in Stanford type A dissections than in other types of dissections.
- In one study, 8% of patients with type A dissections had ST-elevation, while no patients with type B dissections had ST-elevation.
- More commonly, the ECG abnormality is ST-depression.
- If the dissection involves the coronary ostia, it is the right coronary artery that is most commonly involved, leading to inferior ST-segment elevation pattern.

MANAGEMENT

Medical therapy: Initiate medical therapy as soon as the diagnosis is considered. The goal is to decrease the blood pressure and the shearing forces of myocardial contractility in order to decrease the intimal tear and propagation of the dissection.

Admit the patient to the intensive care unit or coronary care unit for hemodynamic studies, as follows:

- Arterial blood pressure monitoring with an arterial line

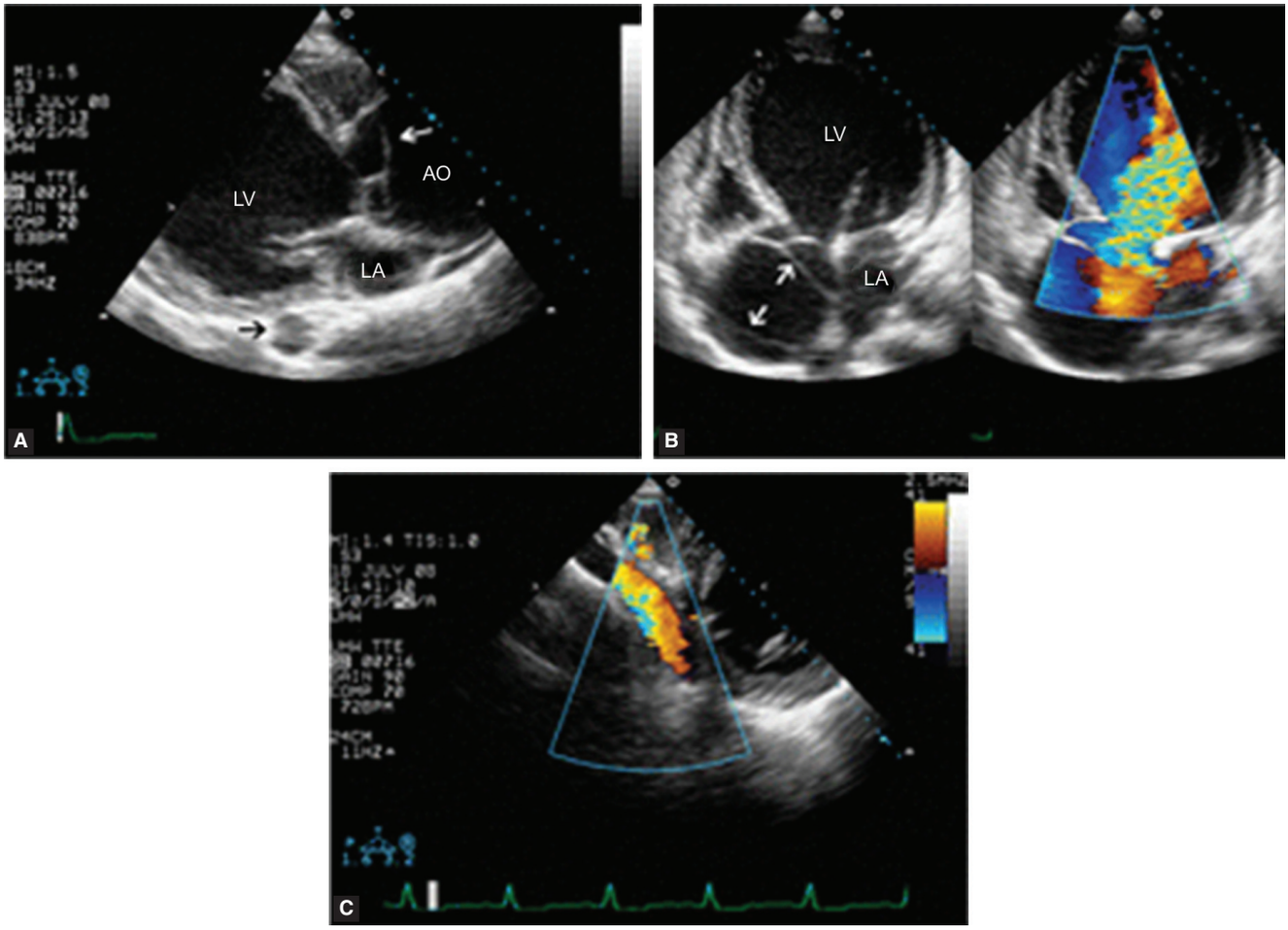

Fig. 18.14: Transthoracic echocardiography in a patient with Marfan's syndrome and type A dissection. (A) Parasternal long-axis view. There is severe dilatation of the aorta and a linear echo is seen just above the aortic valve (white arrow). Note the normal caliber and appearance of the descending thoracic aorta, posterior to the left atrium (black arrow). LV=left ventricle; LA=left atrium; AO=aorta, (B) Apical five-chamber view. The dilated aortic root, with two reflections of the intimal flap, (white arrows) is seen. Severe aortic regurgitation (right panel) is seen with color flow mapping, (C) Subcostal view. Normal caliber, no dissection flap and normal flow are seen

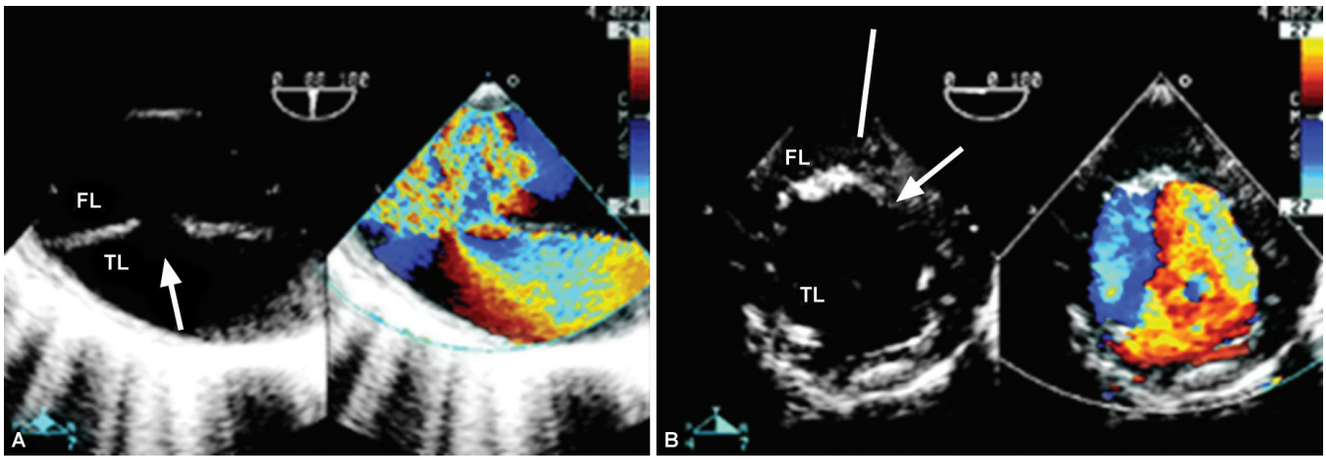

Fig. 18.15: A 53-year-old male, 5 weeks after acute thoracic pain and diagnosis of aortic type-B dissection. (A) long axis view of the entry site of a type-B aortic dissection in 2D and color-Doppler TEE before stent-graft implantation. Arrow marks the entry. TL=true lumen; FL=false lumen. (B) post-stent-graft implantation. Arrow indicates the bright echo of the stent graft; white line points to the beginning formation of clot in the false lumen

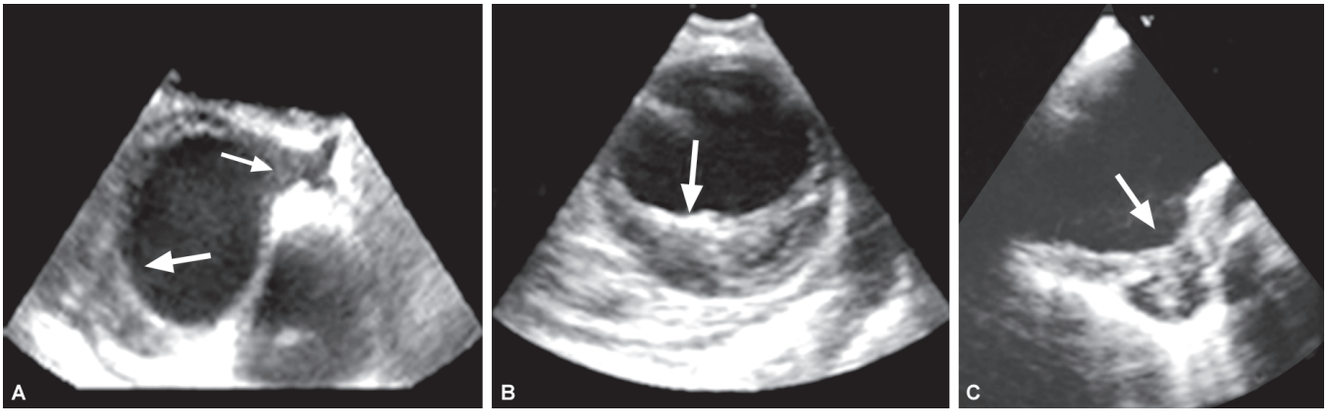

Fig. 18.16: Transoesophageal echocardiography. (A) Crescentic intramural hematoma in ascending aorta (large arrow) adjacent to the left main coronary ostium (small arrow). (B) Intramural hematoma in descending aorta. Arrow shows intima calcification. (C) Penetrating aortic ulcer deforming the adventitia (arrow)

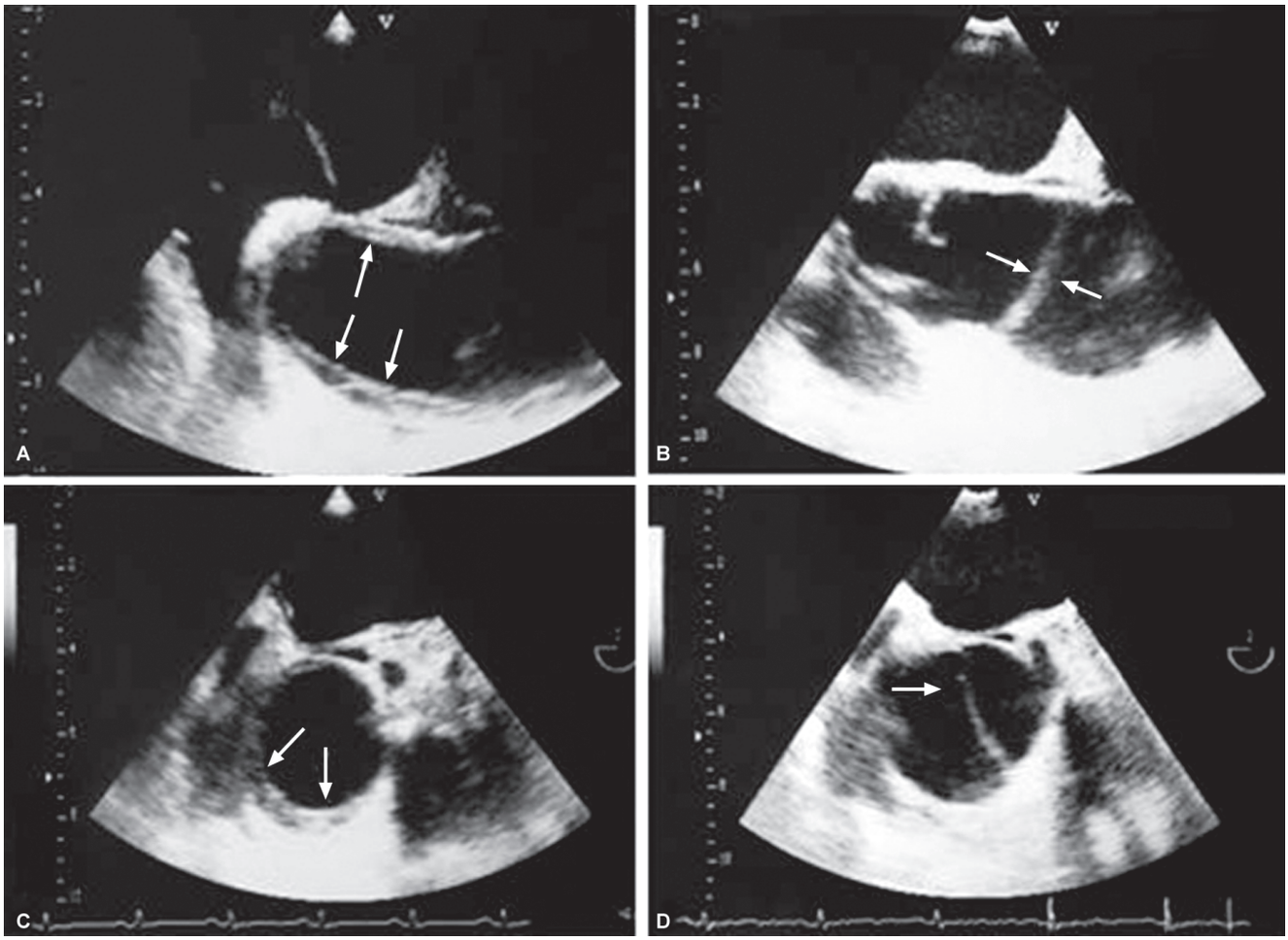

Fig. 18.17: Transesophageal echocardiography visualizing the ascending aorta in the longitudinal (A and B) and transverse (C and D) planes. Intramural hematoma (A) in the ascending aorta (arrows) evolving into dissection at 3 months (B). The arrows indicate the intimal dissection

- Central venous pressure monitoring with a central catheter
- Cardiac performance and filling pressures with Swan-Ganz catheterization
- Urine output monitoring with a Foley catheter and bag.

Initiate therapy to reduce cardiac contractility. Administer drugs with negative inotropic effects, such as beta-blockers (the agents of choice); administer calcium channel blockers if beta-blockers are contraindicated. The following beta-blockers are commonly used:

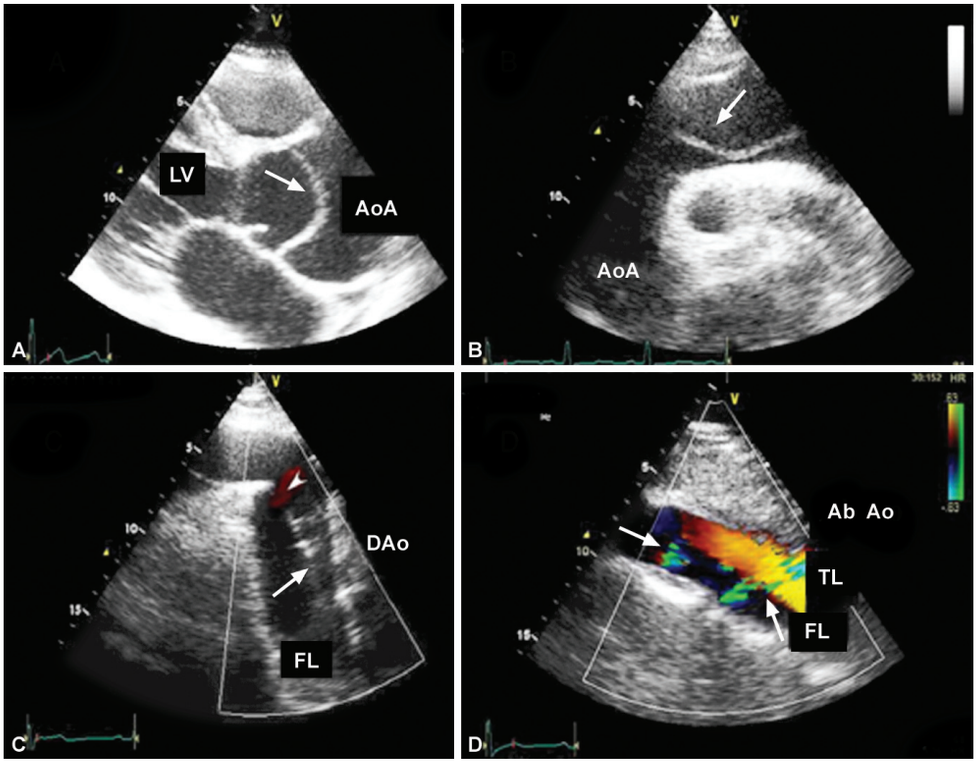

Fig. 18.18: Aortic dissection diagnosis by transthoracic echocardiography. Intimal flap (arrows) and two lumina are visualized in—(A) aortic root, (B) aortic arch and distal ascending aorta, (C) proximal descending aorta (arrowhead shows the entry tear), and (D) dissection of abdominal aorta. Color-Doppler helps to identify the true lumen (TL). Arrowheads signal secondary communications

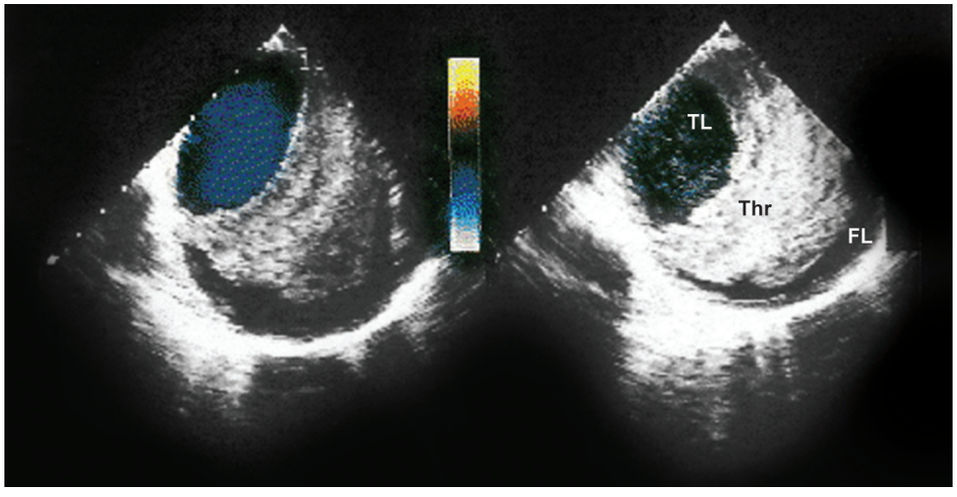

Fig. 18.19: Dissection of the ascending thoracic aorta. A dissecting aneurysm of the ascending segment of the thoracic aorta was diagnosed by two-dimensional transesophageal echocardiography. The horizontal imaging plane is approximately 3 cm above the aortic valve and shows a separation of the true lumen (TL) and the false lumen (FL) of the dissecting aneurysm. A color-coded flow signal in blue identifies flow away from the aortic valve in the true lumen. An echogenic crescent-shaped thrombus (Thr) almost completely fills the false lumen and leaves only a narrow unobstructed mural rim. Two images, taken at slightly different gray-scale gain settings, are shown side by side; the lower setting in the image on the left allows better visualization of the color-coded flow signal. Blue denotes flow away from and red or yellow flow toward the transducer

- Intravenous or oral labetalol
- Intravenous or oral propranolol
- Intravenous or oral esmolol

Initiate therapy to reduce systemic arterial pressure and shear stress if the patient's blood pressure allows for this type of intervention. The following agents are commonly used.

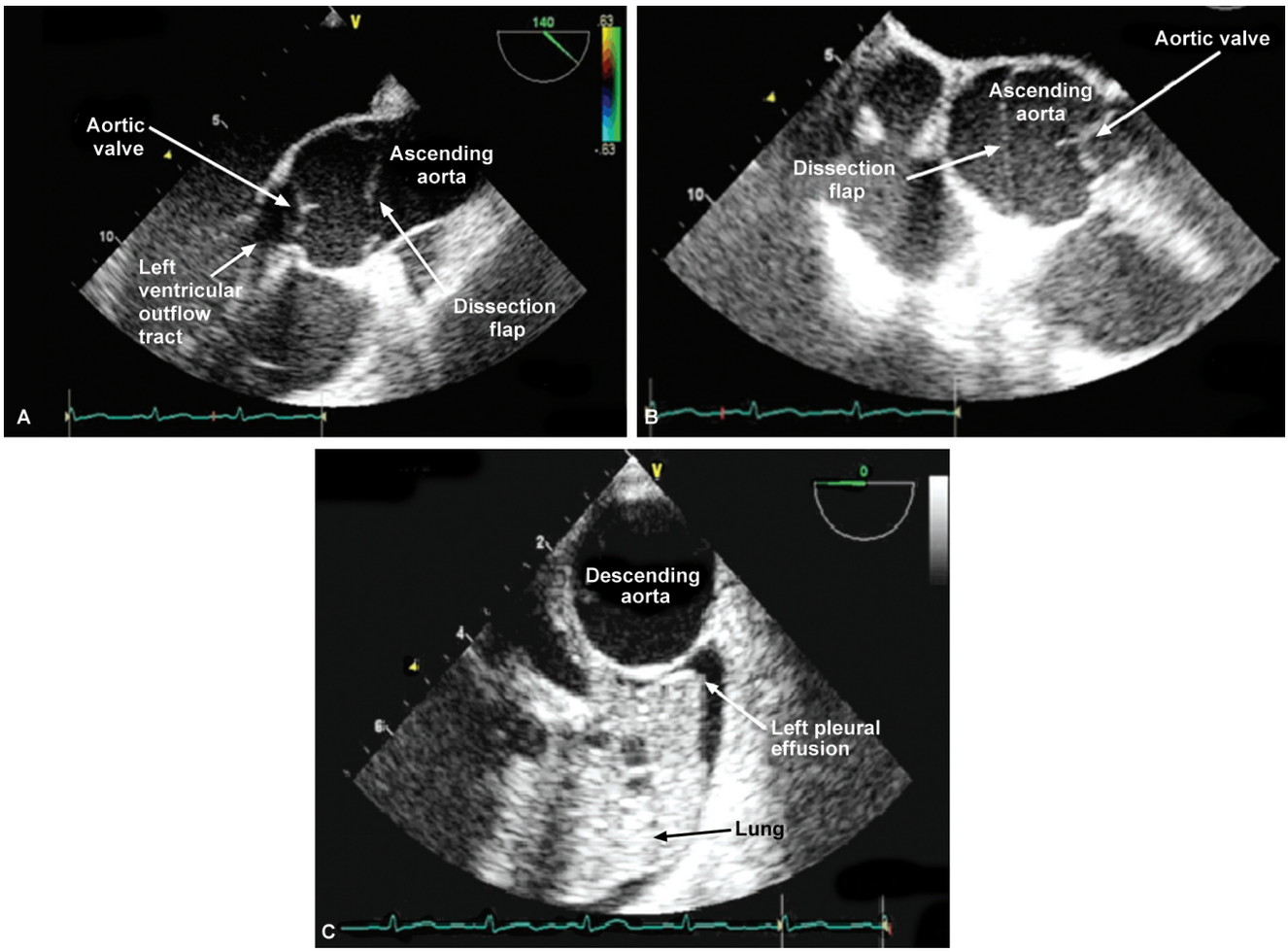

Fig. 18.20: (A, B and C) The TEE confirmed a 5.5 cm aortic aneurysm with a dissection flap in the sinuses of Valsalva extending distally to the sinotubular junction. The dissection did not involve the coronary arteries, but did extend into the aortic arch and further into the thoracic aorta. There was minimal aortic insufficiency but a left pleural effusion (assumed to be a hemothorax) was present. It was also noted that the aortic arch and descending aorta were dilated and aneurismal

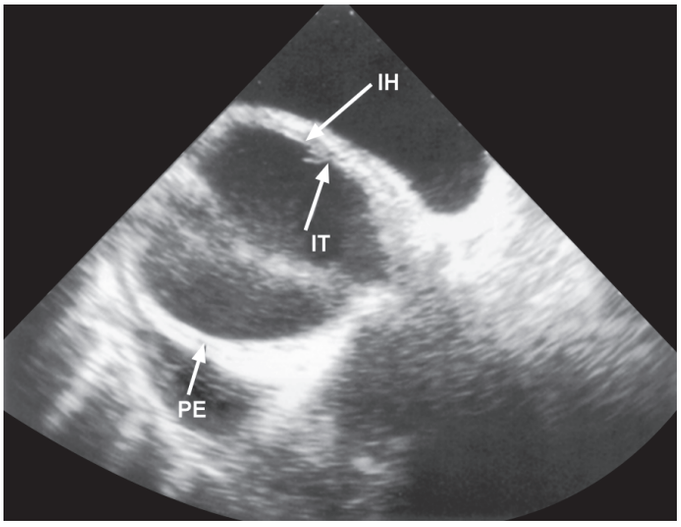

Fig. 18.21: TEE imaging shows subtle typical signs of discrete dissection of the proximal ascending aorta

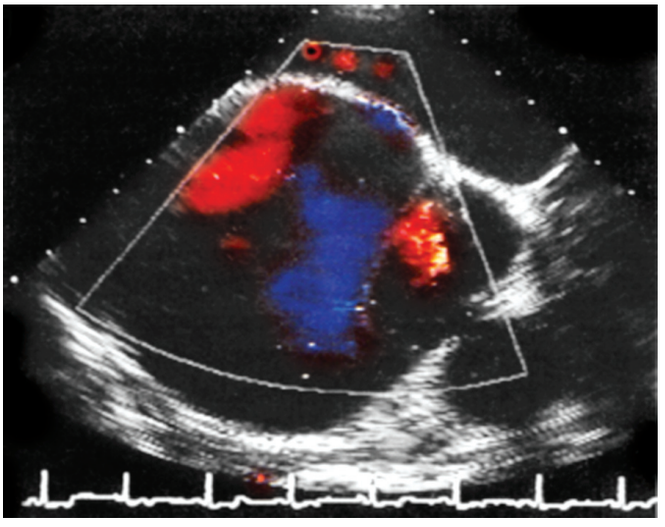

Fig. 18.22: TEE scan showing dissection of ascending aorta in patient with hypertension admitted in emergency department with acute chest pain

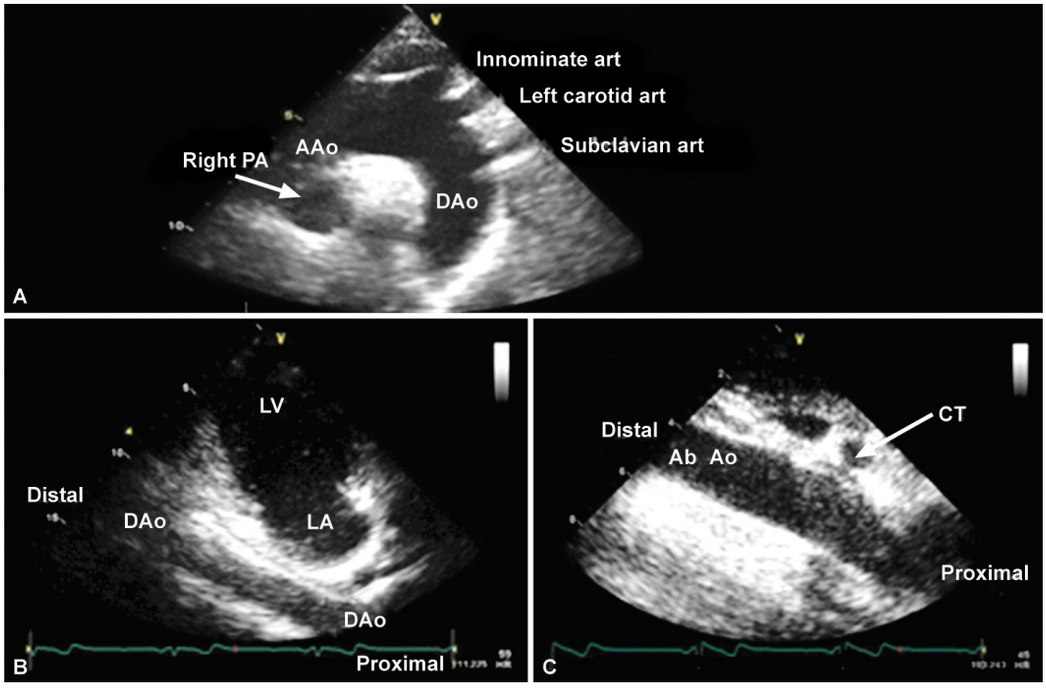

Fig. 18.23: (A) Suprasternal view of aortic arch and supraaortic great arteries. (B) Mid part of the descending thoracic aorta visualized by long-axis view from apical window, (C) Abdominal aorta visualized by subcostal view. In nonobese patients, it is not difficult to visualize distal abdominal aorta. (art=artery; PA= pulmonary artery; AAo=ascending aorta; DAo=descending aorta; CT=coeliac trunk)

- Intravenous nitroprusside drip
- Intravenous labetalol has a dual effect by decreasing blood pressure and cardiac contractility alcium channel blockers (e.g. diltiazem) lower blood pressure and cardiac contractility.

The following conditions contraindicate beta-blocker therapy:

- Hypersensitivity to drug/class
- Severe asthma

Heart block uncompensated heart failure, bradycardia (heart rate <60 beats/min), severe chronic obstructive pulmonary disease, and hypotension.

The following conditions contraindicate calcium channel blocker therapy:

- Hypersensitivity to drug/class
- Second- or third-degree atrioventricular block, sick sinus syndrome, and hypotension
- Left ventricular dysfunction
- Pulmonary congestion

The following conditions contraindicate nitroprusside infusion:

- Hypersensitivity to drug/class
- Poor cerebral perfusion
- Poor coronary perfusion

Pain management is always difficult in persons with aortic dissection. Narcotics and opiates are the preferred agents. Medical therapy is also administered to surgical patients preoperatively, intraoperatively, and postoperatively to prevent progression or recurrence of aortic dissection.

Surgical therapy: The major objectives of surgery for aortic dissection are to alleviate the symptoms, decrease the frequency of complications, prevent aortic rupture and death. Improved cardiopulmonary bypass circuits have decreased the prevalence of injury to blood elements. A decrease in complications such as brain injury has resulted from a more detailed understanding of the physiology and limitations of hypothermic circulatory arrest (Figs 18.24–18.28) (Table 18.2).

Aortic arch repair and reconstruction can be partial or complete. A number of advances have resulted in a decreased frequency of complications associated with surgery on the aorta. Dacron grafts with impregnated collagen or gelatin have been developed that are impervious to blood. Adjunct procedures, including distal aortic perfusion, profound hypothermia, cerebrospinal fluid drainage, and monitoring of somatosensory and motor evoked potentials in the brain and spinal cord, have decreased the frequency of procedure-related spinal cord injury during descending aorta and thoracoabdominal surgeries. Percutaneous fenestrations and stent placements are peformed. The area of the aorta with the intimal tear is usually resected and replaced with a Dacron graft. The operative mortality rate is usually less than 10%; serious complications are rare with ascending aortic dissections. The development of more impermeable grafts, such as

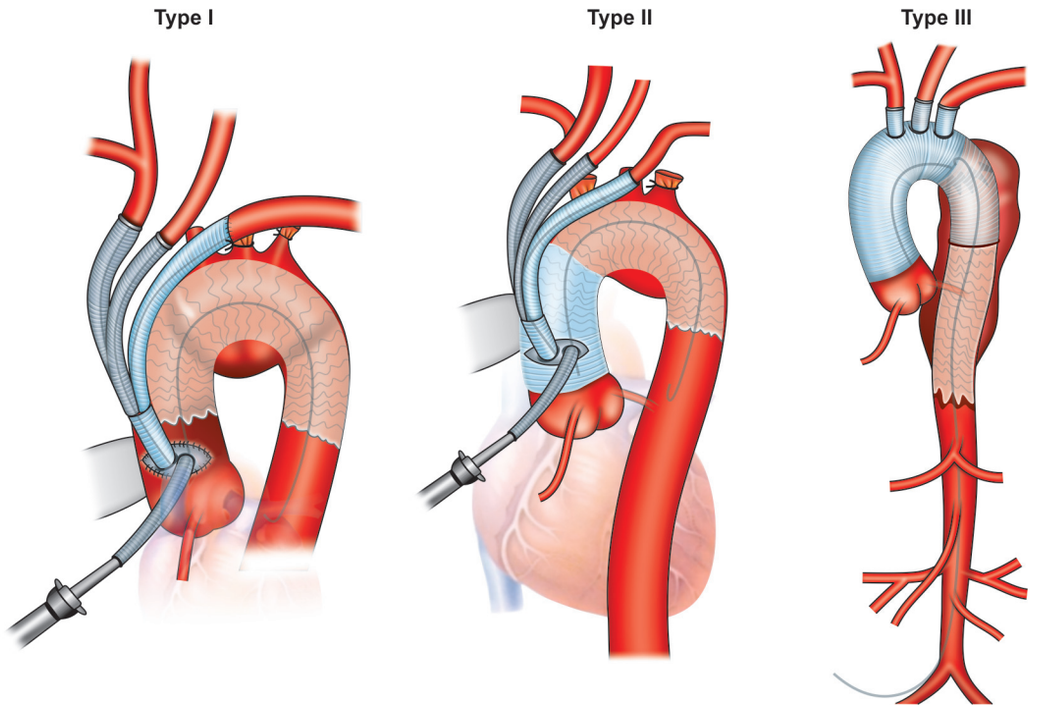

Fig. 18.24: Hybrid aortic arch repair. Types I, II and III

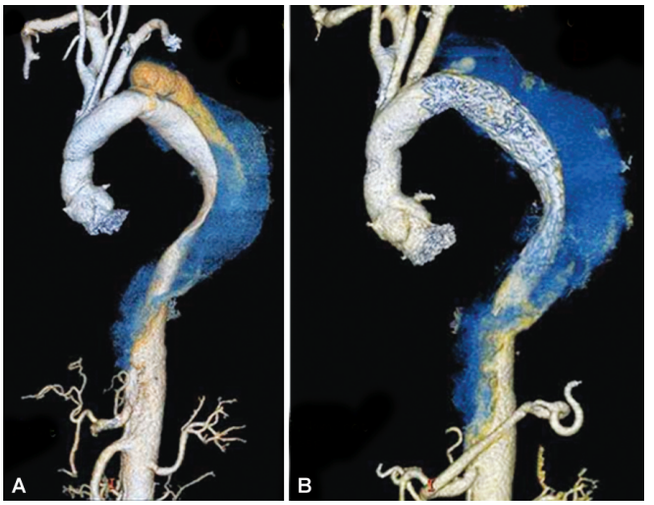

Fig. 18.25: (A) Preoperative three-dimensional reconstruction of computed tomography scan of the chest in a patient with a 5 cm aneurysm of the descending thoracic aorta associated with a chronic type B aortic dissection. (B) Postoperative three-dimensional computed tomography scan of the chest following endovascular repair of a 5 cm aneurysm of the descending thoracic aorta associated with a chronic type B aortic dissection which demonstrates a proximal type I endoleak and a small retrograde type I endoleak in the false lumen

woven Dacron, collagen-impregnated Hemashield (Meadox Medicals; Oakland, NJ), aortic grafts, and gel-coated Carbo-Seal Ascending Aortic Prothesis (Sulzer CarboMedics; Autin, Tex), has greatly enhanced the surgical repair of thoracic aortic dissections. Morbidity and mortality rates associated with this highly invasive surgery have decreased with the introduction of profound hypothermic circulatory arrest and retrograde cerebral perfusion.

Dissections involving the arch are more complicated than those involving only the ascending aorta because the innominate, carotid, and subclavian vessels branch from the arch. Deep hypothermic arrest is usually required. If the arrest time is less than 45 minutes, the rate of central nervous system complications is less than 10%.

Retrograde cerebral perfusion may improve the protection of the CNS during the arrest period. The mortality rate associated with aortic arch dissections is approximately 10–15%, with significant neurologic complications occurring in an additional 10% of patients.

Preoperative details: A number of factors may increase mortality and morbidity rates for surgical intervention on the aorta, including a history of myocardial infarction, respiratory failure, renal failure, and/or stroke.

Preoperative evaluation is therefore essential in patients with these histories. Because aortic dissection is more common in elderly patients (i.e. aged 70–80 years), this group of patients has different comorbidities.

Patients older than 50 years have a high prevalence of atherosclerotic heart disease and may require a thorough cardiac workup. Symptoms of aortic dissection are always difficult to differentiate from those of myocardial infarction.

Patients with ECG changes suggestive of myocardial infarction or ischemia undergo workups with emergency cardiac catheterization and angiography, followed by

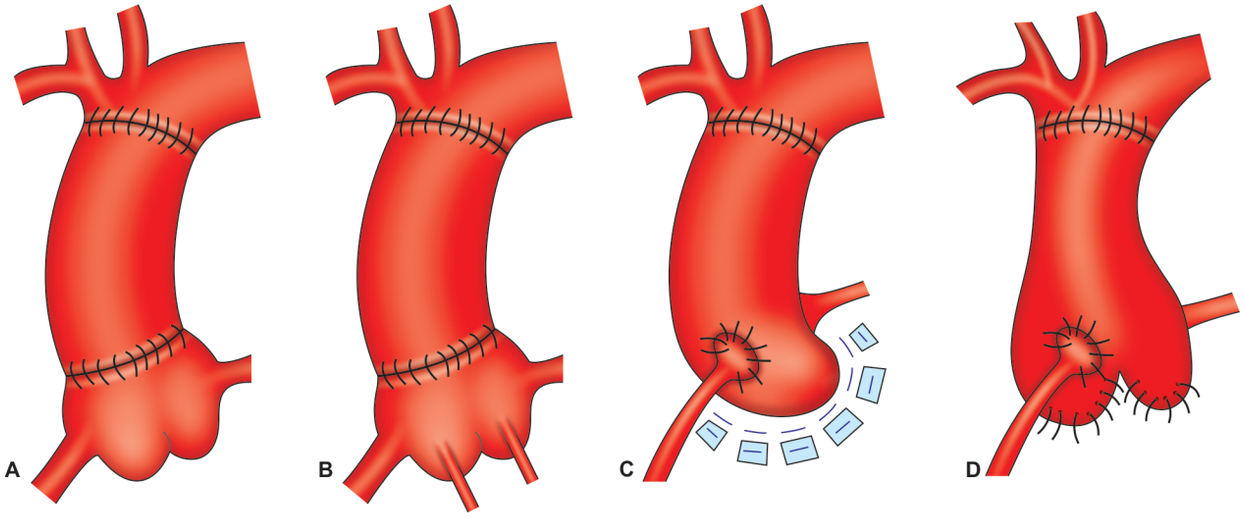

Fig. 18.26: Operations for aortic dissection or ascending aortic replacement. (A) Simple tube replacement of the aorta for the sinotubular junction to the brachiocephalic origin. (B) Tube graft replacement and aortic valve replacement as separate components of the operation. (C) Composite graft replacement. (D) Leaflet sparing aortic root replacement

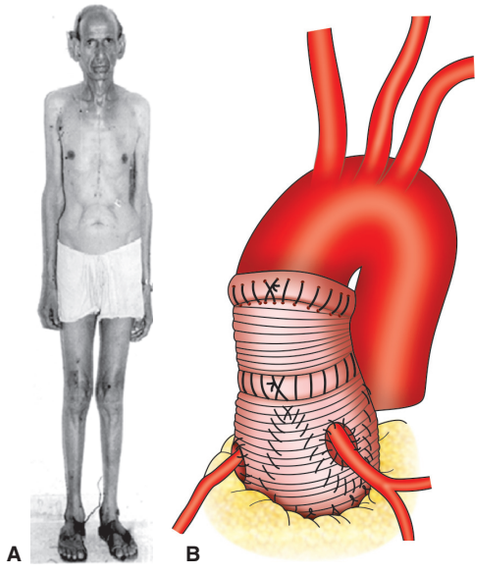

Fig. 18.27: (A) Middle-aged patient operated for annuloaortic ectasia in Marfan syndrome (see midsternal scar). (B) Valve-sparing aortic root repair

percutaneous transluminal coronary angioplasty or coronary artery bypass grafting concomitant with aortic repair or construction.

Patients with valvular heart disease undergo workups with echocardiography or coronary angiography. If any valvular abnormalities are found, then appropriate surgical correction (valve replacement or commissurotomy) is performed prior to or simultaneous with aortic repair.

Surgeries involving the descending or thoracoabdominal aorta require a lateral thoracotomy. A history of smoking or chronic obstructive pulmonary disease is of significant concern; perform pulmonary function testing on such patients. Additionally, arterial blood gas testing may be required. In elective cases, treat reversible restrictive diseases and excessive sputum production with antibiotics and bronchodilators.

Preoperative renal dysfunction is considered the most important predictor of postoperative acute renal failure (ARF). Preoperative management involves adequate hydration and avoidance of hypotension, a low cardiac output state, and hypovolemia in order to decrease the frequency of ARF.

Table 18.2: Surgical versus medical therapy for aortic dissection

Medical therapy	Surgical therapy
Uncomplicated type III dissection	Acute: Type I or II dissection
Stable: Lone arch dissection	Acute: Complicated type III dissection End-organ dystunction Rupture/impending rupture Aortic insufficiency Associated with Marfan syndrome Retrograde extension into the ascending aorta
Stable: Chronic dissection (more than 2 weeks after onset of symptoms)	

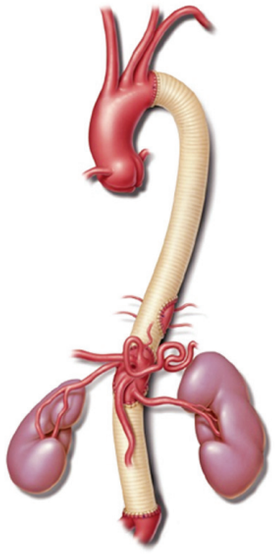

Fig. 18.28: Completed aortic reconstruction. The completed extent II repair. Note the proximal anastomosis located just distal to the left subclavian artery; the intercostal patch incorporating two pairs of intercostal arteries; the single visceral patch incorporating the celiac axis, superior mesenteric artery, and both renal arteries; and the distal anastomosis at the aortic bifurcation

Perform appropriate workups for patients presenting with any neurological signs suggestive of CNS pathology (e.g. stroke). This usually consists of Doppler imaging of the carotid arteries and, if needed, angiography of brachiocephalic and intracranial arteries. If the study findings are positive, perform a carotid endarterectomy before the aortic surgery.

Intraoperative details: The objectives of surgical therapy for aortic dissection are to resect the damaged segment, excise the intimal tear, and obliterate the entry into in the false lumen. Suturing the edges of the dissected aorta both proximally and distally obliterates the entry into the false lumen. The desirability of obliterating the entrance to the false lumen is controversial because of multiple portals. Aortic continuity after dissection of a diseased segment is reestablished by means of a prosthetic sleeve graft between the two ends of the aorta.

Patients with type A dissections are treated with immediate surgical correction. This involves transfer to the operating room, where median sternotomy is performed. Profound hypothermia is initiated after the patient is placed on cardiopulmonary bypass. Cardiopulmonary bypass is performed by femoral-femoral cannulation and through the superior vena cava for retrograde cerebral perfusion. Myocardial temperature is kept below 15°C (59°F) by cardioplegic perfusion via the coronary sinus. This provides myocardial protection throughout the procedure.

Ventricular distension is avoided by decompressing the left ventricle by venting through the left superior pulmonary vein or artery. The pump is stopped when the electroencephalogram is isoelectric and the nasopharyngeal temperature reaches 12°C (53.6°F). Retrograde cerebral perfusion is then started via the superior vena cava.

The ascending aorta is inspected for the site and extent of the tear and the involvement of the transverse arch and for an assessment of intimal disruption that requires repair. Through a longitudinal approach, the ascending aorta is opened and transected just proximal to the innominate artery. If the transverse arch is free of reentry, the intima and adventitia are sutured together with fine 4–0 and 5–0 polypropylene suture. A gelatin-or collagen-woven Dacron graft is sutured to the reinforced proximal aortic arch in end-to-end fashion and reinforced from both inside and outside with 4–0 pledgeted sutures.

At the time of completion of the distal anastomosis, retrograde cerebral perfusion is stopped and cardiopulmonary bypass is restarted via the femoral artery. This evacuates all air and debris from the brachiocephalic vessels. The graft is clamped proximal to the origin of the innominate artery. Flow to the cerebral and systemic circulation is restored after clamping the graft proximal to the origin of the innominate artery.

Hypothermic circulatory arrest is a valuable tool in aortic dissection repair. Emptying the major vessels allows ingress of air, which causes complications related to air embolism, a major hazard associated with this procedure. Ensure that the patient's head is not elevated; rather, depress it and allow blood to gravitate into the head vessels, thus displacing the air (upward) to the periphery. This is essential.

The patient is rewarmed with restoration of anterograde flow through a side arm line inserted in the ascending aorta. The aortic valve is suspended with 4–0 polypropylene pledgeted sutures if it is normal and no evidence of aortic root dilatation is present. The intima and adventitia of the aorta superior to the coronaries are sutured together and reinforced from inside the graft. If the aortic valve or the root is dilatated, a composite valve graft is placed.

A button or modified Cabrol technique is used to reattach the coronaries. When aortic regurgitation is present, simple decompression of the false lumen may be all that is required to allow resuspension of the aortic leaflets and restoration of valvular competence. More often, however, the two layers of the dissected aortic wall are approximated, and resuspension of the commissures is accomplished with pledgeted sutures. Prosthetic aortic valve replacement also may be necessary in certain situations. After the procedure is completed and the patient is brought to sinus rhythm by defibrillation, the patient is weaned from cardiopulmonary bypass. In patients with involvement of the transverse aortic arch, either the proximal arch or the total arch is replaced. If the intima is fragmented or shows evidence of rupture, then the whole arch is replaced.

Surgical management of acute type B aortic dissections is undertaken only in the presence of indications such as persistent pain, aneurysmal dilatation greater than 5 cm, end organ or limb ischemia, or evidence of retrograde

dissection to the ascending aorta. The remaining patients are treated with intense medical therapy.

The operation involves transection of the proximal descending aorta distal to the left subclavian artery. Similar to operation on the ascending aorta, the proximal and distal intima and adventitia of the transected aorta are reinforced in the same manner as that for the ascending aorta, with a 4–0 polypropylene suture. A gelatin-or collagen-woven Dacron graft is sewn directly to the reinforced acutely dissected proximal thoracic aorta, with the posterior row reinforced using interrupted polypropylene sutures. Blood is rechanneled into the true lumen of the distal aorta by cutting the descending thoracic graft and suturing it to the reinforced distal aorta.

Adjunct procedures are used to minimize complications. The entire thoracoabdominal aorta is opened if extensive involvement of the descending and abdominal aorta is present that requires replacement. The septum between the false and true lumen is excised, and the visceral vessels and renal arteries are reattached to the graft directly or via a Dacron graft.

In chronic dissections, the intercostal arteries (T9–T12) are reimplanted by side graft or a side hole. This is in contrast to acute dissections, in which the intercostals and lumbar arteries are ligated. Newer surgical techniques have been developed that use fibrin sealant or gelatin-resorcin-formaldehyde glue. Glue replaces the use of pledgeted sutures to seal the false lumen of the aortic stumps after resection of the diseased aortic segment and before the implantation of the Dacron prosthesis. The glue hardens and reinforces the dissected aortic tissue. Other advantages include simplification of the operation, facilitation of the resuspension of the aortic valve, and, possibly, reduction in the frequency of late aortic root aneurysm formation.

Because of high operative mortality rates in people with renal or visceral artery compromise from dissection, endovascular techniques are under investigation. Several endovascular techniques are available. One involves the formation of a site of reentry to allow blood to pass from the false lumen to the true lumen. This requires passing a wire past the intact intimal flap, passing a balloon-tipped catheter over the wire, and tearing a hole in the intimal flap by inflating the balloon. Another technique involves percutaneous stenting to decrease the ischemic complications of aortic dissection. This is performed on arteries that have compromised flow from the dissection. Sutureless intraluminal prostheses placed during cardiopulmonary bypass are also being used. Another technique involves **percutaneously placed intraluminal stent-grafts using a transfemoral catheter technique**. This procedure results in the closure of the site of entry into the false lumen and decompresses and promotes thrombosis of the false lumen. It also alleviates obstruction of the branch vessels complicating a dissection.

Intramural hematomas and penetrating atherosclerotic ulcers of the aorta are conditions that result in aortic dissection or rupture. Both are more common in the descending aorta; medical therapy is the first-line treatment. When either affects the ascending aorta or the arch, the need for surgery is more likely. Intramural hematomas are hemorrhage into the medial layer of the aortic wall without an intimal tear. Because these hematomas have a natural history similar to aortic dissection and aneurysm, they are treated similarly.

Surgical therapy is initiated for patients with proximal hematomas; medical therapy is reserved for patients with distal hematomas. Medical therapy consists of optimizing blood pressure control, decreasing aortic pulse pressure, controlling risk factors for atherosclerosis, and maintaining close long-term follow-up care. Penetrating atherosclerotic ulcers penetrate the internal elastic lamina, causing hematoma formation within the media of the aortic wall. Almost all are in the descending aorta. Because the natural history of these ulcers is undefined, a definitive treatment strategy has not been formulated.

Consider surgery in patients with penetrating atherosclerotic ulcers who are hemodynamically unstable or who have evidence of pseudoaneurysm formation or transmural rupture. Other indications for surgery include recurrent pain, distal embolization, and progressive aneurysmal dilatation from the ulcer. If patients do not present with these complications, they are treated with antihypertensive medications and close monitoring.

Postoperative details: Postoperative complications for extensive disease involving the thoracoabdominal aorta include myocardial infarction, respiratory failure, renal failure, stroke, and paraparesis or paraplegia.

Follow-up care: Provide the following long-term care for patients with aortic dissection, whether treated medically or surgically:

- One-month follow-up check for any new symptoms, such as chest or back pain, and signs suggestive of progression of the aortic dissection.
- Adequate blood pressure control, with the systolic blood pressure maintained at 90–120 mmHg
- Routine chest radiographs, CT scans with contrast, and MRIs, at 3-, 6-, and 12-month intervals, respectively, in an outpatient setting to evaluate any progression of the condition

Complications are diverse and numerous; anatomic-related complications are deducible and include the following (Fig. 18.29 and Table 18.3):

- Hypotension and shock as a result of aortic rupture and eventual death from exsanguination. Pericardial tamponade secondary to hemopericardium—complicates type A aortic dissection
- Acute aortic regurgitation as a complication of proximal aortic dissection propagating into a sinus of Valsalva with resultant aortic valve insufficiency
- Pulmonary edema secondary to acute aortic valve regurgitation
- Rare occurrence of right or left coronary ostium involvement leading to myocardial ischemia

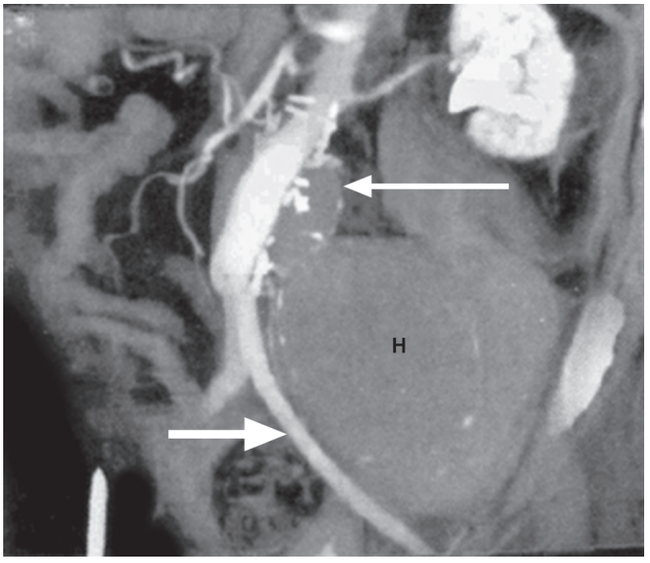

Fig. 18.29: 3-D VR MDCT. Large hematoma (H) post AAA surgical repair (arrow) displacing left iliac arteries (arrowhead)

Table 18.3: Complications in patients undergoing abdominal aortic aneurysm repair

Complication	Incidence (%)
Death	9.6
Myocardial infarction	7.2
Cerebrovascular accident	4.8
Paralysis/paresis	6.0
Non-Q-wave mycardial infarction	8.4
Distal emboli/thrombosis	6.0

- Neurologic findings due to carotid artery obstruction—ischemic CVA, hemiplegia, hemianesthesia (aortic branch involvement can lead to spinal cord ischemia, ischemic paraparesis, and paraplegia)
- Mesenteric and renal ischemia—can lead to bowel or visceral ischemia, renal infarction, hematuria, or ARF.

Compressive symptoms, such as superior vena cava syndrome, Horner syndrome (when it affects the superior cervical ganglia), dysphagia (when it involves the esophagus), airway compromise, and hemoptysis (when it compresses the bronchus)

- Other compressive symptoms—can be associated with vocal cord paralysis and hoarseness
- Claudication—can develop from extension of the dissection into the iliac arteries.

Redissection and progressive aortic diameter enlargement

- Aneurysmal dilatation and saccular aneurysm also can complicate aortic dissection
- Hospital-based mortality rates for aortic dissection are approximately 30%
- Patients with type A aortic dissection who undergo surgical treatment have a 30% mortality rate; patients who receive medical treatment have a mortality rate of 60%. Comorbidities and advanced aged can pose a contraindication to surgery in selected patients.

Medically treated patients with type B dissection have a 10% mortality rate; surgically treated patients with type B dissection have a 30% mortality rate.

Treated aortic dissection patients have a 60% 10-year survival rate. The mortality rate is influenced by the patient's clinical condition. The aortic dissection mortality rate is still high despite advancements in diagnostic and therapeutic modalities. Ideally, researchers will devise a test that detects aortic dissection before severe complications develop, thus allowing early intervention and eventually reducing mortality rates.

The findings of the smooth muscle myosin heavy-chain assay are not elevated in persons with acute myocardial infarction or other nonaortic conditions of chest pain syndromes. The test's sensitivity and specificity are promising, and, in the future, a battery of tests will help determine a genetic predisposition to aortic dissection, including conditions such as Ehlers-Danlos syndrome and Marfan syndrome.

Emergent surgical correction is the preferred treatment for the following classifications of aortic dissection:

- Stanford type A (DeBakey type I and II) ascending aortic dissection
- Complicated Stanford type B (DeBakey type III) aortic dissections with clinical or radiological evidence of the following conditions:
  - Propagation (increasing aortic diameter)
  - Increasing size of hematoma
  - Compromise of major branches of the aorta
  - Impending rupture
  - Persistent pain despite adequate pain management
  - Bleeding into the pleural cavity
  - Development of saccular aneurysm

Prehospital Care

- Assure adequate breathing, maintain oxygenation, treat shock, and obtain useful historic information.
- Establishing the diagnosis in the field is usually difficult or impossible, but certain salient features of aortic dissection may be observed. It is life threatening if not quickly recognized and treated.
- Radio communication with the receiving hospital permits the medical control physician to direct care and select a capable destination hospital while permitting the ED to mobilize appropriate resources.
- In the rare event that the diagnosis can be made based on prehospital information, the physician directing prehospital care should request transport to a facility capable of operative treatment of an aortic dissection.

Emergency Department Care

- The mortality rate of patients with aortic dissection is 1–2% per hour for the first 24–48 hours. Initial therapy should begin when the diagnosis is suspected. This

includes two large-bore intravenous lines (IVs), oxygen, respiratory monitoring, and monitoring of cardiac rhythm, blood pressure, and urine output.

- Clinically, the physician should reassess the patient frequently for hemodynamic compromise, mental status changes, neurologic or peripheral vascular changes, and development or progression of carotid, brachial, and femoral bruits.
- Aggressive management of heart rate and blood pressure should be initiated.
- Beta-blockers should be given initially to reduce the rate of change of blood pressure (dP/dt) and the shear forces on the aortic wall.
- The target heart rate should be 60–80 beats per minute.
- The target systolic blood pressure should be 100–120 mm-Hg.
- End organ perfusion should be evaluated. Balancing the risks of dP/dt on the aortic wall versus the benefits of acceptable end organ perfusion may be a difficult clinical decision.
- Urgent surgical intervention is required in type A dissections.
- The area of the aorta with the intimal tear usually is resected and replaced with a Dacron graft.
- The operative mortality rate is usually less than 10%, and serious complications are rare with ascending aortic dissections.
- The development of more impermeable grafts, such as woven Dacron, collagen-impregnated Hemashield (Meadox Medicals, Oakland, NJ), aortic grafts, and gel-coated Carbo-Seal Ascending Aortic Prothesis (Sulzer CarboMedics, Austin, TX) has greatly enhanced the surgical repair of thoracic aortic dissections.
- With the introduction of profound hypothermic circulatory arrest and retrograde cerebral perfusion, the morbidity and mortality rates associated with this highly invasive surgery have decreased.
- Dissections involving the arch are more complicated that those involving only the ascending aorta because the innominate, carotid, and subclavian vessels branch from the arch. Deep hypothermic arrest usually is required. If the arrest time is less than 45 minutes, the incidence of central nervous system complications is less than 10%.
- Aortic stent grafting is a challenging technique. It may prove feasible and has offered good results in a small series of patients. It may be a reasonable alternative in high-risk patients in the near future.
- Retrograde cerebral perfusion may increase the protection of the central nervous system during the arrest period.
- The mortality rate of aortic arch dissections is about 10–15%, with significant neurologic complications occurring in another 10%.
- The mortality rate is influenced by the patient's clinical condition.
- The definitive treatment for type B dissections is less clear.
- Uncomplicated distal dissections may be treated medically to control blood pressure.
- Distal dissections treated medically have the same or a lower mortality rate as those treated surgically.
- Surgery is reserved for distal dissections that are leaking, ruptured, or compromising blood flow to a vital organ.
- Acute distal dissections in patients with Marfan syndrome usually are treated surgically.
- Inability to control hypertension with medication is also an indication for surgery in those with a distal thoracic aortic dissection.
- Patients with a distal dissection are usually hypertensive, emphysematous, or older.

Long-term medical therapy involves a beta-adrenergic blocker combined with other antihypertensive medications. Avoid antihypertensives (e.g. hydralazine, minoxidil) that produce a hyperdynamic response that would increase dP/dt (i.e. alter the duration of P or T-waves).

- Survivors of surgical therapy also should receive beta-adrenergic blockers.
- A recent series of patients with type B dissections demonstrates that aggressive use of distal perfusion, CSF drainage, and hypothermia with circulatory arrest improves early mortality and long-term survival rates.
- Aortic stent grafting may play a role in how type B dissections are treated in the near future.
- Definitive treatment involves segmental resection of the dissection with interposition of a synthetic graft.
- When thoracic dissections are associated with aortic valvular disease, replace the defective valve.
- With combined reconstruction—valve replacement, the operative mortality rate is approximately 5% with a late mortality rate of less than 10%.
- Operative repair of the transverse aortic arch is technically difficult, with an operative mortality rate of 10% despite induction of hypothermic cardiocirculatory arrest.
- Repair of the descending aorta is associated with a higher incidence of paraplegia than repair of other types of dissections because of interruption of segmental blood supply to the spinal cord.
- The operative mortality rate is approximately 5%.

Consultations

- Once a thoracic dissection is suspected, consult a thoracic surgeon.
- Because many patients with this disorder have concomitant medical illness, consult the patient's primary care physician to expedite preoperative preparation.
- Early consultation is encouraged when ordering further imaging studies if the patient requires rapid operative intervention.
- Consult a radiologist prior to obtaining aortography.

Initial therapeutic goals include elimination of pain and reduction of systolic blood pressure to 100–120 mmHg or

to the lowest level commensurate with adequate vital organ (i.e. cardiac, cerebral, and renal) perfusion.

Whether systolic hypertension or pain is present, beta-blockers are used to reduce arterial dP/dt.

To prevent exacerbations of tachycardia and hypertension, treat patients with IV morphine sulfate. This reduces the force of cardiac contraction and the rate of rise of the aortic pressure (dP/dt). It then retards the propagation of the dissection and delays rupture

Pharmacology of Dissection of Aorta

Drug Category

Antihypertensives: These agents are used to reduce arterial dP/dt. For acute reduction of arterial pressure, the potent vasodilator sodium nitroprusside is effective. To reduce dP/dt acutely, administer an IV beta-blocker in incremental doses until a heart rate of 60–80 beats/min is attained.

When beta-blockers are contraindicated, such as in second-or third-degree atrioventricular block, consider using calcium channel blockers. Sublingual nifedipine successfully treats refractory hypertension associated with aortic dissection.

Drug name: Esmolol (brevibloc)—ultrashort-acting beta2-blocker, particularly useful in patients with labile arterial pressure, especially if surgery is planned, because it can be discontinued abruptly if necessary. Normally used in conjunction with nitroprusside. May be useful as a means to test beta-blocker safety and tolerance in patients with history of obstructive pulmonary disease who are at uncertain risk of bronchospasm from beta-blockade. Elimination half-life is 9 min.

Adult dose: 250–500 mcg/kg/min for 1 min as loading dose, followed by a 4-min maintenance infusion of 50 mcg/kg/min; repeat loading dose and follow with maintenance infusion using increments of 50 mcg/kg/min for 4 min; if therapeutic effects not observed in 5 min, repeat sequence up to 4 times prn. As desired BP is approached, omit loading infusion and reduce incremental dose of maintenance infusion from 50 mcg/kg/min to 25 mcg/kg/min or lower; may increase interval between titration steps to 5–10 min if desired.

Pediatric dose: Not established

Contraindications: Documented hypersensitivity; uncompensated CHF; bradycardia; cardiogenic shock; AV conduction abnormalities

Interactions: Aluminum salts, barbiturates, NSAIDs, penicillins, calcium salts, cholestyramine, and rifampin may decrease bioavailability and plasma levels, possibly resulting in decreased pharmacologic effect; sparfloxacin, astemizole **(recalled from US market)**, calcium channel blockers, quinidine, flecainide, and contraceptives may increase cardiotoxicity; digoxin, flecainide, acetaminophen, clonidine, epinephrine, nifedipine, prazosin, haloperidol, phenothiazines, and catecholamine-depleting agents may increase toxicity

Pregnancy: C-Safety for use during pregnancy has not been established.

Precautions: Beta-adrenergic blockers may mask signs and symptoms of acute hypoglycemia and clinical signs of hyperthyroidism; symptoms of hyperthyroidism, including thyroid storm, may worsen when medication is withdrawn abruptly; withdraw drug slowly and monitor patient closely

Drug name: Labetalol (normodyne, trandate)—blocks alpha-, beta1-, and beta2-adrenergic receptor sites, decreasing BP.

Adult dose: Initial dose—20 mg (0.25 mg/kg for 80 kg patient) IV over 2 min; follow with 20–80 mg q10–15 min until BP controlled. Maintenance dose—2 mg/min continuous IV infusion; titrate up to 5–20 mg/min; not to exceed a total dose of 300 mg

Pediatric dose: Not established

Contraindications: Documented hypersensitivity; cardiogenic shock; AV block; uncompensated CHF; pulmonary edema; bradycardia; reactive airway disease

Interactions: Decreases effects of diuretics and increases toxicity of methotrexate, lithium, and salicylates; may diminish reflex tachycardia associated with nitroglycerin use without interfering with hypotensive effects; cimetidine may increase blood levels; glutethimide may decrease effects by inducing microsomal enzymes

Pregnancy: C-Safety for use during pregnancy has not been established.

Precautions: Caution in impaired hepatic function; discontinue therapy with signs of liver dysfunction; in elderly patients, lower response rate and higher incidence of toxicity may be observed.

Drug name: Propranolol (inderal, betachron E-R)—class II antiarrhythmic nonselective beta-adrenergic receptor blocker. Has membrane-stabilizing activity and decreases automaticity of contractions. Not suitable for emergency treatment of hypertension. Do not administer IV in hypertensive emergencies.

Adult dose: 40–80 mg PO bid initially; increase to usual range of 160-320 mg/d prn; up to 640 mg/d may be required

Pediatric dose: 0.5 mg/kg/d PO divided bid/qid; increase gradually q3–7d; usual dosage range is 2–4 mg/kg/d divided bid; not to exceed 16 mg/kg/d

Contraindications: Documented hypersensitivity; uncompensated CHF; bradycardia; cardiogenic shock; AV conduction abnormalities

Interactions: Aluminum salts, barbiturates, NSAIDs, penicillins, calcium salts, cholestyramine, and rifampin may decrease effects; calcium channel blockers, cimetidine, loop

diuretics, and MAOIs may increase toxicity; may increase toxicity of hydralazine, haloperidol, benzodiazepines, and phenothiazines

Pregnancy: B-Usually safe but benefits must outweigh the risks.

Precautions: Beta-adrenergic blockade may decrease signs of acute hypoglycemia and hyperthyroidism; abrupt withdrawal may exacerbate symptoms of hyperthyroidism, including thyroid storm; withdraw drug slowly and monitor closely.

Drug name: Metoprolol (lopressor)—selective beta1-adrenergic receptor blocker that decreases automaticity of contractions. During IV administration, carefully monitor BP, heart rate, and ECG. When considering conversion from IV to PO dosage forms, use ratio of 2.5 mg PO to 1 mg IV metoprolol.

Adult dose: 100 mg/d PO qd or divided bid/tid initially; increase at 1-week intervals prn; not to exceed 450 mg/d prn

Pediatric dose: Not established

Contraindications: Documented hypersensitivity; uncompensated CHF; cardiogenic shock; bradycardia; AV conduction abnormalities

Interactions: Aluminum salts, barbiturates, NSAIDs, penicillins, calcium salts, cholestyramine, and rifampin may decrease bioavailability and plasma levels, possibly resulting in decreased pharmacologic effects; sparfloxacin, phenothiazines, astemizole **(recalled from US market)**, calcium channel blockers, quinidine, flecainide, and contraceptives may increase toxicity; may increase toxicity of digoxin, flecainide, clonidine, epinephrine, nifedipine, prazosin, verapamil, and lidocaine

Pregnancy: B-Usually safe but benefits must outweigh the risks.

Precautions: Beta-adrenergic blockade may reduce signs and symptoms of acute hypoglycemia and may decrease clinical signs of hyperthyroidism; abrupt withdrawal may exacerbate symptoms of hyperthyroidism, including thyroid storm; monitor patient closely and withdraw drug slowly; during IV administration, carefully monitor BP, heart rate, and ECG

Drug name: Nitroprusside (nitropress) causes peripheral vasodilation by direct action on venous and arteriolar smooth muscle, thus reducing peripheral resistance. Commonly used IV because of rapid onset and short duration of action. Easily titratable to reach desired effect. Light sensitive; both bottle and tubing should be wrapped in aluminum foil. Prior to initiating nitroprusside, administer beta-blocker to counteract physiologic response of reflex tachycardia that occurs when nitroprusside used alone. This physiologic response increases shear forces against aortic wall, thus increasing dP/dt. Objective is to keep heart rate at 60–80 bpm.

Adult dose: 0.5–3 mcg/kg/min IV; rates >4 mcg/kg/min may lead to cyanide toxicity

Pediatric dose: Administer as in adults

Contraindications: Documented hypersensitivity; subaortic stenosis; idiopathic hypertrophic subaortic stenosis; atrial fibrillation or flutter

Interactions: None reported

Pregnancy: C-Safety for use during pregnancy has not been established.

Precautions: Caution in increased intracranial pressure, hepatic failure, severe renal impairment, and hypothyroidism; in renal or hepatic insufficiency, levels may increase and can cause cyanide toxicity; sodium nitroprusside has ability to lower BP and thus should be used only in patients with mean arterial pressures >70 mmHg

Drug category: Analgesics—pain control is essential to quality patient care. It ensures patient comfort, promotes pulmonary toilet, and prevent exacerbations of tachycardia and hypertension.

Drug name: Morphine sulfate (astramorph, infumorph)—DOC for narcotic analgesia because of reliable and predictable effects, safety profile, and ease of reversibility with naloxone. Similar to fentanyl, morphine sulfate easily titrated to desired level of pain control. If administered IV, may be dosed in a number of ways; commonly titrated until desired effect obtained.

Adult dose: Initial dose—0.1 mg/kg IV/IM/SC. Maintenance dose: 5–20 mg/70 kg q4h IV/IM/SC.

Pediatric dose: 0.1–0.2 mg/kg IV/IM/SC q2-4h prn.

Contraindications: Documented hypersensitivity; hypotension; potentially compromised airway in which establishing rapid airway control would be difficult.

Interactions: Phenothiazines may antagonize analgesic effects; tricyclic antidepressants, MAOIs, and other CNS depressants may potentiate adverse effects.

Pregnancy: C-Safety for use during pregnancy has not been established.

Precautions: Avoid in hypotension, respiratory depression, nausea, emesis, constipation, and urinary retention; caution in atrial flutter and other supraventricular tachycardias; has vagolytic action and may increase ventricular response rate.

Further Inpatient Care

- Patients with symptomatic dissection should undergo immediate repair, especially if it is leaking or expanding.
- Symptomatic patients require admission to a center experienced in cardiopulmonary bypass and operative care.
- Completely asymptomatic patients may have their repair performed electively but may require admission to

expedite their evaluation or for preoperative stabilization of their condition.
- Patients with chest pain should undergo serial ECGs and CK determinations if AMI is indicated.

Further Outpatient Care

- Follow-up examinations with radiologic studies are recommended at 3-month intervals for the first year and every 6 months for the next 2 years.
- After this, follow up annually.

Transfer

- Symptomatic patients require care at a facility equipped to perform cardiopulmonary bypass with aortic and/or valvular repair.
- Contact the receiving physician as soon as possible to transfer patients before their condition deteriorates.
- Early airway management is indicated in the presence of hemoptysis or stridor.
- If coronary insufficiency is suspected, nitrates may be used, but therapy with thrombolytic agents and aspirin should be avoided.
- Patients should be monitored and accompanied by personnel capable of resuscitation.
- If a prolonged ground transport time is anticipated, consider air transport.

Prognosis

- On the basis of his experience, Crawford has stated that 'no patient should be considered cured of the disease.'
- The 5-year survival rate is about 75% whether the patient is treated medically or surgically.

The 10-year survival rate is between 40% and 69% for both surgically and medically treated dissections.

In the pretreatment era, the 1-year survival rate was 5–10%.

Reoperation may be necessary for late complications.

Medical/Legal Pitfalls

- Failure to diagnose (especially in patients presenting with chest pain). Use of thrombolytics in the patient presenting with chest pain and ECG changes
- Multiple case reports describe patients who received thrombolytics and were found later to have a dissection. The diagnosis of aortic dissection can be subtle.

The diagnosis depends on clinical suspicion, with contributory findings on history, physical examination, and imaging studies.

Obtaining a chest radiograph prior to administering thrombolytics is considered prudent.

Checking blood pressures in both arms and listening for carotid bruits also can help diagnose aortic dissection prior to administering thrombolytics. The entire clinical picture must be taken into account knowledgement.

KEY POINTS

1. Aortic dissection may originate anywhere along the aorta but is most common at the proximal ascending aorta (within 5 cm of the aortic valve) or the descending thoracic aorta just beyond the origin of the left subclavian artery.
2. Dissection requires preexisting degeneration of the aortic media (e.g. caused by connective tissue disorders, injury) but hypertension is commonly also involved.
3. Patients typically have excruciating, tearing precordial or interscapular pain.
4. Other manifestations depend on whether the aortic root and/or branches of the aorta are affected, and the presence and location of any rupture; heart failure, organ ischemia and hemorrhagic shock may occur.
5. Diagnose using TEE, CTA, or MRA.
6. Immediately give beta-blockers and other drugs as needed to control BP.
7. Drug therapy alone is appropriate for uncomplicated, stable dissection confined to the descending aorta or the aortic arch; other cases require surgery.

BIBLIOGRAPHY

1. Bickerstaff LK, Pairolero PC, Hollier LH, et al. Thoracic aortic aneurysms: a population-based study. Surgery 1982; 92(6):1103-8.
2. Chen K, Varon J, Wenker OC, et al. Acute thoracic aortic dissection: the basics. J Emerg Med 1997;15(6): 859–67.
3. Cigarroa J, Isselbacher E, DeSanctis R. Diagnostic Imaging in the Evaluation of Suspected Aortic Dissection. N Engl J Med 1993;328(1):35–43.
4. De Bakey ME, Cooley DA, Creech O. Surgical considerations of dissecting aneurysm of the aorta. Ann Surg 1955; 142(4): 586–610;(discussion),611–2.
5. De Bakey ME, Cooley DA. Successful resection of aneurysm of thoracic aorta and replacement by graft. J Am Med Assoc 1953;152(8):673–6.
6. DeSanctis R, Doroghazi R, Austen G. Aortic Dissection. N Engl J Med 1987;317(17):1060–66.
7. Erbel R, Engberding R, Daniel W, et al. Echocardiography in diagnosis of aortic dissection. Lancet 1989;1(8636):457–61.
8. Erdheim J. Medionecrosis Aorte Idiopathica Apitca. Virchows Arch Pathol Anat 1930;276:187–229.
9. Goldman L, Ausiello D. Cecil Textbook of Medicine, 22nd ed. Philadelphia, Pa: WB Saunders Co; 2004.
10. Hagan PG, Nienaber CA, Isselbacher EM, et al. The International Registry of Acute Aortic Dissection (IRAD): new insights into an old disease. JAMA 2000;283(7): 897–903.
11. Hasham SN, Lewin MR, Tran VT, et al. Nonsyndromic genetic predisposition to aortic dissection: a newly recog-nized, diagnosable, and preventable occurrence in families. Ann Emerg Med 2004;43(1):79–82.
12. Jagannath AS, Sos TA, Lockhart SH, et al. Aortic dissection: a statistical analysis of the usefulness of plain chest radiographic findings. AJR Am J Roentgenol 1986; 147(6): 1123–6.

13. Januzzi JL, Marayati F, Mehta RH, et al. Comparison of aortic dissection in patients with and without Marfan's syndrome (results from the International Registry of Aortic Dissection). Am J Cardiol 2004;94(3):400–2.
14. Knaut AL, Cleveland JC. Aortic emergencies. Emerg Med Clin North Am 2003;21(4):817–45.
15. Krukenberg E. Beitrage zur Frage des Aneurysma Dissecans. Beitr Pathol Anat Allerg Pathol 1920;67:329–51.
16. Lee JT, White RA. Current status of thoracic aortic endograft repair. Surg Clin North Am 2004;84(5):1295–318,
17. Nichols F. Observations Concerning the Body of His Late Majesty. Philos Trans Lond 1762;52:265–75.
18. Pansini S, Gagliardotto PV, Pompei E, et al. Early and late risk factors in surgical treatment of acute type A aortic dissection. Ann Thorac Surg 1998; 66(3):779–84.
19. Ponraj P, Pepper J. Aortic dissection. Br J Clin Pract 1992 Summer; 46(2):127–31.
20. Prokop EK, Palmer RF, Wheat MW Jr. Hydrodynamic forces in dissecting aneurysms. In-vitro studies in a Tygon model and in dog aortas. Circ Res 1970; 27(1):121–7.
21. Rogers RL, McCormack R. Aortic disasters. Emerg Med Clin North Am 2004; 22(4):887–908.
22. Safi HJ, Miller CC, Reardon MJ, et al. Operation for acute and chronic aortic dissection: recent outcome with regard to neurologic deficit and early death. Ann Thorac Surg 1998; 66(2):402–11.
23. Sarasin FP, Louis-Simonet M, Gaspoz JM, et al. Detecting acute thoracic aortic dissection in the emergency department: time constraints and choice of the optimal diagnostic test. Ann Emerg Med 1996;28(3):278–88.
24. Spiegel EA, Wassreman S. Experimentalstudien uber die Entsehungdes Aortenschmerzes und seine Leitung zum zentralnervensystem. Ztschr F. d. ges. Exper Med 1926;52: 180–96.
25. Svensson LG, Crawford ES, Hess KR, et al. Experience with 1509 patients undergoing thoracoabdominal aortic operations. J Vasc Surg 1993;17(2):357–68;(discussion) 368–70.
26. Tatli S, Yucel EK, Lipton MJ. CT and MR imaging of the thoracic aorta: current techniques and clinical applications. Radiol Clin North Am 2004; 42(3):565–85.

19 Peripheral Vascular Disease and Endovascular Therapy

ANATOMICAL BASIS OF PERIPHERAL VASCULAR SYSTEM

Peripheral vascular diseases (PVDs) are circulation disorders that affect blood vessels outside of the heart and brain. PVD typically strikes the veins and arteries that supply the arms, legs, and organs located below your stomach. These are the blood vessels that are distant from the heart. They are known as peripheral vessels. In PVD, blood vessels are narrowed. Narrowing is usually caused by arteriosclerosis. Arteriosclerosis is a condition where plaque builds up inside a vessel. It is also called 'hardening of the arteries.' Plaque decreases the amount of blood and oxygen supplied to the arms and legs. As plaque growth progresses, clots may develop. This further restricts the affected vessel. Eventually, arteries can become obstructed.

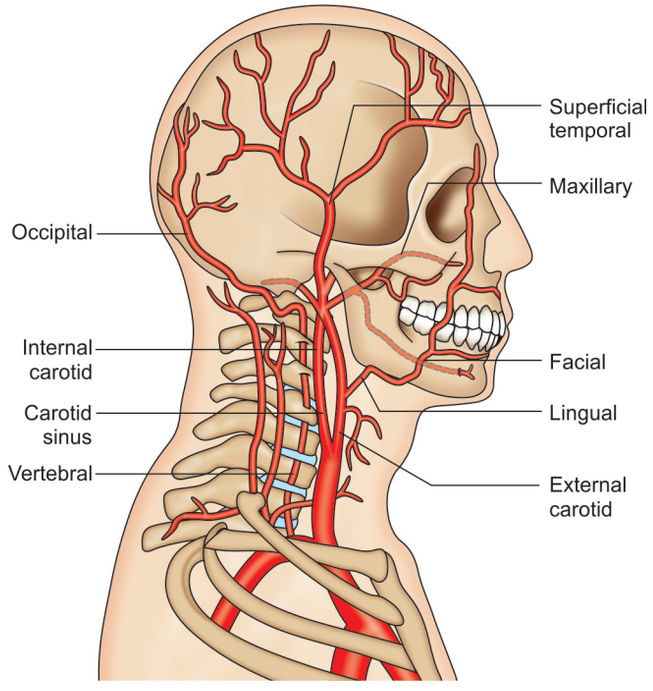

Fig. 19.1: Anatomical localization of arterial system of head and neck

PVD that develops only in the arteries is called peripheral arterial disease (PAD). This is the most common form of PVD. Approximately 12–20% of people over age 65 have PAD. PVD that develops in the deep veins in the body is usually caused from claudication and is called deep vein thrombosis (DVT) (Figs 19.1–19.6).

PVD and PAD are often used to mean the same condition that affects the arteries. PVD may also be referred to as:

- Arteriosclerosis obliterans
- Arterial insufficiency of the legs
- Claudication
- Intermittent claudication

Types of PVD

There are two main types of PVD (Tables 19.1 and 19.2):

1. **Functional PVD:** This does not involve physical problems in the blood vessels. It causes incidental or short-term symptoms. Usually these spasms occur erratically.
2. **Organic PVD:** This involves changes in blood vessel structure. This type of PVD causes inflammation, tissue damage, and blockages.

Causes of PVD

Functional PVD: The body responds to certain external stimuli by restricting blood flow to the peripheral vessels. The most common causes of functional PVDs are:

- Emotional stress
- Smoking
- Cold temperatures
- Operating vibrating machinery or tools

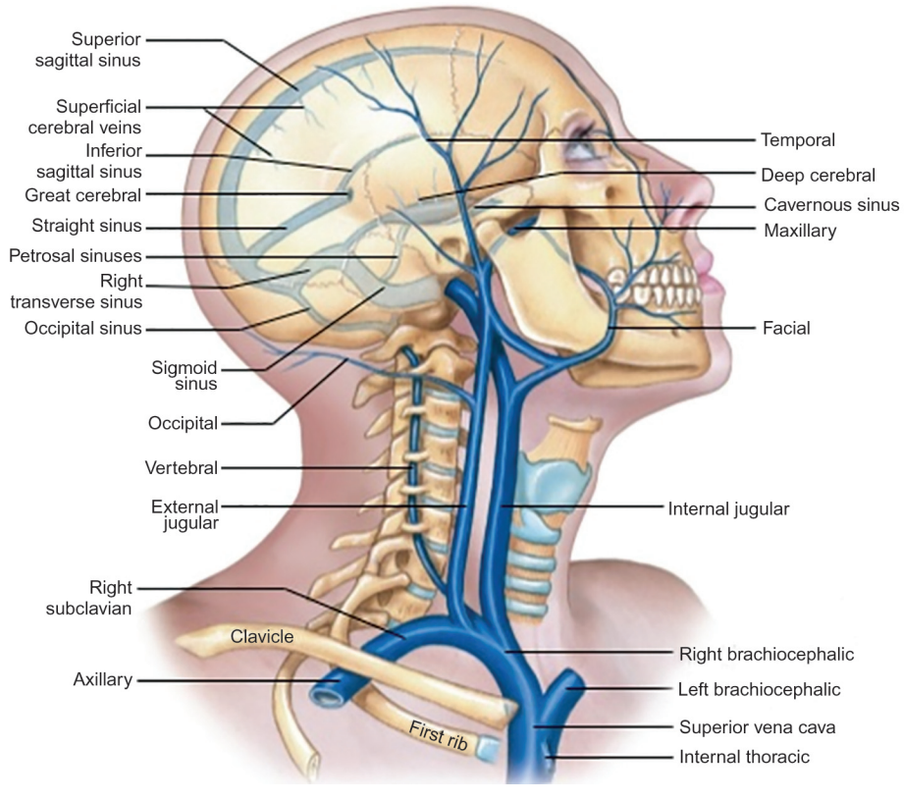

Fig. 19.2: Anatomical localization of venous system of head and neck

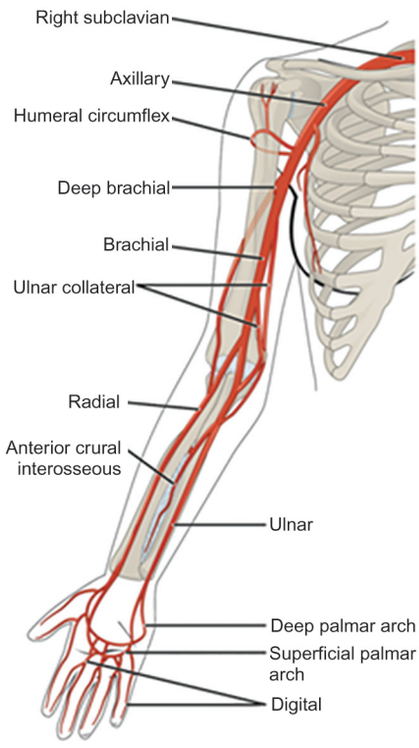

Fig. 19.3: Anatomy of various arteries of upper limbs

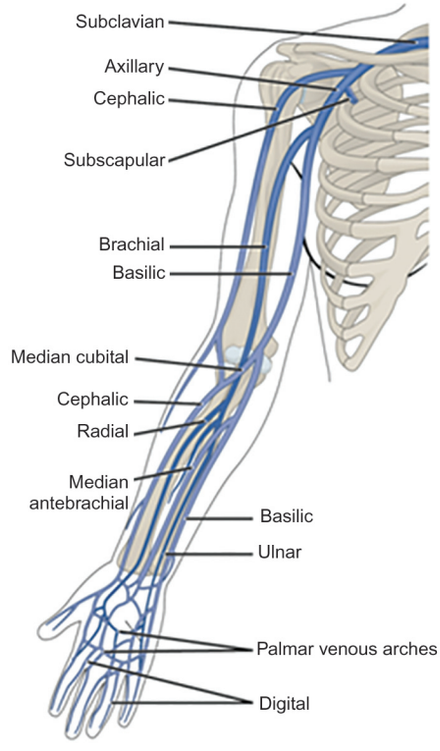

Fig. 19.4: Anatomical localization of various veins of upper limbs

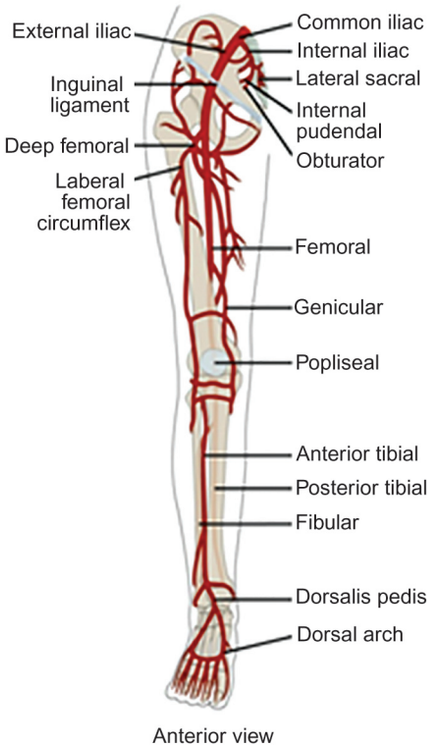

Fig. 19.5: Anatomical localization of various arteries of lower limbs

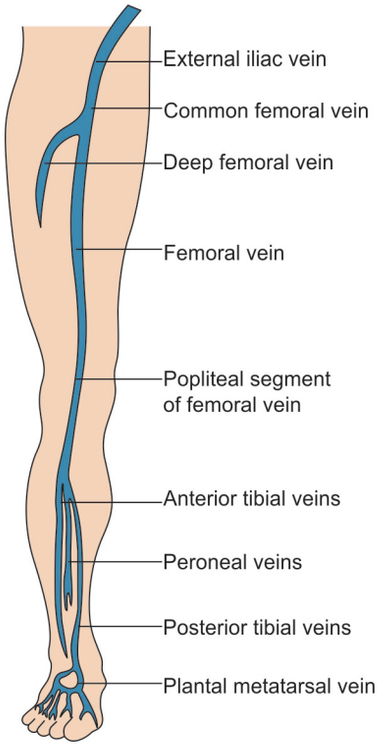

Fig. 19.6: Anatomical localization of various veins of lower limbs

Table 19.1: Fontaine classification of peripheral arterial disease (PAD)

Stage	Characteristic symptoms
1	Clinically symptom-free vascular occlusion
2	Exercise-induced ischemia causing intermittent claudication. No pain at rest
3	Ischemia at rest, causing rest pain
4	Ulceration and ischemic gangrene

Table 19.2: Non-atherosclerotic causes of PAD

- Peripheral emboli
- Aneurysm thrombosis or thromboembolism (aortic, popliteal)
- Arteritis
- Takayasu's disease
- Thromboangitis obliterans (Buerger's disease)
- Giant cell arteritis
- Polyarteritis nodosa
- Fibromuscular dysplasia
- Prior trauma or irradiation injury
- Aortic coarctation
- Endofibrosis of the external iliac artery syndrome in cyslists)
- Primary vascular tumors
- Pseudoxanthoma elasticum
- Young patients
- Adventitial cyst of the popliteal artery
- Popliteal entrapment
- Persistent sciatic artery

Organic PVD

Physical changes can affect the structure of blood vessels. For example, arteriosclerosis can cause plaque buildup. The primary causes of such organic PVDs are:

- Smoking
- High blood pressure
- Diabetes
- High cholesterol
- Additional causes of organic PVDs include:
  - injury to extremities
  - muscles or ligaments with abnormal structures
  - infection
  - coronary artery disease There are numerous risk factors for PVD. Some are due to underlying medical conditions, age, and gender while others are due to lifestyle choices.
- You are at a higher risk for acquiring PVD if you are a man over age 50 or a postmenopausal woman. The likelihood of developing PVD also increases if you have:
  - abnormal cholesterol
  - cerebrovascular disease (stroke)
  - heart disease

- diabetes mellitus (type 1 diabetes)
- family history of high cholesterol, high blood pressure, or PVD
- high blood pressure
- kidney disease on hemodialysis

- The lifestyle choices that can increase your risk of developing PVD are:
  - being overweight
  - being sedentary and not engaging in physical exercise
  - smoking

CLINICAL EXAMINATION

Examination of the pulse can provide clues to the presence of systemic diseases. Ancient physicians would diagnose heart, liver, renal, and gastrointestinal problems from assessment of the pulse. Today, other tests have been developed to assist in the work-up of systemic illness, but examination of the pulse is still an important part of patient assessment (Figs 19.7–19.56 and Table 19.3).



Fig. 19.7: A doctor conducting clinical examination of a patient with vascular disease of the leg



Fig. 19.8: Duplex ultrasonography transducer is being placed in the neck by a doctor on young patient

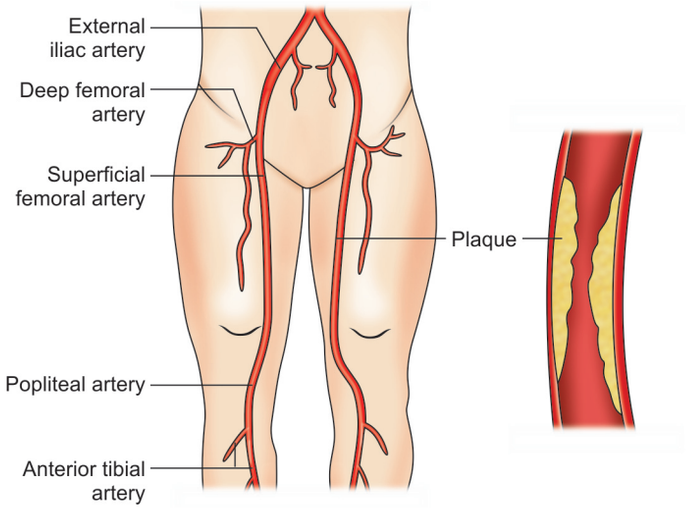

Fig. 19.9: Different arteries of lower limbs with atherosclerotic occlusion of left superficial femoral artery



Fig. 19.10: A doctor examining lower limb artery with Doppler ultrasonography



Fig. 19.11: A doctor examining lower limb arteries with Doppler ultrasonography



Fig. 19.12: Secondary lymphedema—left upper extremity lymphedema 2 years after mastectomy, radiation, and lymphadenectomy for breast cancer

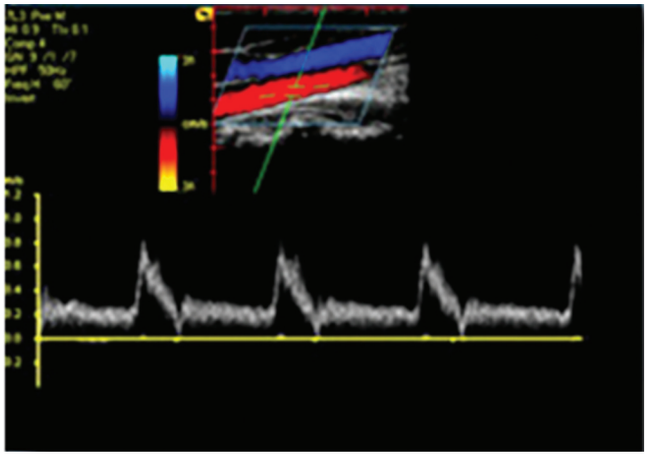

Fig. 19.13: Normal common carotid artery (CCA)—PW Doppler

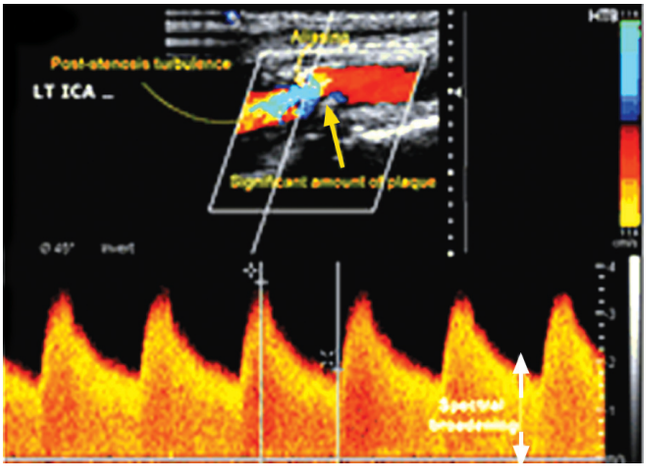

Fig. 19.14: Severe stenosis (70% to near occlusion) of the ICA. Duplex US image of the left ICA shows a high PSV (366 cm/sec), a significant amount of visible plaque, the presence of aliasing despite a high color scale setting (114 cm/sec), color flow turbulence immediately distal to the stenotic segment, broadening of the PW Doppler spectrum, and a high end-diastolic velocity (182 cm/sec)

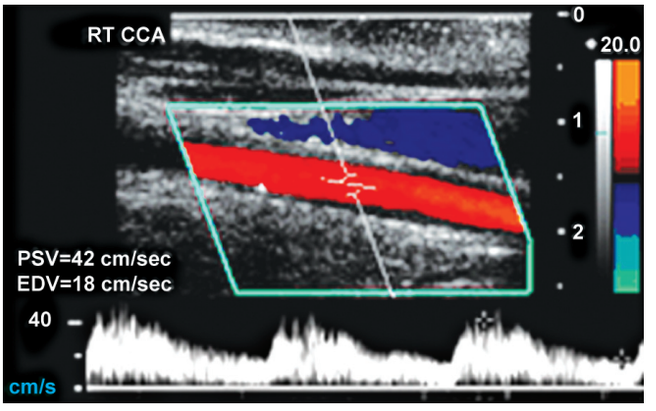

Fig. 19.15: Severe stenosis of the innominate artery. PW Doppler spectral image of the right CCA shows a tardus-parvus waveform, which is suggestive of a severe stenosis proximal to the point of sampling

Conditions associated with tachycardia or bradycardia have been discussed, as have the causes of a pulse irregularity. Reduced or absent arterial pulses are a sign of impaired blood flow. The causes include:

1. Congenital abnormalities (coarctation of the aorta, anomalous peripheral arteries);
2. Intrinsic arterial disease (atherosclerosis, thrombosis, and arteritis);
3. Vasospastic disorders (Raynaud's phenomenon); or
4. Involvement of the vessel by extrinsic compression (thoracic outlet syndrome, trauma, and neoplasms).

The resultant alteration of pulses, with or without accompanying bruits, may be indicative of either acute or chronic changes in a given patient. The vascular history, together with associated physical findings such as skin color, temperature, and neuromotor status of the extremity, should help to elucidate these points. More refined diagnostic techniques such as Doppler ultrasound examination and arteriography may be required to evaluate abnormalities suspected from the physical examination. In this regard, it is important to understand that significant arterial occlusive disease of the lower extremities may exist in a patient who has almost normal peripheral pulses in the resting state, since collateral circulation can produce pulsatile flow in the peripheral arterial bed in some patients. If such an individual is instructed to exercise to the point of claudication, however, pulse distal to the major vascular occlusion will diminish or disappear.

Significant widening of an artery to the examining fingers may be the best clue to an otherwise silent arterial aneurysm. The wary examiner will not be misled by tortuosity of the vessel giving a false impression of increased diameter. Careful palpation may also reveal the

Table 19.3: Clinical tests used in the diagnosis of peripheral arterial diseases (PAD)

Test modality	Diagnostic indicators
Medical history	• Evidence of atherosclerosis, such as ischemic heart disease, cerebrovascular disease • Risk of atherosclerosis, such as cigarette smoking, diabetes mellitus
Pulses in the lower limb	Popliteal, posterior tibial, dorsalis pedis and peroneal pulses • Pulse quality (bounding, full, normal, weak, and absent) • Rate (beats/minute) • Regularity (regular, irregular, irregular, and irregularly irregular)
Presenting symptoms	• Cold, numb feet • Intermittent claudication • Rest pain • Painful ulceration
Ankle-branchial index (ABI)	• 0.9–1.1 = normal • 0.7–0.9 = PAD, some compromise of tissue viability • 0.5–0.7 = severe PAD, compromised tissue viability • <0.5 = threat of ischaemic gangrene/very poor tissue viability • >1.2 = calcification of tunica media of leg/foot artery, compromised tissue viability
Segmental systolic pressure	Serial measurement of systolic blood pressure along length of limb • A sudden decrease indicates the location of the vascular obstruction
Venous filling time Note: This test is not valid if the patient has venous incompetence	• The time it takes for veins to refill in a limb that has been drained of venous blood (with the patient supine, the leg is elevated to 45° for 1 minute, then the leg placed in a dependent position and the timetaken for the dorsal foot veins to refil) • <15 seconds = normal • 20–30 seconds = moderate ischemia • >40 second = severe ischemia
Buerger's test	• The observation of the change in skin color in response to limbe elevation and dependency (with the patient supine, the leg is elevated to 45° for 1 minute, then the leg is placed in a dependent position and the time taken for normal skin color to return is noted) • <10 seconds = normal response • Patchy persistent rubor indicates limb ischemia • Persistent pallor (>10 seconds) indicates limb ischemia • Presistent cyanosis indicates limb ischemia
Buerger's angle	• The color response of the sole of the foot to limb elevation (with the patient supine, the leg is elevated and the angle of limb elevation is noted when the skin of medial longitudinal arch shows pallor) • 60–70° = normal arterial supply to foot • <45° = compromised arterial supply to foot • <30° = severe compromised arterial supply to foot
Capillary refill time Note: This test is not valid if the patient has signs of current Raynaud's disease	• The time taken for normal skin tone of a horizontal limb to retum after the nail bed or digital pulp has been compressed by thumb pressure • <5 seconds = normal response • >5 seconds = some ischaemia • >15 seconds = marked ischemia
Doppler sounds	• Triphasic = normal • Biphasic = normal/some loss of arterial elasticity • Monophasic = loss of arterial elasticity/arterial stenosis • Loud = high rate of blood flow • Quiet = slow rate of blood flow • No sound = no blood flow (proximal arterial occlusion)
Skin temperature Note: This test is not vaild if the patient has signs of current Raynaud's disease	• ~31°C = normal foot skin temperature • <29°C = possible poor skin perfusion

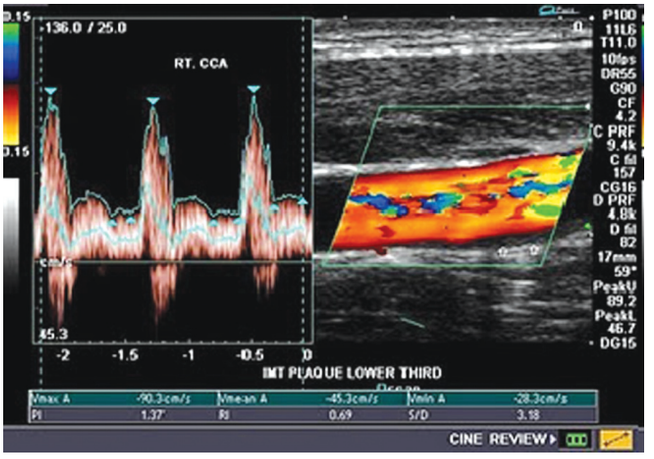

Fig. 19.16: This middle-aged male patient had a recent partial stroke affecting the left side of face and left upper limb. The B-mode ultrasound images of the right common carotid artery show an atheromatous plaque of the lower third of the vessel. This plaque is noncalcific and shows no evidence of ulceration. The color-Doppler images of the common carotid artery show no significant obstruction to blood flow in this artery. Possibly, there might have been a small embolic episode some time ago resulting in cerebral ischemia on this side

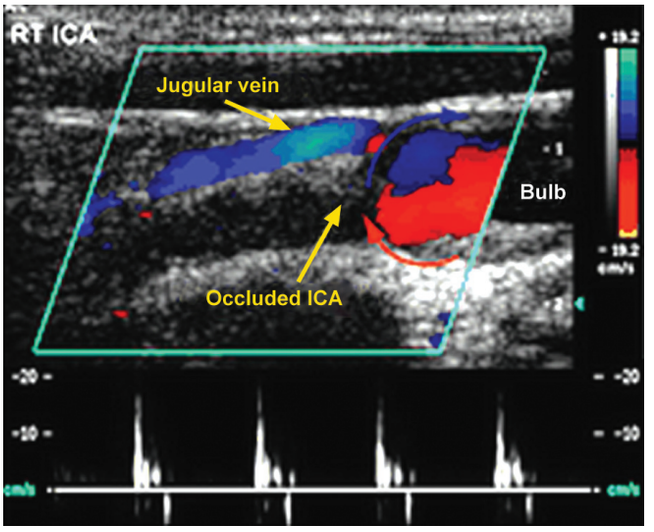

Fig. 19.17: Thud flow. Color-Doppler image of the right ICA and carotid bulb shows no flow in the ICA lumen and reversed flow in the bulb at the point of occlusion

rock-hard vessel wall of calcified atherosclerosis, the harsh systolic thrill of a tight arterial stenosis, or the continuous thrill of a peripheral arteriovenous fistula. In the latter condition, auscultation should confirm a continuous, or machinery-like, murmur with systolic accentuation. Much valuable information can be gained from examination of the peripheral pulses in addition to the status of the arterial system itself. The attentive examiner may detect variations in the rate, rhythmicity, intensity, and contour of the pulse wave that yield insight into a variety of disease states. The rapid, thready pulse of hypovolemic shock is a well-known clinical sign, as is the rapid, snapping pulse characteristic of thyrotoxicosis, and the collapsing, 'water-hammer' pulse of aortic insufficiency.

There are at least four reasons why it is important to determine if a patient does or does not have thrombophlebitis. These include the threat and prophylaxis of pulmonary embolism, the risk of septicemia, the use of certain drugs other than anticoagulants, and the occasional detection of any other primary disease processes.

Deep vein thrombophlebitis requires hospitalization and anticoagulation to prevent morbidity and mortality from associated pulmonary embolism. The efficacy of anticoagulant therapy in this setting was clearly demonstrated in control studies done many years ago. Evidence is not convincing that anticoagulant therapy is of benefit in phlebitis clearly isolated to superficial veins of the arm or saphenous system of the leg. However, there are communicating leg veins between the superficial and deep venous system, and the examiner bears the responsibility for determining that the aforementioned signs of deep phlebitis are absent.

Pelvic thrombophlebitis and thrombophlebitis associated with indwelling intravenous catheters are a surprisingly frequent source of septicemia. Recognition of either requires careful evaluation of the patient for evidence of bloodstream infection. Thrombophlebitis and pulmonary embolism are more frequent in recently diuresed patients. One should therefore use therapeutic discretion in planning diuretic therapy for patients who belong to any of the previously described 'suspicious clinical settings.' In addition, patients receiving corticosteroid therapy are more susceptible to phlebitis. The same is true for women taking estrogen-containing oral contraceptives; other family planning measures should be substituted for such therapy in the presence of spontaneous thrombophlebitis. Thrombophlebitis that is either recurrent, located in unusual veins (subclavian, jugular), or migratory to various superficial veins may be the first sign of an underlying disease process such as occult malignancy or systemic lupus erythematosus.

Brachiocephalic Artery or Trunk

The brachiocephalic artery or trunk is the first and largest artery that branches to form the right common carotid artery and the right subclavian artery. This artery provides blood to the right upper chest, right arm, neck, and head, through a branch called right vertebral artery. The right and left vertebral artery feed into the basilar artery and upward to the posterior cerebral artery, which provides most of the brain with oxygenated blood. The posterior cerebral artery and the posterior communicating artery are within the circle of Willis.

The left common carotid artery divides to form the internal carotid artery (ICA) and an external carotid artery (ECA). The ICA supplies the brain. The ECA supplies the neck and face. The left subclavian artery and the right subclavian artery, one on each side of the body form the internal

thoracic artery, the vertebral artery, the thyrocervical trunk, and the costocervical trunk. The subclavian becomes the axiliary artery at the lateral border of the first rib. The left subclavian artery also provides blood to the left upper chest and left arm.

Subclavian Artery

The subclavian arteries are a pair of large arteries in the thorax that supply blood to the thorax, head, neck, shoulder and arms.

Course: On the left side of the body the subclavian comes directly from the aortic arch whereas on the right side it arises from the brachiocephalic trunk. Both course above the cervical pleura towards the anterior scalene muscle and through the posterior scalene gap (between the anterior and medial scalene muscles). It enters the axilla between the first rib and the clavicle and becomes the axillary artery. During its course it gives off numerous branches:

The Thoracic Region: The following branches arise medial to the scalenus anterior muscle:

- The first artery is the vertebral artery which ascends until it reaches the vertebral column at the transverse foramen of the sixth or seventh cervical vertebra.
- Second is the internal thoracic artery which runs in the opposite direction to the vertebral artery behind the sternum and costal cage. It branches off into three smaller arteries.
- The superior epigastric artery arises and runs below the costal margin, entering the rectus sheath. The pericardiophrenic artery accompanies the phrenic artery at the level of the fourth cervical vertebra and helps supply the pericardium.
- The musculophrenic artery supplies the upper musculature of the diaphragm.
- The third artery is the **thyrocervical trunk** which gives off four branches as it ascends.
- The inferior thyroid artery ascends, makes a loop behind the common carotid artery and courses towards the backside of the thyroid crossing the recurrent laryngeal nerve. It branches off arteries to the larynx (inferior laryngeal artery), infrahyoid and prevertebral muscles and many more smaller ones to the surrounding structures.
- The ascending cervical artery is next and ascends along the phrenic nerve at the level of the fourth cervical vertebra.
- The **transverse cervical artery** divides into a superficial and deep branch. The superficial branch runs superficially in the lateral cervical region and then under the trapezius muscle (together with the accessory nerve). The deep branch branches off into two smaller arteries, one of which follows the dorsal scapular nerve along the medial border of the scapula.
- The **suprascapular artery** courses above the scapula in front of the anterior scalene muscle and behind the clavicle. It anastomoses with the scapular circumflex and thoracoacromial arteries (via the acromial branches).
- **The costocervical trunk** arises behind the anterior scalene muscle and divides into two main branches.
- The supreme intercostal artery is the highest of all intercostal arteries and supplies the upper two intercostal spaces, the deep neck and back muscles, the skin of the back and the vertebral canal.
- As the trunk descends it gives rise to the deep cervical artery between the first rib and the seventh cervical vertebra which supplies the deep neck musculature.

Cervical Region

Very often the deep branch of the transverse cervical artery arises directly from the subclavian artery lateral to the anterior scalene muscle. It is then referred to as the dorsal scapular artery. In this case it passes through the brachial plexus, usually through the upper and superior trunk.

Brachial Artery

The brachial artery stems from the axillary artery and moves along the humerus (upper arm bone) down to the elbow. It gives rise to the deep brachial artery, which curves around the back of the humerus to supply blood to the triceps muscles (Fig. 19.18).

Shorter branches pass into various other muscles on the front of the upper arm, and others descend down each side of the elbow to join arteries in the forearms.To examine the *brachial artery* in the right arm, the examiner supports the patient's forearm in his left hand, with the subject's upper arm abducted, the elbow slightly flexed, and the forearm externally rotated. The examiner's right hand is then curled over the anterior aspect of the elbow to palpate along the course of the artery just medial to the biceps tendon and lateral to the medial epicondyle of the humerus. The position of the hands should be switched when examining the opposite limb.



Fig. 19.18: Study of brachial artery with vascular Doppler which communicates by way of its neck (arrow) with the radial artery (RA)

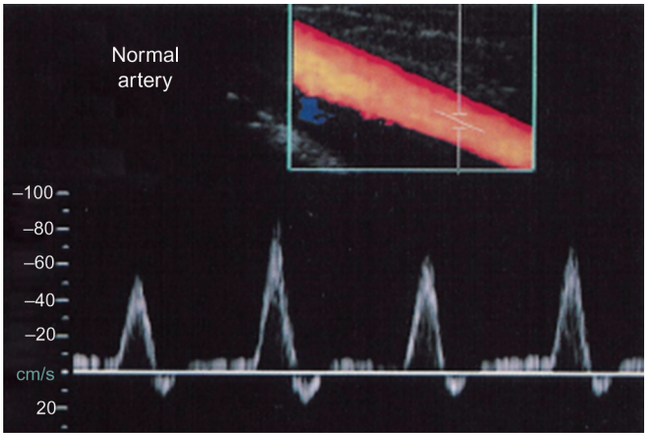

Fig. 19.19: Doppler flow of brachial artery showing normal velocity of this vessel

Radial Artery

For the radial artery the patient's forearm should be supported in one of the examiner's hands and his other hand used to palpate along the radialvolar aspect of the subject's forearm at the wrist.

This can best be done by curling the fingers around the distal radius from the dorsal toward the volar aspect, with the tips of the first, second, and third fingers aligned longitudinally over the course of the artery (Fig. 19.20).

Aorta

The aorta is the largest artery of your body, and it is a strong and sturdy vessel. In this lesson, you will learn about its downward path through the chest and abdomen and discover the organs and structures supplied by its branches (Figs 19.21 and 19.22).

Descending Aorta

The largest artery in your body is called the aorta (Figs 19.23–19.31). We previously learned that it originates at the left ventricle of the heart and ascends a short distance before making a U-turn at the aortic arch and plunging downward through your chest, which is referred to as the thorax, and into your abdomen. In this lesson, you will learn about the descending aorta, which begins at the aortic arch and is divided into two sections, the thoracic and the abdominal aorta.

The main thing to note about the descending aorta is that it has a number of branches coming off of it, much like back roads would come off of a highway. These branches

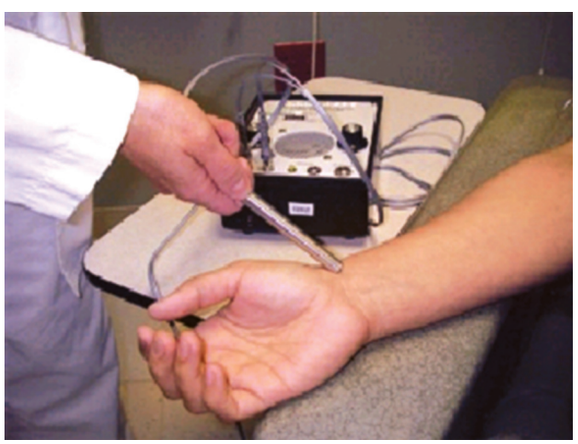

Fig. 19.20: Study of radial artery with vascular Doppler

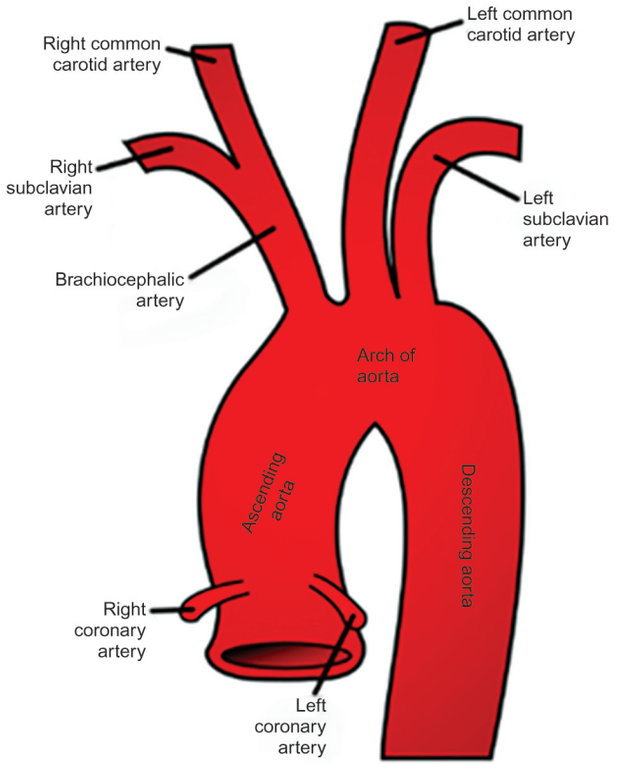

Fig. 19.21: Ascending aorta, emerging left and right coronary arteries, arch of aorta with its branches and descending aorta

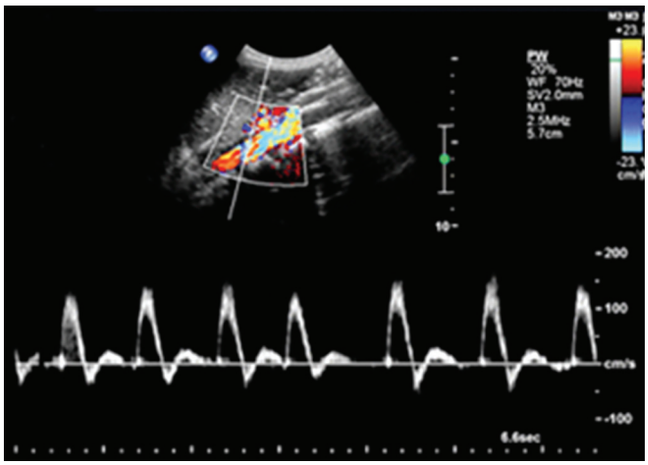

Fig. 19.22: Normal Doppler spectrum from the upper abdominal aorta in a 20-year-old boy shows a typical waveform characterized by a sharp increase in antegrade flow velocity during systole, followed by a reversal of flow in early diastole and then low-velocity antegrade flow in the remainder of diastole

feed the organs and structures within the thorax and abdomen before terminating into two final branches that eventually supply the legs.

The aorta is a very large artery and where it originates, right off of the left ventricle of the heart, it's about the size of a garden hose. It maintains this large size and decreases only slightly in size as it runs down through your body to its end. The different sections of the aorta are named for their location.

Thoracic Aorta

Therefore, we see that the section that runs through your thorax is named the thoracic aorta. This portion of the aorta spans from the aortic arch to the level of the diaphragm. The thoracic aorta has a number of paired blood vessels that branch off like back roads off of a highway. If you think about the organs and structures that are found in your chest, you will easily be able to tell where these branches travel (Fig. 19.23).

For instance, there's a paired branch of arteries that come off of the thoracic aorta that feed the lungs, there are branches that feed your esophagus, which lies deep and runs through your thoracic cavity. There are also branches that feed the surrounding structures, including the diaphragm, which lies at the bottom of the thoracic region, just below the lungs and just above the liver.

Abdominal Aorta

The abdominal aorta is the next section of the aorta, and it travels from the diaphragm through the abdominal cavity. It travels just anterior to your spinal column. In fact, it travels so close to your spine that it traces the natural curve of your lumbar spine (Fig. 19.23).

The first branch off of the abdominal aorta is called the **celiac trunk**. You can recall this term by remembering that the word 'celiac' is the anatomical term that refers to the abdomen.

The celiac trunk is a single vessel, but it has three branches. If you think about the abdominal aorta as a major highway, then the celiac trunk can be thought of as an exit ramp that leads to three back roads. Here again, if you think abut the organs and structures that are found in the top portion of your abdomen, then you will have a good idea of what these back roads, or branches, feed. What we find is that the branches supply blood to the stomach, the spleen, the pancreas, and the liver.

Additional branches off of the abdominal aorta supply the remaining organs and structures of the abdomen, including the intestines, kidneys, reproductive organs, and muscles of the region. These branches are not simply named branch 1, branch 2, branch 3, but their naming system is still pretty easy to remember. The reason that it's easy to remember is because these branches are often named for the organs or area that they supply. For instance, the term 'renal' stands for 'kidneys,' and the renal arteries come directly off of the abdominal aorta and serve the kidneys.

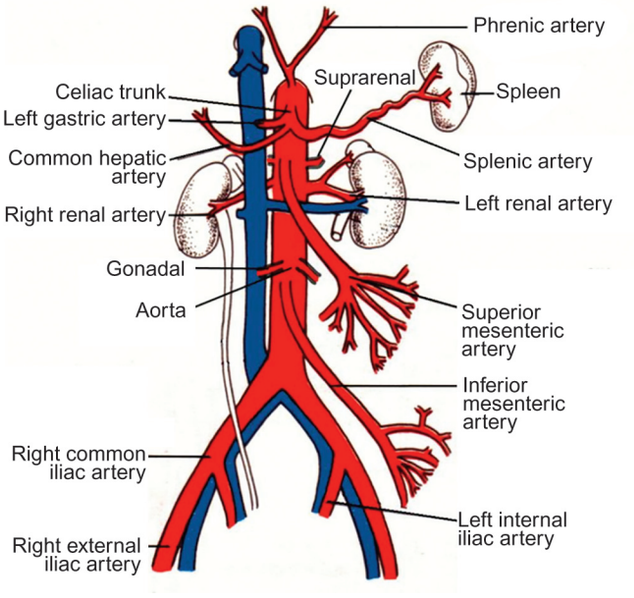

Fig. 19.23: Arterial system of the abdomen

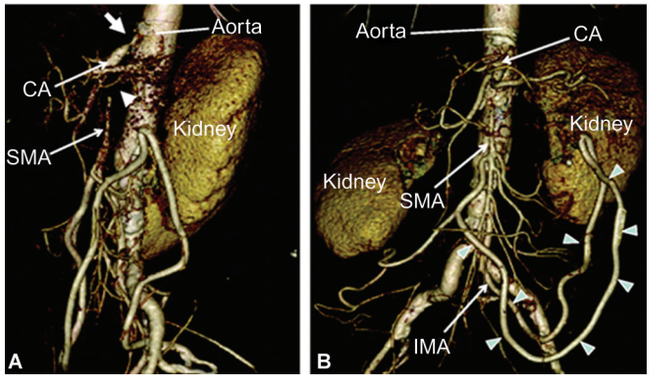

Fig. 19.24: Volume-rendered CT angiograms demonstrate the normal anatomy of the celiac axis. The left gastric artery (arrow) is seen to arise from the celiac axis

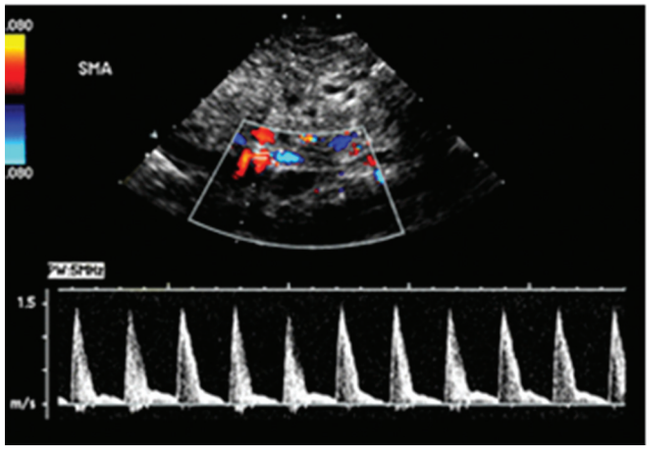

Fig. 19.25: Normal spectral waveforms in the superior mesenteric artery. Fasting waveform from a person showing a high-resistance flow pattern

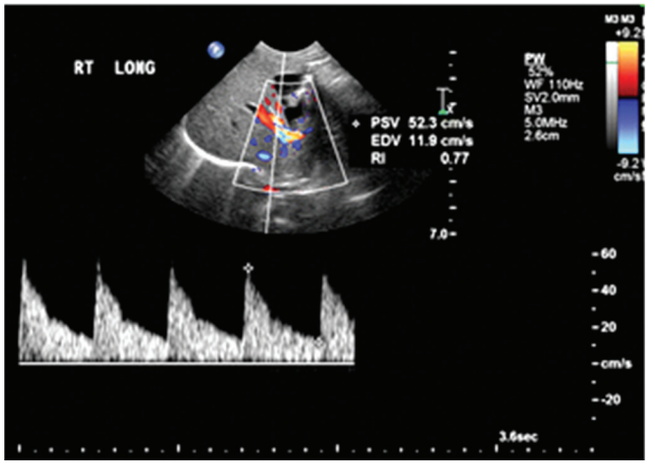

Fig. 19.26: Normal spectral waveforms from different segments of the hepatic artery. Spectrum from the hepatic artery at the porta hepatis in a patient with low-resistance and high-velocity diastolic flow

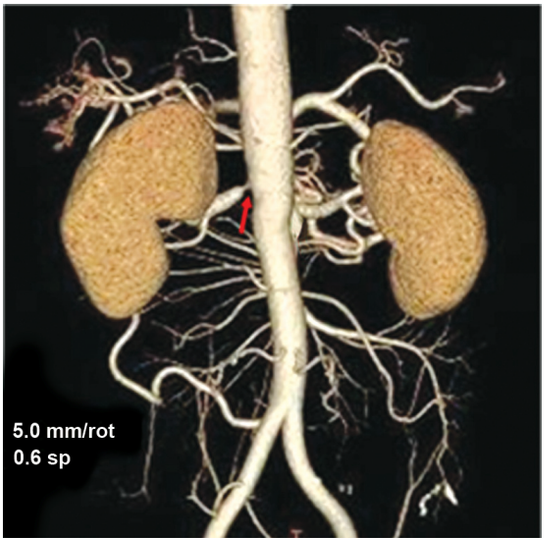

Fig. 19.27: A MD computed tomographic renal angiogram with right sided renal artery stenosis (arrow)

At this point, there is the end of the abdominal aorta as it splits into two final branches called the right and left common iliac arteries. The term 'iliac' comes from the fact that the vessels are situated near the large pelvic bone called the ilium. These arteries split at the level of the pelvis and travel down toward each leg. Therefore, they supply blood to the pelvic organs and legs. This would include the bladder, rectum, reproductive organs, and muscles of the lower extremities.

Branches of the Abdominal Aorta Mnemonic

Here's a mnemonic which can help the readers to remember the branches of the abdominal aorta from superior to inferior—**C**anned **S**oup **R**eally **G**ood **I**n **C**ups.

- **C**eliac trunk
- **S**uperior mesenteric artery
- **R**enal arteries
- **G**onadal arteries
- **I**nferior mesenteric artery
- **C**ommon Iliacs

The branches of the celiac trunk are common hepatic, left gastric, and splenic artery. The branches of the splenic artery are left gastroepiploic artery and short gastric arteries.

Middle Suprarenal Artery

- These arise level with the superior mesenteric artery.
- The right passes behind the IVC.
- Both are related to the coeliac ganglion of the respective sides.
- These anastomose with the suprarenal branches of the inferior phrenic and renal arteries.

Renal Vessels

- These two larger arteries branch from the aorta, just inferior to the level of the superior mesenteric artery (Figs 19.27–19.30).

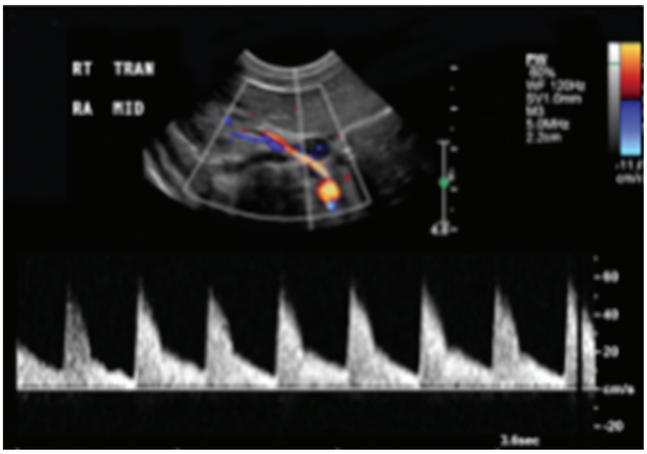

Fig. 19.28: Normal spectral waveforms from renal arteries. Spectrum from the midportion of the right renal artery in a person with a prominent systolic peak, with antegrade flow throughout diastole

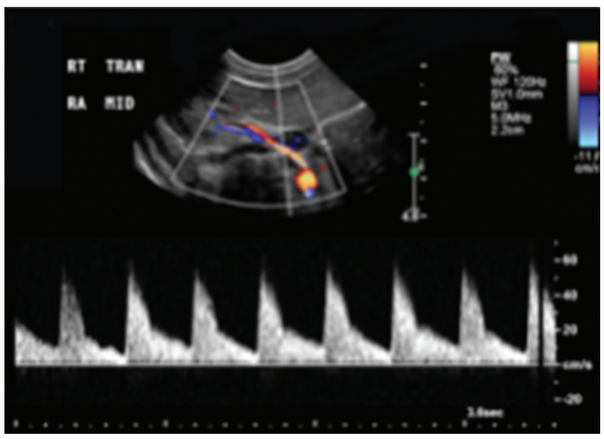

Fig. 19.29: Normal spectral waveforms from renal arteries. Spectrum from an intraparenchymal renal artery in a preterm 6-day-old girl

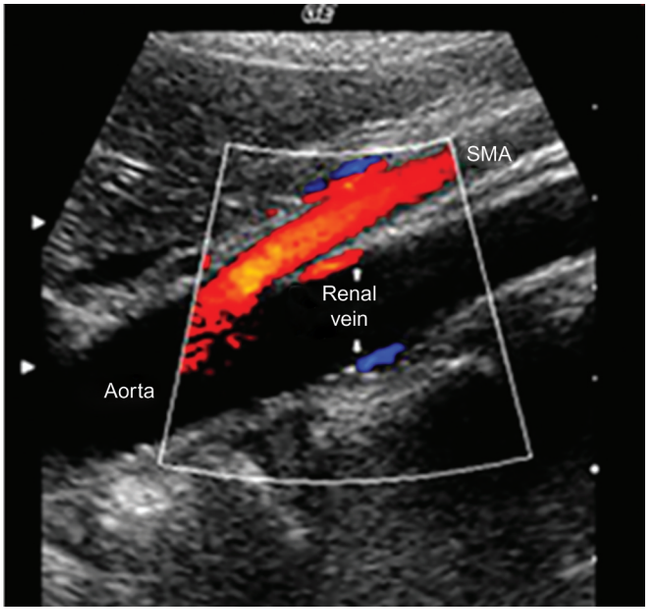

Fig. 19.30: Anomalous left renal vein. The patient has a retroaortic left renal vein. A sagittal color-Doppler image captured in diastole shows the renal vein in cross section on each side of the abdominal aorta

- The right is longer and passes posterior to the IVC, right renal vein, body of the pancreas and descending part of the duodenum.
- The left passes posterior to the left renal vein, body of the pancreas and splenic vein.
- Each of these divides into 4 or 5 branches.
- Each renal artery gives off an inferior suprarenal branch and supplies the ureter in its upper extent.

Testicular Artery (Fig. 19.31)

- These two arise anteriorly from the aorta, slightly inferior to the renal artery.
- Each passes anterior to the psoas major behind the parietal peritoneum.

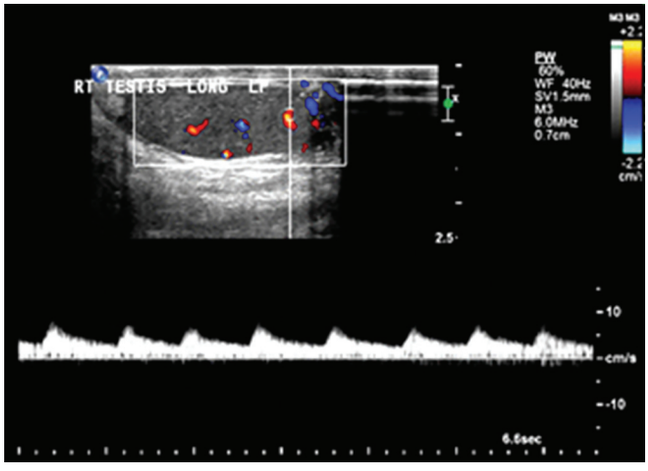

Fig. 19.31: Spectra from intratesticular arteries. Waveform shows a normal low-resistance flow pattern

- They then pass to the deep inguinal ring and enter.
- The testicular artery supplies the testis, perirenal fat, ureter, iliac lymph nodes and cremaster.

Ovarian Artery (Fig. 19.32)

- These correspond to the testicular arteries, but are obviously in the female.
- They enter the pelvis to supply the ovaries.
- After entering the suspensory ligament of the ovary, they continue into the broad ligament of the uterus.
- Branches are given off to the ovary, ureter, uterine tubes and one branch passes to the side of the uterus to anastomose with the uterine artery. Other branches follow the round ligament of the uterus to the inguinal ligament and supply the skin of the labium majus.

Common Femoral Artery

The *common femoral artery* (Figs 19.33 and 19.34) emerges into the upper thigh from beneath the inguinal ligament one-third of the distance from the pubis to the anterior

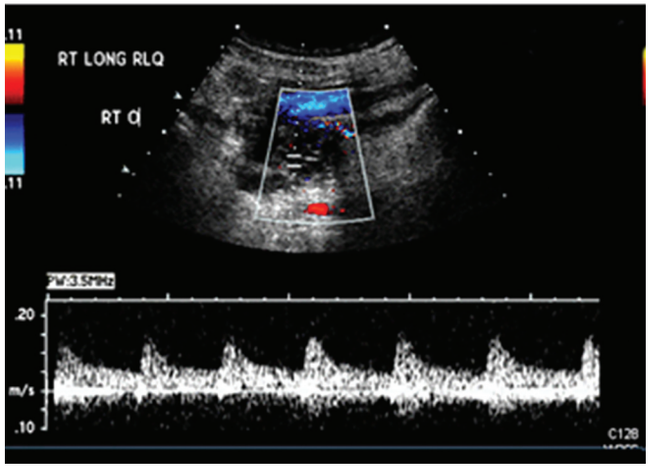

Fig. 19.32: Spectrum from a normal intra-ovarian artery in a person with low-resistance flow and a low PSV



Fig. 19.33: Palpation of right common femoral artery in inguinal region

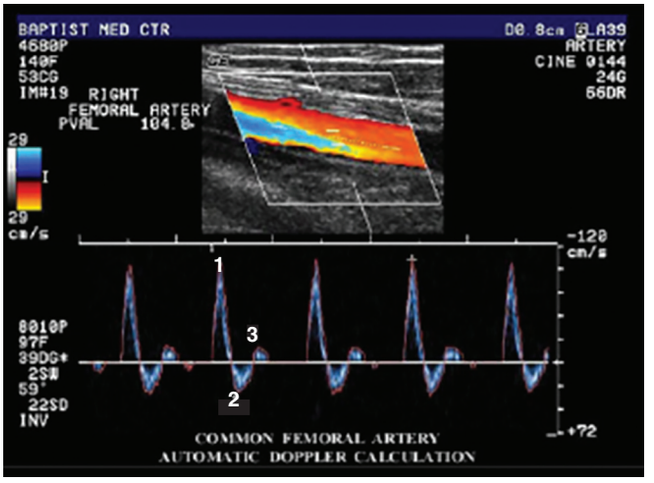

Fig. 19.34: A Doppler spectral waveform from a normal right femoral artery. The Doppler signal was obtained from a longitudinal view and with the Doppler sample volume placed in middle of the lumen. The characteristic triphasic Doppler signal shows a fast upstroke to peak systole (1), reversal of blood flow during early diastole (2), and a forward flow component during late diastole (3)

superior iliac spine. It is best palpated with the examiner standing on the ipsilateral side of the patient and the fingertips of the examining hand pressed firmly into the groin. Auscultation should be performed in this area, as well.

Popliteal Artery

The popliteal artery passes vertically through the deep portion of the popliteal space just lateral to the midplane (Fig. 19.35). It may be difficult or impossible to palpate in obese or very muscular individuals. Generally this pulse is felt most conveniently with the patient in the supine position and the examiner's hands encircling and supporting the knee from each side. The pulse is detected by pressing deeply into the popliteal space with the supporting fingertips. Since complete relaxation of the muscles is essential to this examination, the patient should be instructed to let the leg 'go limp' and to allow the examiner to provide all the support needed.



Fig. 19.35: Doctor palpating popliteal artery in popliteal fossa with application of fingers of both of his two hands

Posterior Tibial Artery

The *posterior tibial artery* lies just posterior to the medial malleolus. It can be felt most readily by curling the fingers of the examining hand anteriorly around the ankle, indenting the soft tissues in the space between the medial malleolus and the Achilles tendon, above the calcaneus. The thumb is applied to the opposite side of the ankle in a grasping fashion to provide stability. Again, obesity or edema may prevent successful detection of the pulse (Fig. 19.36).

Dorsalis Pedis Artery

The *dorsalis pedis artery* (Fig. 19.37) is examined with the patient in the recumbent position and the ankle relaxed. The examiner stands at the foot of the examining table and places the fingertips transversely across the dorsum of the forefoot near the ankle. The artery usually lies near the



Fig. 19.36: Palpating posterior tibial artery



Fig. 19.37: Palpating dorsalis pedis artery

center of the long axis of the foot, lateral to the extensor hallucis tendon but it may be aberrant in location and often requires some searching. This pulse is congenitally absent in approximately 10% of individuals.

Bruits

After palpating the artery, auscultation for a bruit should be performed. Bruits are detected by auscultation over the large and medium-sized arteries (e.g. carotid, brachial, abdominal aorta, femoral) with the diaphragm of the stethoscope using light to moderate pressure. Excessive pressure may produce, intensify, or prevent a bruit from being detected by indenting the vessel wall or occluding blood flow in the artery.

One should listen over the artery after palpation of the artery to avoid overlooking a significant lesion. Occasionally, bruits are audible over the upper abdomen in young, healthy individuals. These sounds apparently originate from tortuous vessels and are of no clinical significance; if the subject has a normal blood pressure and is free of abdominal symptoms, such findings may be disregarded. Frequently the examiner will detect a "thrill" or palpable vibratory sensation over a vessel in which a loud bruit is audible. The thrill is indicative of marked turbulence in local blood flow and suggests significant vascular pathology. If a thrill is noted during examination of the pulses, it should be recorded in the appropriate space on the data base (Figs 19.38 and 19.39).



Fig. 19.38: Auscultation over the carotid artery

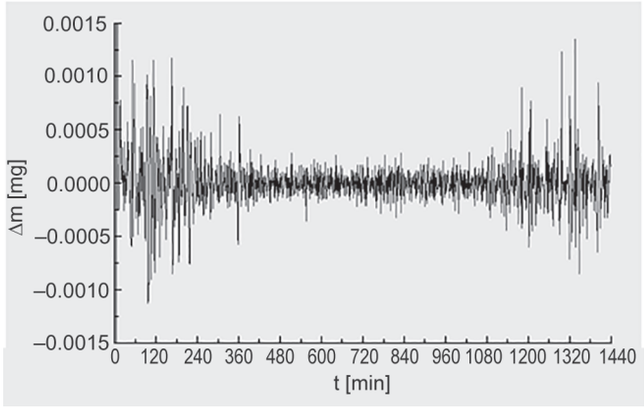

Fig. 19.39: A carotid bruit is an abnormal sound from the heart. The sound is in synchronization with the heartbeat. It is generally caused by turbulent blood flow, caused by irregularities in the wall of the blood vessel or by an abnormal connection (fistula) between an artery and vein. A bruit that is normally heard over the carotid artery is a sign that there are fats in the wall of the vessel. The bruit can be heard by using a stethoscope to listen to blood flow in the carotid artery. The carotid artery is the main artery in the neck region and is responsible for bringing blood to the head. A bruit indicates a fatty buildup (atherosclerosis) in the artery. Carotid bruit is a sign of the person's higher stroke risk

Venous System of the Abdomen

Peripheral venous disease is a term describing damage, defects or blockage in the veins that carry blood from the hands and feet to the heart. Peripheral venous disease can occur almost anywhere in the body but is mostly seen in the arms and legs (Fig. 19.40).

Phlebitis

With the patient supine, the veins of the extremities usually cannot be palpated but can be examined by inspection. Phlebitis most commonly occurs in the superficial arm veins and the deep veins of the lower extremity (Figs 19.41 and 19.43).

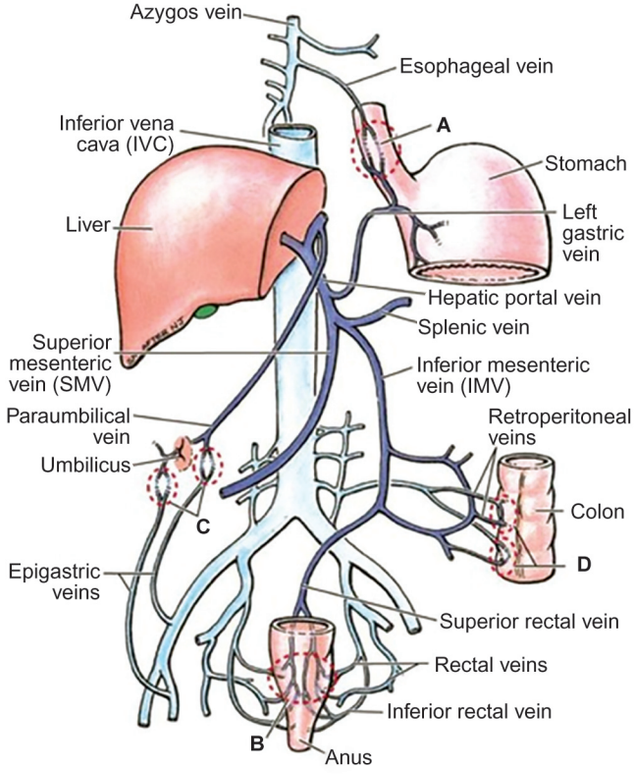

Fig. 19.40: Venous system of the body

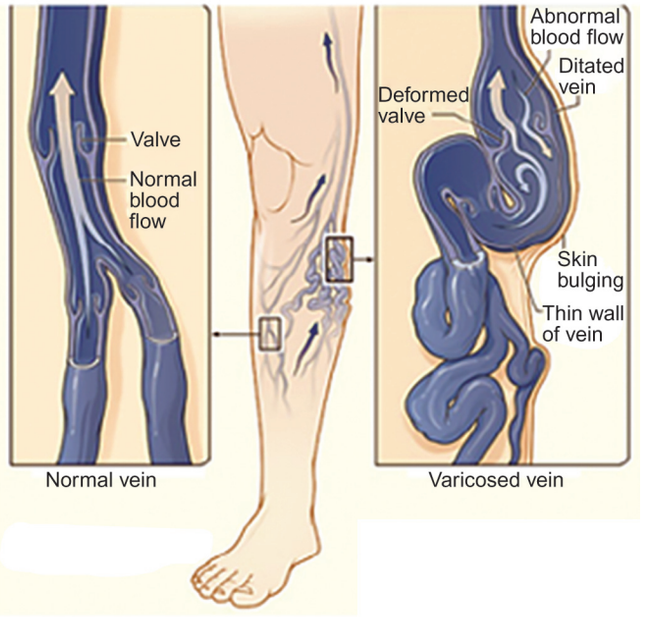

Fig. 19.41: The illustration shows how a varicose vein forms in a leg. (A) shows a normal vein with a working valve and normal blood flow, (B) shows a varicose vein with a deformed valve, abnormal blood flow, and thin, stretched walls. The middle image shows where varicose veins might appear in a leg

Arm vein phlebitis is suggested by noting erythema occurring along the course of the vein, which may be tender to palpation if secondary venous thrombosis has occurred; this may be palpable (i.e. a 'cord'). Lower extremity thrombophlebitis can be clinically silent and may be very difficult to detect by physical examination. Changes secondary to the venous obstruction may develop and be observed as increased thigh or calf girth, erythema, warmth, tenderness, or palpation of a cord. Numerous laboratory techniques have been developed to assist the physician in the search for lower extremity thrombophlebitis. Measurement of calf circumference should be obtained in all patients with suspected lower extremity thrombophlebitis. This should be done with the patient standing and the feet 30 cm apart. The maximum circumference is recorded and a significant difference exists if the two sides differ by 1.5 cm in males and 1.2 cm in females. Skin erythema or warmth may be noted in active phlebitis. A thrombosed segment of vein (i.e. a cord) may be palpable, especially in the superficial veins of the lower extremity.

Pain is a prominent feature of muscular, synovial, or vascular leg disease and various tests have been suggested to help identify the specific aetiology. Homan's test **(dorsiflexion sign**) is most popularly used to detect irritability of the posterior leg muscles through which inflamed or thrombosed veins course. A popular clinical misconception is that calf pain is the endpoint of the test; however, Homan clearly stated that 'discomfort need have no part in this reaction.' A positive sign is when dorsiflexion of the foot on the affected side is less complete or is met with more resistance than on the unaffected side. Resistance to dorsiflexion may also be manifested by involuntary



Fig. 19.42: Arterial obstruction in the leg with swelling, redness and skin discoloration



Fig.19.43: DVT in the right leg with swelling and redness

flexion of the knee. The **Lowenberg cuff test** is another helpful clinical manoeuvre for detection of calf vein thrombosis. Wrap a blood pressure cuff around the thigh just above the knee, taking care not to pinch the skin behind the knee. Close the valve and inflate the cuff gradually to 180 mmHg. Ask the patient to tell you of any unusual discomfort. Minimal discomfort immediately under the cuff is common. Spontaneous complaint of calf pain at 20–80 mmHg (that is, above venous pressure) is highly suggestive of local venous disease, particularly if 150–180 mmHg contralateral thigh pressure is well tolerated.

Other symptoms and signs include Moses' test (calf pain greater with anteroposterior than side-to-side palpation), localized leg pain on coughing (**Lawrence's sign**), and tenderness to touch in the sole of the foot **(Owane's sign).**

Classification: Peripheral artery occlusive disease. It is commonly divided in the Fontaine stages, introduced by René Fontaine in 1954 for ischemia:

- **Stage I**: Asymptomatic, incomplete blood vessel obstruction
- **Stage II**: Mild claudication
- **Stage IIA**: Claudication at a distance of greater than 200 metres
- **Stage IIB**: Claudication distance of less than 200 metres

- **Stage III**: Rest pain, mostly in the feet
- **Stage IV**: Necrosis and/or gangrene of the limb

A more recent classification by Rutherford consists of three grades and six categories.

- **Category 0**: Asymptomatic
- **Category 1**: Mild claudication
- **Category 2**: Moderate claudication
- **Category 3**: Severe claudication
- **Category 4**: Rest pain
- **Category 5**: Minor tissue loss; ischemic ulceration not exceeding ulcer of the digits of the foot
- **Category 6**: Major tissue loss; severe ischemic ulcers or frank gangrene

EPIDEMIOLOGICAL FEATURES

The prevalence of peripheral vascular disease in the general population is 12–14%, affecting up to 20% of those over 70; 70–80% of affected individuals are asymptomatic; only a minority ever require revascularisation or amputation. Peripheral vascular disease affects 1 in 3 diabetics over the age of 50.

In the USA peripheral arterial disease affects 12–20 percent of Americans age 65 and older. Approximately 10 million Americans have PVD. Despite its prevalence and cardiovascular risk implications, only 25% of PAD patients are undergoing treatment.

The incidence of symptomatic PVD increases with age, from about 0.3% per year for men aged 40–55 years to about 1% per year for men aged over 75 years. The prevalence of PVD varies considerably depending on how PAD is defined, and the age of the population being studied. Diagnosis is critical, as people with PAD have 4–5 times higher risk of heart attack or stroke.

The Diabetes Control and Complications Trial and The United Kingdom prospective diabetes study trials in people with type 1 and type 2 diabetes, respectively, demonstrated that glycemic control is more strongly associated with microvascular disease than macrovascular disease. It may be that pathologic changes occurring in small vessels are more sensitive to chronically elevated glucose levels than is atherosclerosis occurring in larger arteries.

For many people, there are no symptoms of PVD. For others, the first signs of PVD begin slowly and irregularly. You may feel discomfort in your legs and feet. You may experience:

- Painful cramping
- Achiness
- Fatigue
- Burning

Typically, you will feel these sensations when you walk. You may first notice them when walking quicker, with more exertion, or for long distances. The pain will intensify with activity and subside when you rest. This is called intermittent claudication. Intermittent claudication occurs because your muscles need more blood flow during activity. In PVD, the vessels are narrowed with plaque. They can only supply a limited amount of blood. This causes more problems during activity than at rest. Lack of blood causes pain and discomfort. As your PVD progresses, symptoms will occur more frequently. It will require less exertion to bring them on. Eventually, you will experience leg pain and fatigue even at rest.

Additional symptoms may occur as a result of reduced blood supply. With PVD, you may have:

- Skin changes on your legs and feet (thinning, shiny, or paleness may occur)
- Weak pulses in your legs and feet
- Gangrene—tissue death caused by lack of blood flow
- Wounds or ulcers on the legs and feet that won't heal
- Reduced hair growth on your legs
- Toes that turn blue
- Severe burning pain in your toes
- Leg cramps and pain when you are lying in bed
- Muscles that feel numb or heavy
- Arms and legs that are reddish blue
- Toenails that are thick and opaque

It is important to tell your doctor if you experience any symptoms of PVD. Do not assume that the symptoms are simply the results of aging. Delaying diagnosis and treatment could allow the disease to progress further.

COMPLICATIONS OF PVD

Complications from undiagnosed and untreated PVD can be serious and even fatal (Figs 19.44–19.56). The restricted blood flow of PVD can be a warning sign of other forms of vascular disease. When arteries leading to the heart and brain become clogged with plaque, it can cause:

- Heart attack
- Stroke
- Death

Complications of PVD can include:

- Bood clots that obstruct small arteries
- Coronary artery disease
- Limb amputation due to tissue death in the limb
- Heart attack
- Impotence
- Pallor or paleness
- Pain when the legs are elevated
- Severe pain that restricts mobility
- Stroke
- Wounds that don't heal

If you have any of the classic symptoms of PVD, it is important to tell your doctor. Early diagnosis is crucial to successful treatment. It can prevent life-threatening complications, such as heart attack and stroke. To diagnose PVD, your physician will begin with a complete medical history and physical exam. Several tests may be used to diagnose PVD.

Your physician can check the pulses in your legs and feet with a stethoscope. A whooshing sound called a bruit indicates a narrowed area in the vessel.

Table 19.4: Risk factors for the development of peripheral arterial disease (PAD)

Risk factor	Feature of the risk factor
Modifiable factor	
Smoking	Cigarette smoking is the most powerful risk factor for the development of PAD. It is dose-dependent and the risk declines within 6 months of quiting. A non-smoker is 10 times less likely to develop PAD than a smoker
Blood lipid disorders	Plasma cholesterol levels of >5.2 mmol/L Increased plasma concentrations of low-density lipoprotein (LDL) cholesterol, low plasma concentrations of high-density lipoproteins (HDLs), and higher concentrations of plasma triglycerides all correlate with incraeased incidence of PAD Familial hyper cholesterolaemia (affecting 1:500 in UK) Familial combined hyperlipidaemia (affecting 1:250 in UK)
Diabetes mellitus (DM)	Type 2 DM increases risk of PAD by 1.5–4.0, due to the associated hypertension, hyperlipidaemia and altered vascular reactivity
Hypertension	Raised systolic blood pressure (BP) incareases the risk of PAD and atherosclerosis by 4 due to endothelial injury caused by increased intra-arterial shear stresses at the blood-endothelium interface (raised systolic pressure are more predictive than raised diastolic pressures)
Obesity	Central obesity is an independent risk for PAD, but also predisposesto other risk factors for PAD, such as type 2 DM, hypertension
Homocysteine	Homocyteine is an amino acid that in high levels is associated with thromboembolism
Haemostatic variables	Increased levels of clotting factors FXII, FXI, FIX prothrombin and fibrinogen are associated with increased risk of atherosclerosis
Sedentary lifestyle	Low levels of regular activity are associated with increased risk of PAD (higher levels of activity are associated with higher levels of plasma HDL-cholesterol and reduced blood pressures and facilitate the development of the collateral circulation.
Dietary deficiencies	Low levels of antioxidant vitamins (vitamins C and E) and polyunsaturated fatty acids facilitate the formation of oxidized LDLs and thus predispose to the risk of atherosclerosis.
Type A behaviours (TABs)	People who tend to aggression, ambitiousness, restlessness, time urgency and high anxietytend to an increased incidence of PAD, possibly due to increased levels of circulating catecholamines
Non-modifiable or fixed factor	
Age and sex	Atherosclerosis is more common in males, and in postmenopausal women
Family history	Atherosclerosis shows familial patterns of incidence, possibly due to genetic factors and/or lifestyle choices and patterns
Early environment	Fetal origins hypothesis—adverse conditions in utero or infancy pedispose to the risk of cardiovascular disease in later life (e.g. statistically, small-birth-weight babies have a higher incidence in adult life of hypertension, type 2 DM, altered plasma lipids, altered bone densities, altered stress responses, less elastic arteries, thicker-walled ventricles and 'age' quicker)



Fig. 19.44: Swelling of both legs in patient with cellulitis



Fig. 19.45: Massive edema. Note: Remaining imprint of fingers



Fig.19.46: Neuropathic ulcer in a patient with diabetic neuropathy



Fig. 19.47: Swelling and discoloration of right leg in patient with chronic arterial insufficiency with ulcers

INVASIVE AND NONINVASIVE TECHNIQUES IN PVD

Doppler ultrasound: This test shows the blood flow in your vessels. Ultrasound is not invasive. It uses sound waves to take images (Figs 19.44–19.56).



Fig. 19.48: Swelling and discoloration of left leg in a patient with venous stasis ulcer



Fig. 19.49: Ischemic changes with ulcer over left foot in patient with peripheral occlusive arterial disease

Ankle-brachial index (ABI) (Fig. 19.57 and Table 19.5): This is the most common test used to diagnose PVD. A blood pressure cuff and ultrasound assess blood pressure and flow. The blood pressure in your ankle is compared to the blood pressure in your arm. In some cases, readings will be taken before and after you walk on a treadmill. This helps demonstrate how the arteries react to exercise.

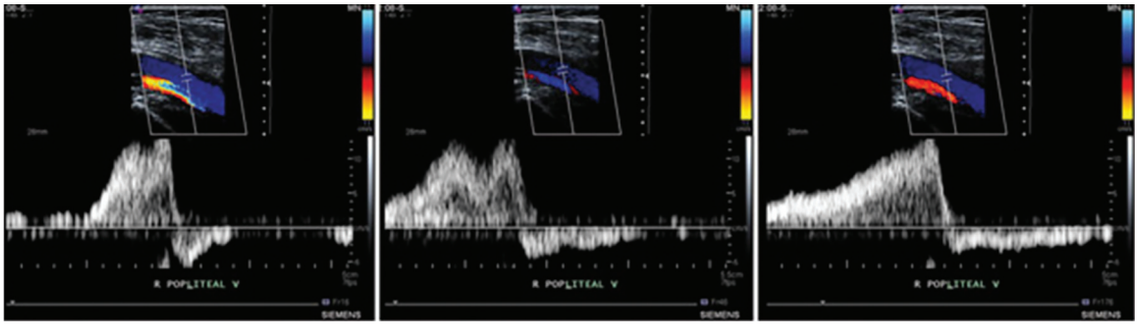

Fig. 19.50: Variability of reflux response. The effect of the length of augmentation on the tendency of lower extremity veins to reflux. All images are obtained from the same sample site in the popliteal vein of the same patient. Left image—short augmentation resulting in reflux time of only 0.7 seconds. Middle image—longer augmentation resulting in reflux time of 1.5 seconds. Right image—prolonged augmentation resulting in continuous reflux for many seconds

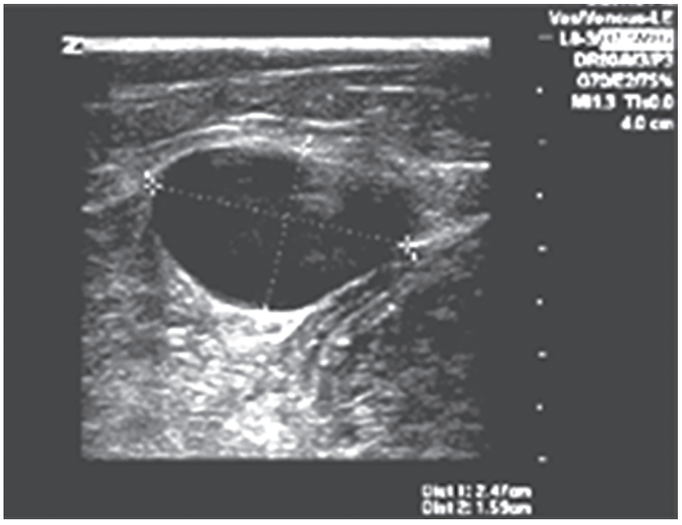

Fig. 19.51: Patient is a 59-years-old male that presented with swelling and aching of both lower extremities. He had bilateral varicose veins especially on the right with discoloration and stasis changes however no ulceration or previous ulceration was reported. He denied previous deep venous thrombosis or phlebitis. The patient was finally diagnosed as venous aneurysm of inferior vena cava



Fig. 19.52: Swelling and discoloration of right leg in patient with venous insufficiency

Pulse volume recording (PVR): This test checks the blood flow in your legs. Blood pressure cuffs are wrapped around one arm and leg as you are lying down. The cuffs are inflated slightly. As blood flows through the arteries, a device records the ability of the vessels to expand (Fig. 19.57).

Angiography: A catheter is guided through an artery in your groin. It is passed to the targeted area. Contrast dye is injected. An X-ray can then diagnose the clogged artery. By inflating a balloon at the end of the catheter, the artery can be opened in the same procedure (Figs 19.58–19.63).

Noninvasive imaging studies: These are noninvasive imaging techniques that allow doctors to view blood flow and diagnose blockages (Figs 19.65–19.69).

- Treat conditions such as diabetes, high blood pressure, or high cholesterol

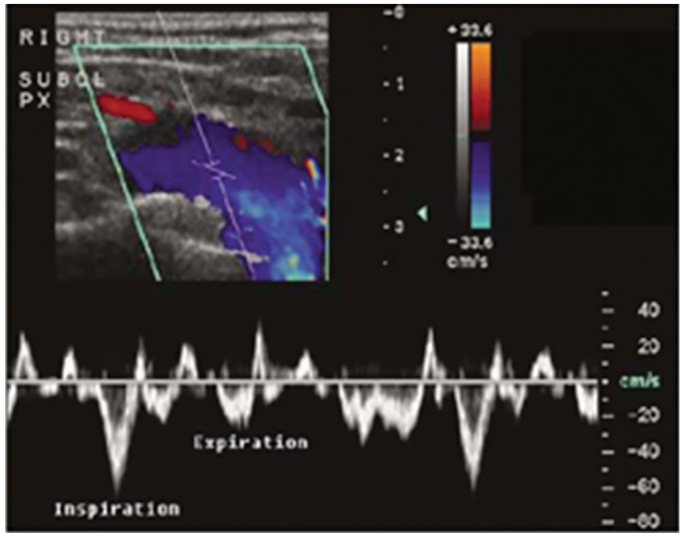

Fig. 19.53: Doppler spectra of the right subclavian vein from a healthy volunteer, which is characterized by two phasic variations in amplitude. The action of the right atrium is reflected back into the vessel and manifests as a choppy and sometimes biphasic flow pattern, otherwise known as cardiac pulsatility. Also notice the respiratory phasicity reflected in the spectral waveform. Considerable flow is seen with inspiration, whereas there is decrease in flow during expiration. Of note, there is increased pulsatility of the upper extremity spectral waveforms when compared with those of the lower extremity veins because of their proximity to the heart

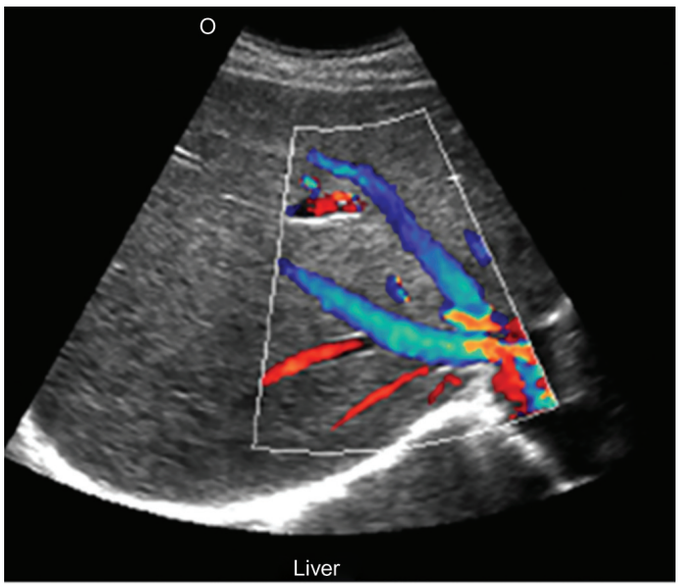

Fig. 19.54: Color-Doppler ultrasonography showing normal vasculature of the liver

- Smoking cessation is one of the most important ways to treat PVD. Smoking directly causes reduced blood flow in vessels.

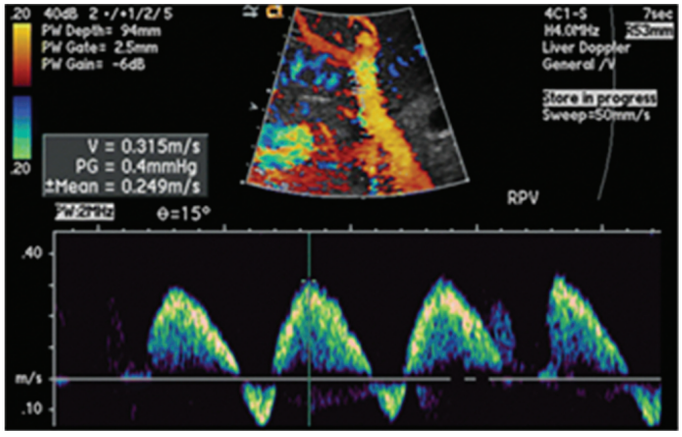

Fig. 19.55: Spectral Doppler ultrasound image shows a pulsatile waveform with flow reversal in the right portal vein. The waveform may be systematically characterized as predominantly antegrade, pulsatile, biphasic-bidirectional, and di-inflectional

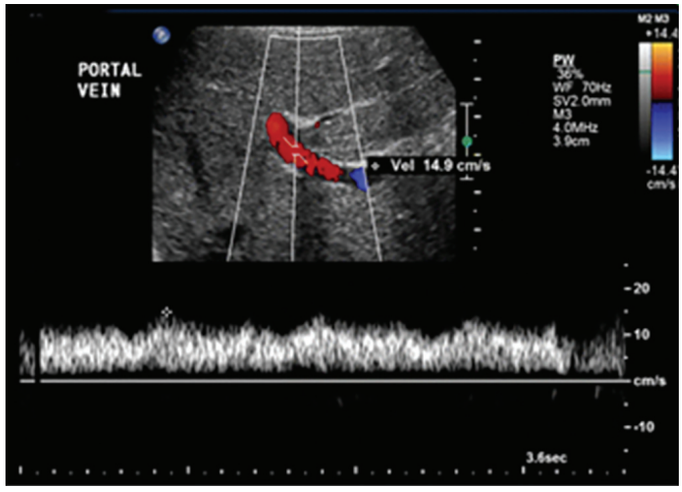

Fig. 19.56: Spectral waveform from the portal vein in a patient who shows a typical flow pattern, with fairly uniform velocity and slight phasic variations due to respiration and cardiac motion



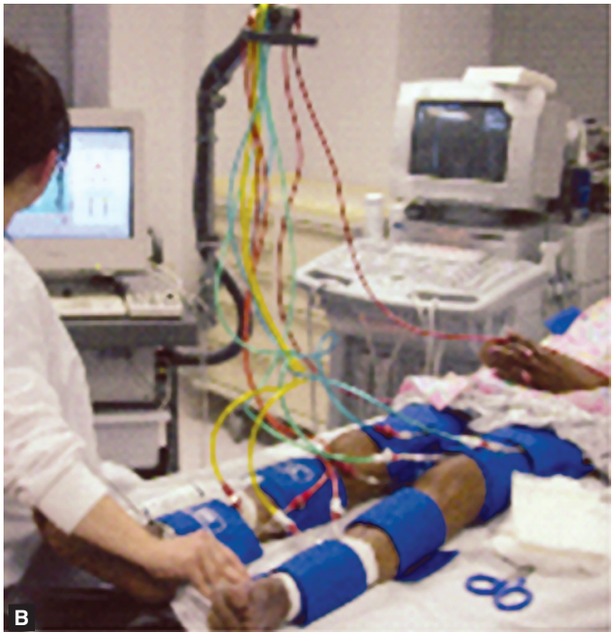

Fig. 19.57: (A) Pulse volume recording with plethysmography to various levels of legs, (B) pulse volume recording and segmental pressures measurements in patient with PVD

Table 19.5: Ankle-brachial index (ABI) results

ABI number	Diagnosis	What it means
1.00 to 1.29	Normal	Your ABI is in the normal range and you are not likely to have PAD
0.91–0.99	Borderline	Your ABI is slightly lower than normal, but not low enough to diagnose PAD. Your doctor may want to measure your ABI again soon to make sure it is not getting worst, or measure your ABI after exercise.
0.41–0.90	Mild-to-moderate PAD	You have PAD. Working with your doctor to get your risk factors under control can prevent the disease from getting worse, and treatments are available to help relieve your PAD symptoms.
0.40 to less	Severe PAD	The blood flow in your legs is severely obstructed, and you may need immediate treatment to relieve your symptoms and prevent serious complications.

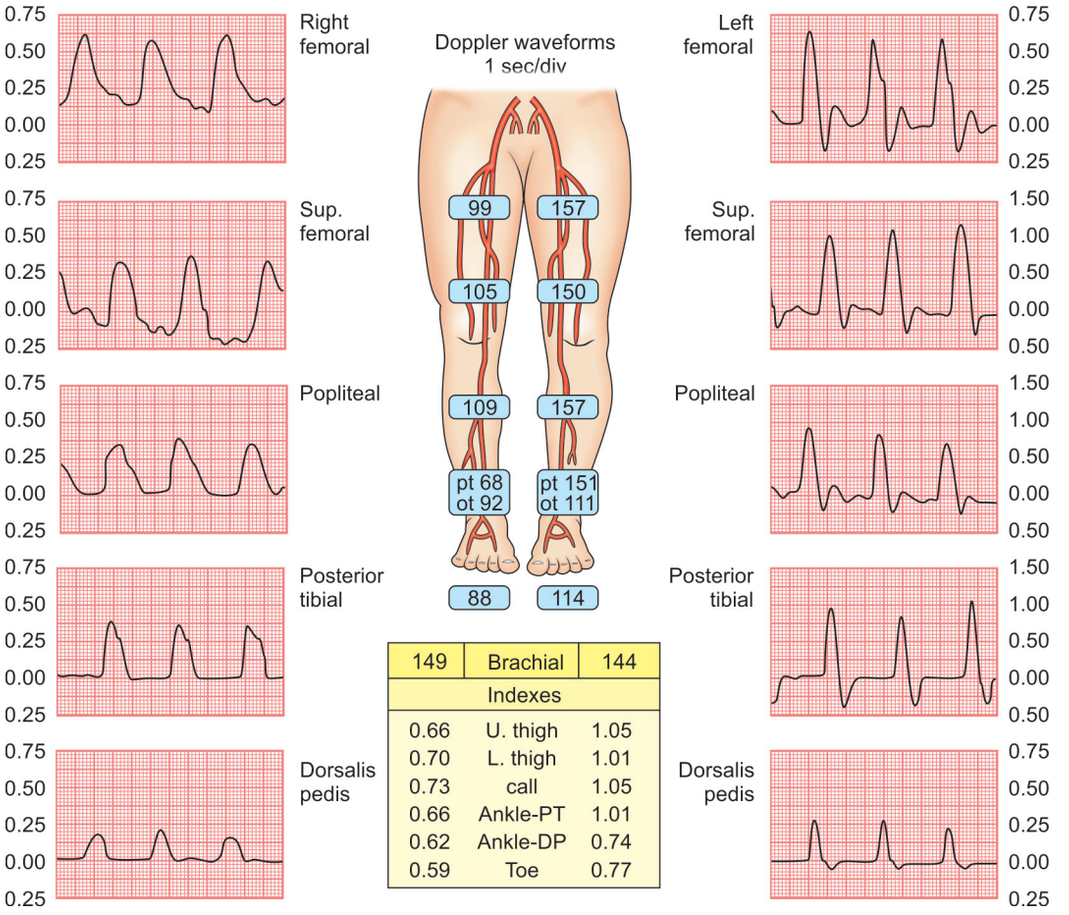

Fig. 19.57C: Typical report of peripheral vascular study with arterial segmental pressure measurement plus Doppler evaluation of the lower extremity

- If lifestyle changes do not control your PVD, you may need medication.

Treatment for peripheral vascular disease: There are two main goals for treatment of peripheral artery/vascular disease—control the symptoms and halt the progression of the disease to lower the risk for heart attack, stroke, and other complications. Specific treatment will be determined by your physician based on:

- Age, overall health, and medical history
- Extent of the disease
- Signs and symptoms
- Tolerance for specific medications, procedures, or therapies
- Expectations for the course of the disease
- Lifestyle modifications to control risk factors, including regular exercise, proper nutrition, and smoking cessation
- Aggressive treatment of existing conditions that may aggravate PVD, such as diabetes, hypertension, and hyperlipidemia (elevated blood cholesterol)
- Medications for improving blood flow, such as antiplatelet agents (blood thinners) and medications that relax the blood vessel walls Whether medication is a good choice for you depends on the underlying cause of your peripheral vascular disease. Medications used to treat peripheral vascular disease and intermittent claudication include those that aim to lower the risk and progression of atherosclerosis throughout the body, such as those to help stop smoking, lower blood pressure, lower cholesterol, and optimize the bloodsugar in people with diabetes.

MEDICATIONS

Pentoxifylline (trental): How this drug helps in intermittent claudication is not completely understood. It is believed to improve blood flow by decreasing the viscosity of blood and making red blood cells more flexible. With these alterations, the blood can move more easily past-obstructions in the blood vessel.

Cilostazol (pletal): This drug keeps platelets from clumping together. This clumping promotes formation of clots and slows down blood flow. The drug also helps dilate, or expand, the blood vessels, encouraging the flow of blood. Sudden blockage of an artery by a blood clot (thrombus) has been treated with medication for many years. Choices include antiplatelet agents, anticoagulants, and 'clot-busters' (thrombolytics).

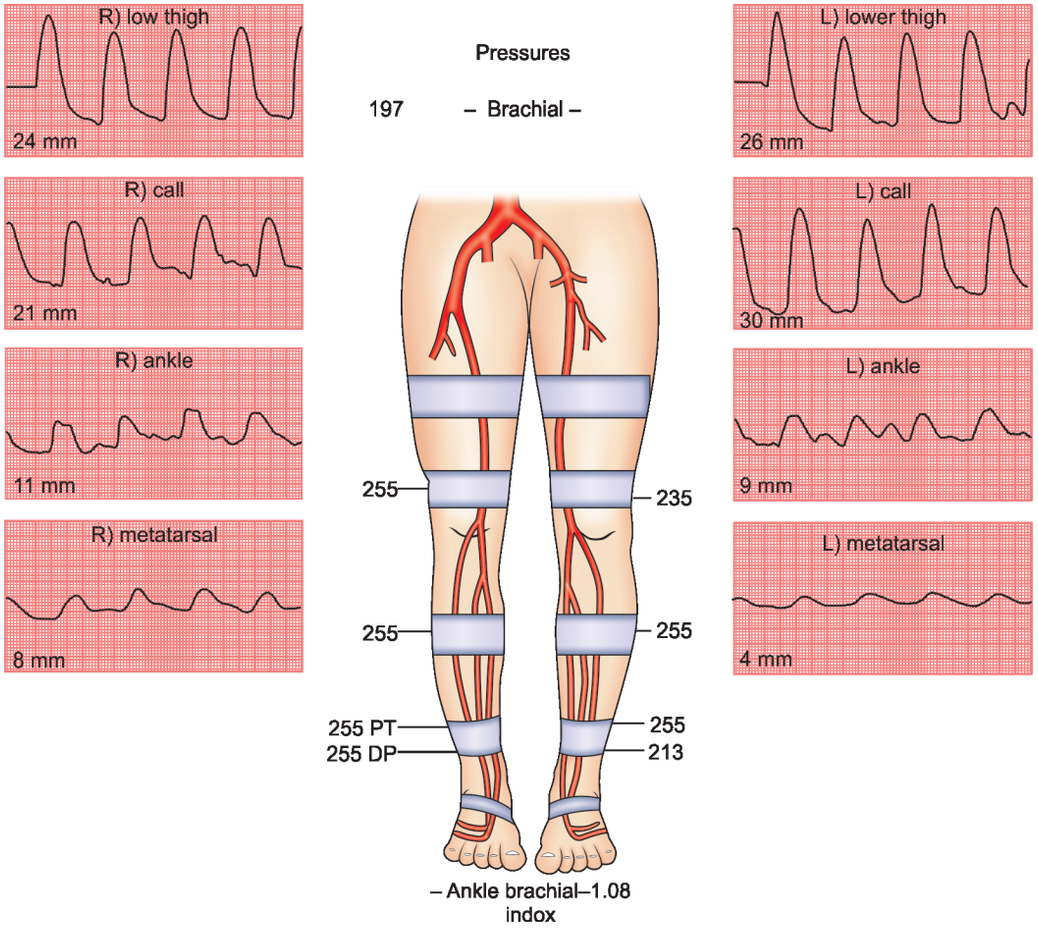

Fig. 19.57D: Segmental blood pressure, ABI, and PVRs at rest and after exercise. The tracings display PVRs taken at the thigh, calf, ankle, metatarsal, and toe. The lowest diagram depicts an ankle PVR after exercise. The ABIs at rest are 0.80 on the right and 1.16 on the left. The patient walked on a treadmill for 3 min 20 sec. The exercise was ended because of right calf pain. The ABIs after exercise are 0.45 on the right and 0.76 on the left. The right ankle pressure is 98 mmHg at rest and decreases to 65 mmHg with exercise. The left ankle pressure is 141 mmHg at rest and decreases to 108 mmHg with exercise. The brachial artery systolic pressure is 122 mmHg at rest and augments to 143 mmHg with exercise. Note the pressure drop between the right thigh and the right calf, and the lack of augmentation of the right calf pulse volume waveform, which are consistent with right superficial femoral artery or popliteal artery disease. The left side was normal at rest but the decrease in ankle pressure after exercise indicates that there is peripheral artery disease in the left leg as well. The location of disease cannot be determined on the left. ABI=ankle-brachial index; DP=dorsalis pedis; PT=posterior tibial; PVRs=pulse volume recordings

Antiplatelet agents: These include aspirin, ticlopidine, and clopidogrel. These agents do not get rid of an existing clot. They prevent further clots from forming by keeping blood cells and platelets from clumping together.

Anticoagulant agents include heparin, warfarin (coumadin), enoxaparin (lovenox), and low-molecular-weight heparin. These agents also do not remove an existing clot. They interfere with the sequence of blood clotting factors that causes a clot to form.

Thrombolytics: These are powerful drugs that can actually dissolve an existing clot. They can be used only under certain circumstances and are given only in the hospital. They can be injected directly into the blocked artery under angiographic guidance. To be effective, they have to be administered intravenously within the first 4–8 hours after a patient develops symptoms. The most effective medications are those that help prevent the development and progression of atherosclerosis.

Invasive and Minimal Invasive Treatment of Peripheral Vascular Disease (Figs 19.71–19.90)

Angioplasty: A catheter (long hollow tube) is used to create a larger opening in an artery to increase blood flow. Angioplasty may be performed in many of the arteries in the body. There are several types of angioplasty procedures, including:

- **Balloon angioplasty**—a small balloon is inflated inside the blocked artery to open the blocked area

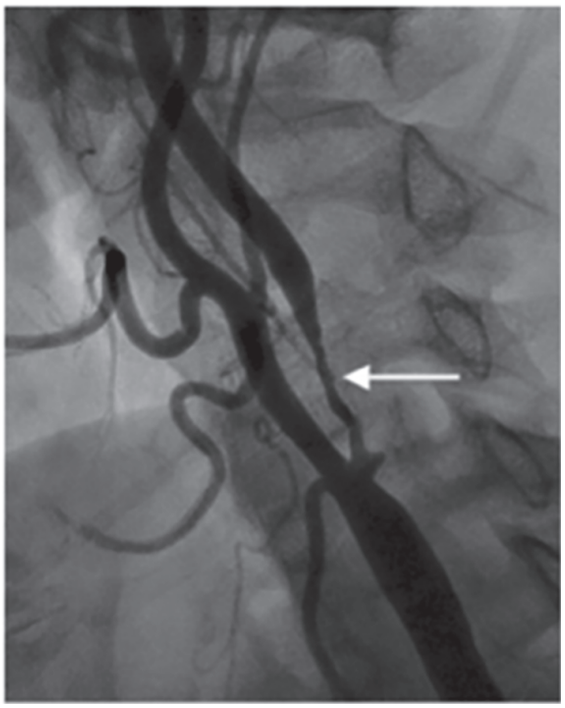

Fig. 19.58: Angiogram of carotid artery showing more than 90% of stenosis of left internal carotid artery (arrow)

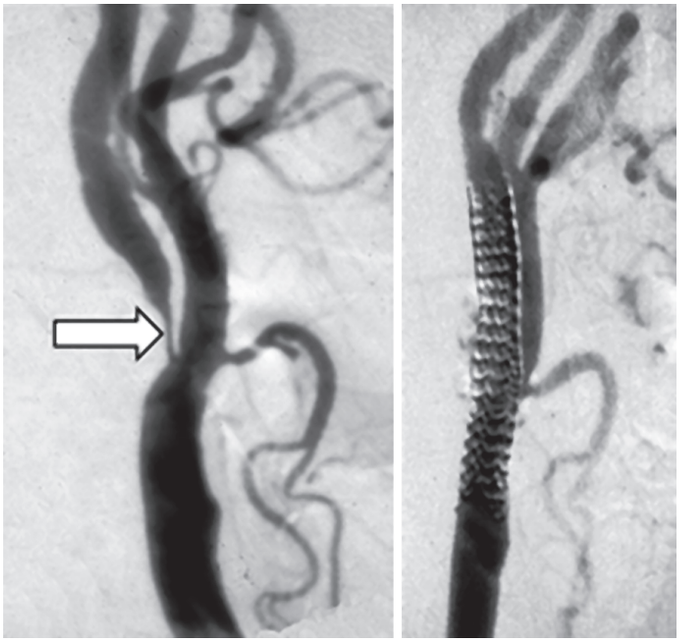

Fig. 19.60: Carotid angiography after injection of dye into the carotid artery showing severe carotid artery narrowing in the left hand figure (arrow). The right hand figure shows the appearances after the insertion of a metallic stent across the narrowing



Fig. 19.59: Red arrow points to site of occlusion. Arrow points to collateral filling of the distal portion of the internal carotid artery on delayed film

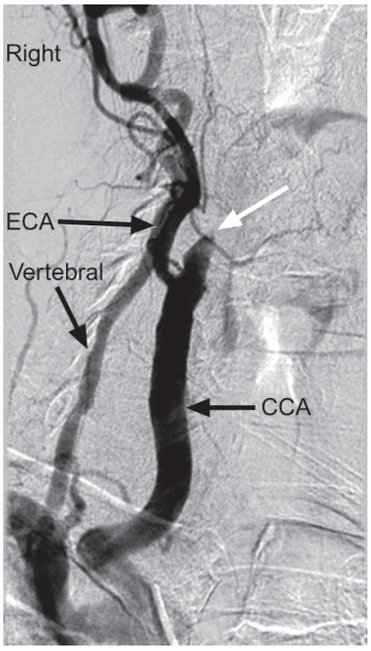

Fig. 19.61: Internal carotid artery stenosis white arrow—occlusion of internal carotid artery. ECA=external carotid artery; CCA=common carotid artery

- **Atherectomy**—the blocked area inside the artery is 'shaved' away by a tiny device on the end of a catheter
- **Laser angioplasty**—a laser is used to 'vaporize' the blockage in the artery

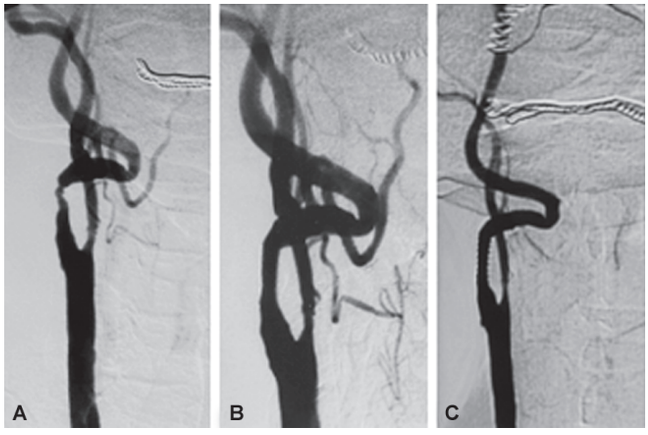

Fig. 19.62: (A) Right common carotid angiogram shows severe stenosis and tortuosity of the right ICA. (B) Control angiogram after stent placement. (C) Follow-up angiogram obtained at 6 months demonstrates a patent stent without stenosis



Fig. 19.63: Renal angiography showing renal artery stenosis in chronic persistent hypertension

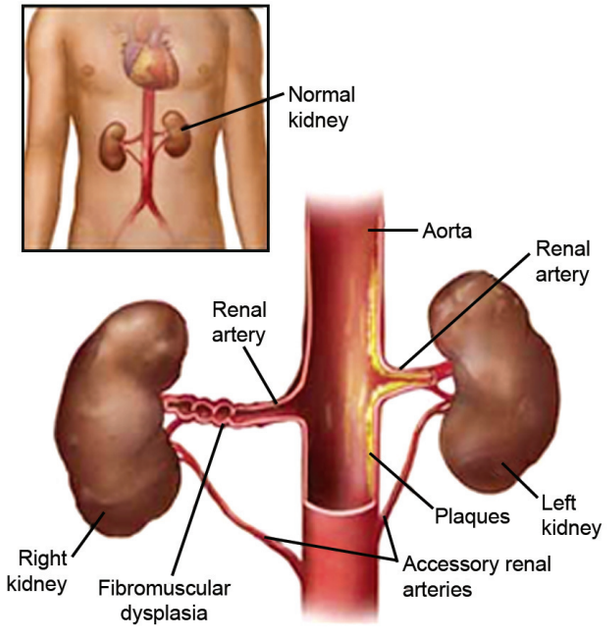

Fig. 19.64: Fibromuscular dysplasia in chronic persistent hypertension

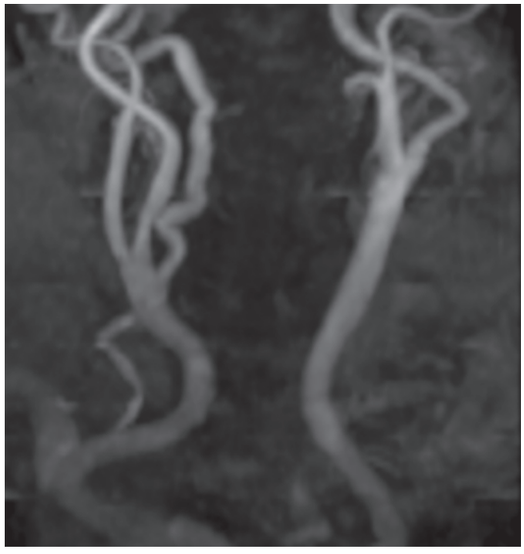

Fig. 19.65: High grade left proximal subclavian artery stenosis with signal loss of the left VA on time-of-flight images due to flow reversal. The normal antegrade flow signal of the left VA is missing in the 3D TOF images. On time-resolved 3D CE-MRA, the vessel shows delayed, retrograde contrast filling

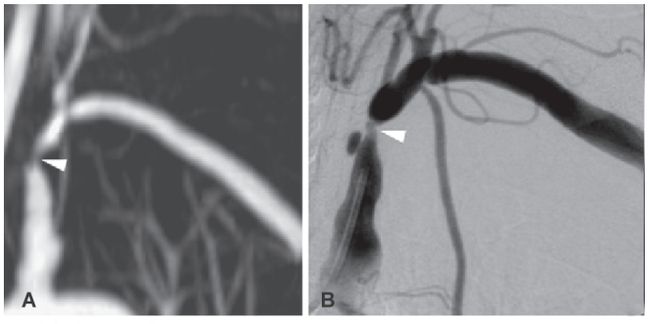

Fig. 19.66: (A) Typical example of a subclavian artery stenosis, initially detected by CE-MRA and (B) confirmed by DSA. The arrow indicates the location of the stenosis

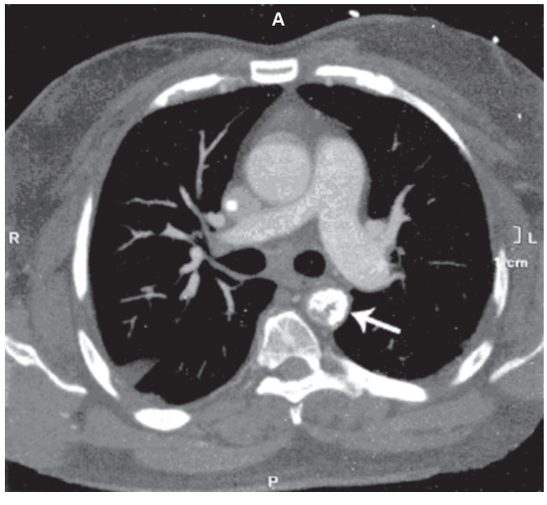

Fig. 19.67: 64 slice sagital section at the level of calcific plaque revealed nondilated descending thoracic aorta, densely calcific and lumen filled with superadded thrombus (white arrow)



Fig. 19.68: CE-MRA thin-slab MIP A. Max 3 cm aneurysm of the right subclavian artery giving rise to the vertebral artery, the thyrocervical trunk, and the internal thoracic artery

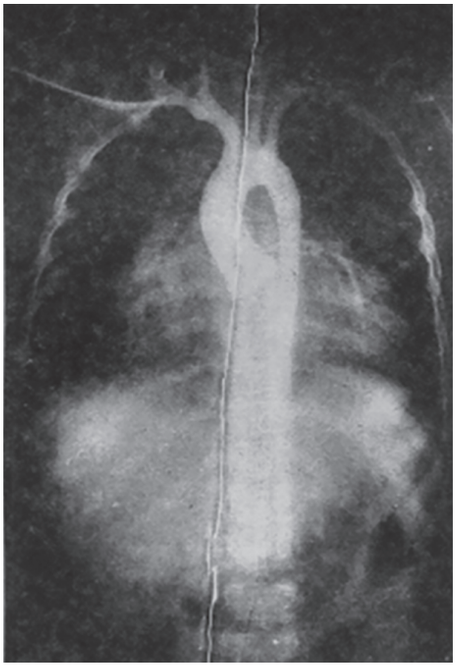

Fig. 19.70: Aortography showing narrowing of descending aorta in nonspecific aorto-arteritis syndrome

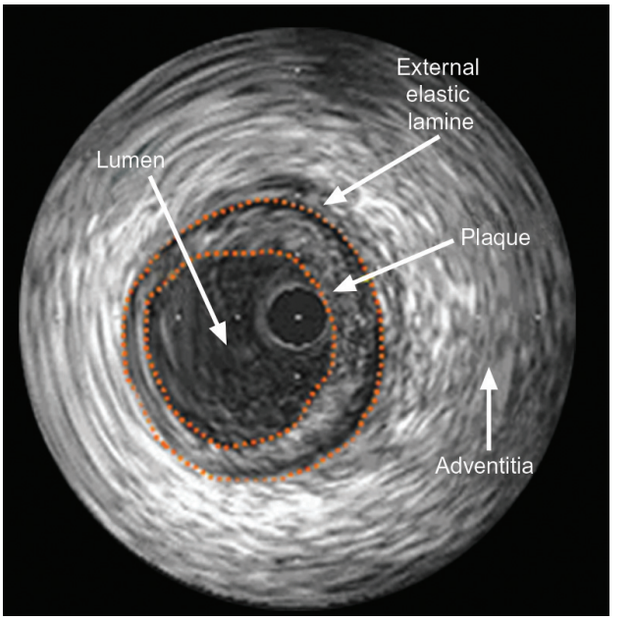

Fig. 19.69: IUVS scan of an artery showing all the three layers and plaque inside two circles

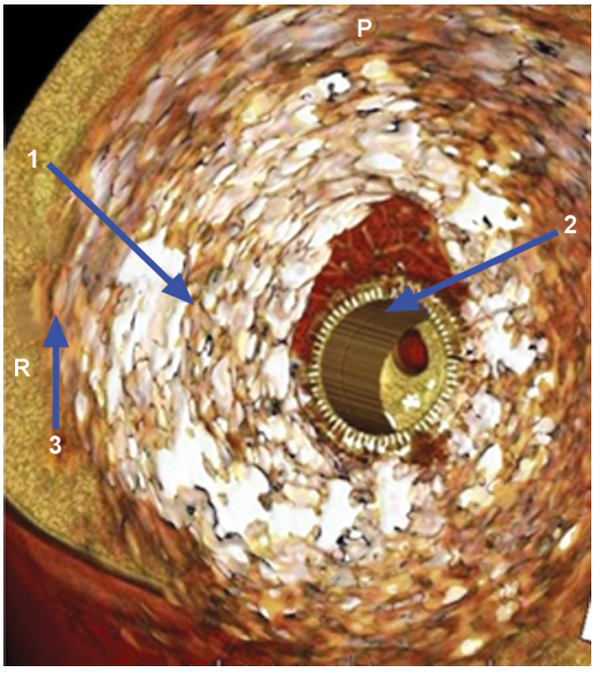

Fig. 19.71: Sectional anatomical structutes in superficial femoral artery. 1=stent, 2=artery and 3=IUVS catheter

- **Stent**—a tiny coil is expanded inside the blocked artery to open the blocked area and is left in place to keep the artery open
- **Vascular surgery**—a bypass graft using a blood vessel from another part of the body or a tube made of synthetic material is placed in the area of the blocked or narrowed artery to reroute the blood flow.

With both angioplasty and vascular surgery, an angiogram is often performed prior to the procedure.

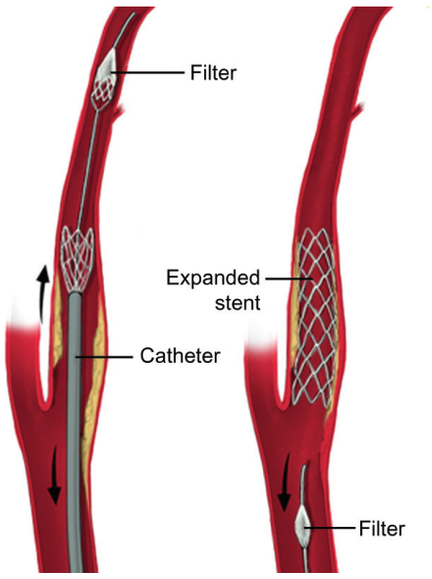

Fig. 19.72: Diagrammatic representation of placement of stents in the management of occluded carotid arteries



Fig. 19.74: Angiography. (A) Occluded femoral artery. (B) Fully revascularized after laser angioplasty

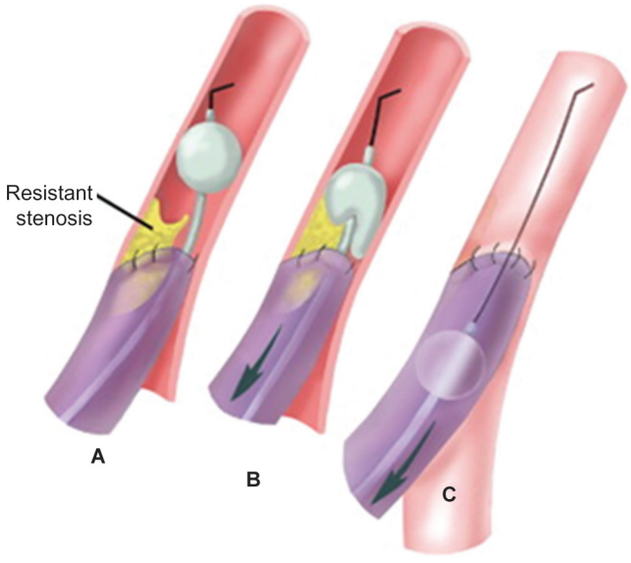

Fig. 19.73: Fogarty thrombectomy of resistant thrombus. (A) A 4-F over-the-wire Fogarty catheter is advanced into the brachial artery beyond the resistant inflow stenosis, and the balloon is inflated. (B) The catheter is forcefully withdrawn. (C) Dislodging the resistant thrombus

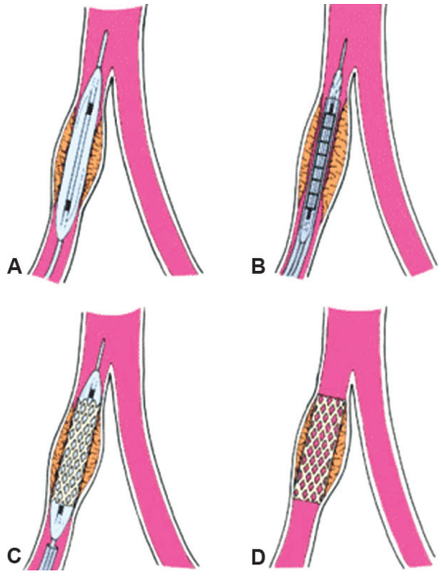

Fig. 19.75: Schematic diagram of a peripheral artery being treated with angioplasty and stenting. (A) Balloon angioplasty of the blockage. (B) Positioning of a balloon-expandable stent, (C) Deployment of the stent. (D) Final result with the stent in place

HOW TO PREVENT PVD

You can reduce your risk of developing PVD by having a healthy lifestyle. This includes (Fig. 19.91).

- avoiding smoking
- controlling your blood sugar, if you have diabetes
- setting an exercise goal of 30 minutes a day, 3 times a week
- working to lower cholesterol and blood pressure
- eating a healthy diet that is low in saturated fat

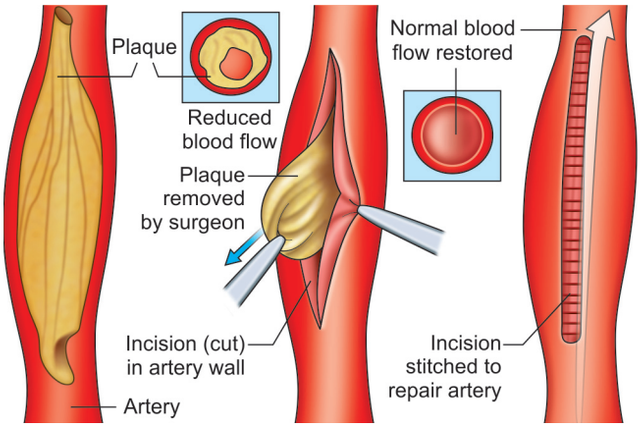

Fig. 19.76: Endarterectomy. This surgical procedure involves the manual removal of plaque from the affected artery. It is generally used in case of arteries that are easily accessible, and is more commonly used in the treatment of carotid artery blockages

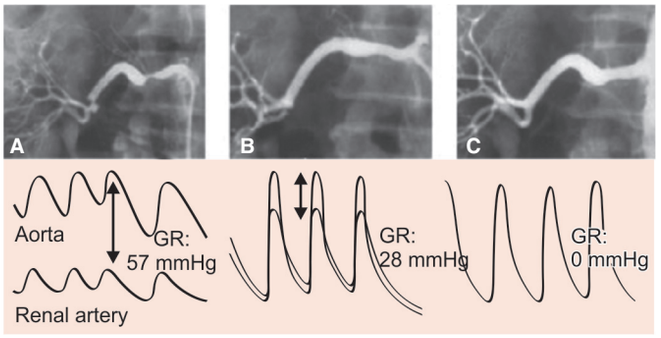

Fig. 19.77: Treatment of renal artery stenosis with balloon angioplasty and stenting. (A) Angiogram showing substantial narrowing of the renal artery and a systolic pressure gradient of 57 mmHg. (B) After balloon angioplasty, the angiographic stenosis is improved with a residual translesional gradient of 28 mmHg. (C) Following stent placement, minor angiographic improvement is evident, but the hemodynamic gradient has completely resolved

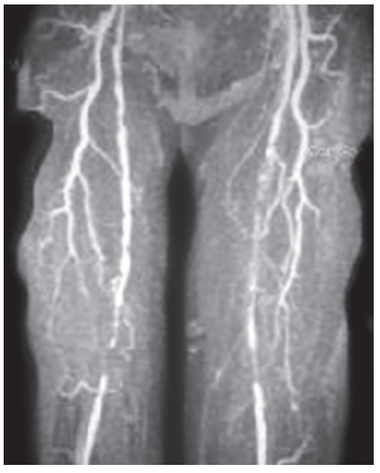

Fig. 19.78: This magnetic resonance angiogram (MRA) of the lower extremities was obtained by using the bolus-chase technique. Atherosclerotic disease involves the bilateral superficial femoral arteries. Note the multiple lesions, which are primarily in the middle portions, and the large collateral arterial supply



Fig. 19.79: Angiograms of acute arterial occlusion. (A) Acute embolic occlusion at the typical location of the trifurcation just below the knee joint. There is a typical cut-off of the contrast column and only a few collaterals are seen. (B) Acute thrombotic occlusion of the superficial femoral artery secondary to atherosclerotic stenosis. Note contrast around fresh thrombus (arrows) and tortuous collaterals as seen in preexisting stenosis

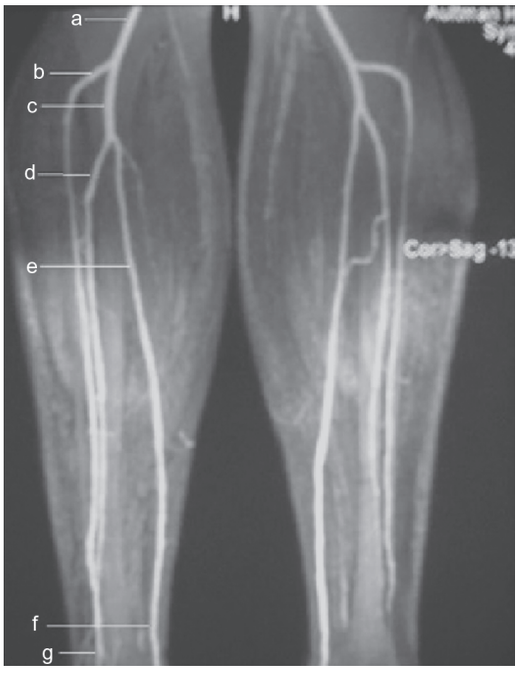

Fig. 19.80: Magnetic resonance angiogram (MRA) obtained by using the bolus-chase technique shows the normal anatomy of the lower-extremity arterial vasculature, including the popliteal artery (a), the anterior tibial artery (b), the tibioperoneal trunk (c), the peroneal artery (d), and the posterior tibial artery (e)

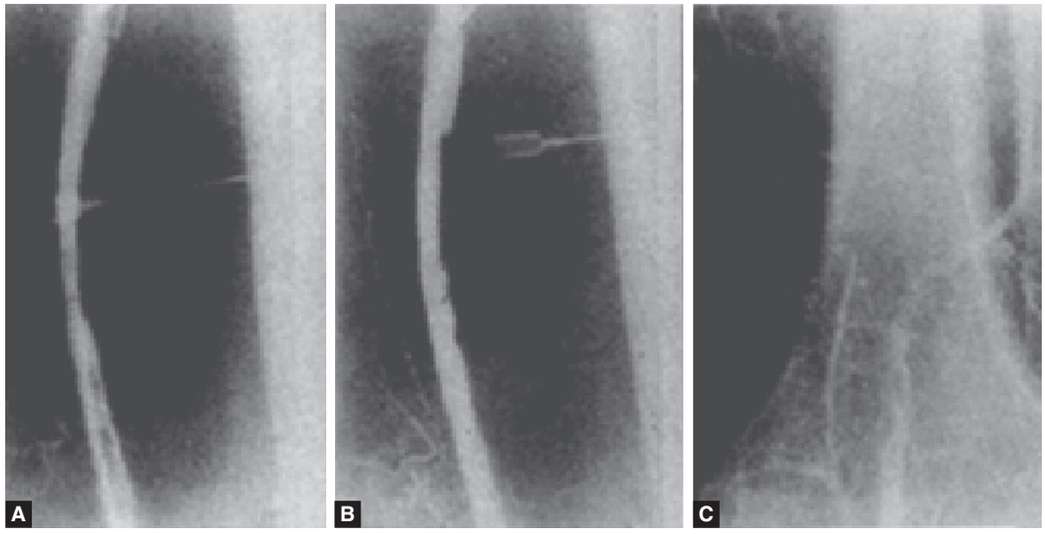

Fig. 19. 81: (A) Filling defect probably representing thrombus that partly occludes the superficial femoral artery. (B) Disappreance of the filling defect after balloon angioplasty. (C) Laser evidence of distal thrombus migration,resulting in occlusion of the trifurcation vessels

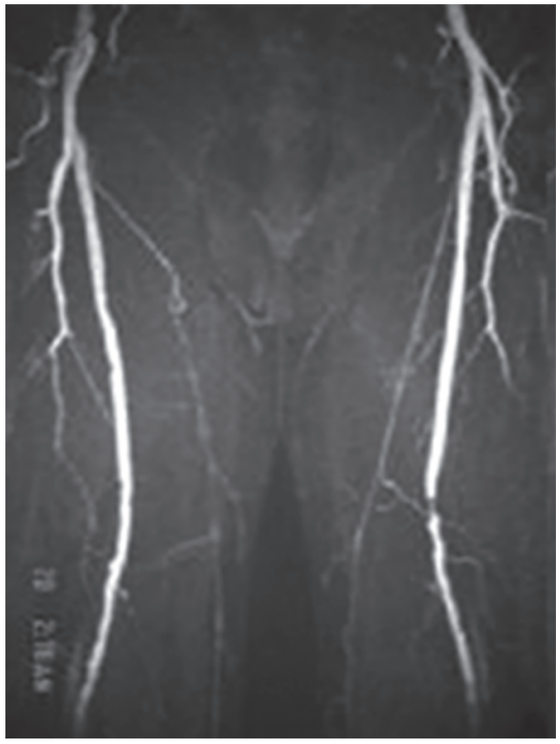

Fig. 19.82: This magnetic resonance angiogram (MRA) of the lower extremities was obtained by using the bolus-chase technique. A short-segment high-grade stenosis is present in the middle of the left superficial femoral artery. Note the collateral arterial supply

- keeping your weight at a healthy level
- if you experience symptoms of PVD, talk to your doctor. Your doctor may also recommend testing if you are at risk for the disease.

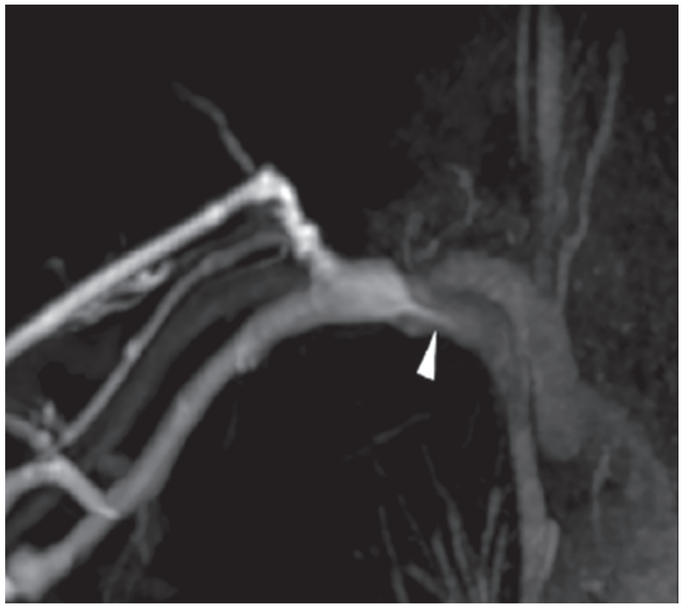

Fig. 19.83: Example of a direct MR venogram of a patient with a central venous stenosis. The arrowhead points at the venous outflow stenosis

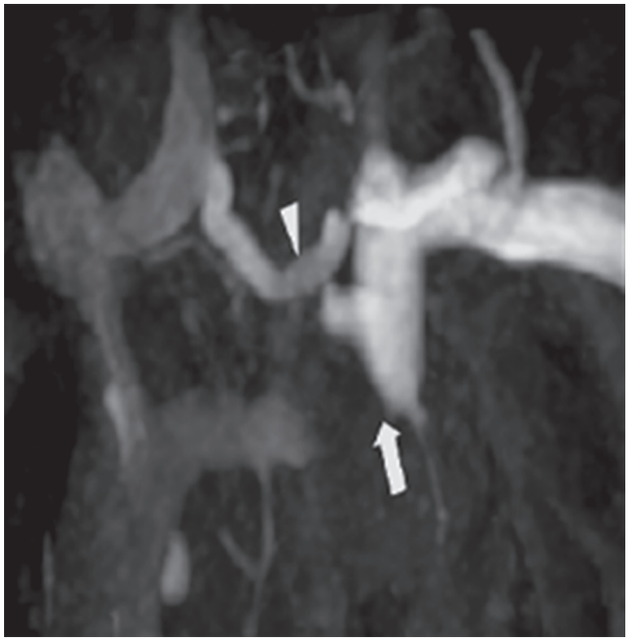

Fig. 19.84: Brachiocephalic vein occlusion in a patient who had multiple central venous catheters. The arrow points at the obstructed brachiocephalic vein in the direct CE-MR venogram. The arrowhead indicates a draining collateral vein

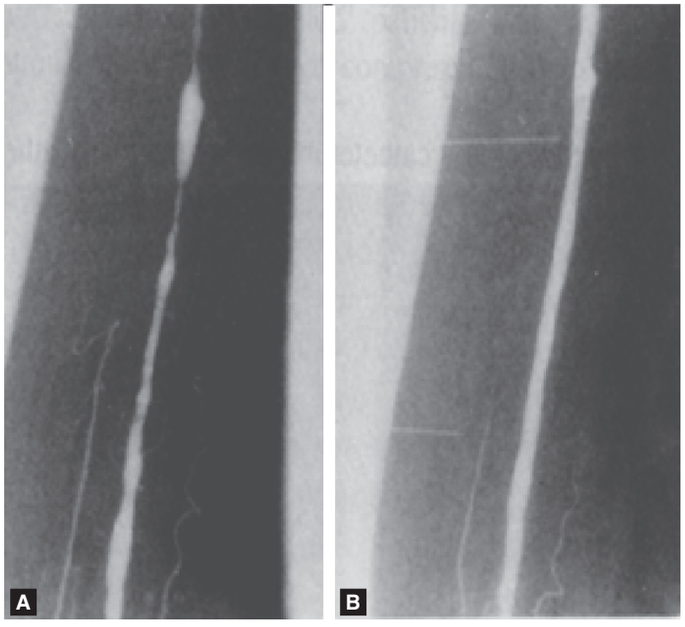

Fig. 19.86: (A) Angiographic picture showing diffusely diseased segment of the superficial femoral artery, (B) treated successfully with the atherectomy catheter



Fig. 19.85: A newly formed thrombolic occlusion of the poplitial and trifurcation vessels and successfully treated with urokinase infusion

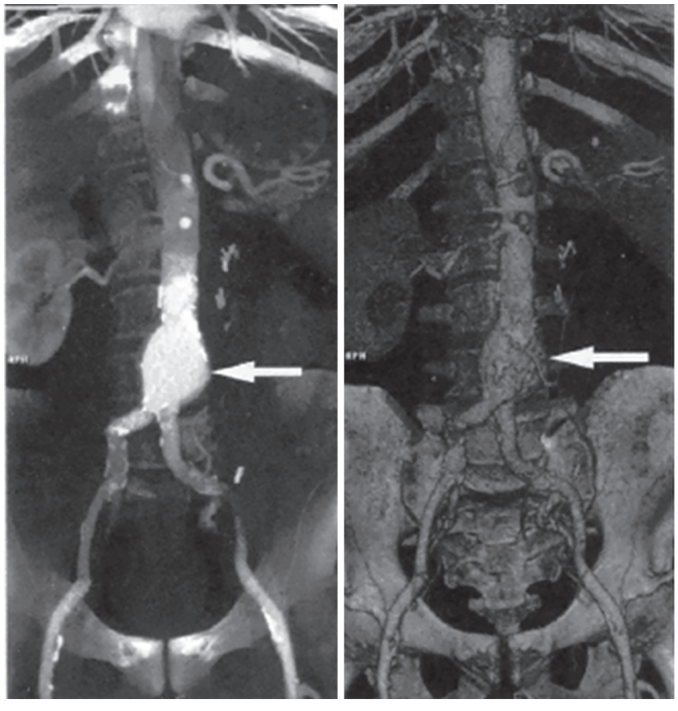

Fig. 19.87: 3-D VR MDCT. Abdominal fusiform aneurysm (arrow)

- early diagnosis and treatment can keep symptoms to a minimum. They can also increase the effectiveness of your treatment.

Prognosis for PVD

If diagnosed early, most cases of PVD will respond to lifestyle treatments. One way to measure improvement is to determine how far you can walk without pain.

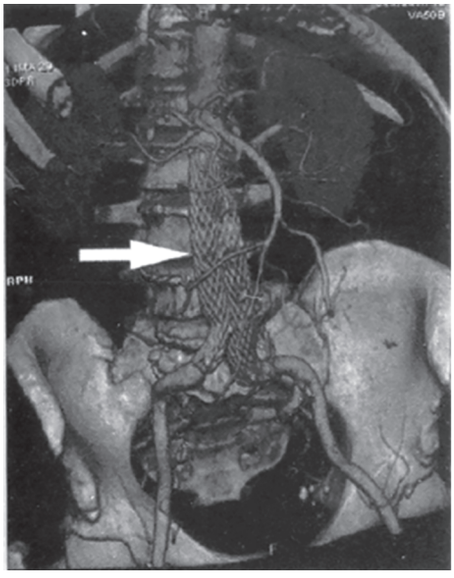

Fig. 19.88: 3-D VR MDCT. Endovascular aortic stent (arrow)

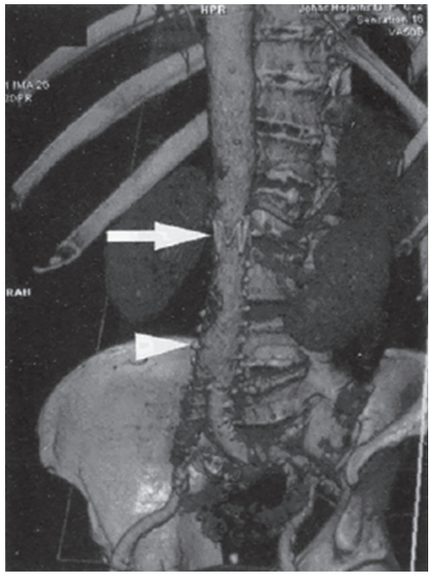

Fig. 19.89: VR MDCT. Endovascular stent. Stent neck (arrow) and stent body (arrowhead) components

With effective treatment, you should be able to gradually increase the distance.

Contact your doctor if your symptoms get worse or you experience any of the following:

- Your leg looks pale or blue
- Your leg becomes cold
- Chest pain accompanies leg pain
- Your leg becomes red, swollen, or hot
- New sores or ulcers develop and do no heal
- You experience fever, chills, weakness, or other signs of infection.

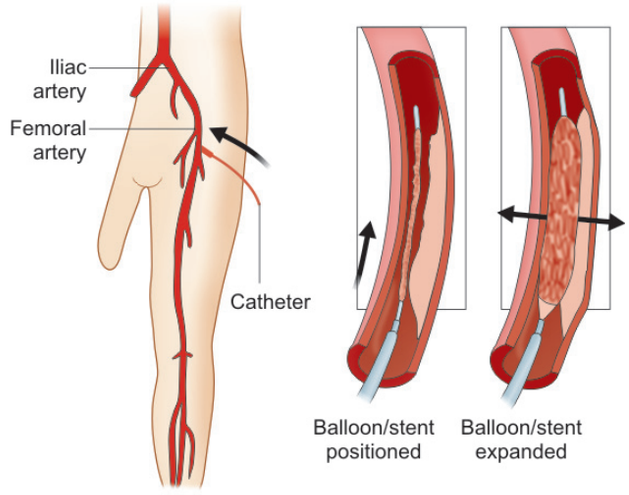

Fig. 19.90: Management of iliac artery by stentoplasty



Fig. 19.91: Stopping cigarette smoking not only prevents PAD but it can significantly regress the process of atherosclerosis

BIBLIOGRAPHY

1. Albers M, Fratezi AC, De Luccia N. Assessment of quality of life of patients with severe ischemia as a result of infrainguinal arterial occlusive disease. J Vasc Surg 1992; 16:54–9.
2. Aronow WS. Office management of peripheral arterial disease. Am J Med 2010;123(9):790–2.
3. Bergamini TM, Towne JB, Bandyk DF, Seabrook GR, Schmitt DD. Experience with in situ saphenous vein bypasses during 1981 to 1989: determinant factors of long-term patency. J Vasc Surg 1991;13:137–47.
4. Brown AL, Juergens JL. Arteriosclerosis and atherosclerosis. In: Allen EV, et al. Peripheral vascular disease. Philadelphia: Saunders, 1972;57–66.
5. Burns P, Gough S, Bradbury AW. Management of peripheral arterial disease in primary care. BMJ 2003; 326(7389):584–8.
6. Cheshire NJ, Wolfe JH, Noone MA, Davies L, Drummond M. The economics of femorocrural reconstruction for critical leg ischemia with and without autologous vein. J Vasc Surg 1992;15:167–74.

7. Cutajar CL, Marston A, Newcombe JF. Value of cuff occlusion pressures in assessment of peripheral vascular disease. Br Med J 1973;2(863):392–5.
8. DeBakey ME, Crawford ES, Garrett E, et al. Occlusive disease of the lower extremities in patients 16 to 37 years of age. Ann Surg 1964;159:873–90.
9. Diagnosis and management of peripheral arterial disease, Scottish Intercollegiate Guidelines Network-SIGN (2006).
10. Diagnosis and Treatment of Peripheral Artery Diseases, European Society of Cardiology (2011).
11. Donaldson MC, Mannick JA, Whittemore AD. Femoral-distal bypass with in situ greater saphenous vein. Long-term results using the Mills valvulotome. Ann Surg 1991;213: 457–64.
12. Dormandy J, Verstraete M, Andreani D, et al. Second European consensus document on chronic critical leg ischemia. Circulation 1991;84(suppl 4):1–26.
13. Eklund AE, Eriksson G, Olsson AG. A controlled study showing significant short term effect of prostaglandin E1 in healing of ischaemic ulcers of the lower limb in man. Prostaglandins Leukot Med 1982;8:265–71.
14. Golledge J. Lower-limb arterial disease. Lancet 1997;350: 1459–65.
15. Gordon T, Kannel WB. Predisposition to atherosclerosis in the head, heart, and legs. The Framingham study. JAMA 1972;221:661–6.
16. Haid SP, Conn J Jr, Bergan JJ. Cystic adventitial disease of the popliteal artery. Arch Surg 1970;101:765–70.
17. Haimovici H. Patterns of arteriosclerotic lesions of the lower extremity. Arch Surg 1967;95:918–33.
18. Lower limb peripheral arterial disease, NICE Clinical Guideline (August 2012).
19. Mangiafico RA, Fiore CE. Current management of intermittent claudication: the role of pharmacological and Curr Vasc Pharmacol 2009;7(3):394–413.
20. Mavor GE. The pattern of occlusion in atheroma of the lower limb arteries. The correlation of clinical and arteriographic findings. Br J Surg 1956;43:352–64.
21. Mazari FA, Gulati S, Rahman MN, et al. Early outcomes from a randomized, controlled trial of supervised exercise, Ann Vasc Surg 2010;24(1):69–79. Epub 2009 Sep 17.
22. No authors listed. MRC/BHF Heart Protection Study of cholesterol lowering with simvastatin in 20, 536 high-risk individuals: a randomised placebo-controlled trial; Lancet 2002;360(9326):7–22.
23. Ouriel K, McDonnell AE, Metz CE, Zarins CK. Critical evaluation of stress testing in the diagnosis of peripheral vascular disease. Surgery 1982;91:686–93.
24. Peach G, Griffin M, Jones KG, et al. Diagnosis and management of peripheral arterial disease. BMJ 2012;345: e5208. doi:10.1136/bmj.e5208.
25. Percutaneous atherectomy of femoropopliteal arterial lesions with plaque excision devices, NICE Interventional Procedure Guideline (February 2011).
26. Peripheral arterial disease-cilostazol, naftidrofyryl oxalate, pentoxifylline and inositol nicotinate; NICE Technology Appraisal Guideline (May 2011).
27. Quinones-Baldrich WJ, Prego AA, Ucelay-Gomez R, Freischlag JA, Ahn SS, Baker JD. Long-term results of infrainguinal revascularization with polytetrafluoroethylene: a ten-year experience. J Vasc Surg 1992;16:209–17.
28. Robless P, Mikhailidis DP, Stansby GP. Cilostazol for peripheral arterial disease. Cochrane Database Syst Rev 2008; (1):CD003748.
29. Ruffolo AJ, Romano M, Ciapponi A. Prostanoids for critical limb ischaemia. Cochrane Database Syst Rev 2010;(1): CD006544.
30. Santilli JD, Rodnick JE, Santilli SM. Claudication: diagnosis and treatment. Am Fam Physician 1996;53:1245–53.
31. Schuler JJ, Flanigan DP, Holcroft JW, Ursprung JJ, Mohrland JS, Pyke J. Efficacy of prostaglandin E1 in the treatment of lower extremity ischemic ulcers secondary to peripheral vascular occlusive disease: results of a prospective randomized, double-blind, multicenter clinical trial. J Vasc Surg 1984;1:160–70.
32. Taylor LM Jr, Edwards JM, Porter JM. Present status of reversed vein bypass grafting: five-year results of a modern series. J Vasc Surg 1990;11:193–205.
33. Taylor LM Jr, Porter JM. Current status of the reversed saphenous vein graft. In: Bergan JJ, Yao J, eds. Arterial surgery. New York: Grune and Stratton, 1987:494–501.
34. The Edinburgh Claudication Questionnaire.
35. Vascular disease-clopidogrel and dipyridamole, NICE Technology Appraisal Guideline (December 2010).
36. Watson L, Ellis B, Leng GC. Exercise for intermittent claudication. Cochrane Database Syst Rev 2008;(4):CD000990.
37. Weiss N, Hilge R, Hoffmann U. Mild hyperhomocysteinemia: risk factor or just risk predictor for cardiovascular diseases? Vasa 2004;33(4):191–203.
38. Welch HJ. Chronic lower extremity ischemia. Compr Ther 1997;23:534–8.
39. Yusuf S, Sleight P, Pogue J, et al. Effects of an angiotensin-converting-enzyme inhibitor, ramipril, on cardiovascular events in high-risk patients. The Heart Outcomes Prevention Evaluation Study Investigators. N Engl J Med 2000; 342(3): 145–53.

20 Recognition and Management of Cardiac Arrhythmia

Arrhythmias may be defined as a disturbance in either the formation of impulse or its transmission through various pathways of conduction or through both the combinations. The term sinus arrhythmia is a misnomer as the phenomenon is only an exaggeration of the normal and the impulse arises normally at the S-A node. Similarly, the term nodal rhythm is misleading as this does not mean that the impulse arises at the S-A node. It has now been replaced by the term A-V junctional rhythm.

GENESIS OF CARDIAC DYSARRHYTHMIA

The Heart's Electrical System

The atria (the heart's upper chambers) and ventricles (the heart's lower chambers) work together, alternately contracting and relaxing to pump blood through the heart. The electrical system of the heart is the power source that makes this possible (Figs 20.1–20.3).

What Happens during a Normal Heartbeat

Irregular heart rhythms can also occur in normal, healthy hearts. Arrhythmias can also be caused by certain

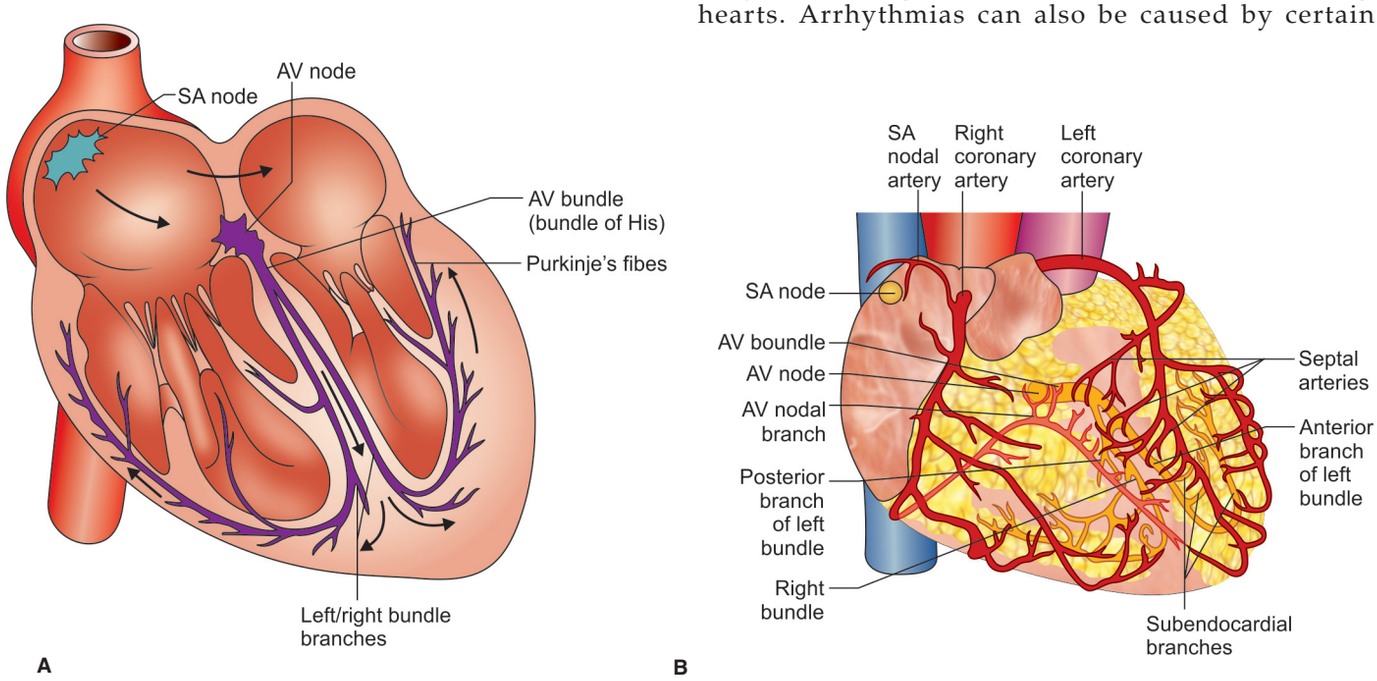

Fig. 20.1: (A) Diagrammatic representation of anatomical structures of conduction system of the heart. (B) Shows blood supply of conduction system of the heart

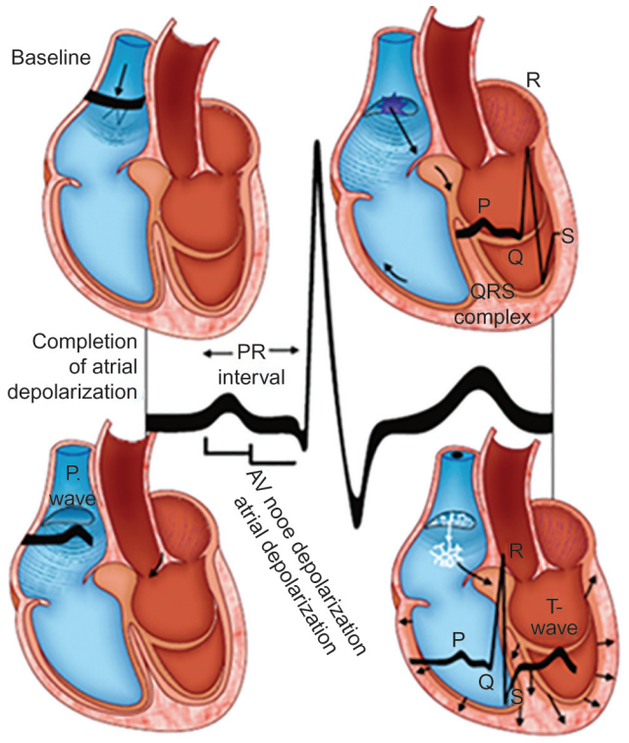

Fig. 20.2: The formation and conduction of cardiac impulse by the process of depolarization along the conducting system

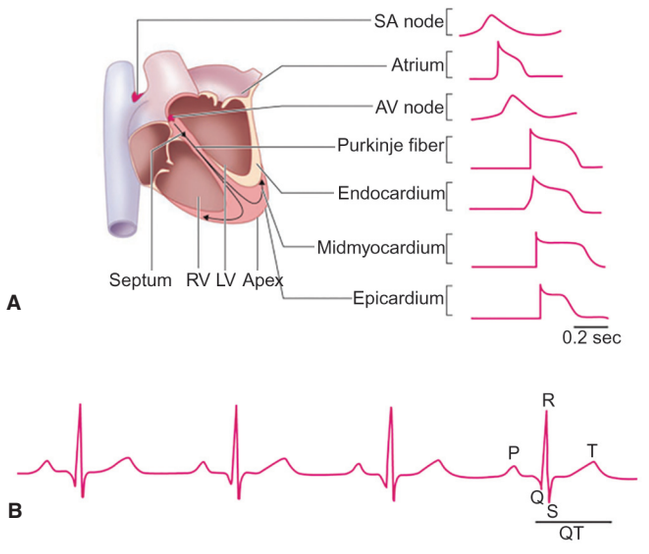

Fig. 20.3: Electrical activity in the myocardium. (A) Schematic of a human heart with illustration of typical action potential waveforms recorded in different regions. (B) Schematic of a surface

substances or medications, such as caffeine, nicotine, alcohol, cocaine, inhaled aerosols, diet pills, and cough and cold remedies. Emotional states such as shock, fright or stress can also cause irregular heart rhythms. Arrhythmias that are recurrent or related to an underlying heart condition are more concerning and should always be evaluated by a doctor. In most cases, treating the underlying condition will take care of the arrhythmia. If not, many medications and procedures are available to eliminate or control the abnormal heart rhythm. It can be caused either by the disturbance of impulse formation or impulse conduction or both.

Disturbance of impulse formation: Disturbance of cardiac impulse formation may lead to the common type of cardiac arrhythmia, called ectopic rhythm.

Ectopic rhythms: These are of two types, either escape beats and escape rhythms or extra systoles and ectopic tachycardias. An escape beat appears when there is a pause in the existing rhythm, and it is, thus always late in appearance and never premature. If the sinus node fails for a long period, repeated escape beats will occur, giving a characteristically slow escape rhythm. The commonest site of escape rhythm is the A-V junction. Extrasystoles and ectopic rhythms arise from foci in the specialized electrocardiogram; three sequential beats are displayed (Figs 20.1–20.4) (From Nerbonne J, Kass R. Molecular physiology of cardiac repolarization. Physiol Rev. 2005; 85:1206) conducting tissue, which have been well-defined in the intranodal tracts of the atria. If the extra-systole or tachycardia is above the bifurcation of the bundle of His, it is termed as A-V junctional tachycardia.

CLASSIFICATION OF CARDIAC ARRHYTHMIAS

Anatomically, the dysrhythmias may be classified according to the site of origin of the impulse. Given below is a simple and workable classification of cardiac arrhythmias (Tables 20.1 and 20.2).

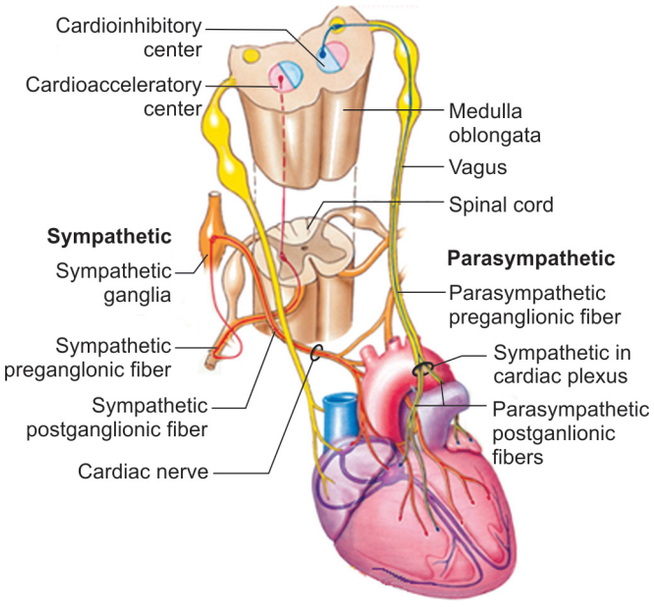

Fig. 20.4: Diagrammatic representation of sympathetic and parasympathetic nerve innervation of the heart influencing cardiac rhythm

Table 20.1: ECG features of supraventricular tachycardias

	R-R regularity	P-wave morphology
Atrial tachycardias		
Sinus tachycardia	Regular	Positive in II, III, aVF
Sinus node re-entry	Regular	Positive in II, III, aVF
Atrial tachycardia, unifocal	Regular	P different from sinus
Atrial tachycardia, multifocal	Irregular	≥3 different P-wave morphologies
Atrial flutter, common, counter-AV block	Regular, irregular if variable negative in II, III, aVF	Sawtooth flutter waves; regular waveform; clockwise
Atrial flutter, uncommon, clockwise	Regular, irregular if variable AV block	Upright flutter waves; positive waveform II, III, aVF
Atrial fibrillation	Irregularly irregular	Irregular fibrillation waves
AV junctional tachycardias		
AV re-entry (using accessory pathways)		
Orthodromic	Regular	Retrograde P in ST-T-wave
Antidromic	Regular preexcited	Retrograde P, short RP
Slow conducting	Regular	Retrograde P at end of T-wave or later (long RP)
Atriofascicular (antidromic)	Regular preexcited	Retrograde P, short RP
AV nodal re-entry		
Common (slow-fast)	Regular	Retrograde P obscured by QRS or alters the end of QRS (short RP)
Uncommon (fast-slow)	Regular	Retrograde P at end of T-wave or later (long RP)
Others (slow-slow)	Regular	PR-RP approximately equal
Nonparoxysmal junctional tachycardia	Regular, slow rate	AV dissociation
Automatic junctional tachycardia	Regular	AV dissociation

Table 20.2: P-wave morphology in atrial tachycardia—general principles

Location		P-wave polarity during atrial tachycardia	
Right atrium	+ or ± in aVL and – in VI	Crista terminalis (CT)	May be +, ±, or – in II, III, aVF in the high, mid and inferior CT, respectively; – or ± inVI; – in aVR
		Tricuspid annulus	– in V1–V2; + in a VL and frequently in 1
		Right atrial appendage	Insufficient data
Left atrium	– in aVL and + in VI	Right pulmonary veins	+ in V1–V6; + in 1: narrow P-wave in VI
		Left pulmonary veins	+ in V1–V6; –/isoelectric in aVL; broad or notched P-wave in VI
		Mitral annulus	± with initially narrow negative deflection in V1; –/isoelectric in 1 aVL; slightly +/isoelectric in II, III, aVF
Interatrial spetum and adjacent structures	Specific to location	Coronary sinus ostium	+ in V1; isoelectric in I: – in II, III, aVF; + in aVL, aVR
		Snteroseptum	–/± in V1; +/± in II, III, aVF
		Mid septum	–/± in V1; in two of three inferior leads (II, III, aVF)
		Left septum	Uncommon; variable findings

+ positive; – negative; ± biphasic

Site of origin and type of dysrhythmia:

1. Sinu-atrial node

i. Sinus tachycardia
ii. Sinus bradycardia
iii. Sinus arrhythmia
iv. S-A arrest of block
v. Wandering pacemaker
vi. Sinu extrasystoles

2. Atria

i. Atrial extrasystoles
ii. Atrial tachycardia
iii. Atrial flutter
iv. Atrial fibrillation
v. Chaotic atrial rhythm
vi. Atrial standstill

3. **Atrio-ventricular junction**
   i. A-V junctional extrasystoles
   ii. A-V junctional tachycardia
   iii. A-V junctional rhythm
   iv. Heart block-first, second and third degree
4. **Ventricles**
   i. Bundle branch block
   ii. Ventricular extrasystoles
   iii. Ventricular tachycardia
   iv. Ventricular flutter and fibrillation
   v. Ventricular standstill.

It has been, frequently, observed that most of the arrhythmias are transient and may be of only a few seconds duration. It is in that brief period, if the ECG is taken, that a particular type of arrhythmia could be found out, otherwise, in majority of the patients, it could be missed. This problem has been overcome by frequent use of the Holter monitoring system which can detect cardiac arrhythmia, not only being present for a shorter period, but can also provide useful therapeutic guidelines for its final management. The arrhythmias, which originate in the sinus (or sinoatrial SA) node, are classified as sinus tachycardia, sinus bradycardia, sinus arrhythmia, SA block, SA nodal re-entry, sick sinus syndrome, and sinus arrest. In all these conditions, the sinus node is the pacemaker of the heart, though its rate may be too fast, too slow, irregular, or inconsistent.

SINUS TACHYCARDIA

In a patient with sinus tachycardia, there is regular sinus rhythm of more than 100 beats/min. It can be considered as one of the first signs of congestive heart failure, cardiogenic shock, pulmonary embolism, or infarct extension (Figs 20.5–20.7).

ECG Characteristics

1. Rate : >100 beats/min
2. Rhythm : Regular
3. PR interval : Normal, although the PR may be too long or too short because of other conditions. All the P-waves have the same shape and are upright in leads I, II, aVF, and V4 to V6
4. QRS complex : Normal but may be prolonged due to other associated conditions

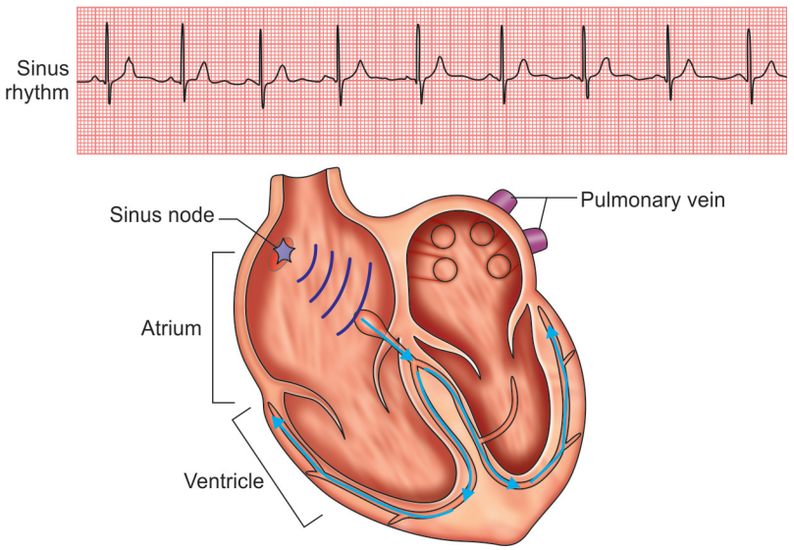

Fig. 20.5: This illustration shows the normal pathway through which electric activities needed for cardiac excitation (impulse conduction pathway) are transmitted. First generated at the site called the sinus node in the atrium, the electric impulse is transmitted via the atrioventricular node to the ventricle, which causes the ventricular contraction to pump blood to the entire body

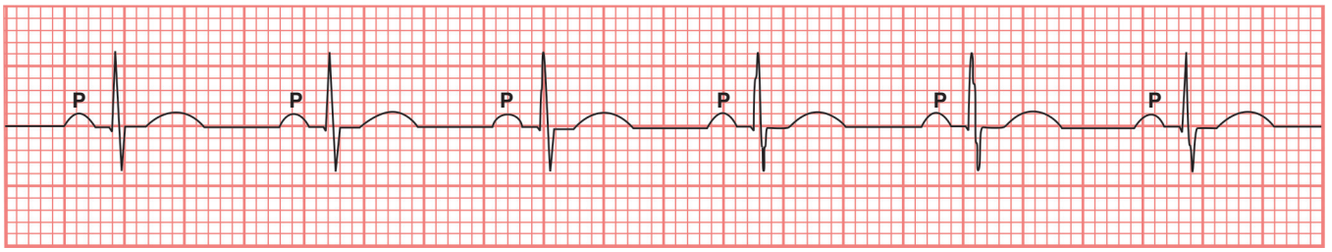

Fig. 20.6: ECG trace showing normal sinus rhythm. Each narrow complex is preceded by a normal P-wave

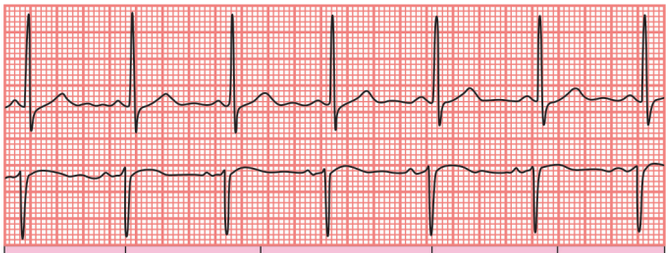

Heart rate	Rhythm	P-wave	PR interval (in seconds)	QRS (in seconds)
60–100 bpm	Regular	Before each QRS, identical	.12 to .20	<.12

Fig. 20.7: ECG trace showing sinus tachycardia above and its markers at bottom end

Causes

1. **Drug**
   - i. Atropine,
   - ii. Isoproterenol (isuprel),
   - iii. Quinidine,
   - iv. Epinephrine (adrenalin)
2. Exercise, emotions, fever or pain
3. Hyperthyroidism
4. Conditions involving increased sympathetic stimulation.

Sinus tachycardias vary only if they are part of a bradycardia-tachycardia syndrome or because of associated conditions, such as AV block, bundle-branch block, PVCs, or PACs.

The diagnosis of sinus tachycardia is always made by identifying uniform P-wave with regular rhythm.

Treatment of Sinus Tachycardia

The basic treatment is of the underlying cause. Beta-blockers will slow down the rate. Sinus tachycardia caused by thyrotoxicosis will respond to beta-blockers; on the other hand. Sinus tachycardia resulting from left ventricular dysfunction, usually, should not be treated with beta-blockers as these drugs may precipitate heart failure.

SINUS BRADYCARDIA

Sinus bradycardia can be diagnosed both clinically and electrocardiographically when the peripheral pulse is of regular rhythm with heart rate less than 60 beats/min, and has regular sinus rhythm character (Fig. 20.8 and Table 20.3).

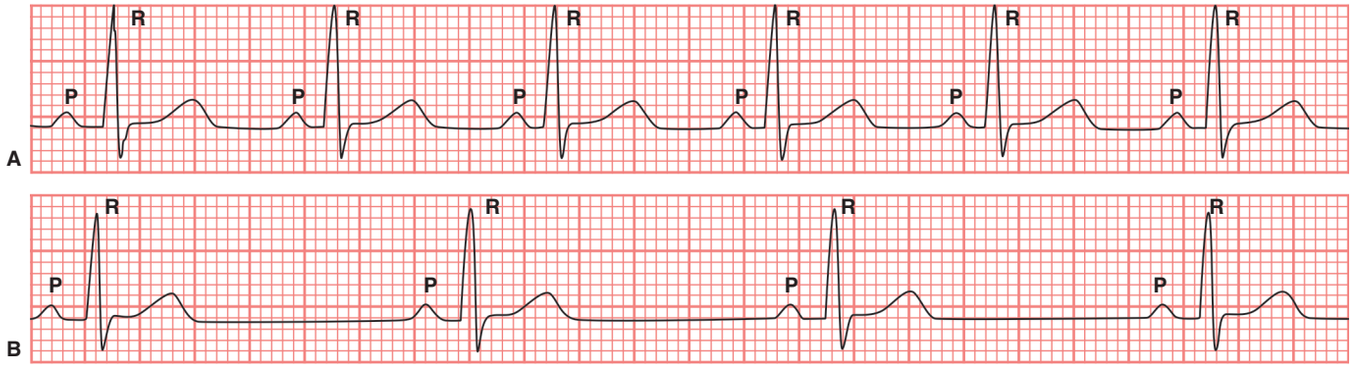

Fig. 20.8: The EKG shows normal sinus rhythm (A) and sinus bradycardia (B) with heart rate less than 60 beats/min

Table 20.3: Differential diagnosis in bradyarrhythmias (ventricular rate less than 60)

Nature of defect	Ventricular	A-V relationship	Atrial rate	Additional clues
1. Sinus bradycardia	Less than 60	Normal (1:1)	Less than 60	May be sinus arrhythmia
2. Sinus arrest	Less than 60	May be nodal or ventricular	Less than 60; abrupt	none halving of atrial rate
3. AV-nodal rhythm	Less than 60	Short P-R or P-wave buried in QRS or superimposed on S-T segment	Less than 60	Normal QRS complexes-P waves may be hard to see
4. Wenekebach block	Less than atrial rate	P-R interval lengthens with successive beats until QRS is is dropped. The cycle is repeated	Normal; usually over 60	QRS complexes often in pairs or triplets
5. Second degreee block	Usually 30–50; (1/2, 1/3)	2:1 AV block or greater (3:1, 4:1, etc.)	Normal; usually over 60	P-waves never occur in QRS complexes
6. Third degree (complete block)	Regular 30–50 (no P-QRS relationship)	A-V dissociation	Normal; usually over 60	P-waves from time to time in QRS complexes

ECG Characteristics

1. Rate : <60 beats/min
2. Rhythm : Regular
3. PR interval : Normal, although the PR may be too long or too short because of other conditions. All the P-waves have the same shape and are upright in leads I, II, aVF, and V4 to V6
4. QRS complex : Normal, although the QRS may be prolonged as a result of other associated conditions.

Causes

1. During fast sleep
2. Cardiac response in atheletes
3. Increased vagal tone
4. Therapy with beta-adrenergic drugs

Sinus bradycardias vary only if they are part of a bradycardia-tachycardia or because of associated conditions, such as AV block, bundle-branch block, PVCs, or PACs. The diagnosis of sinus bradycardia is always established by looking at the underlying rhythm.

Treatment of Sinus Bradycardia

It is treated only if the patient is symptomatic or if the condition is associated with hemodynamic deterioration and marked decrease in cardiac output. Acute treatment in the sick sinus syndrome includes 0.5 mg of atropine sulfate IV, administered every 5 minutes until the desired response is achieved or a 2 mg total does has been employed. If this is unsuccessful, isoproterenol may be administered in infusion form, which is monitored according to heart and response. These patients do need permanent pacemaker implantation in case where stokes-adams attacks are manifested frequently.

SINUS ARRHYTHMIA

Sinus arrhythmia can be diagnosed by an irregular sinus rhythm in which the cycles lengths vary so that the difference between the shortest PP interval and the longest PP interval is 0.12 sec (Fig. 20.9).

ECG Characteristics

1. Rate : It varies with respiration: faster with inspiration-slower with expiration
2. Rhythm : Irregular
3. PR interval : Normal, although the PR may be too long or too short because of other conditions. All the P-waves have the same shape and are upright in leads. I, II, aVF, and V4 to V 6
4. QRS complex : Normal, although the QRS may be prolonged as a result of other conditions.

It can be isolated from other conditions by the presence of varying rate, cyclical, irregular rhythm, and uniform shape of the P-waves.

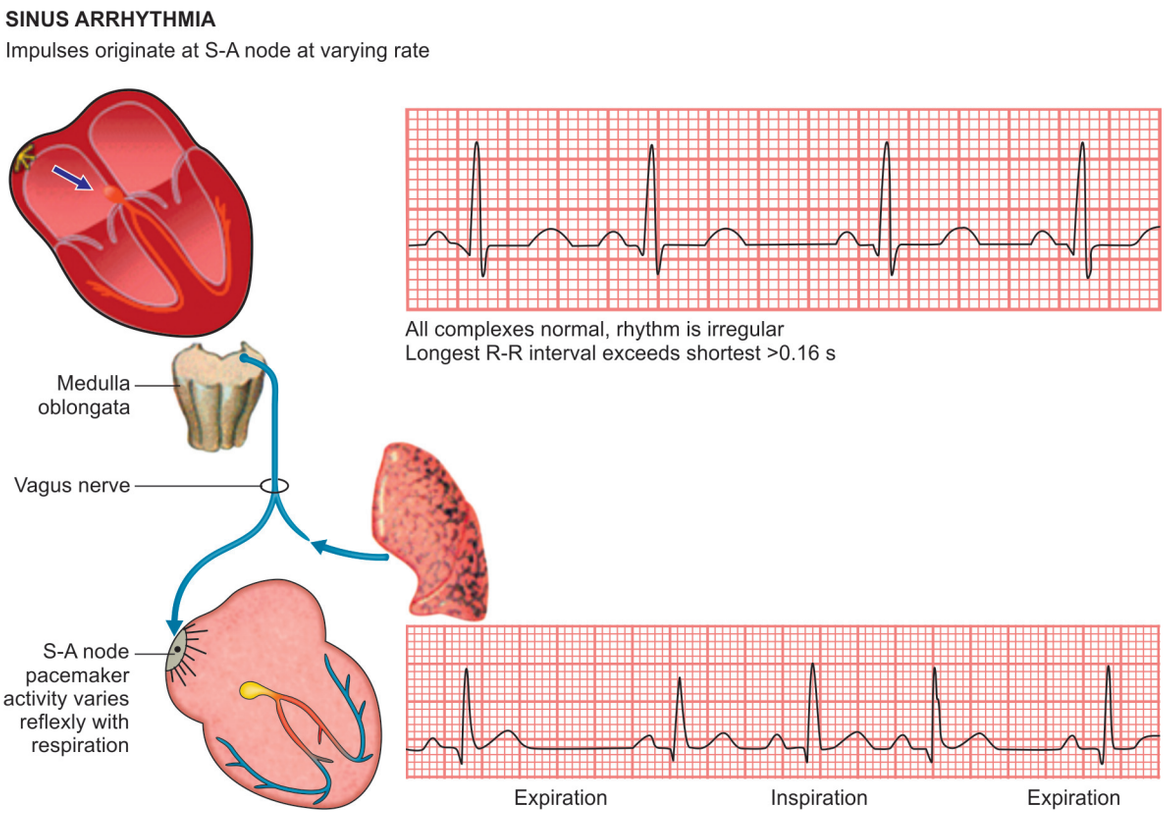

Fig. 20.9: Lead II showing normal sinus rhythm with sinus arrhythmia in a healthy person. Note the marked variation in the P-P intervals induced by respiration

Causes

Normal respiratory pattern: Sinus arrhythmia can be differentiated from SA nodal re-entry due to the presence of transition with abrupt faster rate which is, usually, not related to respiration although P-waves may remain of similar morphology in both the conditions.

SA BLOCK

SA block is characterized by the absence of P-waves, intermittently, due to incomplete conduction of sinus P-waves as they emerge from the sinus pacemaker (Fig. 20.10).

ECG Characteristics

1. Rate : Normal, but varies because of pauses.
2. Rhythm : Irregular
3. PR interval : Normal, although the PR may too long or too short because of other conditions. All the P-waves have the same shape and upright in leads I,II, aVF, and V4 to V6
4. QRS complex : Normal, although the QRS may be prolonged as a result of other conditions.

Causes

1. Acute infection
2. Digitalis, quinidine, or salicylates
3. Carotid sinus sensitivity and increased vagal tone.
4. Coronary artery disease.

Distinguishing Features

Type-I (wenchebach) SA block: PP intervals shorten until a P-wave is dropped; pauses are less than twice the shortest cycle.

Type-II SA block: PP intervals are an exact multiple of the sinus cycle and are regular, before and after the dropped P-wave.

Differential Diagnosis: Nonconducted PACs are far more common and should be suspected first. Usually, the P-wave can be seen distorting the T-wave before the pause. The diagnosis of sinus arrest can be made after ruling out nonconducted PACs and SA block.

SINUS ARREST

Sinus arrest may be defined as that condition in which the sinus impulses are not generated, with the result that one

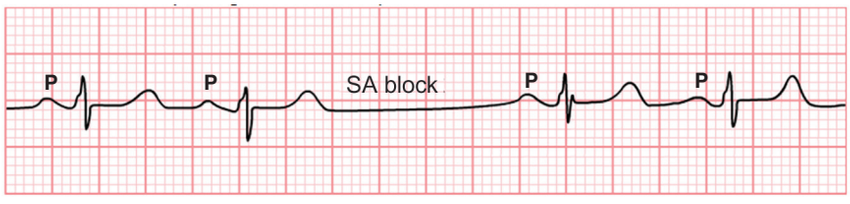

Fig. 20.10: SA block. The basic rhythm is regular. The length of the pause is not a multiple of the sinus interval

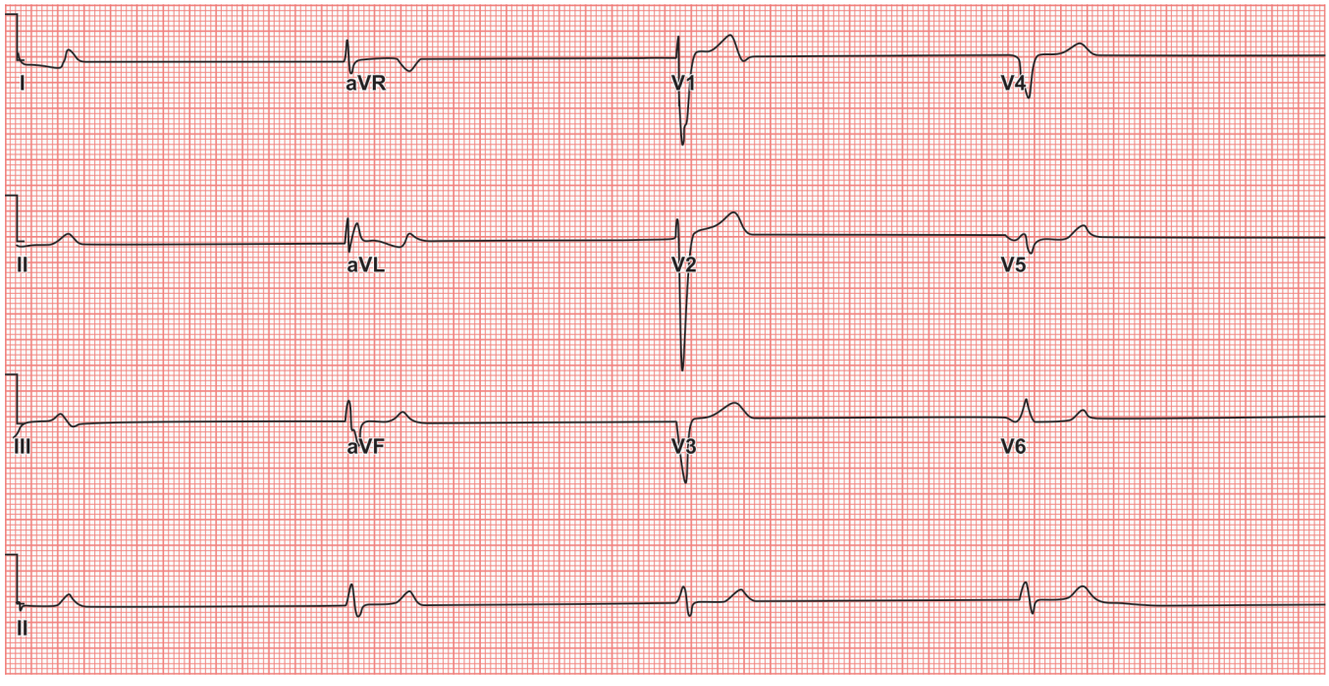

Fig. 20.11: Sinus arrest with a ventricular escape rhythm

may find occasional absent P-waves. In case this type of rhythm persists, it may lead to atrial standstill (Fig. 20.11).

ECG Characteristics

1. Rate : Normal, but varies because of pauses.
2. Rhythm : Irregular
3. PR interval : Normal, althought the PR may be too long or too short as a result of other conditions. All the P-waves have the same shape and are upright in leads I, II, aVF, and V4 to V6.
4. QRS complex : Normal, although the QRS may be prolonged. Because of other conditions.
5. Distinguishing features : Abrupt interruption of the sinus rhythm. PP interval of the pause is not a multiple of the sinus cycle.

Causes

1. Digitalis, quinidine, or salicylates
2. Coronary artery disease
3. Acute infection
4. Carotid sinus sensitivity and increased vagal tone.

Differential Diagnosis

Nonconducted PACs are far common and are always suspected first. Usually, the P-wave can be seen distorting the T-wave before the pause.The diagnosis of sinus arrest can be made after ruling out nonconducted PACs and SA block.

SICK SINUS SYNDROME

Sick sinus syndrome may be defined clinically by the presence of near syncope, syncope, convulsions, fatigue, angina pectoris and other symptoms of hypoperfusion of the brain and electrocardiographic manifestations of bradycardia and tachycardia along with other features of cardiac arrhythmia due to sinus node dysfunction and failure of an adequate escape pacemaker (Fig. 20.12).

ECG Characteristics

1. Rate : Too fast or too slow
2. Rhythm : Irregular
3. PR interval : May be abnormal
4. QRS complex : Normal, although the QRS may be prolonged because of other conditions.

Distinguishing Features

Any of the following arrhythmias may be present and associated with syncope:

1. Severe sinus bradycardia
2. Sinu arrest
3. Atrial stand still
4. SA block
5. Sinus bradycardia with recurring atrial fibrillation
6. Bradycardia-tachycardia
7. Temporary asystole following tachycardia or following electrical cardioversion of atrial tachyarrhythmia
8. Paroxysmal atrial fibrillation
9. Failure of the sinus node to accelerate in response to fever or exercise.

Causes

1. Ischemic disease due to obstructive blood supply to the sinus node
2. Inflammatory disease of sinus node
3. Amyloidosis: Infilteration of the sinus node with amlyoid material
4. Collagen disease
5. Metastatic disease
6. Surgical injury
7. Idiopathic

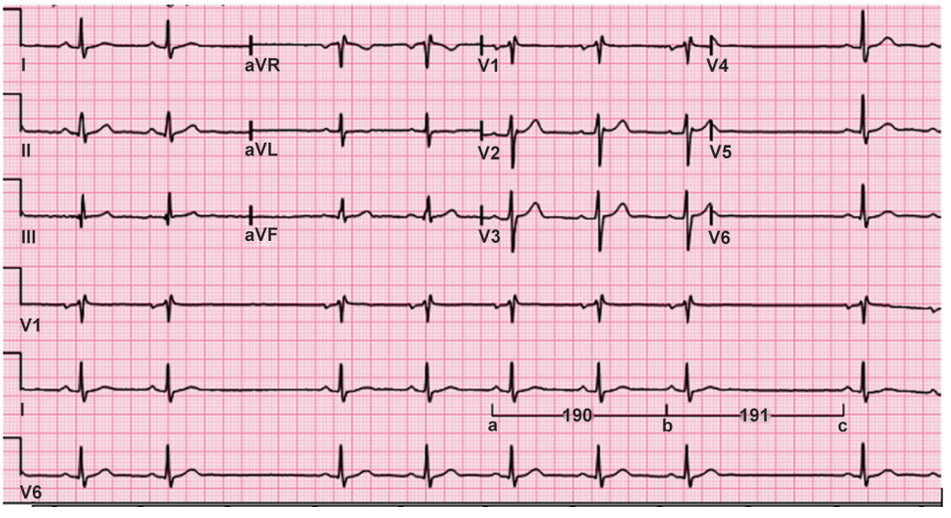

Fig. 20.12: ECG shows the irregularity of the QRS complexes with changing rates and the changing P-waves in sick sinus syndrome, a pattern of atrial dysbalance, which can be of the slow or the fast type. The conduction velocity is different from beat-to-beat and there are blocked actions with sinus pauses

Variations

There are many variations among which are:

1. SSS with type II second-degree SA block
2. SSS in the form of a bradycardia- tachycardia syndrome
3. SSS with inappropriate overdrive suppression following an early PAC (in the T-wave before the pause)

Treatment

Before a pacemaker is inserted, ensure that no drugs have been given at all for several days; the arrhythmia may be drug related.

PAROXYSMAL SINUS TACHYCARDIA RESULTING FROM NODAL RE-ENTRY

Paroxysmal sinus tachycardia is the sudden onset of the sinus tachycardia (Fig. 20.13).

ECG Characteristics

1. Rate : Too fast
2. Rhythm : Irregular
3. PR interval : Normal although the PR may be too long or too short because of other conditions. All the P-waves have the same shape and are upright in leads I, II, aVF, and V4 to V6
4. QRS complex : Normal, although the QRS may be prolonged as a result of other conditions.
5. Distinguishing features :
   a. Heart rate suddenly accelerates; tachycardia ends abruptly
   b. Rhythm of the tachycardia, usually, regular
   c. Normal sinus P-waves.

Causes

1. Ischemia
2. Cardiomyopathy.

Differential Diagnosis

Sinus arrhythmia

Treatment

Short paroxysms may require no treatment.

1. Termination may, often be achieved by vagal manoeuvres, but carotra artery message should not be advised in patients with or at risk for carotid artery disease
2. Intravenous verapamil is considered by some to be treatment of choice, but should be used cautiously in those patients who had poor left ventricular functions.
3. Digitalis and beta-blockers, which prolong AV nodal conduction and refractoriness in both alpha and beta-pathways are usually, effective.
4. Type IA antiarrhythmic agents may be useful.
5. Oral diltizaem, 90 mg 3 times a day, may be effective in preventing recurrence.

In situations where one can find severe hemodynamic disturbances, direct synchronous cardioversion, using 40/w/s, is, often, quite contributory.

SUPRAVENTRICULAR ARRHYTHMIA (Figs 20.14–20.23 and Table 20.4)

1. Premature atrial contraction (PAC)
2. Atrial flutter
3. Atrial fibrillation
4. Atrial tachycardia

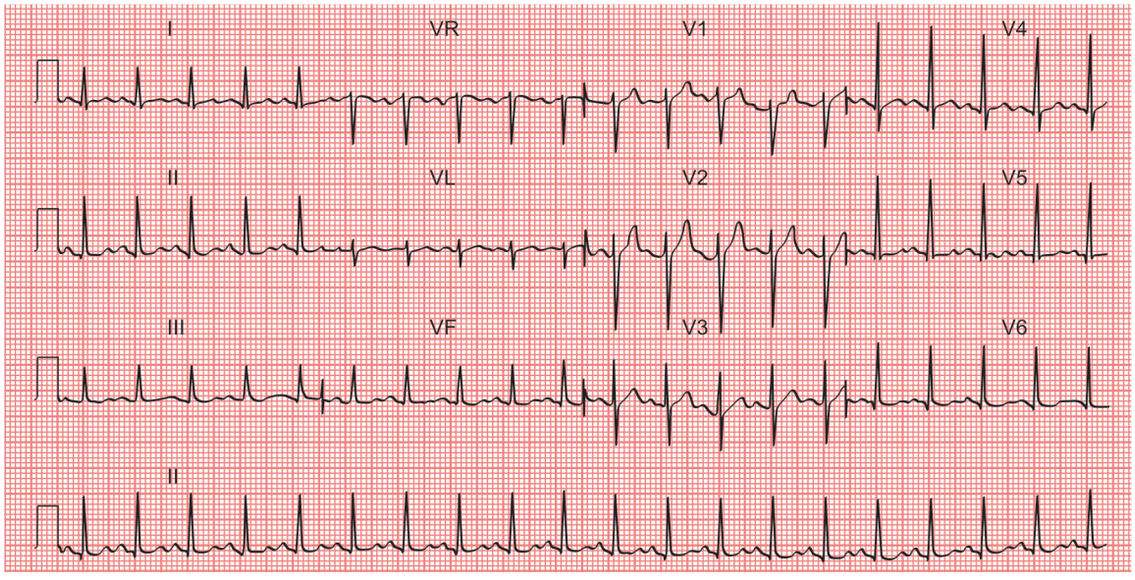

Fig. 20.13: ECG trace showing features of sinus tachycardia with heart rate more than 150 beat/min

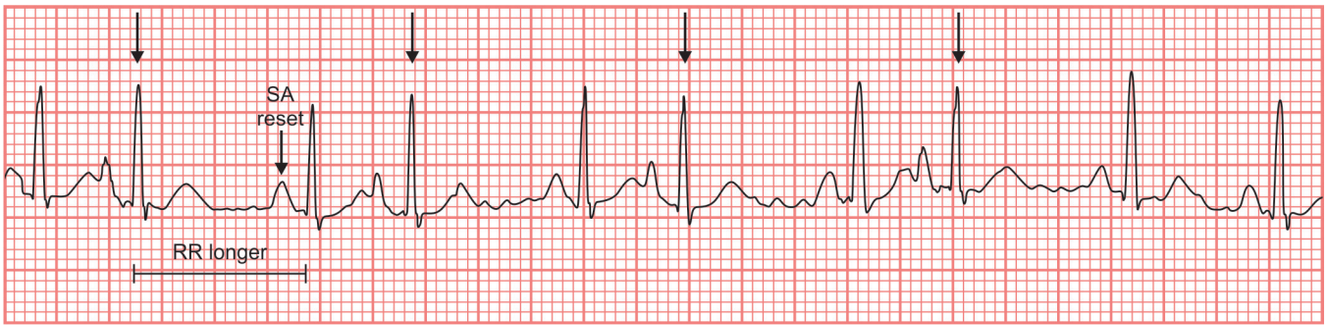

Fig. 20.14: This rhythm strip displays the typical pattern of frequent PACs (arrows) separated by postextrasystolic pauses

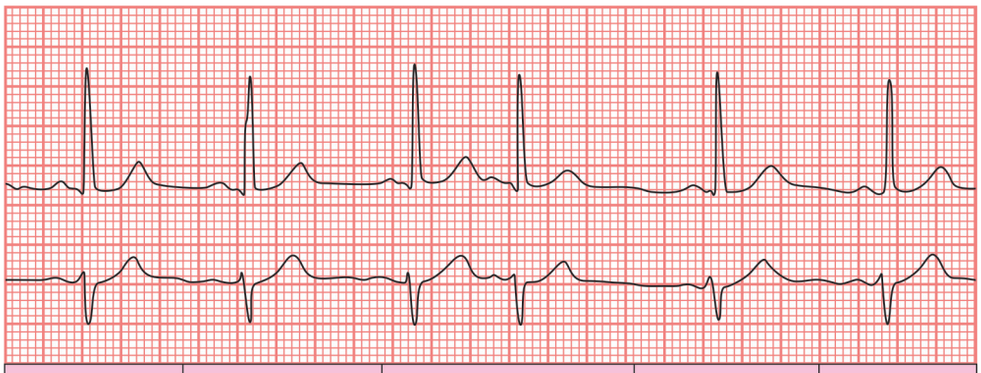

Heart rate	Rhythm	P-wave	PR interval (in seconds)	QRS (in seconds)
N/A	Irregular	Premature and abnormal or hidden	<.20	<.12

Fig. 20.15: Premature atrial contraction with pause

Table 20.4: Differential diagnosis in atrial ectopic tachycardia and PSVT

	Atrial ectopic tachycardia	PSVT (AV nodal re-entry)	Sinus tachycardia
1. P-waves	Visible	Usually, buried within QRS complex; may distort V1 patterns (pseudo RBBB)	Visible
	+ in II, III and aVF (digitalis toxicity)	Retrograde (negative in II, III and aVF)	Normal
2. Rate	Gradually incareases (warm-up)	Begins abruptly and remains the same; ends abruptly	Gradually incareases; gradually decreases
3. P-R interval	Normal	Long (first one)	

5. Atrial fusion
6. Atrial parasystole
7. Paraxysmal supraventricular tachycardia (PSVT)
8. Wandering pacemaker
9. Premature junctional contraction (PJC).
10. Accelerated junctional rhythm.
11. Junctional tachycardia.

Mechanism

Cardiac arrhythmia, which usually, has it origin outside the sinus node and above the branching portion of the bundle of His, can be called as supraventricular arrhythmia, manifesting, initially, as ectopic(s). They may be either abnormal premature mechanisms or normal escape mechanisms, occurring in response to an abnormality in the sinus node. The two most common mechanisms involved are enhanced automaticity in the atria or AV junction (bundle of His) and AV nodal re-entry or re-entry, using an accessory pathway (WPW syndrome). Enhanced automaticity may be secondary to digitalis, electrolyte imbalance, hypoxia, myocardial stretch, or acute myocardial infarction, and may result in single PACs or PJCs, ectopic atrial tachycardia, accelerated junctional rhythm, or junctional tachycardia.

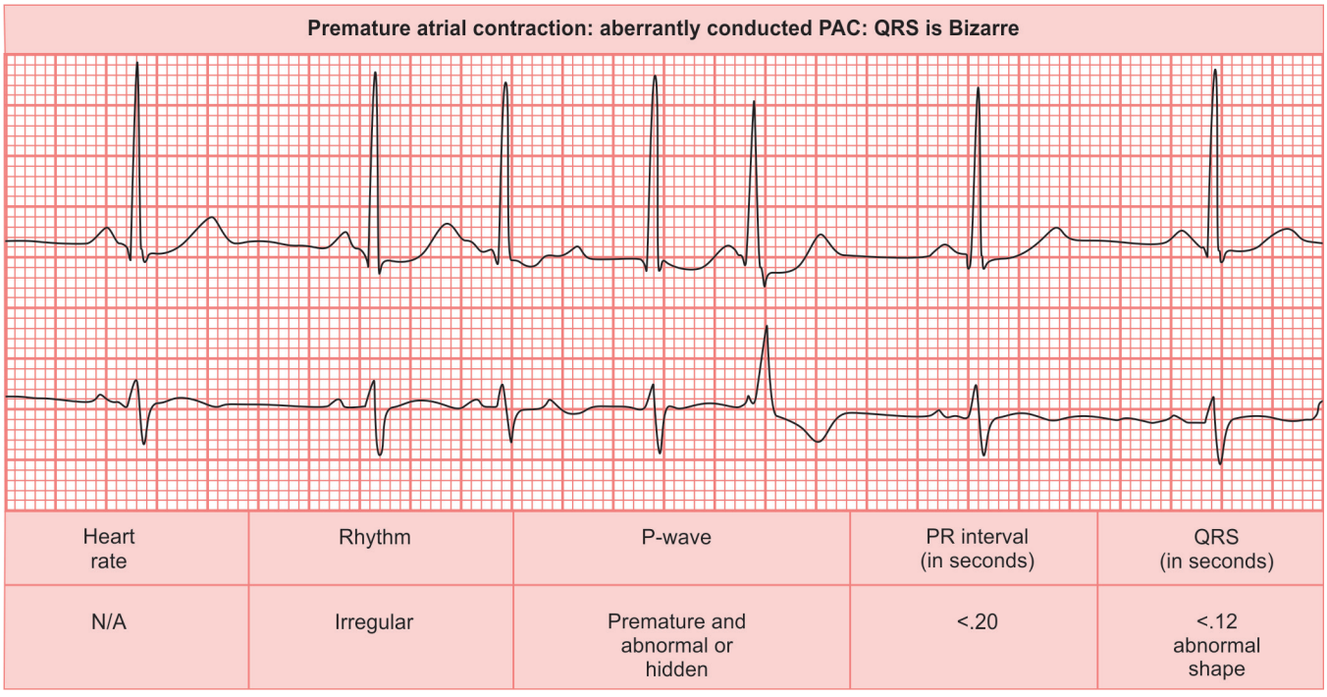

Fig. 20.16: PAC with RBBB aberrant conduction

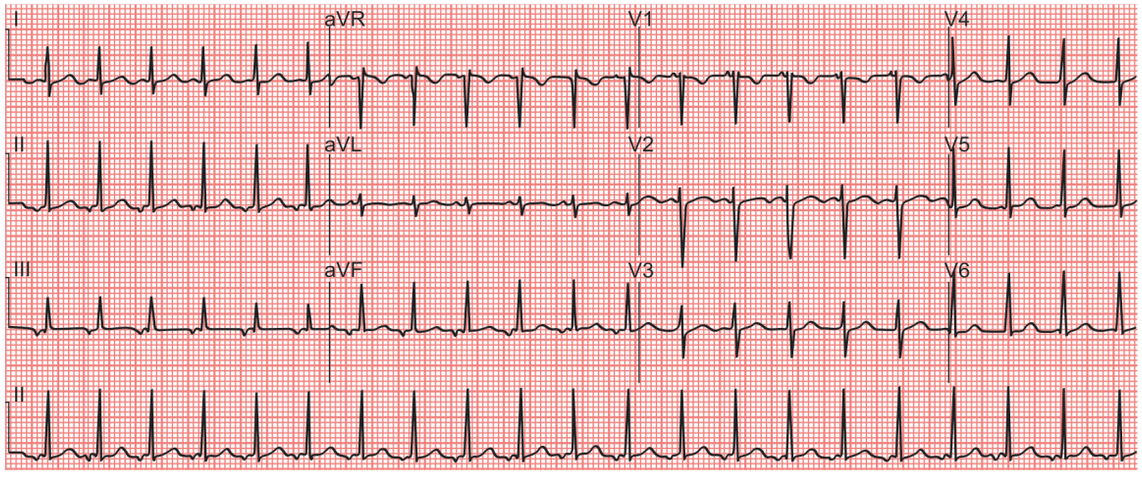

Fig. 20.17: ECG trace showing atrial tachycardia with 2.1 conduction with heart rate more than 120 bpm. Each QRS complex is preceded by an abnormal P-wave, upright in V1, inverted in the inferior leads II, III and aVF

An AV nodal re-entry mechanism may be initiated by a single premature atrial, junctional, or ventricular complex, resulting in paroxysmal supraventricular tachycardia (PSVT).

PREMATURE ATRIAL ECTOPICS (PAC)

PACs are premature atrial beats that originate outside the sinus node. The resulting ECG deflection is called a P′ (P prime) wave.

Pathophysiology and Mechanism

PACs are a result of enhanced automaticity or after depolarizations. The mechanisms of AV conduction and compensatory pauses, following PACs are described here.

AV conduction. The PAC may be so premature that it is not conducted at all, because both bundle branches are refractory or, it may be conducted down only one bundle branch and be blocked in the other (aberrant ventricular conduction).

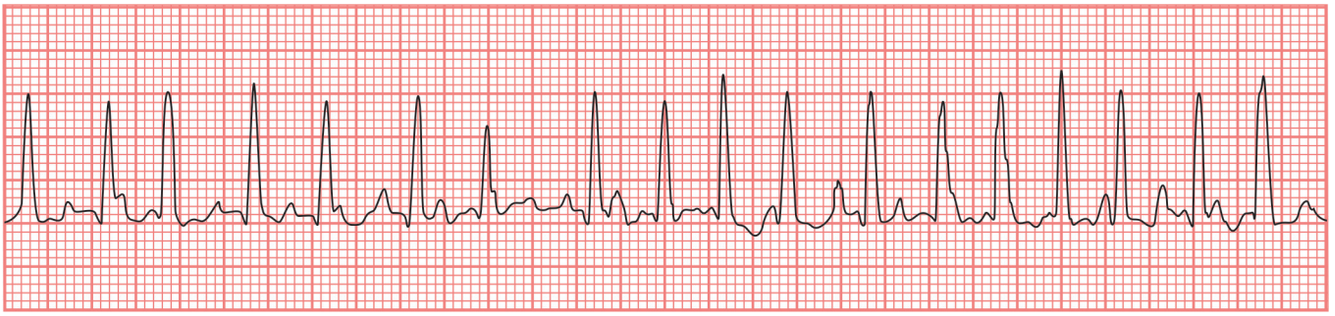

Fig. 20.18: Graph showing multifocal atrial tachycardia

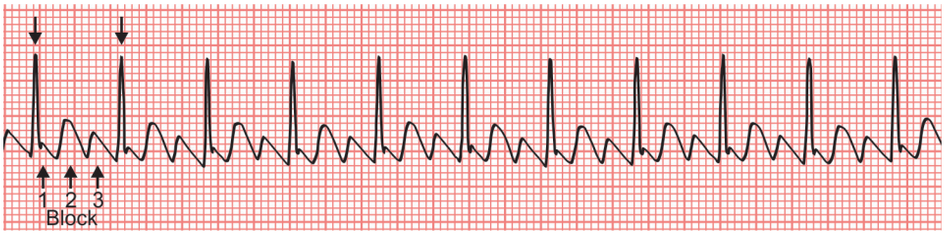

Fig. 20.19: Atrial flutter. Narrow QRS complexes are associated with regular flutter waves (arrows)

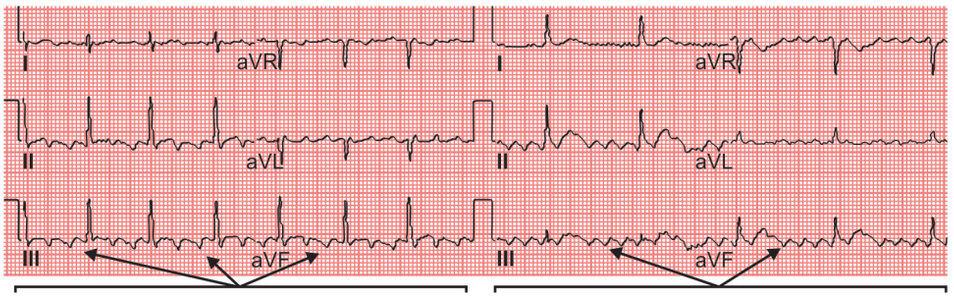

Fig. 20.20: Atrial flutter with negative flutter waves in leads II and III (left panel) and positive flutter waves (right panel)

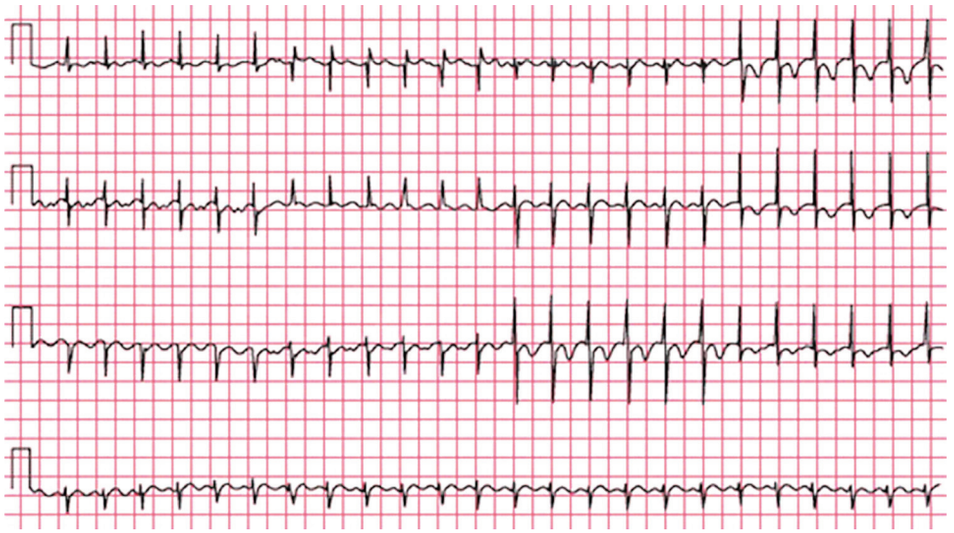

Fig. 20.21: Atrial flutter (heart rate >300 bpm) with regular R-R interval

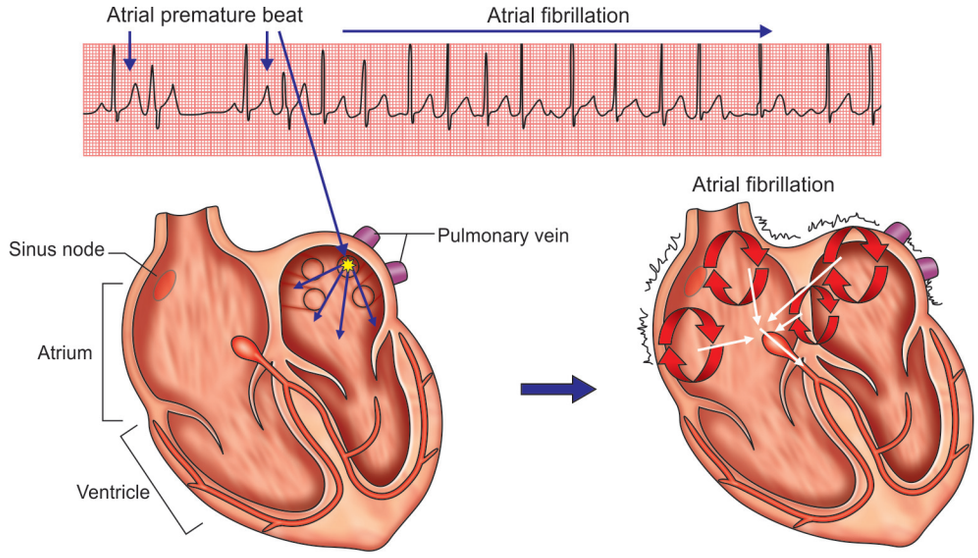

Fig. 20.22: Mechanism of onset of atrial fibrillation

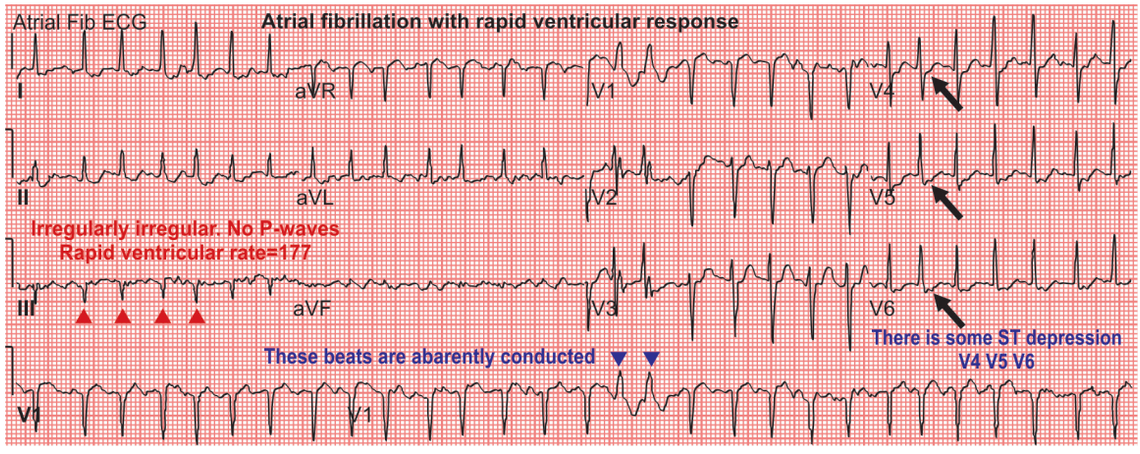

Fig. 20.23: Various ECG diagnostic features of atrial fibrillation

Less-than-full compensatory pause. The PAC resets the SA node, causing the next expected sinus P-wave to be on time if measured from the PAC, but earlier than it would have if the sinus node had not been disturbed.

Full or more-than- full compensatory pause. The PAC may suppress the SA node (overdrive suppression) and cause the next few sinus cycles to lengthen.

ECG Characteristics

1. Rate : That of the underlying rhythm
2. Rhythm : Irregular, resulting from PACs (underlying rhythm may be regular)
3. PR interval : Normal, although the PR interval may be too long or too short because of other conditions. All the P-waves have the same shape and upright in leads I,II, aVF, and V4 to V6 (the P-R interval may be the same, longer, or shorter than the PR interval, or the P-wave may not be conducted to the ventricles (a blocked PAC).
4. QRS complex : Normal, although the QRS may be prolonged as a result of aberrancy or other conditions
5. Distinguishing features : Normal QRS and a P-wave that is premature and different in shape from the sinus P-wave.

Aetiological Factors

1. Various stimuli—emotion, tobacco, or coffee
2. Congestive heart failure (in the setting of myocardial infarction).

3. Atrial dilation or hypertrophy, resulting from mitral stenosis or atrial septal defect
4. Electrolyte imbalance
5. Hypoxia
6. Digitalis toxicity

Variations

1. PACs hidden in T-waves
2. Bigeminal PACs
3. Nonconducted PACs
4. Bigeminal nonconducted PACs.

Differential Diagnosis

Sinus arrest or SA block. Nonconducted PACs are statistically far more common and can, usually, be stotted distorting the T-wave.

Treatment

PACs are not treated, but in association with acute myocardial infarction, their cause is identified and treated.

ATRIAL TACHYCARDIA

Atrial tachycardia is an ectopic atrial rhythm with a rate of 140–250 beats/min.

ECG Features

1. Rate : 140–250 beats/min (atrial). The ventricular rate depends on the AV conduction ratio
2. Rhythm : Regular
3. PR interval : Not applicable; P-R interval may be normal or prolonged. The P-waves are ectopic.
4. QRS complex : Normal, although the QRS may be prolonged because of other conditions.
5. Distinguishing features : Rate and AV conduction ratio, which is, usually, 2:1. In digitalis toxicity, the P-wave axis is, often, superior-inferior (positive in inferior leads), and often, in 2:1 block. The PP interval, across the QRS, is shorter than the one without a QRS (ventriculo-Phasic PP interval)

Causes

1. Digitalis toxicity
2. Heart disease.

Variations

Atrial tachycardia with 4:1 AV conduction (other conduction ratios are also possible).

CHAOTIC ATRIAL TACHYCARDIA (CAT)

Chaotic atrial tachycardia is a multifocal atrial tachycardia.

ECG Features

1. Rate : 100–250 beats/min.
2. Rhythm : Irregular
3. PR interval : May or may not be normal. P-R intervals may vary.
4. QRS complex : Normal
5. Distinguishing features : P-waves of several different shapes and an irregular rhythm.

Aetiological Factors

1. Chronic pulmonary disease
2. Hypoxia
3. Electrolyte imbalance

Differential Diagnosis

Atrial fibrillation.

Treatment

Verapamil is found to be effective but basic underlying cause/s, leading to such abnormality, is important to manage first.

ATRIAL FLUTTER

Atrial flutter is a rapid atrial tachycardia of two types.

ECG Characteristics

1. Rate : Type-1 (classical). The atrial rate ranges from 230–250 beats/min Type-II. The range is 340–430 beats/min.
2. Rhythm : Atrial rhythm is regular, ventricular rhythm depends on the AV conduction pattern.
3. P-R interval : 0.26–0.46 sec
4. QRS complex : Normal
5. Distinguishing features : Regular sawtooth pattern in II, III, aVF sharp positive P-waves in V1. Normal QRS complexes AV conduction in 2:1 to 8:1 ratios. T-wave may distort the flutter pattern.

Causes

1. Any form of heart disease such as rheumatic heart disease, coronary artery disease, preexcitation syndrome etc.
2. Acute illness

Variations

1. Varying degrees of AV conduction ratios
2. Atrial flutter with AV dissociation (an accelerated idioventricular rhythm).

Differential Diagnosis

When the conduction ratio is 2:1, atrial flutter is, often, mistaken for sinus tachycardia of 140–175 beats/min. The ventricular rate makes one suspicious of a hidden flutter

wave, and, usually, the onset of the R wave is distorted by the flutter wave.

Treatment

1. The hemodynamic compromise is present due to a fast ventricular rate, direct synchronous cardioversion with 40–50 w/s should be administered.
2. Fast ventricular response rate can be controlled with digitalis. Propranolol or verapamil can also be used but are less effective. Normal rhythm can be achieved, usually, by the administration of these drugs.
3. Digoxin and verapamil should not be prescribed to patients with flutter associated with Wolff-Parkinson-White syndrome.
4. Reversion to sinus rhythm may also be, often, achieved with the use of a type IA antiarrhythmic agents.
5. A patient should not be administered quinidine until digitalization is achieved since quinidine may facilitate AV conduction. Procainamide may rarely increase the ventricular response to atrial flutter by slowing the flutter rate; the AV node may conduct every second atrial depolarization instead of every third, producing an increased ventricular rate.
6. Atrial flutter can be converted to sinus rhythm with temporary overdrive pacing. It is done by pacing 115–125% of the spontaneous atrial rate at a critical duration. Overdrive pacing can also be successful, utilizing a special esophageal electrode.
7. If an artial thrombus has been diagnosed by echocardiography, the patient should be given warfarin with the prothrombin time, 1.2–1.5 times of control, for 3 weeks. If there is an abnormal slow atrial flutter rate or a high degree of AV block when the patient is receiving no antiarrythmic agents, disease of the AV node should be suspected, and backup temporary pacing should be done till the rhythm is converted to normal rate response.

ATRIAL FIBRILLATION

Atrial fibrillation (AF) is an ectopic atrial arrhythmia characterized by erratic depolarization of the atrial.

Newer Classification of AF

Some of the workers have classified atrial fibrillation into three different types on electrophysiological studies. They observed that all patients had uniform conduction in the free wall of the right atrium, during sinus rhythm, rapid atrial pacing procedure.

Type-I seen in 40% of patients in whom there are uniform, single broad wave fronts that propagate through the atrial wall without significant conduction delay. There may be short areas of conduction block, small areas of slow conduction, that do not interfere with the main course of propagation. The cycle length is somewhat slow (median 174 ms), there is almost no re-entry, and no source of activation waves is visible, despite the persistence of atrial fibrillation.

Type-II, found in 32% of patients in which there is intermediate pattern, which describes either a single wave associated with major areas of conduction block and/or slow conduction or two wavelets, separated by a line of functional conduction block.

Type-III which manifests with a highly fragmented and complex pattern, seen in 28% of cases, and characterized by three or more wavelets, associated with lines of functional conduction block under the mapping electrode. This type of fibrillation is associated with a shorter cycle length (median interval, 136 ms) than type I and with a wide 100 ms variation in cycle length spanning very short and very long cycles. It may also be kept in mind that the three types of atrial fibrillation do not constitute three separate entities, but rather a continuous spectrum of increasing complexity.

ECG Characteristics

1. Rate	:	Uncontrolled, 110–180 beats/min. controlled, 70–80 beats/min.
2. Rhythm	:	Irregular
3. PR interval	:	Absent P-waves
4. QRS complex	:	Normal
5. Distinguishing features	:	Absent P-waves and irregular ventricular response.

Causes

i. Mitral valve disease
ii. Ischemic disease, particularly acute myocardial infarction.
iii. Hypertension
iv. Thyrotoxicosis
v. Increasing left-atrial size in elderly patients.
vi. Idiopathic (lone) type of atrial fibrillations.

Variations

1. Coarse atrial fibrillation with signs of digitalis toxicity (regularization of the ventricular response)
2. Fine atrial fibrillation with uncontrolled ventricular response.
3. Atrial fibrillation with complete AV block
4. Atrial fibrillation with conduction over an accessory pathway.

Treatment

1. Therapy with digoxin still remains the basic method of treatment of atrial fibrillation in controlling the ventricular response. Depending upon the clinical urgency and the ventricular rate, it may be given orally or intravenously. Digoxin is strongly contraindicated in atrial fibrillation with antegrade pre-excitation by an accessory pathway. Verapamil is also contraindicated in this situation
2. If severe hemodynamic compromise is present due to atrial fibrillation with a rapid ventricular response, synchronous cardioversion is considered. After cardio-

version, it may be helpful to administer digitalis and/or to start procainamide or quinidine to help maintain the patient in sinus rhythm.

3. In a stable patient, one should determine if the rhythm is acute or chronic and whether electrical cardioversion is required. The patient should be anticoagulated with warfrain for 3 weeks if the rhythm has been present for more than 2 days or if the duration is uncertain, prior to cardioversion. The prothrombin time should be 1.2 to 1.5 times of the control. While the patient is being anticoagulated, the ventricular response should be controlled with digitalis, at times, adding either beta-blockers or verapamil. The digoxin may be initated intravenously, and, when the ventricular rate is brought under check, it should be switched over to the oral medication. Acute short-term heparinization does not exclude the possibility of embolic episode, following cardioversion, and should not be employed. Quinidine or procainamide is, usually, started 24–48 hours to elective cardioversion. Occasionally, this will produce cardioversion, and usually, the medication should be continued after successful electrical cardioversion to prevent recurrence.
4. Long term administration of anticoagulation be considered in patients with chronic atrial fibrillation.
5. If atrial fibrillation is as short as 2–3 days' duration, medical cardioversion may be considered by administering 1–2 mg of digoxin over 24 hours. If the patient fails to achieve normal rhythm, procainamide or quinidine is added. A patient should be fully digitalized prior to starting quinidine which may increase the ventricular response.
6. Electrical cardioversion is usually, successful, but atrial fibrillation may return if the underlying cause is not removed. Quinidine or procainamide should be given, after cardioversion, to check further reoccurrence of atrial fibrillation.
7. Electrical or medical cardioversion should be avoided in sick sinus syndrome, if the ventricular rate is less than 80 beats per minute, or if digitalis toxicity is suspected. If necessary, such patients may be electively cardioverted, after a temporary pacing catheter is inserted, to avoid a bout of asystole.
8. Beta-blockers and diltiazem may show some therapeutic response on rare occasions when added to the therapeutic does of digioxin to control the ventricular rate in chronic atrial fibrillation.

WANDERING PACEMAKER

It may be defined as that of atrial arrhythmia in which there is shifting of impulse formation from focus to focus within the atrial tissue virtually with every beat. Sinus beats may be interspersed throughout. P-waves are of many forms, and the cadence tends to be somewhat irregular. Ventricular complexes are without alteration (Fig. 20.24).

ECG Characteristics

1. Rate : Normal or 50 beats/min
2. Rhythm : Slightly irregular
3. PR interval : Normal
4. QRS complex : Normal
5. Distinguishing features : A sinus rhythm that gives way to an ectopic atrial or junctional rhythm, often, with atrial beats at the transitions; there is retrograde conduction to the atria from junctional focus.

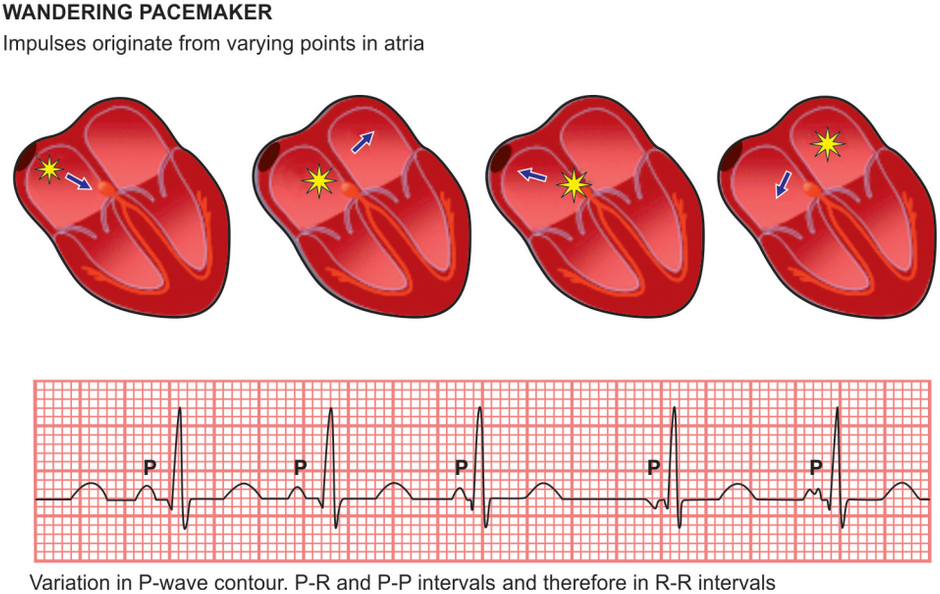

Fig. 20.24: Graph showing changing P-wave morphology between sinus node and atrioventricular junction in wandering pacemaker rhythm

Junctional rhythm

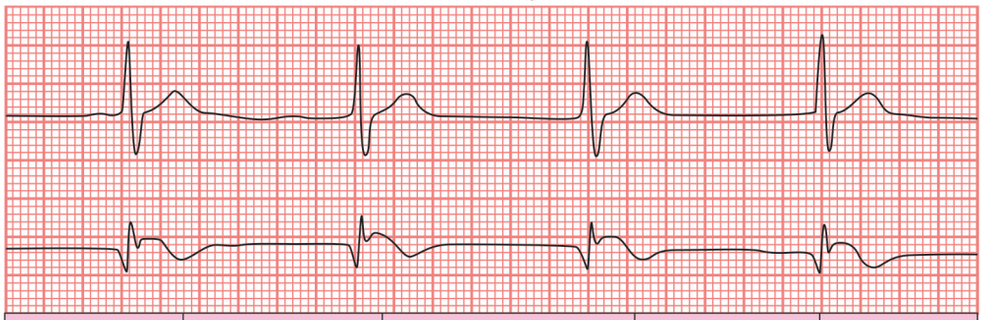

Heart rate	Rhythm	P-wave	PR interval (in seconds)	QRS (in seconds)
40–60 bpm	Regular	Inverted, absent or after QRS	<.12	<.12

Fig. 20.25: Junctional escape rhythm. This is a sequence of 3 or more junctional escapes occurring by default at a rate of 40–60 bpm. There may be AV dissociation or the atria may be captured retrogradely by the junctional pacemaker. In the ECG example below the retrograde P-waves are not seen and must be hidden in the QRS the significant Q-wave with ST-elevation in the bottom strip suggests an acute MI

Causes

1. It is associated with ischemic heart disease, involving the sinus node.
2. Acute rheumatic fever
3. Digitalis toxicity enhancing vagal tone.
4. Normal heart due to vagotonia.

Variations

Normal sinus rhythm with an accelerated junctional or atrial rhythm.

Treatment

If there is a normal escape mechanism, no treatment is indicated unless there is haemodynamic deterioration, and then, IV atropine may be appropriate, Ask the patient to cough; coughing decreases vagal tone and promotes the reappearance of the sinus rhythm. If the ectopic rhythm is enhanced, then the cause should be sought and treated.

JUNCTIONAL ECTOPIC MECHANISMS: PREMATURE AND ESCAPE JUNCTIONAL BEATS

A junctional beat takes its origin from the bundle of His and may be either premature or escape, and it may or may not follow retrograde conduction to the atria (Figs 20.25–20.35).

ECG Characteristics

1. Rate : It is of the underlying rhythm
2. Rhythm : Irregular as a result of the premature and escape junctional beats (PJCs) (underlying rhythm may be regular)
3. PR interval : Normal in the underlying sinus rhythm. The P-wave associated with the junctional beat may be absent if there is no retrograde conduction to the atria. If present, it is negative in II, III and aVF, and may appear before, during or after the QRS complex.
4. QRS complex : It is normal although it may be prolonged due to other conditions.

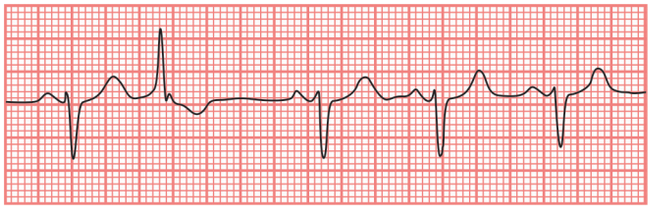

Fig. 20.26: Junctional ectopic



Fig. 20.27: Atrioventricular junctional rhythm with P-waves buried in QRST complex

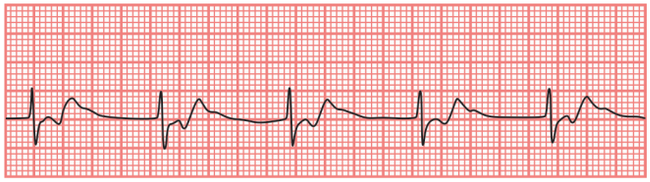

Fig. 20.28: Atrioventricular junctional rhythm with P-waves follow the QRS complexes and distorts ST-segment

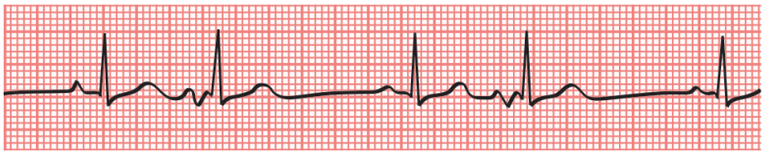

Fig. 20.29: Junctional ectopic with pause

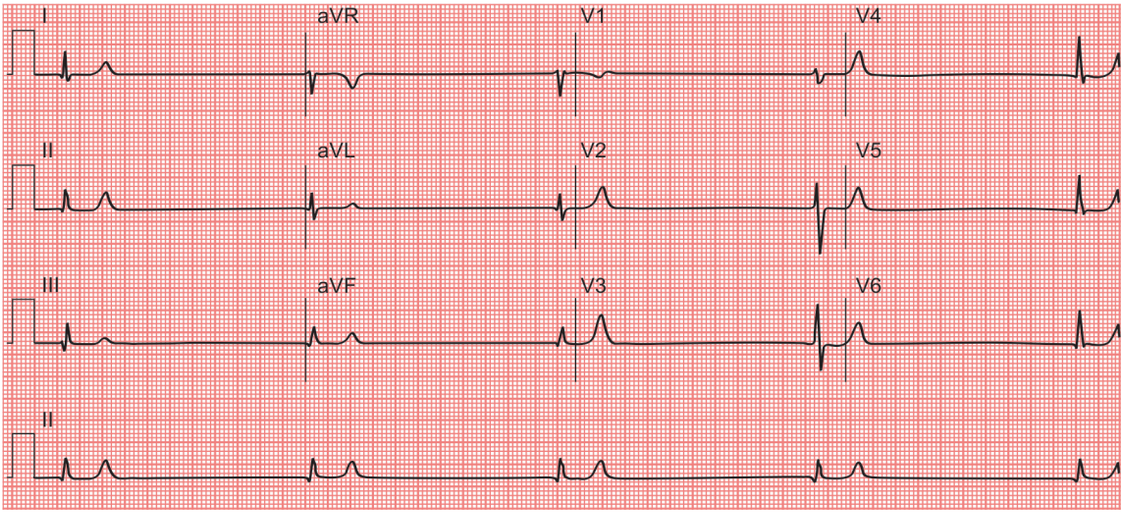

Fig. 20.30: ECG showing a junctional bradycardia with wide QRS, deep anterior Q-waves and tall anterior T-waves

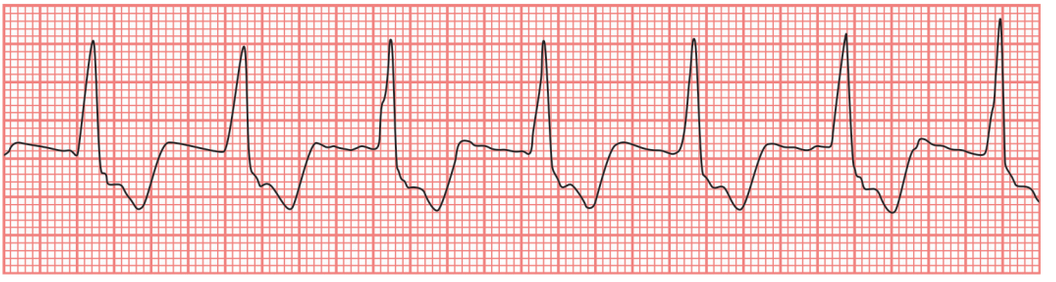

Fig. 20.31: Accelerated Idiojunctional rhythm

5. Distinguishing features : Normal QRS complex and a P-wave that is not seen, buried in the QRS complex, or negative in II, III, and aVF. If the P-wave precedes the QRS, it does so by no more than 0.12 sec.

Aetiological Factors

1. Digitalis
2. Acute inferior-wall myocardial infarction
3. Tricuspid prosthesis
4. Rheumatic fever
5. Distinguishing features: Escape junctional beats are caused by excessively long pauses in the cardiac cycle.

Variations

1. Premature junctional contraction (PJC) with the P receding the QRS complex
2. PJC with the P hidden in the QRS complex.
3. PJC with the P following the QRS complex.

Treatment

Normally, PJCs are not treated, but if their cause is identified, these should be, appropriately treated.

ACCELERATED IDIOJUNCTIONAL RHYTHM

It may be defined as that ectopic rhythm which originates from the bundle of His and monitors the ventricles at a rate of 60–100 beats/min. when the rate exceeds 100 beats/min, it is called junctional tachycardia.

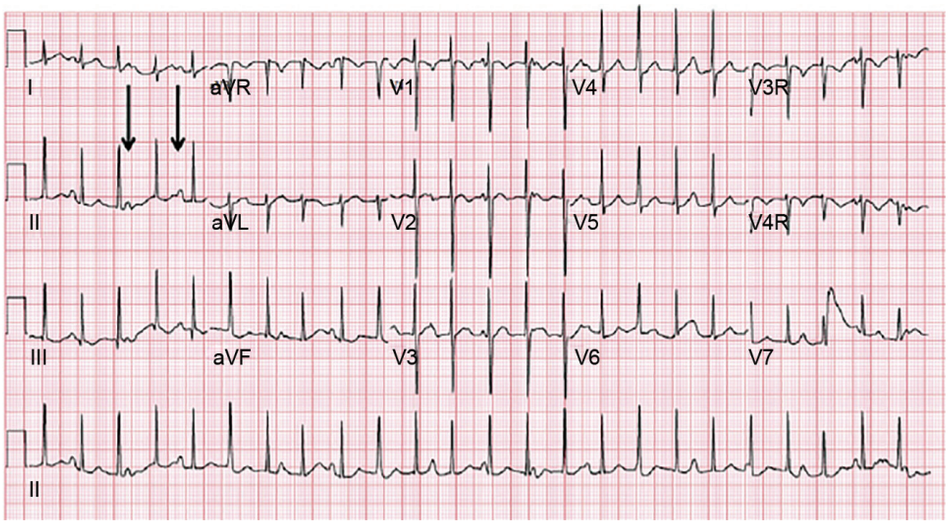

Fig. 20.32: Junctional ectopic tachycardia. ECG of 5-year-old girl with junctional ectopic tachycardia. Arrows denote P-waves with atrial rate of 100 bpm. Narrow QRS complexes originating from the AV junction occur at the rate of 144 bpm. There is AV dissociation with a faster junctional than atrial rate

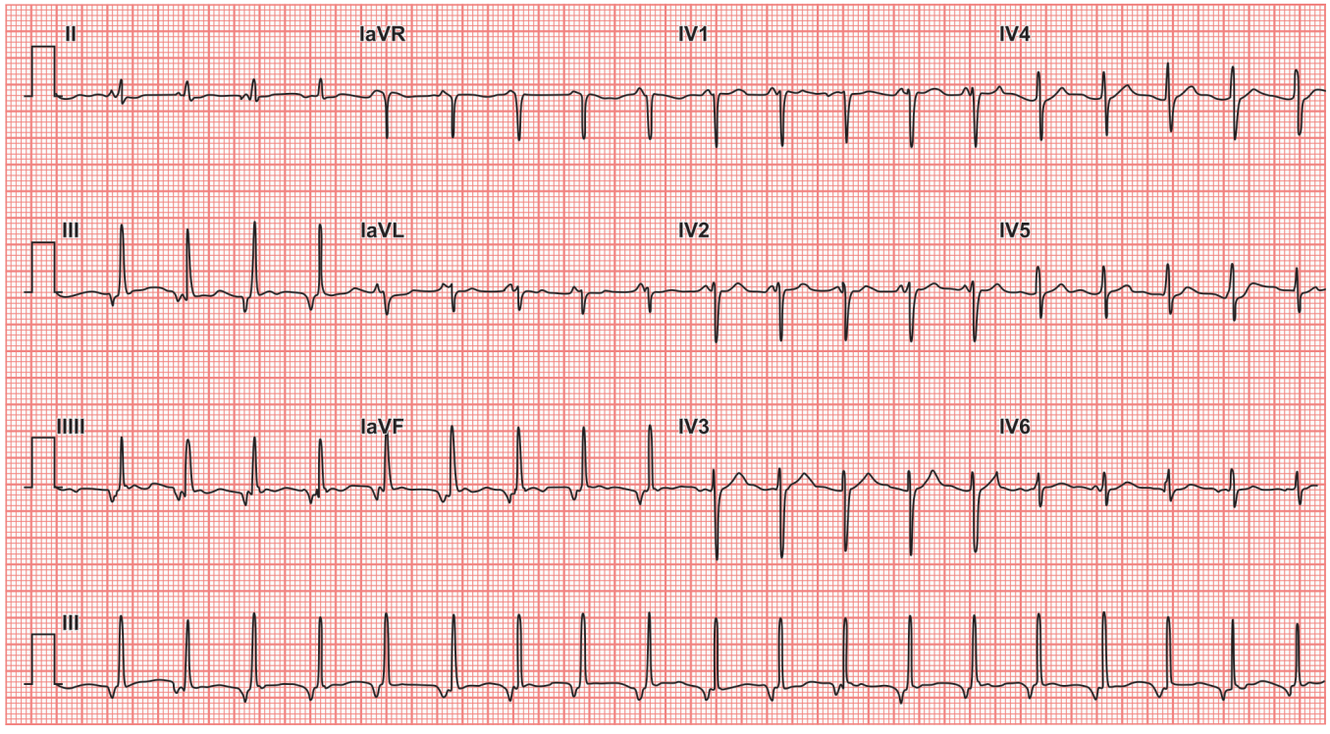

Fig. 20.33: Accelerated junctional rhythm. Narrow complex tachycardia at 115 bpm. Retrograde P-waves, inverted in II, III and aVF; upright in V1 and aVR. Short PR interval (<120 ms) indicates a junctional rather than atrial focus

ECG Features

1. Rate : 60–100 beats/min
2. Rhythm : Regular
3. PR interval : Normal in the underlying sinus rhythm. When the junctional focus begins to take over. The PR interval may appear to shorten. However. When this happens, there is no relationship between the P-wave and the QRS complex (AV dissociation).
4. QRS complex : Normal, although the QRS complex may be prolonged as a result of other conditions.
5. Distinguish features : A junctional rhythm reveals itself when its rate is about the same as that of the sinus node. Resulting in AV

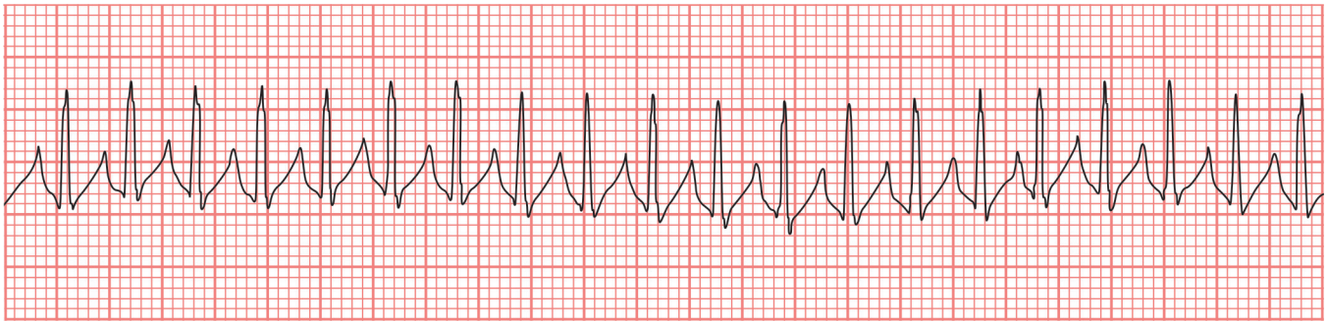

Fig. 20.34: ECG trace showing junctional tachycardia. Narrow QRS complexes with no visible P-waves

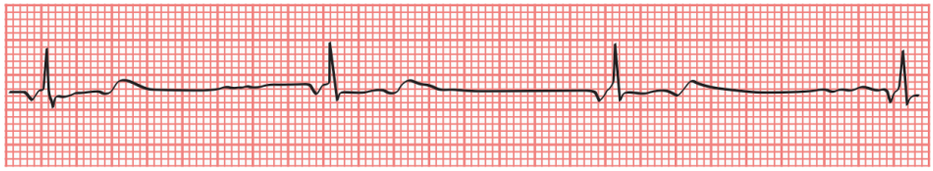

Fig. 20.35: ECG trace showing features of junctional escape rhythm

dissociation. P-waves get closer and closer to the QRS complex as the rate of the junctional focus exceeds that of the sinus node.

Aetiological Factors

1. Myocardial infarction
2. Digitalis toxicity.

Treatment: No treatment is advisable unless it is associated with hemodynamic disturbances when 0.5–1.0 mg atropine I/V may be required for the treatment.

Junctional Tachycardia

This kind of ectopic rhythm is produced as a result of focus, with enhanced automaticity, lying in the bundle of His, and controlling the ventricles at a rate of 100–130 beats/min. if the rate is less than 100 beats/min, it is termed accelerated junctional or idiojunctional rhythm.

ECG Features

1. Rate : 100–130 beats/min
2. Rhythm : Regular
3. PR interval : When the junctional focus begins to take over. The PR interval may appear to shorten; however, when this happens, there is no relationship between the P and the QRS complex (AV dissociation). The P-wave will be absent if there is no retrograde conduction to the atria; if present, it is negative in II, III, and aVF and may be before. During, or after the QRS complex depending on the relative speed of anterograde and retrograde conduction and the location of the ectopic focus in the bundle of His.
4. QRS complex : Normal, although the QRS complex may be prolonged as a result of other conditions.
5. Distinguishing features : A junctional rhythm of more than 100 beats/min. The QRS complex will be narrow if there is no associated intraventricular conduction problem.

Differential Diagnosis

There is hardly any other condition which closely resembles the junctional tachycardia unless its rate exceeds 130 beats/min, and then, there may difficulty in differentiating it from an AV node re-entry mechanism (PSVT). A vagal manoeuvre, usually, interrupts the PSVT and has no effect on junctional tachycardia.

Treatment

Identify and treat the cause.

JUNCTIONAL ESCAPE

In junctional (AV junctional) beat or rhythm the atrial depolarization current points cephalad and to the right, away from lead II and toward lead aVR. Therefore, the P-wave, if seen, would be negative in lead II and positive in lead aVR. However this P-wave is usually buried by the QRS complex and not visible. On less common occasions when the P-wave is visible, it may be either immediately before or immediately after the QRS complex. Since the impulse is conducted to the ventricles via the His bundle and bundle branches, the QRS complex of junctional beats is narrow and looks exactly like the QRS complex of the sinus beat. The inherent rate of junctional escape rhythm is 40–60 beats/min.

PAROXYSMAL SUPRAVENTRICULAR TACHYCARDIA RESULTING FROM AV NODAL RE-ENTRY

It has it supraventricular origin, and, usually, comes in recurrent episodes, and, hence, termed as paroxysmal supraventricular tachycardia (PSVT). It is characterized by spontaneous and abrupt termination. It may be, further, supported by either an AV nodal re-entry or by an AV re-entry circuit and achieves rates of 170–250 beats/min (Figs 20.36–20.38).

ECG Characteristics

1. Rate : 170–250 beats/min
2. Rhythm : Regular
3. PR interval : It may be normal in the sinus rhythm. The P-R interval at the onset of the tachycardia is, abnormally, long
4. QRS complex : Identical features of the sinus conducted QRS complex. It may be aberrantly, conducted at times.
5. Distinguishing features : A narrow QRS tachycardia that, usually, exceeds 170 beats/min and begins, abruptly, with a prolonged P-R interval. This is necessary to accommodate the refractoriness, and establish the re-entry circuit. The rest of the P-waves will either not be seen or they will distort the end of the QRS (P-waves just barely showing). There is no alternans of the QRS after the first 5–6 seconds: may be interrupted by a vagal manoeuvre.

Aetiological Factors

1. One early PAC
2. Rarely, a PJC

Variations

1. AV nodal re-entry, using a slow anterograde intranodal pathway and a fast retrograde pathway, causing simultaneous atrial and ventricular activation (P buried within or peeking out at the end of the QRS).
2. AV nodal re-entry, using a fast anterograde intranodal pathway and a slow retrograde pathway, causing atrial activation to follow ventricular activation with a long PR interval.

Treatment

Short paroxysms may require no treatment.

1. Termination may, often, be achieved by vagal manoeuvres, but carotid artery massage should not be advised in patients having or likely to have carotid artery disease.
2. Intravenous verapamil is considered by some to the treatment of choice, but should be used cautiously in those patients who had poor left ventricular functions.
3. Digitalis and beta-blockers, which prolong AV nodal conduction and refractoriness in both alpha and beta pathways, are usually, effective.
4. Type IA anti-arrhythmic agents may be useful.
5. Oral diltiazem, 90 mg, 3 times a day, may be effective in preventing recurrence.

In situations, where one can find severe hemodynamic disturbances, direct synchronous cardioversion, using 40 w/s, is often, quite contributory.

VAGOTONIC MANOEUVRES FOR PSV

1. **Carotid sinus stimulation:** Out of vagotonic manoeuvres, carotid sinus stimulation is, commonly, practised by physicians and quite reliable test when done by an experienced health worker. The main purpose of this test is to create an elevation of blood pressure in the

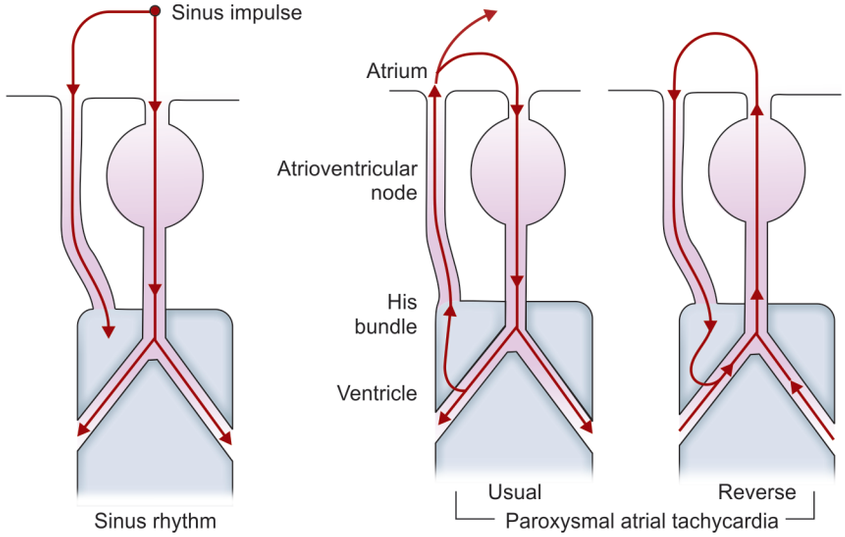

Fig. 20.36: Normal conduction system and the accessary atrioventricular connection showing the conduction sequence during sinus rhythm in the left hand panel and during tachycardia in the middle and right hand panels

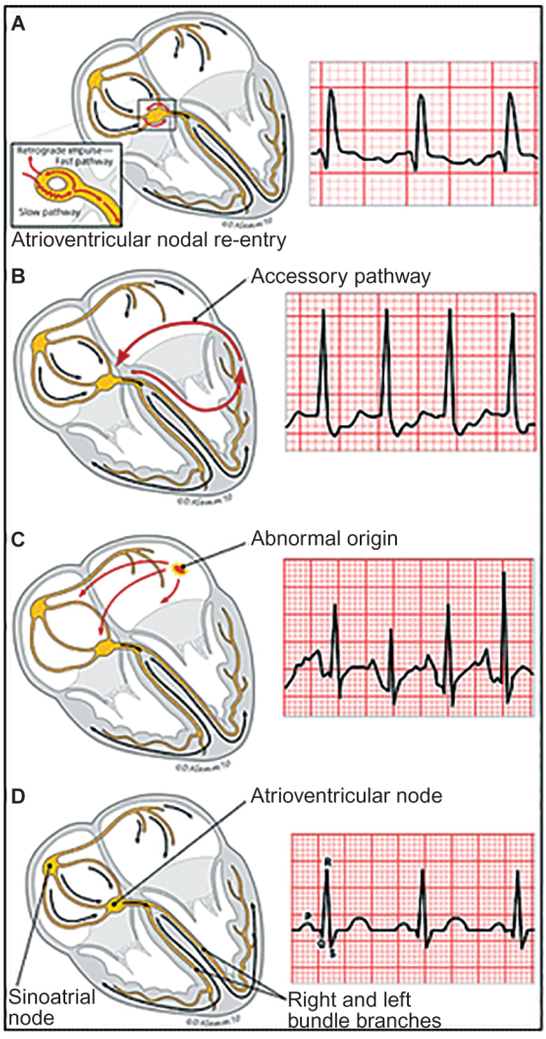

Fig. 20.37: (A) In typical atrioventricular nodal re-entrant tachycardia (antegrade conduction down the slow atrioventricular nodal pathway and retrograde conduction up the fast pathway), the retrograde P-wave may not be seen or may be visible early after the QRS complex. When visible, it often appears as a pseudo R wave in lead V1. (B) In atrioventricular reciprocating tachycardia, there is typically a short RP interval, with the timing and morphology of the P-wave dependent on the site and conduction velocity of the accessory pathway. (C) Atrial tachycardia typically produces variable RP and PR intervals because atrioventricular conduction depends on atrioventricular nodal properties and the tachycardia rate. In atrial tachycardia, the morphology and axis of the P-wave are influenced by atrial site of origin and tachycardia mechanism. Short- and long-term therapies are discussed in the text. (D) Normal sinus rhythm

carotid sinus so that there will be reflex slowing of AV conduction. This is achieved by pressing the carotid sinus against the lateral processes of the vertebra. It will cause pain for a seconds for which the individual should be educated before performing this manoeuvre.

2. **Technical aspects:** To start with, grip the patient's chin, with your right palm, and swing your right thumb around; you will find that it, automatically, falls at the angle of the jaw, the location of the carotid bifurcation. This area, then, is pressed with tolerable force with the thumb for not more than 3 seconds as a longer duration of pressure, with greater force, may lead to dangerous complications. Prior to the performance of this manoeuvre, one should always record the history of transient ischemic attacks and listen to the carotid bruit. One should never perform sinus stimulation test without ECG monitoring so that the results can be observed and acted upon, if required. This manoeuvre is relatively safe and effective.
3. **Gagging:** This is a good vegotonic manoeuvre. If the episodes of PSVT occur, instruct the patient to try to vomit.
4. **Trendelenburg position:** The patient can be instructed to perform this at home.
5. **Valsalva manoeuvre:** Blowing against a closed glottis is an effective vegotonic manoeuvre.
6. **Squatting:** Squatting with hands, gripped across the belly and pulling in, is a fairly easy thing to do and is very effective. This is obvious not for the older patient who cannot squat. It is, usually, prescribed for a younger patient. It is not only ineffective, but it is also dangerous as it may lead to retinal detachment in a few elderly patients.

ATRIAL FUSION COMPLEXES

The collision of two atrial impulses, within atria, leads to the formation of a new complex, which is termed as atrial fusion complex (Fig. 20.39).

ECG Characteristics

1. Rate : That of the underlying rhythm
2. Rhythm : Regular
3. PR interval : The PR interval of the fusion beat is the same as that of the sinus rhythm. The P-wave of the fusion beat is, sometimes, isoelectric or intermediate between the P-waves of the fusing impulses.
4. QRS complex : It is same as that of the underlying rhythm.
5. Distinguishing features : There are other atrial ectopic beats in the tracing, and there is reason to believe that one beat was due at the same time as the sinus P-wave.

Causative Factors

These are the same as those of the atrial ectopics or atrial rhythm.

Variations

1. Atrial parasystole
2. Wandering pacemaker

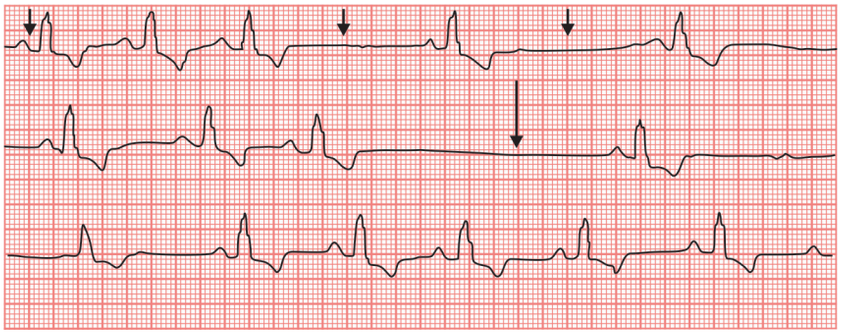

Fig. 20.38: Graph explaining as to how pressure on carotid sinus produces sinus arrest or sinus block

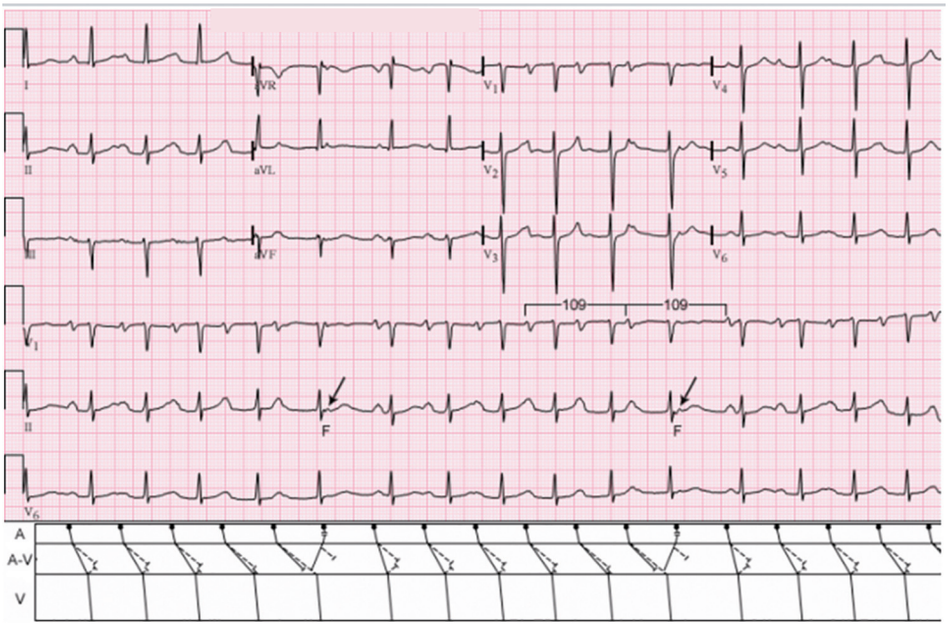

Fig. 20.39: ECG showing atrial fusion beats (F)

Atrial Parasystole

Atrial parasystole is an independent and undisturbable ectopic rhythm whose pacemaker cannot be discharged by impulses of the dominant (usually, sinus) rhythm. It is far less common than the ventricular parasystole (Fig. 20.40).

ECG Characteristics

1. Rate : That of the underlying rhythm.
2. Rhythm : Irregular, because of atrial premature beats
3. PR interval : Normal
4. QRS complex : Normal
5. Distinguishing features : Atrial ectopic with no fixed coupling Interectopic intervals that are multiples of a common denominator

Cause

Myocardial infarction.

Differential Diagnosis

PACs and fusion beats

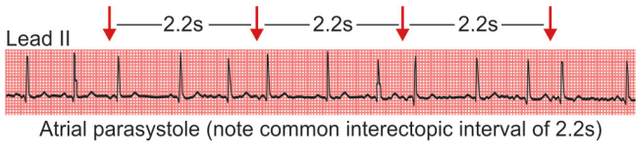

Fig. 20.40: Parasystolic rhythms involve an independent ectopic pacemaker resulting in nonfixed coupled premature beats. Parasystole may occur in the atria, as seen in this example, in the AV junction, and in the ventricles. Note the common interectopic interval separating the parasystolic PACs

Pre-excitation Syndromes and Accessary Pathways

Pre-excitation syndrome is a condition where the ventricles of the heart become depolarized too early, which leads to their partial premature contraction (Figs 20.41–20.58 and Table 20.5). Normally, the atria (chambers taking venous blood) and the ventricles (chambers pumping blood towards organs) are electrically isolated, and electrical contact between them exists only at the 'atrioventricular node'. In all pre-excitation syndromes, at least one more conductive pathway is present. Physiologically, the normal

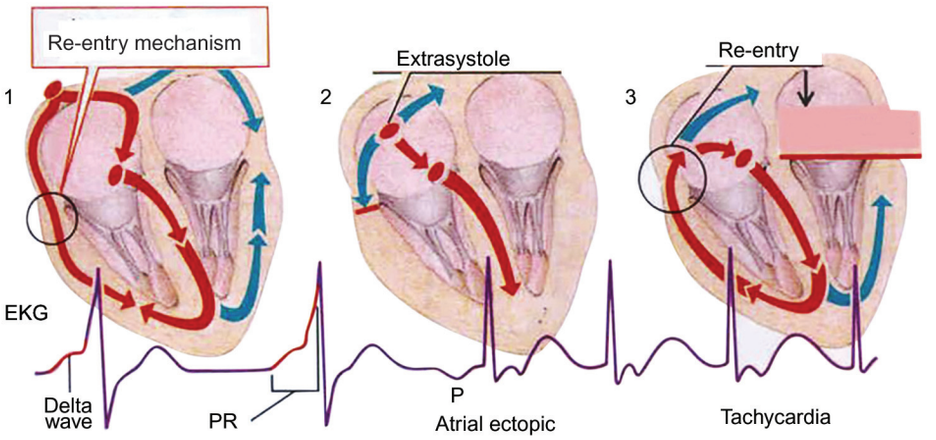

Fig. 20.41: Diagrams explaining re-entry mechanism in the WPW syndrome, i.e. extrasystoles and supraventricular tachycardia

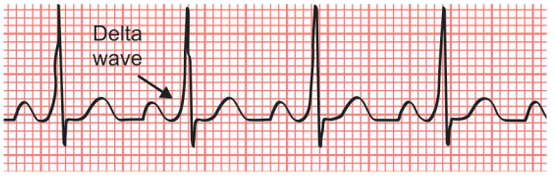

Fig. 20.42: Short PR (<120 ms), broad QRS and delta waves in WPW syndrome (arrows)

electrical depolarization wave is delayed' at the atrioventricular node to allow the atria to contract before the ventricles contract.

This function of the AV node is important, be cause if the signals generated in the atria of the heart were to increase in rate (as they do during atrial fibrillation or atrial flutter), the AV node will limit the electrical activity that conducts to the ventricles. For instance, if the atria are electrically activated at 300 beats per minute, half those electrical impulses are blocked by the AV node, so that the ventricles are activated at 150 beats per minute (giving a pulse of 150 beats per minute). Another important property of the AV node is that it slows down individual electrical impulses. This is manifest on the ECG as the PR interval, the time from activation of the atria (manifest as the P-wave) and activation of the ventricles (manifest as the QRS complex) individuals with WPW syndrome have an accessory pathway that connects the atria and the ventricles, in addition to the AV node. This accessory pathway is known as the **bundle of Kent**. This accessory pathway does not share the rate-slowing properties of the AV node, and may conduct electrical activity at a significantly higher rate than the AV node. For instance, in the example above, if an individual had an atrial rate of 300 beats per minute, the accessory bundle may conduct all the electrical impulses from the atria to the ventricles, causing the ventricles to activate at 300 beats per minute. Extremely fast heart rates are potentially dangerous, and cause hemodynamic instability. In some cases, the combination of an accessory pathway and cardiac arrhythmias can trigger ventricular fibrillation, a leading cause of sudden cardiac death.

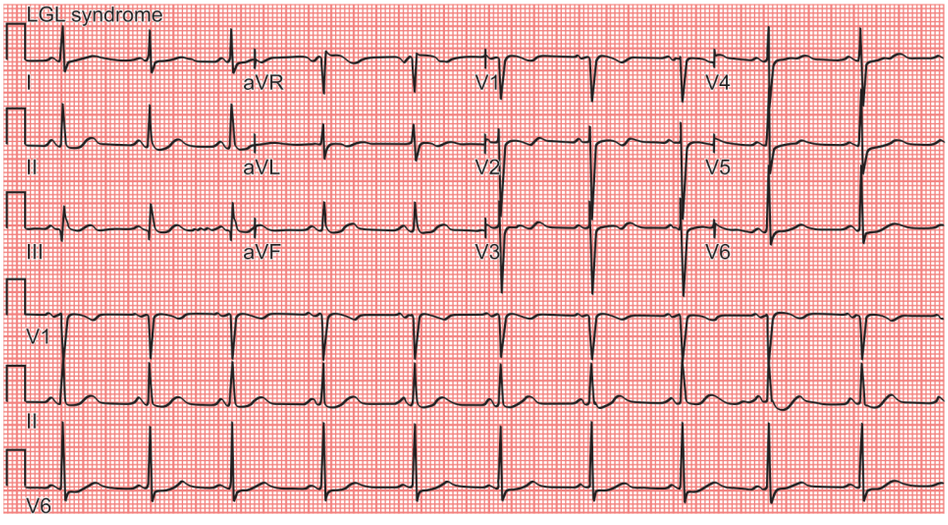

Fig. 20.43: ECG trace showing LGL syndrome. Very short PR interval, narrow QRS complexes and no evidence of delta waves

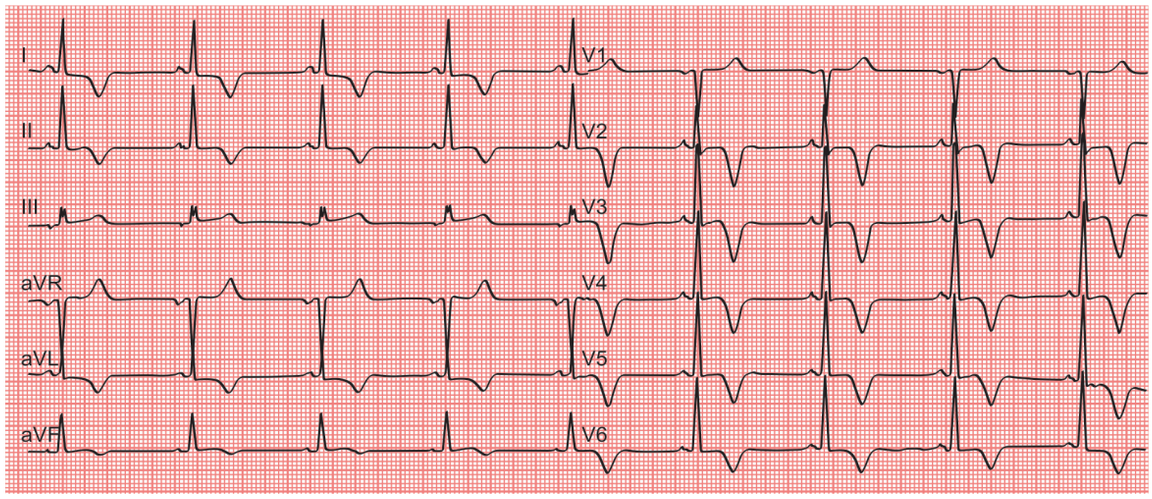

Fig. 20.44: ECG showing type A WPW pattern with dominant R-wave in V1 and right precordial T-wave inversions simulating RVH. Sinus rhythm with short PR interval and large delta waves seen best in precordial leads, and confirming Wolff-Parkinson-White (WPW) syndrome of pre-excitation down an accessory pathway. There are large upright R-waves in right precordial leads because the accessory pathway is left lateral, depolarizing the ventricle from left to right) and repolarization

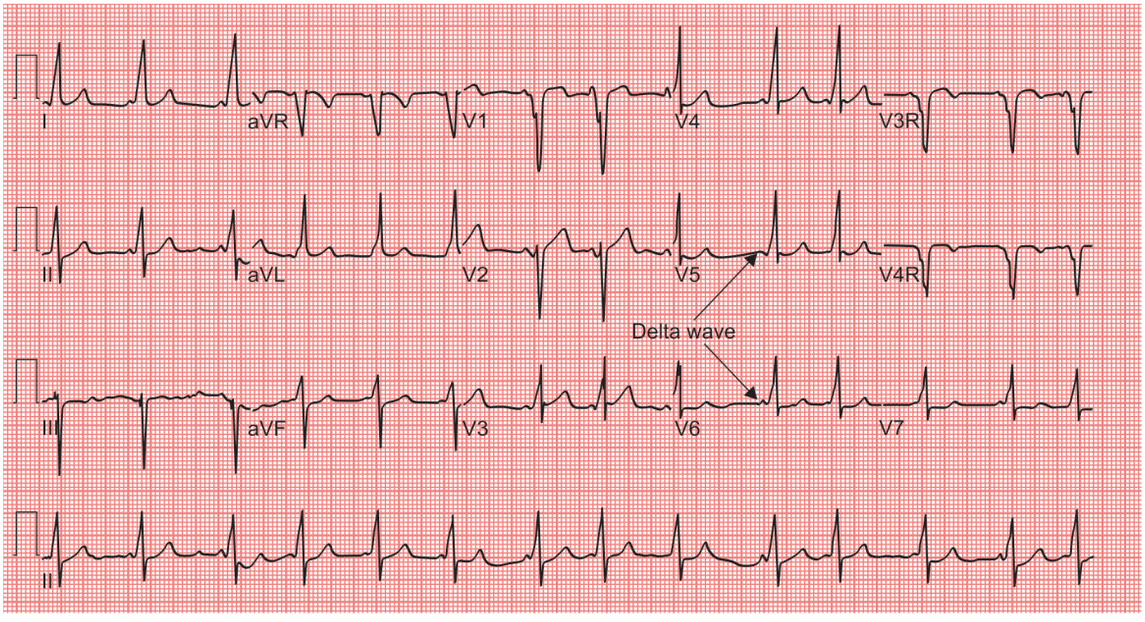

Fig. 20.45: Sinus rhythm with very short PR interval (<120 ms). Broad QRS complexes with a slurred upstroke to the QRS complexes—the *delta* wave. Dominant S-wave in V1—this pattern is known as 'Type B' WPW and indicates a right-sided accessory pathway. Tall R-waves and inverted T-waves in the inferior leads and V4–V6 mimic the appearance of left ventricular hypertrophy—again, this is due to WPW and does not indicate underlying LVH

Table 20.5: Showing conduction pathways in various types of pre-excitations

Type	Conduction pathway	PR interval	QRS interval	Delta wave
Wolff-Parkinson-White syndrome	Bundle of Kent (atria to ventricles)	Short	Long	Yes
Lown-Ganong-Levine syndrome	James bundle (atria to bundle of His)	Short	Normal	No
Mahaim-type	Mahaim fibers	Normal	Long	Yes

Diagnosis

One beat from a rhythm strip in V2 demonstrating characteristic findings in WPW syndrome. Note the characteristic delta wave (subtler here than in some cases), the short PR interval of 0.08 seconds, and the long QRS complex at 0.12 seconds. WPW syndrome is commonly

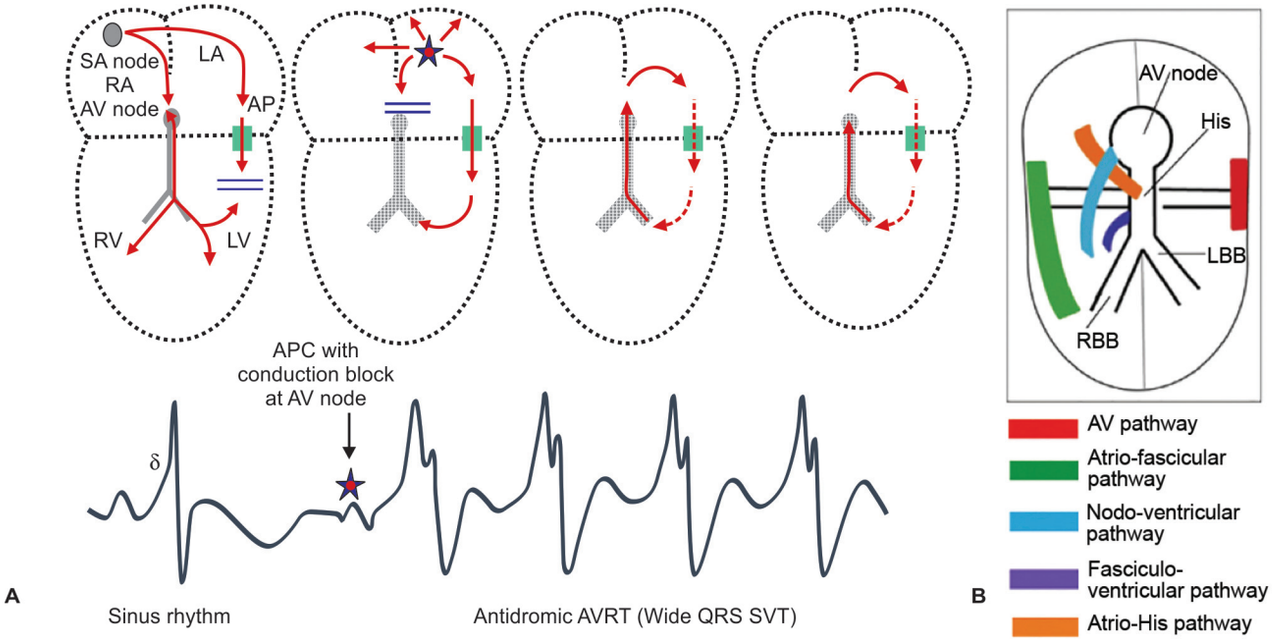

Fig. 20.46: (A) Conduction of cardiac impulse through aberrant pathways. (B) Schema of type of accessory pathways

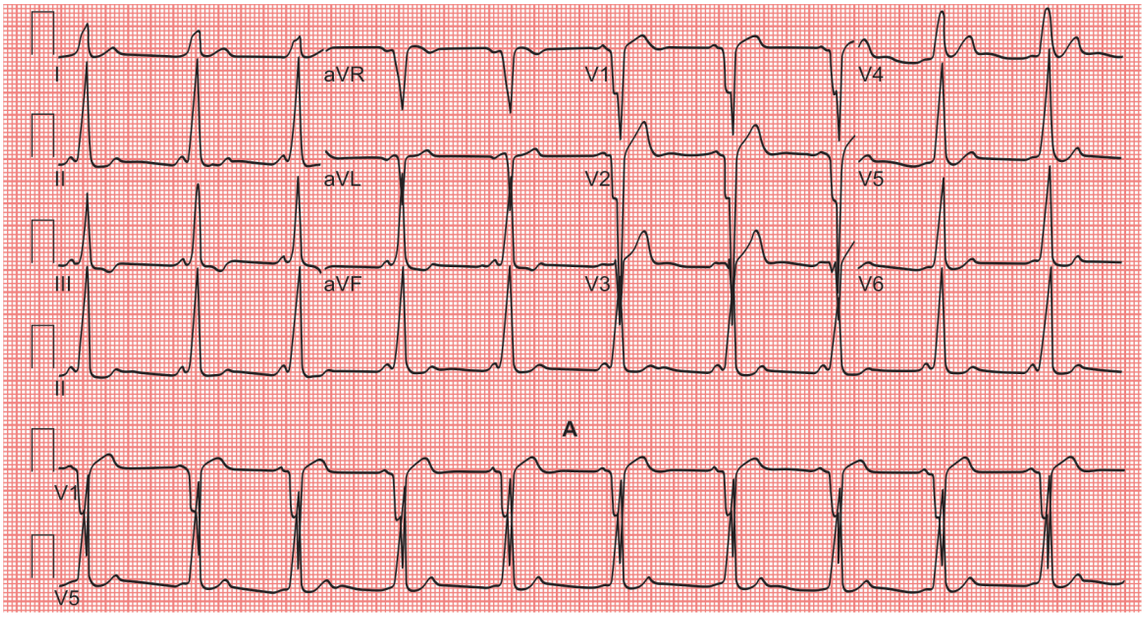

Fig. 20.47: Right anteroseptal accessory pathway (AP). A left axis (with a negative delta wave in lead V1) suggests a right lateral AP

diagnosed on the basis of the surface ECG in anasymptomatic individual. In this case it is manifested as a **delta wave**, which is a slurred upstroke in the QRS complex that is associated with a short PR interval.

The short PR interval and slurring of the QRS complex is actually the impulse making it through to the ventricles prematurely (across the accessory pathway) without the usual delay experienced in the AV node. If the patient experiences episodes of atrial fibrillation, the ECG will show a rapid polymorphic wide-complex tachycardia (without torsades de pointes). This combination of atrialfibrillation and WPW is considered dangerous, and most antiarrhythmic drugs are contraindicated. When an individual is in normal sinus rhythm, the ECG characteristics of WPW syndrome are a short PR interval, widened QRS complex (greater than 120 ms in length) with slurred upstroke of the QRS complex, and secondary repolarization changes reflected in ST-segment-T-wave changes. In individuals with WPW syndrome, electrical activity that is initiated in the SA node travels through the accessory pathway *as well as* through the AV node to activate the ventricles via both pathways. Since the accessory pathway

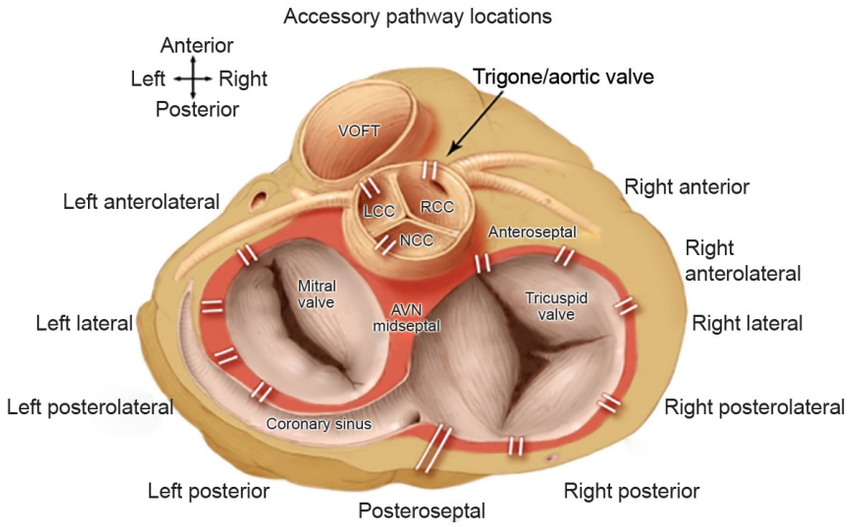

Fig. 20.48A: Atrial ventricular accessory pathways may occur anywhere along the atrial ventricular annulus. Note the posteroseptal region is not a part of the true septum. Note also the position of the aortic annulus interspersed between the right and left anteroseptal regions. Midseptal pathways are among the most difficult to ablate because of the proximity of the AV node. VOFT=ventricular outflow tract; LCC=left coronary cusp; RCC=right coronary cusp; NCC=noncoronary cusp; AVN=AV node

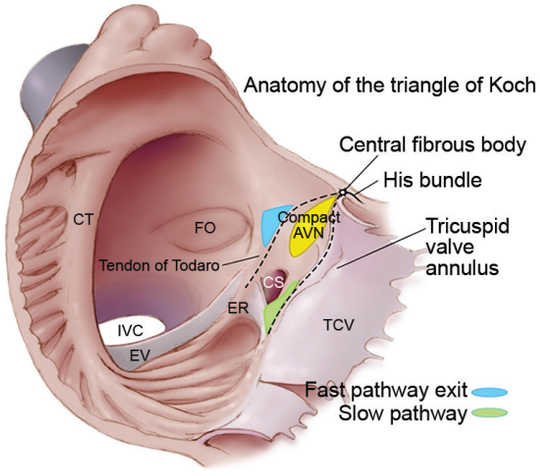

Fig. 20.48B: The true interatrial septum near the tricuspid annulus consists of the anterior and midseptal regions. Midseptal pathways are inserted into the triangle of Koch region, close to the compact AV node. Accurate assessment of pathway slant and ablation preferably of the ventricular insertion site along with the use of cryoenergy may all be required to minimize the risk of AV block when ablating pathways in this region. CT=crista terminalis; FO=Forman ovale; EV=Eustachian valve; IVC=inferior vena cava; TCV=tricuspid valve; CS=coronary sinus; ER=Eustachian ridge; AVN=AV node

does not have the impulse slowing properties of the AV node, the electrical impulse first activates the ventricles via the accessory pathway, and immediately afterwards via the AV node. This gives the short PR interval and slurred upstroke to the QRS complex known as the delta wave. Patients with WPW often exhibit more than one accessory pathway, and in some patients as many as eight additional abnormal pathways can be found. This has been seen in individuals with Ebstein's anomaly. Wolff-Parkinson-White syndrome is sometimes associated with Leber's hereditary optic neuropathy (LHON), a form of mitochondrial disease. WPW syndrome is, basically, a type of pre-excitation characterized by narrow P-R interval, delta wave, wide QRS complex and normal PQRST duration on electrocardiographic recording. It was first described by three workers, Wolff, Parkinson and White, in 1930. However, ECG parameters of the syndrome were clearly demonstrated by Wilson in 1915, and, later, by Wedd in 1921. The WPW syndrome is considered as a benign entity and no subjective symptoms or hemodynamic changes are recorded unless associated with ecotopic tachyarrhythmias. The tachyarrhythmias may be recorded at birth or during infancy, childhood or adult life. The individuals, already, disgnosed as having WPW syndrome are, usually, found to be in sinus rhythm suffering from no organic heart ailment in about 60.70% of the cases. The true incidence of the WPW syndrome is difficult to assess, but it is estimated to be 0.15–0.2% in the general population. The syndrome occurs more frequently in men than in women, with an incidence of 54–70% in males.

Diagnosis in WPW Syndrome

It can be disgnosed by the following methods.

Clinical Manifestations

The clinical manifestations of the WPW syndrome are mainly dependent up the physiologic properties of the accessory pathways. The dominant symptom which these patients mostly manifest is the recurrent palpitation due to underlying paroxysmal regular supraventricular tachycardia and/or atrial fibrillation which may be, at times, so severe as to cause sudden death. The other symptoms in such patients are, dyspnea, anginal pain, perspiration, fatigue, anxiety, dizziness and oliguria.

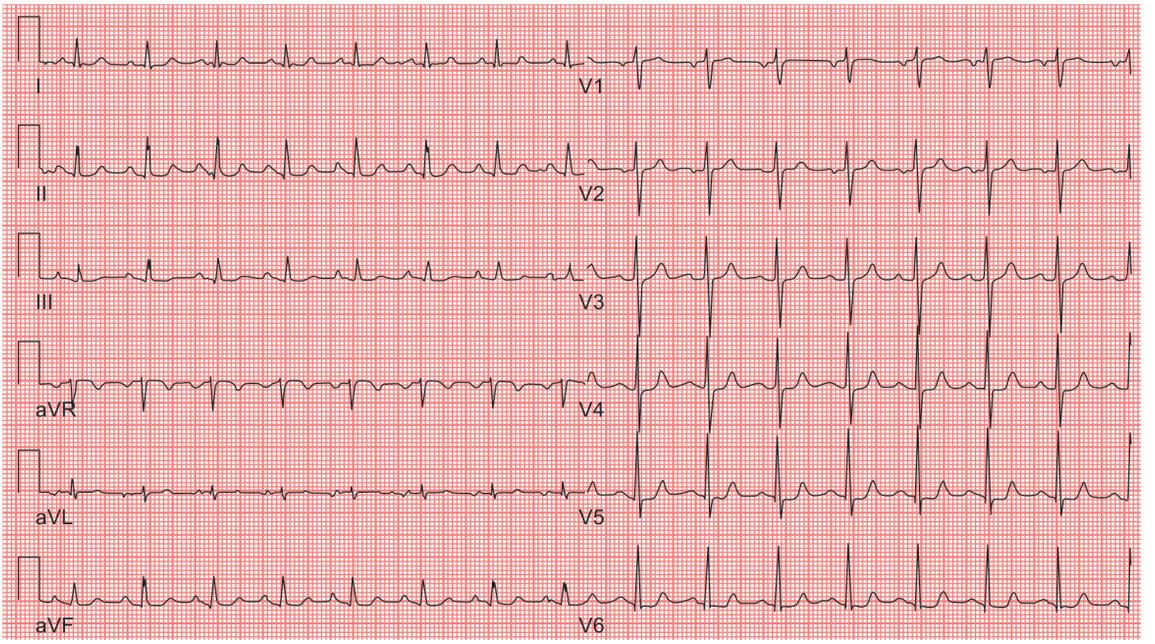

Fig. 20.49: Right lateral accessory pathway (AP). If the delta waves in the inferior leads are negative, then it denotes a posteroseptal AP right, or left, depending on the delta wave vector in lead V1 as described above

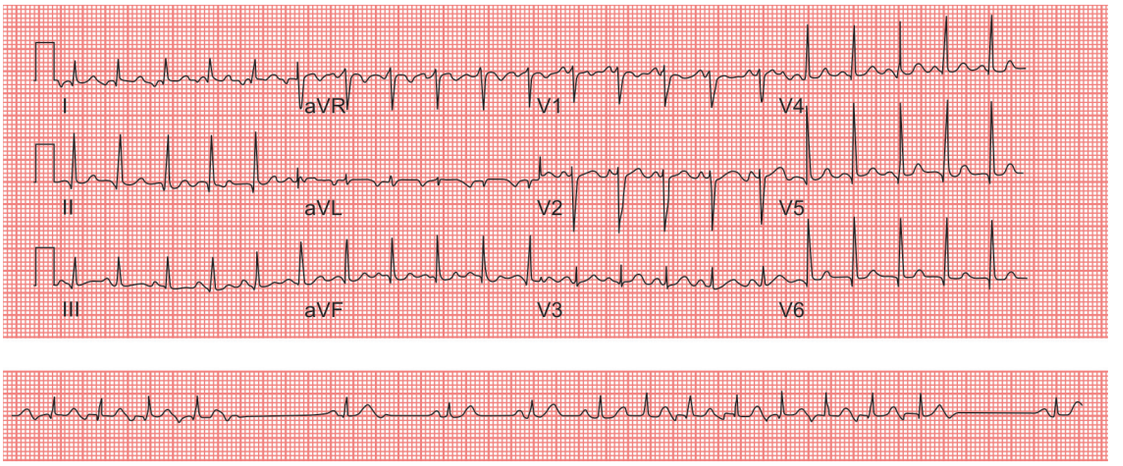

Fig. 20.50: Permanent from of junctional reciprocating tachycardia (PJRT) in a patient with a left-sided accessory pathway. The 12-lead electrocardiogram demonstrates a long RP interval-short PR interval tachycardia, which in contrast to the usual form of PJRT, exhibits negative P-waves in leads I and aVL. The rhythm strips below (lead I) indicate that whenever a nonconducted P-wave occurs, the tachycardia always terminates, only to begin again after several sinus beats

Parameters

The typical ECG findings include a short P-R interval and a prolonged QRS interval due to a delta wave (initial slurring of the QRS complex). Recoginition of the delta wave is a key point in the diagnosis of the syndrome. In some patients who have WPW syndrome, however, the delta wave may *not* be obvious. However, the P-R interval may be longer than 0.12 see, whereas the QRS interval may be narrower than 0.10 see in the proven WPW syndrome. The P-R and the QRS intervals in the WPW syndrome are greatly influenced by the pre-existing values of these intervals.

The term **'Lown-Ganong-Levine (LGL) syndrome'** is used when the ECG shows a short P.R interval and narrow QRS complex, without a clear-cut delta wave, associated with recurrent tachyarrhythmias. In reality, the LGL syndrome is considered to be a variant of the WPW syndrome. It is very well known that many normal individuals may have a short P-R interval, particularly during stressful situations. Obviously, this isolated ECG finding, usually, does not have any clinical significance in WPW syndrome: In a doubtful case of WPW syndrome, the His bundle ECG may be necessary to confirm the diagnosis. The H-V interval is shorter than normal; the His

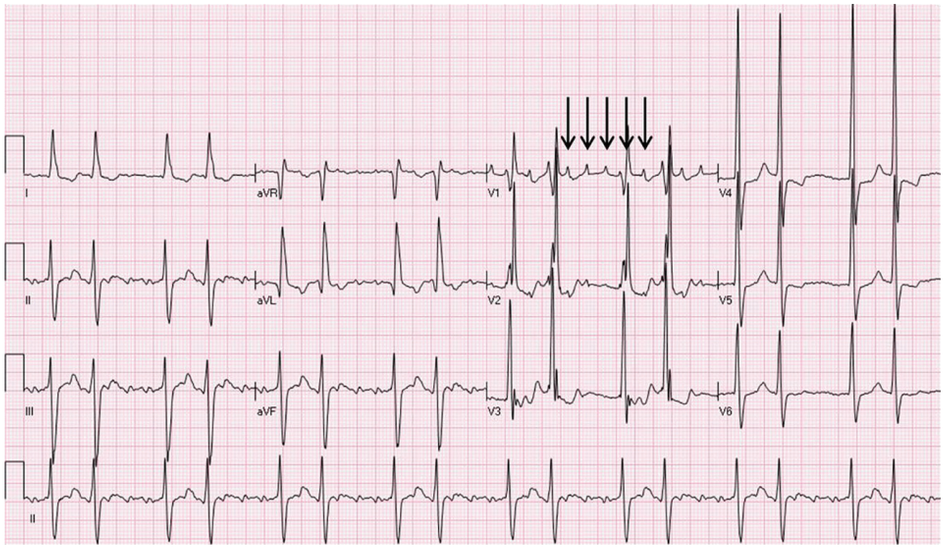

Fig. 20.51: ECG is suggestive of an atypical atrial flutter with variable atrioventricular conduction. An electrophysiology study demonstrated a macro-reentrant atrial tachycardia around the mitral annulus with an area of slow conduction medial to the left atrial appendage on the anterior mitral annulus. Solid arrows point to the atrial tachycardia waves in lead V1

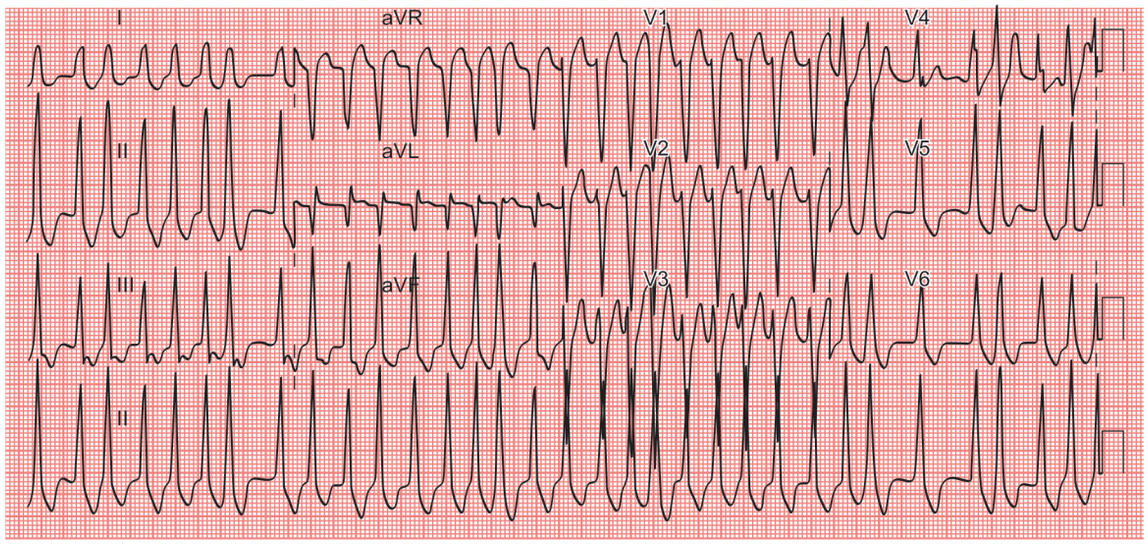

Fig. 20.52: Pre-excited wide complex tachycardia in a patient with Wolff-Parkinson-White (WPW) and atrial fibrillation

bundle potential may occur simultaneously with the ventricular deflection, or the His bundle potential may occur even later than the onset of the ventricular deflection. These findings occur because of a premature activation of a portion of the ventricles by way of anomalous conduction.

Classification of WPW Syndrome

The WPW syndrome is traditionally classified into two types, A and B, depending upon the direction in the delta wave. This classification, however, is an over simplification because many cases with WP syndrome do not belong either to type A or B. The direction of the delta wave is primarily influenced by the location of the accessory pathway.

Type A WPW Syndrome

i. In type A, the delta wave is directed anteriorly (commonly to the right and less commonly to the left).
ii. In general, lead VI shows R. RS, Rs, RSr' and Rsr' patterns, whereas leads V5 and V6 show Rs or R deflection.
iii. Superficially, type A WPW syndrome resembles the right bundle branch block (RBBB), right ventricular hypertrophy, and posterior myocardial infarction (MI).
iv. When the QRS complexes, in all precordial leads, are upright, a type A WPW syndrome should be considered as the first diagnostic possibility.
v. In type A, a premature activation occurs in the left ventricle.

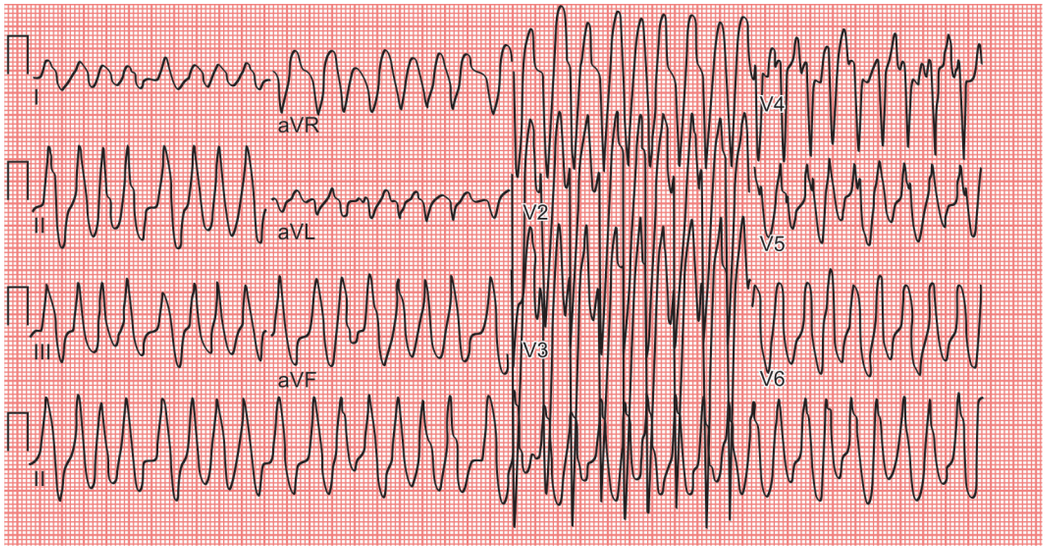

Fig. 20.53: ECG shows atrial fibrillation in a patient with WPW; rapid, irregular, broad complex tachycardia (overall rate >200 bpm) with a LBBB morphology (dominant S-wave in V1). This could easily be mistaken for AF with LBBB. However, the morphology is not typical of LBBB, the rate is too rapid (up to 300 bpm in places, i.e. too rapid to be conducted via the AV node) and there is a subtle beat-to-beat variation in the QRS width which is more typical of WPW (LBBB usually has fixed width QRS complexes)

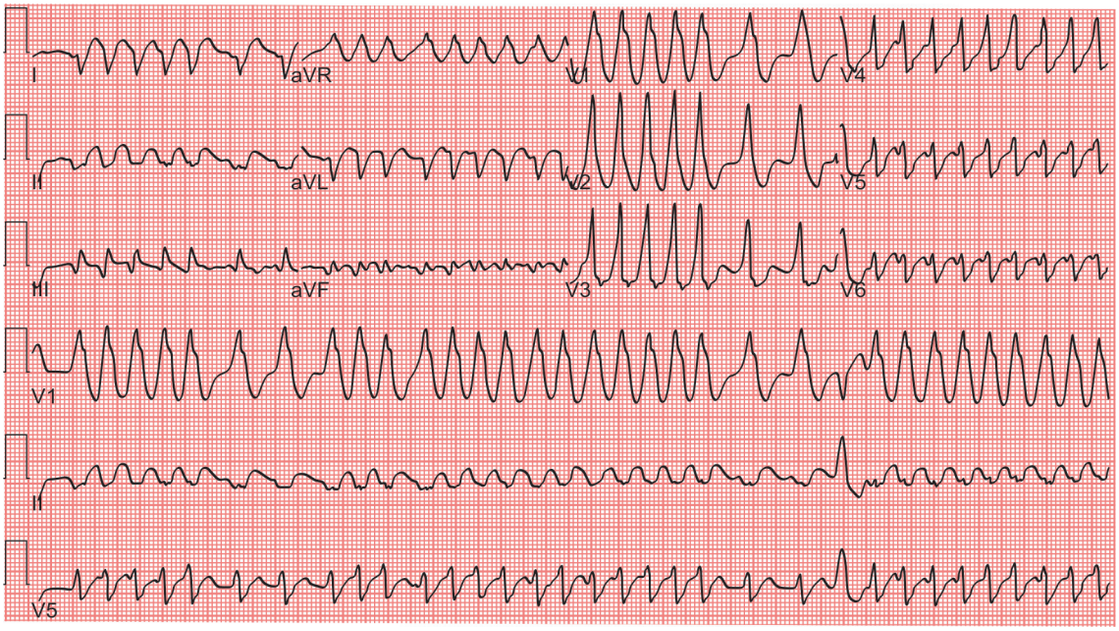

Fig. 20.54: ECG of a patient with atrial fibrillation and WPW syndrome. Note the wide-complex, irregularly irregular rhythm with delta waves. This ECG can be mistaken for polymorphic ventricular tachycardia (Tosades de Pointes), however the QRS axis remains stable in the setting of atrial fibrillation with WPW

Type B WPW Syndrome

i. In type B, the delta wave is directed posteriorly (commonly to the left and less commonly to the (right).
ii. Thus, the left precordial leads (leads I, aVL and V4) show tall R waves with delta waves, whereas leads V1-V2 show negative QRS complexes (Q-S waves) with delta waves.
iii. The ECG findings in type B WPW syndrome may closely resemble left bundle branch block (LBBB) and left ventricular hypertrophy.
iv. At times, a pseudoanteroseptal myocardial infarction is produced in WPW syndrome, type B.
v. In type B, a premature activation takes place in the right ventricle. In both type A and type B WPW syndromes, the delta wave is, often, directed

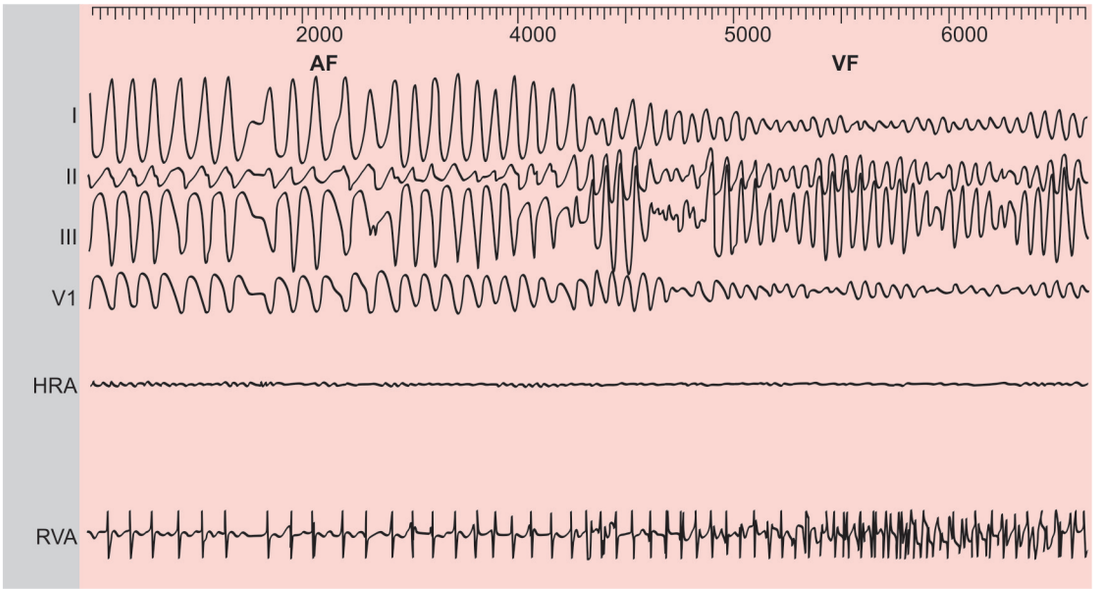

Fig. 20.55: ECG showing atrial fibrillation (AF) becoming ventricular fibrillation (VF)

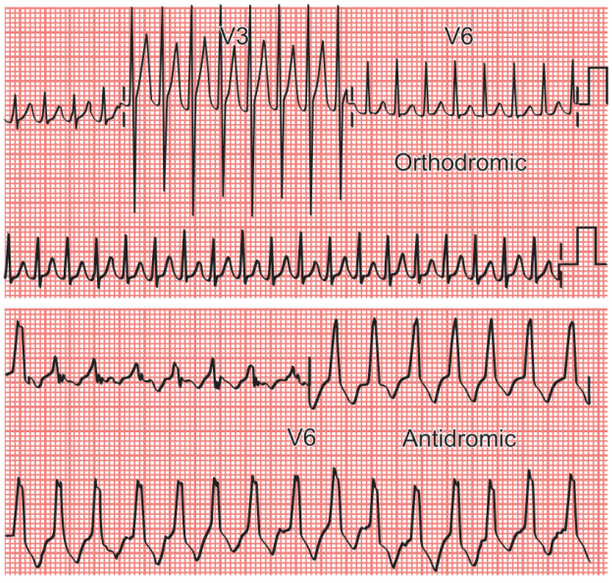

Fig. 20.56: ECG showing difference between the two conduction pathways. In orthodromic the normal 'Fast' conduction pathway of the ventricles is 'borrowed' by the arrhythmia, so the complexes on an ECG are narrow. In antidromic AVRT the conduction of the signal through the ventricles travels from cell to cell (more slowly) and therefor the complexes on an ECG are broad

superiorly. This ECG) finding, commonly, produces Q-S or Q-waves in leads II, III and aVF, that closely.

SIMULATE DIAPHRAGMATIC (INFERIOR) MI

Types of Cardiac Arrhythmias in WPW Sydrome

The most clinically significant feature of the WPW syndrome is the frequent occurrence of supraventricular tachyarrhythmias. The incidence of tachyarrhythmias in WPW syndrome is 40–80%.

Reciprocating Tachycardia

Reciprocating tachycardia (the usual rate 140–250 beats/min) is found in most cases (75–80% of all tachyarrhythmias). This type of tachycardia is also called '**paroxysmal atrial tachycardia'**. The term 'reciprocating' or 're-entrant tachycardia' is, more commonly used because the tachycardia is considered to be due to a re-entry phenomenon. On the other hand, the term 'circus movement tachycardia' is used frequently by other workers. In reciprocating tachycardia, the QRS complex is, usually, normal (narrow); the broad QRS complex due to anomalous conduction is much less common.

Atrial flutter or fibrillation is rather uncommon in the WPW syndrome, the incidence rates constituting only 20–25% of all tachyatrhythmias. Of these two rhythm disorders, atrial flutter is rare. The QRS complexes during

Key points: *Supraventricular tachycardias*

- The following groups of patients may benefit from referral to a cardiac electrophysiologists
  1. All patients with regular SVT on antiarrhythmic drugs
  2. All patients with recurrent regular SVT
  3. Patients with established AF in whom control of the ventricular response is suboptimal
  4. Patients with lone paroxysmal AF in whom maintenance of sinus rhythm cannot be achieved with class Ic antiarrhythmics
- It is likely that an effective curative catheter ablation procedure for established AF will be established within the next 10 years

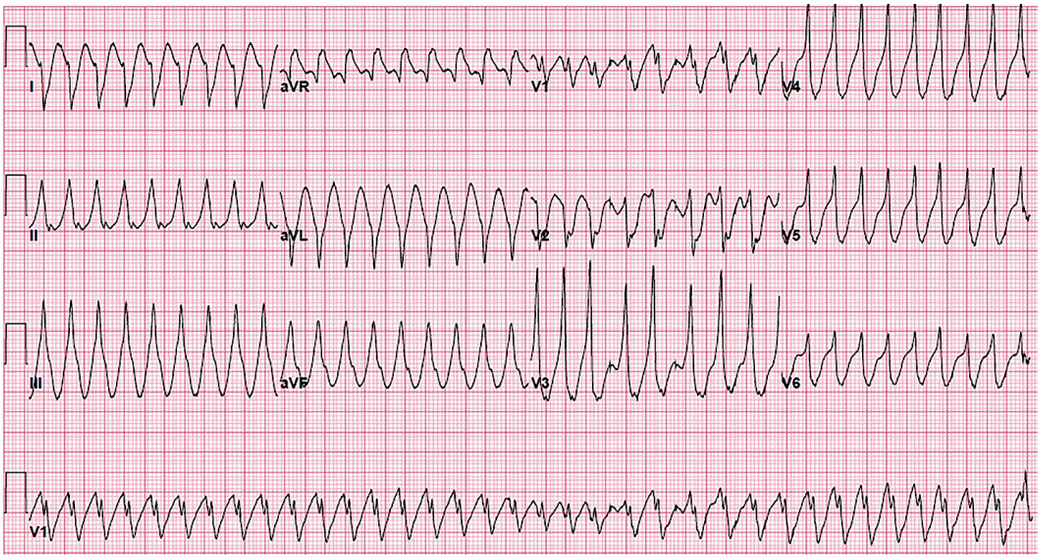

Fig. 20.57: ECG of a patient with atrial fibrillation and WPW syndrome. Note the wide-complex, irregularly irregular rhythm with 'delta waves.' This ECG can be mistaken for polymorphic ventricular tachycardia (Torsades de pointes), however the QRS axis remains stable in the setting of atrial fibrillation with WPW

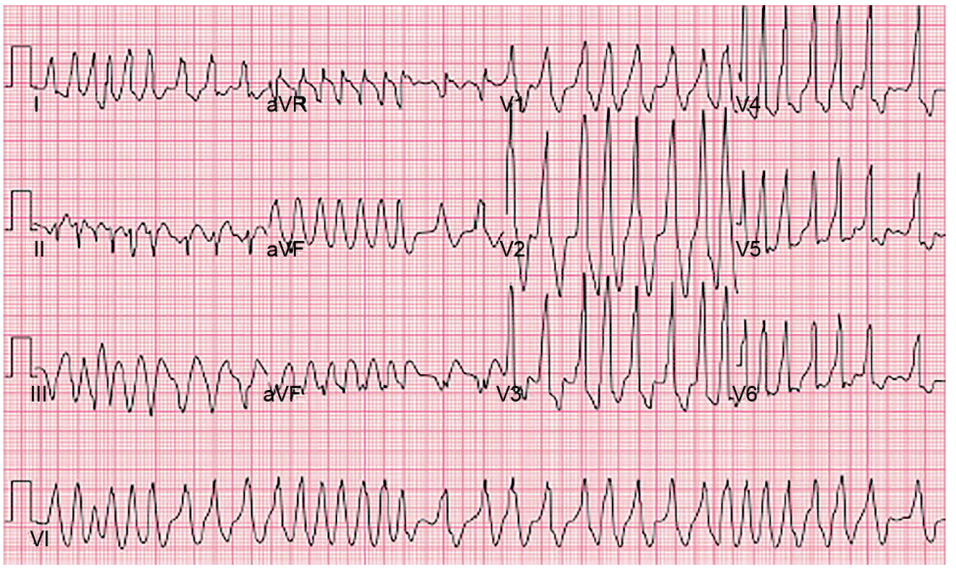

Fig. 20.58: Aberrant conduction

atrial fibrillation or flutter in the WPW syndrome are extremely bizarre and broad in most cases, because of anomalous A-V conduction due to the nature of the WPW syndrome itself plus aberrant ventricular conduction due to very rapid ventricular rate. Ventricular tachycardia (Vf) or even ventricular fibrillation (VF) is closely.

VENTRICULAR ARRHYTHMIAS (Figs 20.59–20.81)

1. Premature ventricular contractions (PVC)
2. Ventricular tachycardia
3. Ventricular fibrillation
4. Torsades de points
5. Accelerated idioventricular rhythm

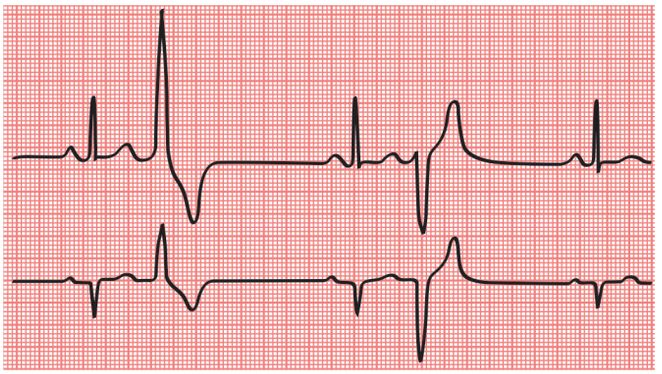

Fig. 20.59: Multifocal PVCs—more than one shape.

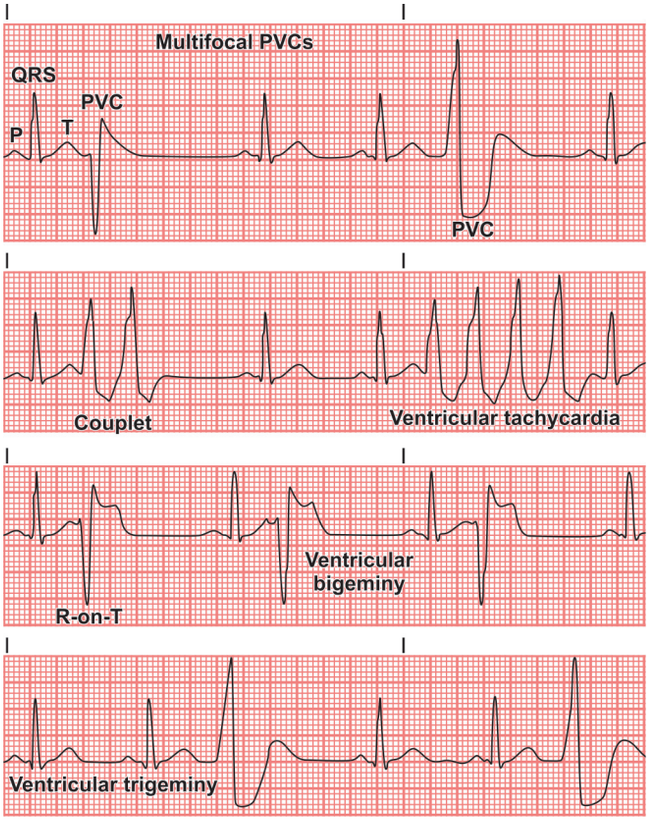

Fig. 20.60: Different types of ventricular ectopic activity

6. Ventricular parasystole
7. Ventricular fusion
8. Ventricular flutter.

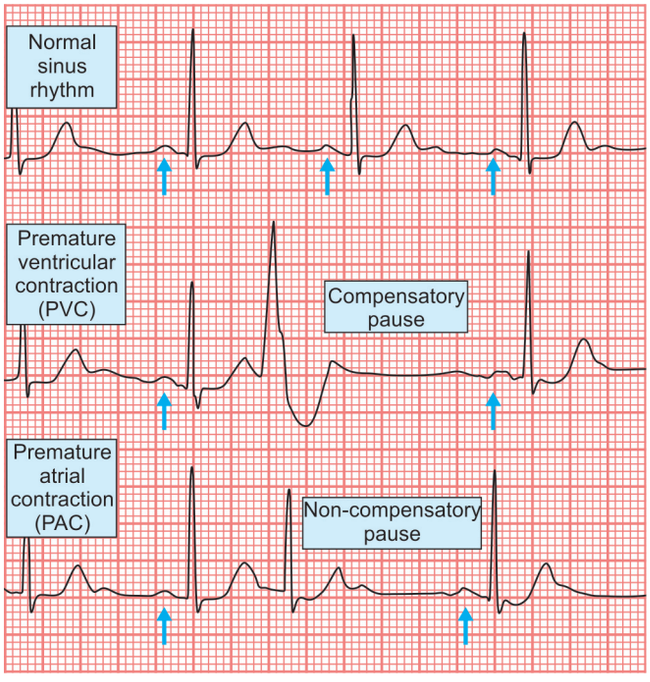

Fig. 20.62: Atrial and ventricular premature beats with compensatory and noncompensatory pauses

PREMATURE VENTRICULAR COMPLEXES

Premature ventricular complexes (PVCS) are premature ectopics, which are generated in the ventricles below the branching of the bundle of His (Table 20.6). Ventricular ectopics are produced as a result of enhanced automaticity

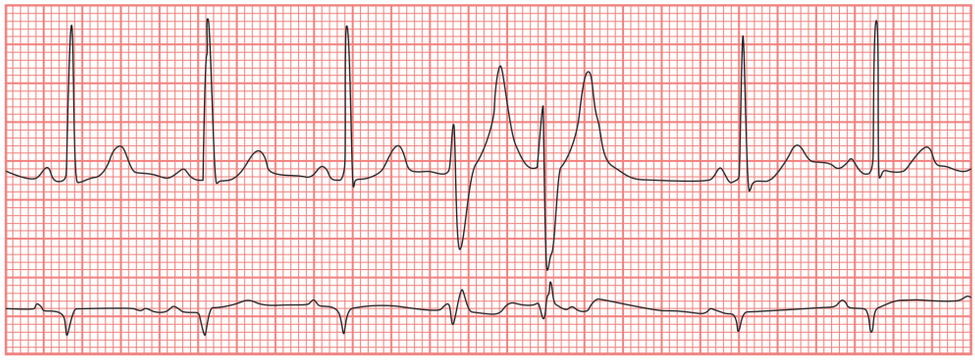

Fig. 20.61: Coupled PVCs—occurs in pairs

Table 20.6: Modified lown classification for ventricular ectopy and common synonyms used for description of ventricular arrhythmias on long-term monitoring

0	No ectopy		
1	Occasional VPBs (30/hours)	'Isolated'	
2	Frequent VPBs (>30/hours)		Low grade
3	Multiform VPBs		Moderate grade
4a	Couplets		
4b	VT or VF	'Repetitive'	High grade
5	Early VPB (R on T)		

VPB, ventricular premature beta; VT, ventricular tachycardia (≥3 consecutive beats): and VF, ventricular fibrillation

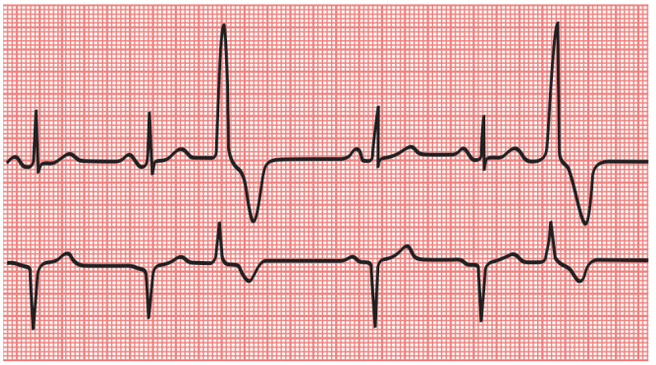

Fig. 20.63: Trigeminal PVCs—every third beat is a VPC

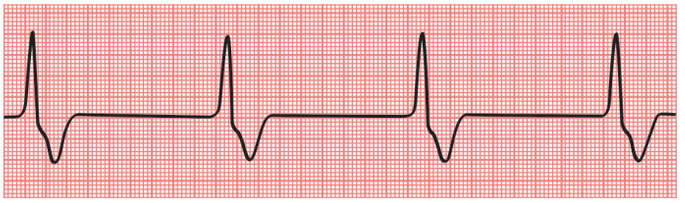

Fig. 20.64: ECG trace showing features of ventricular escape rhythm

re-entry, or altered depolarizations. These manifest as premature beats, ventricular tachycardia, ventricular fibrillation, accelerated idioventricular rhythm, or parasystole. Premature ventricular complexes (PVCs) may be right or left ventricular, unifocal, multifocal, bigeminal, interpolated, R-on-T, end- diastolic, or fusion beats; in the setting of acute myocardial infarction, they produce dangerous consequences and are treated on emergency basis.

ECG Characteristics

1. Rate	:	It is of the underlying rhythm
2. Rhythm	:	It is irregular, due to PVC
3. PR interval	:	It is of the underlying rhythm. There is no P-wave associated with the PVC.
4. QRS complex	:	It is wider due to PVC and may be normal with the basic underlying rhythm
5. Distinguishing	:	No related P-wave: premature, broad QRS complex; T-wave of opposite polarity.

Aetiological Factors

1. Digitalis
2. Drugs (epinephrine, isoproterenol, or aminophylline)
3. Hypoxia
4. Ischemia
5. Myocardial infarction
6. Significant anemia
7. Myocardial stretch

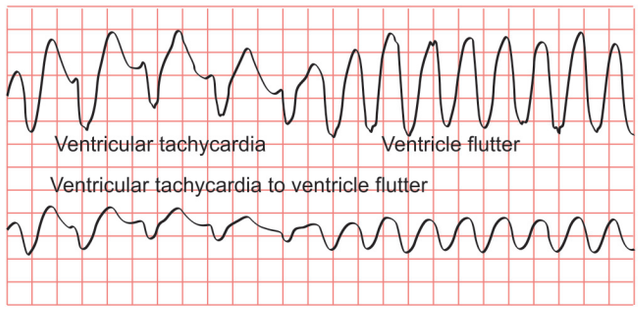

Fig. 20.66: Episodes of sustained ventricular tachycardia, ventricular flutter, and ventricular fibrillation

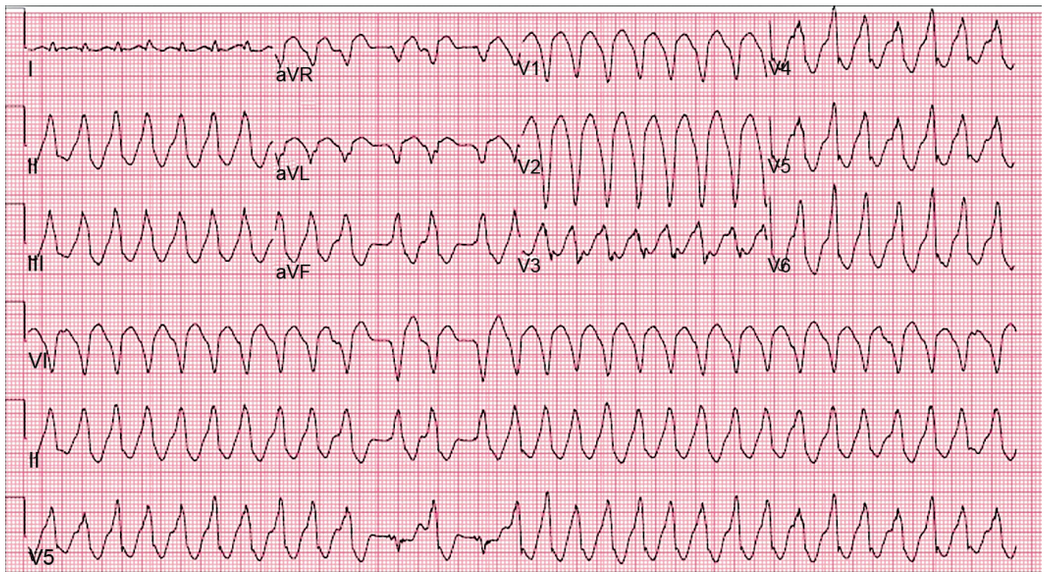

Fig. 20.65: Ventricular tachycardia

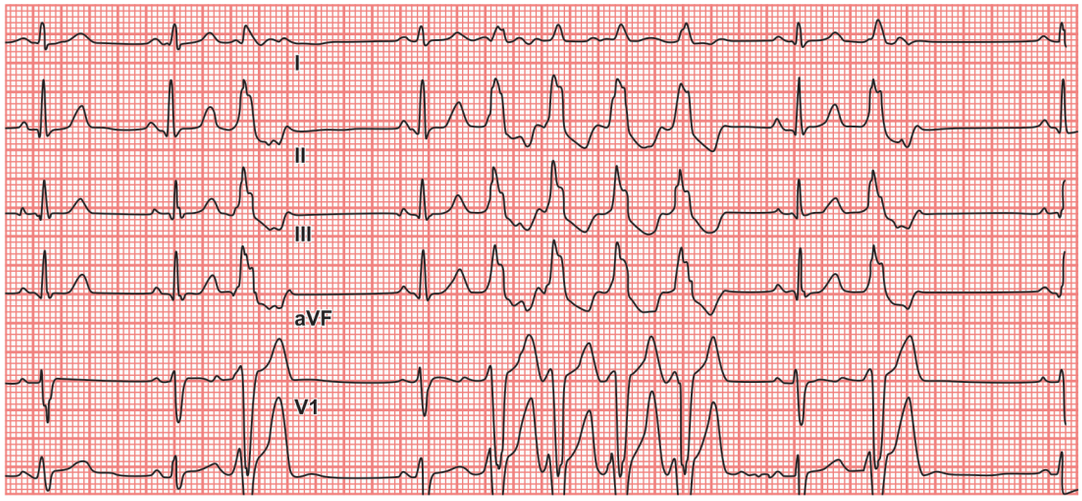

Fig. 20.67: ECG showing nonsustained ventricular tachycardia

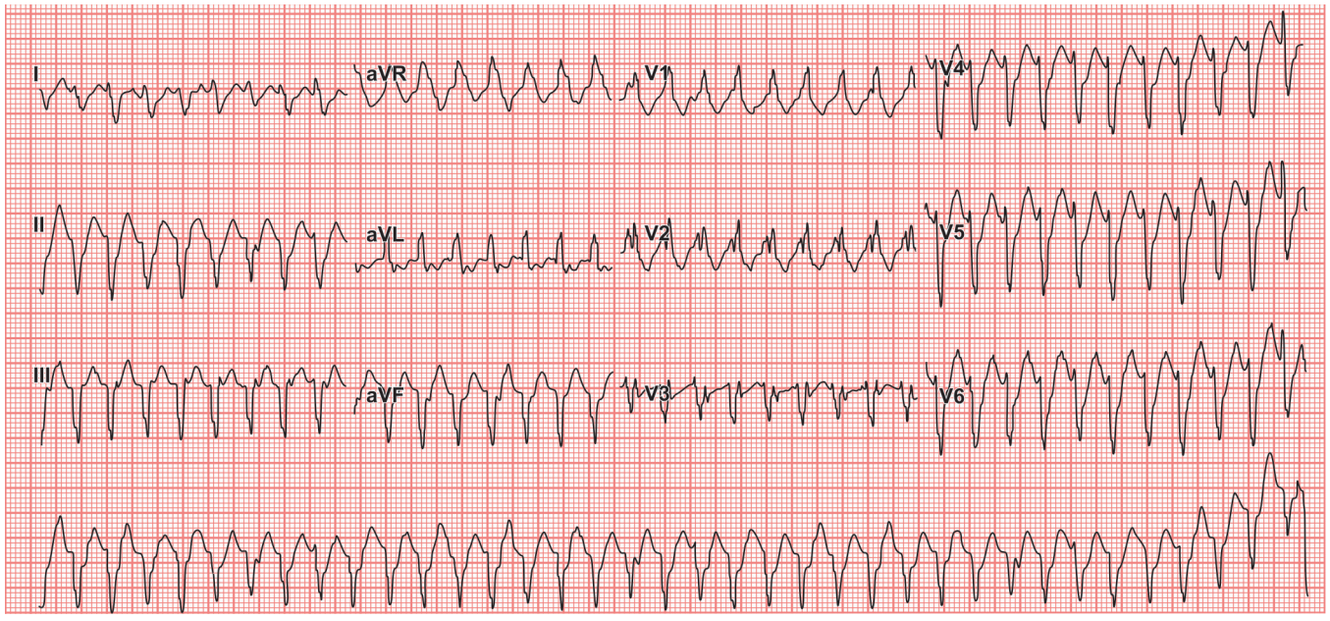

Fig. 20.68: Monomorphic VT. Although there is a broad complex tachycardia (HR >100, QRS >120), the appearance in V1 is more suggestive of SVT with aberrancy, given that the complexes are not that broad (<160 ms) and the right rabbit ear is taller than the left. However, on closer inspection there are signs of AV dissociation, with superimposed P-waves visible in V1. Also, the presence of a northwest axis and an rS complex in V6 (tiny R-wave, deep S-wave) indicate that this is VT

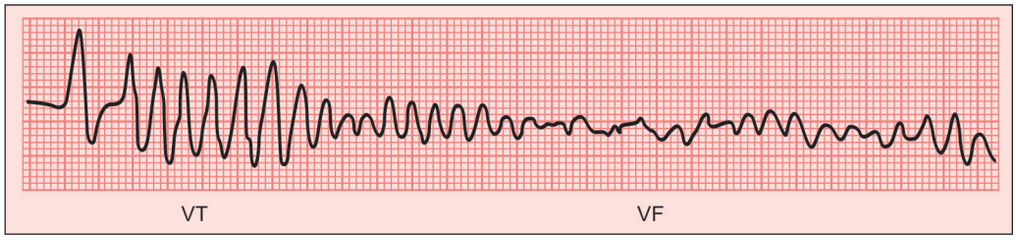

Fig. 20.69: Ventricular fibrillation

8. Catecholamines
9. Caffeine
10. Hypokalemia
11. Hypomagnesemia

Variations

1. Unifocal PVCs and ventricular bigeminy
2. Ventricular trigeminy (one normal and two PVCs)
3. Paired PVCs

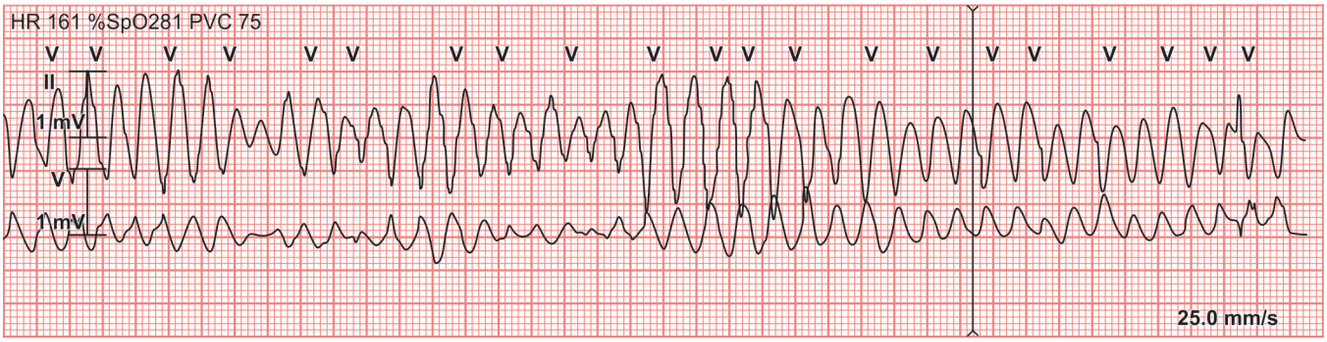

Fig. 20.70: Ventricular fibrillation occurs when multiple ventricular foci discharge rapidly and chaotically. The ventricles twitch asynchronously and are not effective as pumps. No organized QRS complexes are seen—just disorganized oscillatory waves which can be coarse (as shown) or fine in appearance



Fig. 20.71: ECG trace showing R on T phenomenon (arrow) giving rise to ventricular fibrillation (arrow)

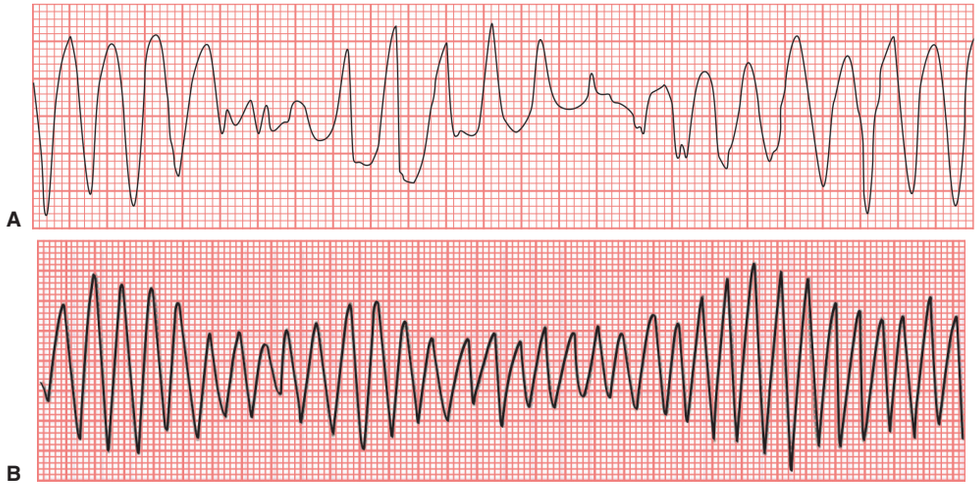

Fig. 20.72A and B: ECG traces showing polymorphic ventricular tachycardia. In polymorphic ventricular tachycardia, there is beat-to-beat variation in the QRS morphology. A common example is Torsades de pointes (twisting of the points)

4. R-on-T PVCs
5. End-diastolic PVC
6. Interpolated PVC
7. PVC with retrograde conduction to the atria
8. Right-ventricular PVC
9. Left-ventricular PVC

Differential Diagnosis

Premature atrial contraction with aberrant ventricular unless a P-wave comes in front of the broad beat or there is morphological proof of ventricular aberrancy. One should always make the diagnosis of ventricular ectopy unless proved otherwise.

Treatment

In the diseased, ischemic, or infracted heart, antiarrhythmics (lidocaine or procainamide) are given.

Ventricular Escape

In ventricular escape beat or rhythm, the depolarization wave spreads slowly via abnormal pathway in the ventricular myocardium and not via the His bundle and bundle

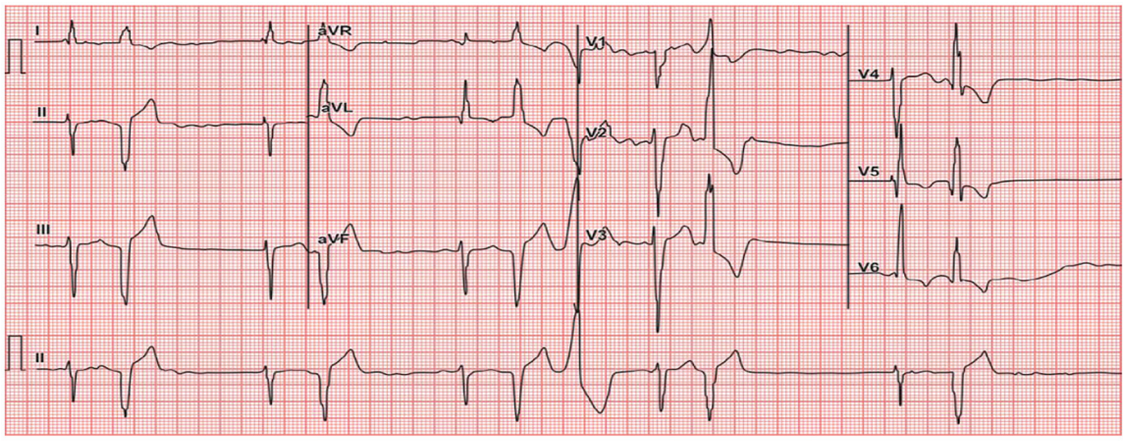

Fig. 20.73: Bidirectional ventricular tachycardia due to severe digoxin toxicity

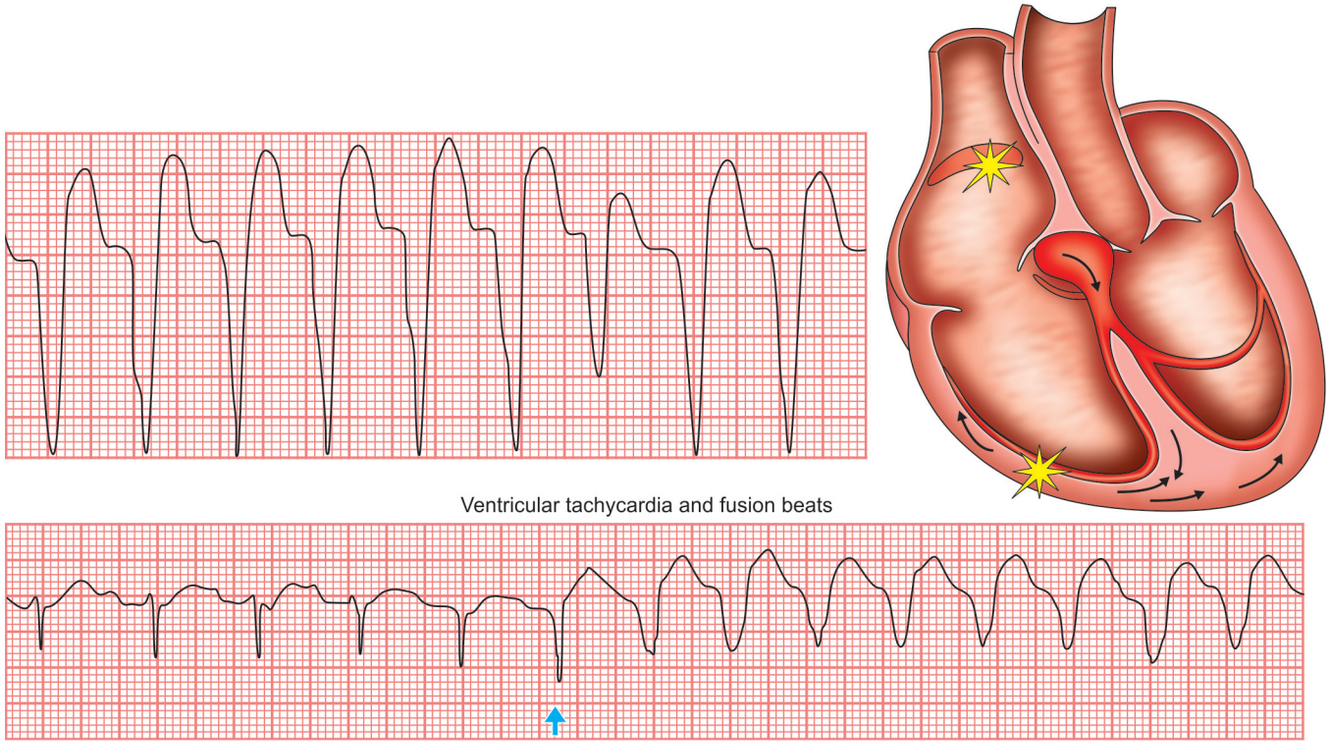

Fig. 20.74A: Electrocardiographic signs of AV dissociation. A fusion beat occurs when a sinus beat conducts to the ventricles via the AV node concurrent with a beat arising from the ventricles. The resulting QRS complex has an intermediate appearance between a normal beat and a VT beat. A capture beat occurs when the ventricle is depolarized via the AV node resulting in a narrow (normal-appearing) QRS (The presence of capture and/or fusion beats indicates AV dissociation and if present points to a diagnosis of VT. Their absence, however, does not exclude VT.)

branches. Therefore, the QRS complex is wide (>120 ms) and has a shape different from that of the sinus beat. If the ventricular escape rhythm is the result of sinus node failure, no P-wave of atrial contraction is seen as in the tracing above. If the ventricular escape rhythm is the result of 3rd degree (complete) heart block, the sinus node paces the atria independently and regular P-waves unrelated to the ventricular escape beats can be seen. The inherent rate of ventricular escape rhythm is between 20 and 40 beats/min.

VENTRICULAR TACHYCARDIA

When ventricular ectopics takes the shape of a rhythm, with a rate of 100–170 beats/min, it is called as ventricular tachycardia.

ECG Characteristics

1. Rate : 100–170 beats/min
2. Rhythm : Regular 75% of the time
3. PR interval : Not applicable

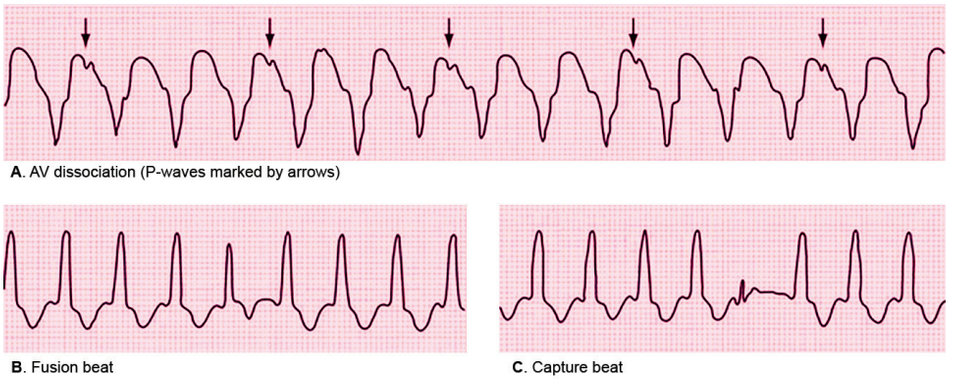

Fig. 20.74B: Fusion beats—the first of the narrower complexes is a fusion beat (the next two are capture beats)

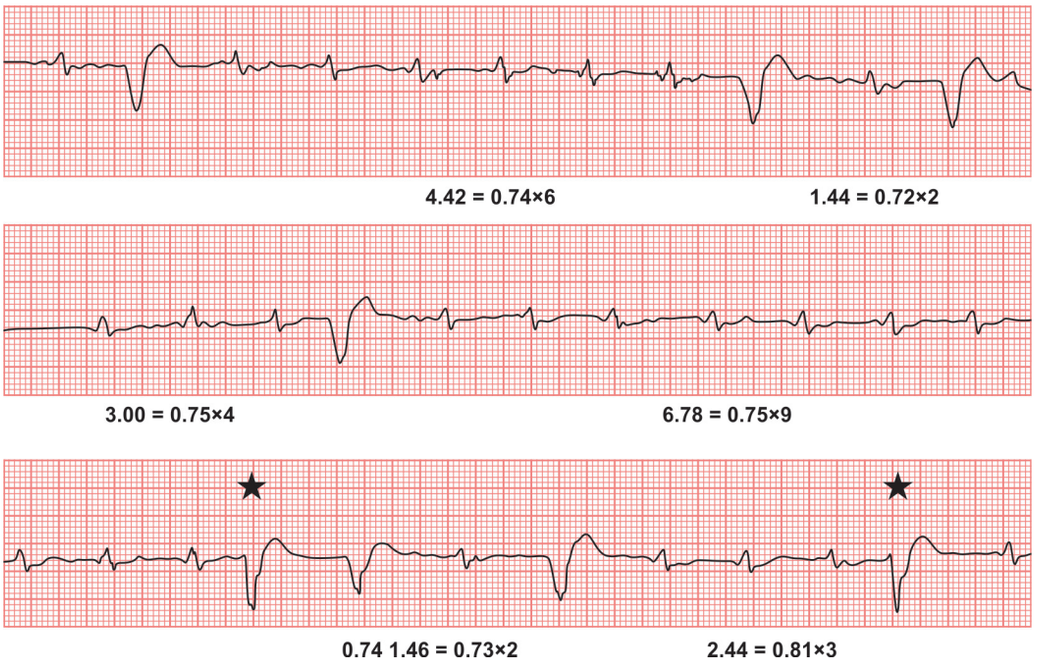

Fig. 20.75: In ventricular parasystole, non-fixed coupled PVCs occur at a common interectopic interval. Fusion beats, indicated by arrows, are often seen. Fusions occur when the sinus impulse entering the ventricles find the ventricles already partially depolarized by the parasystolic focus

4. QRS complex : 0.12 sec and most often 0.14 sec
5. Distinguishing features : Broad QRS complex with a regular rhythm and a rate between 100 beats/min and 170 beats/min left axis deviation, and, in VI, a monophasic R, QR, qR, RS, or a 'rabbit ear' configuration (that is, two peaks, the first being the tallest). In slower rates, AV dissociation may be seen; however, in 40% cases, there is retrograde conduction to the atria.

Aetiological Factors

1. Drugs (digitalis, isoproterenol)
2. Coronary artery disease
3. Acute myocardial infarction
4. Significant underlying cardiac disease
5. May occur in the absence of structural heart disease.

Variations

1. Ventricular tachycardia with retrograde conduction to the atria
2. Bidirectional ventricular tachycardia
3. Torsades de pointes
4. Ventricular flutter.

Treatment

If there is hemodynamic deterioration, cardioversion is indicated; otherwise, lidocaine or procainamide may be given. Cardioversion attempts with 10 watt-seconds should be started and increments increased until results are obtained.

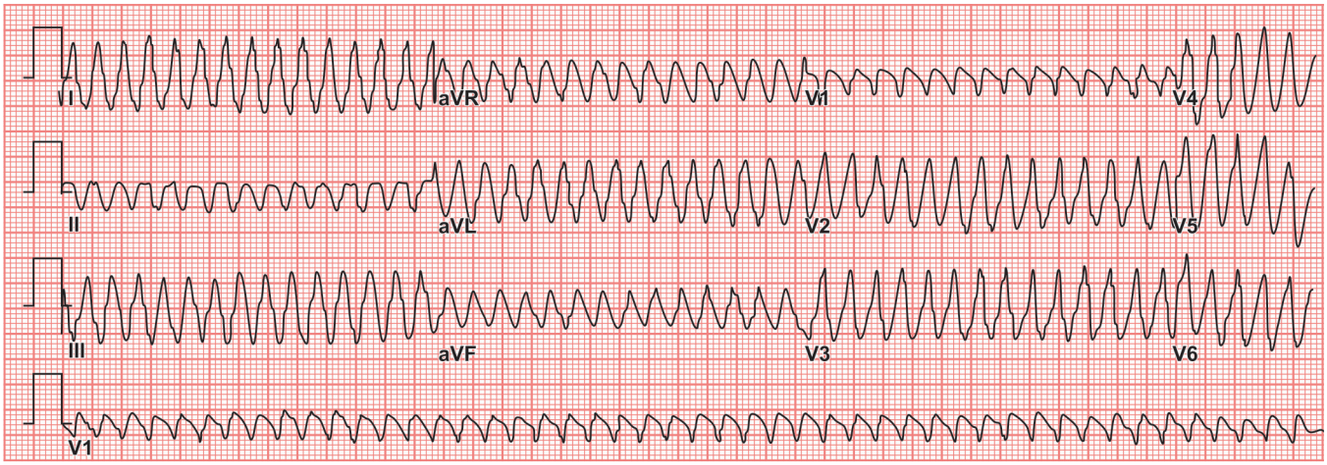

Fig. 20.76: Ventricular flutter

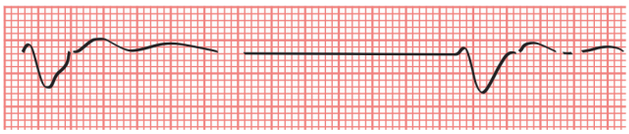

Fig. 20.77: ECG showing broad and slow rhythm in association with release electrical activity

VENTRICULAR FIBRILLATION

It may be defined as disorganized electrical activity in the ventricles, resulting into inadequate contraction of the ventricle, incapable of maintaining sufficient cardiac output.

Differential Diagnosis: Ventricular fibrillation should always be distinguished from that of an erratic fibrillatory line within QRS complex.

Aetiological Factors

1. Myocardial infarction
2. Myocardial ischemia
3. R-on-T, frequent, paired, or multifocal PVCs in the setting of acute myocardial infarction

Variations

1. Coarse ventricular fibrillation
2. Fine ventricular fibrillation.

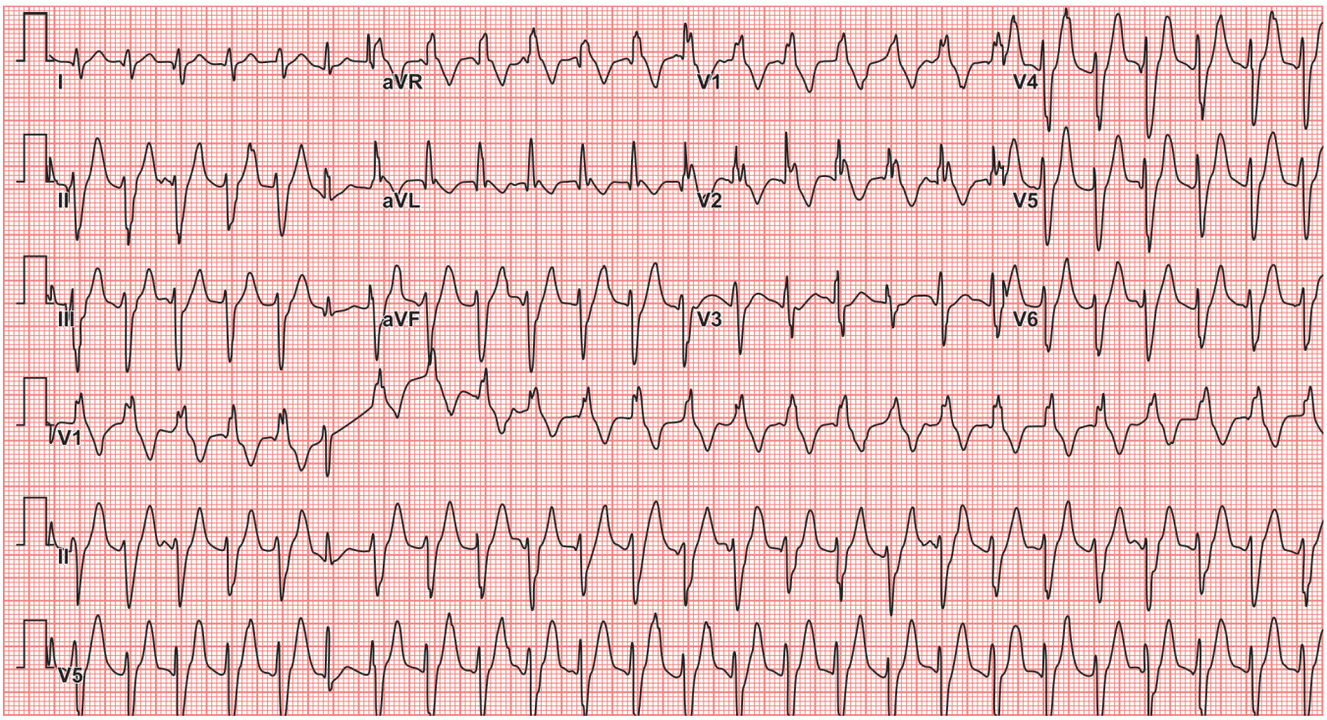

Fig. 20.78: Ventricular tachycardia. Broad QRS complexes with RBBB no visible P-waves

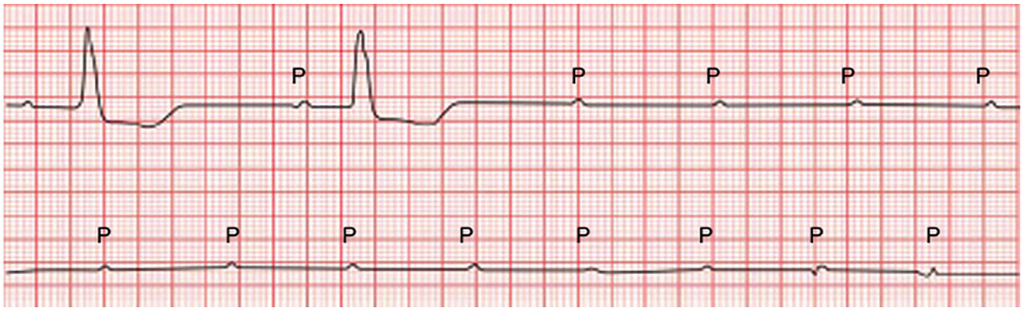

Fig. 20.79: ECG records a straight-line pattern indicating asystole



Fig. 20.80: Graph showing ventricular tachycardia with direct evidence of independent atrial activity. P-waves are separated by intervals of 0.75 s, and can clearly be seen after the first, third, sixth, eighth, tenth, thirteenth, fifteenth and seventeenth ventricular complexes

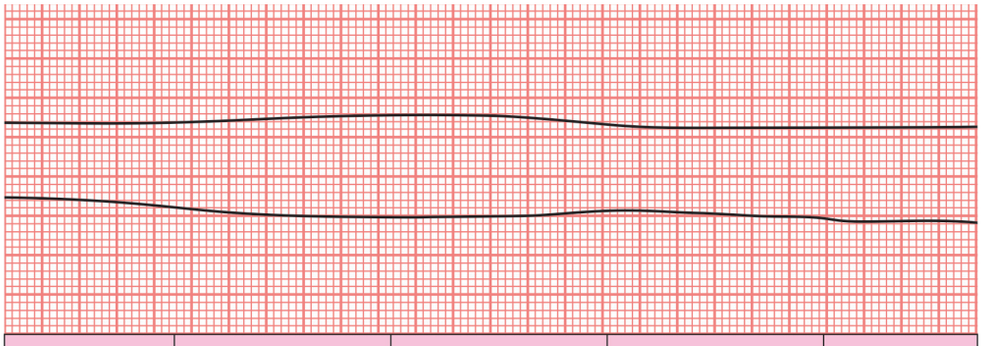

Heart rate	Rhythm	P-wave	PR interval (in seconds)	QRS (in seconds)
Absent	Absent	Absent or present	N/A	Absent

Fig. 20.81: Ventricular asystole (standstill)

Treatment of Ventricular Fibrillation (VF)

1. Cough, CPR, if patient awake and able to cough
2. Defibrillate with 200 joules; repeat once, if necessary
3. If successful, administer lidocaine, a bolus and an infusion per protocol.
4. If VF persists initiate chest compression and positive pressure ventilation. Start IV line.
5. Epinephrine 1:10,000, 5 to 10 ml (0.5 to 1 mg) IV or intratracheal.
6. After 30–60 sec of ventilation and chest compression, defibrillate with 300–400 joules; may repeat once.
7. Bretylium 5 mg-kg IV bolus.
8. Sodium bicarbonate 1 mEq.kg IV push, especially if metabolic acidosis is documented by arterial blood gases.
9. If VF persists, attempt improvement of ventilation and oxygenation, continuous CPR, obtain arterial blood gases. Further sodium bicarbonate administration guided by arterial blood gas results, if available, if not, repeat one-half dose in 10 min.
10. Repeat epinephrine 0.5–1 mg IV stat.
11. Repeat defibrillation 300–400 joules.

12. Consider other drugs—magnesium, nitroglycerine, or additional bretylium.
13. Consider methods of 'new CPR'.

TORSADES DE POINTES

Torsades de points (twists of points) is a polymorphous ventricular tachycardia, associated with a prolonged Q-T interval.

ECG Characteristics

1. Rate : 150–250 beats/min
2. Rhythm : May be regular or irregular
3. PR interval : Not applicable
4. QRS complex : 0.12sec; usually, 0.14 sec
5. Distinguishing features : In sinus rhythm, the QT interval is too long (0.46–0.50 sec or 33% of baseline). This measurement is absolute as opposed to the corrected. A ventricular tachycardia, with phasic variation in the electrical polarity of the QRS complex. The tachycardia may be paroxysmal, repetitive, the patient remaining fully conscious.

Aetiological Factors: Any of the factors, which leads to the lengthening of the Q-T interval, as mentioned below, can lead to this disorder:

1. Antiarrhythmic drugs such as quinidine, procainamide, disopyramide, or amiodarone
2. Hypokalemia
3. Hypomagnesemia
4. Psychotropic drugs
5. Unilateral alteration of sympathetic tone
6. Profound bradycardia
7. Intracerebral pathology

Differential Diagnosis

Coarse ventricular fibrillation, without preceding QT lengthening; ventricular flutter.

Treatment

It consists of removing any predisposing cause and suppressing the rapid ventricular rhythm. The antiarrhythmic drugs such as quinidine, procainamide, disopyramide, and most others that may prolong the QT interval should be avoided. Magnesium may be effective, especially when the rhythm is related to an anti-arrhythmic drug. For acute management, isoproterenol infusion may be useful, particularly if there is underlying bradycardia. Atrial or ventricular overdrive pacing is also frequently very effective in acutely suppressing the rhythm. It should, usually, be continued for 24 hours. Prolonged episodes may require electrical defibrillation. If the rhythm recurs after all possible predisposing causes have been excluded, the patient should be treated with a beta-adrenergic blocking agent, which, usually, is successful. Occasionally refractory patient need operation in which a left stellate ganglion sympathectomy or implantation of an automatic, defibrillation device is considered.

Temporary overdrive ventricular or atrial pacing IV magnesium sulfate (IV push 2 g over 1–2 min IV infusion 1–2 g/h for 4–6 h)

ACCELERATED IDIOVENTRICULAR RHYTHM

The accelerated idioventricular rhythm (AIVR) is an ectopic ventricular rhythm with a rate of 40–100 beats/min.

ECG Characteristics

1. Rate : 40–100 beats/min
2. Rhythm : Regular
3. PR interval : Not applicable, but that of the underlying rhythm may be normal.
4. QRS complex : 0.12 sec; usually, 0.14 sec
5. Distinguishing features : A ventricular ectopic rhythm that, often, begins and ends with fusion beats and misifests itself when its rate is approximately that of the sinus node.

Cause

Acute myocardial infarction

Variations

Accelerated idioventricular rhythm with atrial flutter.

VENTRICULAR FUSION COMPLEXES

It may be defined as the type of resultant complex, when two impulses collide with each other in the ventricles, like the one, seen in atrial fusion beats in atria.

ECG Characteristics

1. Rate : That of the underlying rhythm
2. Rhythm : Regular
3. PR interval : PR interval of the fusion beat may be the same as or shorter than that of the sinus rhythm, but is never more than 0.06 sec shorter than the dominant PR interval.
4. QRS complex : Normal in the underlying rhythm, but may be variable in the fusion beats.
5. Distinguishing features : It should be differentiated from other ventricular ectopic beats by critically analyzing the basic rhythm. QRS of the fusion beat has a contour intermediate between that of the fusing impulses.

Causes

That of the ventricular ectopic beat or rhythm.

Variations

1. Ventricular parasystole
2. Accelerated idioventricular rhythm

3. Electronic pacemaker fusion beat
4. End-diastolic PVCs
5. Bigeminal end-diastolic PVCs

Differential Diagnosis

Electrical alternans vs bigeminal end-diastolic PVCs.

VENTRICULAR PARASYSTOLE

These are, usually, unifocal premature ventricular contractions which have varying coupling intervals at regular cadence. Such a constantly recurring ectopic beat is termed as parasystole. Parasystole is diagnosed by observing on active focus of automaticity, usually, in the region of ventricle, which operates independently of the dominant pacemaker. The rhythmic discharges are, somewhat, not affected by the propagation of the primary impulse. In this condition, both the dominant and the parasystolic rhythms have separate and independent cadences.

In classical ventricular parasystole, the rate of impulses from the ectopic focus is considerably slower than that of the sinus node, because the sinus node and the ventricular ectopic focus are firing independently of one another and at different rates. Premature ventricular contractions produced by this mechanism, usually, will show marked variation in coupling (R-V) intervals. Electrocardiographic analysis will reveal that the intervals, between successive premature ventricular contractions, are all multiples of a manifest or calculated minimum V-V interval. Clinically, it seems to be benign condition. The parasystolic arrhythmia is, frequently, resistant to anti-arrhythmic drug therapy.

ECG Characteristics

1. Rate : That of the underlying rhythm
2. Rhythm : Irregular, as a result of extrasytoles
3. PR interval : Normal is the underlying rhythm
4. QRS complex : Normal in the underlying rhythm; broad in the parasystolic beats
5. Distinguishing features :
   a. No fixed coupling
   b. Interectopic intervals that have a common denominator
   c. Fusion beats

Variations

Fixed coupling in parasystole if the rates of the two pacemaker happen to be mathematically related. No fixed coupling, but interectopic intervals are not exact multiples, because the ectopic focus is influenced, but not reset, by the sinus impulses.

Differential Diagnosis

Accelerated idioventricular rhythm.

VENTRICULAR FLUTTER AND FIBRILLATION

The electrocardiographic diagraphic of ventricular flutter is made, the ventricular tachyarrhythmias is greater than 200 beats/min, and large sinusoidal or zigzag waves are observed. The rate is frequently, between 240–280 beats/min. In ventricular flutter, QRS complex cannot be clearly distinguished from ST-T-waves. The diagnosis of ventricular flutter may be applied when the rate is less than 200 beats/min if the ECG morphology is absolutely typical.

Ventricular fibrillation is recognized on ECG tracing by the absence of QRS complex and T-waves and the presence of low-amplitude base-line undulations which are quite variable, both in amplitude and periodicity. Clinically, ventricular flutter is, rarely, recorded, perhaps, due to its highly unstable rhythm that tends to convert to sinus-rhythm or, more often, to ventricular fibrillation. Ventricular flutter, nearly always, leads to severe and symptomatic hemodynamic impairment.

Ventricular fibrillation on the other hand is the most catastrophic cardiac arrhythmia. It is usually, observed in myocardial infarction, hypokalamia marked hypothermia, electrocution and drug toxicity, i.e. with digitalis, quinidine, procainamide or tricyclic antidepressants. Ventricular fibrillation can lead to death, within a short period, due to cardiogenic collapse if such a rhythm is not converted to hemodynamically effective rhythm.

ECG Characteristics

1. Rate : 150–300 beats/min
2. Rhythm : Regular or irregular
3. PR interval : Not applicable
4. QRS complex : Broad and poorly defined
5. Distinguishing features : A zig-zag, almost a sine wave configuration, instead of clearly defined QRS complex.

Aetiological Factors

1. Myocardial infarction
2. Myocardial ischemia
3. R-on-T frequent, paired, or multifocal PVCs in the setting of acute myocardial infarction.
4. An interim arrhythmia between ventricular tachycardia and fibrillation.
5. Drugs (digitalis, procainamide, quinidine and tricyclic antidepressants).
6. Electrolyte imbalance, i.e. hypokalaemia.

Differential Diagnosis

Torsades de pointes.

PULSELESS ELECTRICAL ACTIVITY

Pulseless electrical activity is defined as the absence of a pulse or blood pressure measured by usual methods with the continued presence of electrical activity of the heart (Table 20.7).

A. Aetiology

1. Pulseless electrical activity may result from a variety of rhythm disturbances, such as electrical mechanical

Table 20.7: Conditions that cause pulseless electrical activity

Condition	Clues	Management
Hypovolemia	History, flat neck veins	Volume infusion
Hypoxia	Cyanosis, blood gases, airway problems	Ventilation
Cardiac temponade	History (trauma, renal failure, and thoracic malignancy), no pulse with CPR, vein distention; impending tamponade—tachycardia, hypotension, low pulse pressure—changing to sudden bradycardia as terminal event	Pericardiocentesis
Tension pneumothorax	History (asthma, ventilator, chronic obstructive pulmonary disease, and trauma), no pulse with CPR, neck vein distention, and tracheal deviation	Needle decompression
Hypothermia	History of exposure to cold, central body temperature	Warming
Massive pulmonary embolism	History, no pulse felt with CPR	Pulmonary arteriogram surgical embolectomy, thrombolytics
Drug overdose (tricyclics, digoxin, β-blockers, calcium channel blockers)	Bradycardia, history of ingestion, empty bottles at the scene, pupils, and neurologic exam	Drug screens, intubation, lavage, activated charcoal, lactulose per local protocols
Hyperkalemia	History of renal failure, diabetes, recent dialysis, dialysis fistulas, medications	Calcium chloride (immediate); then combination of insulin, glucose, sodium polystyrene sulfonate/sorbitol; dialysis (long term)
Pre-existing acidosis	History of bicarbonate-responsive pre-existing acidosis, renal failure	Sodium bicarbonate, hyperventillation
Acute massive MI	History, ECG, and enzymes	Treat for cardiogenic shock

CPR=cardiopulmonary resuscitation; ECG=electrocardiography; MI=myocardial infarction from Brainard CA, 1997.

dissociation, idioventricular rhythms, and ventricular tachycardias. When the electrical activity is organized and within the physiologic range, the term electrical mechanical dissociation is used.

2. A variety of clinical situations are also associated with pulseless electrical activity, a potentially manageable condition if certain actions are undertaken rapidly.

B. Therapy

1. Specific management of the underlying cause is most likely to result in a successful outcome
2. Emergency intervention should be initiated at once, including:
   a. Cardiopulmonary resuscitation and airway management with intubation to treat any possible hypoxia
   b. Epinephrine, 1 mg intravenous push every 3–5 minutes
   c. Atropine, 1 mg intravenously, if the rate is more than 60 beats/min; may be repeated every 3–5 minutes to a total dose of 0.03–0.04 mg/kg
   d. Empiric intravenous volume infusion

Asystole

1. **Clinical presentation:** Asystole is defined as the absence of myocardial electrical activity. It should be confirmed by switching between several leads or changing the position of the defibrillation paddles.
   a. Most patients with asystole present in a code situation. Persons outside of the hospital who are found to have asystole by the initial responding team usually have it as a result of profound myocardial ischemia. The possibility of a successful outcome in this situation is extremely small.
   b. Hospital in patients monitored by telemetry, on the other hand, may have a favorable outcome.
2. **Aetiology:** Asystole may be due to profound parasympathetic suppression of both atrial and ventricular activity, stunning of the myocardium due to electrical defibrillation, complete heart block, or prolonged myocardial ischemia.
3. **Therapy:** Management consists of cardiopulmonary resuscitation, intubation, and atropine to unmask the possibility of profound parasympathetic suppression of both atrial and ventricular activity.
   a. Routine shocking is strongly discouraged. Electrical shocks have not been demonstrated to have any benefit in the management of asystole and may in fact produce a stunned myocardium, leading to a delay in the return of a rhythm.
   b. Pacing for asystole is controversial. If pacing is to have any effect, it must be initiated early. Patients with asystole due to myocardial ischemia are unlikely to respond to pacing, but those with asystole due to other causes might respond.

Cardiac Conduction Abnormalities

Heart block can occur anywhere in the specialized conduction system beginning with the sinoatrial connections, the AV junction, the bundle branches and their fascicles, and ending in the distal ventricular Purkinje fibers. Disorders of conduction may manifest as slowed conduction **(1st degree)**, intermittent conduction failure **(2nd degree)**, or complete conduction failure **(3rd degree)**. In addition, 2nd degree heart block occurs in two varieties: Type I **(Wenckebach)** and Type II **(Mobitz)**. In Type I block there is **decremental conduction** which means that conduction velocity progressively slows down until failure of conduction occurs. Type II block is all or none. The term *exit block* is used to identify conduction delay or failure immediately distal to a pacemaker site. Sino-atrial (SA) block is an exit block. This section considers conduction disorders in the anatomical sequence that defines the cardiac conduction system (Figs 20.82–20.91).

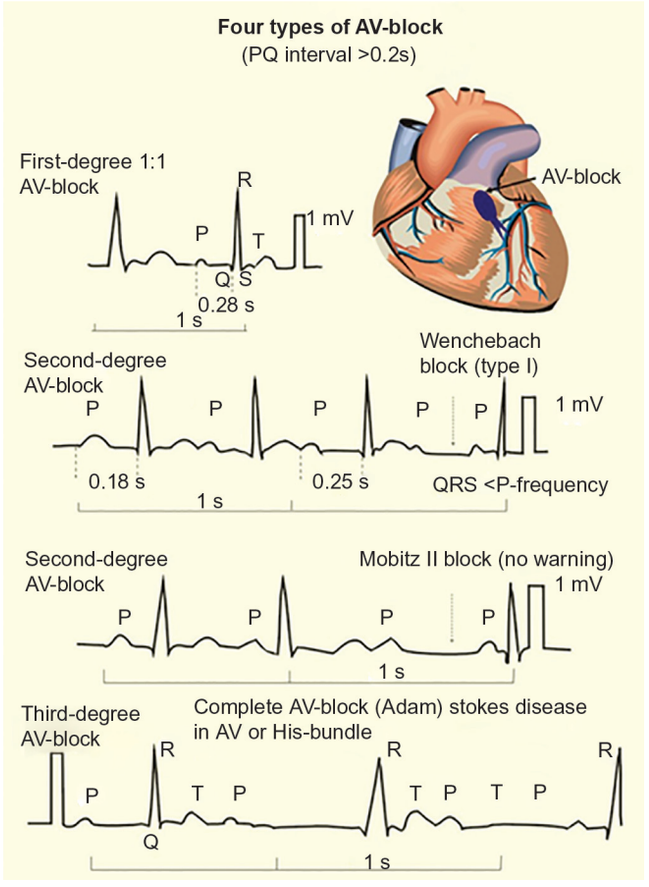

Fig. 20.82: ECG morphology explaining four common types of AV blocks



Fig. 20.83: First degree AV block (PR=280 ms)

INTRAVENTRICULAR BLOCKS

Right Bundle Branch Block

- 'Complete' right bundle branch block (RBBB) has a QRS duration ≥0.12s
- Close examination of QRS complex in various leads reveals that the terminal forces (i.e. second half of QRS) are oriented *rightward* and *anteriorly* because the right ventricle is depolarized *after* the left ventricle. This means the following:
  - Terminal R' wave in lead V1 (usually see rSR' complex) indicating late *anterior* forces
  - Terminal S waves in leads I, aVL, V6 indicating late *rightward* forces
  - Terminal R wave in lead aVR indicating late *rightward* forces
  - The frontal plane QRS axis in RBBB should be in the normal range (i.e. -30 to +90 degrees). If left axis deviation is present, think about *left anterior fascicular block*, and if right axis deviation is present, think about *left posterior fascicular block* in addition to the RBBB.
- 'Incomplete' RBBB has a QRS duration of 0.10–0.12s with the same terminal QRS features. This is often a normal variant.
- The 'normal' ST-T-waves in RBBB should be oriented opposite to the direction of the terminal QRS forces, i.e. in leads with terminal R or R' forces the ST-T should be negative or downward; in leads with terminal S forces the ST-T should be positive or upward. If the ST-T-waves are in the *same direction* as the terminal QRS forces, they should be labeled primary *ST-T-wave abnormalities.*

Left Bundle Branch Block

- 'Complete' left bundle branch block (LBBB) has a QRS duration ≥0.12s

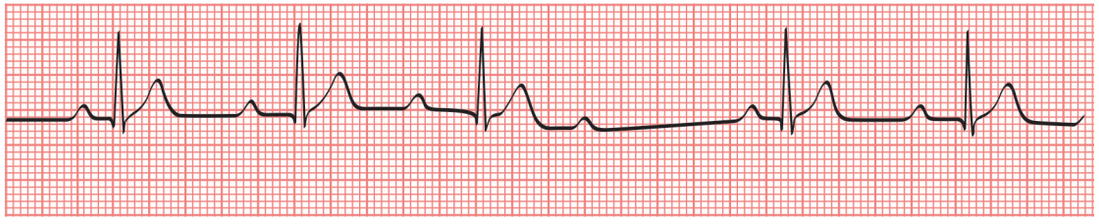

Fig. 20.84: Classic Wenckebach phenomenon in which there is progressive lengthening of PR interval till there is dropping of cardiac cycle

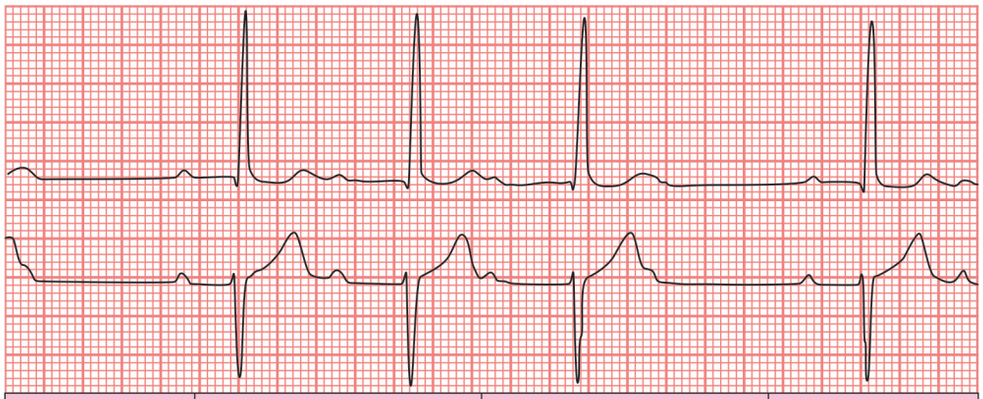

P-wave	PR interval (in seconds)	QRS (in seconds)	Characteristics
Conduction intermittant	Increasingly prolonged	Before each QRS, identical	QRS dropped in a repreating pattern

Fig. 20.85: Second degree AV block-Mobitz (Wenckebach)

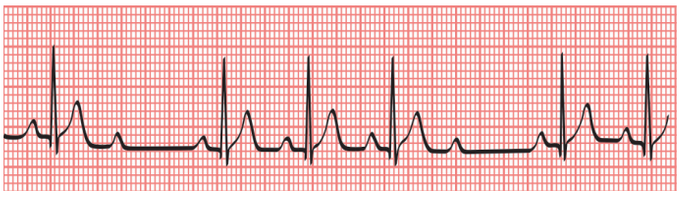

Fig. 20.86: AV block (Mobiz type II)

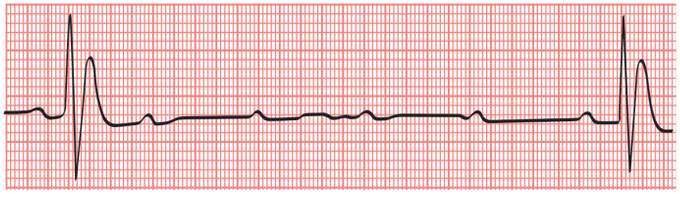

Fig. 20.87: High grade AV block (Mobiz type III)

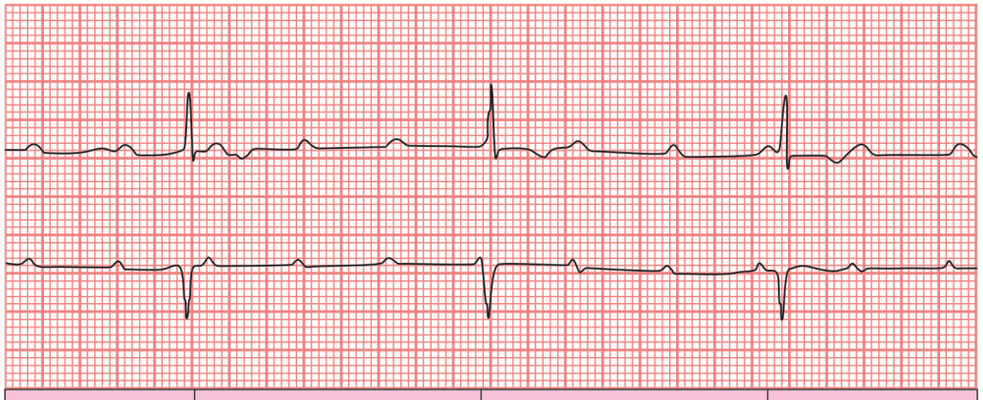

P-wave	PR interval (in seconds)	QRS (in seconds)	Characteristics
Normal but not related to QRS	None	N/A	No relationship between P and RS

Fig. 20.88: Third degree (complete) AV block

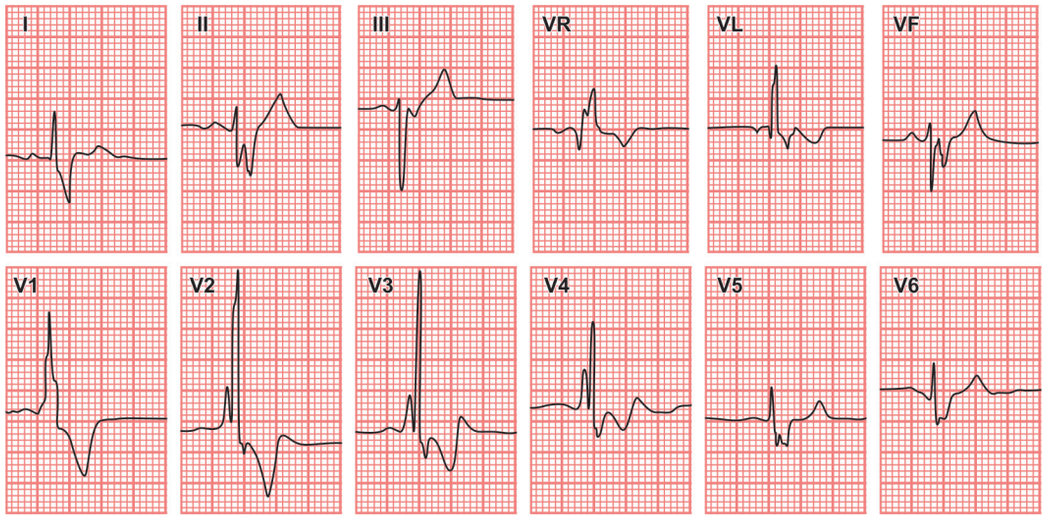

Fig. 20.89: Left axis deviation and RBBB in bifascicular block

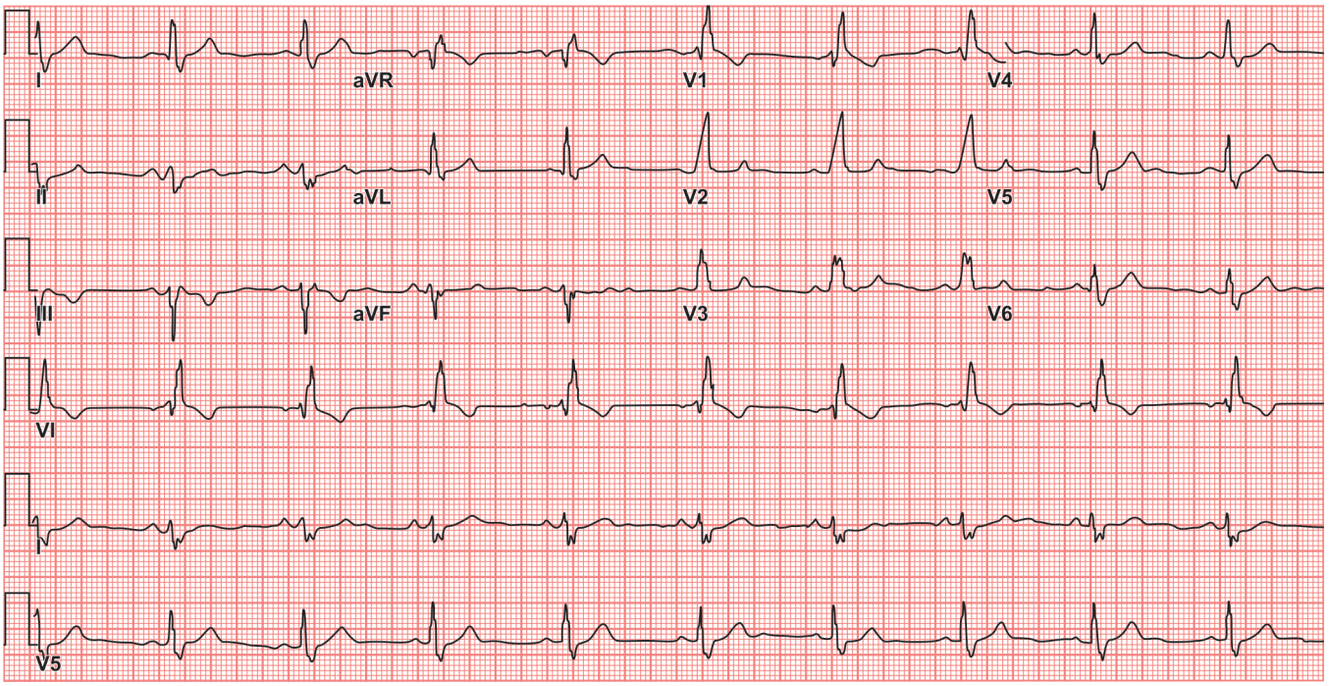

Fig. 20.90: Bifascicular blocks RBBB + LAFB, i.e. RBBB + LAD

- Close examination of QRS complex in various leads reveals that the terminal forces (i.e. second half of QRS) are oriented *leftward* and *posteriorly* because the left ventricle is depolarized *after* the right ventricle.
- Terminal S waves in lead V1 indicating late *posterior* forces
- Terminal R waves in lead I, aVL, V6 indicating late *leftward* forces; usually broad, monophasic R-waves are seen in these leads as illustrated in the ECG below; in addition, poor R progression from V1 to V3 is common.
- The 'normal' ST-T-waves in LBBB should be oriented opposite to the direction of the terminal QRS forces, i.e. in leads with terminal R or R' forces the ST-T should be downward; in leads with terminal S forces the ST-T should be upward. If the ST-T-waves are in the *same direction* as the terminal QRS forces, they should be labeled *primary ST-T-wave abnormalities*. In the above ECG the ST-T-waves are 'normal' for LBBB, i.e. they are *secondary* to the change in the ventricular depolarization sequence.

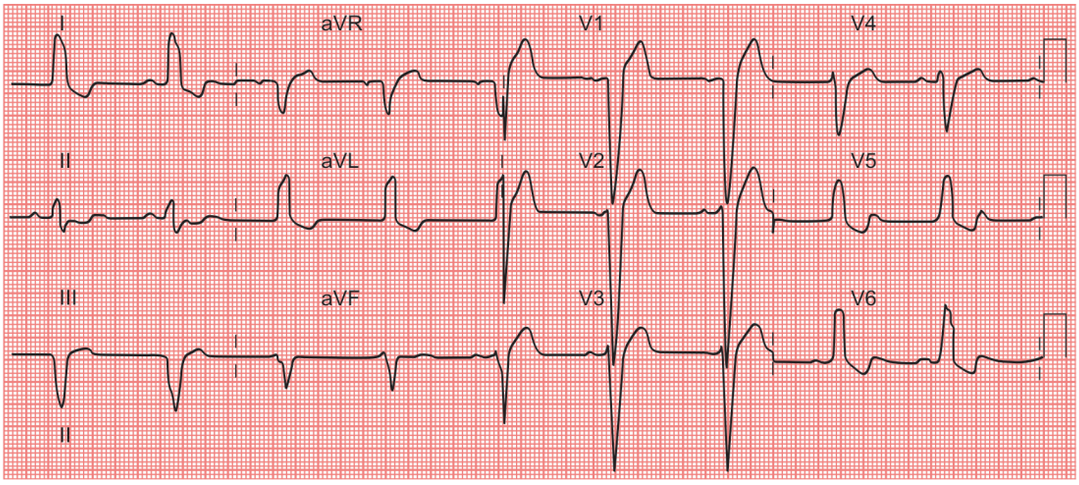

Fig. 20.91: In LBBB, the normal direction of septal depolarisation is reversed (become right to left), as the impulse spreads first to the RV via the right bundle branch and then to the LV via the septum. This sequence of activation extends the QRS duration to >120 ms and eliminates the normal septal Q-waves in the lateral leads

- 'Incomplete' LBBB looks like LBBB but QRS duration = 0.10–0.12s, with less ST-T change. This is often a progression of LVH.
- **Left anterior fascicular block (LAFB):** The most common intraventricular conduction defect
- Left axis deviation in frontal plane, usually –45 to –90 degrees
- rS complexes in leads II, III, aVF
- Small q-wave in leads I *and/or* aVL
- R-peak time in lead aVL >0.04s, often with slurred R wave downstroke
- QRS duration usually <0.12s unless coexisting RBBB
- Usually see poor R progression in leads V1-V3 and deeper S waves in leads V5 and V6
- May *mimic* LVH voltage in lead aVL, and *mask* LVH voltage in leads V5 and V6.
- **Left posterior fascicular block (LPFB):** Very rare intraventricular defect
- Right axis deviation in the frontal plane (usually >+100 degrees)
- rS complex in lead I
- qR complexes in leads II, III, aVF, with R in lead III>R in lead II
- QRS duration usually <0.12s unless coexisting RBBB
- **Must first exclude** (on clinical grounds) other causes of right axis deviation such as cor pulmonale, pulmonary heart disease, pulmonary hypertension, etc. because these conditions can result in the identical ECG picture.

Bifascicular Blocks

- RBBB plus either LAFB (common) or LPFB (uncommon)
- Features of RBBB plus frontal plane features of the fascicular block (axis deviation, etc.)

LONG QT SYNDROME

Patients with a prolonged QT interval are more prone to the risk of recurrent syncope and sudden death due to ventricular tachycardia or ventricular fibrillation. The idiopathic long QT syndrome ventricular fibrillation. The idiopathic long QT syndrome may be either autosomal recessive or autosomal dominant (Figs 20.92 and 20.93).

Prolongation of the QT interval may be:

- Acquired by patients having electrolyte imbalance,
- Taking antiarrhythmic drugs,
- Taking psychotropic drugs,
- Having myocarditis,
- Myocardial ischemia,
- Sinus node disease or
- Central nervous system disease consuming liquid protein diets

It is associated with a specific type of ventricular arrhythmia, Torsade de pointes, which is characterized by the cycles of alternating electrical polarity of the QRS complex peaks that oscillate or twist around the isoelectric line. The alternating cycles may be interrupted by periods of rapid tachycardia and polarity. The rhythm rate varies from 160 to 280 beats per minute and most often is between 200 beats and 250 beats per minute. Assessment and treatment of ventricular tachyarrhythmias present extraordinary challenges to the clinician. Moreover, the prognosis for patients is quite variable with these characteristically sudden-onset, unpredictable, and transitory arrhythmias. In some patients, ventricular ectopic activity may be benign and without sequelae, but in other patients, comparable ectopy is a harbinger of ventricular fibrillation and sudden cardiac death.

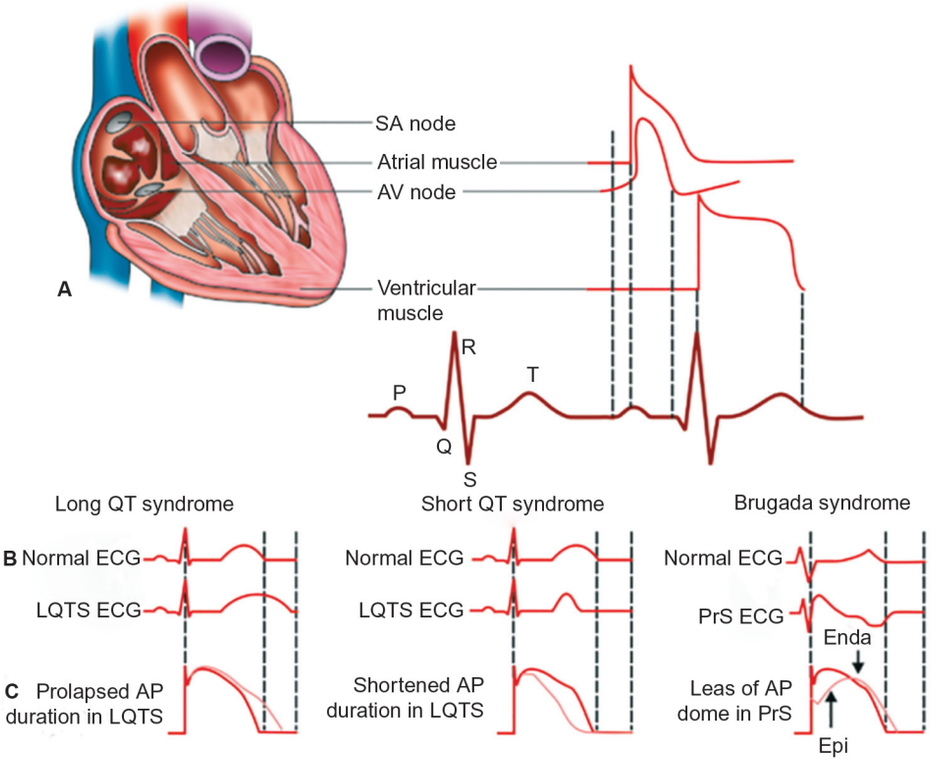

Fig. 20.92: The genesis of long and short QT interval

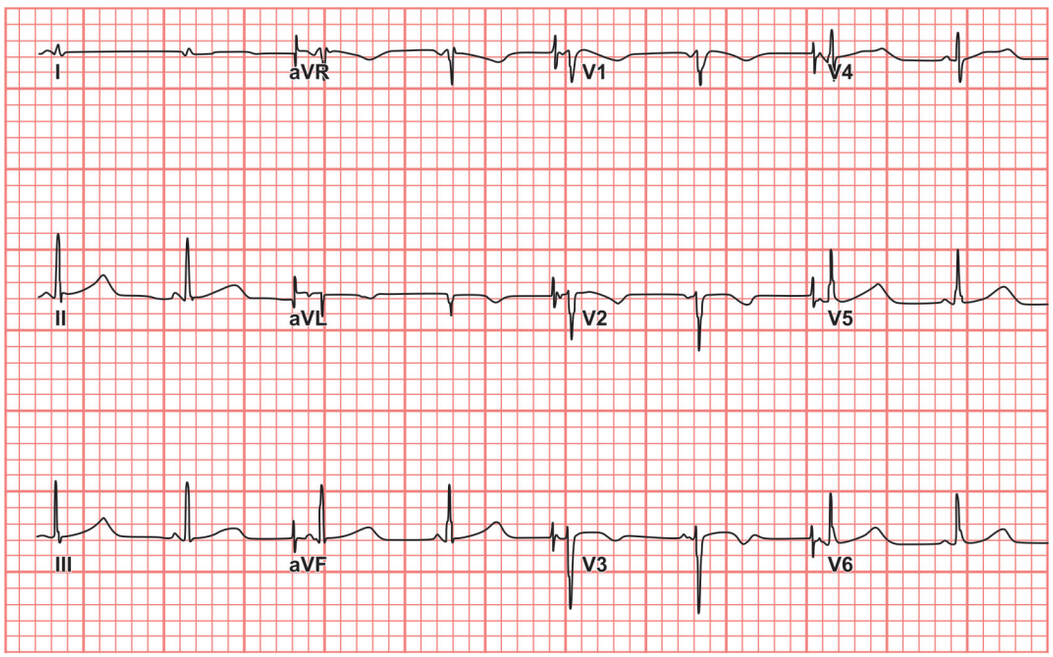

Fig. 20.93: ECG showing long QTc (620 mc) due to severe hypothermia

SHORT QT SYNDROME

Short QT syndrome (Fig. 20.94) is a genetic disease of the electrical system of the heart. It consists of a constellation of signs and symptoms, consisting of a short QT interval interval on EKG (? 300 ms) that doesn't significantly change with heart rate, tall and peaked T-waves, and a structurally normal heart. Short QT syndrome appears to be inherited in an autosomal dominant pattern, and a few affected families have been identified.

Short QT syndrome is inherited in an autosmal dominant pattern. Individuals with short QT syndrome frequently complain of palpitations and may have syncope (loss of

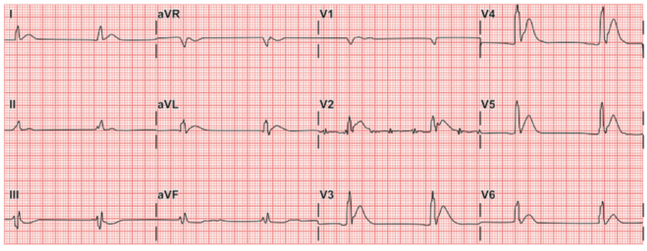

Fig. 20.94: ECG showing very short QTc (280 mc) with tall peaked T-waves due to congenital short QT interval

consciousness) that is unexplained. Mutations in the KCNH2, KCNJ2, and KCNQ1 genes cause short QT syndrome. These genes provide instructions for making proteins that act as channels across the cell membrane. These channels transport positively charged atoms (ions) of potassium into and out of cells. In cardiac muscle, these ion channels play critical roles in maintaining the heart's normal rhythm. Mutations in the KCNH2, KCNJ2, or KCNQ1 gene increase the activity of the channels, which changes the flow of potassium ions between cells. This disruption in ion transport alters the way the heart beats, leading to the abnormal heart rhythm characteristic of short QT syndrome. Short QT syndrome appears to have an autosomal dominant pattern of inheritance. Due to the autosomal dominant inheritance pattern, most individuals will have family members with a history of unexplained or sudden death at a young age (even in infancy), palpitations, or atrial fibrillation. Short QT syndrome is associated with an increased risk of sudden cardiac death, most likely due to ventricular fibrillation.

Diagnosis

The diagnosis of short QT syndrome consists of characteristic history and findings on EKG and electrophysiologic testing. There are currently no set guidelines for the diagnosis of short QT syndrome.

Electrocardiogram

The characteristic findings of short QT syndrome on EKG are a short QT interval, typically 300 ms, that doesn't significantly change with the heart rate. Tall peaked T-waves may also be noted. Individuals may also have an underlying atrial rhythm of atrial fibrillation.

BRUGADA SYNDROME

In 1992, Brugada and colleagues described a clinical syndrome consisting of apparently healthy adults presenting with syncope or sudden death (Fig. 20.95). Their ECGs showed coved ST-segment elevation and negative T-waves in leads V1 and V2 (V3) in the absence of RBBB pattern. This ECG pattern has become to be known as the 'Brugada-ECG.' These patients were thought to have no evidence of structural heart disease, and were at high risk for recurrent syncope or sudden death. In 15–20% of patients a genetic defect in the cardiac sodium channel was

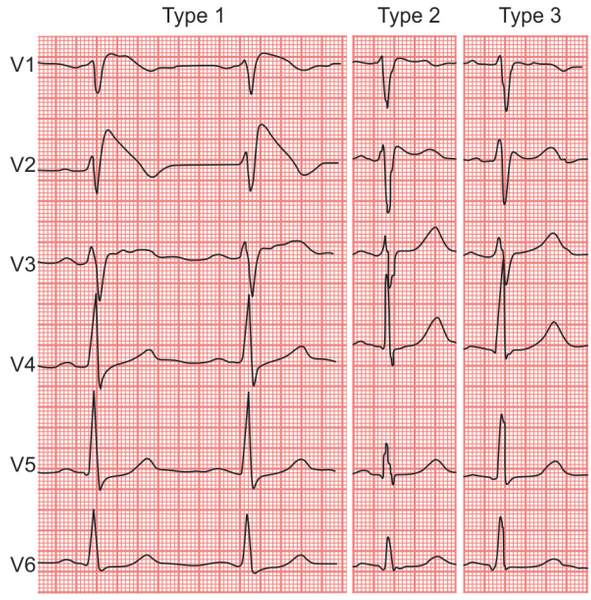

Fig. 20.95: ECG abnormality diagnostic or suspected of Brugada syndrome. Type 1 ECG (coved-type ST-segment elevation) is the only diagnostic ECG in Brugada syndrome and is defined as a J-wave amplitude or an ST-segment elevation of >2 mm or 0.2 mV at its peak (followed by a negative T-wave with little or no isoelectric separation). Type 2 ECG (saddle-back type ST-segment elevation), defined as a J-wave amplitude of >2 mm, gives rise to a gradually descending ST-segment elevation (remaining >1 mm above the baseline) followed by a positive or biphasic T-wave that results in a saddle-back configuration. Type 3 ECG is a right precordial ST-segment elevation (saddle-back type, coved type, or both) without meeting the aforementioned criteria

found. It has been proposed that there is a premature termination of the epicardial action potential with loss of the phase-2 dome pattern. The ECG changes are believed to be due to regional epicardial, endocardial voltage gradient during the plateau phase of the action potential. This voltage gradient may give rise to VT due to phase-2 re-entry caused by inhomogeneity of the voltage in adjacent areas of the myocardium. In patients with the Brugada syndrome, syncope and sudden death are due to polymorphic VT. Since the original description, it has been observed that the 'Brugada-ECG' type ST-segment elevation in V1 in the right precordial leads can be:

- Cove shaped,
- Saddle shaped,
- Transient, and be present in a multitude of clinical-conditions.

There has been a recent attempt to standardize this diagnostic ECG feature as follows:

- **Type I**: Coved-shaped right precordial ST-elevation, in more than one right precordial lead (V1–V3), of >2 mm followed by a negative T-wave
- **Type II**: Saddle-shaped ST-elevation, and
- **Type III**: ST-elevation of <2 mm.

Only type I is said to be diagnostic of Brugada syndrome. These ST-elevations are sensitive to heart rate and the effects

of autonomic stimulation. Furthermore, sodium channel-blocking antiarrhythmic drugs such as procainamide or lecainide have been shown to 'provoke' these ECG changes in patients with otherwise normal baseline ECG, and have been proposed as a screening tool in patients suspected to have the Brugada syndrome. However, the sensitive, specificity and reproducibility of this drug provocation are not well established. Of interest, certain gene mutations are sensitive to temperature with regard to their phenotypic expression. Indeed, Brugada-type ECG changes have been seen in patients only during febrile illness. Some speculate that seizures during febrile illness may be related to self-terminating ventricular arrhythmias due to a temperature sensitive mutation in the sodium channel, giving rise to the 'Brugada syndrome.' Patients with resuscitated sudden death or syncope or with a family history of premature sudden death and typical type I Brudaga ECG changes are at increased risk of recurrent events, and should be considered for ICD therapy. Asymptomatic patients who have an unprovoked typical Brudaga ECG (type I) are also at increased risk for arrhythmic events, but the magnitude of the risk is unclear. In one study the event rate over a mean of 24 months follow up was 8% in these patients. Those presenting with typical Brugada ECG (type I) only after drug exposure or those presenting with nondiagnostic right precordial ECG abnormalities (type II, type III) are believed to be at low risk. The role of electrophysiologic study and prognostic value of inducible VF remain controversial.

HOW ARE ARRHYTHMIAS DIAGNOSED?

Arrhythmias can be hard to diagnose, especially the types that only cause symptoms every once in a while. Doctors diagnose arrhythmias based on medical and family histories, a physical exam, and the results from tests and procedures (Figs 20.96–20.99).

Specialists Involved

Doctors who specialize in the diagnosis and treatment of heart diseases include:

- Cardiologists: These doctors diagnose and treat adults who have heart problems.
- Pediatric cardiologists: These doctors diagnose and treat babies, children, and youth who have heart problems.
- Electrophysiologists: These doctors are cardiologists or pediatric cardiologists who specialize in arrhythmias (Table 20.8).

Medical and Family Histories

To diagnose an arrhythmia, your doctor may ask you to describe your symptoms. He or she may ask whether you feel fluttering in your chest and whether you feel dizzy or light-headed (Table 20.9).

Your doctor also may ask whether you have other health problems, such as a history of heart disease, high blood pressure, diabetes, or thyroid problems. He or she may ask about your family's medical history, including whether anyone in your family:

- Has a history of arrhythmias
- Has ever had heart disease or high blood pressure
- Has died suddenly
- Has other illnesses or health problems



Fig. 20.96: ECG measurements are challenging because changes as small as 0.5 millimeters can indicate the presence of a serious or emergency heart condition. AirStrip cardiology's high resolution can detect such small differences through completely interactive iPad or iPhone views. Unlike traditional remote diagnostics, zooming in on waveforms does not affect visual clarity. With AirStrip cardiology, clinical information is available from 12- and 15-lead ECGs, supporting high precision levels. Clinicians can view current data and historical tests conducted up to 1 year ago, in 10-second increments. Regardless of where remote cardiologists are when a critical decision is needed, they can leverage AirStrip cardiology to quickly determine the best treatment paths for their patients. This may reduce the need to return to the hospital or access a computer connected to the hospital network. A remote cardiologist can now use AirStrip cardiology to precisely measure ECG waveforms, helping on-site ED clinicians determine, for example, if a patient requires Cath lab intervention

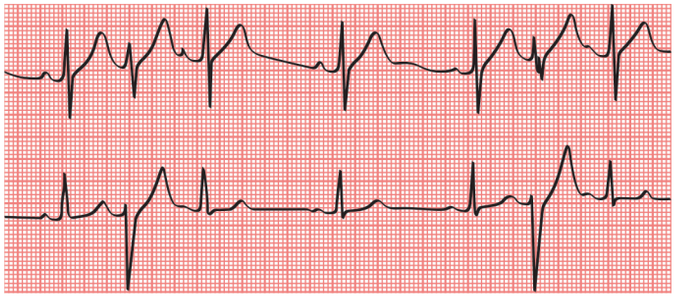

Fig. 20.97: Interpolated VPCs. There is no pause after the premature contractions

Table 20.8: Ventricular arrhythmias: who to refer and who not to refer to an electrophysiologist

Do not refer	Do refer
• Patients with mildly symptomatic or asymptomatic ventricular ectopic activity	• Patients with highly symptomatic ventricular ectopic activity
• Asymptomatic patients with 'benign' ventricular tachycardia on or off antiarrhythmic drug treatment	• Symptomatic patients with 'benign' ventricular tachycardia or controlled only with unacceptable side effects from antiarrhythmic drugs
• Patients who are candidates for prophylactic ICD implantation but without symptomatic arrhythmia	• Patients who are candidates for prophylactic ICD implantation but with symptomatic arrhythmia
	• Any patient with symptomatic ventricular tachycardia with or without prophylactic ICD indication
	• Any patient suspected of having a 'sudden cardiac death syndrome'
	• Any patient in whom arrhythmia mechanism is uncertain

ICD=implantable cardioverter-defibrillator.

Table 20.9: Specific arrhythmias and associated defects in adults with congenital heart disease

Arrhythmias	Do associated defects
Tachycardias	
Accessory pathways	Ebstein's anomaly, L-TGA
Twin AV nodes	Heterotaxy syndrome
Intra-atrial re-entrant tachycardia (atrial flutter)	Postoperative mustard, postoperative senning, postoperative fontan, and others
Atrial fibrillation	Mitral valve disease, aortic stenosis, and unrepaired single ventricle
Ventricular tachycardia	Tetralogy of fallot, congenital aortic stenosis, and others
Bradycardias	
Congenital sinus node dysfunction	Heterotaxy syndrome
Acquired sinus node dysfunction	Postoperative mustard, postoperative senning, postoperative fontan, posterative glenn, and others
Congenital AV block	Endocardial cushion defects, L-TGA
Acquired AV block	VSD closure, subaortic stenosis relief, and AV valve replacement

VSD=ventricular septal defect



Fig. 20.98: Contineous Holter monitoring ECG shows ventricular tachycardia is terminated with ventricular burst pacing from the ICD

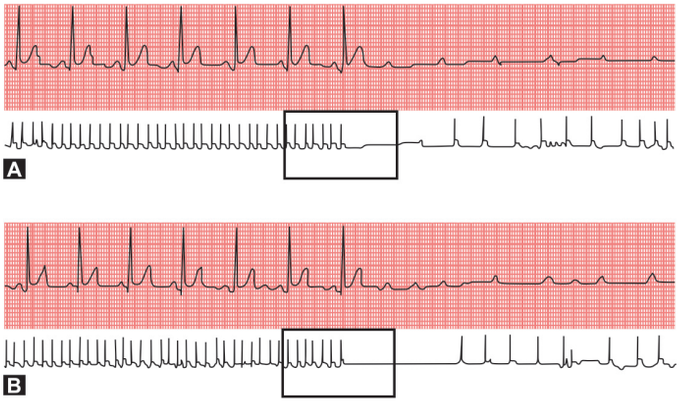

Fig. 20.99: Holter recording showing complete heart block in a woman who complained of attacks of palpitations and syncope

- Your doctor will likely want to know what medicines you're taking, including over-the-counter medicines and supplements.
- Your doctor may ask about your health habits, such as physical activity, smoking, or using alcohol or drugs (for example, cocaine). He or she also may want to know whether you have had emotional stress or anger.

Physical Exam

During a physical exam, your doctor may:

- Listen to the rate and rhythm of your heartbeat
- Listen to your heart for a heart murmur (an extra or unusual sound heard during your heartbeat)
- Check your pulse to find out how fast your heart is beating
- Check for swelling in your legs or feet, which could be a sign of an enlarged heart or heart failure
- Look for signs of other diseases, such as thyroid disease, that could be causing the problem

DIAGNOSTIC TESTS AND PROCEDURES

Electrocardiogram

An electrocardiogram (EKG) is a simple, painless test that detects and records the heart's electrical activity. It's the most common test used to diagnose arrhythmias (Table 20.10).

An EKG shows how fast the heart is beating and its rhythm (steady or irregular). It also records the strength and timing of electrical signals as they pass through the heart.

A standard EKG only records the heartbeat for a few seconds. It won't detect arrhythmias that don't happen during the test.

To diagnose arrhythmias that come and go, your doctor may have you wear a portable EKG monitor. The two most common types of portable EKGs are Holter and event monitors.

Holter and Event Monitors

A Holter monitor records the heart's electrical signals for a full 24- or 48-hour period. You wear one while you do your normal daily activities. This allows the monitor to record your heart for a longer time than a standard EKG.

- An event monitor is similar to a Holter monitor. You wear an event monitor while doing your normal activities. However, an event monitor only records your heart's electrical activity at certain times while you're wearing it.
- For many event monitors, you push a button to start the monitor when you feel symptoms. Other event monitors start automatically when they sense abnormal heart rhythms.
- Some event monitors are able to send data about your heart's electrical activity to a central monitoring station. Technicians at the station review the information and send it to your doctor. You also can use the device to report any symptoms you are having.
- You can wear an event monitor for weeks or until symptoms occur.

Other Tests

Other tests also are used to help diagnose arrhythmias.

Blood tests: Blood tests check the level of substances in the blood, such as potassium and thyroid hormone. Abnormal levels of these substances can increase your chances of having an arrhythmia.

Chest X-ray: A chest X-ray is a painless test that creates pictures of the structures in your chest, such as your heart and lungs. This test can show whether your heart is enlarged.

Table 20.10: Initial categorization of tachycardiac rhythms using the 12-lead electrocardiogram

Rhythm	Narrow	Wide
Regular	**Short-RP** • Typical (slow-fast) • Atypical (slow-slow) AVNRT (usually) • Orthodromic, AVRT • JT • AT (less commonly) **Long-RP** • Atypical (fast-slow) AVNRT • Orthodromic AVRT (slowly conducting accessory pathway) • ST • AT (more commonly) • PJRT **Flutter waves** • AFI (fixed AV block)	AVNRT ST, JT, AT, AVNRT, orthodromic AVRT, or AFI with aberrancy Antidromic AVRT Monomorphic ventricular tachycardia
Irregular	AF AFI (variable AV block) MAT	AF, AFI or MAT with aberrancy AF, AFI with pre-excitation Polymorphic ventricular tachycardia

AF=atrial fibrillation: AFI=atrial flutter; AT=atrial tachycardia; AVNRT=antriventricular node re-entrant tachycardia; AVRT=atrioventricular re-entrant tachycardia; JT=junction tachycardia; MAT=multifocal atrial tachycardia; PJRT=permanent junctinoal reciprocating tachycardia; ST=sinus tachycardia

Echocardiography: This test uses sound waves to create a moving picture of your heart. Echocardiography (echo) provides information about the size and shape of your heart and how well your heart chambers and valves are working.

The test also can identify areas of poor blood flow to the heart, areas of heart muscle that aren't contracting normally, and previous injury to the heart muscle caused by poor blood flow.

There are several types of echo, including stress echo. This test is done both before and after a stress test. A stress echo usually is done to find out whether you have decreased blood flow to your heart, a sign of coronary heart disease (CHD).

A transesophageal (tranz-ih-sof-uh-JEE-ul) echo, or *TEE*, is a special type of echo that takes pictures of the heart through the esophagus. The esophagus is the passage leading from your mouth to your stomach.

Stress test: Some heart problems are easier to diagnose when your heart is working hard and beating fast. During stress testing, you exercise to make your heart work hard and beat fast while heart tests are done. If you can't exercise, you may be given medicine to make your heart work hard and beat fast.

The heart tests done during stress testing may include nuclear heart scanning, echo, and positron emission tomography (PET) scanning of the heart.

Electrophysiology study (EPS): This test is used to assess serious arrhythmias. During an EPS, a thin, flexible wire is passed through a vein in your groin (upper thigh) or arm to your heart. The wire records your heart's electrical signals (Figs 20.100–20.107).

Your doctor can use the wire to electrically stimulate your heart and trigger an arrhythmia. This allows your doctor to see whether an antiarrhythmia medicine can stop the problem.

Catheter ablation, a procedure used to treat some arrhythmias, may be done during an EPS.

Tilt table testing: This test sometimes is used to help find the cause of fainting spells. You lie on a table that moves from a lying down to an upright position. The change in position may cause you to faint.

Your doctor watches your symptoms, heart rate, EKG reading, and blood pressure throughout the test. He or she

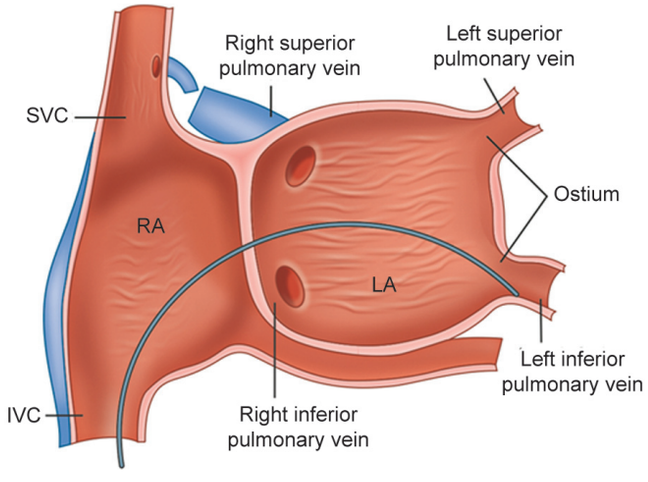

Fig. 20.100: Targeting the triggers in atrial fibrillation (AF) ablation

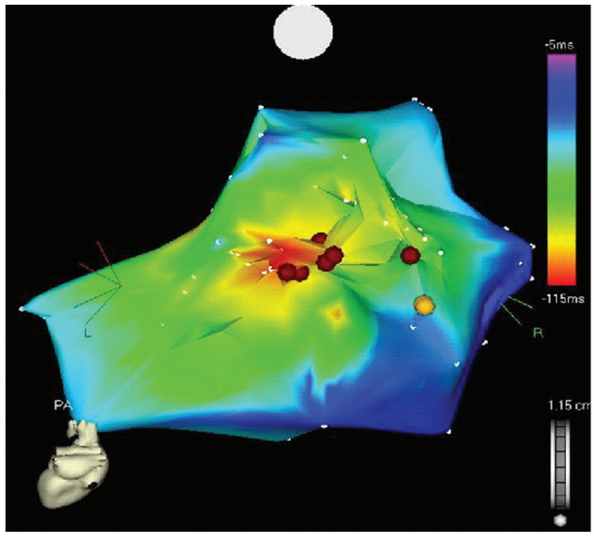

Fig. 20.101: A posteroanterior view of a right ventricular endocardial activation map during ventricular tachycardia in a patient with a prior septal myocardial infarction. Earliest activation is recorded in red; late activation shows as blue to magenta. Fragmented low amplitude diastolic local electrograms were recorded adjacent to the earliest (red) breakout area, and local ablation in this scared zone (red dots) resulted in termination and noninducibility of this previously incessant arrhythmia

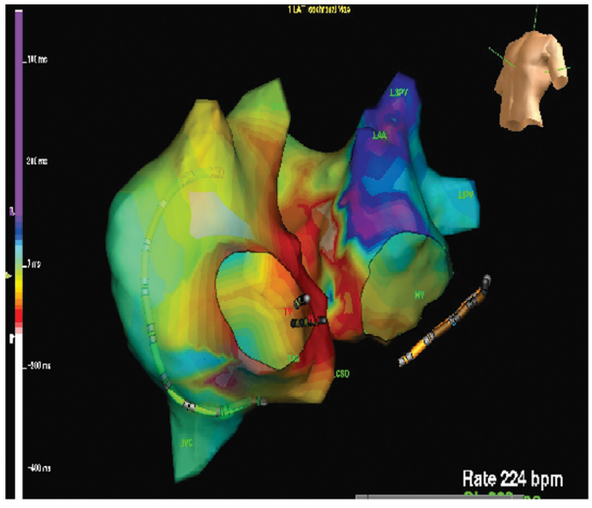

Fig. 20.102: Three-dimensinal mapping. This is a specialized mapping technique which utilizes a computer to delineate the source of complex arrhythmias. It works by projecting a virtual 3-D image of the heart in the computer to help the cardiac electrophysiologist navigate his catheters, in ways very similar to what GPS does for driving a car or flying an airplane. For many types of ablation, such as those for atrial fibrillation, 3-D mapping is essential to ensure optimal success rates and safety for the patients

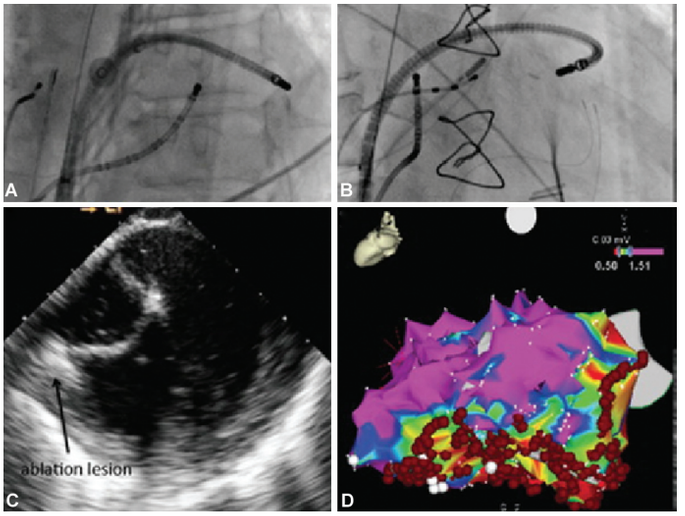

Fig. 20.103: Mapping and ablation of a basal lateral scar. (A and B) Robotic catheter position in left and right anterior oblique fluoroscopic views, respectively. The mid-lateral wall is being mapped. (C) Intracardiac echocardiographic image showing catheter contact and lesion formation in the left ventricular lateral wall. (D) Three-dimensional map of the lateral scar and the ablation lesions created

may give you medicine and then check your response to the medicine.

Coronary angiography: Coronary angiography uses dye and special X-rays to show the inside of your coronary arteries. To get the dye into your coronary arteries, your doctor will use a procedure called cardiac catheterization (KATH-e-ter-ih-ZA-shun).

A thin, flexible tube called a catheter is put into a blood vessel in your arm, groin (upper thigh), or neck. The tube is threaded into your coronary arteries, and the dye is released into your bloodstream.

Special X-rays are taken while the dye is flowing through your coronary arteries. The dye lets your doctor study the flow of blood through your heart and blood vessels. This helps your doctor find blockages that can cause a heart attack.

Implantable loop recorder: This device detects abnormal heart rhythms. Minor surgery is used to place this device under the skin in the chest area.

An implantable loop recorder helps doctors figure out why a person may be having *palpitations* or fainting spells, especially if these symptoms do not happen very often. The device can be used for as long as 12–24 months.

HOW ARE ARRHYTHMIAS TREATED?

Common arrhythmia treatments include medicines, medical procedures, and surgery. Your doctor may recommend treatment if your arrhythmia causes serious symptoms, such as dizziness, chest pain, or fainting. Your doctor also may recommend treatment if the arrhythmia increases your risk for problems such as heart failure, stroke, or sudden cardiac arrest.

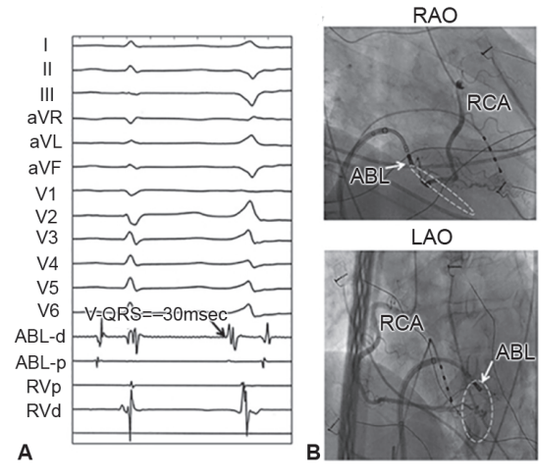

Fig. 20.104: (A) The intracardiac ECG at a successful middle cardiac vein (MCV) ablation site. (B) RAO (top) and LAO (bottom) fluoroscopic views at the site of successful ablation of a basal crux ventricular tachycardia within the MCV. ABL=ablation catheter; LOA=left anterior oblique; RAO=right anterior oblique; RCA=right coronary artery

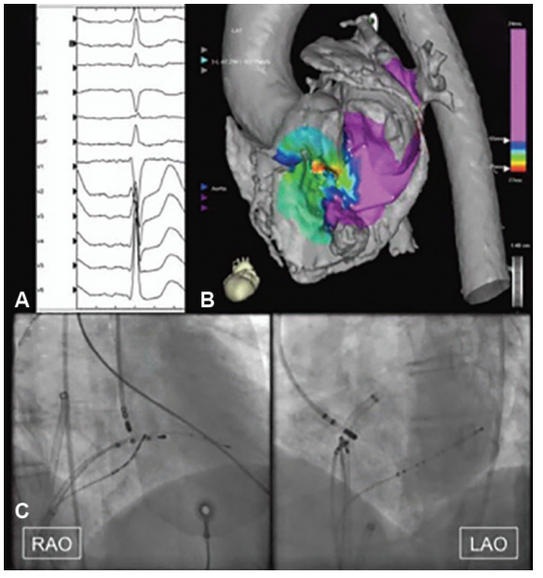

Fig. 20.105: Graph ablation of a focal parahisian atrial tachycardia from the noncoronary aortic sinus of Valsalva. The P-wave morphology (A) with a multiphasic configuration in V1. (B) displays an electroanatomic activation map merged into a preacquired CT geometry with the segmented ventricle removed. The red zone in the noncoronary aortic sinus of Valsalva represents the earliest breakthrough of the tachycardia with later activation seen on either side of the interatrial septum. The fluoroscopic catheter position at the successful ablation site, and (C) close proximity to the His catheter

Medicines

Medicines can slow down a heart that's beating too fast. They also can change an abnormal heart rhythm to a normal, steady rhythm. Medicines that do this are called antiarrhythmics (Tables 20.11–20.13).

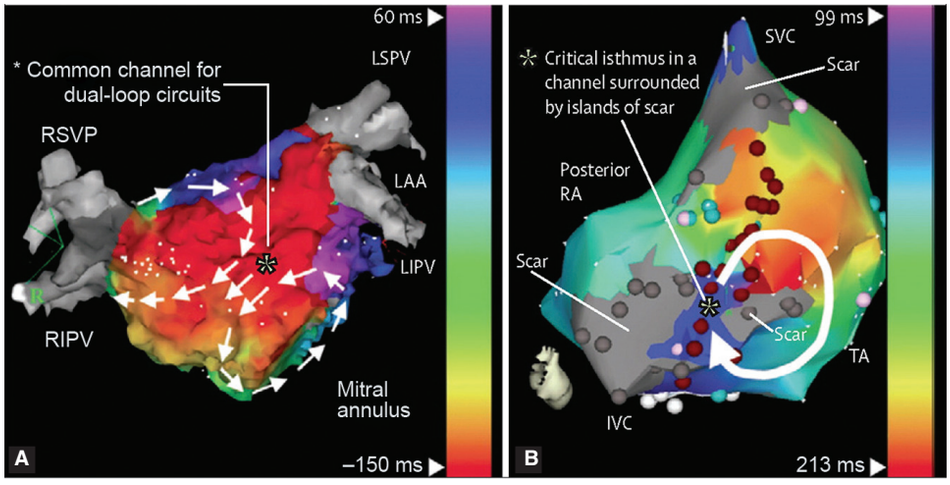

Fig. 20.106A: Catheter ablation of atrial arrhythmias. (A) Dual-loopleft atrial flutter (anterioposterior view), (B) Rightatrial flutter after ASD repair (right lateral view)

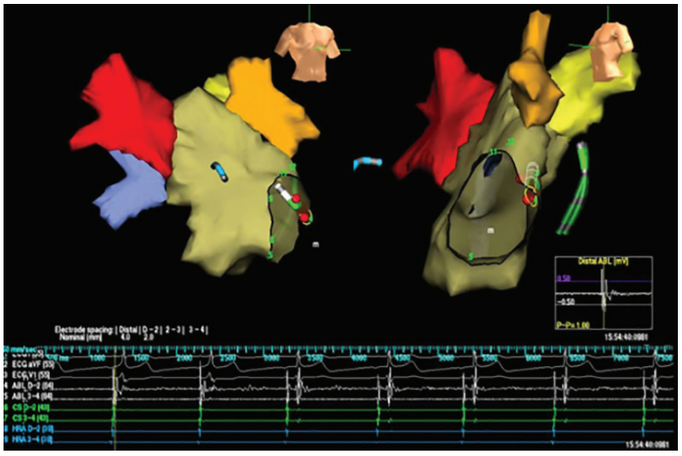

Fig. 20.106B: Accessory pathway ablation; palpitations and syncope found to have delta wave. Please note the near continuous activation of AV at 0300 mitral annulus. After application of RF at 25 watts, AV separate (with loss of delta wave) during the third beat

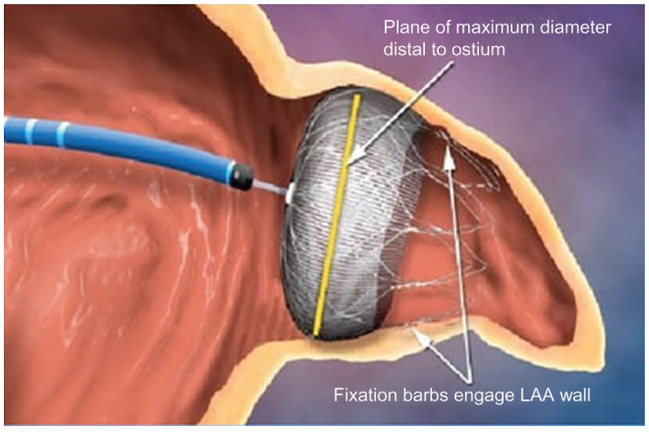

Fig. 20.107: Left atrial appendage closure device. Patients with atrial fibrillation (AF) are at an increased risk of stroke that can originate in the left atrial appendage (LAA). WATCHMAN device from Boston Scientific was developed to fill the space of the LAA and capture any clots that form within. Now the company received expanded indication approval in Europe to offer this treatment to AF patients that have a contraindication to the currently available anticoagulants

Some of the medicines used to slow a fast heart rate are beta-blockers (such as metoprolol and atenolol), calcium channel blockers (such as diltiazem and verapamil), and digoxin (digitalis). These medicines often are used to treat atrial fibrillation (AF).

Some of the medicines used to restore a normal heart rhythm are amiodarone, sotalol, flecainide, propafenone, dofetilide, ibutilide, quinidine, procainamide, and disopyramide. These medicines often have side effects. Some side effects can make an arrhythmia worse or even cause a different kind of arrhythmia.

Currently, no medicine can reliably speed up a slow heart rate. Abnormally slow heart rates are treated with pacemakers.

People who have AF and some other arrhythmias may be treated with blood-thinning medicines. These medicines reduce the risk of blood clots forming. Warfarin (Coumadin®), dabigatran, heparin, and aspirin are examples of blood-thinning medicines.

Medicines also can control an underlying medical condition that might be causing an arrhythmia, such as heart disease or a thyroid condition.

Medical Procedures

Some arrhythmias are treated with pacemakers. A pacemaker is a small device that's placed under the skin of your chest or abdomen to help control abnormal heart rhythms (Figs 21.108–21.110).

Pacemakers have sensors that detect the heart's electrical activity. When the device senses an abnormal heart rhythm, it sends electrical pulses to prompt the heart to beat at a normal rate.

Table 20.11: Classwise antiarrhythmic drugs

Class	Known as	Examples	Mechanism	Clinical uses in cardiology
Ia	Fast-channel blockers-affect QRS complex	• Quinidine • Procainamide • Disopyramide	Na^+ channel block (intermediate association/dissociation)	• Ventricular arrhythmias • Prevention of paroxysmal recurrent atrial fibrillation (triggered by vagal overactivity) • Procainamide in Wolff-Parkinson-White syndrome
Ib-	Do not affect QRS complex	• Lidocaine • Phenytoin • Mexiletine • Tocainide	Na^+ channel block (fast association/dissociation)	• Treatment and prevention during and immediately after myocardial infarction, though this practice is now discouraged given the increased risk of asystole • Ventricular tachycardia • Atrial fibrillation
Ic	—	• Flecainide • Propafenone • Moricizine	Na^+ channel block (slow association/dissociation)	• Prevents paroxysmal atrial fibrillation • Treats recurrent tachyarrhythmias of abnormal conduction system. • Contraindicated immediately post-myocardial infarction
II	Beta-blockers	• Propranolol • Esmolol • Timolol • Metoprolol • Atenolol • Bisoprolol	Beta blocking Propranolol also shows some class I action	• Decrease myocardial infarction mortality • Prevent recurrence of tachyarrhythmias
III	—	• Amiodarone • Sotalol • Ibutilide • Dofetilide • Dronedarone • E-4031	K^+ channel blocker Sotalol is also a beta-blocker Amiodarone has class I, II, III and IV activity	• In Wolff-Parkinson-White syndrome • Sotalol: Ventricular tachycardias and atrial fibrillation • Ibutilide: Atrial flutter and atrial fibrillation
IV	Slow-channel blockers	• Verapamil • Diltiazem	Ca^{2+} channel blocker	• Prevent recurrence of paroxysmal supraventricular tachycardia • Reduce ventricular rate in patients with atrial fibrillation
V	—	• Adenosine • Digoxin • Magnesium sulfate	Work by other or unknown mechanisms (direct nodal inhibition).	Used in supraventricular arrhythmias, especially in heart failure with atrial fibrillation, contraindicated in ventricular arrhythmias. Or in the case of magnesium sulfate, used in torsades de pointes

Table 20.12: Drugs commonly used to control ventricular rate in patients with atrial fibrillation

Drugs	Initial dosing	Maintenance dosing	Comments
Calcium channel blockers			
Diltiazem (cardizem)	15–20 mg IV over 2 minutes; may repeat in 15 minutes	5–15 mg per hour by continuous IV infusion	Convenient; easy to titrate to heart rate goal
Verapamil (calan, isoptin)	5–10 mg IV over 2 minutes; may repeat in 30 minutes	Not standardized	More myocardial depression and hypotension than with diltiazem
Beta-blockers			
Esmolol (brevibloc)	Bolus of 500 mcg per kg IV over 1 minute; may repeat in 5 minutes	50–300 mcg per kg per minute by continuous IV infusion	Very short-acting; easy to titrate to heart rate goal
Propranolol (inderal)	1 mg IV over 2 minutes 5 minutes to maximum of 5 mg	1–3 mg IV every 4 hours may repeat every	Short duration of action; hence, need for repeat dosing
Digoxin (lanoxin)	0.25–0.5 mg IV; then 0.25 mg IV every 4–6 hours to maximum of 1 mg	0.125–0.25 mg per day IV or orally	Adjunctive therapy; less effective for rate control than beta-blockers or calcium channel blockers

IV=intravenous.

Adapted with permission from Li H, Easley A, Barrington W, Windle J. Evaluation and management of atrial fibrillation in the emergency department. Emerg Med Clin North Am 1998;16:389–403.

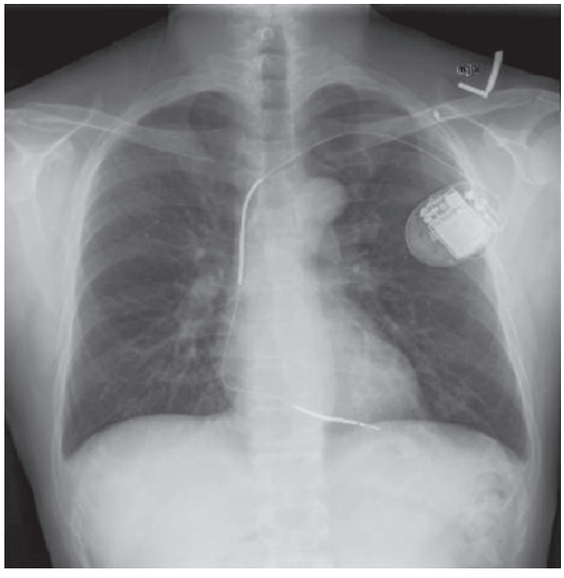

Fig. 20.108: Chest X-ray showing an implantable cardioverter-defibrillator (ICD), with its battery fixed at left subclavicular region and is connected with a wire placed in the trabecular part of the right ventricular apex



Fig. 20.109: An implantable cardioverter-defibrillator (ICD)

Some arrhythmias are treated with a jolt of electricity to the heart. This type of treatment is called cardioversion or defibrillation, depending on which type of arrhythmia is being treated.

Some people who are at risk for ventricular fibrillation are treated with a device called *an implantable cardioverter defibrillator (ICD).* Like a pacemaker, an ICD is a small device that's placed under the skin in the chest. This device uses electrical pulses or shocks to help control life-threatening arrhythmias.

- An ICD continuously monitors the heartbeat. If it senses a dangerous ventricular arrhythmia, it sends an electric shock to the heart to restore a normal heartbeat.
- A procedure called catheter ablation is used to treat some arrhythmias if medicines don't work. During this procedure, a thin, flexible tube is put into a blood vessel in your arm, groin (upper thigh), or neck. Then, the tube is guided to your heart.
- A special machine sends energy through the tube to your heart. The energy finds and destroys small areas of heart

Table 20.13: Summarizes drugs used in the emergency management of life-threatening ventricular arrhythmias

Medication	VF pulseless VT	Stable monomorphic VT	Stable wide complex tachycardia aetiology uncertain	Unstable monomorphic VT	Torsades de pointes
Amiodarone	Initial:300 mg Recurrent/persistent: 150 mg diluted in 100 ml D5W over 10 min	150 mg diluted in 100 mL D5W over 10 min. Follow with continuous infusion 1 mg/min for 6 h, then 0.5 mg/min for 18 h	150 mg diluted in 100 ml D5W over with continuous infusion 1 mg/min for 6 h, then 0.5 mg/min for 18 h	Not first treatment of choice	Not treatment of choice
Lidocaine	Recurrent/persistent: 1–1.5 mg/kg IV push. May follow with repeat bolus every 5–10 mins. Maximum total dose: 3 mg/kg	1.5 mg/kg IV push. May follow with repeat bolus of 0.5–0.75 mg/kg every 5 to 10 mins to max total dose of 3 mg/kg or maintenance infusion of 2–4 mg/min (30–50 mcg/kg/min)	Not treatment of choice	Not first treatment of choice	Not treatment of choice
Magnesium sulfate	Only indicated if hypomagnesemia is suspected or known	Only indicated if hypomagnesemia is suspected or known	Only indicated if hypomagnesemia is suspected	Only indicated if hypomagesemia is suspected	For cardiac arrest: 1–2 grams over a maximum of 15 mins given IV push
Procainamide	Persistent/recurrent Loading dose: 20–50 mg/min (or 100 mg every 5 mins) IV infusion	Loading dose: 20–50 mg/min (or 100 mg every 5 mins) IV infusion Maintenance infusion: 1–4 mg/min Maximum dose: 17 mg/kg Not drug of choice for persons with reduced ventricular function	Loading dose: 20–50 mg/min (or 100 mg every 5 Maintenance infusion: 1–4 mg/min Not drug of choice for persons with reduced ventricular function	Not first treatment of choice	Not treatment of choice

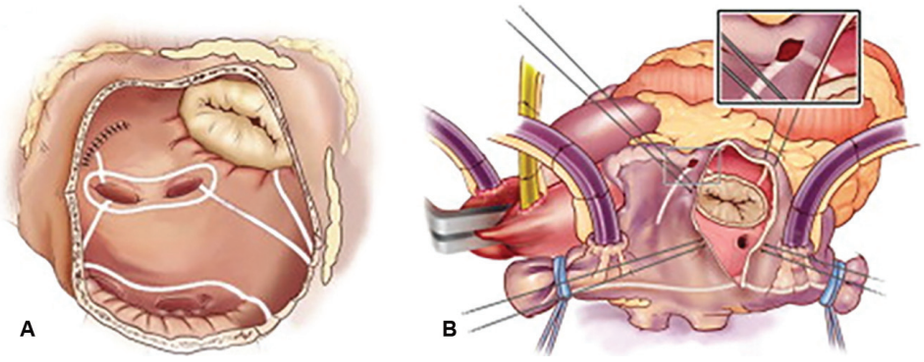

Fig. 20.110: Cox-Maze procedure for atrial fibrillation. Showing right atrial lesion set and left atrial lesion set. The surgeon can use small incisions, radio waves, freezing, or microwave or ultrasound energy to create scar tissue. The scar tissue, which does not conduct electrical activity, blocks the abnormal electrical signals causing the arrhythmia. The scar tissue directs electric signals through a controlled path, or maze, to the lower heart chambers (ventricles)

tissue where abnormal heart rhythms may start. Catheter ablation usually is done in a hospital as part of an electrophysiology study.

- Your doctor may recommend transesophageal echocardiography before catheter ablation to make sure no blood clots are present in the atria (the heart's upper chambers).

Surgery

Doctors treat some arrhythmias with surgery. This may occur if surgery is already being done for another reason, such as repair of a heart valve. One type of surgery for AF is called maze surgery. During this surgery, a surgeon makes small cuts or burns in the atria. These cuts or burns prevent the spread of disorganized electrical signals. If coronary heart disease is the cause of your arrhythmia, your doctor may recommend coronary artery bypass grafting. This surgery improves blood flow to the heart muscle.

Other Treatments

Vagal maneuvers are another type of treatment for arrhythmia. These simple exercises sometimes can stop or slow down certain types of supraventricular arrhythmias. They do this by affecting the vagus nerve, which helps control the heart rate.

Some vagal maneuvers include:

- Gagging
- Holding your breath and bearing down (Valsalva maneuver)
- Immersing your face in ice-cold water
- Coughing
- Putting your fingers on your eyelids and pressing down gently
- Vagal maneuvers aren't an appropriate treatment for everyone. Discuss with your doctor whether vagal maneuvers are an option for you.

Living with an Arrhythmia

Many arrhythmias are harmless. It's common to have an occasional extra heartbeat or mild palpitations. People who have harmless arrhythmias can live healthy lives. They usually don't need treatment for their arrhythmias.

Even people who have serious arrhythmias often can be successfully treated and lead normal lives.

ONGOING CARE

If you have an arrhythmia that requires treatment, you should:

- Keep all of your medical appointments. Bring a list of all the medicines you are taking to every doctor and emergency room visit. This will help your doctors know exactly what medicines you're taking, which can help prevent medication errors.
- Take your medicines as prescribed. Check with your doctor before taking over-the-counter medicines, nutritional supplements, or cold and allergy medicines. Some of these products can trigger rapid heart rhythms or interact poorly with heart rhythm medicines.
- Tell your doctor if you are having side effects from your medicines. Side effects might include depression and palpitations. These side effects often can be treated.
- Tell your doctor if arrhythmia symptoms are getting worse or if you have new symptoms.
- See your doctor for regular checkups if you are taking blood-thinning medicines. You may need routine blood tests to check how the medicines are working.
- If you have an arrhythmia, taking care of yourself is important. If you feel dizzy or faint, you should lie down. Do not try to walk or drive. Let your doctor know about these symptoms.
- Ask your doctor whether vagal manoeuvres are an option for you. These exercises can help stop a rapid heartbeat, but they are not appropriate for everyone.

- Learn how to take your pulse. Discuss with your doctor what pulse rate is normal for you. Keep a record of changes in your pulse rate and share this information with your doctor.

LIFESTYLE CHANGES

Many arrhythmias are caused by underlying heart disease. Keep your heart healthy by following a healthy diet.

A healthy diet includes a variety of fruits and vegetables. It also includes whole grains, fat-free or low-fat dairy products, and protein foods, such as lean meats, poultry without skin, seafood, processed soy products, nuts, seeds, and beans and peas.

A healthy diet is low in sodium (salt), added sugars, solid fats, and refined grains. Solid fats are saturated fat and *trans* fatty acids. Refined grains come from processing whole grains, which results in a loss of nutrients (such as dietary fiber).

For more information about following a healthy diet, go to the national heart, lung, and blood institute's 'your guide to lowering your blood pressure with DASH' and the United States Department of Agriculture's Choose MyPlate.gov website. Both resources provide general information about healthy eating.

A healthy lifestyle also includes being physically active, quitting smoking, maintaining a healthy weight, and keeping your blood cholesterol and blood pressure at healthy levels.

Strong emotional stress or anger can lead to arrhythmias. Try to manage stress and anger through activities such as yoga, quiet time, meditation, and relaxation techniques. Getting support from friends and family also can help you manage stress.

Your doctor may want you to avoid certain substances if they make your heart beat too fast. These substances may include alcohol and cold and cough medicines.

NEWER ANTIARRHYTHMIC DRUGS

Dronedarone

Amiodarone is generally accepted to be a valuable antiarrhythmic drug, but it accumulates in tissues during long-term therapy, which may result in significant toxicity in several organ systems. Several compounds that were designed to be similar in structure and electrophysiological effects to amiodarone have completed or are now in clinical trials.

Dronedarone is, like amiodarone, a benzofuranyl compound with iodine removed and a methane sulfonyl group added. Removing iodine from the molecule was intended to eliminate or reduce iodine-related organ toxicity. The side chain modification decreased lipophilicity, resulting in a shorter elimination half-life with less potential for tissue accumulation. The basic and clinical pharmacology of dronedarone has been recently reviewed.

Dronedarone retains many of amiodarone's electrophysiological effects. It is a multichannel blocker with effects on the rapid and slow components of the delayed rectifier current (IKr and IKs), L-type calcium currents, (ICa-L), the inward sodium current (INa), and the inward rectifier potassium current (IK1). Dronedarone also inhibits the acetylcholine receptor-dependent K^+ current (IKAch) and the pacemaker current (If) and is a noncompetitive a- and β-adrenergic antagonist. Dronedarone reduces sinus rate and prolongs AV nodal conduction and refractoriness. Effects on the QT and QTc intervals have been variable when studied in different species. In several animal models of ischemia or reperfusion-induced arrhythmias, dronedarone effectively prevents spontaneous and induced ventricular fibrillation.

Budiodarone

Unlike dronedarone, **budiodarone (**AT1-2042), another compound that structurally resembles amiodarone, retains iodine atoms in its molecular structure. A sec-butyl acetate side chain has been added at position 2 of the benzofuranyl ring. This ester modification changes the compound's metabolic pathways such that budiodarone undergoes rapid degradation by plasma and tissue esterases, not by CYP3A-mediated oxidation, to an inactive compound. During *in-vitro* studies, budiodarone has shown electrophysiological properties similar to amiodarone.

Only limited clinical data on budiodarone are available. One study assessed twice-daily placebo or doses of 200, 400, 600, and 800 mg during sequential 2-week periods in a very small group of patients with paroxysmal atrial fibrillation and implanted pacemakers. Atrial fibrillation burden (defined as percent time in atrial fibrillation) was calculated during each period. Budiodarone reduced total atrial fibrillation burden by reducing the duration but not the number of atrial fibrillation episodes. Preliminary data from a similar but a larger phase 2 trial compared placebo and budiodarone (200, 400, and 600 mg twice daily) in 72 patients with pacemakers and paroxysmal atrial fibrillation. There were 54.4% and 75% reductions in AF burden in the 400 mg and 600 mg groups. Some patients manifested a rise in thyroid-stimulating hormone, but clinical symptoms of thyroid disease did not appear.

Celivarone

Celivarone (SSR149744C) is another noniodinated benzofuran derivative with electrophysiological effects similar to amiodarone. Few clinical data have been published in manuscript form, but a phase 2 trial tested celivarone's efficacy at 300- or 600-mg daily doses for conversion of atrial fibrillation and flutter (CORYFEE, NCT00232310) and a dose ranging study compared celivarone at 50, 100, 200, or 300 mg once daily with amiodarone for maintenance of sinus rhythm (MAIA, NCT00233441) have been completed but not yet published. A preliminary report from the dose-ranging study showed the lowest rate of atrial fibrillation recurrence at the 50 mg dose with no enhanced efficacy at the higher doses. In another study in patients with ICDs, 2 doses of celivarone (100 and 300 mg daily) were compared with placebo over 6 months of therapy. A 46% reduction

in the number of sustained ventricular arrhythmia episodes requiring ICD therapy was noted in the 300 mg daily group, but this reduction did not achieve statistical significance (P=0.172). Additional trials in patients with ventricular arrhythmias and ICDs are planned.

Vernakalant

Vernakalant is an atrial-selective, multiple ion channel blocker that is in the advanced stages of investigation for the treatment of atrial fibrillation. Both intravenous and oral forms of vernakalant have undergone clinical trials. The intravenous form has been recommended for approval by the Cardiorenal Advisory Committee of the Food and Drug Administration, but a formal letter of approval has not been issued. Vernakalant is an atrial repolarization-delaying agent with its major target IKur. Vernakalant also blocks Ito and INa, although there is little effect on IKr or IKs. As IKur is present in higher density in the atria, vernakalant is relatively atrial selective. The INa inhibition is rate- and voltage-dependent. Vernakalant has, therefore, a much greater effect in fibrillating atria than in the ventricle and is less likely to be proarrhythmic.

Vernakalant is hepatically metabolized by CYP2D6. It is not clear what effect abnormal liver function has on the metabolism of the drug. In a study of intravenous vernakalant, coadministration of CYP2D6 inhibitors did not appear to decrease clearance, and little difference was seen in maximum plasma concentrations between CYP2D6 poor and extensive metabolizers. Differences in renal function, age, sex, race, blood pressure, and heart failure status have not been shown to affect the pharmacokinetics of vernakalant. Vernakalant demonstrates 2-compartment elimination pharmacokinetics, and its half-life after intravenous administration is 2–5 hours. The oral bioavailability of vernakalant is approximately 20%. During oral therapy in the dose range of 300 to 600 mg twice daily, steady-state concentrations are achieved in 4 days. It remains to be seen whether CYP2D6 poor and extensive metabolizers will require different doses during chronic oral therapy.

Phase 3 trials have not been completed for oral vernakalant, although phase 2 trials have been promising for the long-term maintenance of sinus rhythm. The phase 2a trial was double-blinded, randomized, and compared a 300-mg dosage, a 600-mg dosage, and placebo for 25 days after cardioversion. Electrical cardioversion was permitted for patients who did not convert within 3 days after initiation of the medication. Significantly more patients remained in sinus rhythm at the end of the trial period in the 300-mg dosing group and in the combined 300- and 600-mg groups, when compared with placebo. The phase 2b trial compared 150-, 300-, and 500-mg dosages with placebo, and the trial duration was 90 days. The 500-mg dosage group showed durable maintenance of sinus rhythm at 90 days compared with placebo, with low incidence of side effects. There were no reported cases of torsades de pointes.

In summary, intravenous vernakalant for cardioversion of recent onset AF is moderately effective for rapid termination of atrial fibrillation with durable maintenance of sinus rhythm up to 24 hours. The side effect profile shows relatively modest potential for toxicity. Age, sex, ethnicity, and concomitant illnesses do not appear to alter efficacy. Of course, drugs used only for the acute conversion of atrial fibrillation must also be compared with electrical cardioversion as well as other agents. Oral vernakalant may prove useful for maintenance of sinus rhythm, but phase 3 trials have yet to be completed. If these trials show efficacy, vernakalant probably will be more widely used in conversion attempts as a step to long-term therapy. There are no clinical data on the effects of vernakalant in ventricular arrhythmias, and its mechanisms of action suggest it would not be useful.

Ranolazine

Ranolazine is currently approved for the treatment of chronic angina pectoris. Ranolazine reduces myocardial ischemia by its effects on the late inward Na^+ current (INaL). During myocardial ischemia and heart failure, INaL is augmented. This results in increased sodium entry and, via sodiumcalcium exchange, increased cytosolic calcium concentrations. These changes produce action potential prolongation and increased susceptibility to early afterdepolarizations. Ranolazine is an inactivated sodium channel blocker. At concentrations near its therapeutic range for angina (2–6 μmol/L, IC50 60 μmol/L), ranolazine inhibits INaL. In the same concentration range, ranolazine inhibits peak INa in the atrium but not the ventricle. This effect results in reduced atrial excitability and a rate-dependent increase in postrepolarization atrial refractoriness. In experiments using an isolated canine ventricular wedge preparation, ranolazine results in either no change or a decrease in transmural ventricular dispersion of refractoriness and does not produce early after depolarizations, triggered activity, or polymorphic ventricular tachycardia. In other experiments, ranolazine has been shown to suppress excitability and triggered activity in an isolated canine pulmonary vein sleeve preparation, terminate acetylcholine- and isoproterenol-induced atrial fibrillation, and prevent its reinitiation.

Ranolazine has variable systemic availability after oral administration due to its extensive first-pass metabolism in the gut and liver. Metabolism is mainly via CYP3A4 and, to a lesser extent, CYP2D6. The terminal elimination half-life is 7 hours. The recommended dosage in patients with angina is 500–1000 mg twice daily. Ranolazine should not be used as concurrent therapy with strong CYP3A4 inhibitors (e.g. ketoconazole), and dose reduction is recommended with moderate CYP3A4 inhibitors (e.g. diltiazem) or P-glycoprotein inhibitors. Ranolazine is a weak inhibitor of CYP3A4 and a moderate inhibitor of CYP2D6 and P-glycoprotein.

Ranolazine's effects on ECG intervals underwent extensive study during its development for its current indication of chronic angina. Ranolazine results in a 2- to 6-ms mean increase in the QTc interval, but drug-induced polymorphic ventricular tachycardia has not been observed. The MERLIN-TIMI trial enrolled 6560 patients

with a non-ST-elevation acute coronary syndrome who were randomly assigned to either ranolazine (intravenous initiation, then 1000 mg twice daily) or matched placebo, in addition to standard medical therapy. No significant improvement was shown in the primary end point of death and recurrent ischemic events with ranolazine in MERLIN-TIMI, but data from continuous ambulatory ECG recordings during the first 7 days of therapy were recently reported. Significant decreases in the frequency of nonsustained ventricular and supraventricular tachycardia were noted. A trend toward less frequent new-onset atrial fibrillation was also seen. A single case report on the successful use of ranolazine to suppress high-density ventricular tachycardia has been reported. An uncontrolled case series has also described control of recurrent atrial fibrillation in 4 of 7 patients with drug-resistant arrhythmia. Controlled trials with ranolazine as an antiarrhythmic drug in patients with atrial fibrillation are in the planning stages.

One form of the long-QT syndrome (LQT3) is caused by mutations in the SCN5A sodium channel that lead to enhanced and sustained activity of late INa. Moss et al. administered intravenous ranolazine to 5 patients with LQT3. During the infusion, ranolazine shortened QTcf by 26±3 ms. Diastolic function on echocardiography was also improved. Ranolazine may also prove useful in another form of the long-QT syndrome. The Timothy syndrome (LQT8) is a multisystem disorder characterized by facial dysmorphism, syndactyly, QT prolongation, and premature sudden death. The syndrome is caused by a missense mutation in Cav1.2, the gene that encodes the a-subunit of the L-type calcium channel, resulting in a gain in function of the L-type calcium current. In an animal model of the Timothy syndrome, ranolazine suppressed polymorphic ventricular tachycardia induced by the calcium channel agonist BayK8644. Clinical data on the chronic treatment of arrhythmias in LQT3 and Timothy syndrome patients are not available.

At present, the only approved indication for ranolazine is the treatment of angina. It remains to be proven whether it will also be useful as an antiarrhythmic agent.

Ivabradine

Ivabradine selectively inhibits the spontaneous pacemaker activity of the sinus node by blocking the I_f current. This reduces the heart rate without altering myocardial contractility or other hemodynamics. Ivabradine has been approved for use as an antianginal in Europe. It has also been used off-label in Europe as a treatment for inappropriate sinus tachycardia. It has not yet been approved for any use in the United States. The blockage of the If current is dose-dependent and heart rate-dependent. There is a greater efficiency in blocking I_f at faster heart rates, limiting the risks of symptomatic bradycardia. Electrophysiological studies of ivabradine in humans have shown little effect on the conduction system or on atrial and ventricular refractoriness. Some remodeling of the sinus node appears to occur in response to ivabradine, but no rebound tachycardia has been seen after discontinuing the drug.

Ivabradine is 80% hepatically metabolized by the CYP3A4 enzyme and cannot be used concomitantly with drugs that inhibit this enzyme, such as azoles and macrolide antibiotics. There does not appear to be a difference in heart rate response between patients who are CYP3A4 rapid metabolizers and those who are slow metabolizers. It is 20% renally cleared. The oral bioavailability is approximately 40% and it takes 60 to 90 minutes to reach maximal plasma concentrations. The half-life is approximately 2 hours.

The major trial that evaluated ivabradine is the BEAUTIFUL study. This randomized, double-blind, placebo-controlled trial enrolled 10917 patients with ischemic cardiomyopathy to receive ivabradine versus placebo. There was no difference in the primary end point of cardiovascular death or admissions for acute infarction or heart failure. In patients with baseline heart rates >70 bpm, however, the secondary end points of admission for fatal and nonfatal infarction and the need for revascularization were significantly reduced. The heart rate reduction due to ivabradine was 6±2 bpm. A previous study compared ivabradine with atenolol for treatment of patients with stable angina and found that ivabradine was as effective as atenolol. It is on this basis that it was approved for use in Europe.

Composite data from phase 2 and phase 3 trials suggest that most side effects are dose-related. Ion channels in the retina that generate the I_h current are also affected by ivabradine. This is the mechanism for ivabradine's major side effect, visual luminous phenomena, also known as phosphenes (14.5%). Phosphenes usually resolve with continued treatment and are a rare cause of drug discontinuation. Severe bradycardia is seen in 3.3% of patients. Other less common side effects include palpitations, nausea, headaches, vertigo, muscle cramps, hypereosinophilia, and hyperuricemia.

Little trial data exists regarding the treatment of atrial tachyarrhythmias with ivabradine. The mechanism of action suggests that ivabradine may benefit patients with inappropriate sinus tachycardia. In Europe, where the drug is being marketed, it is used off-label in the treatment of inappropriate sinus tachycardia. Further data will be needed as to its effectiveness in treating this condition.

Adenosine A1 Receptor Agonists

Adenosine is frequently used for termination of supraventricular tachycardias (SVT). Adenosine terminates SVT in patient with AV nodal or AV re-entry by stimulating the A1 adenosine receptor to produce transient AV block. However, adenosine induces atrial fibrillation in up to 15% of patients by decreasing the refractory period of the atrium. In addition, adenosine also stimulates the A2A, A2B, and A3 adenosine receptor subtypes, which contribute to its adverse effect profile. Stimulation of these receptors leads to a variety of systemic side effects, including flushing (18%), dyspnea (12%), and chest pain (7%). Efforts have been made to identify A1 receptor-selective agonists for both the termination of SVT and rate control for atrial

fibrillation. Several are under investigation currently, including tecadenoson, selodenoson, and PJ-875. Tecadenoson is the furthest along in the development process. A phase 3 trial has been completed evaluating tecadenoson for the termination of SVT, and preclinical data are promising for rate control of atrial fibrillation. Selodenoson and PJ-875 are both in the early stages of evaluation for treatment of atrial fibrillation.

Preclinical trials indicate that tecadenoson is a potent and selective agonist of the A1 receptor. Studies in animal models showed that it caused significant prolongation of AV nodal conduction and refractoriness without causing hypotension or negative inotropic effects. In addition, those effects were dose-dependent and persistent with chronic administration of the drug. A phase 1 dose-escalation trial in 32 patients showed a dose-dependent prolongation of the AH interval. There was no effect on the HV interval. The peak effect on AH interval was at 1 minute, and resolution occurred at 20 minutes. Four patients had significant heart block and 3 patients had atrial fibrillation (two after atrial pacing). Two patients had neurological effects. There is incomplete published information regarding the pharmacokinetics tecadenoson. It appears to follow a 2-compartment model and has a longer half-life than adenosine (20–30 minutes).

The most significant trial to evaluate tecadenoson to date is the phase 3 TEMPEST trial. This study was a multicenter, double-blinded, placebo-controlled trial that randomly assigned 181 patients to receive placebo versus 1 of several dose-escalating regimens of tecadenoson for termination of SVT. Overall, the conversion rates were 73.5% in the tecadenoson-treated patients and 6.7% in the placebo group. The rates of conversion did improve with dose escalation. Side effects were relatively mild and increased with dose escalation. Twelve patients had second-degree heart block. Two patients had complete heart block, and both of those patients were in the highest dose treatment group. Five patients in the 2 highest dose treatment groups developed transient atrial fibrillation or atrial flutter. The rates of flushing, dyspnea, and chest pain were 4%, 2.6%, and 3%, respectively. No patients in this study had alterations in blood pressure.

An animal study of tecadenoson for rate control of atrial fibrillation has shown promising results. In combination with metoprolol, rate control was improved with tecadenoson compared with either agent alone. Improved rate control was seen with exercise and with rest. A phase 2 clinical trial to evaluate the safety of tecadenoson to treat atrial fibrillation has been completed. Results have not yet been released.

In summary, the available data regarding adenosine A1 receptor agonists, particularly tecadenoson, is promising for the conversion of SVT and for short-term rate-control of atrial fibrillation. The rate of conversion for SVT is similar to that of adenosine, but the systemic side effects are milder. In addition, although adenosine A1 receptor stimulation is the presumed mechanism for the induction of atrial fibrillation, tecadenoson appears less likely to cause atrial fibrillation, perhaps because the maximal action potential shortening seen with a bolus of adenosine is not observed with longer-acting agents.

It is now recognized that atrial fibrillation originates from atrial tissue that has altered structure or function. Fibrosis within the atrium is one of the major mechanisms of atrial remodeling, which provides the substrate for atrial fibrillation generation and maintenance. Efforts have been made to develop 'upstream' therapies for atrial fibrillation. The renin-angiotensin-aldosterone system has been implicated in the fibrotic process. Therapies that alter renin-angiotensin-aldosterone system, as well as antiinflammatory and antioxidative drugs, are being investigated both alone and in combination with traditional antiarrhythmic drugs. For some newer drugs, data have only been generated in animal models. Further studies will be needed to delineate the full potential benefits of these and other therapies.

KEY POINTS

- Some arrhythmias are life-threatening medical emergencies that can result in cardiac arrest. Others cause symptoms such as an abnormal awareness of heart beat (palpitations), and may be merely uncomfortable.
- The term cardiac *arrhythmia* covers a very large number of very different conditions. The most common symptom of arrhythmia is an abnormal awareness of heartbeat, called palpitations.
- *Automaticity* refers to a *cardiac muscle* cell firing off an impulse on its own. All of the cells in the heart have the ability to initiate an action potential; however, only some are designed to routinely trigger heart beats. These cells are found in the conduction system of the heart.
- Ventricular fibrillation is imminently life-threatening. Atrial fibrillation is not typically a medical emergency.
- Arrhythmia may be classified by rate (normal, *tachycardia*, bradycardia), or mechanism (automaticity, re-entry, and fibrillation). It is also appropriate to classify by site of *origin*.
- Causes of SADS in young people include viral myocarditis, *long QT syndrome*, Brugada syndrome, catecholaminergic polymorphic ventricular tachycardia, hypertrophic cardiomyopathy, and arrhythmogenic right ventricular dysplasia.
- Atrial fibrillation is an irregular atrial rhythm that may be episodic or continuous; paroxysms of tachycardia may occur.
- QRS complexes should be narrow; a wide complex occurs with intraventricular conduction defects or Wolff-Parkinson-White syndrome.
- Patients should have echocardiography and thyroid function testing.
- Heart rate is controlled (typically to <100 beats/min at rest); first-line drugs include beta-blockers and nondihydropyridine calcium channel blockers (e.g. verapamil, diltiazem).

Contd...

Contd...

- Restoration of sinus rhythm is not as important as rate control and does not eliminate the need for anticoagulation but may help patients with continuing symptoms or hemodynamic compromise (e.g. heart failure); synchronized cardioversion or drugs can be used.
- Anticoagulation is usually necessary before cardioversion.
- Long-term oral anticoagulation to prevent stroke is required for patients with risk factors for thromboembolism; aspirin is used for those with no risk factors.

BIBLIOGRAPHY

1. A randomized, placebo-controlled trial of propafenone in the prophylaxis of paroxysmal supraventricular tachycardia and paroxysmal atrial fibrillation. UK Propafenone PSVT Study Group: Circulation 1995;92:2550.
2. Akhtar M, Jazayeri MR, Sra J, et al. Atrioventricular nodal re-entry: clinical, electrophysiological, and therapeutic considerations. Circulation 1993;88:282.
3. Amsterdam EA, Kulcyski J, Ridgeway MG. Efficacy of cardioselective beta-adrenergic blockade with intra-venously administered metoprolol in the treatment of supraventri-cular tachyarrhythmias. J Clin Pharmacol 1991;31:714.
4. Blomström-Lundqvist C, Scheinman MM, Aliot EM, et al. ACC/AHA/ESC Guidelines for the management of patients with supraventricular arrhythmias—executive.
5. Brugada P, Brugada J, Mont L, et al. A new approach to the differential diagnosis of a regular tachycardia with a wide QRS complex. Circulation 1991;83:1649.
6. Campbell RW, Smith RA, Gallagher JJ, et al. Atrial fibrillation in the preexcitation syndrome. Am J Cardiol 1977;40:514.
7. Clague JR, Dagres N, Kottkamp H, et al. Targeting the slow pathway for atrioventricular nodal re-entrant tachycardia: initial results and long-term follow-up in 379 consecutive patients. Eur Heart J 2001;22:82.
8. Clinical Investigator's Brochure: SR33589B Dronedarone. Bridgewater, NJ, Sanofi-Syntholabe Recherche. Edition: E07, 2006.
9. Dale KM, White CM. Dronedarone: an amiodarone analog for the treatment of atrial fibrillation and atrial flutter. Ann Pharmacother. 2007;41:599–605.
10. Dreifus LS, Haiat R, Watanabe Y, et al. Ventricular fibrillation: a possible mechanism of sudden death in patients and Wolff-Parkinson-White syndrome. Circulation 1971;43:520.
11. Ehrlich JR, Biliczki P, Hohnloser SH, Nattel S. Atrial-selective approaches for the treatment of atrial fibrillation. J Am Coll Cardiol. 2008; 51:787–92.
12. Flecainide acetate prevents recurrence of symptomatic paroxysmal supraventricular tachycardia. The Flecainide Supraventricular Tachycardia Study Group: Circulation 1991;83:119. Long-term safety and efficacy of flecainide in the treatment of supraventricular tachyarrhythmias: the United States experience. The Flecainide Supraventricular Tachy arrhythmia Investigators: Am J Cardiol 1992;70:11A.
13. Kay GN, Pressley JC, Packer DL, et al. Value of the 12-lead electro-cardiogram in discriminating atrioventricular nodal reciprocating tachycardia from circus movement atrio-ventricular tachycardia utilizing a retrograde accessory pathway. Am J Cardiol 1987;59:296.
14. Klein GJ, Bashore TM, Sellers TD, et al. Ventricular fibrillation in the Wolff-Parkinson-White syndrome. N Engl J Med. 1979;301:1080.
15. Kottkamp H, Hügl B, Krauss B, et al. Electromagnetic versus fluoroscopic mapping of the inferior isthmus for ablation of typical atrial flutter: A prospective randomized study. Circulation 2000;102(17):2082–6.
16. Lee KL, Chun HM, Liem LB, et al. Effect of adenosine and verapamil in catecholamine-induced accelerated atrio-ventricular junctional rhythm: insights into the underlying mechanism. Pacing Clin Electrophysiol 1999;22:866.
17. Mauritson DR, Winniford MD, Walker WS, et al. Oral verapamil for paroxysmal supraventricular tachycardia: a long-term, double-blind randomized trial. Ann Intern Med 1982;96:409.
18. Mehta D, Wafa S, Ward DE, et al. Relative efficacy of various physical manoeuvres in the termination of junctional tachycardia. Lancet 1988;1:1181.
19. Overholt ED, Rheuban KS, Gutgesell HP, et al. Usefulness of adenosine for arrhythmias in infants and children. Am J Cardiol 1988;61:336.
20. Paydak H, Kall JG, Burke MC, et al. Atrial fibrillation after radiofrequency ablation of type I atrial flutter: time to onset, determinants, and clinical course. Circulation. 1998;98(4): 315–22.
21. Pérez FJ, Schubert CM, Parvez B, Pathak V, Ellenbogen KA, Wood MA. Long-term outcomes after catheter ablation of cavotricuspid isthmus dependent atrial flutter: a meta-analysis. Circ Arrhythmia Electrophysiol. 2009;2(4):393–401.
22. Ross DL, Uther JB. Diagnosis of concealed accessory path-ways in supraventricular tachycardia. Pacing Clin Electro-physiol 1984;7:1069.
23. Savelieva I, Camm AJ. Anti-arrhythmic drug therapy for atrial fibrillation: current anti-arrhythmic drugs, investi-gational agents, and innovative approaches. Europace. 2008; 10:647–65.
24. Scheinman MM, Huang S. The 1998 NASPE prospective catheter ablation registry. Pacing Clin Electrophysiol 2000;23:1020.
25. Singh BN, Connolly SJ, Crijns HJGM, Roy D, Kowey PR, Cappucci A, Radzik D, Aliot EM, Hohnloser SH, for the EURIDIS and ADONIS Investigators. Dronedarone for maintenance of sinus rhythm in atrial fibrillation or flutter. N Engl J Med. 2007;357:23–35.
26. Summary: a report of the American College of Cardiology/American Heart Association Task Force on Practice Guide-lines and the European Society of Cardiology Committee for Practice Guidelines (Writing Committee to Develop Guidelines for the Management of Patients with Supraventri-cular Arrhythmias). Circulation 2003; 108:1871.
27. Sung RJ, Waxman HL, Saksena S, et al. Sequence of retrograde atrial activation in patients with dual

atrioventricular nodal pathways. Circulation 1981;64: 1059.
28. Tafreshi MJ, Rowles J. A review of the investigational antiarrhythmic agent dronedarone. J Cardiovasc Phamacol Ther. 2007;12:15–26.
29. Timmermans C, Smeets JL, Rodriguez LM, et al. Aborted sudden death in the Wolff-Parkinson-White syndrome. Am J Cardiol 1995;76:492.
30. Touboul P, Brugada J, Cappucci A, Crijns HJGM, Edvardsso N, Hohnloser SH. Dronedarone for prevention of atrial fibrillation: a dose-ranging study. Eur Heart J. 2003;24:1481–7.
31. Tsai CF, Tai CT, Yu WC, et al. Is 8-mm more effective than 4-mm tip electrode catheter for ablation of typical atrial flutter? Circulation. 1999;100(7):768–71.
32. Tschuppert Y, Buclin T, Rothuizen LE, Decosterd LA, Galleyrand J, Gaud C, Bioffaz J. Effect of dronedarone on renal function in healthy subjects. Br J Clin Pharmacol. 2007; 64:785–791.
33. Wellens HJ, Bar FW, Lie KI. The value of the electrocardiogram in the differential diagnosis of a tachycardia with a widened QRS complex. Am J Med 1978;64:27.
34. Willems S, Weiss C, Ventura R, et al. Catheter ablation of atrial flutter guided by electroanatomic mapping (CARTO): a randomized comparison to the conventional approach. J Cardiovasc Electrophysiol. 2000;11(11): 1223–30.
35. Winniford MD, Fulton KL, Hillis LD. Long-term therapy of paroxysmal supraventricular tachycardia: arandomized, double-blind comparison of digoxin, propranolol and verapamil. Am J Cardiol 1984;54:1138.
36. Yeh SJ, Lin FC, Chou YY, et al. Termination of paroxysmal supraventricular tachycardia with a single oral dose of diltiazem and propranolol. Circulation 1985;71:104.

21 Cardiogenic Shock

Cardiogenic shock is a major, and frequently fatal, complication of a variety of acute and chronic disorders that impair the ability of the heart to maintain adequate tissue perfusion. Cardiac failure with cardiogenic shock continues to be a frustrating clinical problem; the management of this condition requires a rapid and well-organized approach.

Cardiogenic shock is a physiologic state in which inadequate tissue perfusion results from cardiac dysfunction, most commonly following acute myocardial infarction (MI). Although, ST-elevation MI (STEM, previously termed Q-wave MI) is encountered in most patients, cardiogenic shock may also develop in patients with non–ST-elevation acute coronary syndrome (NSTEMI, NSTACS, or unstable angina). The clinical definition of cardiogenic shock is decreased cardiac output and evidence of tissue hypoxia in the presence of adequate intravascular volume. Hemodynamic criteria for cardiogenic shock are sustained hypotension (systolic blood pressure <90 mmHg for at least 30 min) and a reduced cardiac index (<2.2 L/min/m^2) in the presence of elevated pulmonary capillary occlusion pressure (>15 mmHg).

The diagnosis of cardiogenic shock can sometimes be made at the bedside by observing hypotension and clinical signs of poor tissue perfusion, which include oliguria, cyanosis, cool extremities, and altered mentation. These signs usually persist after attempts have been made to correct hypovolemia, arrhythmia, hypoxia, and acidosis.

HISTORICAL BACKGROUND

Cardiogenic shock is a medical emergency. A complete clinical assessment is critical to understanding the cause of the shock and to targeting therapy for correcting the cause (Figs 21.1 and 21.2).

Cardiogenic shock following acute MI generally develops after admission to the hospital, although a small number of patients are in shock at presentation. Patients demonstrate clinical evidence of hypoperfusion (low cardiac output), which is manifested by sinus tachycardia,

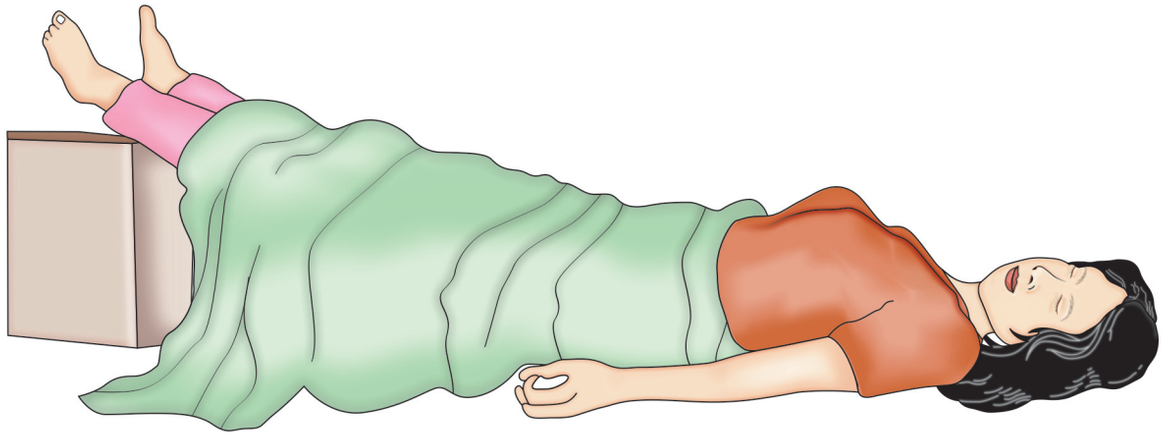

Fig. 21.1: Illustration showing a women patient lying unconcious with cardiogenic shock with raised legs as first step in her resuscitation by a rescue team



Fig. 21.2: A young patient with cardiac arrest being managed with cardioverter defibrillator. Electric paddles have been applied over the chest for imparting electric shock

low urine output, and cool extremities. Systemic hypotension, defined as systolic blood pressure below 90 mmHg or a decrease in mean blood pressure by 30 mm Hg, ultimately develops and further propagates tissue hypoperfusion.

Most patients who develop acute MI present with an abrupt onset of squeezing or heavy substernal chest pain; the pain may radiate to the left arm or the neck. The chest pain may be atypical, the location being epigastric or only in the neck or arm. The pain quality may be burning, sharp, or stabbing. Pain may be absent in persons with diabetes or in elderly individuals.

Patients also may report associated autonomic symptoms, including nausea, vomiting, and sweating.

A history of previous cardiac disease, use of cocaine, previous myocardial infarction (MI), or previous cardiac surgery should be obtained. A patient thought to have myocardial ischemia should be assessed for cardiac risk factors. The evaluation should reveal a history of hyperlipidemia, left ventricular hypertrophy, hypertension, or cigarette smoking or a family history of premature coronary artery disease. The presence of 2 or more risk factors increases the likelihood of acute MI.

Other associated symptoms are diaphoresis, exertional dyspnea, or dyspnea at rest. Presyncope or syncope, palpitations, generalized anxiety, and depression are other features indicative of poor cardiac function.

PHYSICAL EXAMINATION

Cardiogenic shock is diagnosed after documentation of myocardial dysfunction and exclusion of alternative causes of hypotension, such as hypovolemia, hemorrhage, sepsis, pulmonary embolism, pericardial tamponade, aortic dissection, or pre-existing valvular disease. Shock is present if evidence of multisystem organ hypoperfusion is detected upon physical examination (Fig. 21.3 and Table 21.1).



Fig. 21.3: A doctor conducting thorough clinical examination in a patient with cardiogenic shock

Table 21.1: Clinical findings associated with right ventricular infarction

Hypotension
Elevated jugular venous pressure
Kussmaul's sign
Abnormal jugular venous pressure pattern (Y ≥ X descent)
Tricuspid regurgitation
Right sided S3 and S4
Pulsus paradoxus
High-grade atrioventricular block

Characteristics of patients with cardiogenic shock include the following:

- Patients in shock usually appear ashen or cyanotic and have cool skin and mottled extremities
- Peripheral pulses are rapid and faint and may be irregular if arrhythmias are present
- Jugular venous distention and crackles in the lungs are usually (but not always) present; peripheral edema also may be present.
- Heart sounds are usually distant, and third and fourth heart sounds may be present.
- The pulse pressure may be low, and patients are usually tachycardic.
- Patients show signs of hypoperfusion, such as altered mental status and decreased urine output.
- A systolic murmur is generally heard in patients with acute mitral regurgitation or ventricular septal rupture. The associated parasternal thrill indicates the presence of a ventricular septal defect, whereas the murmur of mitral regurgitation may be limited to early systole.
- The systolic murmur, which becomes louder upon Valsalva and prompt standing, suggests hypertrophic obstructive cardiomyopathy (idiopathic hypertropic subaortic stenosis).

PREDISPOSING FACTORS IN CARDIOGENIC SHOCK

Various predisposing conditions development of cardiogenic shock include the following (Fig. 21.4 and Table 21.2).

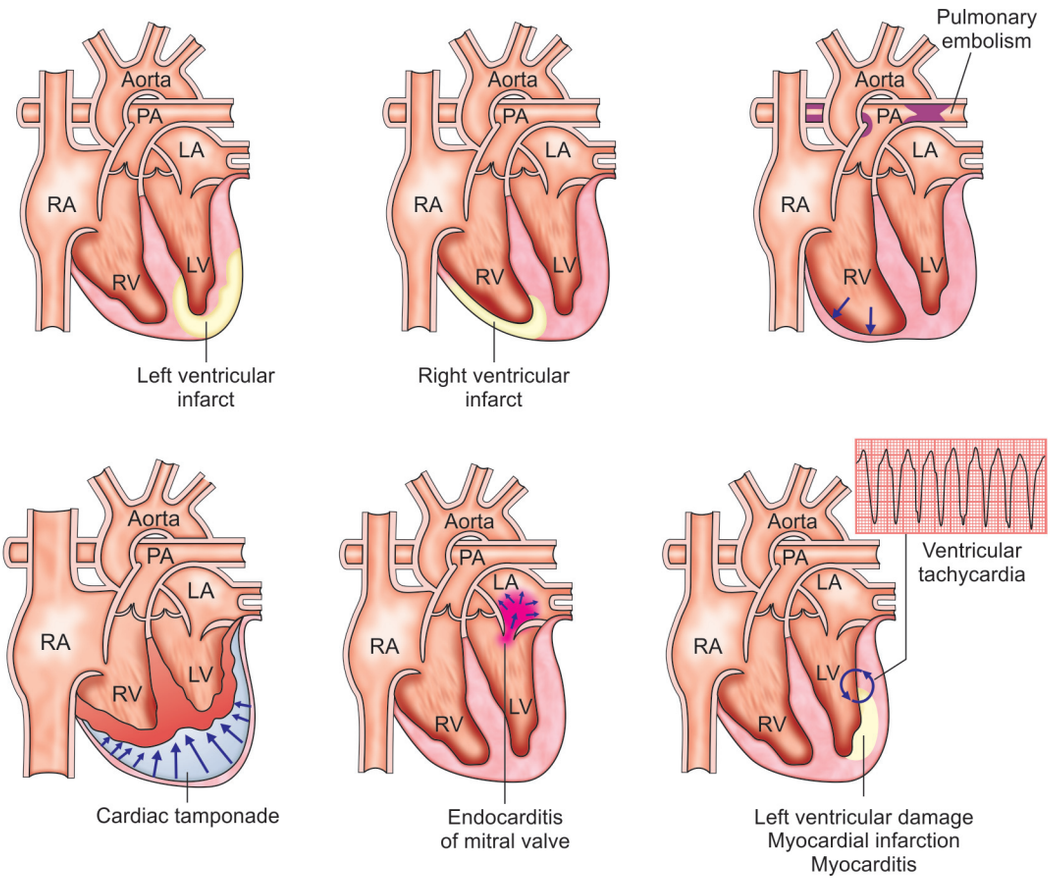

Fig. 21.4: Various causes of cardiogenic shock

Table 21.2: Causes of hypotension among patients with inferior myocardial infarction

Severe right ventricular infarction
Bradyarrythmia
Acute severe mitral regurgitation
Prior myocardial infarction
Left ventricular septal rupture
Bezold-Jarisch reflex

Systemic Inflammatory Response Syndrome

- Acute coronary syndrome
- Aortic regurgitation
- Dilated cardiomyopathy
- Restrictive cardiomyopathy
- Congestive heart failure and pulmonary edema
- Mitral regurgitation
- Pericarditis and cardiac tamponade
- Hypovolemic shock
- Papillary muscle rupture
- Acute valvular dysfunction

Right Ventricular Infarction

Right ventricular infarction occurs in up to 30% of patients with inferior myocardial infarction (MI) and becomes hemodynamically unstable in 10% of these patients. The diagnosis is made by identifying an ST-segment elevation in the right precordial leads (V3 or V4 R) and/or typical hemodynamic findings after right heart catheterization. These are elevated right atrial and right ventricular end-diastolic pressures with normal to low pulmonary artery wedge pressure and low cardiac output.

Echocardiography findings can also be very helpful in the diagnosis of right ventricular infarction. Patients with cardiogenic shock due to this condition have a better prognosis than do patients when compared to those with cardiogenic shock due to left ventricular systolic failure.

Regarding the management of cardiogenic shock due to right ventricular infarction, supportive therapy begins with the restoration and maintenance of right ventricular preload with fluid administration. However, excessive fluid resuscitation may compromise left ventricular filling by introducing an interventricular septal shift.

Inotropic therapy with dobutamine may be effective in increasing cardiac output in patients with right ventricular infarction. Maintenance of systemic arterial pressure in order to maintain adequate coronary artery perfusion may require vasoconstricting agents, such as norepinephrine. In unstable patients, an intra-aortic balloon pump (IABP) may be useful for ensuring adequate blood supply to the already compromised right ventricle.

Revascularization of the occluded coronary artery, preferably by percutaneous transluminal coronary angioplasty (PTCA), is crucial for management and has shown to dramatically improve outcome.

Acute Mitral Regurgitation

Acute mitral regurgitation (Fig. 21.5) is usually associated with inferior MI due to ischemia or infarction of the papillary muscle. It occurs in approximately 1% of MIs, and posteromedial papillary muscle is involved more frequently than anterolateral muscle. Acute mitral regurgitation usually happens 2–7 days following acute MI and manifests with an abrupt onset of pulmonary edema, hypotension, and cardiogenic shock.

Echocardiography findings are extremely useful in making a diagnosis. The two-dimensional (2-D) echocardiographic image shows the malfunctioning mitral valve, and findings from a Doppler study can be used to document the severity of mitral regurgitation. Right heart catheterization is often required for stabilizing the patient. Tall V waves identified on pulmonary arterial and wedge pressure waveforms indicate acute mitral regurgitation. However, the diagnosis must be confirmed based on echocardiography or left ventriculography findings before definitive therapy or surgery is initiated.

Hemodynamic stabilization by reducing afterload, either with nitroprusside or an IABP, is often instituted. Definitive therapy requires revascularization, if ischemia is present, and/or surgical valve repair or replacement, if a structural valvular lesion is present. The mortality rate in the presurgical era was 50% in the first 24 hours, with a 2-month survival rate of 6%.

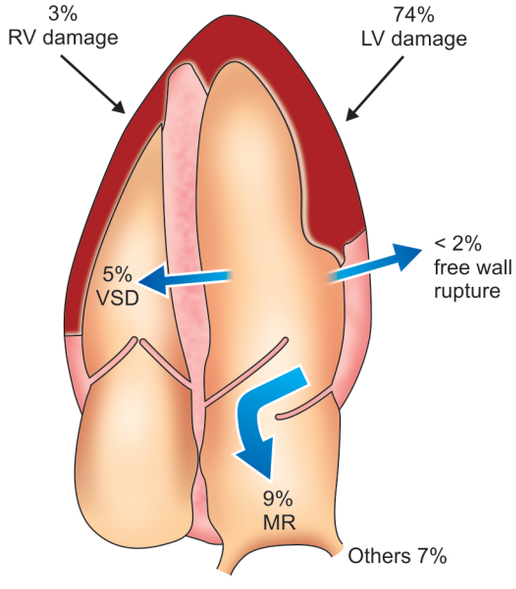

Fig. 21.5: Apical four-chamber echo view with relative incidence of the mechanisms responsible for cardiogenic shock in the SHOCK 8 and MILIS 4 registeries (MR=mitral regurgitation; VSD=ventricular septal defect)

Cardiac Rupture

Rupture of the free wall of the left ventricle occurs within 2 weeks of the MI and may occur within the first 24 hours. The rupture may involve the anterior, posterior, or lateral wall of the ventricle.

Cardiac rupture often presents as sudden cardiac death. Premortem symptoms include chest pain, agitation, tachycardia, and hypotension. This diagnosis should be considered in patients with electromechanical dissociation who have a history of anginal pain. Patients rarely, if ever, survive cardiac rupture.

Ventricular Septal Rupture

Approximately 1–3% of acute MIs are associated with ventricular septal rupture. Most septal ruptures occur within the week following MI. Patients with acute ventricular septal rupture develop acute heart failure and/or cardiogenic shock, with physical findings of a harsh holosystolic murmur and left parasternal thrill.

A left-to-right intracardiac shunt, as demonstrated by a step-up (>5% increase in oxygen saturation) between the right atrium and right ventricle, confirms the diagnosis. Alternatively, 2-D and Doppler echocardiographic findings can be used to identify the location and severity of the left-to-right shunt.

Rapid stabilization using an IABP and pharmacologic measures, followed by emergent surgical repair, is lifesaving. The timing of surgical intervention is controversial, but most experts suggest operative repair within 48 hours of the rupture.

Ventricular septal rupture portends a poor prognosis unless management is aggressive. Immediate surgical repair of patients with ventricular septal rupture is reported to be associated with survival rates of 42–75%; therefore, prompt surgical therapy is imperative as soon as possible after the diagnosis of ventricular septal rupture is confirmed.

Reversible Myocardial Dysfunction

Other causes of severe, reversible myocardial dysfunction are sepsis-associated myocardial depression, myocardial depression following cardiopulmonary bypass, and inflammatory myocarditis. In older literature, this presentation is often referred to as cold septic shock. In these situations, myocardial dysfunction occurs from the effects of inflammatory cytokines, such as tumor necrosis factor and interleukin 1.

Myocardial dysfunction may vary from mild to severe and may lead to cardiogenic shock. For patients in cardiogenic shock, cardiovascular support with inotropic agents may be required until recovery, which generally occurs after the underlying disease process resolves.

DIFFERENTIAL DIAGNOSES

- Myocardial infarction
- Myocardial ischemia
- Myocardial rupture

- Myocarditis
- Pulmonary edema, cardiogenic
- Pulmonary embolism
- Sepsis, bacterial
- Septic shock
- Shock, distributive
- Shock, hemorrhagic

LABORATORY STUDIES

Biochemical Profile

Measurement of routine biochemical parameters, such as electrolytes, renal function (e.g. urea and creatinine), and liver function tests, [e.g. bilirubin, aspartate aminotransferase, alanine aminotransferase, lactate dehydrogenase (LDH)], are useful for assessing proper functioning of vital organs.

CBC Count

A complete blood count (CBC) is generally helpful to exclude anemia. A high white blood cell (WBC) count may indicate an underlying infection, and the platelet count may be low because of coagulopathy related to sepsis.

Cardiac Enzymes

The diagnosis of acute myocardial infarction (MI) is aided by a variety of serum markers, which include creatine kinase and its subclasses, troponin, myoglobin, and LDH. The value for the isoenzyme of creatine kinase with muscle and blood subunits is most specific but may be falsely elevated in persons with myopathy, hypothyroidism, renal failure, or skeletal muscle injury.

The rapid release and metabolism of myoglobin occurs in persons with MI. A 4-fold rise of myoglobin over 2 hours appears to be a test result that is sensitive for MI. The serum LDH value increases approximately 10 hours after the onset of MI, peaks at 24–48 hours, and gradually returns to normal in 6–8 days. The LDH fraction 1 isoenzyme is primarily released by the heart but also may come from the kidneys, stomach, pancreas, and red blood cells.

Troponins

Cardiac troponins T and I are widely used for the diagnosis of myocardial injury. Troponin elevation in the absence of clinical evidence of ischemia should prompt a search for other causes of cardiac damage, such as myocarditis.

Troponin I and T can be detected in serum within the first few hours after onset of acute MI. Troponin levels peak at 14 hours after acute MI, peak again several days later (biphasic peak), and remain abnormal for 10 days. This characteristic could make troponin T (in combination with CK-MB) useful for retrospective diagnosis of acute MI in patients who seek care very late. Troponin T is an independent prognostic indicator of adverse outcomes and can be used as a patient risk-stratifying tool in patients with unstable angina or non-Q-wave MI.

Arterial Blood Gases

Arterial blood gas values indicate overall acid-base homeostasis and the level of arterial blood oxygenation. (Acidosis can have a particularly deleterious effect on myocardial function.) A base deficit elevation (reference range is +3 to –3 mmol/L) correlates with the occurrence and severity of shock. A base deficit is also an important marker to follow during resuscitation of a patient from shock.

Lactate

An elevated serum lactate level is an indicator of shock. Serial lactate measurements are useful markers of hypoperfusion and are also used as indicators of prognosis. Elevated lactate values in a patient with signs of hypoperfusion indicate a poor prognosis; rising lactate values during resuscitation portend a very high mortality rate.

Brain Natriuretic Peptide

Brain natriuretic peptide (BNP) may be useful as an indicator of congestive heart failure and as an independent prognostic indicator of survival. A low BNP level may effectively rule out cardiogenic shock in the setting of hypotension; however, an elevated BNP level does not rule in the disease.

IMAGING STUDIES

Chest Radiography

Chest radiographic findings (Figs 21.6 and 21.7) are useful for excluding other causes of shock or chest pain. A widened mediastinum may indicate aortic dissection. Tension pneumothorax or pneumomediastinum readily



Fig. 21.6: This anteroposterior view chest radiograph shows a massive bottle-shaped heart and conspicuous absence of pulmonary vascular congestion in patient with cardiac tamponade



Fig. 21.7: Chest X-ray PA view showing cardiogenic pulmonary edema in a butterfly distribution due to left ventricular failure. It also shows large perihilar opacities in patient with enlarged cardiac silhouette

detected on radiographic films may manifest as low-output shock.

Most patients with established cardiogenic shock exhibit findings of left ventricular failure, the radiologic features of which include pulmonary vascular redistribution, interstitial pulmonary edema, enlarged hilar shadows, the presence of Kerley B lines, cardiomegaly, and bilateral pleural effusions. Alveolar edema manifests as bilateral perihilar opacities in a so-called butterfly distribution.

Electrocardiography

Acute myocardial ischemia is diagnosed based on the presence of ST-segment elevation, ST-segment depression, or Q-waves. T-wave inversion, although a less sensitive finding, may also be seen in persons with myocardial ischemia. An ECG with right-sided chest leads may document right ventricular infarction and may be prognostically, as well as diagnostically, useful.

Perform electrocardiography immediately to help diagnose myocardial infarction (MI) and/or myocardial ischemia. A normal ECG, however, does not rule out the possibility of acute MI (Figs 21.8–21.15).

Ultrasonography

Ultrasonography can be used to guide fluid management. In the spontaneously breathing patient, inferior vena cava (IVC) collapse with respiration suggests dehydration, whereas a lack of IVC collapse suggests intravascular euvolemia.

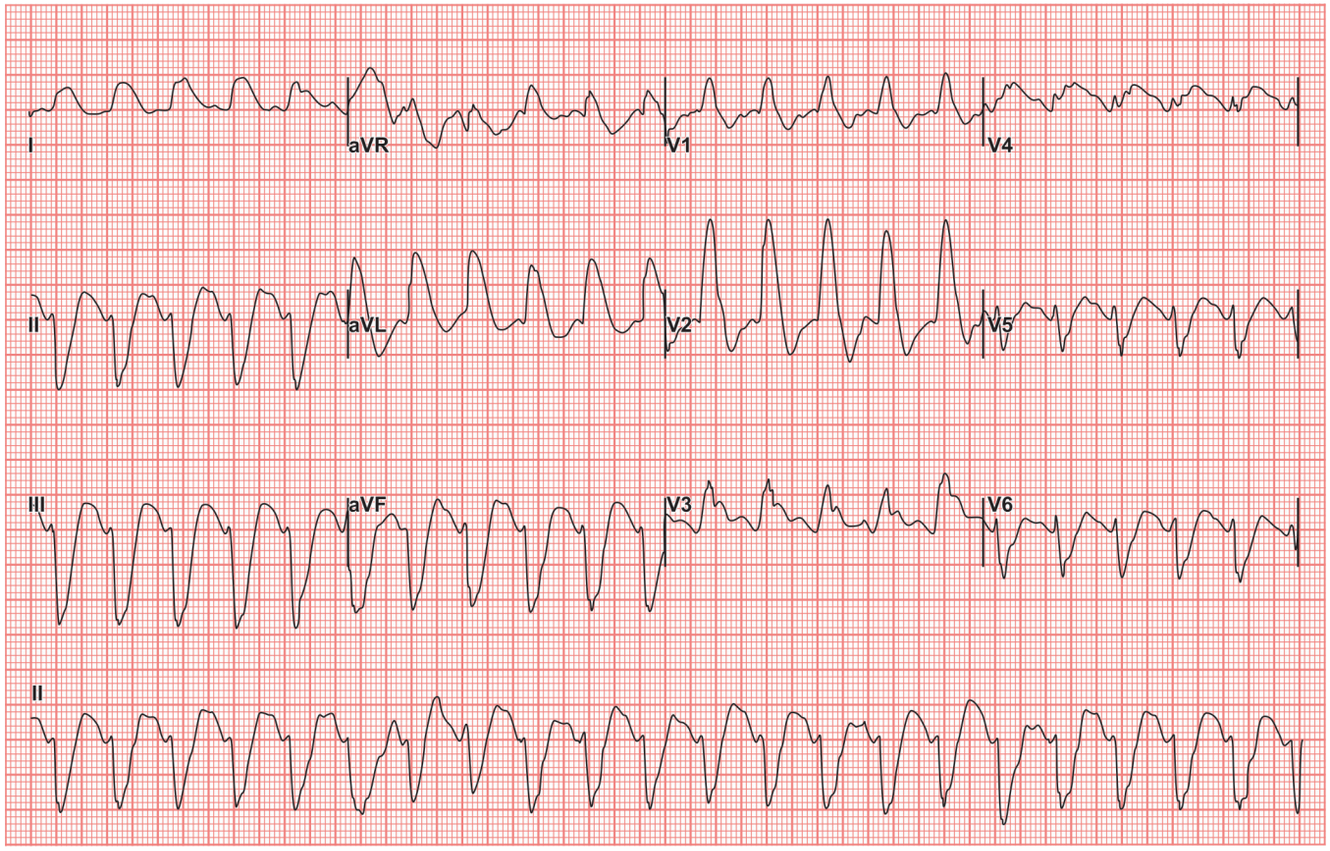

Fig. 21.8: A 51-year-male complained of chest pain, followed by cardiac arrest. He was resuscitated and brought to the ED where his ECG showed wide complex tachycardia, RBBB + LAFB, and massive ST elevation. He was in cardiogenic shock

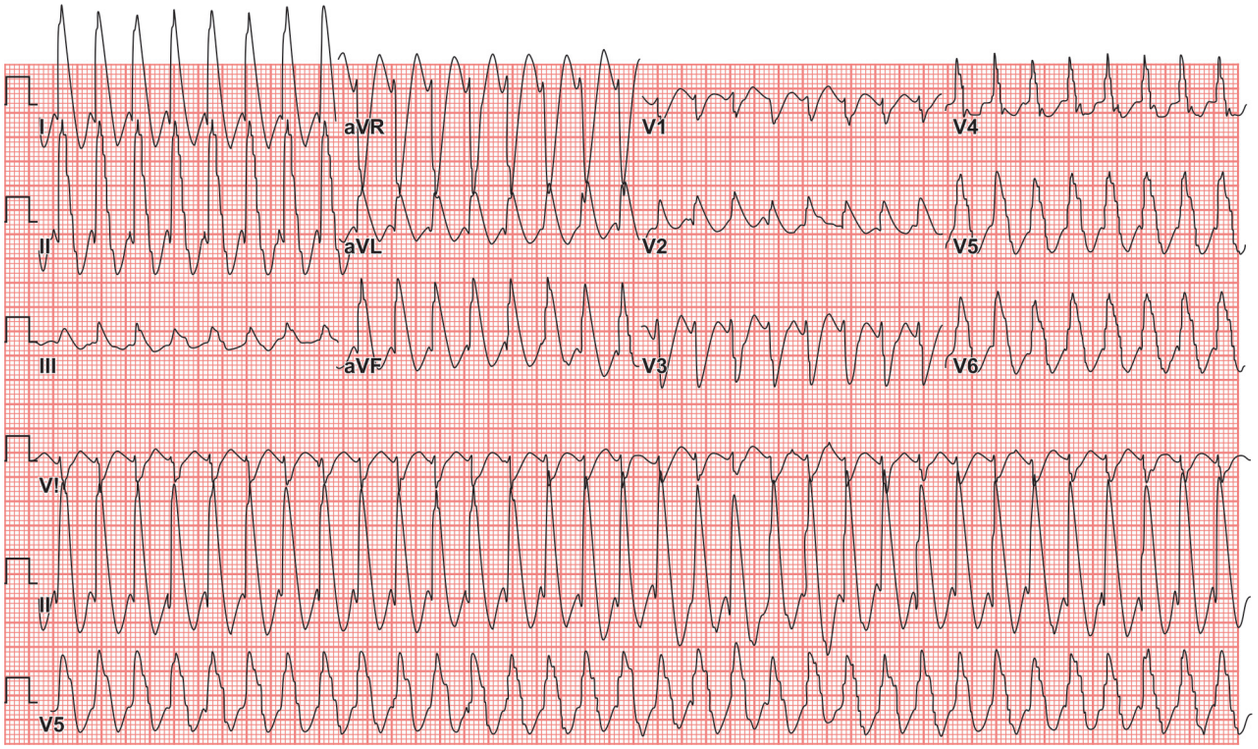

Fig. 21.9: ECG showed ventricular tachycardia in a 70-year-old man, admitted into emergency department with cardiogenic preshocked condition



Fig. 21.10: ECG trace showing acute myocardial infarction with complete heart block

MRI/CT SCANS (Fig. 21.16)

Coronary Artery Angiography

Coronary angiography is urgently indicated in patients with myocardial ischemia or myocardial infarction (MI) who also develop cardiogenic shock. Angiography is required to help assess the anatomy of the coronary arteries and the need for urgent revascularization.

Coronary angiography findings often demonstrate multivessel coronary artery disease in persons with cardiogenic shock. In these patients, a compensatory hyperkinesis cannot occur in the noninfarct territory, because of the severe coronary artery atherosclerosis.

The most common cause of cardiogenic shock is extensive MI, although a smaller infarction in a previously compromised left ventricle also may precipitate shock. Following MI, large areas of nonfunctional, but viable, myocardium (hibernating myocardium) can also cause or contribute to cardiogenic shock.

Echocardiography

Echocardiography should be performed early to establish the cause of cardiogenic shock. Echocardiography provides information on global and regional systolic function and on diastolic dysfunction. Echocardiography findings can also lead to a rapid diagnosis of mechanical causes of shock, such as acute ventricular septal defect, free myocardial wall rupture, pericardial tamponade, and papillary muscle rupture causing acute myocardial regurgitation (Figs. 21.17–21.26).

In addition, an echocardiogram may reveal akinetic or dyskinetic areas of ventricular wall motion or may demonstrate valvular dysfunction. Ejection fraction may be estimated as well (although results from the SHOCK trial indicated that left ventricular ejection fraction is not always depressed in the setting of cardiogenic shock). If a hyperdynamic left ventricle is found, the echocardiogram may suggest other causes of shock such as sepsis or anemia.

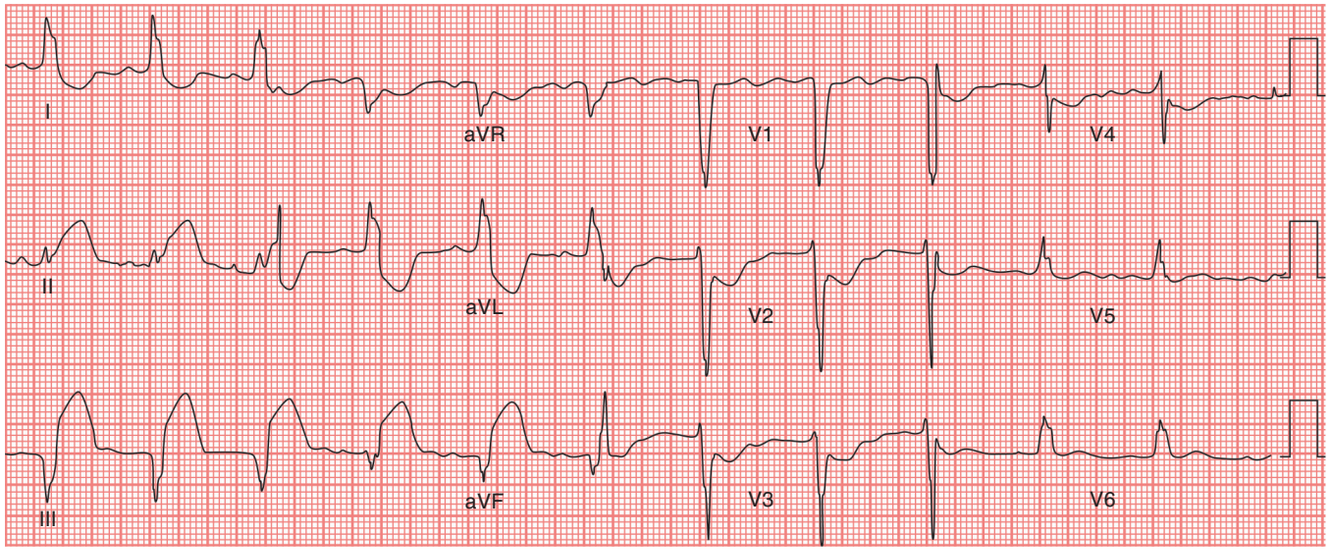

Fig. 21.11: Electrocardiogram displays all of the criteria for the diagnosis of acute myocardial infarction (MI) in the setting of LBBB. ST-segment elevation greater than 1 mm, concordant with QRS in lead II (5 points); ST-segment depression greater than 1 mm in lead V2 and V3 (3 points); and ST-segment elevation greater than 5 mm, discordant with QRS in leads III and VF (2 points). A score of 10 points indicates an extremely high likelihood of inferior MI (From Sgarbossa EB, Wagfier G, 1997, with permission)

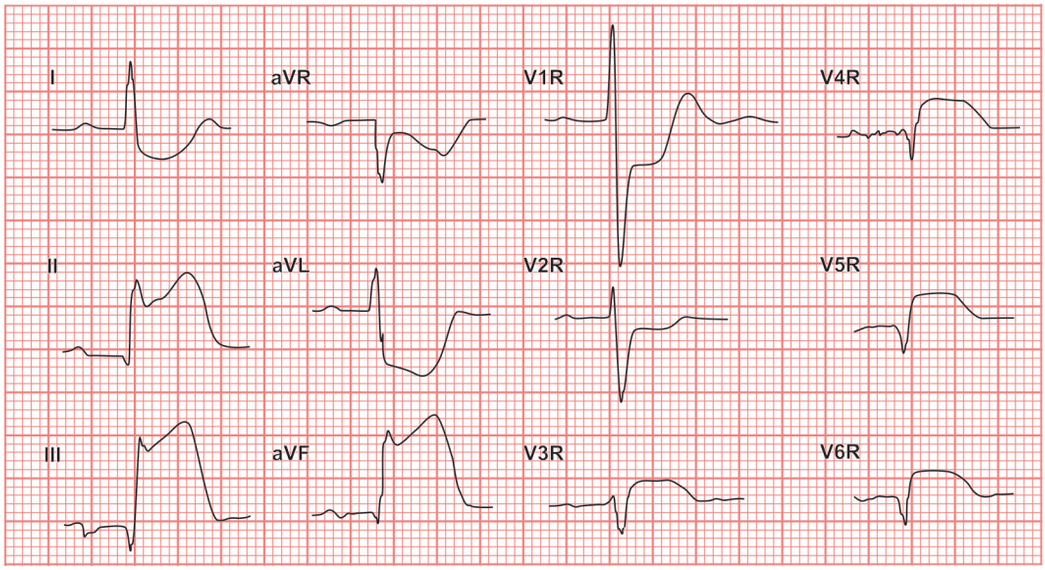

Fig. 21.12: Standard 12-lead electrocardiogram. (A) Showed marked ST-segment elevation in leads V4R, V5R, V6R, and ST-segment elevation in leads II, III, and aVF in right ventricular infarction

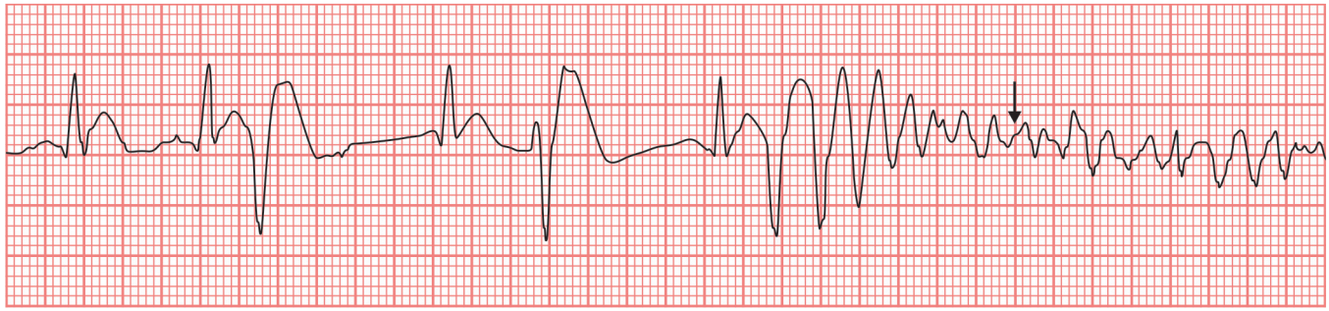

Fig. 21.13: ECG trace showing R on T phenomenon (arrow) giving rise to ventricular fibrillation (arrow)

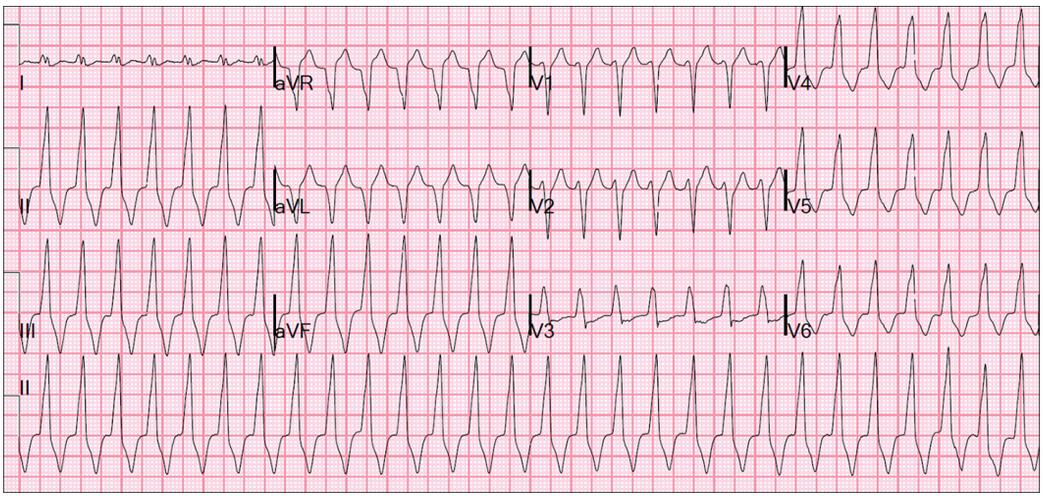

Fig. 21.14: Middle-aged male patient who was brought into hospital with shock showed wide complex regular tachycardia at a rate of 170

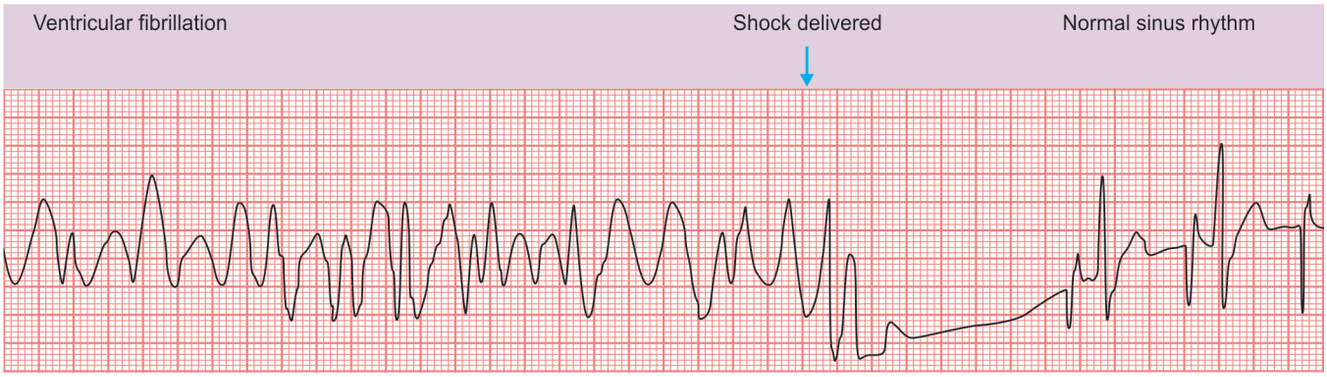

Fig. 21.15: An example of delivery of implantable cardioverter-defibrillator (ICD) shock therapy. The device senses ventricular electrograms. This sensed electrical activity satisfies the criteria of the device's detection algorithm and a 34 J shock is delivered (thick arrow). This returns the patient to (initially) a ventricular paced rhythm with normal sinus rhythm following shortly

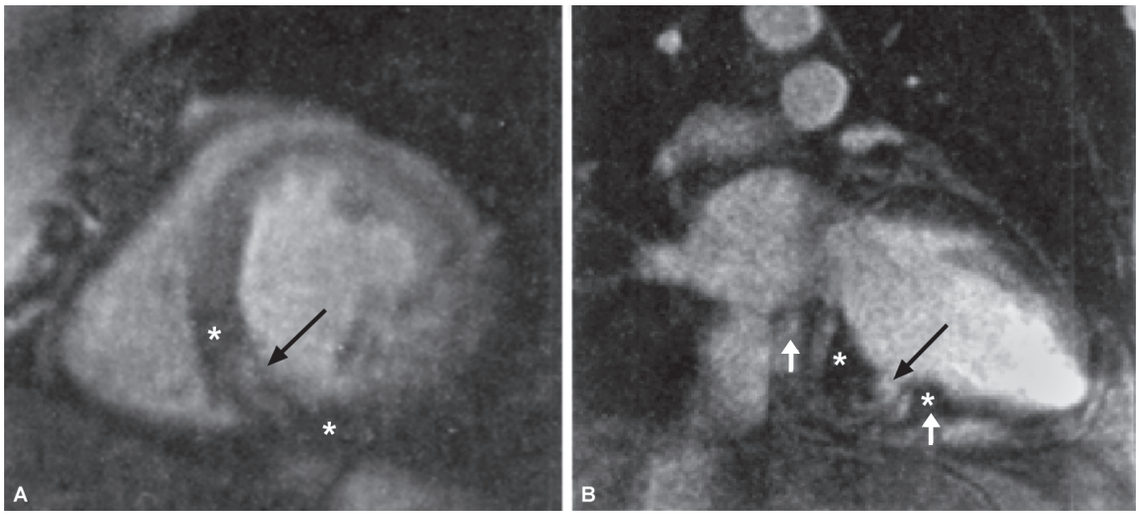

Fig. 21.16: (A) Contrast enhanced dynamic myocardial perfusion imaging at rest demonstrated contrast flow from the cavity of the LV into the myocardium near the basal septum (arrows). The contrast material penetrated about three quarters of the myocardial thickness, thus showing impending myocardial rupture (using late enhancement technique 10 minutes after application of contrast agent,an extended transmural inferior infarction could be seen in the long axis view. (B) Left ventricular angiogram in a LAO 60° position demonstrated an inferiorly located ventricular septal defect (white arrow)

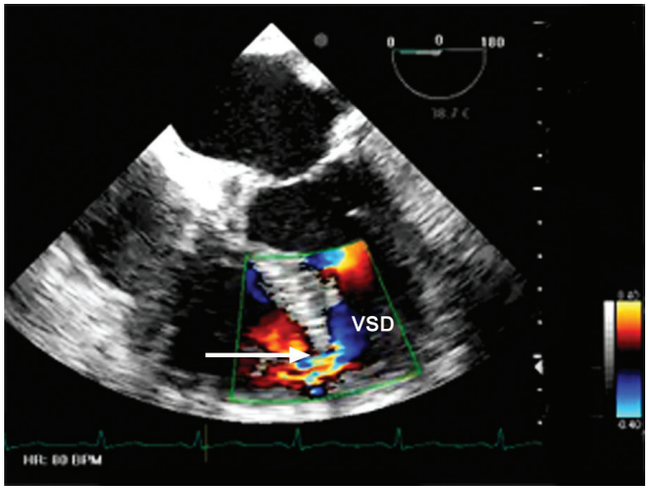

Fig. 21.17: TEE color scan in four-chamber view showing post-MI VSD (arrow). The defect was repaired surgically

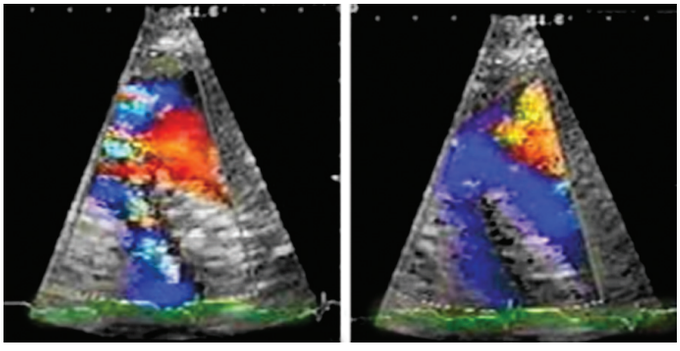

Fig. 21.18: An 80-year-old woman presented with chest pain and anterior AMI. An apical holosystolic murmur was heard and color doppler examination showed systolic/diastolic left to right shunt. The patient developed cardiogenic shock and died before cardiac catheterization

Pleural sliding in an intercostal space demonstrating increased lung comet artifacts suggestive of pulmonary edema.

Invasive Hemodynamic Monitoring

Invasive hemodynamic monitoring **(Swan-Ganz catheterization)** (Figs 21.27 and 21.28) is very useful for helping exclude other causes and types of shock, e.g. volume depletion, obstructive shock, and septic shock.

The hemodynamic measurements of cardiogenic shock are a pulmonary capillary wedge pressure (PCWP) of greater than 15 mmHg and a cardiac index of less than 2.2 L/min/m^2.

The presence of large V waves on the PCWP tracing suggests severe mitral regurgitation, while a step-up in oxygen saturation between the right atrium and the right ventricle is diagnostic of ventricular septal rupture.

High right-sided filling pressures in the absence of an elevated PCWP, when accompanied by electrocardiographic criteria, indicate right ventricular infarction.

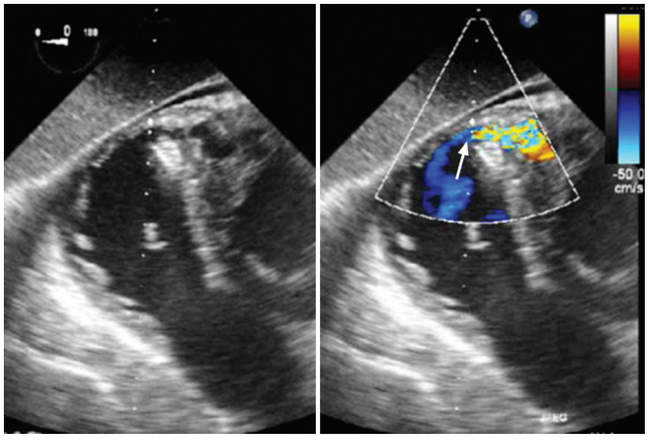

Fig. 21.19: The transgastric view after the first closure device implantation with significant residual VSD blood flow (arrow)

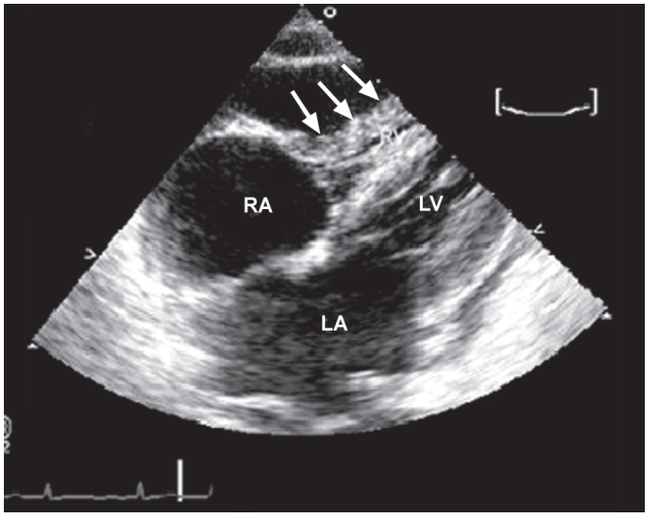

Fig. 21.20: Early diastolic collapse of right ventricular free wall (subcostal view) in cardiac tamponade (white arrows)

APPROACH CONSIDERATIONS

Cardiogenic shock is an emergency requiring immediate resuscitative therapy before shock irreversibly damages vital organs. The key to a good outcome in patients with cardiogenic shock is an organized approach, with rapid diagnosis and prompt initiation of pharmacologic therapy to maintain blood pressure and cardiac output.

All patients require admission to an intensive care setting, which may involve emergent transfer to the cardiac catheterization suite, critical care transport to a tertiary care center, or internal transfer to the intensive care unit (ICU).

Early and definitive restoration of coronary blood flow is the most important intervention for achieving an improved survival rate. At present, it represents standard therapy for patients with cardiogenic shock due to myocardial ischemia.

Correction of electrolyte and acid-base abnormalities, such as hypokalemia, hypomagnesemia, and acidosis, is essential in cardiogenic shock.

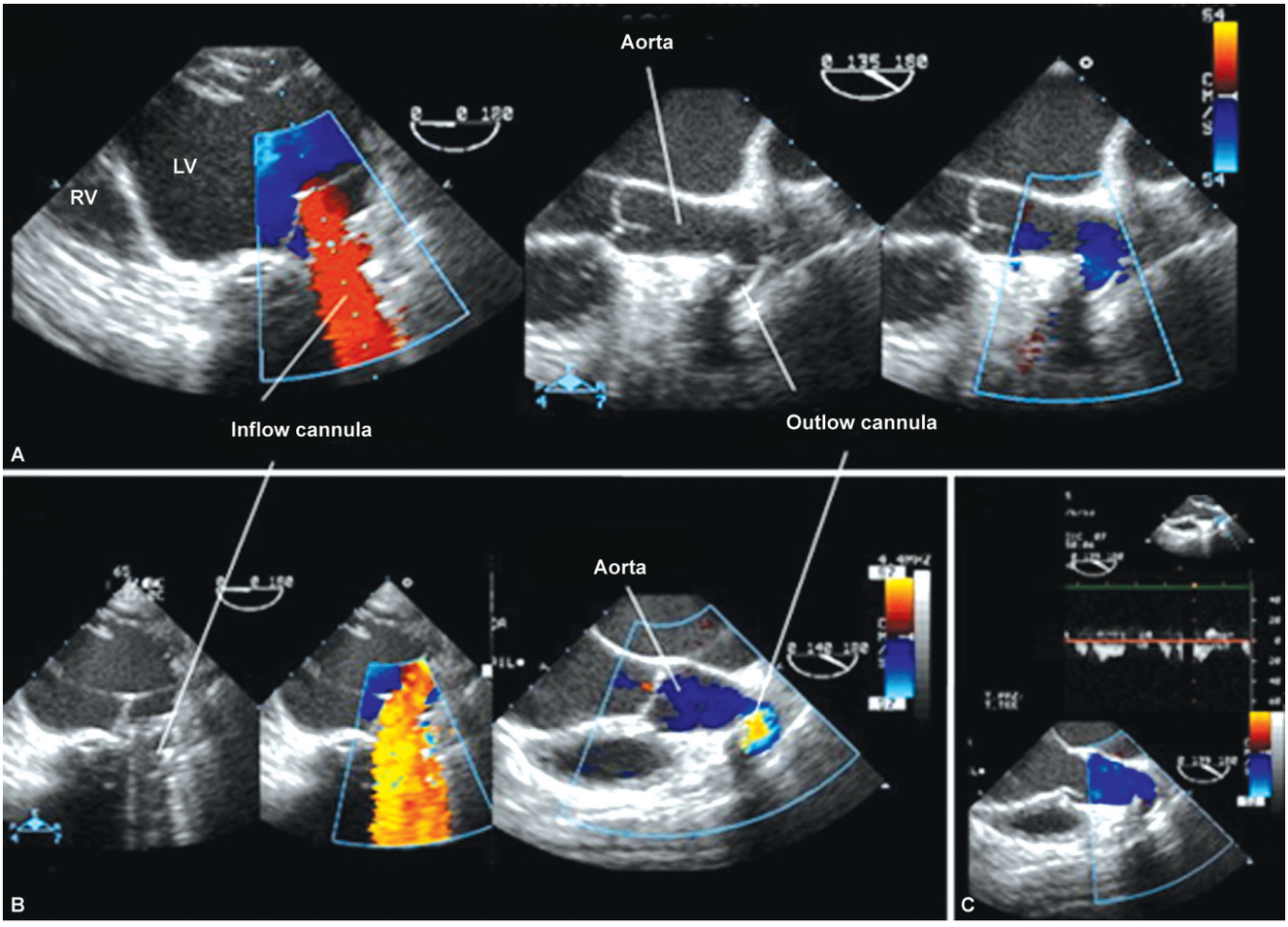

Fig. 21.21: Echocardiography documents a case of pump arrest. (A) Color-Doppler shows a retrograde flow from the outflow cannula visualized by midoesophageal longitudinal view at 135° (right)-through pump-to inflow cannula and left ventricle visualized by midoesophageal four-chamber view (left). (B) In the same patient color-Doppler documents high retrograde flow after v-a ECMO activation with severe LV distension. (C) Color-Doppler and pulsed wave Doppler show the interruption of aorta-to-LV shunt after LVAD outflow cannula clamping. LV=left ventricle; RV=right ventricle

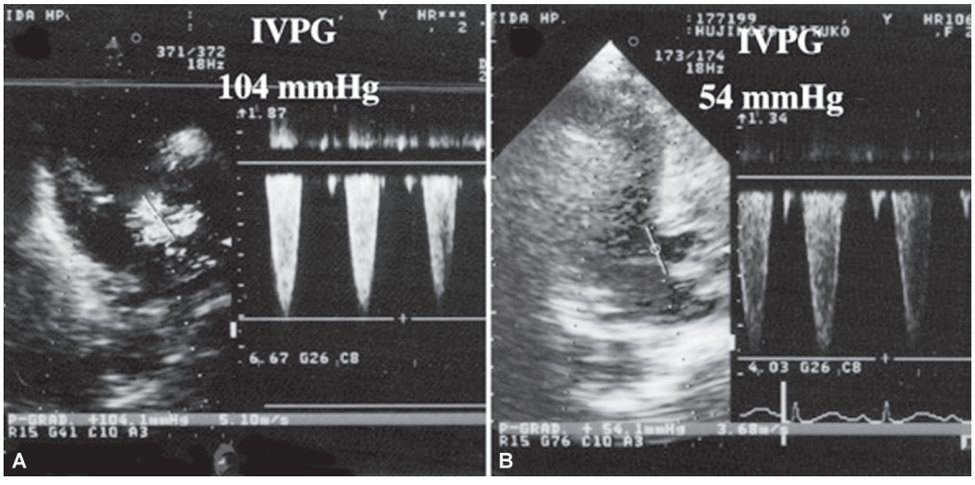

Fig. 21.22: (A) A Doppler echocardiogram on admission showed an intraventricular pressure gradient (IVPG) of 104 mmHg. (B) After cessation of an intravenous administration of dopamine, the IVPG decreased to 54 mmHg

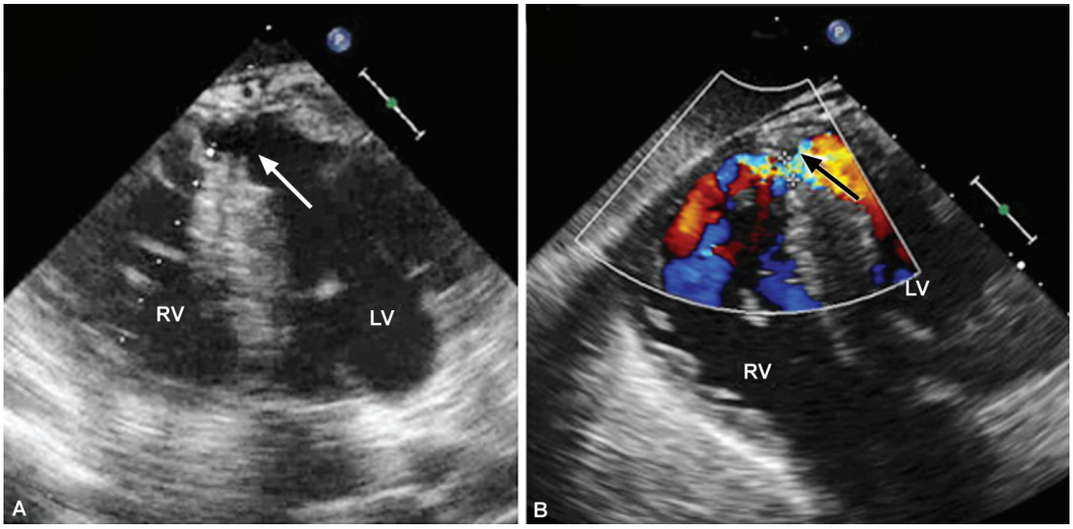

Fig. 21.23: Transgastric transesophageal echocardiographic images showing (A) left ventricular aneurysm (arrow) with (B) the VSD (arrow) after MI. RV=right ventricle; LV=left ventricle

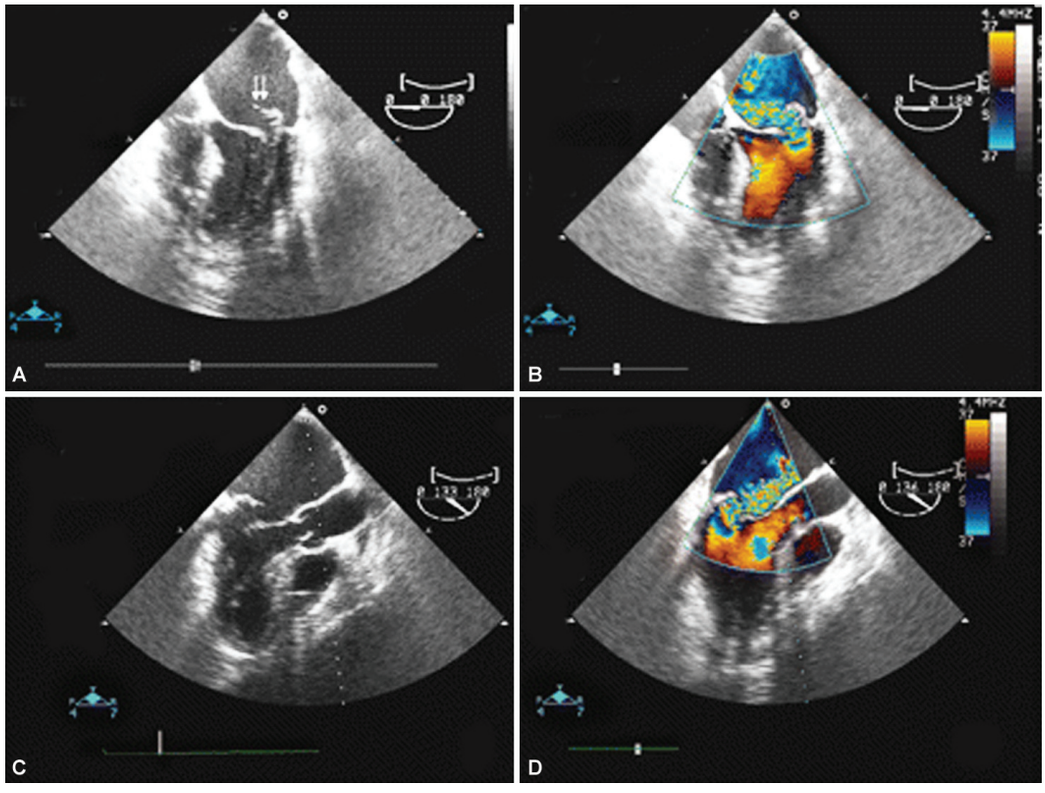

Fig. 21.24: (A) Four-chamber transoesophageal echocardiography (TOE) view showing the presence of chordal rupture (arrows) with a mitral leaflet prolapsing into the left atrium. (B) Four-chamber view with color-Doppler. An eccentric jet of mitral regurgitation can be observed. (C, D) Long axis TOE view showing the jet of severe mitral insufficiency directed towards the anterior portion of the left atrium

Cardiogenic shock may be prevented with early revascularization in patients with myocardial infarction (MI) and with required intervention in patients with structural heart disease.

PROCEDURES

Placement of a central line may facilitate volume resuscitation, provide vascular access for multiple infusions, and allow invasive monitoring of central venous pressure.

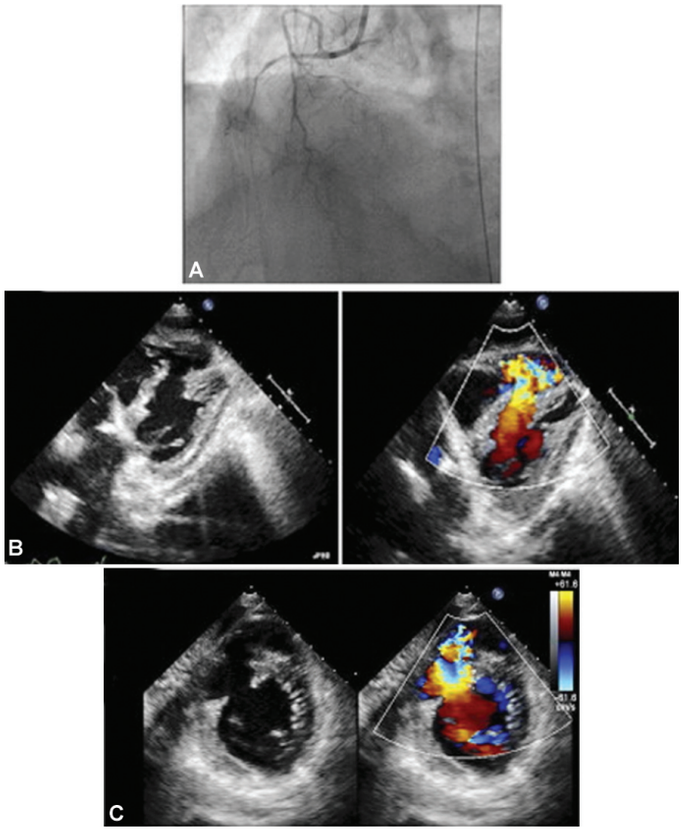

Fig. 21.25: Coronary angiography of RCA and echocardiogram in an elderly female ex-smoker with ventricular septal rupture. (A) Coronary angiogram of right coronary artery (RCA) showing proximal total occlusion. (B) Subcostal view on 2-dimensional electrocardiography. (C) Short axis view of the left ventricle on 2-dimensional echocardiogram, with and without color Doppler, showing large direct ventricular septal rupture

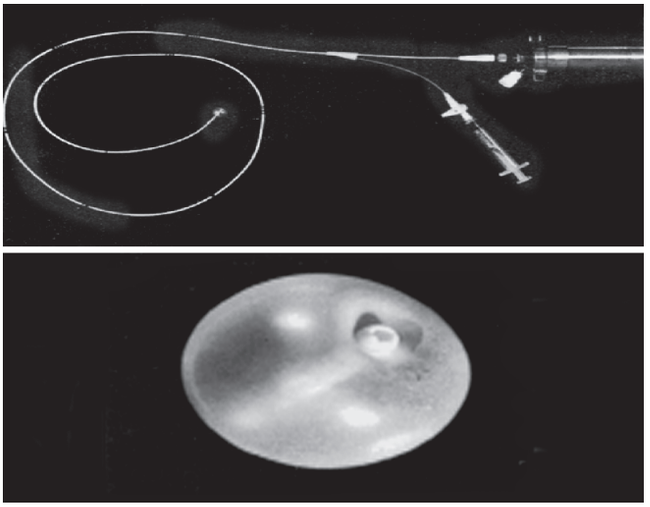

Fig. 21.27: Standard balloon-tipped flow-directed catheter with inflated balloon, closed inflation lumen and a pressure transducer attached to the large lumen. Close-up view of the inflated balloon

Central venous pressure may also be used to guide fluid resuscitation (Figs 21.29–21.33).

Although not necessary for the diagnosis of cardiogenic shock, invasive monitoring with a pulmonary artery catheter may be helpful in guiding fluid resuscitation in situations in which left ventricular preload is difficult to determine.

Pulmonary artery catheter pressure measurements may also be useful in prognosis. Retrospective evaluation of these measurements from the SHOCK trial demonstrated that stroke volume index (SVI) and stroke work index (SWI) vary inversely with mortality.

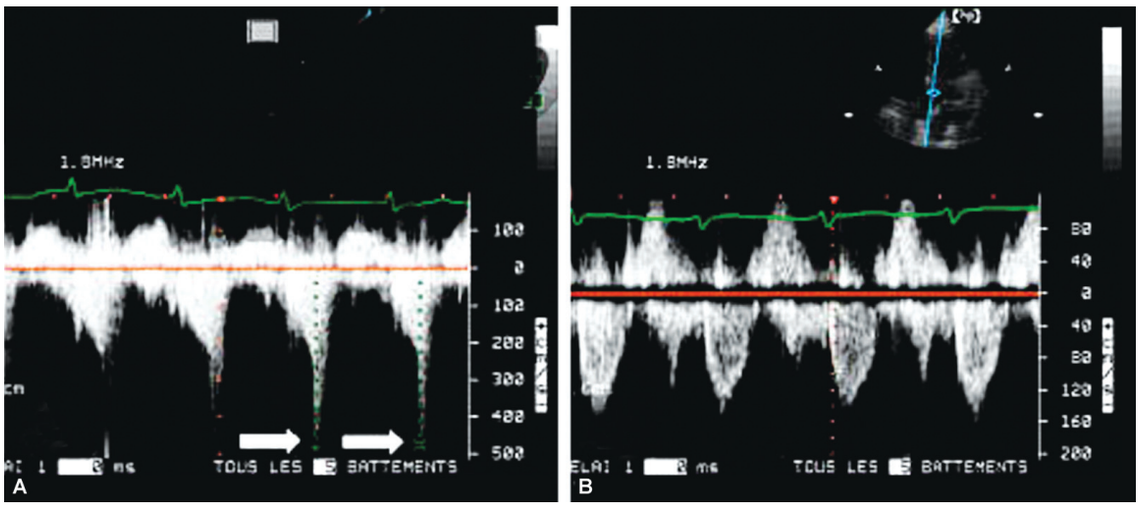

Fig. 21.26: Continuous-wave Doppler findings obtained with a full-feature echocardiographic platform from a ventilated patient receiving high doses of inotropes for a suspected cardiogenic shock after cardiac surgery. (A) Conventional transthoracic echocardiography revealed a systolic left ventricular obstruction with a dynamic pressure gradient up to 94 mmHg, whereas hand-held echocardiography only showed a hyperkinetic left ventricle. (B) The hemodynamics improved after repeated fluid challenges and rapid tapering of positive inotrope doses, as reflected by the absence of Doppler detectable dynamic obstruction

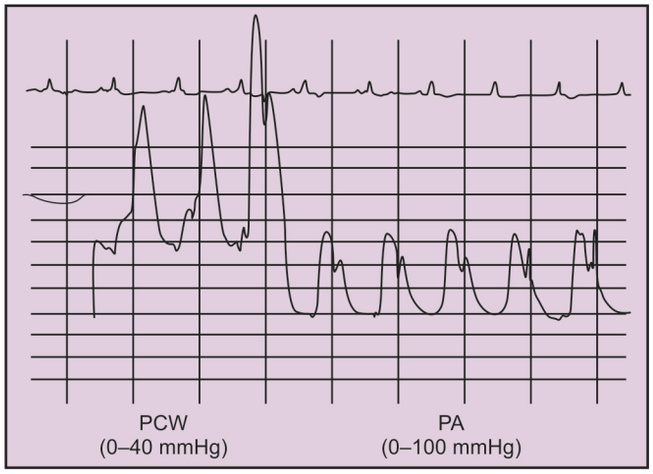

Fig. 21.28: Pressures recorded during insertion of a balloon-tipped flow-directed catheter. RA=right atrial pressure, RV=right ventricular pressure, PA=pulmonary arterial pressure, PCW=pulmonary capillary wedge pressure. The scale at the left calibrates pressure from 0 to 50 mmHg

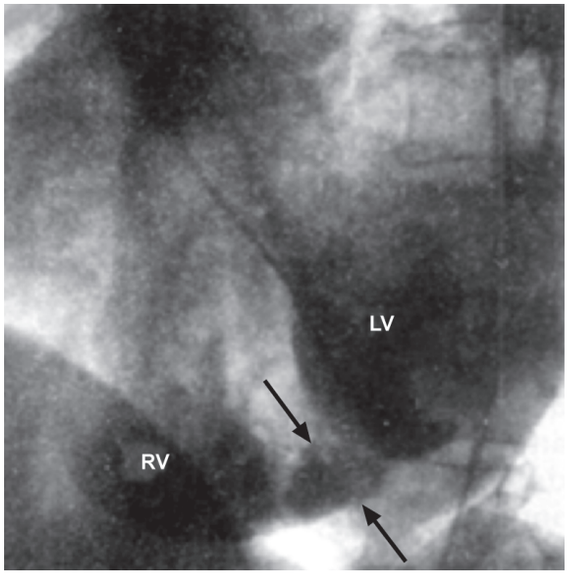

Fig. 21.30: A 63-year-old patient with impending septal ruptue in myocardial infarction by Left ventricular angiogram in a LAO 60° position demonstrated an inferiorly located ventricular septal defect (arrows)

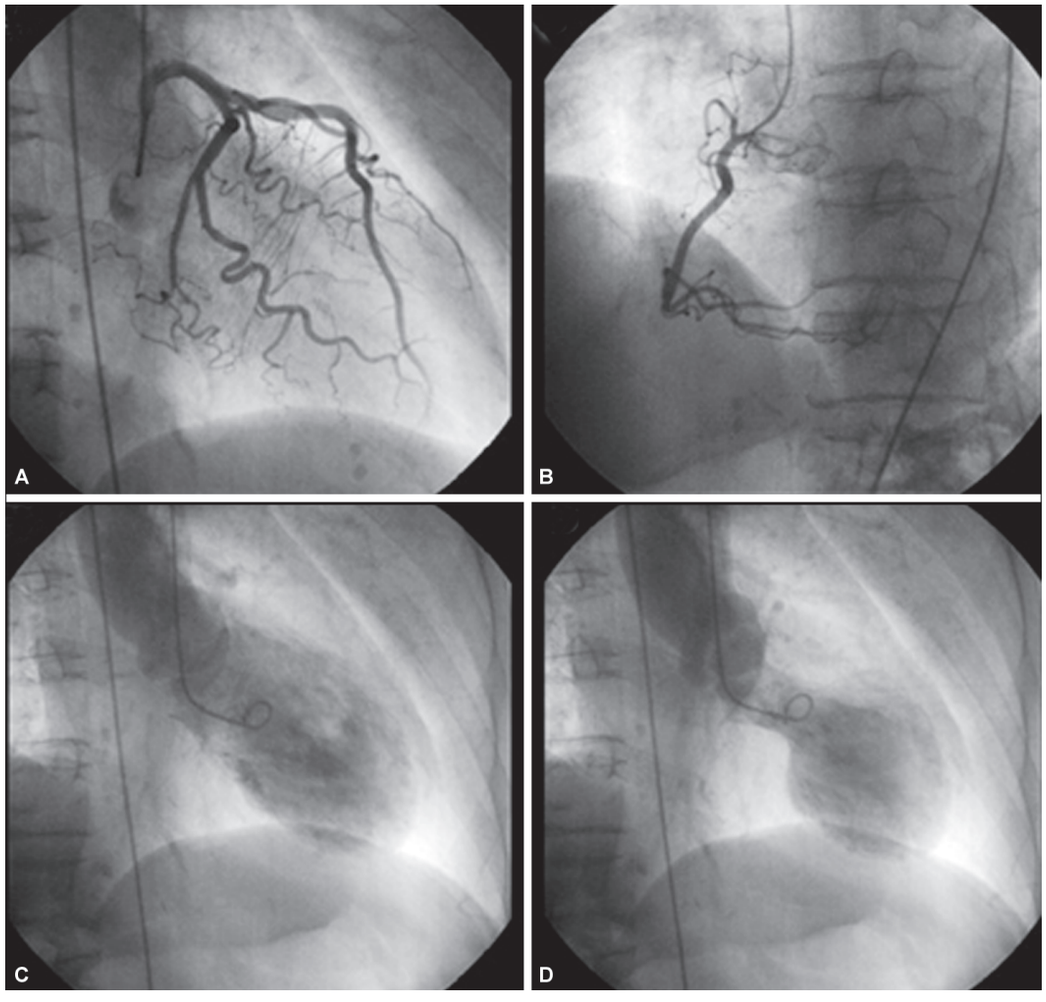

Fig. 21.29: Coronary angiograms showed the intact coronary arteries (A and B), and left ventriculograms showed apical ballooning and excessive hypercontraction of the basal region (C and D) in a 54-years-old male with severe hypotension

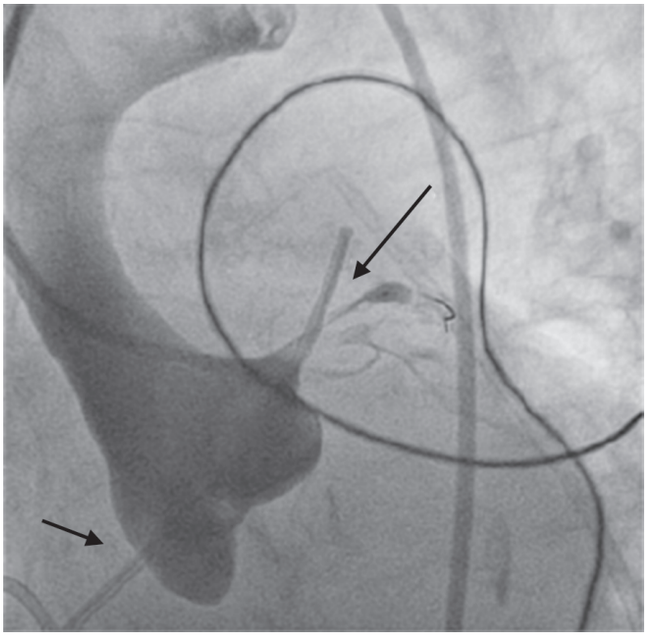

Fig. 21.31: An angiogram showing rupture of left main coronary artery in a 74-year-old male with cardiogenic shock

An arterial line may be placed to provide continuous blood pressure monitoring. This is particularly useful if the patient requires inotropic medications.

An intra-aortic balloon pump may be placed in the emergency department as a bridge to percutaneous coronary intervention (PCI) or coronary artery bypass graft (CABG), to decrease myocardial workload and to improve end-organ perfusion.

PCI and Coronary Artery Bypass

Clinicians should be alert to the fact that the SHOCK trial demonstrated that either PCI or coronary artery bypass is the treatment of choice for cardiogenic shock and that each has been shown to markedly decrease mortality rates at 1 year. PCI should be initiated within 90 minutes of presentation; however, it remains helpful, as an acute intervention, within 12 hours of presentation.

If such a facility is not immediately available, thrombolytics should be considered. However, this treatment is second best. An increased mortality is seen in situations in which thrombolytics are used instead of PCI. This is due to the relative ineffectiveness of the thrombolytic medications to lyse clots in low-blood pressure situations.

Consultations

Consult a cardiologist at the earliest opportunity because his or her insight and expertise may be invaluable for facilitating echocardiographic support, placement of an intra-aortic balloon pump (IABP), and transfer to more definitive care (e.g. cardiac catheterization suite, ICU, operating room). In severe cases, also consider discussing the case with a cardiothoracic surgeon.

Prevention

Although cardiogenic shock is not entirely preventable, measures can be taken to minimize the risk of occurrence, recognize it at earlier stages, and begin corrective therapy more expeditiously. Deterrence and prevention require a high degree of suspicion and heightened awareness.

Care is required in treating patients with acute coronary syndromes who are not yet in cardiogenic shock. Careful use of beta-blockers and ACE inhibitors in these patients is essential to avoid hypotension leading to cardiogenic shock.

Prehospital Care

Prehospital care is aimed at minimizing any further ischemia and shock. All patients require intravenous access, high-flow oxygen administered by mask, and cardiac monitoring.

Twelve-lead electrocardiography performed in the field by appropriately trained paramedics may be useful in decreasing door-to-PCI times and/or time to the administration of thrombolytics because acute ST-segment elevation myocardial infarctions (STEMIs) can be identified earlier. The emergency department (ED) can thus be alerted and may mobilize the appropriate resources.

Inotropic medications should be considered in systems with appropriately trained paramedical personnel.

When clinically necessary, positive pressure ventilation and endotracheal intubation should be performed. Continuous positive airway pressure (CPAP) or bilevel positive airway pressure (BiPAP) support can be considered in appropriately equipped systems.

Resuscitation, Ventilation, and Pharmacologic Intervention

Initial management includes fluid resuscitation to correct hypovolemia and hypotension, unless pulmonary edema is present. Central venous and arterial lines are often required. Swan-Ganz catheterization and continuous percutaneous oximetry are routine.

Oxygenation and airway protection are critical; intubation and mechanical ventilation are commonly required. However, although positive pressure ventilation may improve oxygenation, it may also compromise venous return, preload, to the heart. In any event, the patient should be treated with high-flow oxygen. Studies in patients with acute cardiogenic pulmonary edema have shown noninvasive ventilation to improve hemodynamics and reduce the intubation rate. Mortality is, however, unaffected.

A study by Shin et al. suggested that patients who receive extracorporeal cardiopulmonary resuscitation (CPR) versus conventional CPR for longer than 10 minutes following in-hospital arrest have a greater chance of survival.

All patients with cardiogenic shock require close hemodynamic monitoring, volume support to ensure adequate sufficient preload, and ventilatory support.

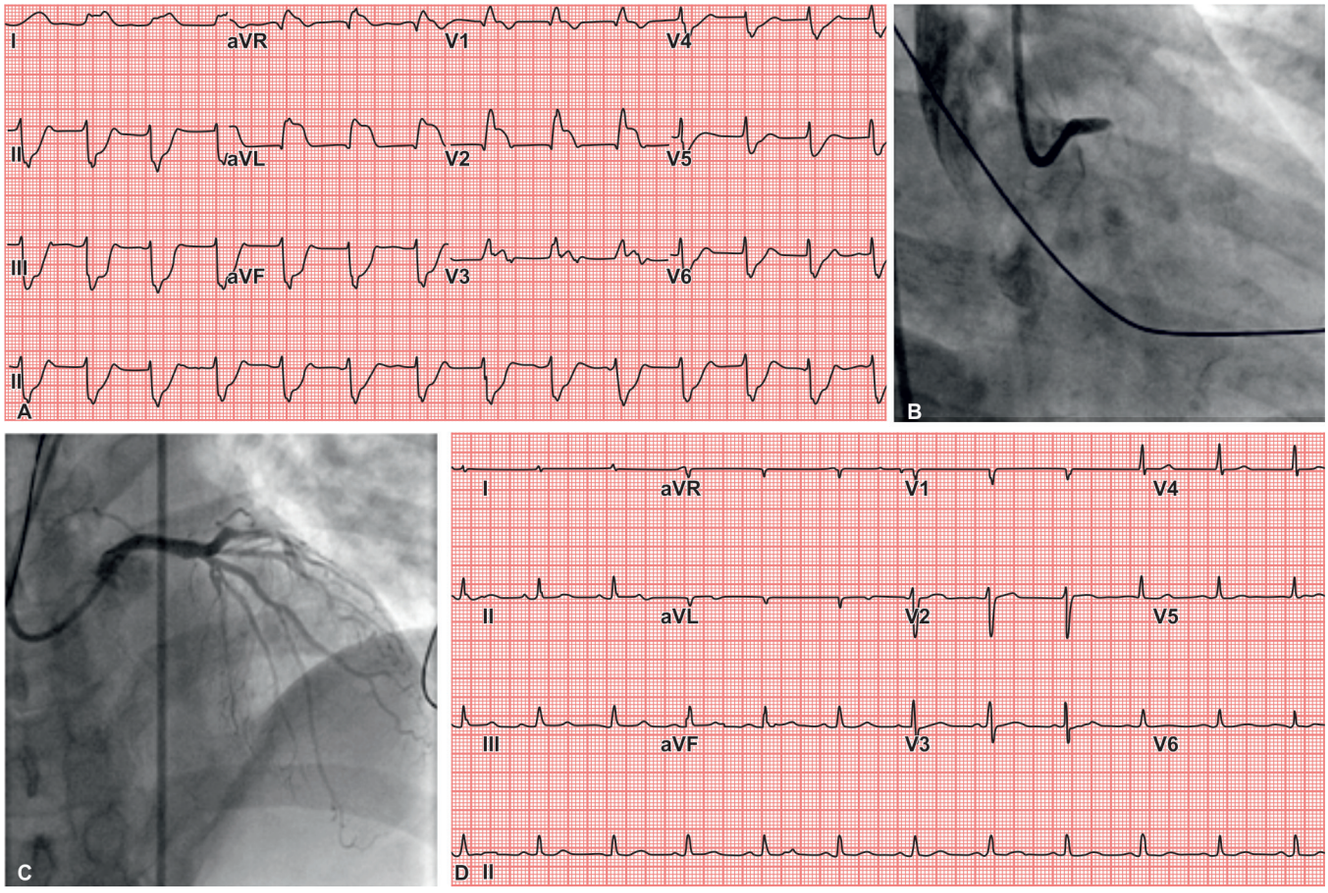

Fig. 21.32: A previously healthy 57-year-old man presented with chest pain that had been ongoing for 50 minutes and had begun while he was playing racquetball. He was conscious and alert, although he was in cardiogenic shock. A 12-lead electrocardiogram showed ST-segment elevation in leads V1, V2, V3, I, aVL, and aVR and ST-segment depression in leads V4, V5, V6, II, III, and aVF, findings suggestive of occlusion of the left main stem of the coronary artery (A). This was confirmed during coronary angiography (B). Prompt revascularization with a stent restored normal anterograde coronary perfusion within 110 minutes after the onset of pain (C) and led to a normal electrocardiogram (D). The creatine kinase level peaked at 1400 U per liter. Hemodynamic support was provided by a percutaneously inserted microaxial-flow pump. The severely impaired left ventricular systolic function and the extensive anterolateral akinesis returned to normal within 4 days. One year later, the patient has had no further ischemic events and remains active

Pharmacologic Therapy

Patients with myocardial infarction (MI) or acute coronary syndrome are given aspirin and heparin. Both of these medications have been shown to be effective in reducing mortality in separate studies. Before initiating therapy, however, care should be taken to ensure that the patient does not have a myocardial wall rupture that is amenable to surgery.

There is no need to start clopidogrel until after angiography, since angiography may demonstrate that there is a need for urgent coronary bypass.

The glycoprotein IIb/IIIa inhibitors improve the outcome of patients with non-ST-segment elevation acute coronary syndrome (NSTACS). They have been found to reduce recurrent MI following percutaneous coronary intervention (PCI) and in cardiogenic shock.

Hemodynamic Support

Dopamine, norepinephrine, and epinephrine are vasoconstricting drugs that help to maintain adequate blood pressure during life-threatening hypotension and help to preserve perfusion pressure for optimizing flow in various organs. The mean blood pressure required for adequate splanchnic and renal perfusion [mean arterial pressure (MAP) of 60 or 65 mmHg] is based on clinical indices of organ function.

In patients with inadequate tissue perfusion and adequate intravascular volume, initiation of inotropic and/or vasopressor drug therapy may be necessary. Dopamine increases myocardial contractility and supports the blood pressure; however, it may increase myocardial oxygen demand. Dobutamine may be preferable if the systolic blood pressure is higher than 80 mmHg; it has the

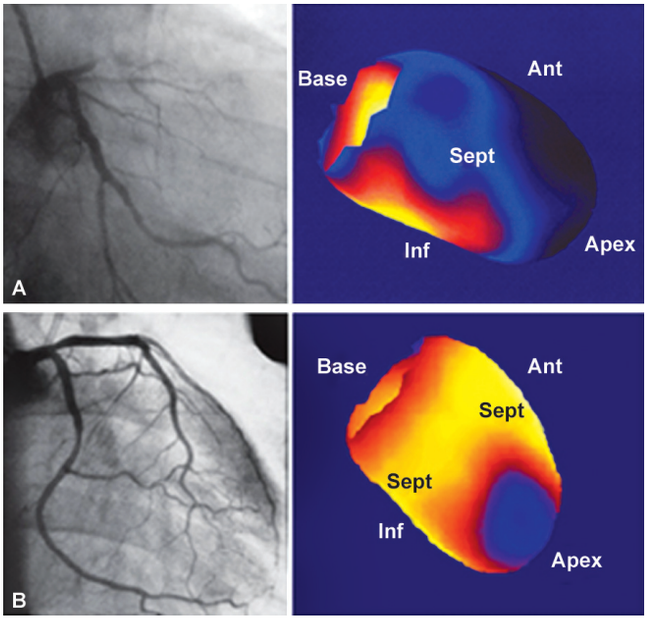

Fig. 21.33: After coronary reperfusion the area of myocardial infarction can be limited, but a much larger territory remains stunned with impaired contractility and compliance through reperfusion injury. (A) A coronary angiogram from a patient with an anterior myocardial infarction and proximally occluded left anterior descending artery (left panel). A 3D MPS that demonstrates a large area of hypoperfusion in the anterior wall, anterior septum, and apex (right panel, blue areas). The inferior wall is perfused normally (yellow/red areas), which corresponds to the area at risk. (B) A coronary angiogram after percutaneous intervention, with stent deployment in the proximal left anterior descending artery (left panel). A 3D MPS that demonstrates a small area of hypoperfusion at the apex (right panel, blue area). All other territories have normal perfusion (yellow/red areas), which corresponds to the final infarct size. Angiograms and MPSs courtesy of Professor Hans Erik Bøtker. ANT=anterior; INF=inferior; MPS=myocardial perfusion scintigram; PPCI=primary percutaneous coronary intervention; SEPT=septum

advantage of not affecting myocardial oxygen demand as much as dopamine does. However, the resulting tachycardia may preclude the use of this inotropic agent in some patients.

Dopamine is usually initiated at a rate of 5–10 mcg/kg/min intravenously, and the infusion rate is adjusted according to the blood pressure and other hemodynamic parameters. Often, patients may require high doses of dopamine (as much as 20 mcg/kg/min).

If the patient remains hypotensive despite moderate doses of dopamine, a direct vasoconstrictor (e.g. norepinephrine) should be started at a dose of 0.5 mcg/kg/min and titrated to maintain a MAP of 60 mmHg. The potent vasoconstrictors (e.g. norepinephrine) have traditionally been avoided because of their adverse effects on cardiac output and renal perfusion.

Vasopressor Supportive Therapy

The following is a brief review of the mechanism of action and indications for drugs used for hemodynamic support of cardiogenic shock.

Dopamine

Dopamine is a precursor of norepinephrine and epinephrine and has varying effects according to the doses infused. A dose of less than 5 mcg/kg/min causes vasodilation of renal, mesenteric, and coronary beds. At a dose of 5–10 mcg/kg/min, beta 1-adrenergic effects induce an increase in cardiac contractility and heart rate.

At doses of approximately 10 mcg/kg/min, alpha-adrenergic effects lead to arterial vasoconstriction and an elevation in blood pressure. The blood pressure increases primarily as a result of the inotropic effect. The undesirable effects are tachycardia and increased pulmonary shunting, as well as the potential for decreased splanchnic perfusion and increased pulmonary arterial wedge pressure.

Norepinephrine

Norepinephrine is a potent alpha-adrenergic agonist with minimal beta-adrenergic agonist effects. Norepinephrine can increase blood pressure successfully in patients who remain hypotensive following dopamine. The dose of norepinephrine may vary from 0.2–1.5 mcg/kg/min, and large doses, as high as 3.3 mcg/kg/min, have been used because of the alpha-receptor down-regulation in persons with sepsis.

Epinephrine

Epinephrine can increase the MAP by increasing the cardiac index and stroke volume, as well as systemic vascular resistance (SVR) and heart rate. Epinephrine decreases the splanchnic blood flow and may increase oxygen delivery and consumption.

Administration of this agent is associated with an increase in systemic and regional lactate concentrations. The use of epinephrine is recommended only in patients who are unresponsive to traditional agents. The undesirable effects are an increase in lactate concentration, a potential to produce myocardial ischemia, the development of arrhythmias, and a reduction in splanchnic flow.

Levosimendan

Levosimendan, though not approved for use in the United States, can be considered for use in conjunction with vasopressors. It should be used with caution, however, as it can cause hypotension. Used with vasopressors, levosimendan may improve hemodynamics and improve coronary blood flow.

Inotropic Supportive Therapy

Dobutamine

Dobutamine (sympathomimetic agent) is a beta1-receptor agonist, although it has some beta2-receptor and minimal alpha-receptor activity. Intravenous dobutamine induces significant positive inotropic effects, with mild chronotropic effects. It also induces mild peripheral vasodilation (decrease in afterload). The combined effect of increased inotropy and decreased afterload induces a significant increase in cardiac output.

In the setting of acute myocardial infarction (MI), dobutamine use could increase the size of the infarct because of the increase in myocardial oxygen consumption that may ensue. In general, avoid dobutamine in patients with moderate or severe hypotension (e.g. systolic blood pressure < 80 mmHg) because of the peripheral vasodilation.

Phosphodiesterase Inhibitors

Phosphodiesterase inhibitors (PDIs), which include inamrinone (formerly amrinone) and milrinone, are inotropic agents with vasodilating properties and long half-lives. The hemodynamic properties of PDIs are—(1) a positive inotropic effect on the myocardium and peripheral vasodilation (decreased afterload) and (2) a reduction in pulmonary vascular resistance (decreased preload).

PDIs are beneficial in persons with cardiac pump failure, but they may require concomitant vasopressor administration. Unlike catecholamine inotropes, these drugs are not dependent on adrenoreceptor activity; therefore, patients are less likely to develop tolerance to these medications.

PDIs are less likely than catecholamines to cause adverse effects known to be associated with adrenoreceptor activity (e.g. increased myocardial oxygen demand, myocardial ischemia). They are also associated with less tachycardia and myocardial oxygen consumption. However, the incidence of tachyarrhythmias is greater with PDIs than with dobutamine.

Thrombolytic Therapy

Although thrombolytic therapy (TT) reduces mortality rates in patients with acute myocardial infarction (MI), its benefits for patients with cardiogenic shock secondary to MI are disappointing. When used early in the course of MI, TT reduces the likelihood of subsequent development of cardiogenic shock after the initial event.

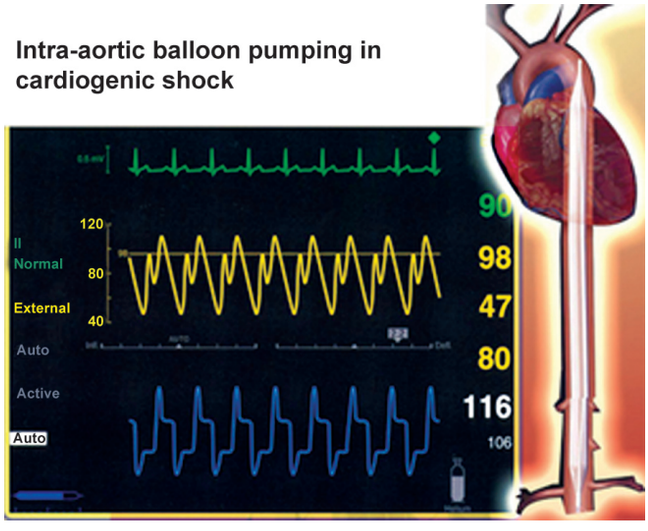

Fig. 21.34: Simultaneous ECG and aortic systolic and diastolic pulsations seen on the monitor screen in a patient before PCI

Similarly, other studies employing a tissue plasminogen activator did not show reductions in mortality rates from cardiogenic shock. Lower rates of reperfusion of the infarct-related artery in patients with cardiogenic shock may help to explain the disappointing results from TT. Other reasons for the decreased efficacy of TT are the existence of hemodynamic, mechanical, and metabolic causes of cardiogenic shock that are unaffected by TT.

Thrombolytic Therapy Plus IABP

A prospective cohort study demonstrated the potential survival benefit of combining TT with IABP counterpulsation in patients with MI complicated by cardiogenic shock.

Patients in cardiogenic shock who were treated with TT had lower in-hospital mortality rates than did those who did not receive TT (54% vs 64%), and patients selected for IABP counterpulsation had lower in-hospital mortality rates than did those who did not receive IABP counterpulsation (50% vs 72%).

Furthermore, a significant difference was noted in inhospital mortality rates among the four treatment groups, i.e. TT plus IABP counterpulsation (47%), IABP counterpulsation only (52%), TT only (63%), no TT and no IABP counterpulsation (77%).

Revascularization influenced in-hospital mortality rates significantly (39% with revascularization vs 78% without revascularization).

Patients who are unsuitable for invasive therapy should be treated with a thrombolytic agent in the absence of contraindications. This is a class I recommendation by American College of Cardiology (ACC)/American Heart Association (AHA) guidelines.

Different Techniques of Resuscitation in Cardiogenic Shock (Figs 21.34–21.37)

- Intra-aortic balloon pump
- Enhanced external counterpulsation (EECP) therapy
- Venoarterial extracorporeal membrane oxygenation (ECMO)

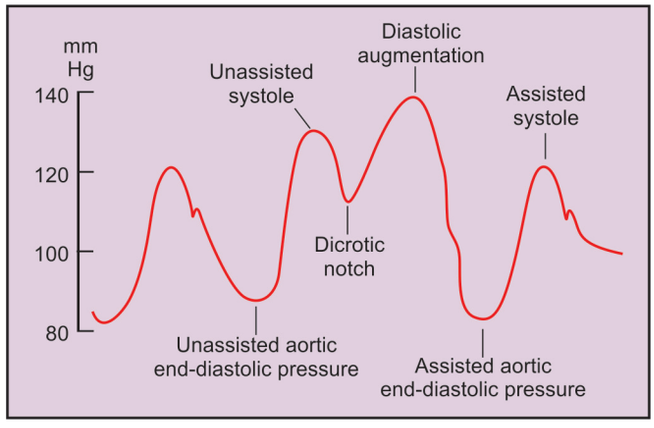

Fig. 21.35: Aortic systolic and diastolic pulsations after insertion of intra-aortic balloon pump

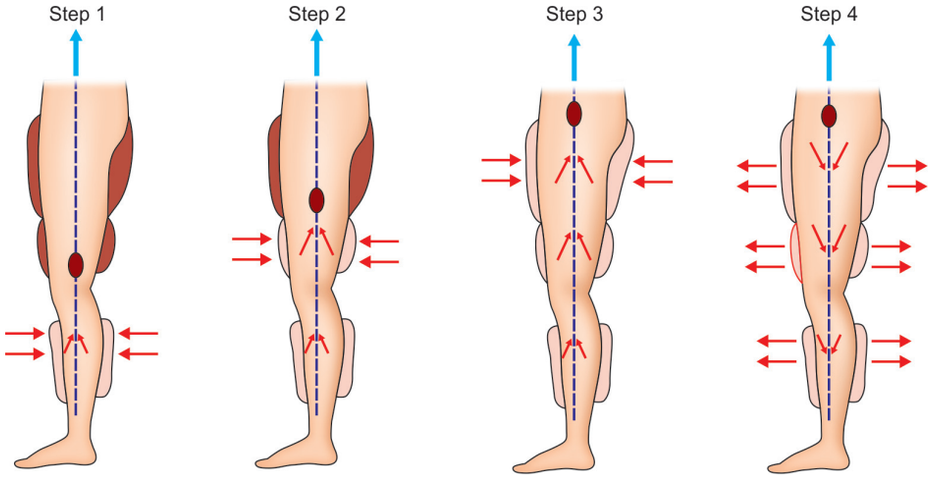

Fig. 21.36: Technique of EECP. Three pairs of pneumatic cuffs are applied to the calves, lower thighs, and upper thighs. The cuffs are inflated sequentially during diastole, distal to proximal. The compression of the lower-extremity vascular bed increases diastolic pressure and flow and increases venous return. The pressure is then released at the onset of systole. Inflation and deflation are timed according to the R-wave on the patient's cardiac monitor. The pressures applied and the inflation-deflation timing can be altered by using the pressure waveforms and electrocardiogram on the enhanced external counterpulsation (EECP) therapy monitor

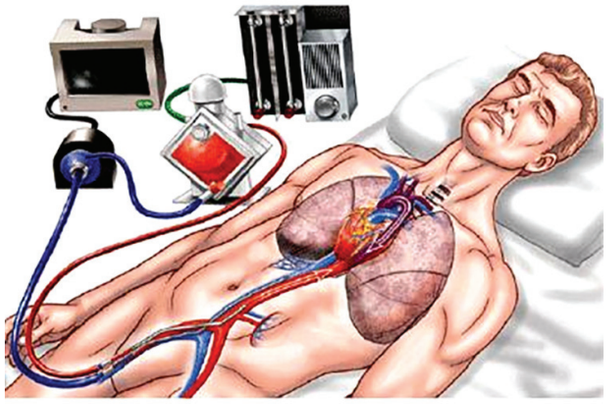

Fig. 21.37: Femoral venoarterial ECMO. When extracorporeal membrane oxygenation (ECMO) is implemented via femoral venous drainage and femoral arterial return in patients with residual native cardiac function and impaired lung function, reinfused oxygenated blood (red arrow), flowing retrograde through the aorta, may meet resistance from poorly oxygenated blood flowing antegrade from the left ventricle (purple arrow). Depending on the amount of cardiac function, the location of the interface between antegrade and retrograde flow will vary, and the reinfused oxygenated blood may not reach the cerebral and coronary vascular beds

- Implantable cardioverter-defibrillator (ICD) shock therapy in life-threatening cardiac arrhythmia

Intra-aortic Balloon Pump

The use of the IABP reduces systolic left ventricular afterload and augments diastolic coronary perfusion pressure, thereby increasing cardiac output and improving coronary artery blood flow. The IABP is effective for the initial stabilization of patients with cardiogenic shock. However, an IABP is not definitive therapy; the IABP stabilizes patients so that definitive diagnostic and therapeutic interventions can be performed.

The IABP also may be a useful adjunct to thrombolysis for initial stabilization and transfer of patients to a tertiary care facility. Some studies have shown lower mortality rates in patients with myocardial infarction (MI) and cardiogenic shock treated with an IABP and subsequent revascularization, as previously mentioned.

Complications may be documented in up to 30% of patients who undergo IABP therapy; these relate primarily to local vascular problems, embolism, infection, and hemolysis.

The impact of treatment with an IABP on long-term survival is controversial and depends on the patient's hemodynamic status and the aetiology of the cardiogenic shock. Patient selection is the key issue; inserting the IABP early, rather than waiting until full-blown cardiogenic shock has developed, may result in clinical benefit.

Ramanathan et al. found that rapid and complete reversal of systemic hypoperfusion with IABP counterpulsation in the SHOCK trial and SHOCK registry was independently associated with improved inhospital, 30-day, and 1-year survival, regardless of early revascularization. This suggests that complete reversal of systemic hypoperfusion with IABP counterpulsation is an important early prognostic feature.

In the IABP-SHOCK II study, 600 patients with cardiogenic shock complicating acute myocardial infarction were randomized to intraaortic balloon counterpulsation or no intraaortic balloon counterpulsation. All patients were expected to undergo early revascularization. Use of intraaortic balloon counterpulsation did not significantly reduce 30-day mortality in these patients.

Ventricular Assist Devices

In recent years, left ventricular assist devices (LVADs) capable of providing complete short-term hemodynamic

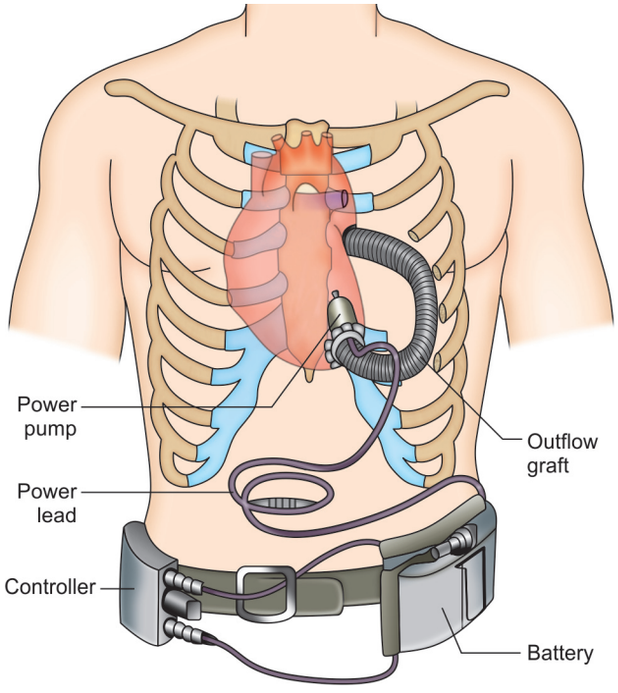

Fig. 21.38: Intracorporeal left ventricular assist device and its components

support have been developed. The application of LVAD during reperfusion, after acute coronary occlusion, causes reduction of the left ventricular preload, increases regional myocardial blood flow and lactate extraction, and improves general cardiac function. The LVAD makes it possible to maintain the collateral blood flow as a result of maintaining the cardiac output and aortic pressure, keeping wall tension low and reducing the extent of microvascular reperfusion injury (Figs 21.38 and 21.39).

A pooled analysis from 17 studies showed that the mean age of this group of patients with LVADs was 59.5 ± 4.5 years and that mean support duration was 146.2 ± 60.2 hours. In 78.5% of patients (range, 53.8–100%), adjunctive reperfusion therapy, mainly percutaneous transluminal coronary angioplasty (PTCA), was used. Mean weaning and survival rates were 58.5% (range, 46–75%) and 40% (range, 29–58%), respectively

In any case, comparing studies is difficult because important data are usually missing, mean age of patients were different, and time to treatment is not standardized.

Hemodynamic presentation seems to be worse compared with data reported in the SHOCK trial, with lower cardiac index, lower systolic aortic pressure, and higher serum lactates. Taking these considerations into account, LVAD support seems to give no survival improvement in patients with cardiogenic shock complicating acute myocardial infarction (MI), compared with early reperfusion alone or in combination with IABP.

In a randomized, controlled trial in which 129 patients with end-stage heart failure who were ineligible for cardiac transplantation were assigned either to receive an LVAD (68 patients) or to undergo optimal medical management, survival rates were higher in the LVAD group. The rates of survival at 1 year were 52% in the device group and 25% in the medical therapy group, while the rates at 2 years were 23% and 8%, respectively. In addition, the quality of life was significantly improved at 1 year in the device group.

Implantable LVADs are being used as a bridge to heart transplantation for patients with acute MI and cardiogenic shock. According to the HeartMate Data Registry, from 1986–1998, 41 patients (5% of the total number of HeartMate IP patients) were supported with this implantable pneumatic device for acute MI, and 25 (61%) were successfully bridged to heart transplantation.

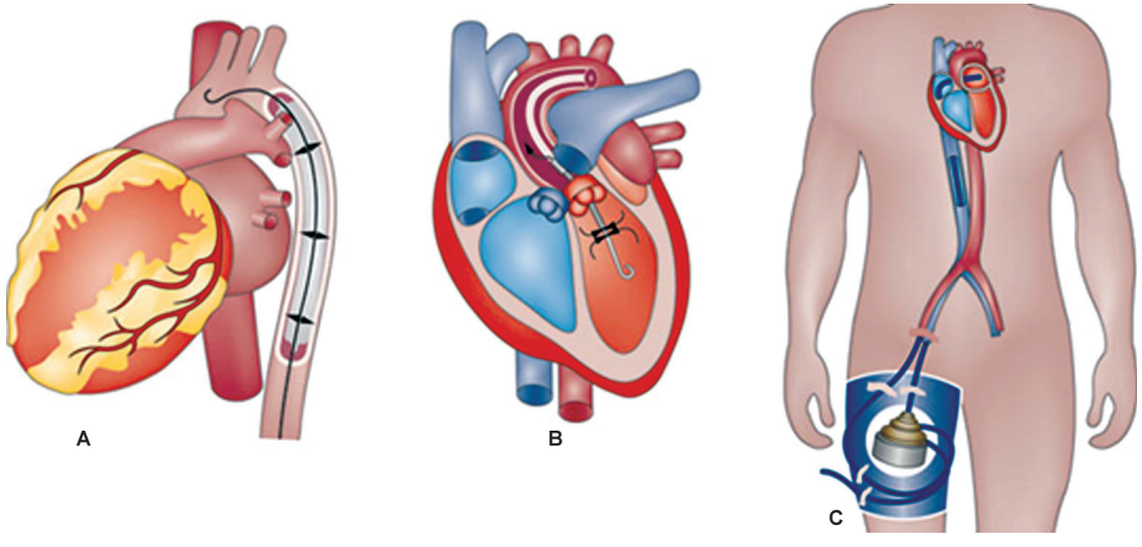

Fig. 21.39: These illustrations (a, b and c) are used either early and long-term accordingly in the management of cardiogenic shock

However, LVADs as a bridging option for patients with cardiogenic shock must be considered cautiously and must be avoided in patients who are unlikely to survive or are not likely to be transplant candidates. Further investigations are required to better define indications, support modalities, and outcomes (Fig. 21.40).

The indications for insertion of a ventricular assist device are controversial. Such an aggressive approach to support the circulatory system in cardiogenic shock is appropriate (1) after the failure of medical treatment and an IABP, (2) when the cause of cardiogenic shock is potentially reversible, or (3) if the device can be used as a support measure.

Percutaneous Transluminal Coronary Angioplasty

The retrospective and prospective data favor aggressive mechanical revascularization in patients with cardiogenic shock secondary to myocardial infarction (MI) (Fig. 21.41).

Re-establishing blood flow in the infarct-related artery may improve left ventricular function and survival following MI. In acute MI, studies show that percutaneous transluminal coronary angioplasty (PTCA) can achieve adequate flow in 80–90% of patients, compared with 50–60% of patients after thrombolytic therapy (TT).

Several retrospective clinical trials have shown that patients with cardiogenic shock due to myocardial ischemia benefitted (reduction in 30d mortality rates) when treated with angioplasty. A study of direct (primary) PTCA in patients with cardiogenic shock reported lower mortality rates in patients treated with angioplasty combined with the use of stents than in patients treat with medical therapy.



Fig. 21.40: The Jarvik 2000. Heart is an axial flow blood pump that uses electrical power to rotate a vaned impeller—it's only moving part. The device is 2.5 cm wide, 5.5 cm long, and weighs 85 grams. The impeller is a neodymium-iron-boron magnet, which is housed inside a welded titanium shell. The impeller is supported by ceramic bearings. A small cable, which exits the body through the abdominal wall, delivers power to the impeller. All of the blood-contacting surfaces are made of highly polished titanium. The normal operating range for the control system is 8,000–12,000 revolutions per minute, which will generate an average pump flow rate of 5 liters per minute

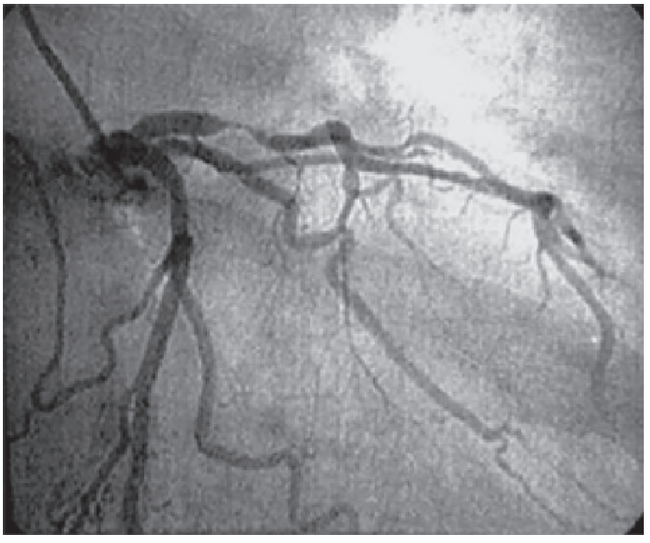

Fig. 21.41: A patient with an acute anterolateral myocardial infarction who developed cardiogenic shock. Coronary angiography images showed severe stenosis of the left anterior descending coronary artery, which was dilated by percutaneous transluminal coronary angioplasty

A study by Antoniucci et al. found that mortality rates increase in relation to the length of time to treatment in patients with acute MI who are not considered to be at low risk. To study the relationship of time to treatment and mortality in patients with acute MI, a series of 1336 patients who underwent successful primary PTCA were stratified into low-risk and not–low risk patient groups. The 6-month mortality rate was 9.3% for not low risk patients and 1.3% for the low-risk patients. An increase in the mortality rate from 4.8–12.9% with increasing time to reperfusion was observed in the not low-risk group. A delay from symptom onset to treatment resulted in higher mortality rates for the not low-risk patients.

CORONARY ARTERY BYPASS GRAFTING

Critical left main artery disease and 3-vessel coronary artery disease are common findings in patients who develop cardiogenic shock. The potential contribution of ischemia in the noninfarcted zone contributes to the deterioration of already compromised myocardial function (Fig. 21.42).

Coronary artery bypass grafting (CABG) in the setting of cardiogenic shock is generally associated with high surgical morbidity and mortality rates. Because the results of percutaneous interventions can be favorable, routine bypass surgery is often discouraged for these patients.

A 2004 task force of the ACC and the AHA gave a class I recommendation to the performance of primary PCI or emergent CABG in patients younger than 75 years who have STEMI who develop shock within 36 hours of myocardial infarction (MI) and can be treated within 18 hours of shock onset. Performance of primary PCI or emergent CABG was considered reasonable in patients older than 75 years (class IIa recommendation).

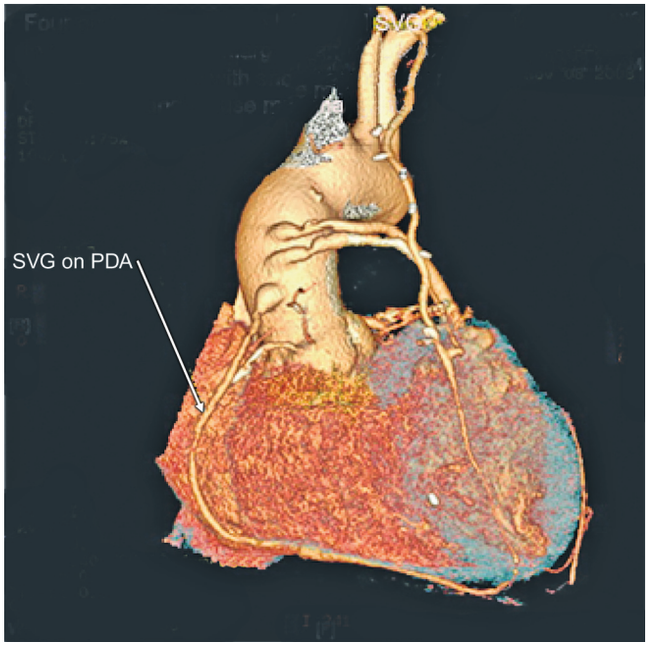

Fig. 21.42: Four grafts from LIMA to LAD, and SVG to diagonal, obtuse marginal and posterior descending artery with short segment stenosis of diagonal and obtuse marginal grafts

REVASCULARIZATION IN THE SHOCK TRIAL

Results from the SHOCK trial supported the superiority of a strategy that combines early revascularization with medical management in patients with cardiogenic shock. In the study, patients were assigned to receive either optimal medical management, including an IABP and TT, or cardiac catheterization followed by revascularization using PTCA or CABG.

The mortality rates at 30 days were 46.7% in the early intervention group and 56% in patients treated with optimal medical management. Although these 30-day results did not reach statistical significance, the mortality rate at 6 months was significantly lower in the early intervention group (50.3% vs 63.1%)

The 1-year survival rates were also reported from the SHOCK trial. The survival rate at 1-year was 46.7% for patients in the early revascularization group and 33.6% in the conservative management group. The treatment benefit was apparent only for patients younger than 75 years (51.6% survival rate in early revascularization group vs 33.3% in patients treated with optimal medical management).

Based on the outcome of this study, the recommendation is that patients with acute myocardial infarction (MI) complicated by cardiogenic shock, particularly those younger than 75 years, should be rapidly transferred to a center with personnel capable of performing early angiography and revascularization procedures.

PATIENT TRANSFER

Immediately transfer a patient who develops cardiogenic shock to an institution at which invasive monitoring, coronary revascularization, and skilled personnel are available to provide expert care.

Patients with cardiogenic shock who are admitted to a hospital without facilities for revascularization should be immediately transferred to a tertiary care center with such facilities. If time to PCI is more than 1 hour and onset of symptoms has been within 3 hours, rapid administration of TT is recommended.

It should be kept in mind, however, that attempts to transfer a patient with cardiogenic shock must be made only when everything possible has been done to stabilize his or her condition and when the level of care during the transfer will not significantly decrease.

SUMMARY

Cardiogenic shock continues to be the most common cause of death in patients hospitalized with acute myocardial infarction. It has also been frequently associated with ST-segment elevation myocardial infarction (STEMI) and patients with comorbidities. Cardiogenic shock presents with low systolic blood pressure and clinical signs of hypoperfusion. Rapid diagnosis and supportive therapy in the form of medications, airway support and intra-aortic balloon counterpulsation is required. Initial stabilization can be followed by reperfusion by fibrinolytic therapy, emergent percutaneous intervention (PCI) or coronary artery bypass grafting (CABG). The latter two have been found to decrease mortality in the long term. Research is being carried out on the role of inflammatory mediators in the clinical manifestation of cardiogenic shock. Mechanical support devices also show promise in the future.

KEY POINTS

1. Cardiogenic shock due to AMI continues to be the main cause of death in these patients.
2. Immediate diagnosis and management is required.
3. There are two strategies in treating cardiogenic shock: medical versus invasive.
4. If institutions lack revascularization facilities, fibrinolytic therapy and IABP should be used while provisions are made for invasive treatment.
5. However, current guidelines favor an invasive approach.
6. Prognosis is established by the outcome of revascularization regardless of the procedure used, such as PCI or surgery.
7. Newer devices are being developed for mechanical support. Inhibitors of nitric oxide have also shown favorable outcomes. These newer therapies may help in decreasing the significant mortality of cardiogenic shock in the future.

BIBLIOGRAPHY

1. Al-Reesi A, Al-Zadjali N, Perry J, Fergusson D, Al-Shamsi M, Al-Thagafi M, et al. Do beta-blockers reduce short-term mortality following acute myocardial infarction? A systematic review and meta-analysis. CJEM. 2008; 10(3): 215–23.

2. Babaev A, Frederick PD, Pasta DJ, Every N, Sichrovsky T, Hochman JS. Trends in management and outcomes of patients with acute myocardial infarction complicated by cardiogenic shock. JAMA 2005;294(4):448–54.
3. Chen ZM, Pan HC, Chen YP, Peto R, Collins R, Jiang LX, et al. Early intravenous then oral metoprolol in 45,852 patients with acute myocardial infarction: randomised placebo-controlled trial. Lancet 2005;366(9497):1622–32.
4. Cheng JM, den Uil CA, Hoeks SE, van der Ent M, Jewbali LS, van Domburg RT, et al. Percutaneous left ventricular assist devices vs. intra-aortic balloon pump counterpulsation for treatment of cardiogenic shock: a meta-analysis of controlled trials. Eur Heart J 2009;30(17):2102–8.
5. De Luca L, Colucci WS, Nieminen MS, Massie BM, Gheorghiade M. Evidence-based use of levosimendan in different clinical settings. Eur Heart J 2006;27(16):1908–20.
6. Ellender TJ, Skinner JC. The use of vasopressors and inotropes in the emergency medical treatment of shock. Emerg Med Clin North Am 2008;26(3):759–86.
7. Fox KA, Steg PG, Eagle KA, Goodman SG, Anderson FA Jr, Granger CB, et al. Decline in rates of death and heart failure in acute coronary syndromes, 1999–2006. JAMA 2007; 297(17):1892–900.
8. Fuhrmann JT, Schmeisser A, Schulze MR, Wunderlich C, Schoen SP, Rauwolf T, et al. Levosimendan is superior to enoximone in refractory cardiogenic shock complicating acute myocardial infarction. Crit Care Med 2008; 36(8): 2257–66.
9. Garatti A, Russo C, Lanfranconi M, Colombo T, Bruschi G, Trunfio S, et al. Mechanical circulatory support for cardiogenic shock complicating acute myocardial infarction: an experimental and clinical review. ASAIO J 2007;53(3): 278–87.
10. Goldberg RJ, Samad NA, Yarzebski J, Gurwitz J, Bigelow C, Gore JM. Temporal trends in cardiogenic shock complicating acute myocardial infarction. N Engl J Med 1999; 340(15): 1162–8.
11. Hamon M, Agostini D, Le Page O, Riddell JW, Hamon M. Prognostic impact of right ventricular involvement in patients with acute myocardial infarction: meta-analysis. Crit Care Med 2008;36(7):2023–33.
12. Hasdai D, Califf RM, Thompson TD, Hochman JS, Ohman EM, Pfisterer M, et al. Predictors of cardiogenic shock after thrombolytic therapy for acute myocardial infarction. J Am Coll Cardiol 2000;35(1):136–43.
13. Hochman JS, Sleeper LA, White HD, Dzavik V, Wong SC, Menon V, et al. One-year survival following early revascularization for cardiogenic shock. JAMA 2001; 285(2):190–2.
14. Jeger RV, Lowe AM, Buller CE, Pfisterer ME, Dzavik V, Webb JG, et al. Hemodynamic parameters are prognostically important in cardiogenic shock but similar following early revascularization or initial medical stabilization: a report from the SHOCK Trial. Chest 2007;132(6):1794–803.
15. Jeger RV, Radovanovic D, Hunziker PR, Pfisterer ME, Stauffer JC, Erne P, et al. Ten-year trends in the incidence and treatment of cardiogenic shock. Ann Intern Med 2008; 149(9):618–26.
16. Naples RM, Harris JW, Ghaemmaghami CA. Critical care aspects in the management of patients with acute coronary syndromes. Emerg Med Clin North Am 2008;26(3):685–702.
17. Ramanathan K, Farkouh ME, Cosmi JE, French JK, Harkness SM, D•avík V, et al. Rapid complete reversal of systemic hypo-per-fusion after intra-aortic balloon pump counterpulsation and survival in cardiogenic shock compli-cating an acute myocardial infarction. Am Heart J 2011; 162(2):268–75.
18. Reynolds HR, Hochman JS. Cardiogenic shock: current concepts and improving outcomes. Circulation 2008; 117(5):686–97.
19. Sanborn TA, Sleeper LA, Bates ER, et al. Impact of thrombolysis, intra-aortic balloon pump counterpulsation, and their combination in cardiogenic shock complicating acute myocardial infarction: a report from the SHOCK Trial Registry. SHould we emergently revascularize Occluded Coronaries for cardiogenic shocK?. J Am Coll Cardiol 2000;36(3 Suppl A):1123–9.
20. Shin TG, Choi JH, Jo IJ, Sim MS, Song HG, Jeong YK, et al. Extracorporeal cardiopulmonary resuscitation in patients with inhospital cardiac arrest: A comparison with conventional cardiopulmonary resuscitation. Crit Care Med 2011;39(1):1–7.